

## Bones of lower limb

### Identify the following

#### **I- Hip**

##### **Ilium**

1. Anterior superior iliac spine
2. Posterior superior iliac spine
3. Anterior inferior iliac spine
4. Posterior inferior iliac spine
5. Iliac crest
6. Gluteal surface of ilium and gluteal lines (Posterior gluteal , Anterior (middle) gluteal and Inferior gluteal lines)
7. Iliac fossa
8. Iliac tuberosity
9. Auricular articular surface
10. Arcuate line

##### **Ischium**

11. Greater sciatic notch
12. Lesser sciatic notch
13. Ischial tuberosity
14. Ischial spine
15. Ischial ramus

##### **Pubic**

16. Body of pubis
17. Pubic tubercle and crest
18. Superior pubic ramus
19. Inferior pubic ramus
20. Pectineal line
21. Obturator Foramen
22. Ischiopubic ramus
23. Acetabulum

## **II-Femur**

### **Upper end**

1. Head
2. Fovea of head
3. Neck
4. Greater trochanter
5. Lesser Trochanter
6. Intertrochanteric line
7. Intertrochanteric crest

### **Shaft**

8. Linea aspera
9. Gluteal tuberosity
10. Spiral line

### **Lower End**

11. Medial and lateral supracondylar lines
12. Medial and Lateral condyle
13. Medial and Lateral epicondyle
14. Adductor tubercle
15. Intercondylar area

**The University Of Jordan  
Faculty Of Medicine**

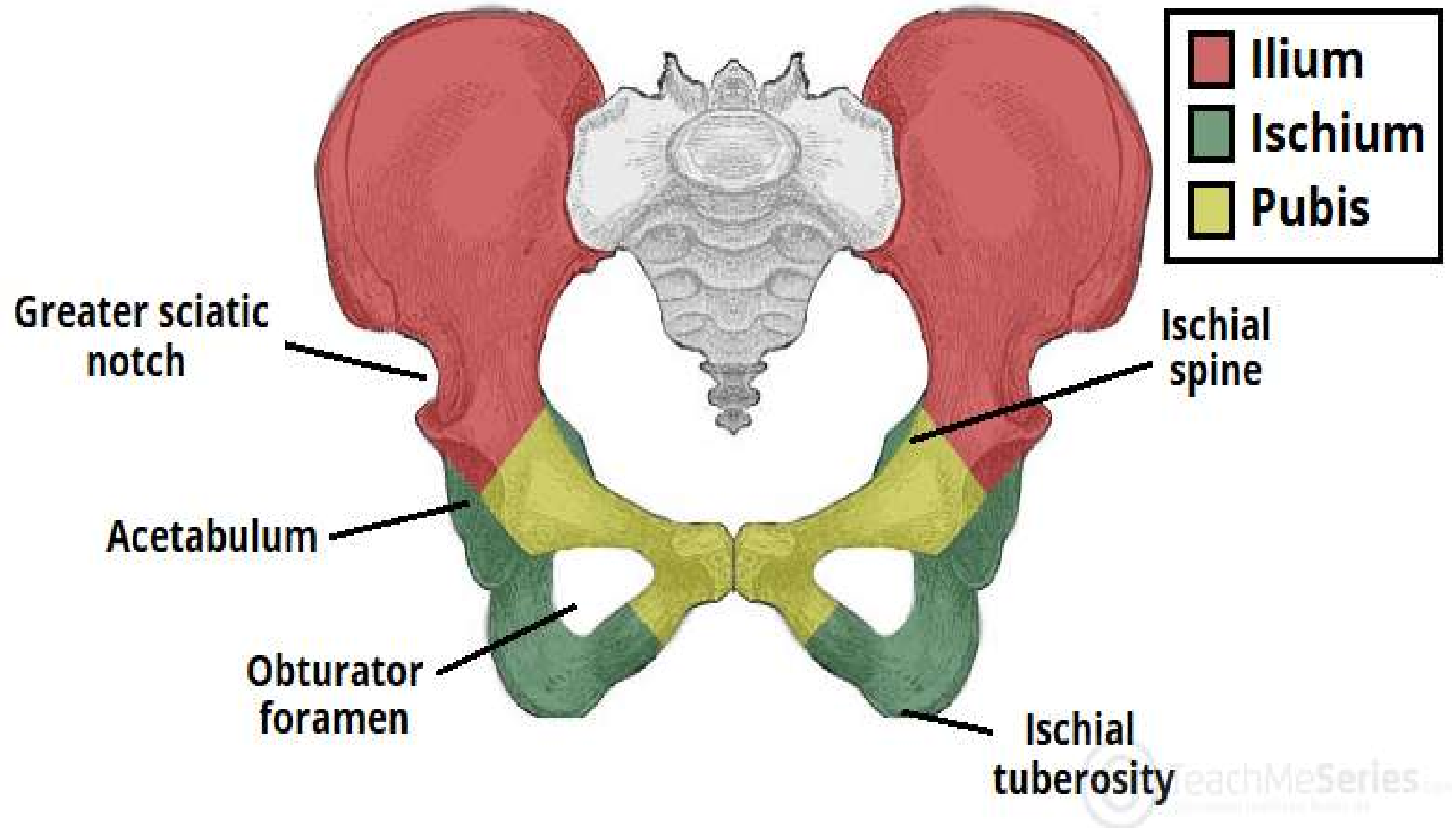


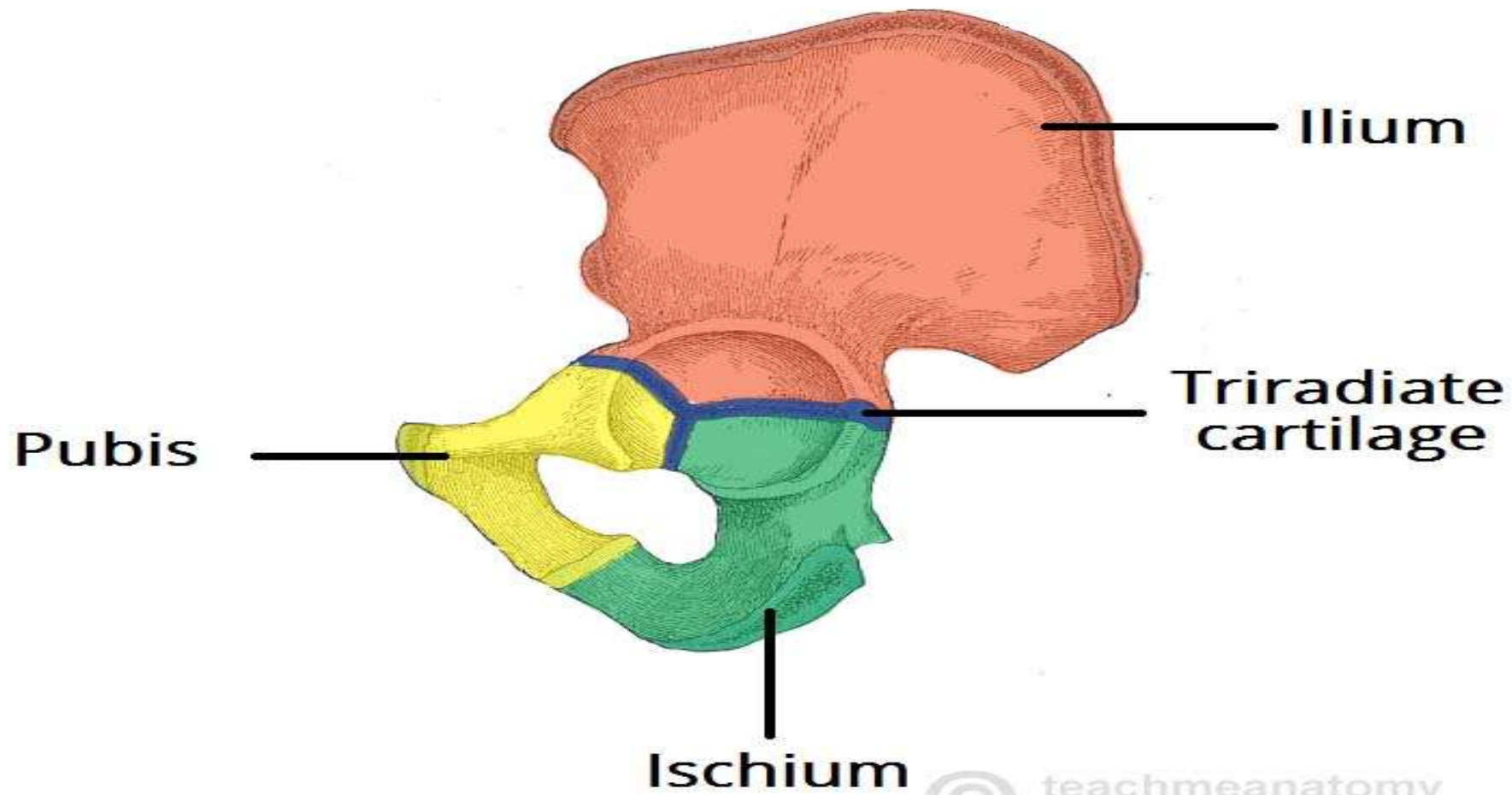
# Hip Bone and Femur

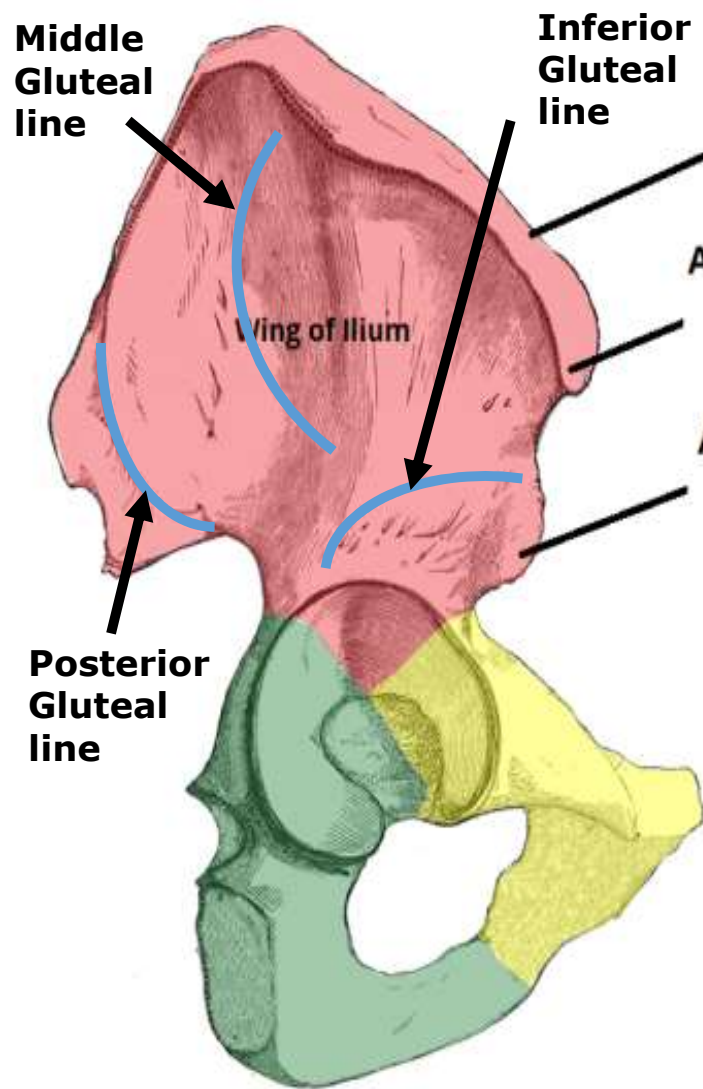
**Dr.Ahmed Salman**

Associate Professor of Anatomy

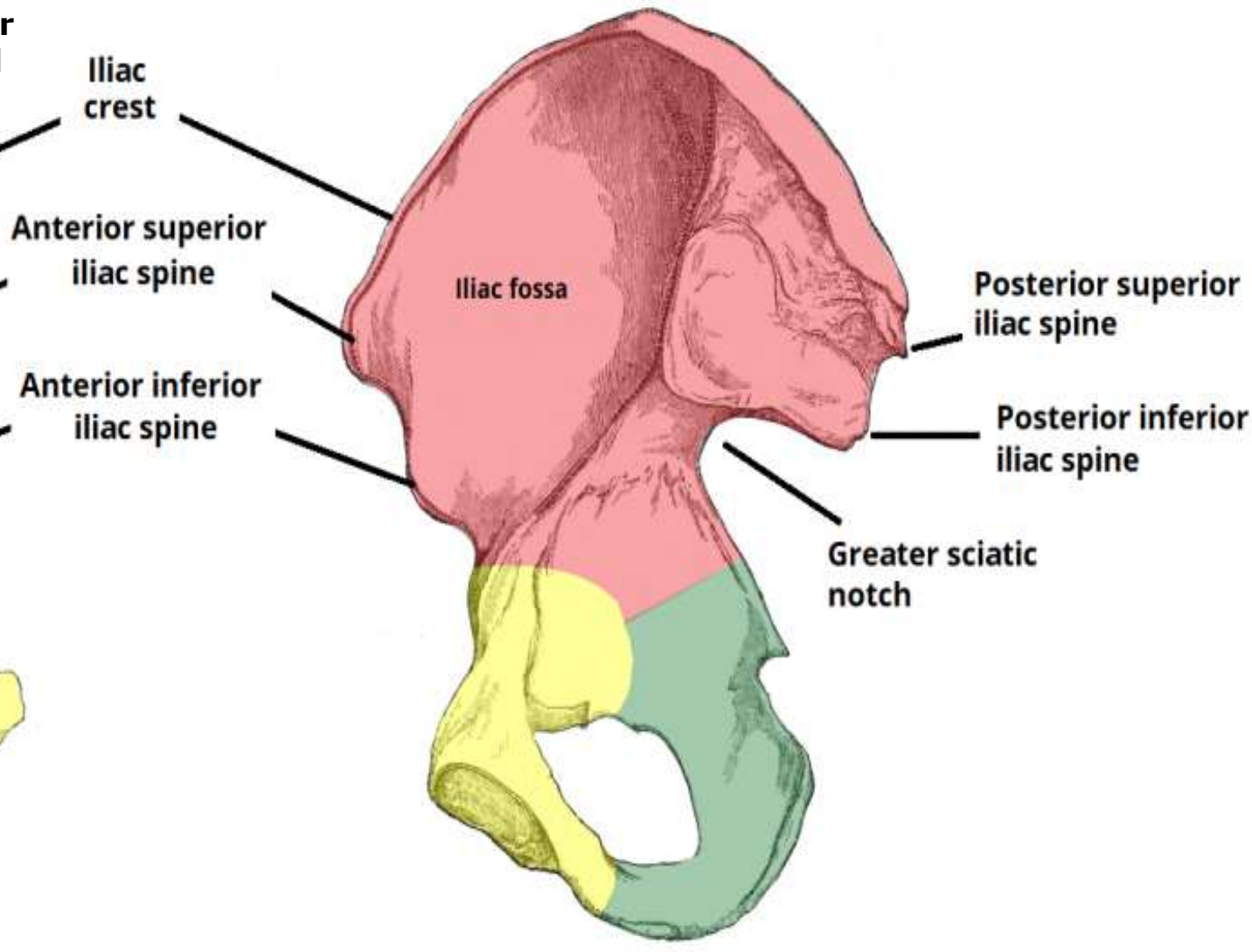
# Hip Bone



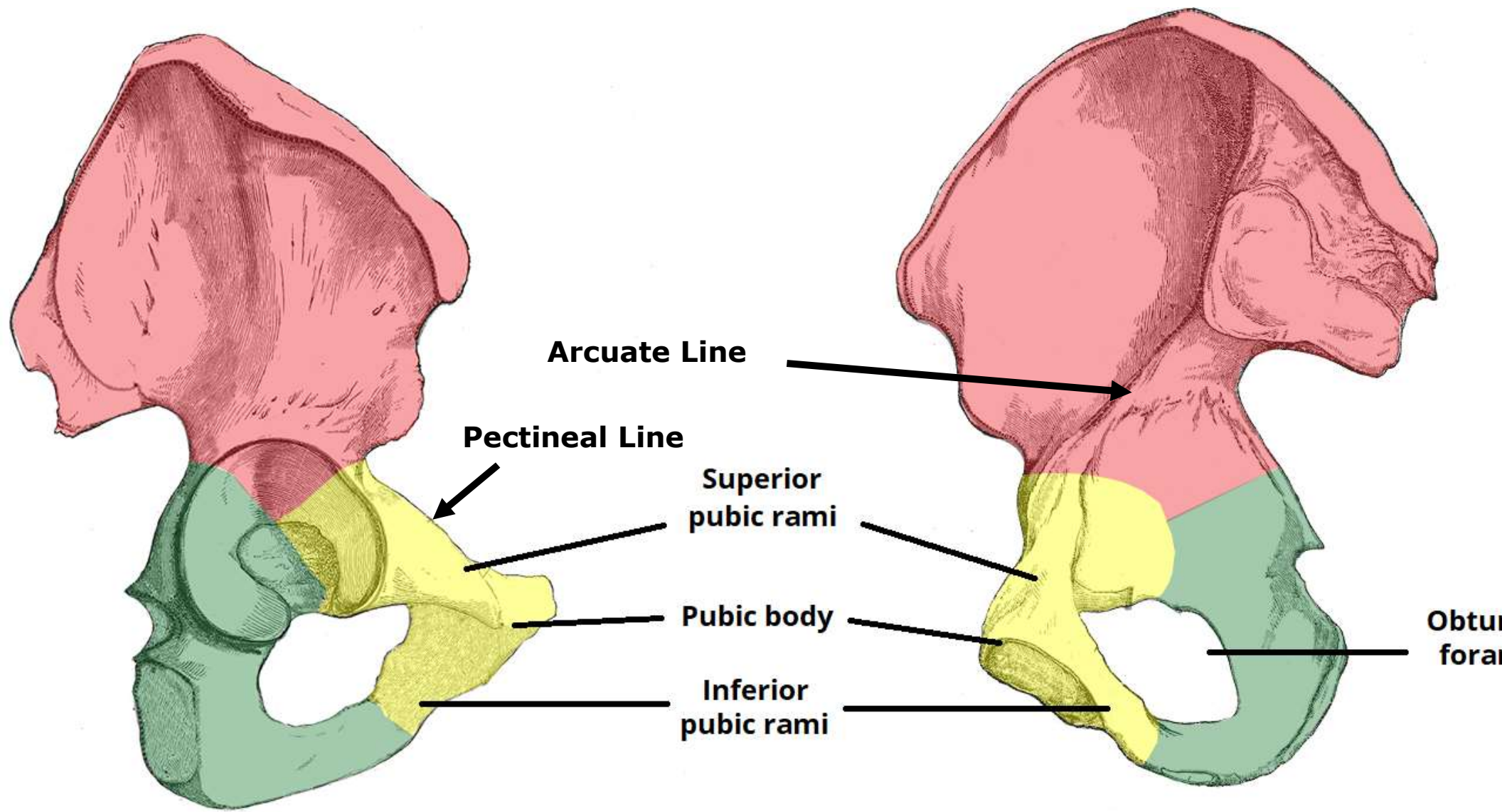




**(i) Lateral View**



**(ii) Medial View**



**Arcuate Line**

**Pectineal Line**

**Superior  
pubic rami**

**Pubic body**

**Inferior  
pubic rami**

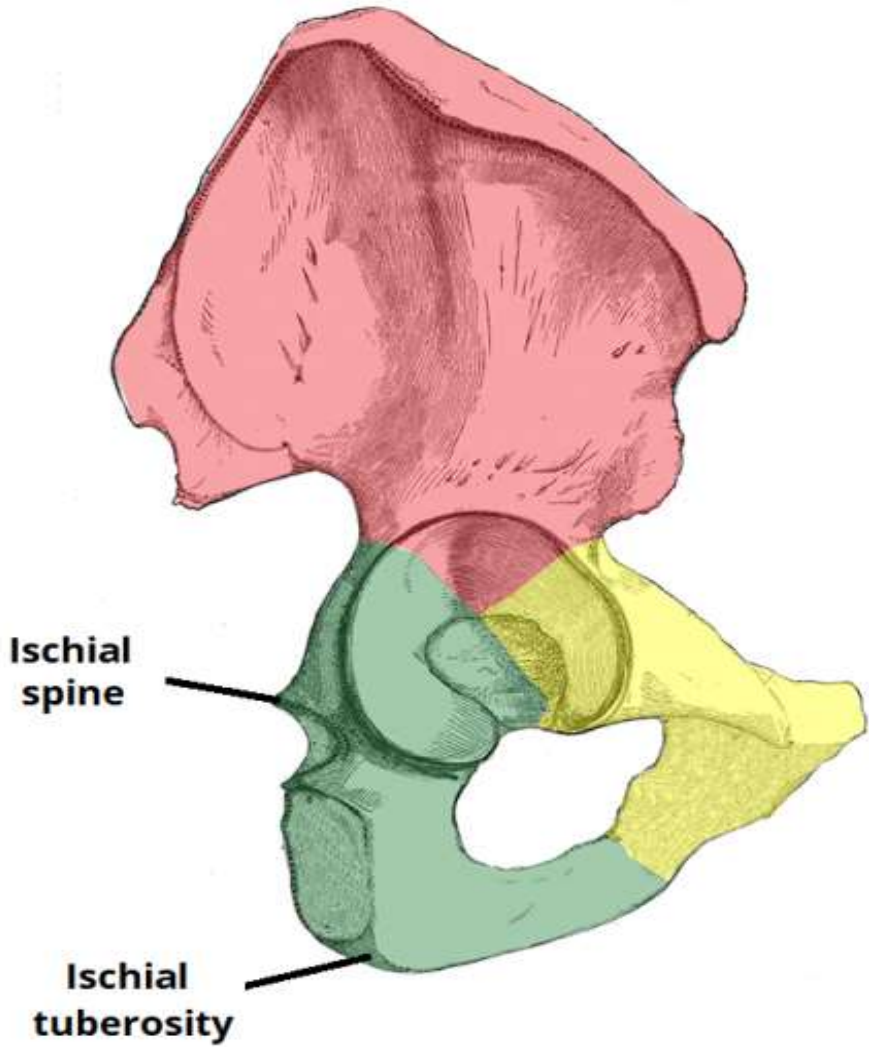
**Obturator  
foramen**

**(i) Lateral View**

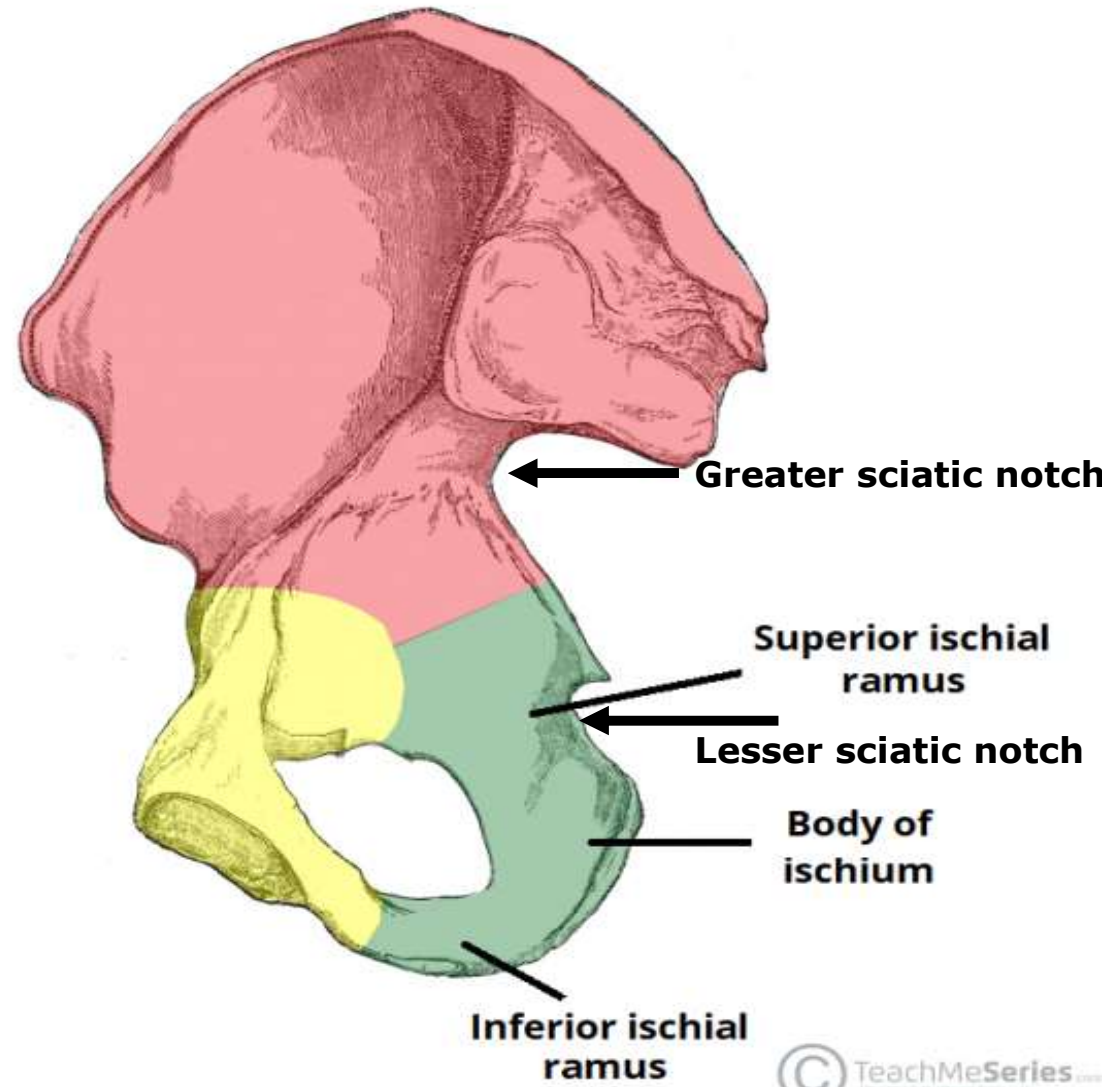
**(ii) Medial View**



**(i) Lateral View**



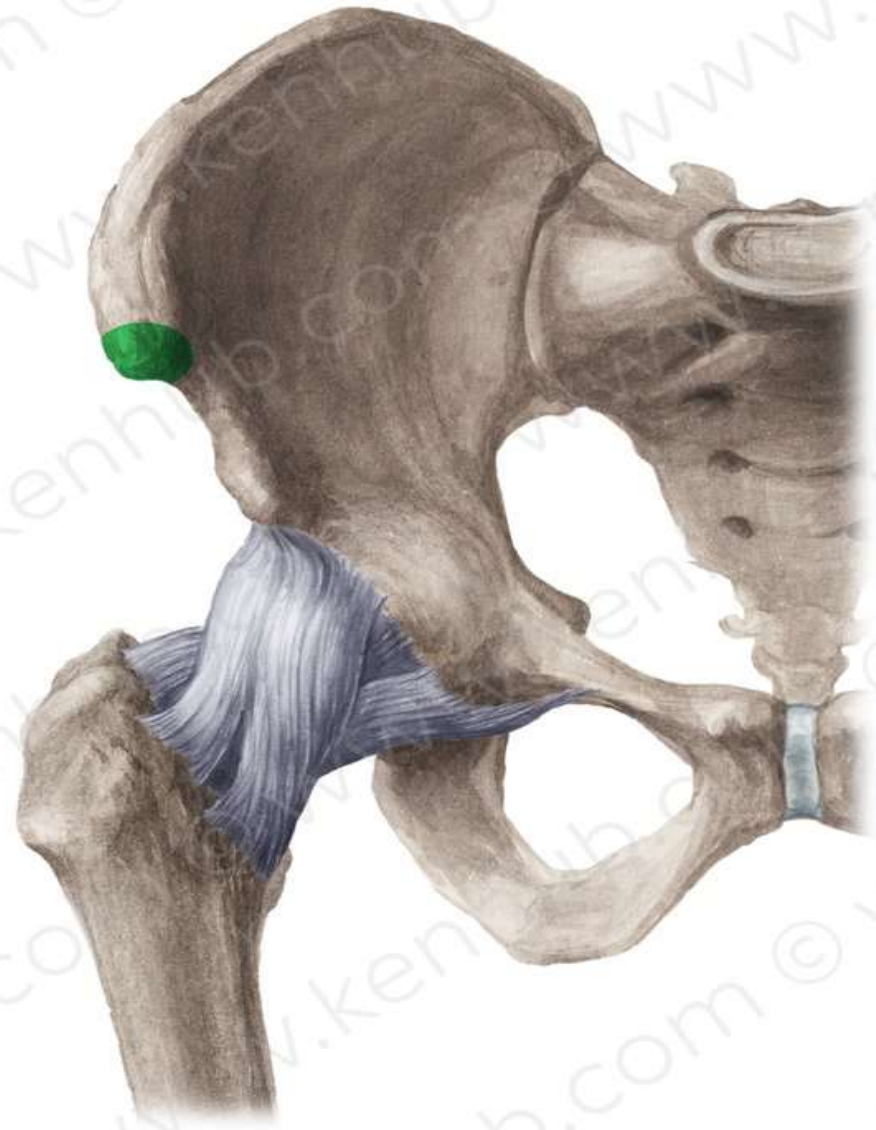
**(ii) Medial View**



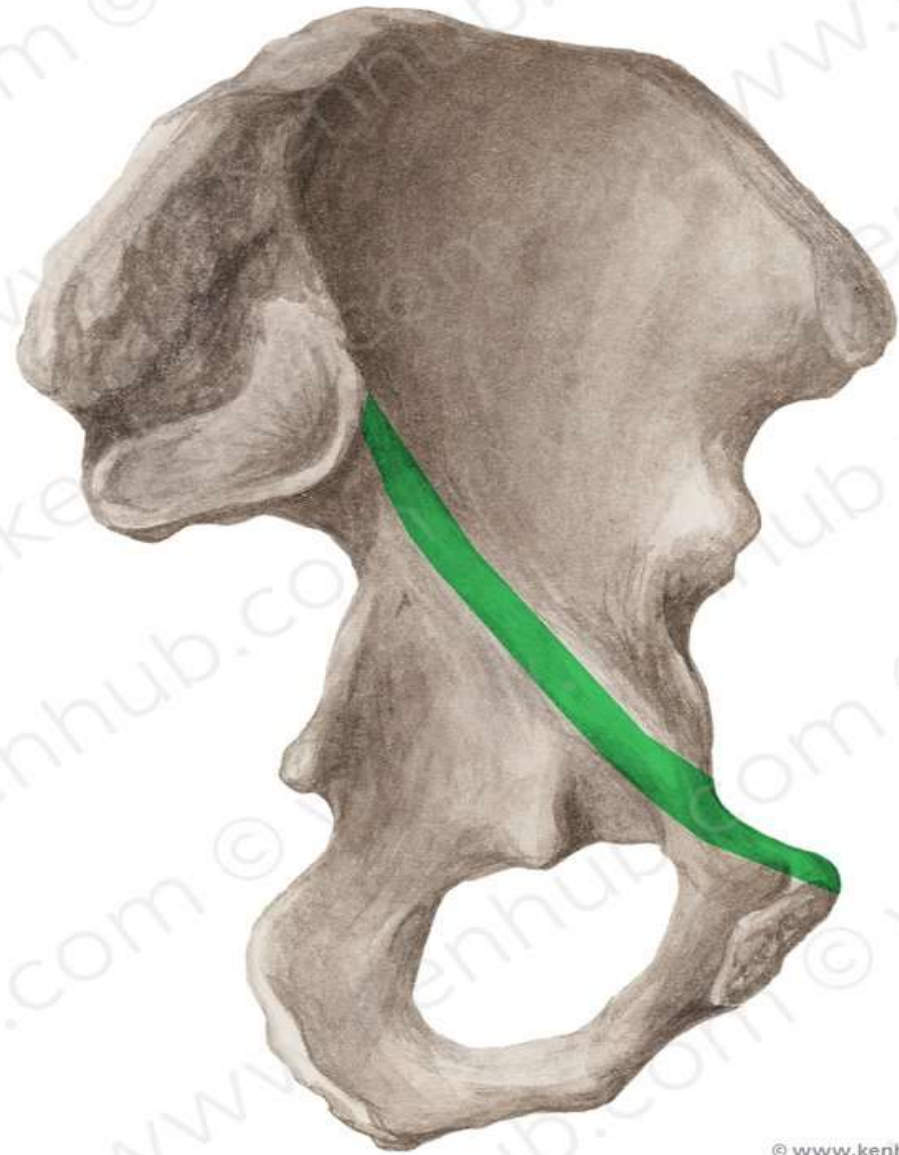


**TEST YOUR KNOWLEDGE**

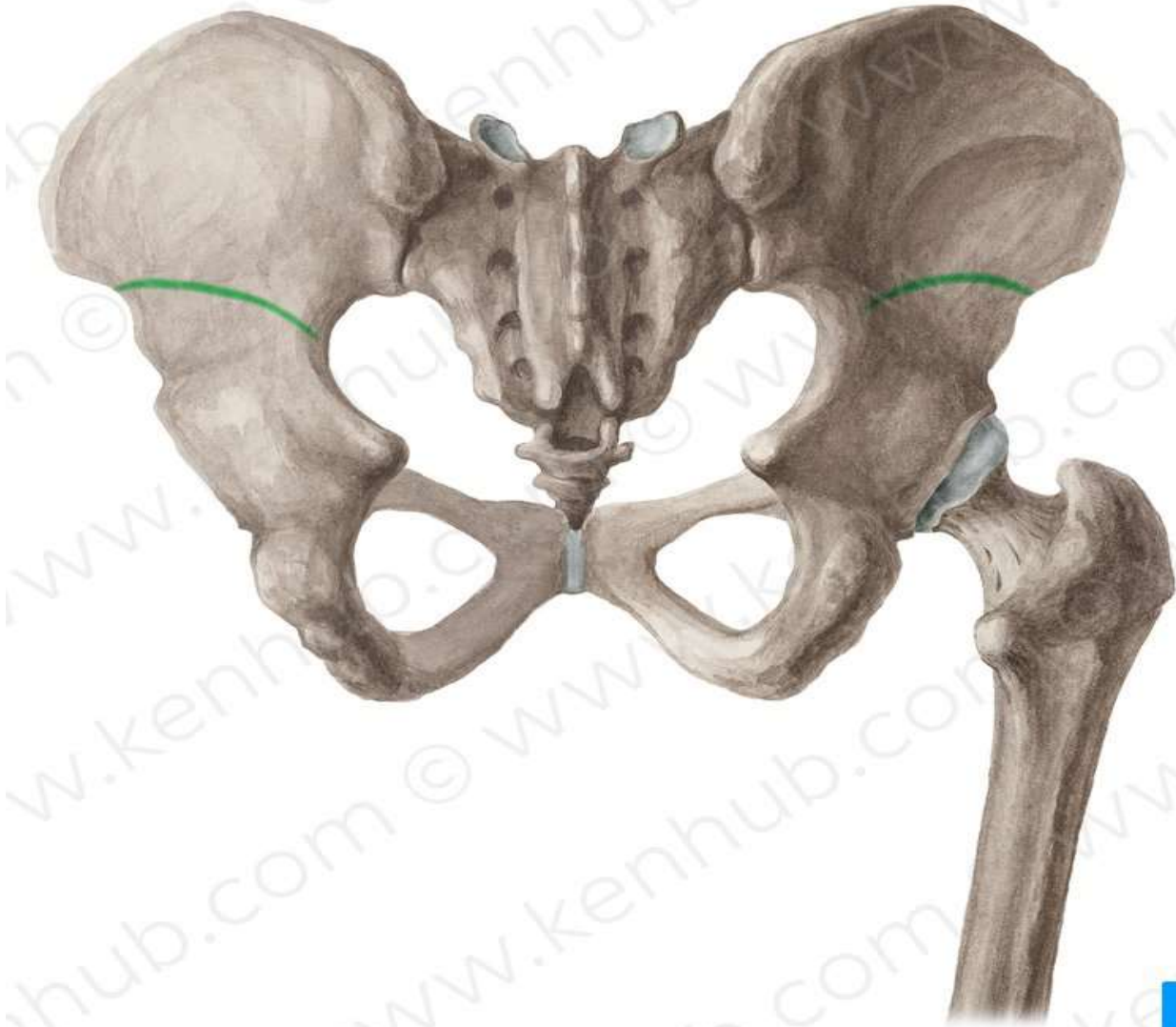
## Anterior superior iliac spine



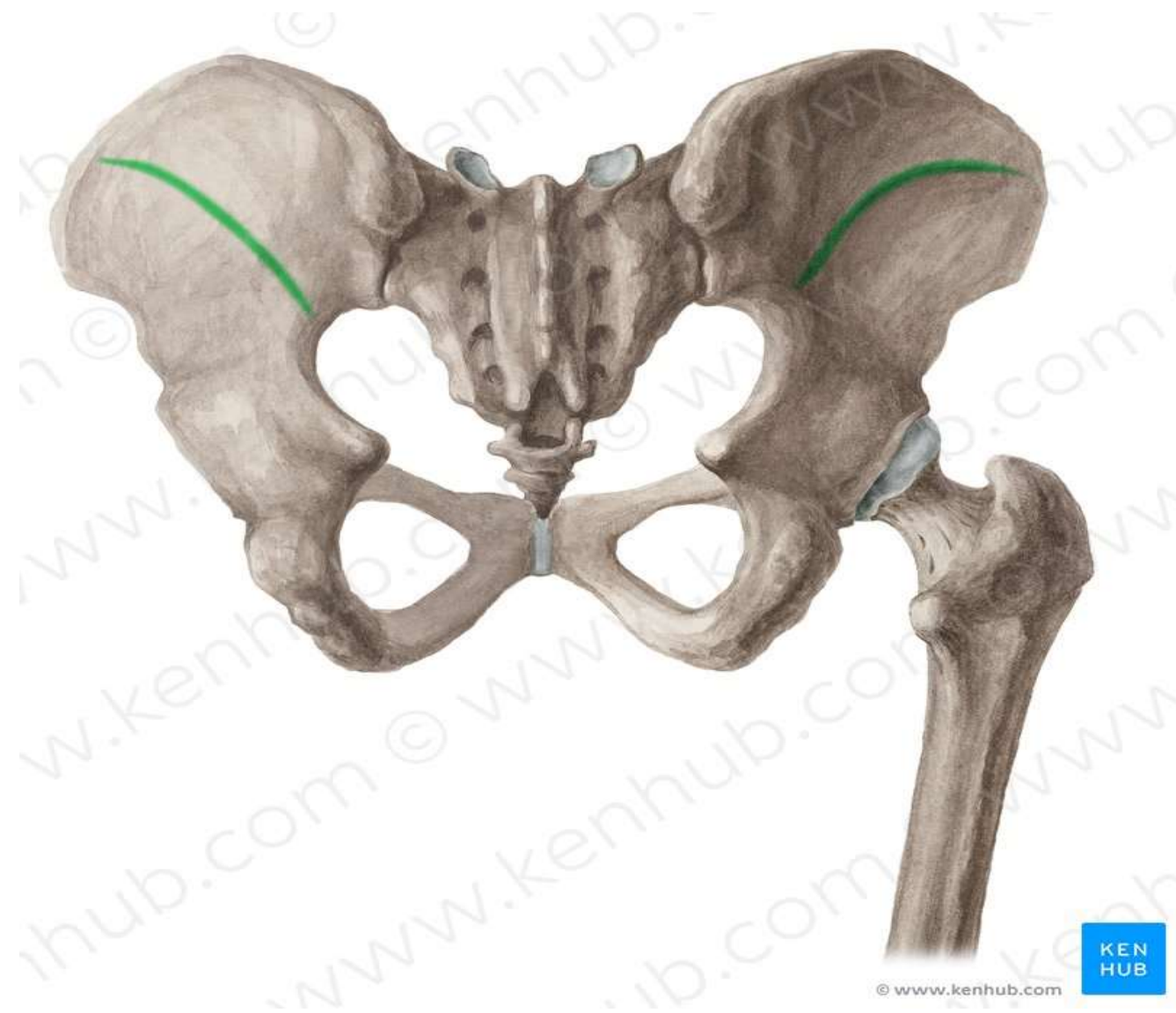
## Arcuate line



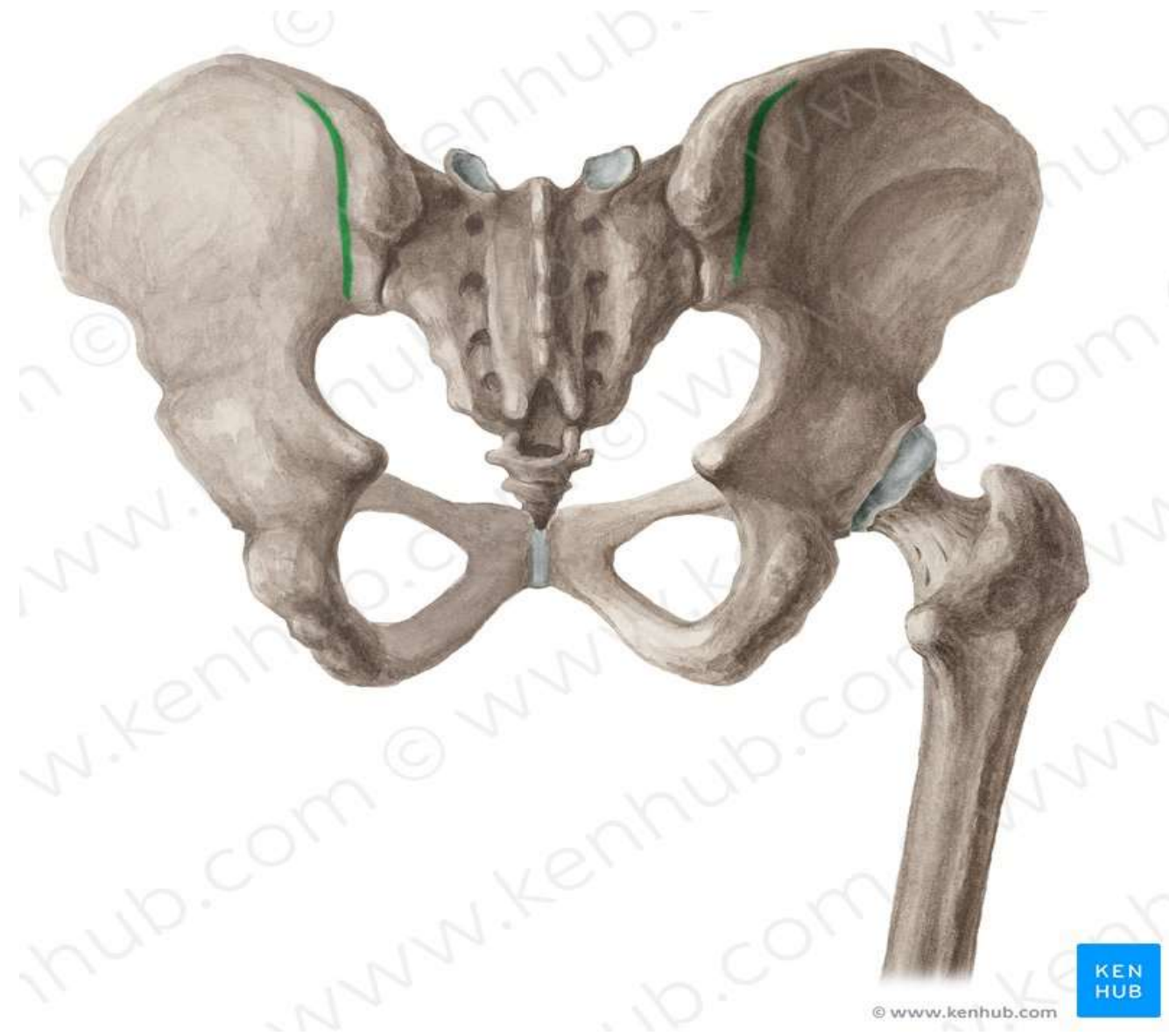
**Inferior Gluteal line**



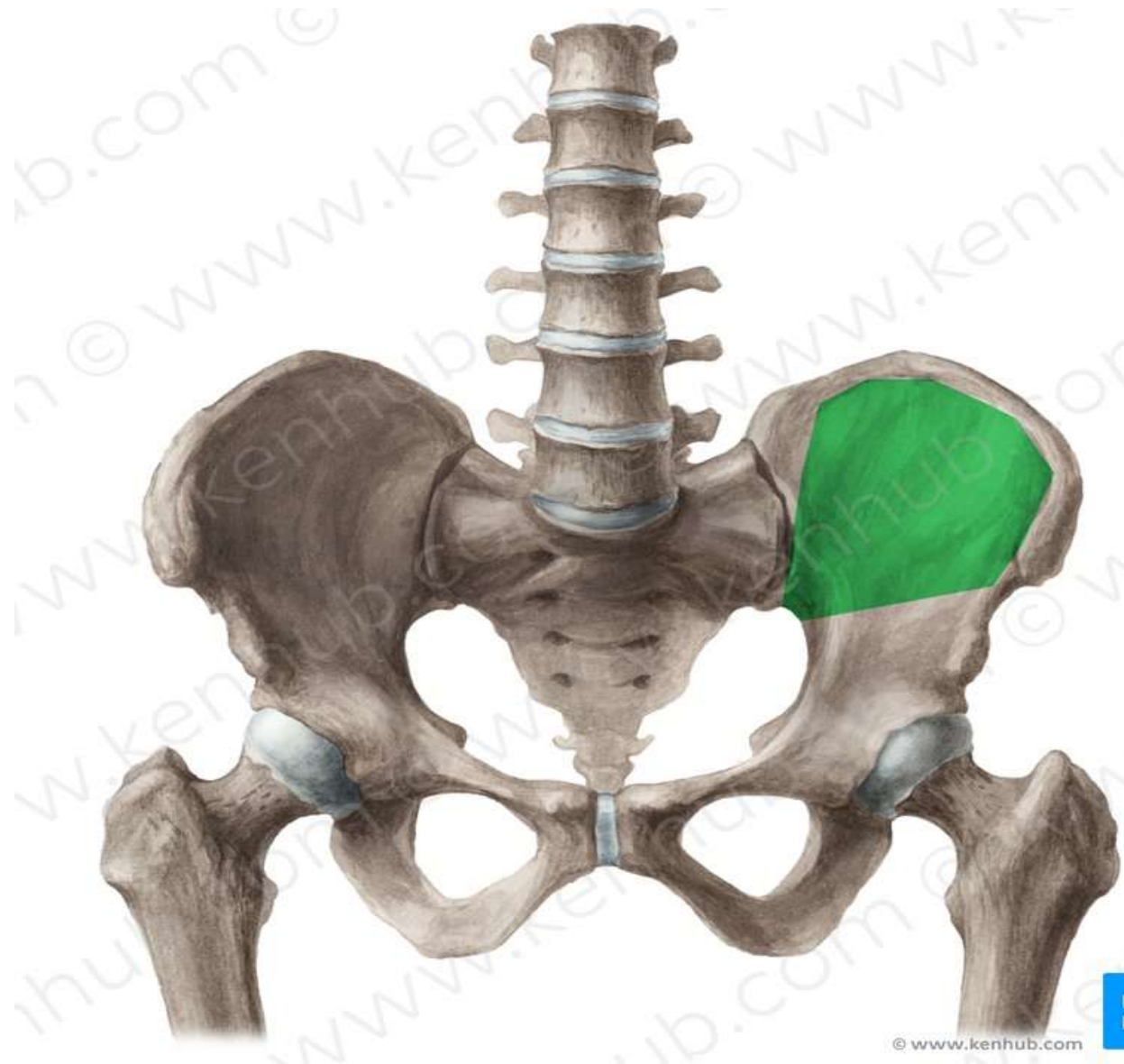
## Middle Gluteal line



## Posterior Gluteal line

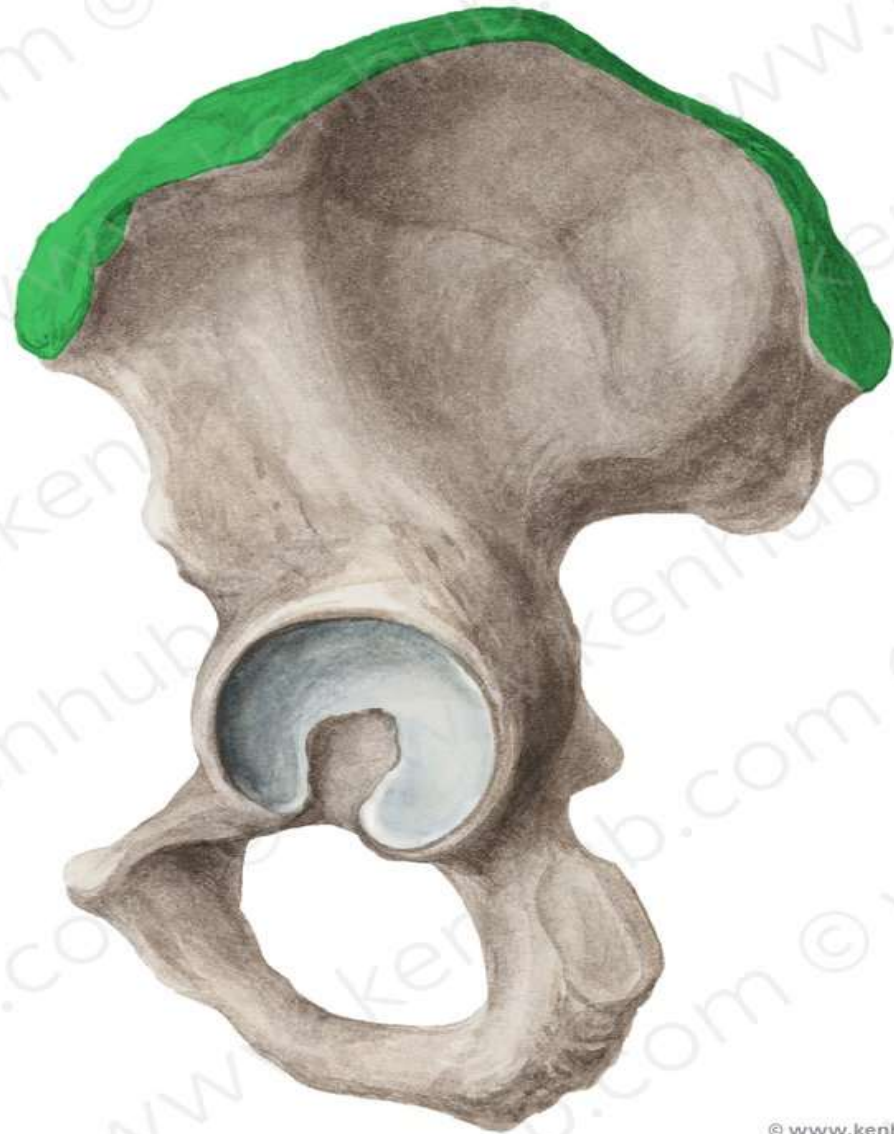


# Iliac Fossa

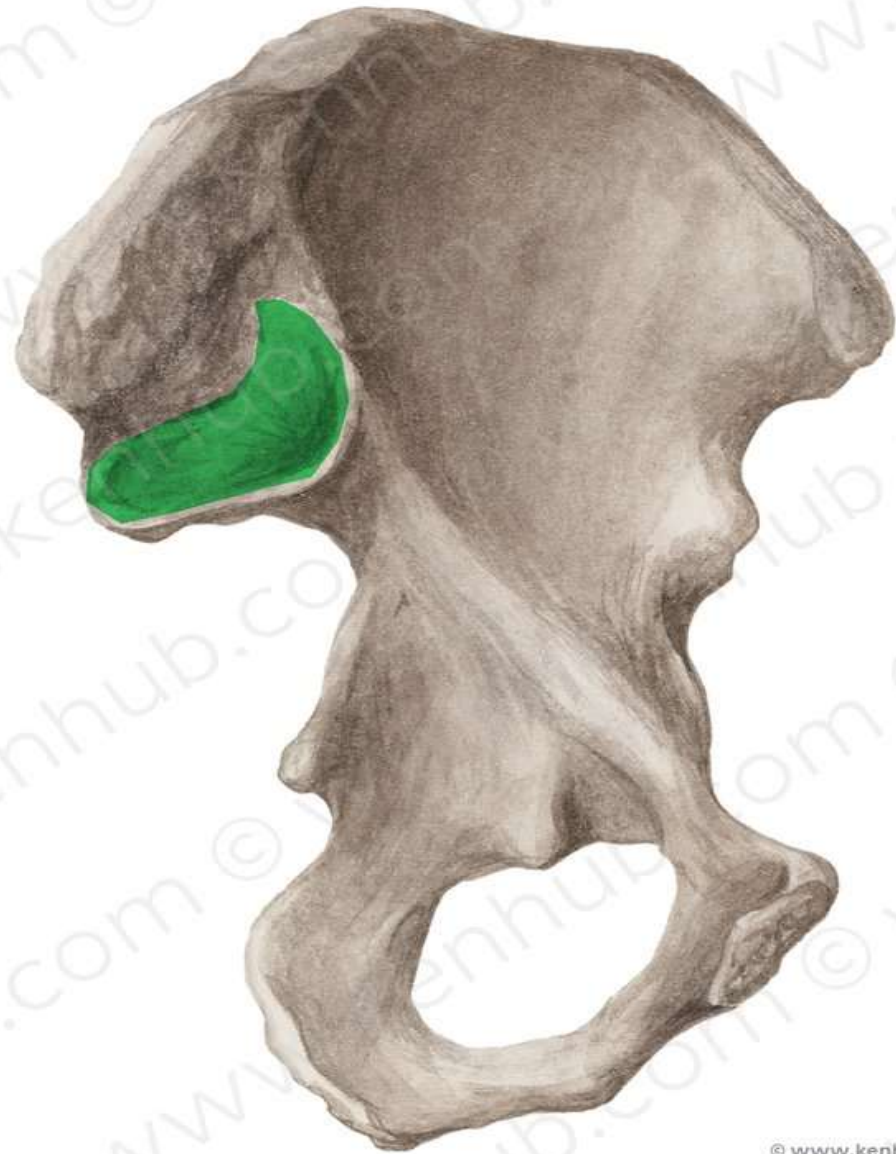



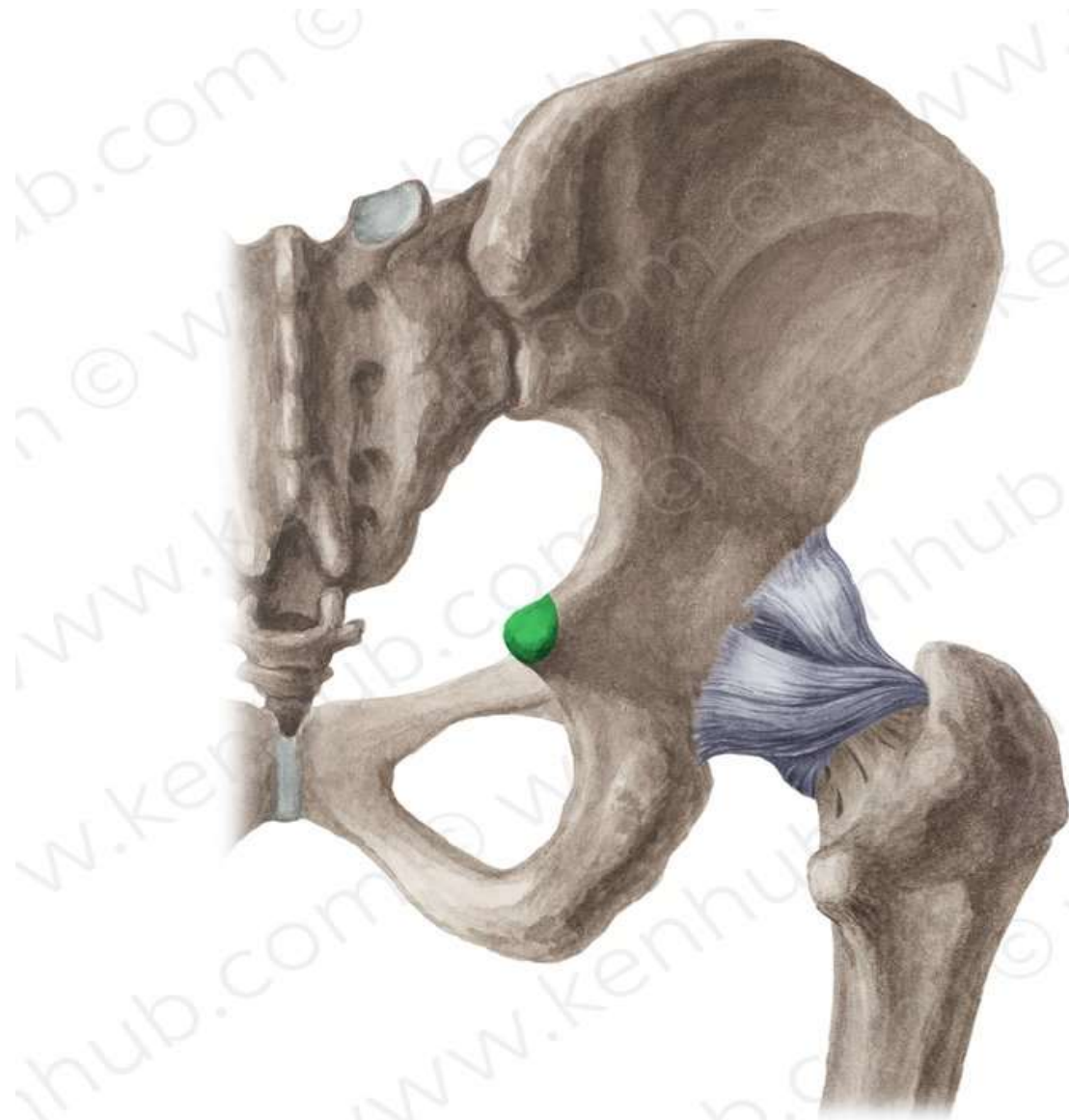
## Iliac crest



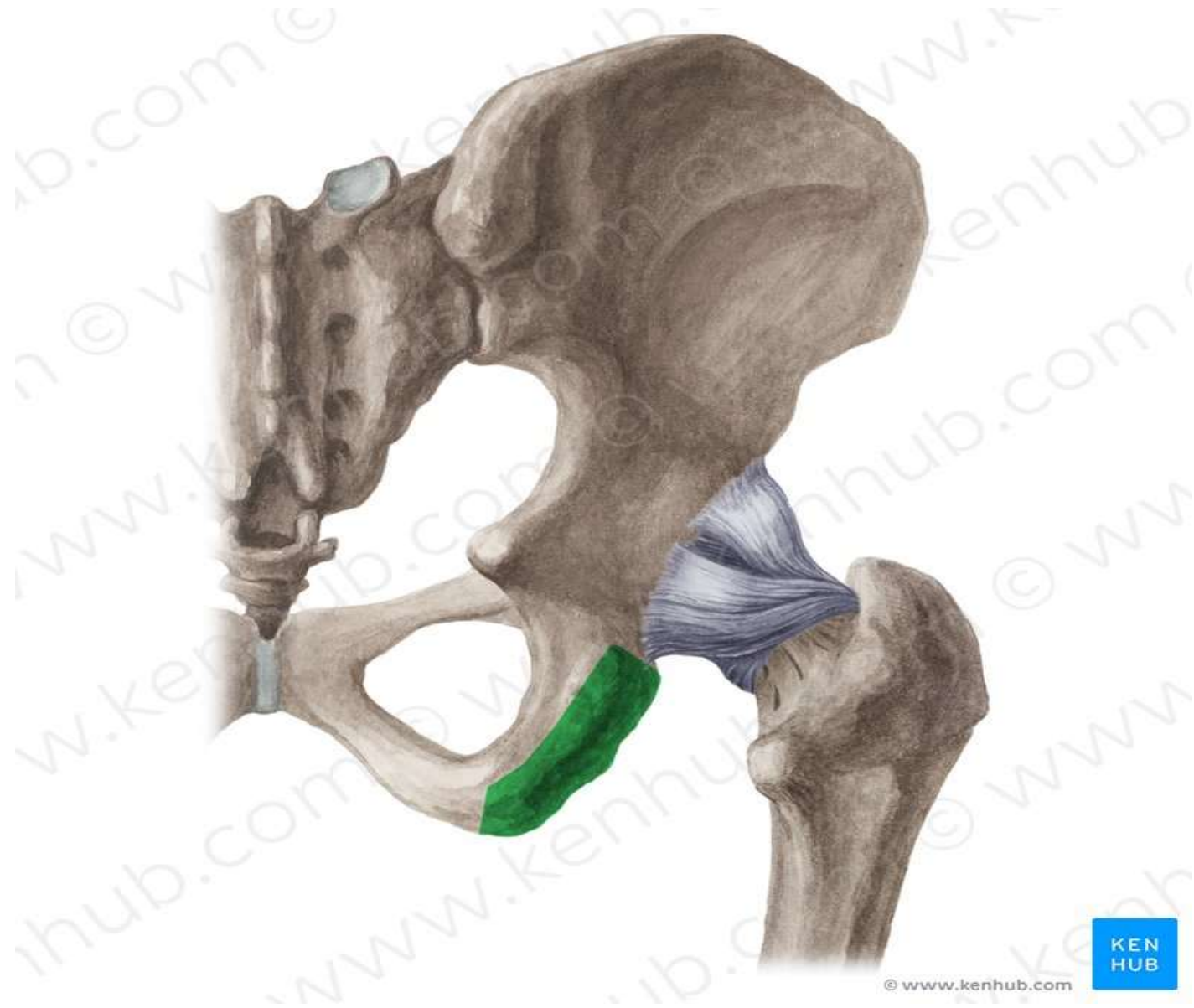
**Auricular surface**



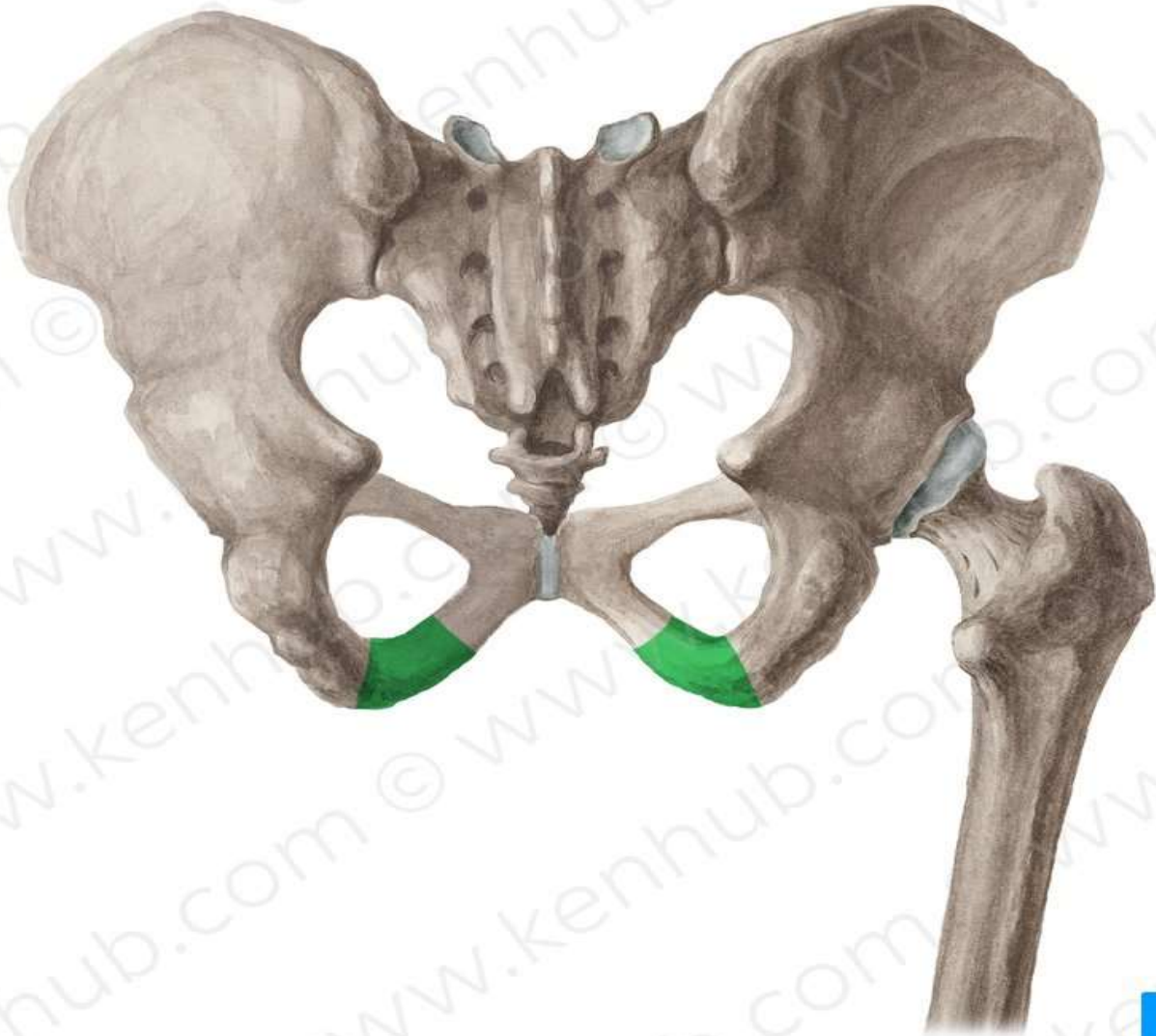
**Ischial spine**



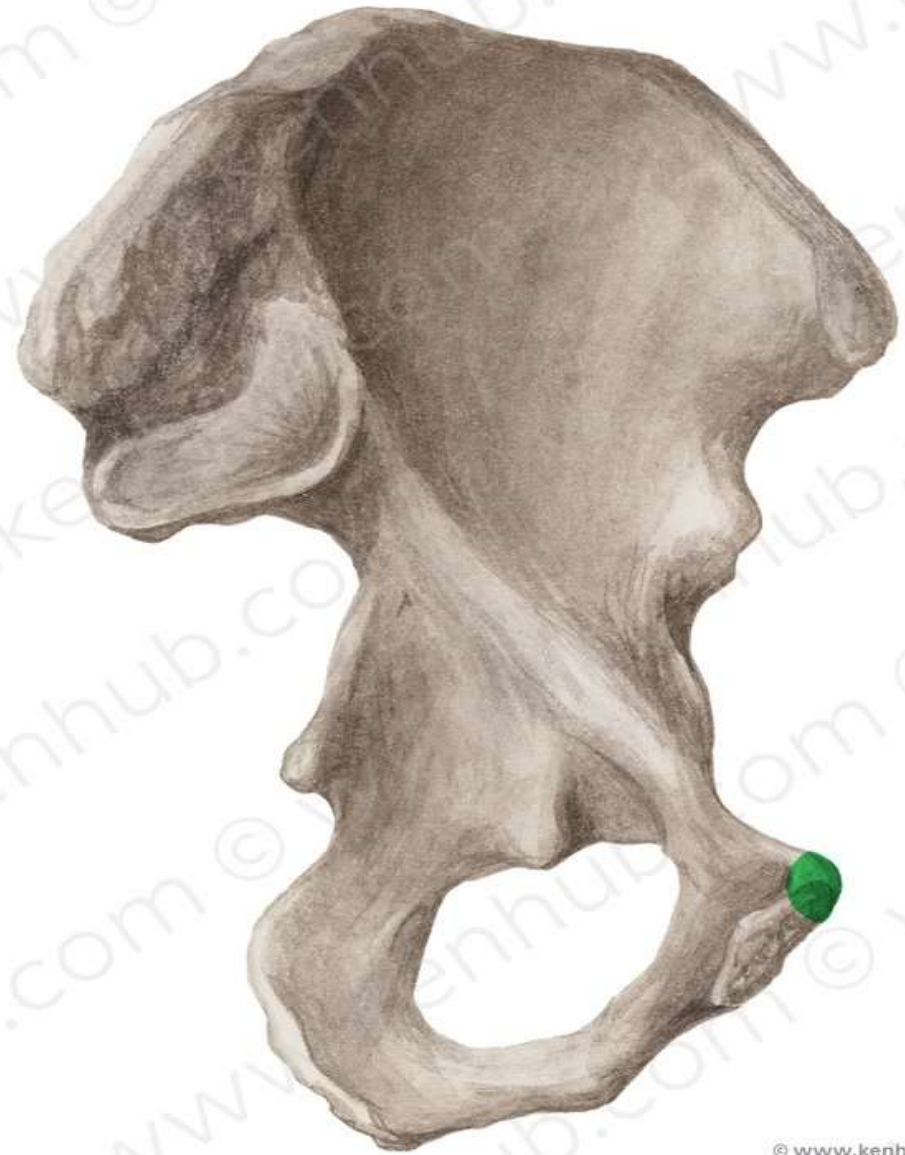# Ischial Tuberosity



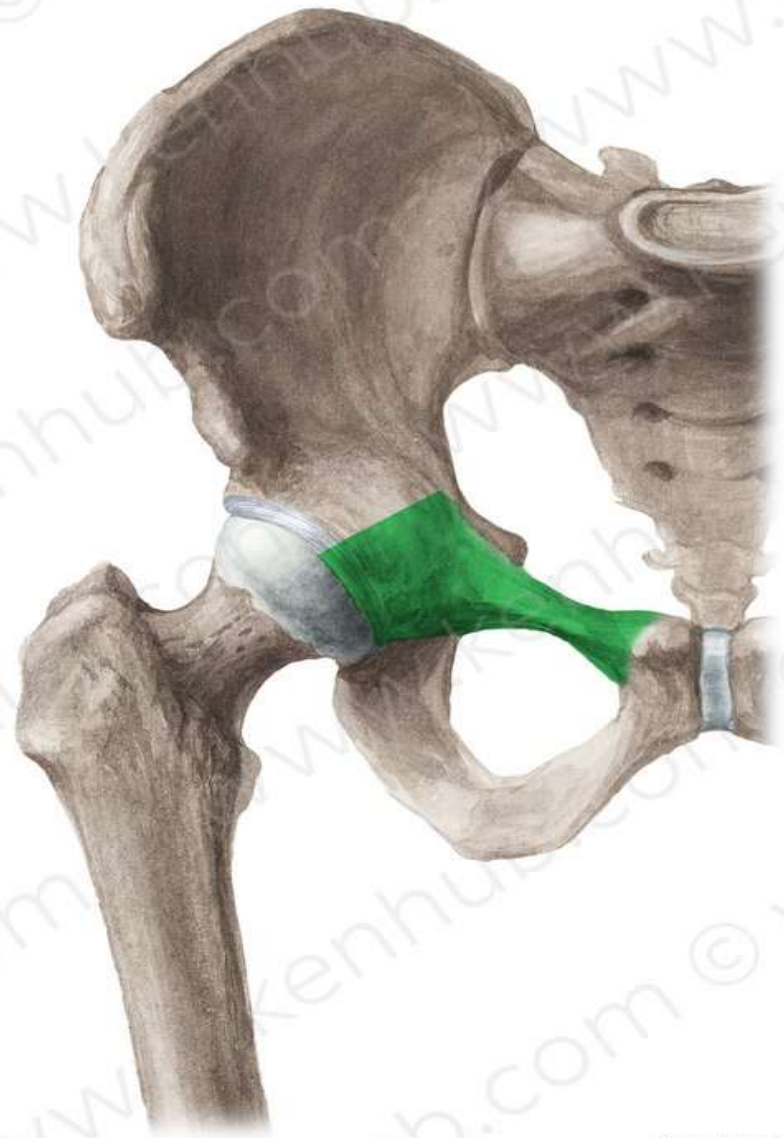
**Ischial ramus**



## Pubic tubercle

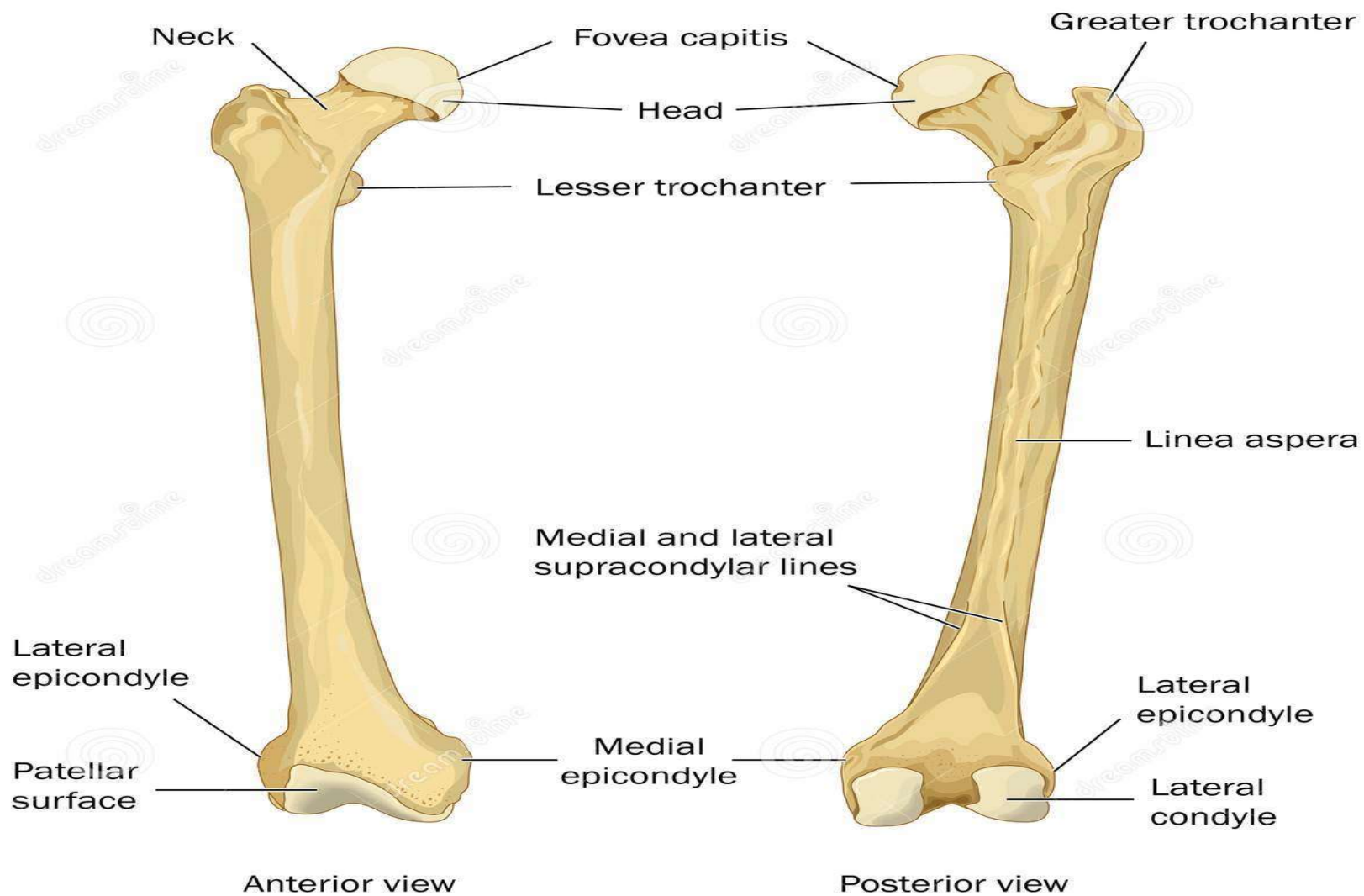


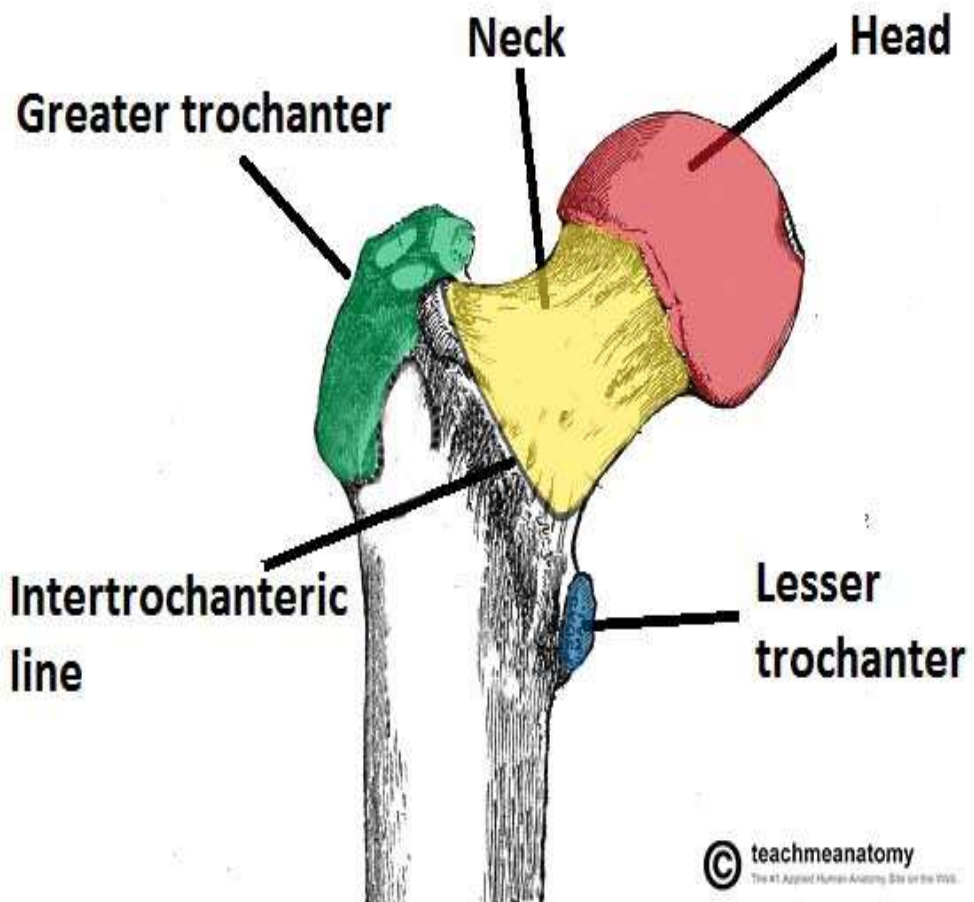
## Superior pubic ramus



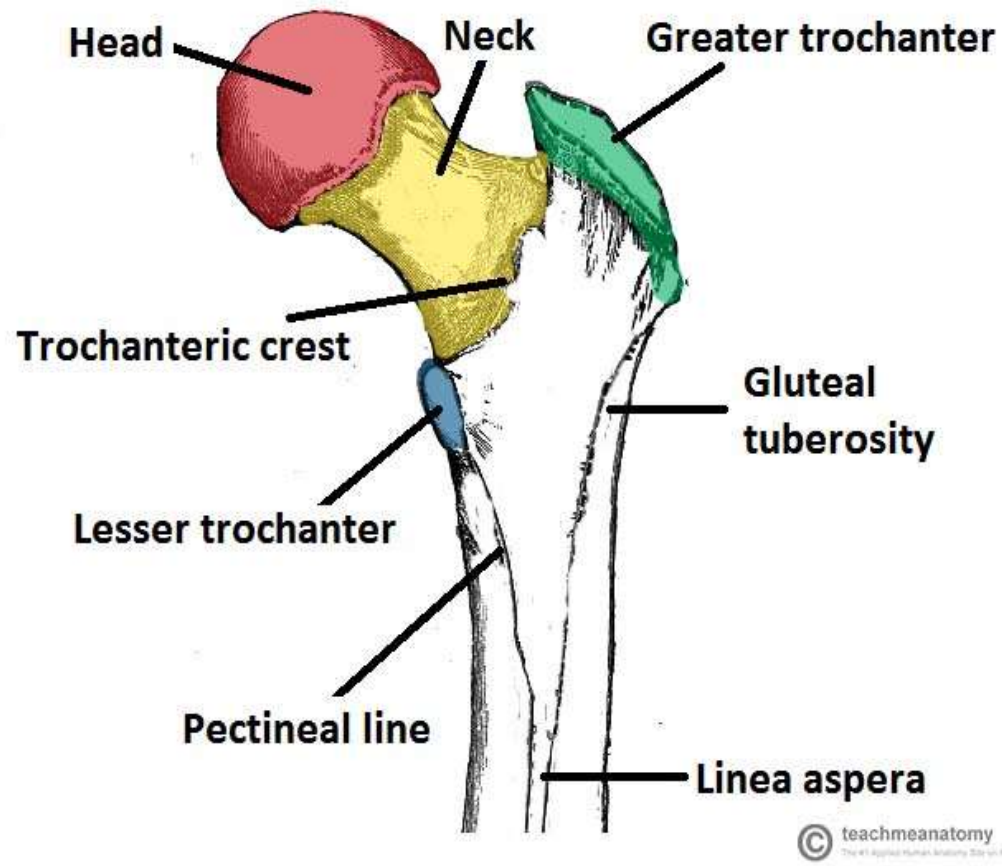
**FEMUR**



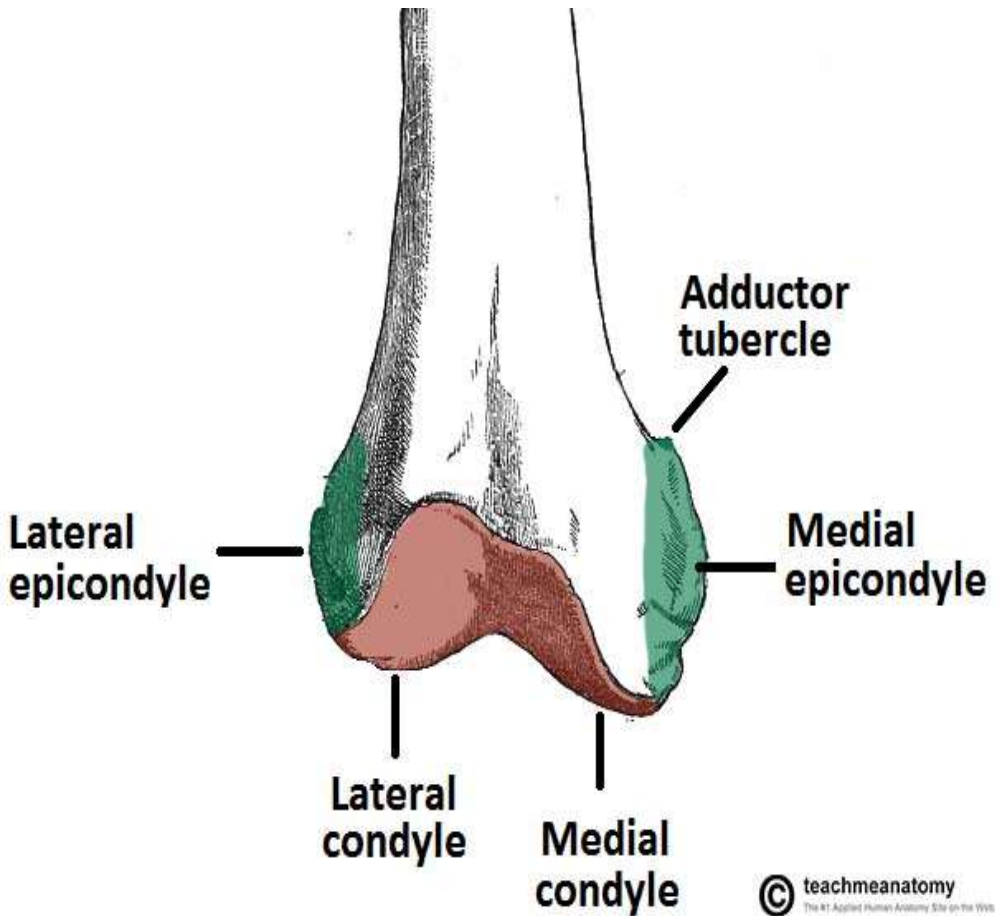




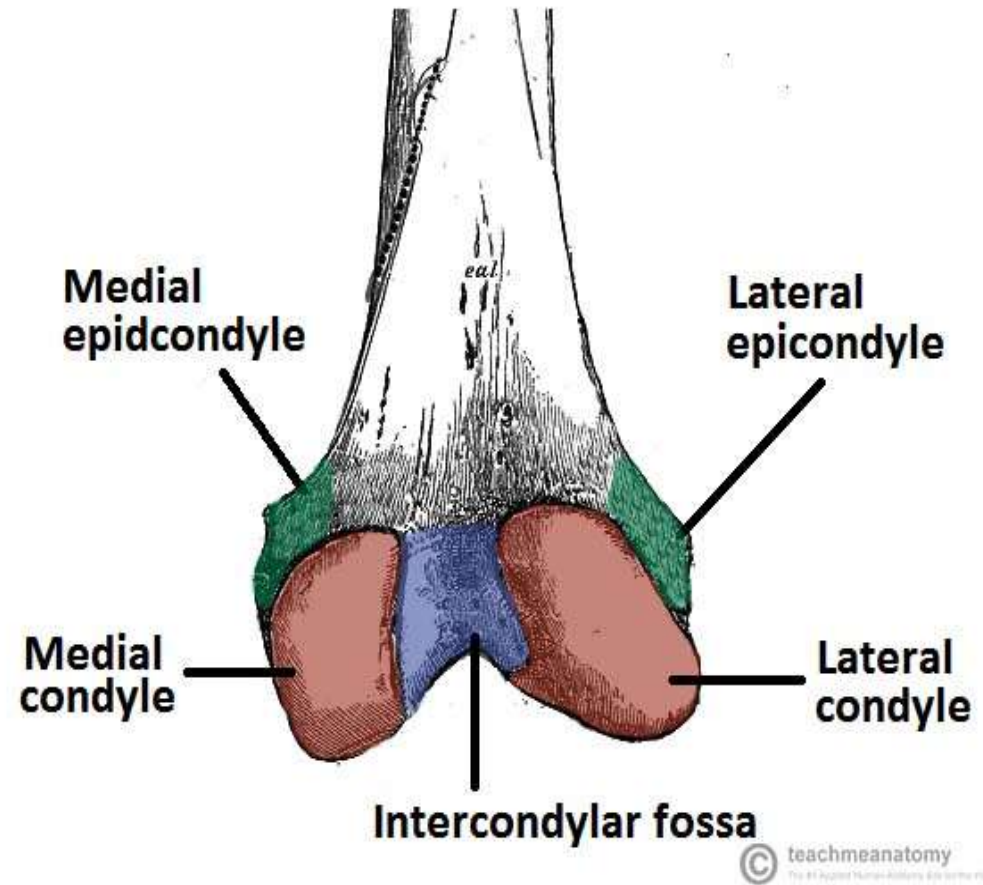
**Anterior View**



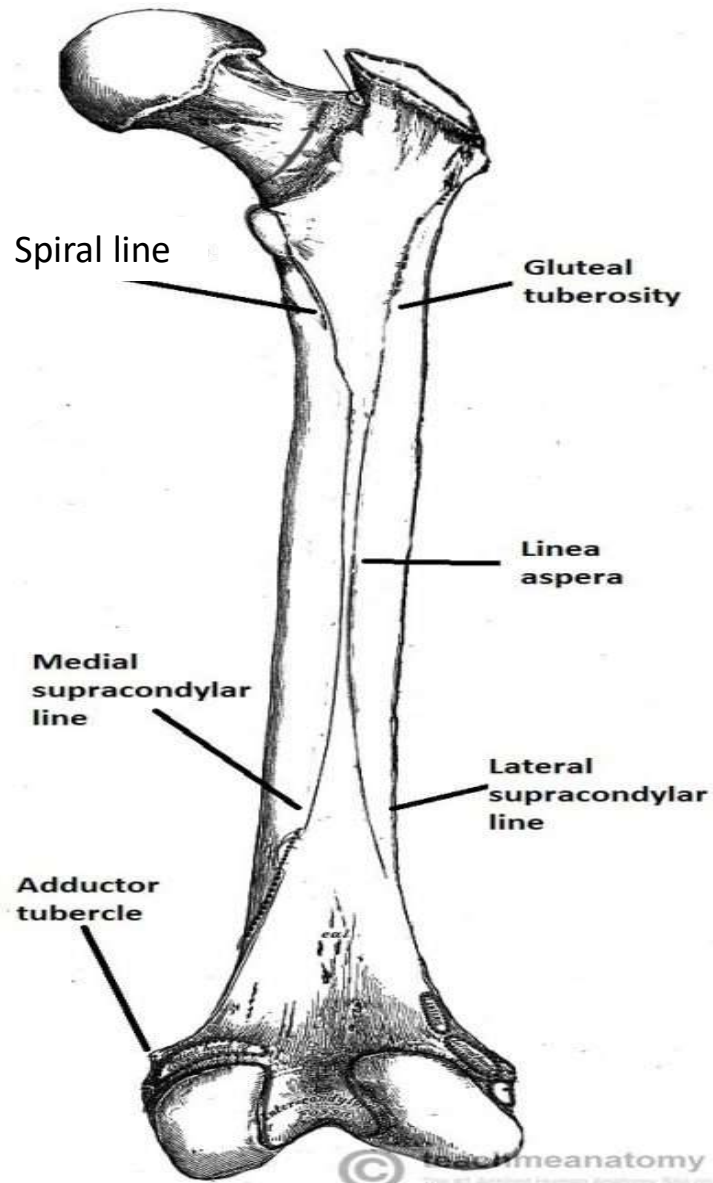
**Posterior View**



**Anterior View**



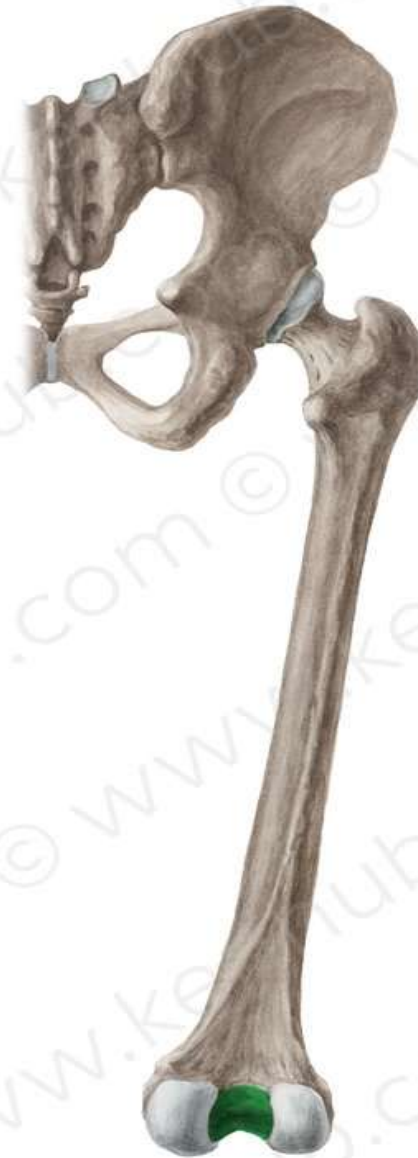**Posterior View**



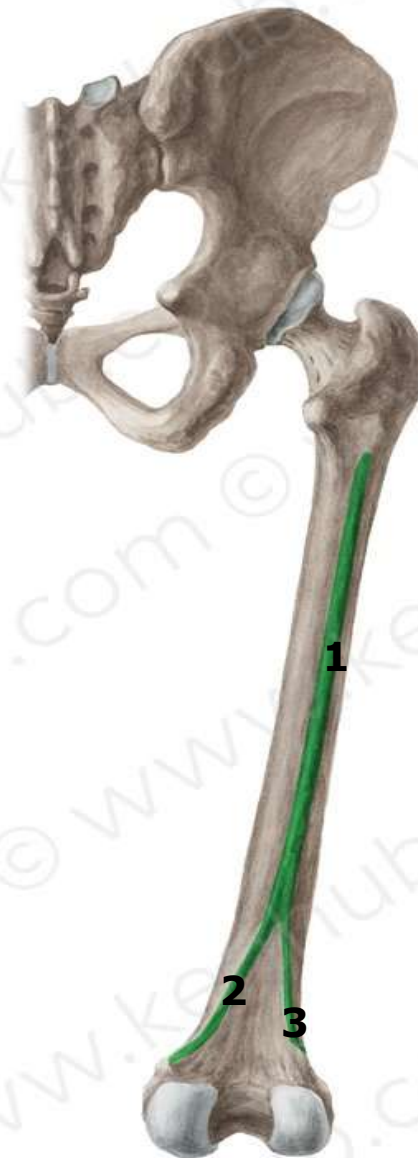

**TEST YOUR KNOWLEDGE**

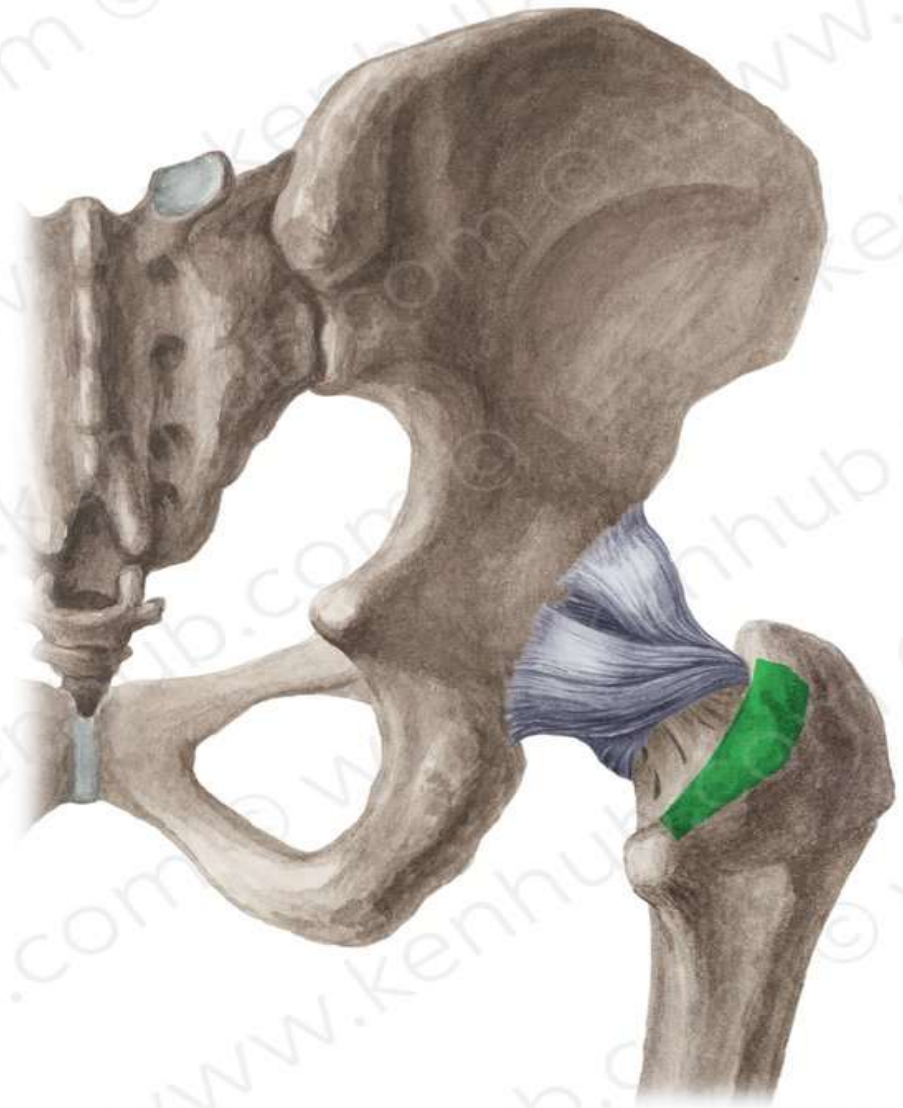
## Intercondylar fossa



- 1-Linea Aspera**
- 2-Medial supracondylar line**
- 3-Lateral supracondylar line**

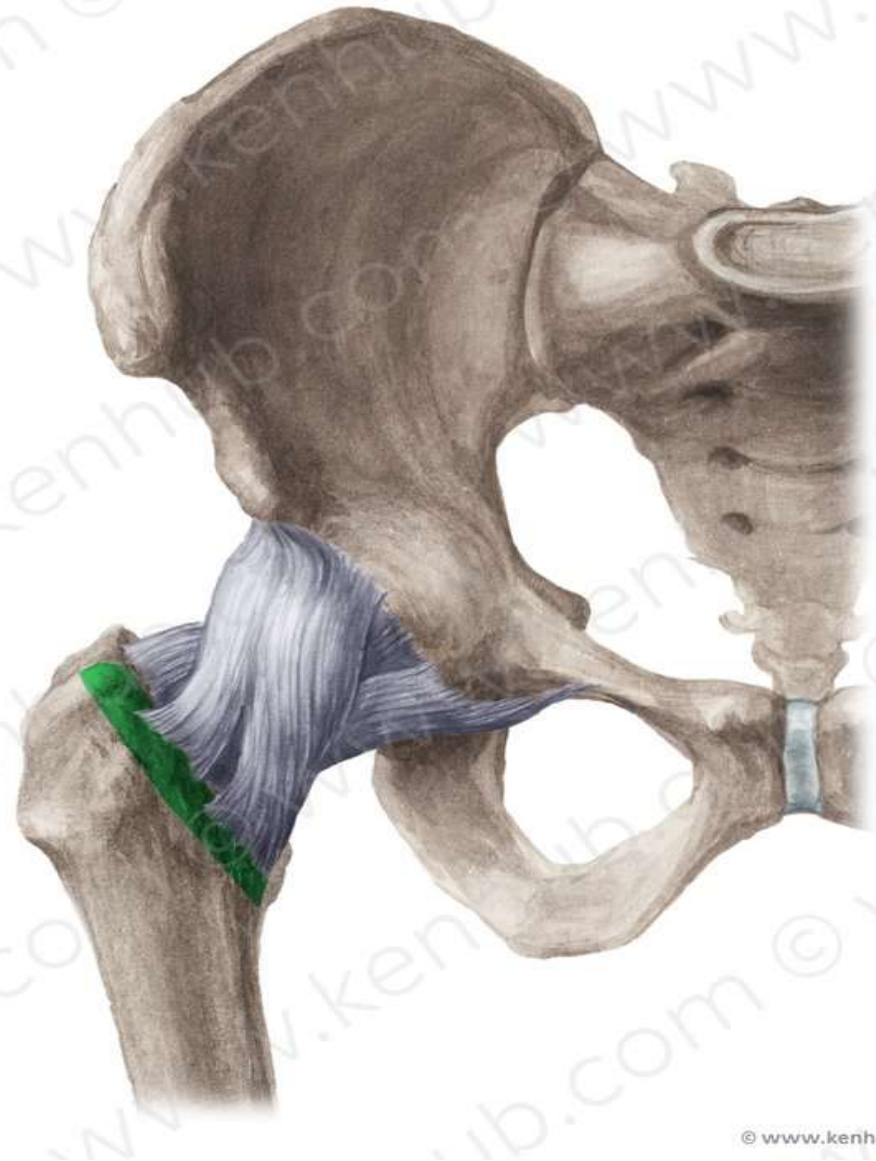


## Intertrochanteric crest

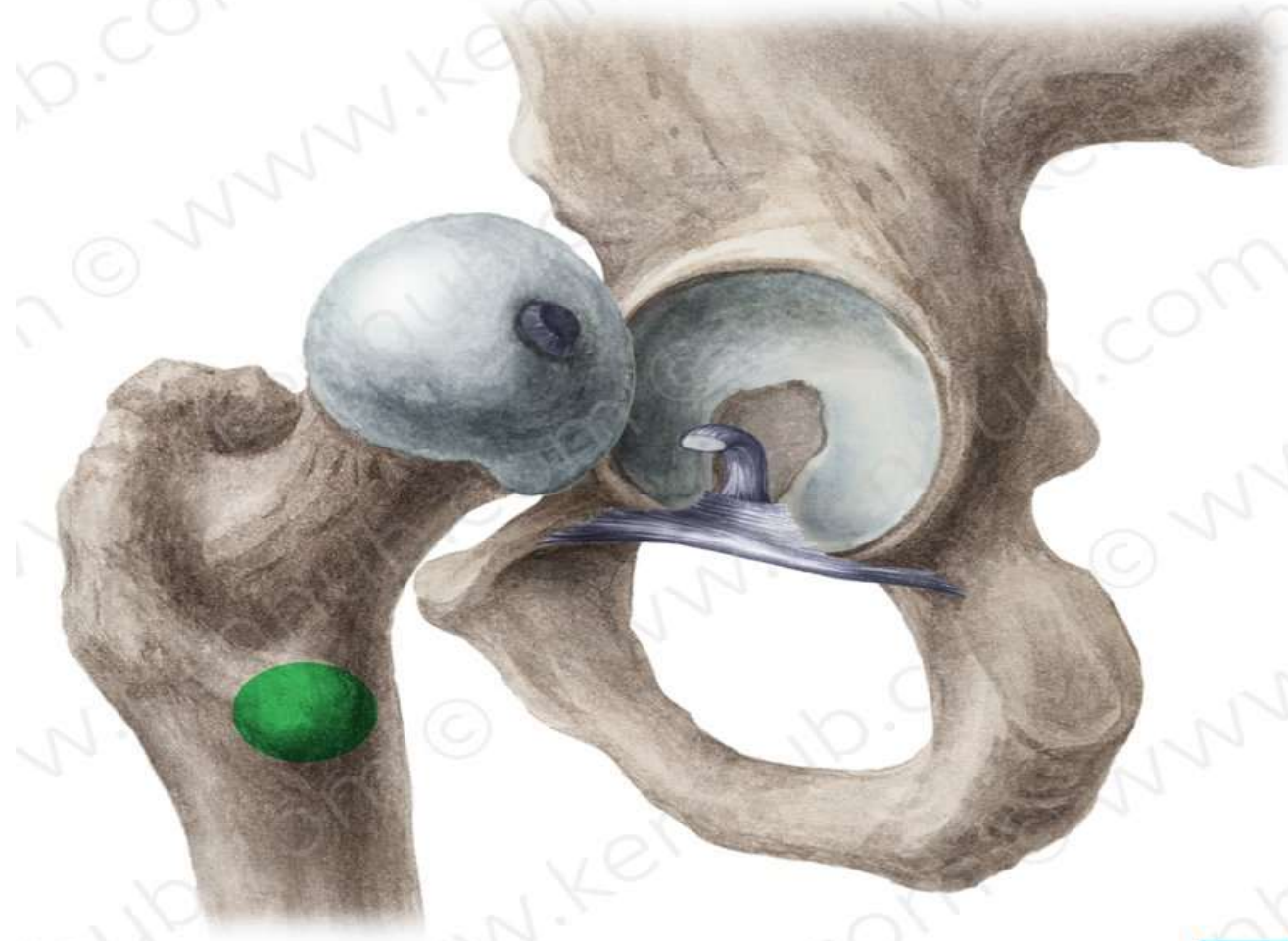




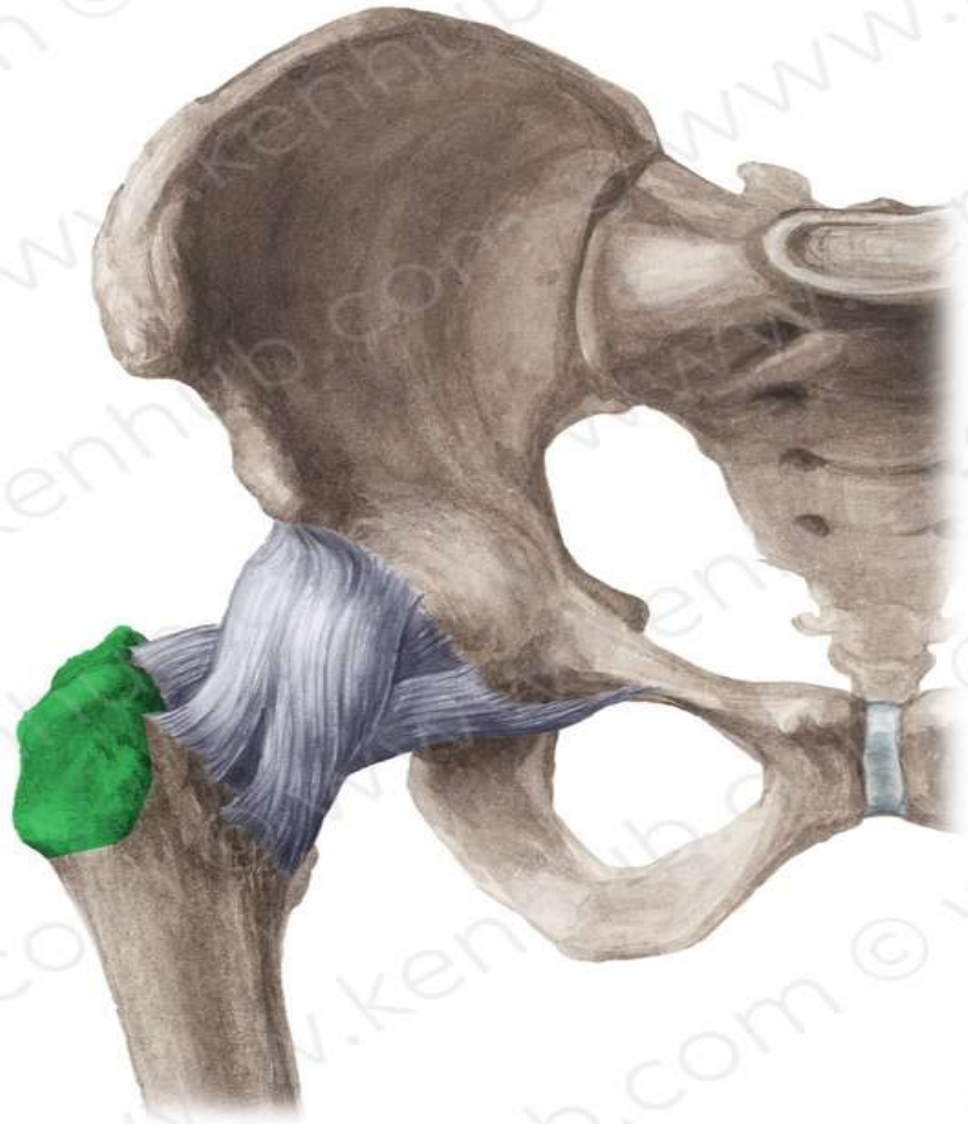
## Intertrochanteric line



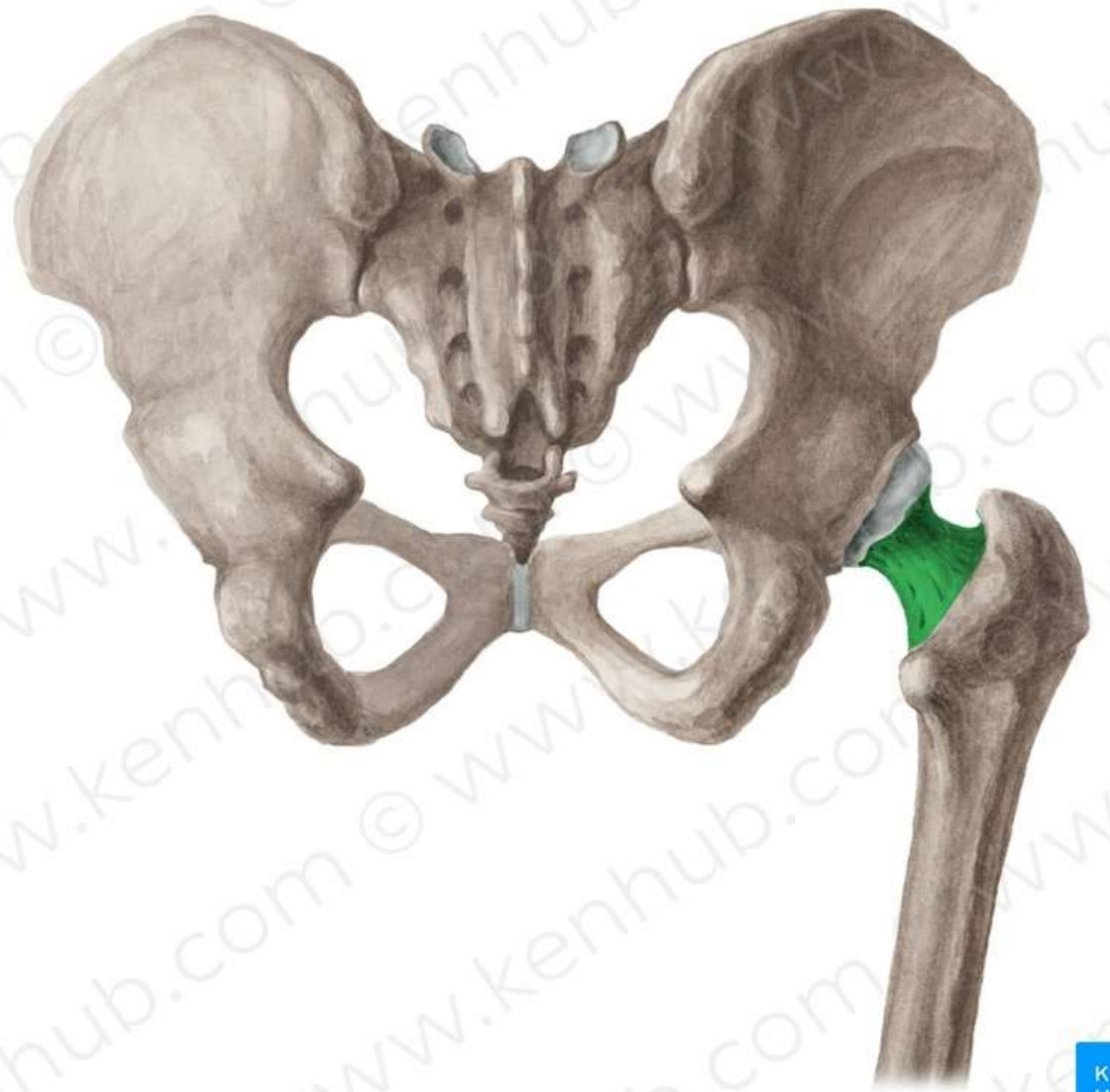
## Lesser Trochanter



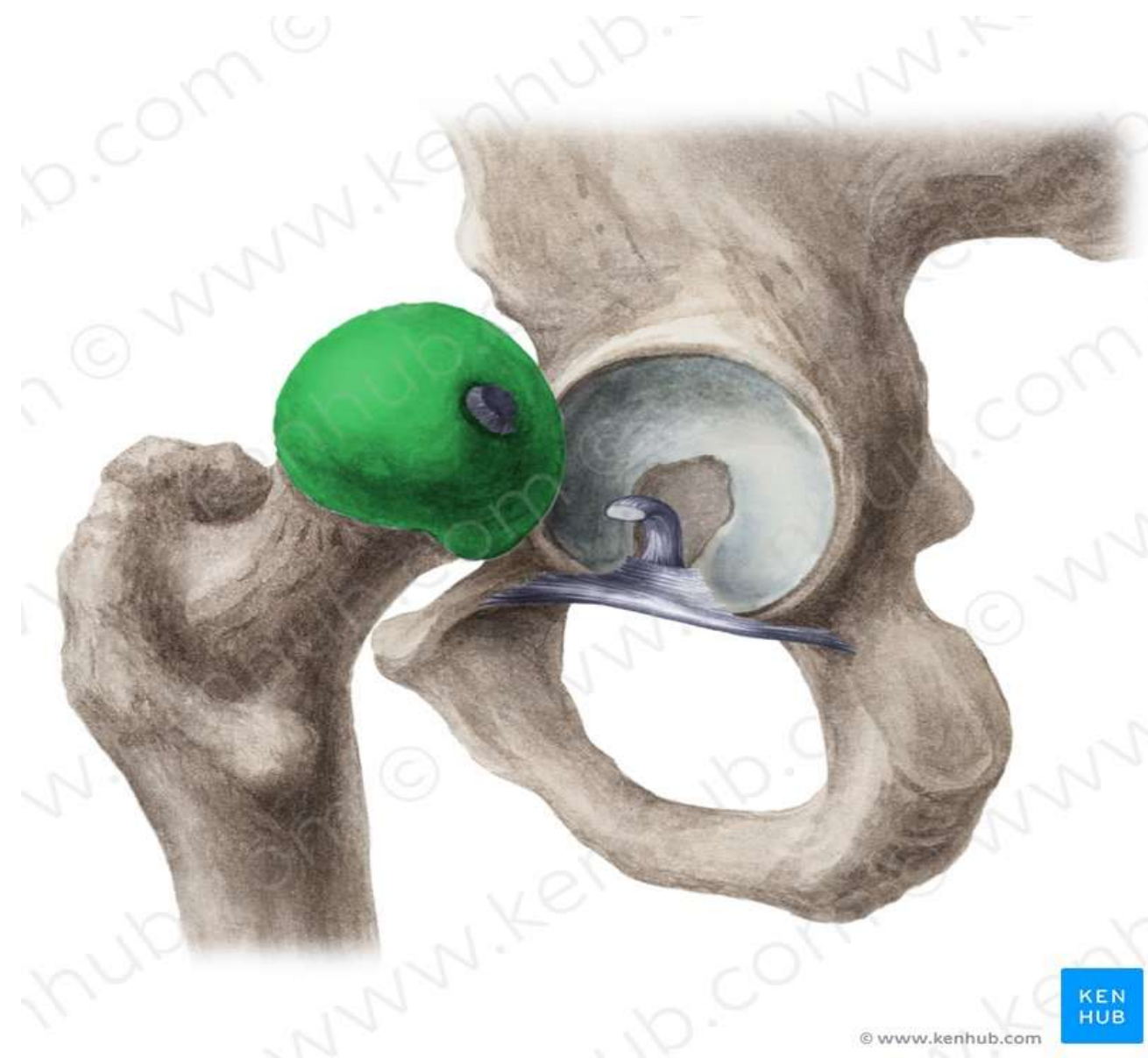## Greater Trochanter



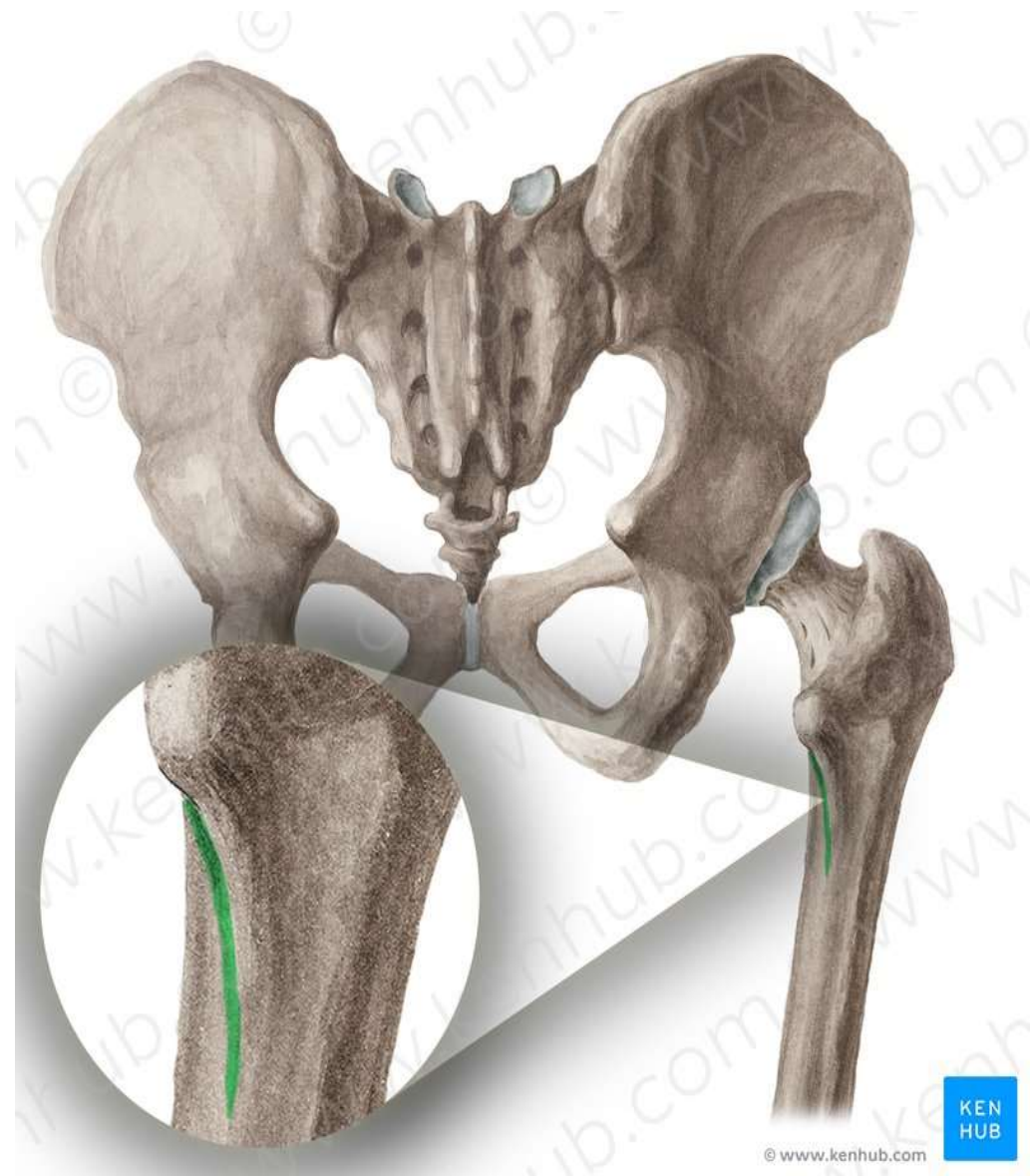
# Neck



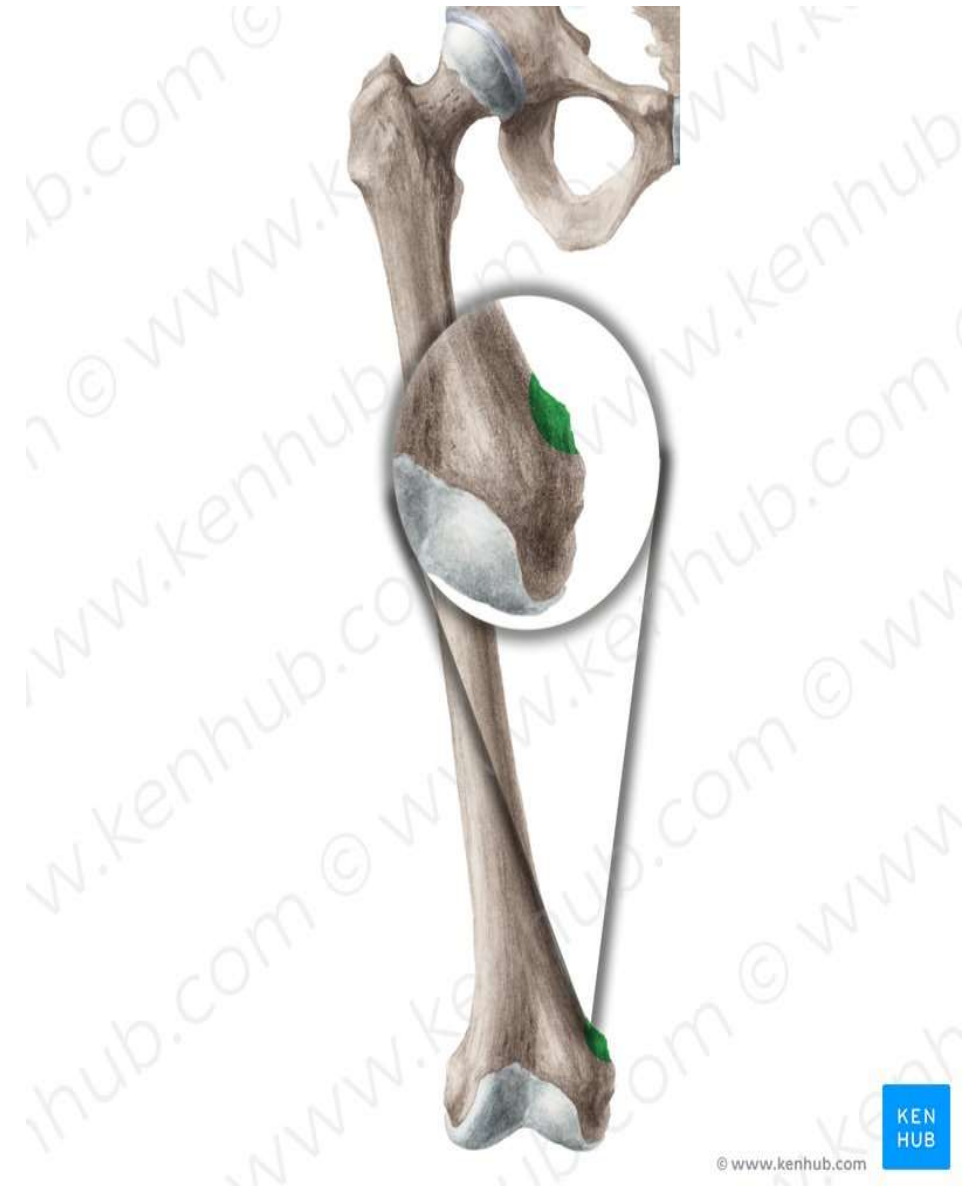# Head



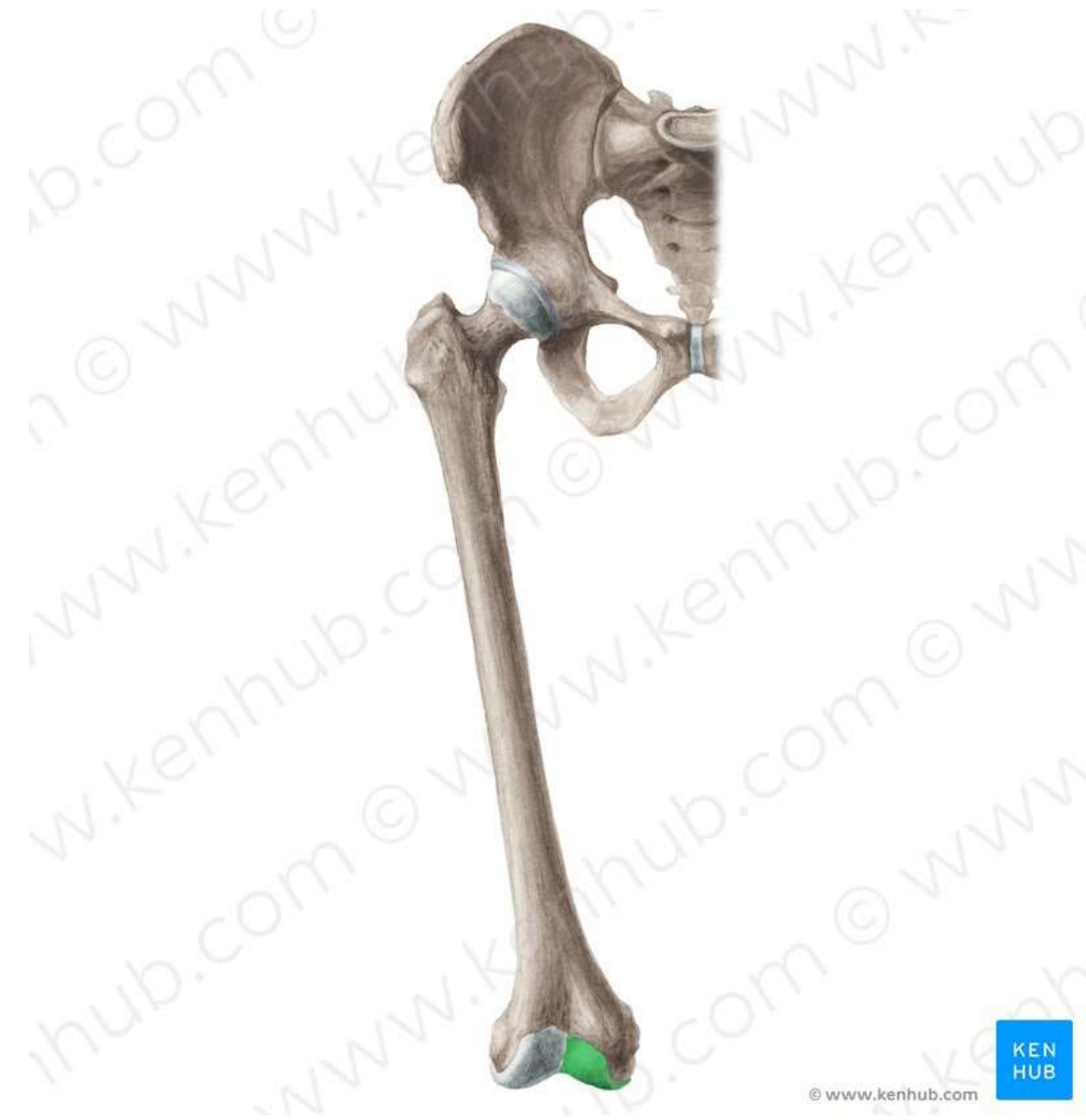## Spiral line



## Adductor tubercle

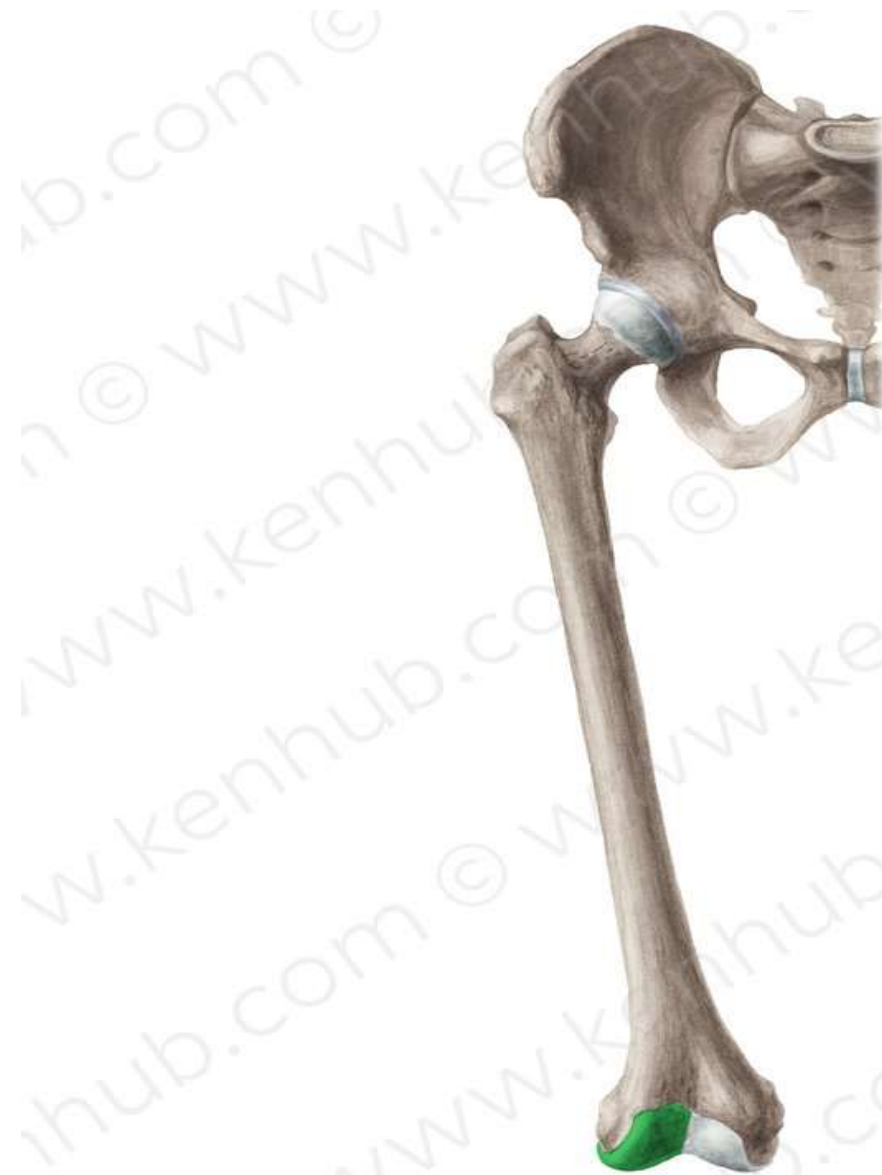

## Medial condyle





## Lateral condyle





**THANK YOU**