

2nd Practical Checklist
Topics: Humerus, Radius and Ulna

HUMERUS:

- Long bone, has
- Upper end .
 - Head
 - 2 Necks (Anatomical and Surgical)
 - 2 Tuberosity (Greater and Lesser)
 - Bicipital or Intertubercular groove (medial lip .lateral lip and floor)
- Shaft
 - Deltoid tuberosity and spiral (radial) groove
 - Medial and lateral supracondylar ridge
- Lower end .
 - Capitulum
 - Trochlea
 - Lateral and medial epicondyles
 - Coronoid ,radial and olecranon fossae

1. Ulna: Medial bone of the forearm

Long bone, has

Upper end :

- **2 Processes;** Olecranon process ,Coronoid process
- Ulnar tuberosity ,supinator crest and supinator fossa
- **2 notches** Radial notch ,Trochlear notch

-Lower end :

- Head (articulates with ulnar notch of the radius) and
- Styloid process

2. Radius : Lateral bone of the forearm

Long bone, has

Upper End

- Head (articulate with capitulum of humerus & radial notch of the ulna)
- Neck
- Radial Tuberosity

Lower End

- Ulnar notch of radius (articulation with the head of the ulna)
- Posterior (has dorsal tubercle)
- lateral has styloid process
- Anterior and inferior surfaces

The University Of Jordan
Faculty Of Medicine
Anatomy Department

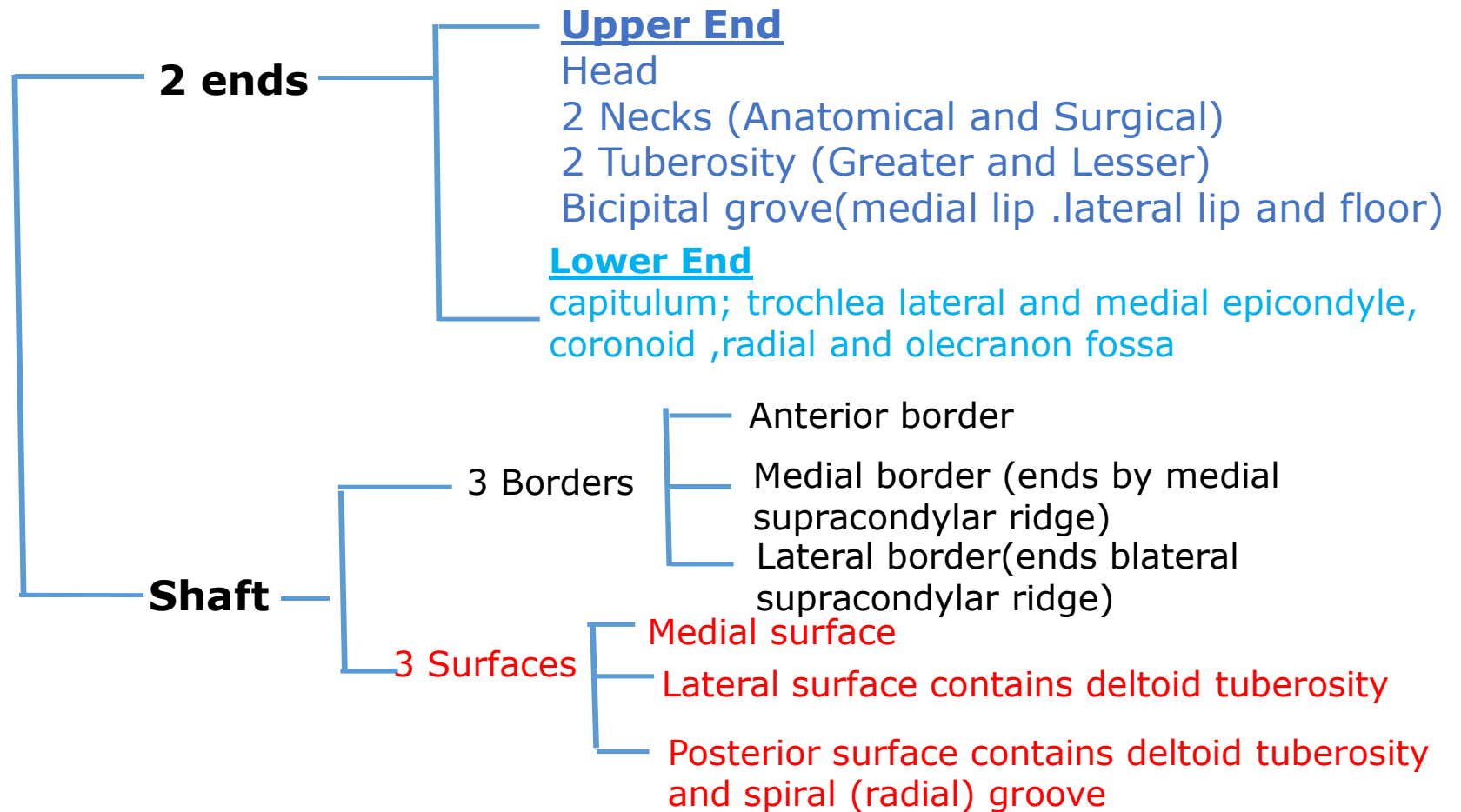


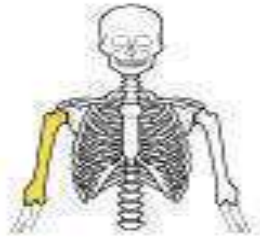Humerus

Dr.Ahmed Salman

Associate Prof. of Anatomy. The University Of Jordan

Humerus





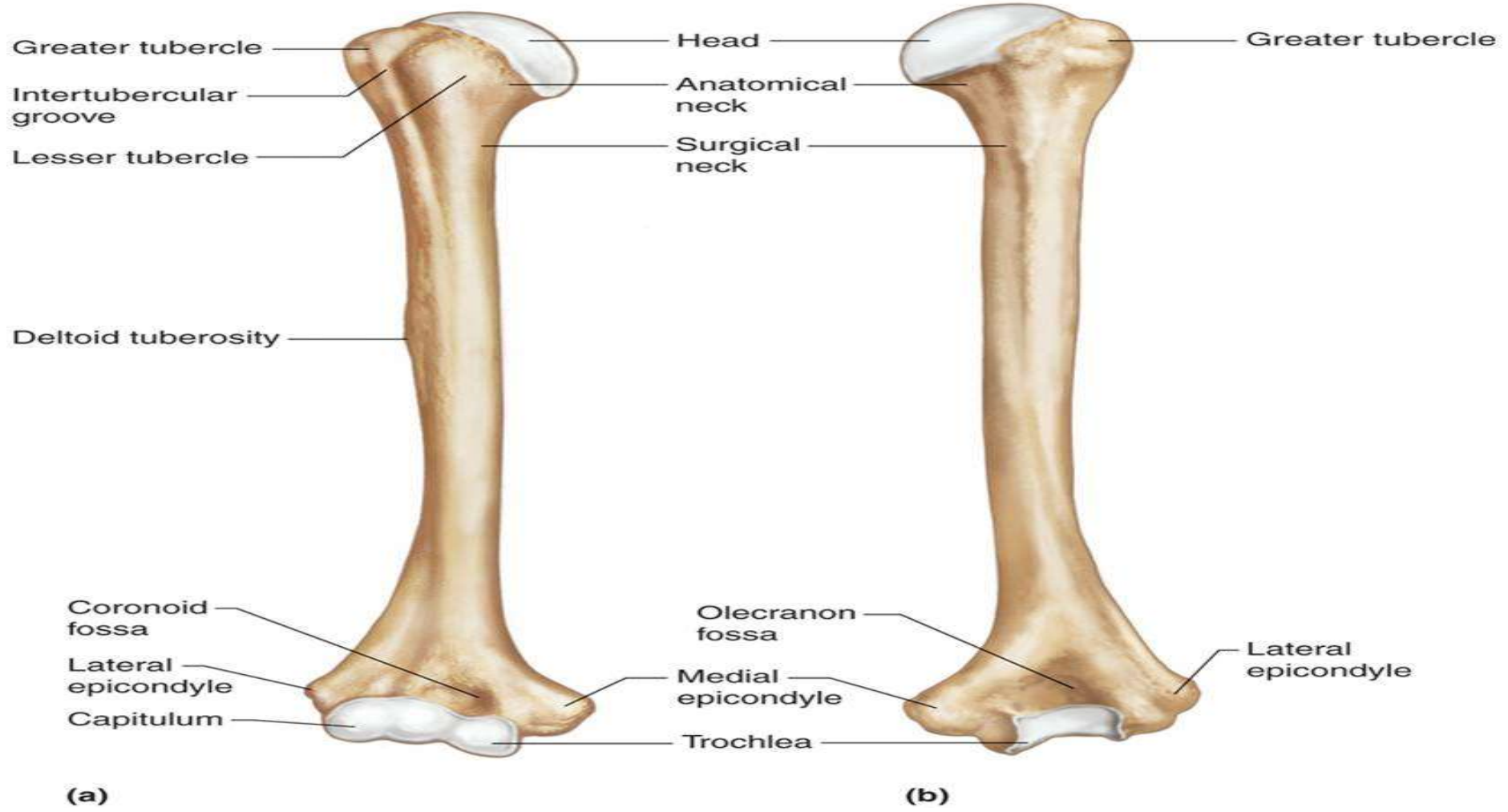
(a) Anterior view



(b) Posterior view

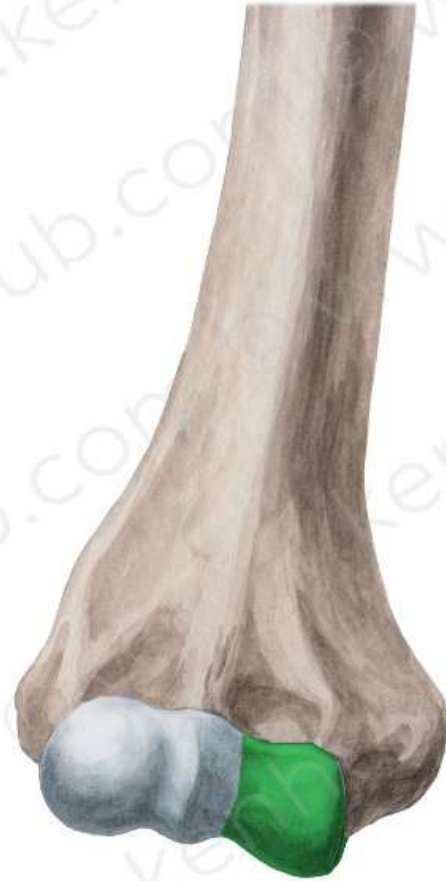Copyright © 2001 Benjamin Cummings, an imprint of Addison Wesley Longman, Inc.

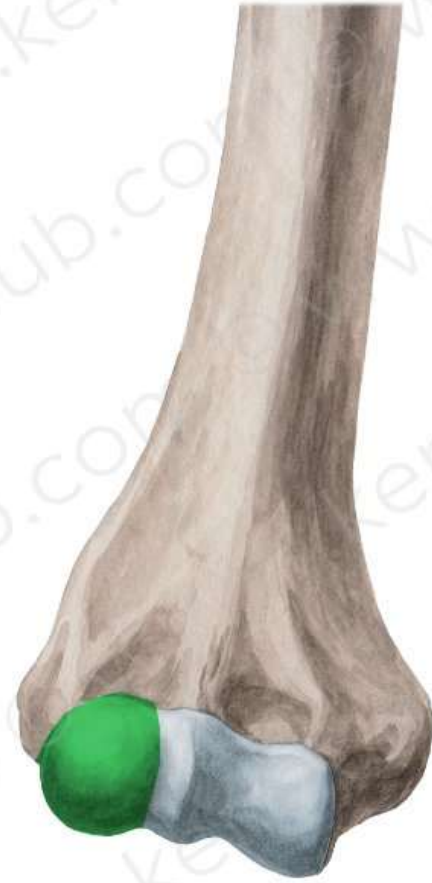Copyright © The McGraw-Hill Companies, Inc. Permission required for reproduction or display.

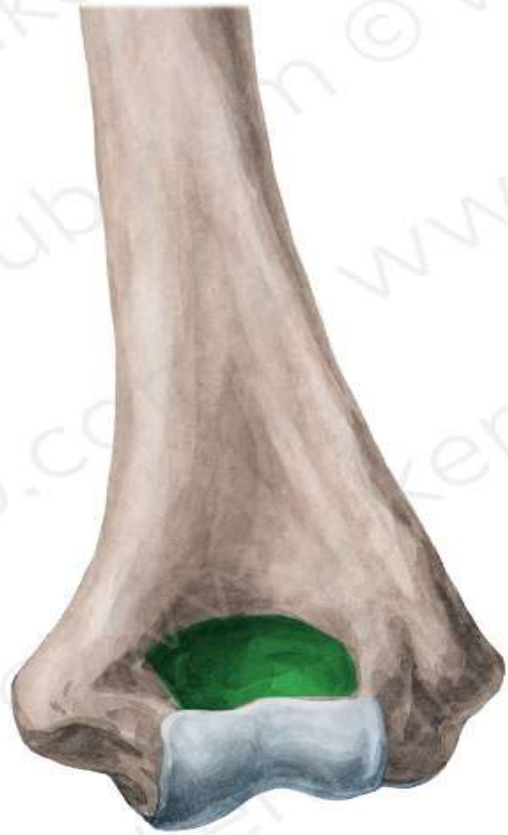

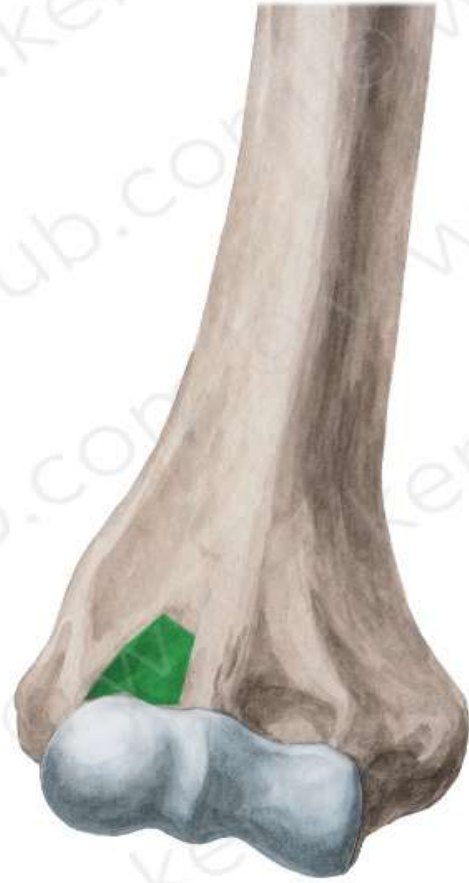TEST YOUR KNOELDGE

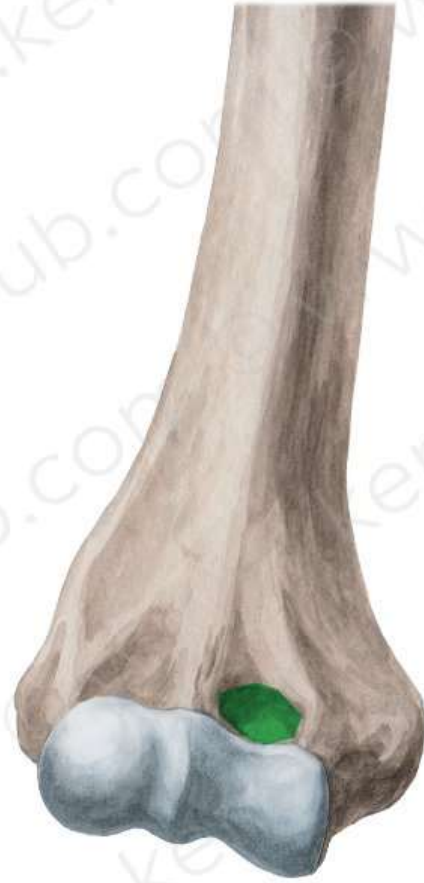[https://www.youtube.com/watch?v=BUmT49z51v4&list=P
LIDhP5E2cVJ2ME00vCyMj71TraL7BkiZT&index=6](https://www.youtube.com/watch?v=BUmT49z51v4&list=P
LIDhP5E2cVJ2ME00vCyMj71TraL7BkiZT&index=6)

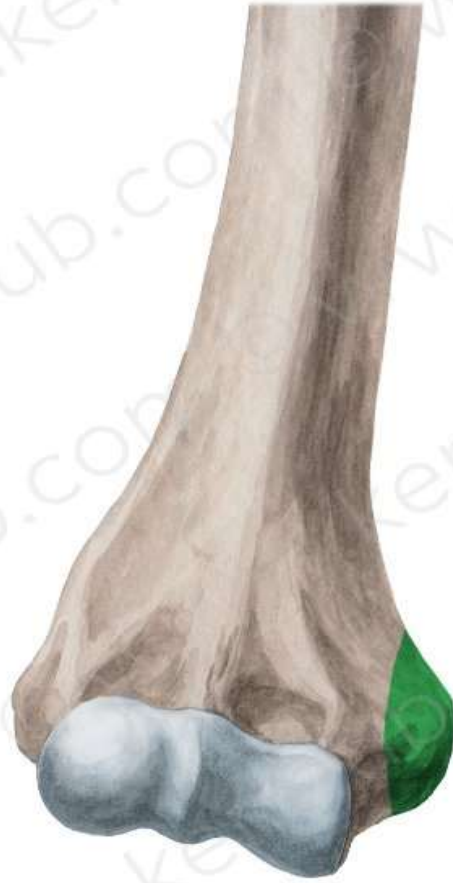


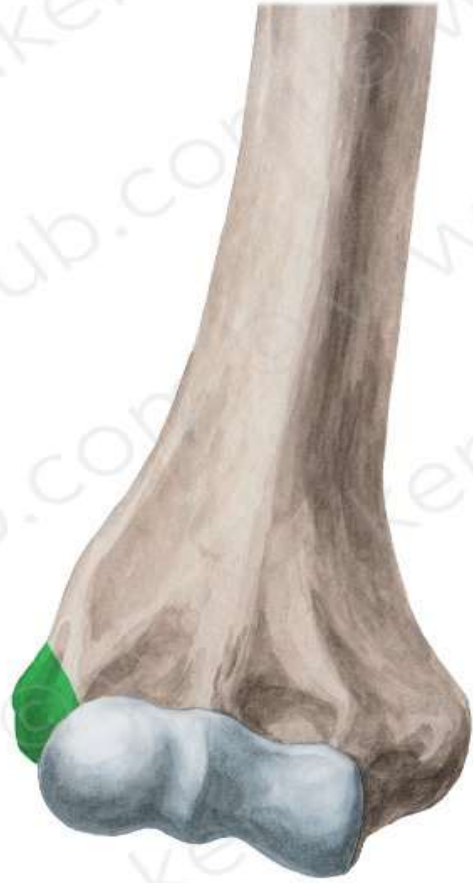


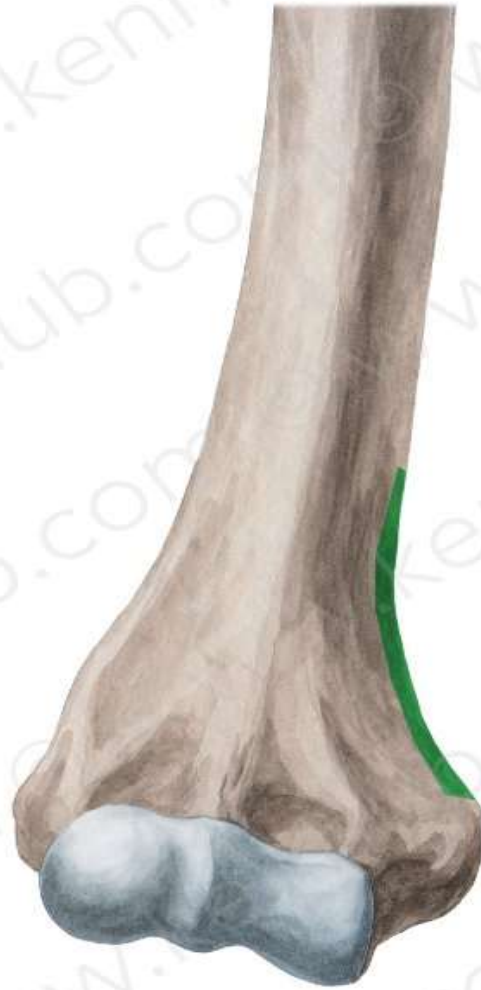

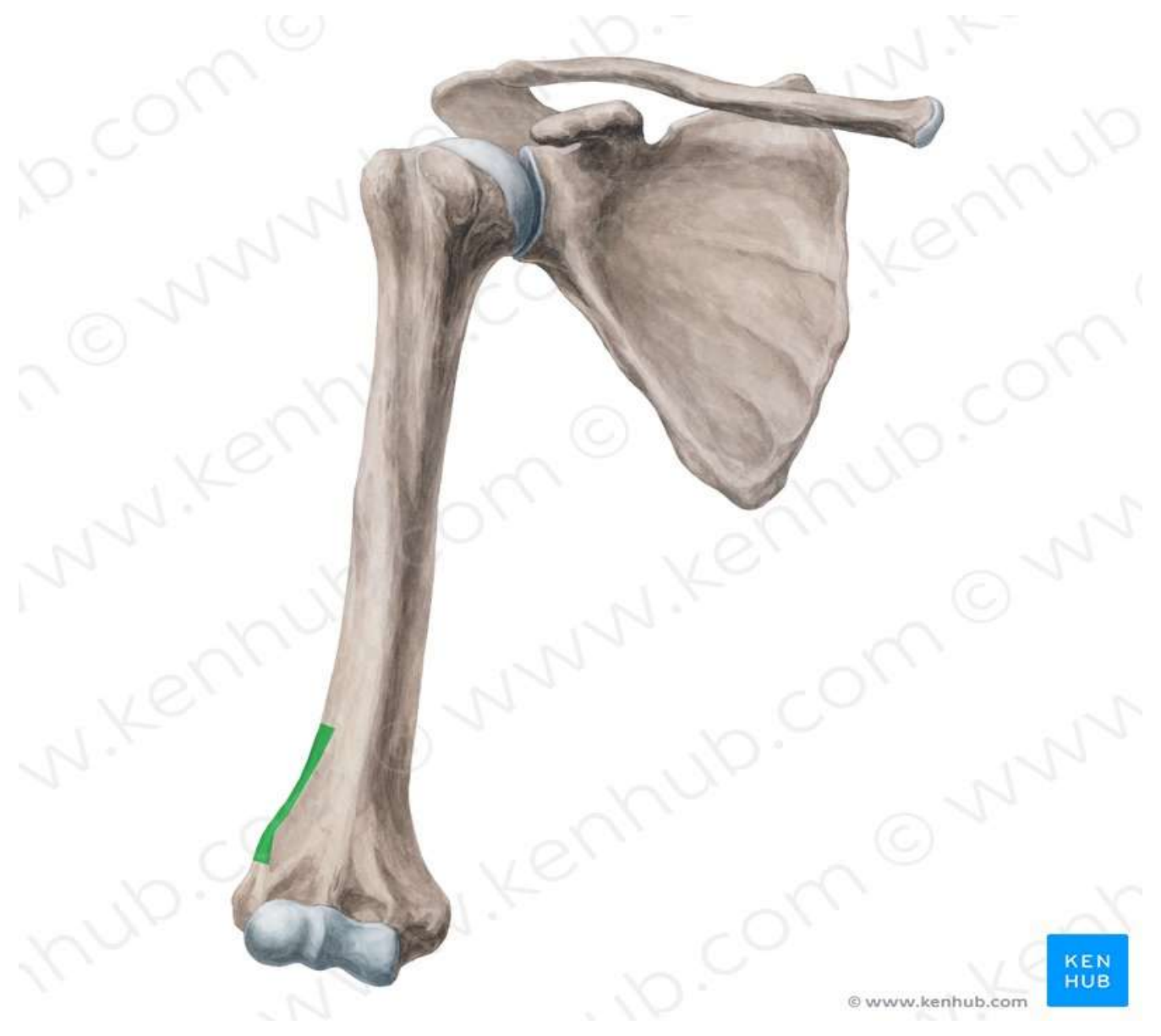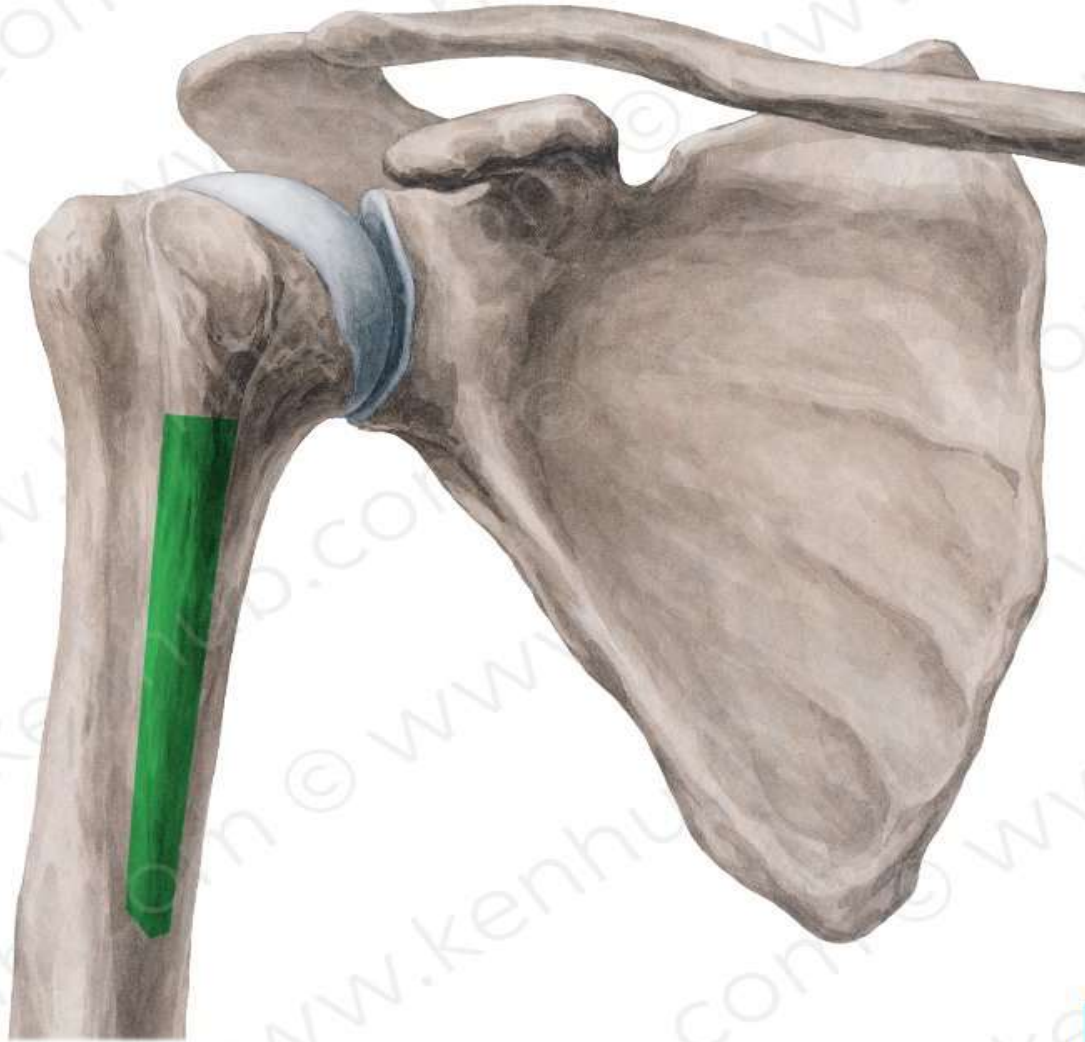


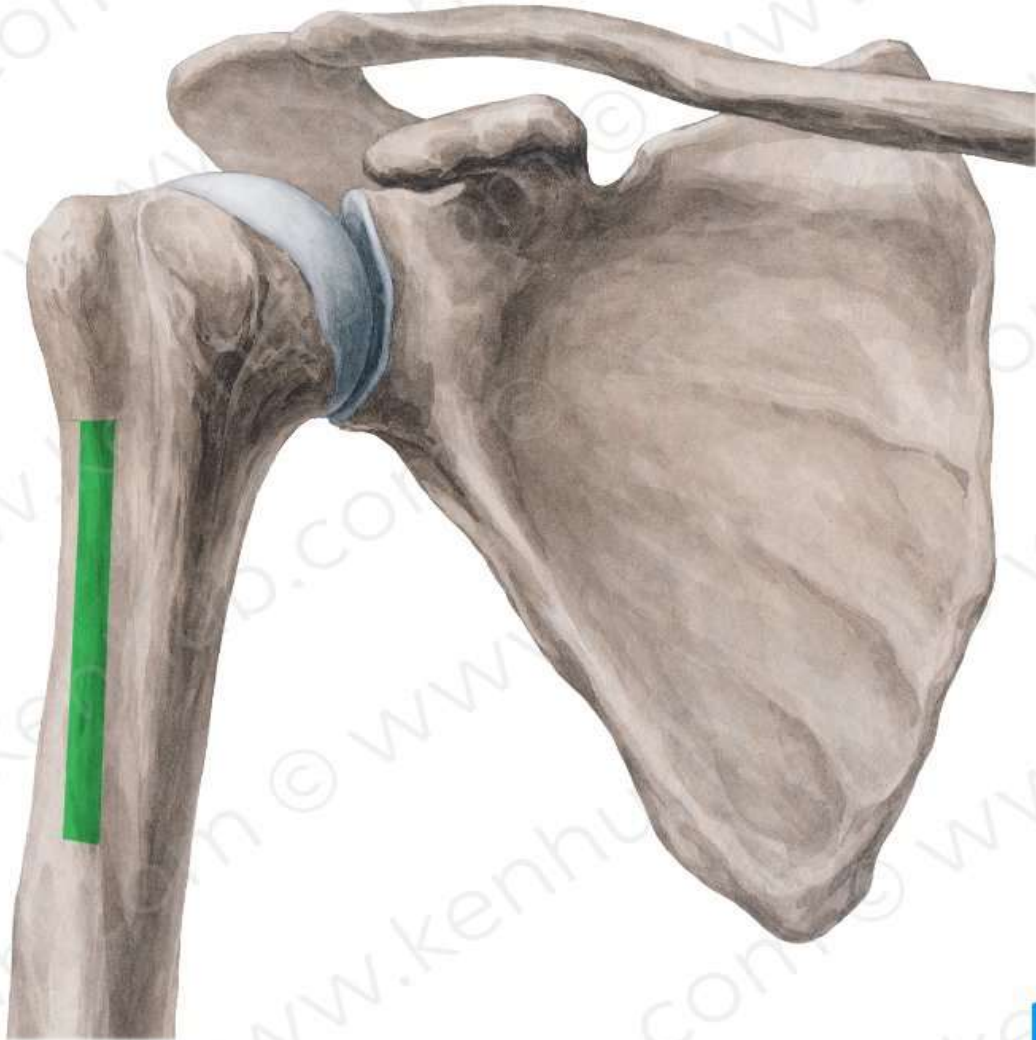


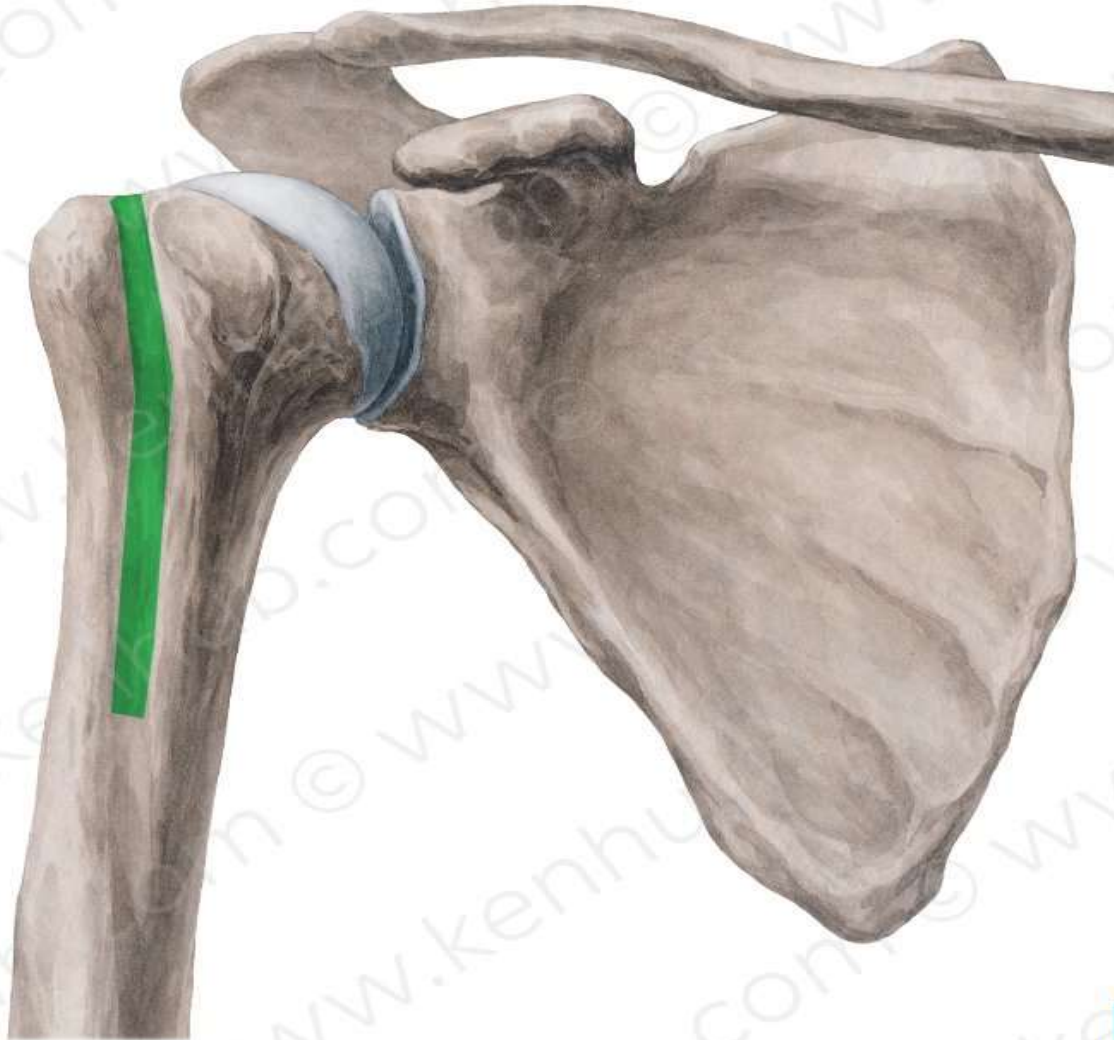




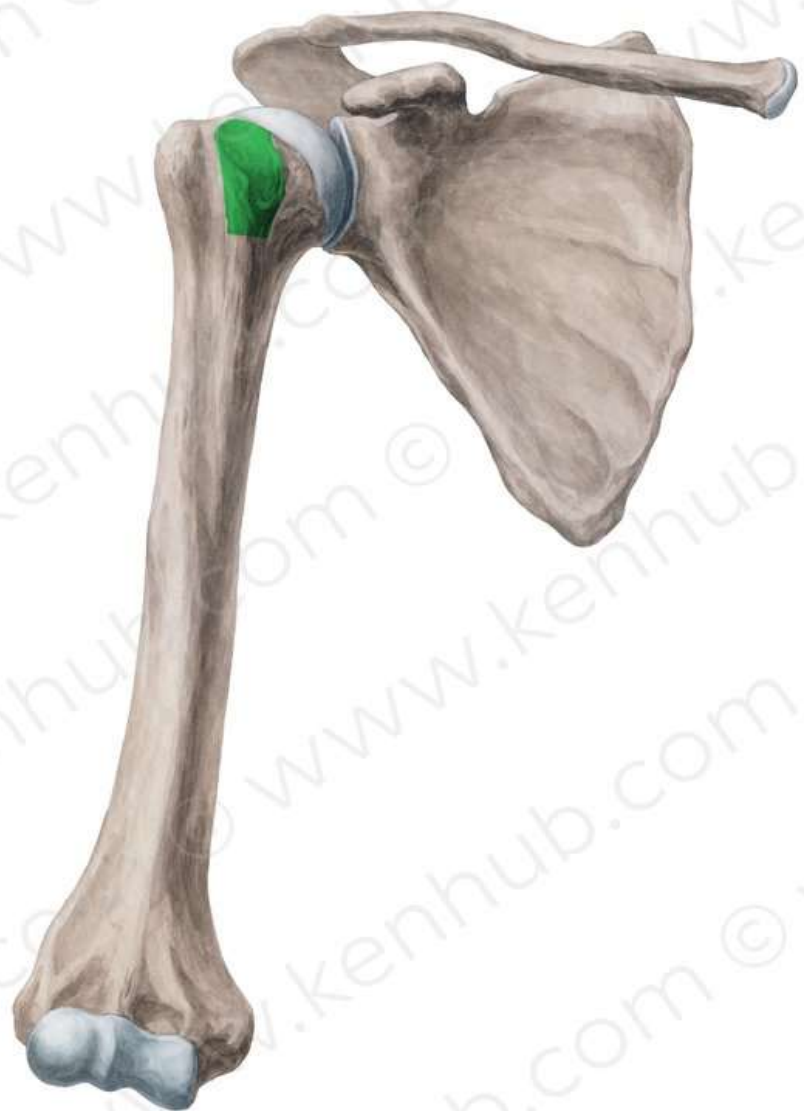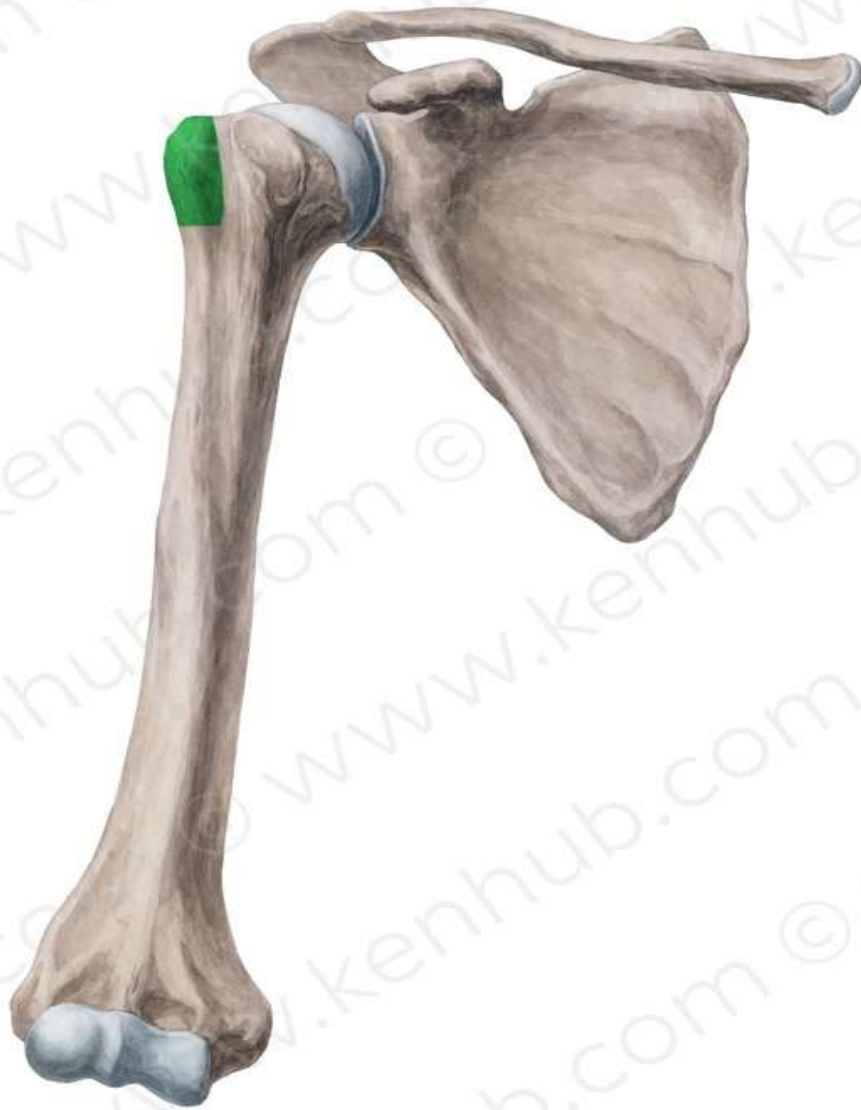


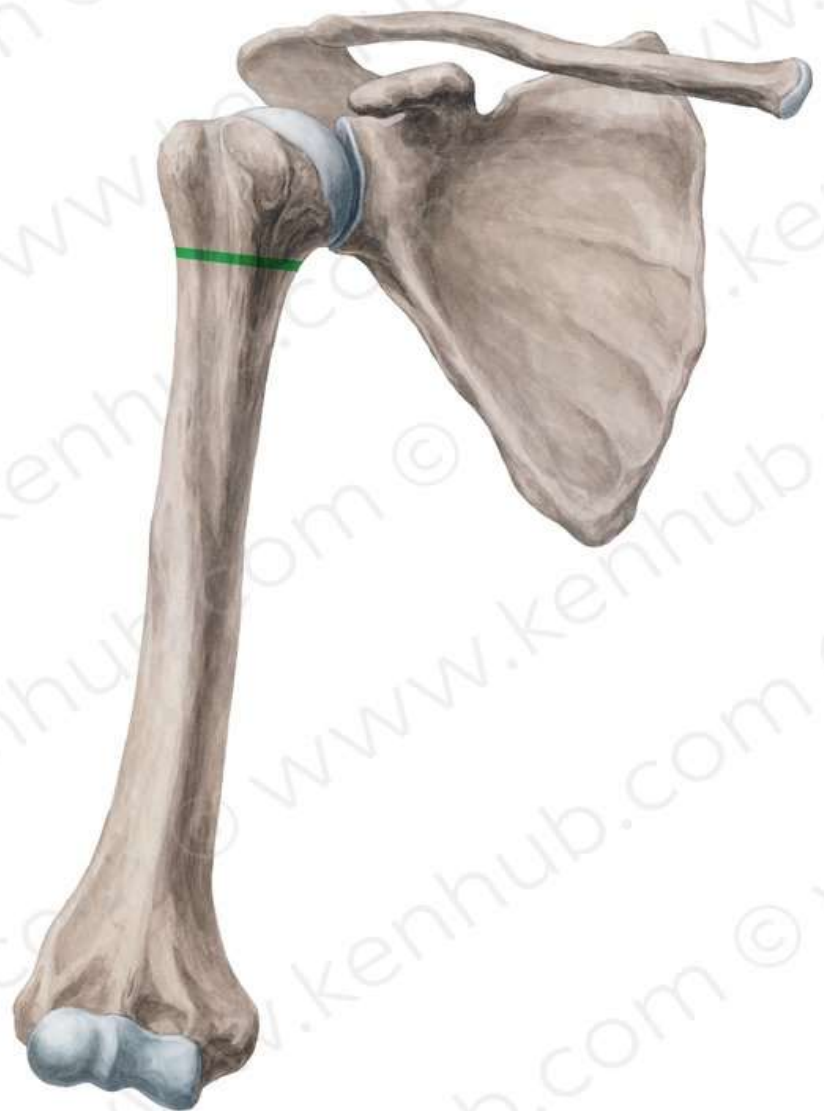


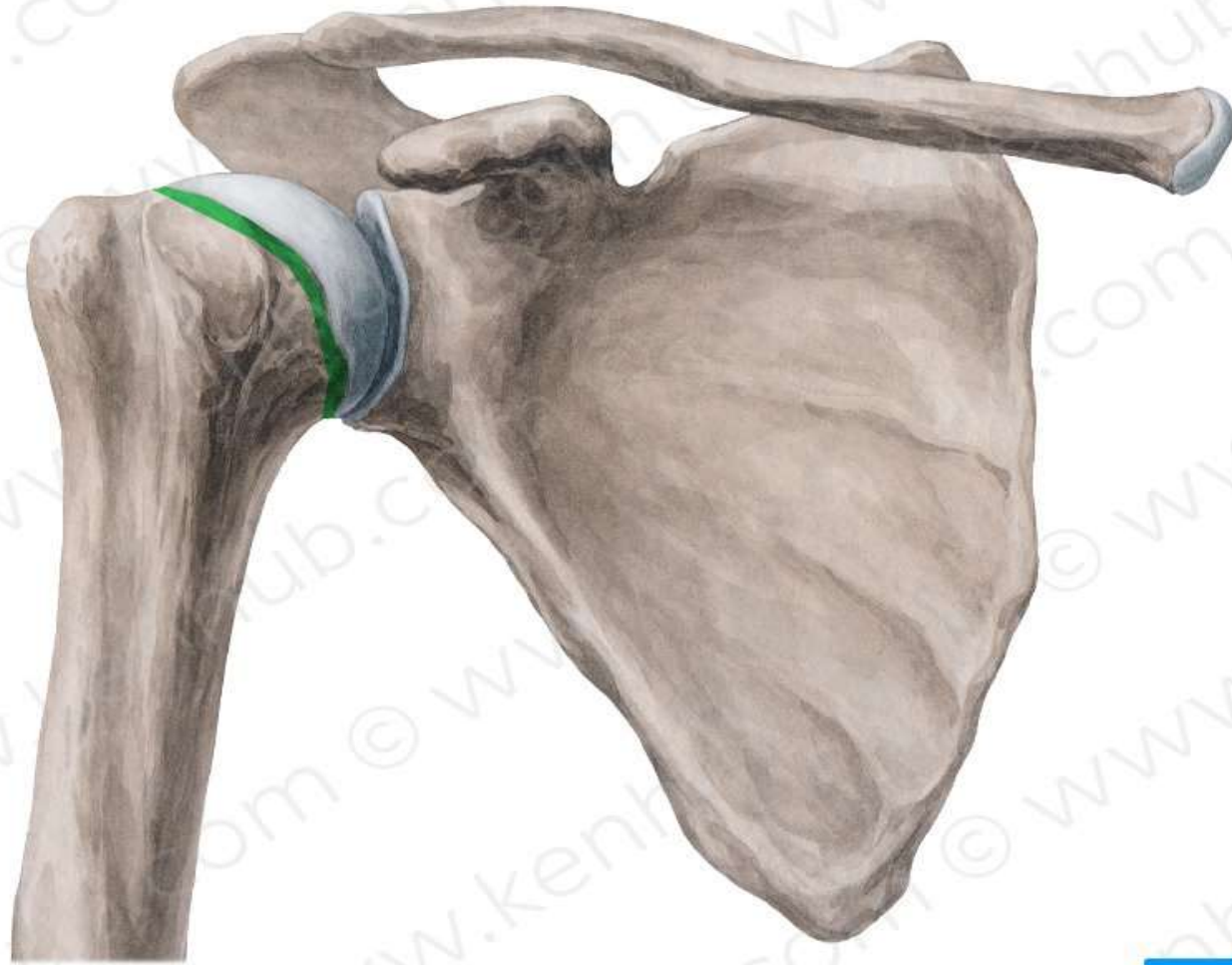


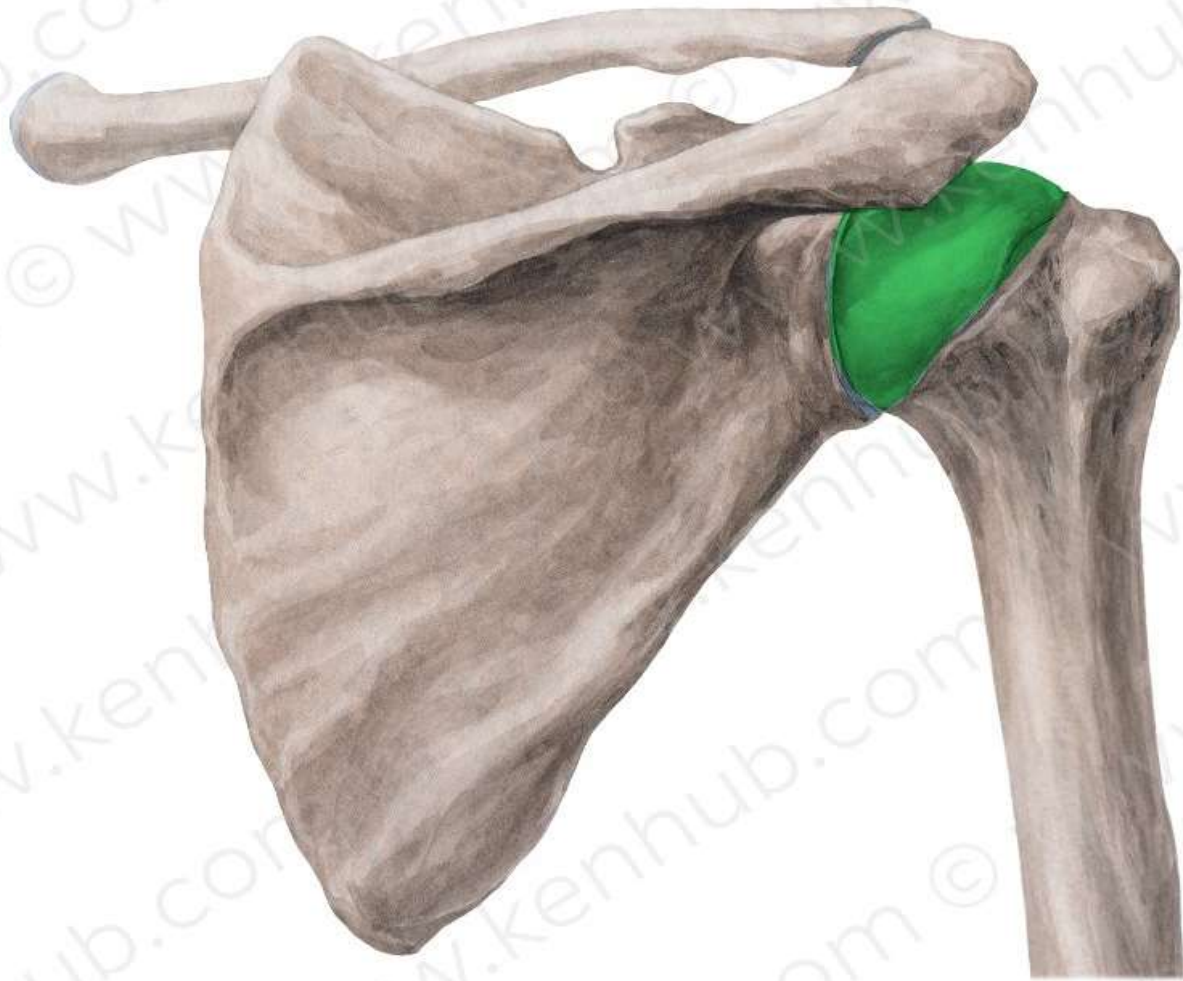









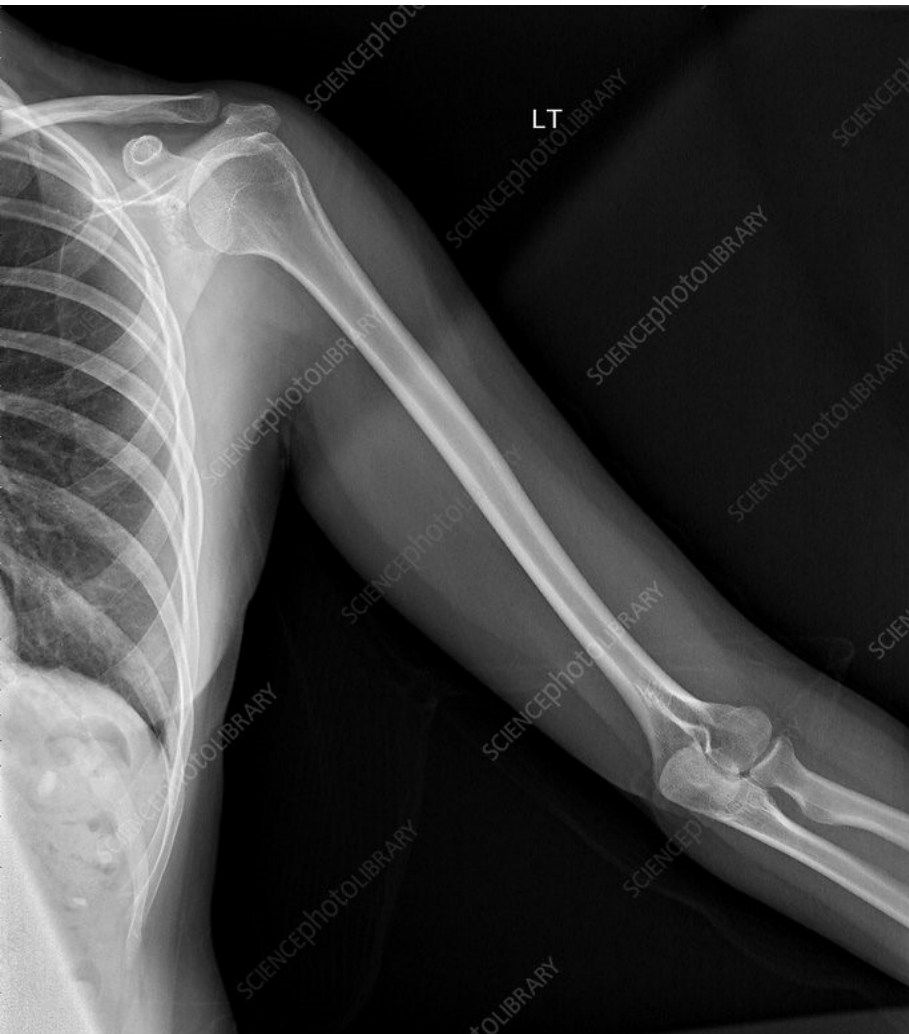


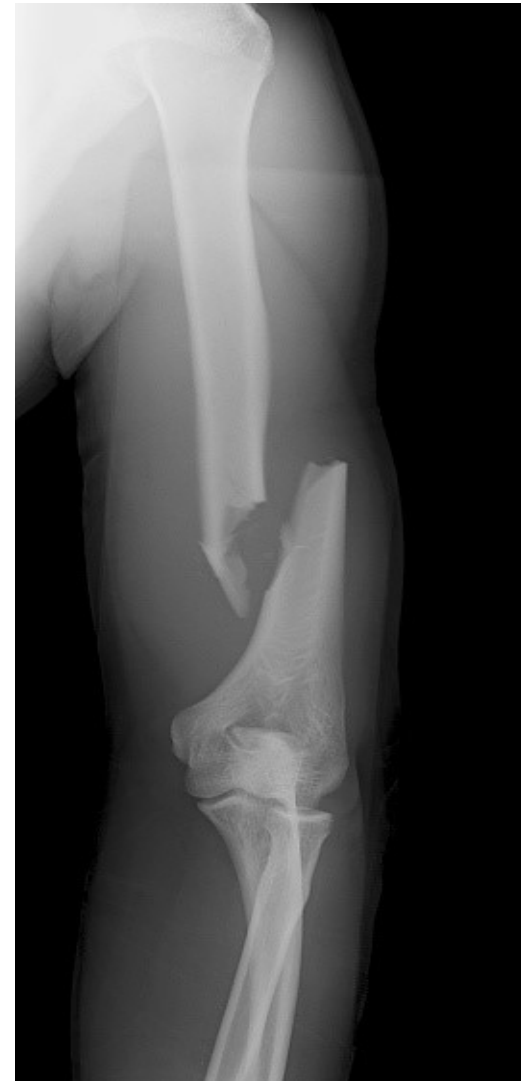X ray Normal



X ray Fracture



The University Of Jordan
Faculty Of Medicine
Anatomy Department

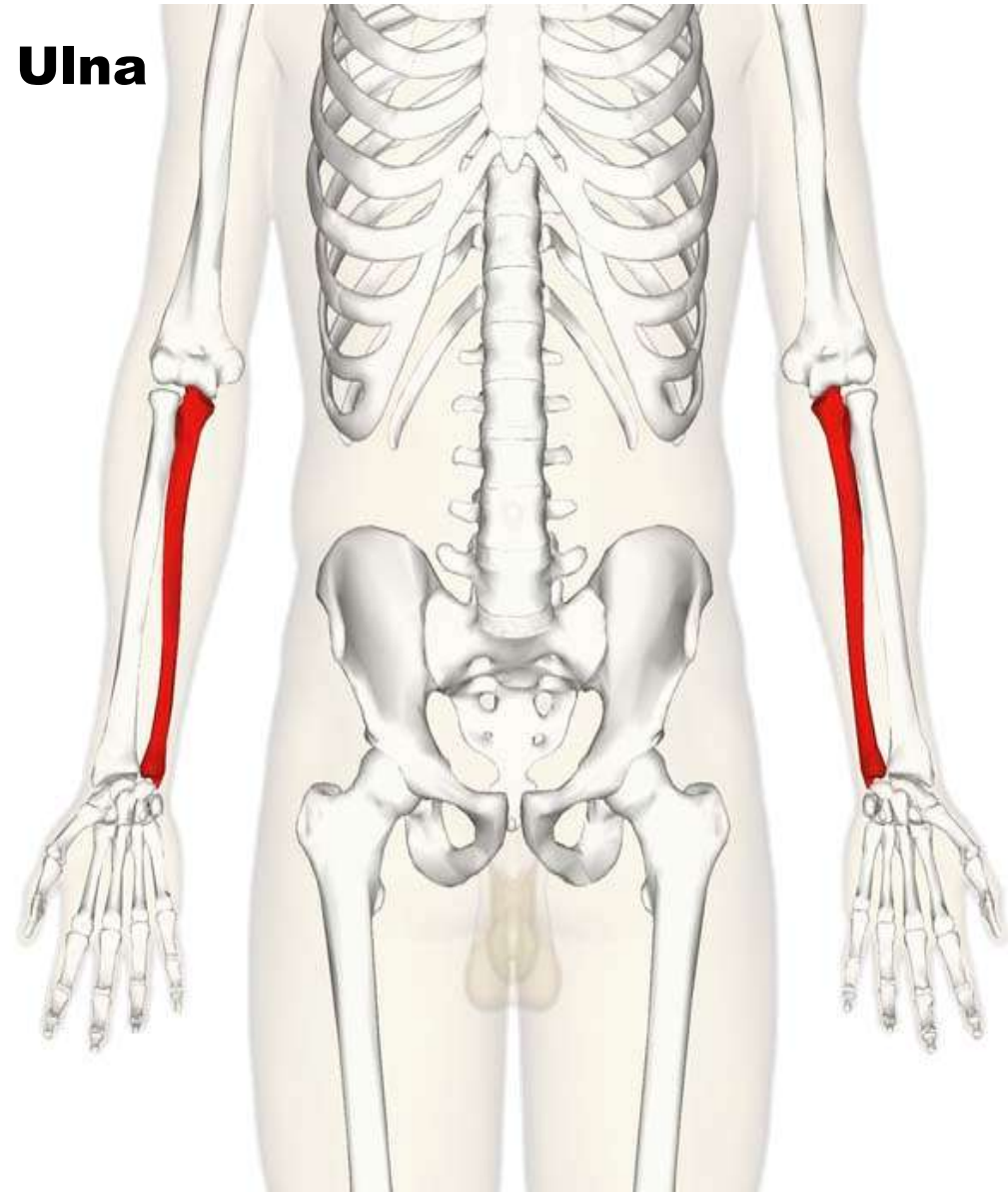


Ulna ,Radius and bones of the hand

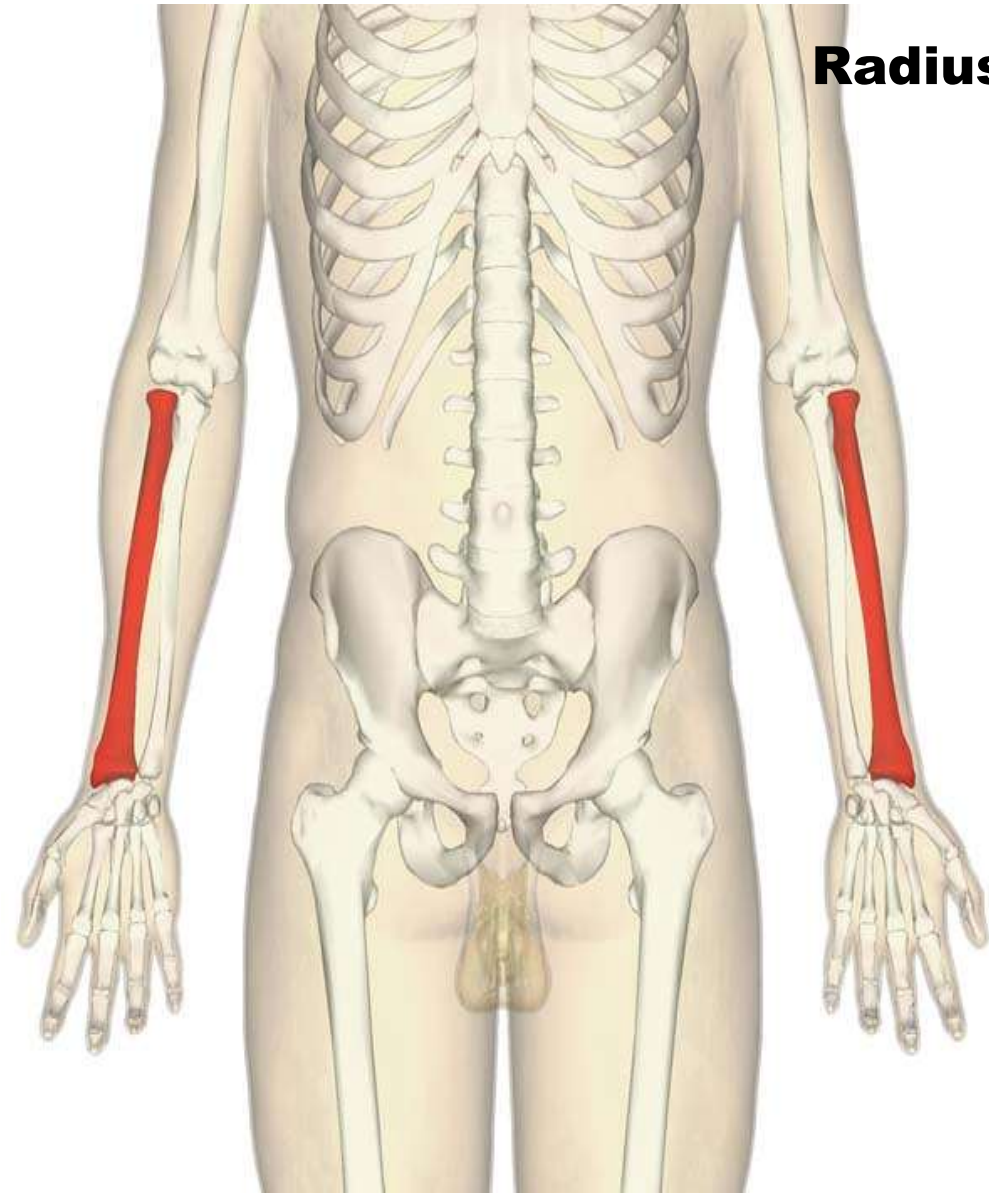
Dr.Ahmed Salman

Associate Prof. of Anatomy. The University Of Jordan

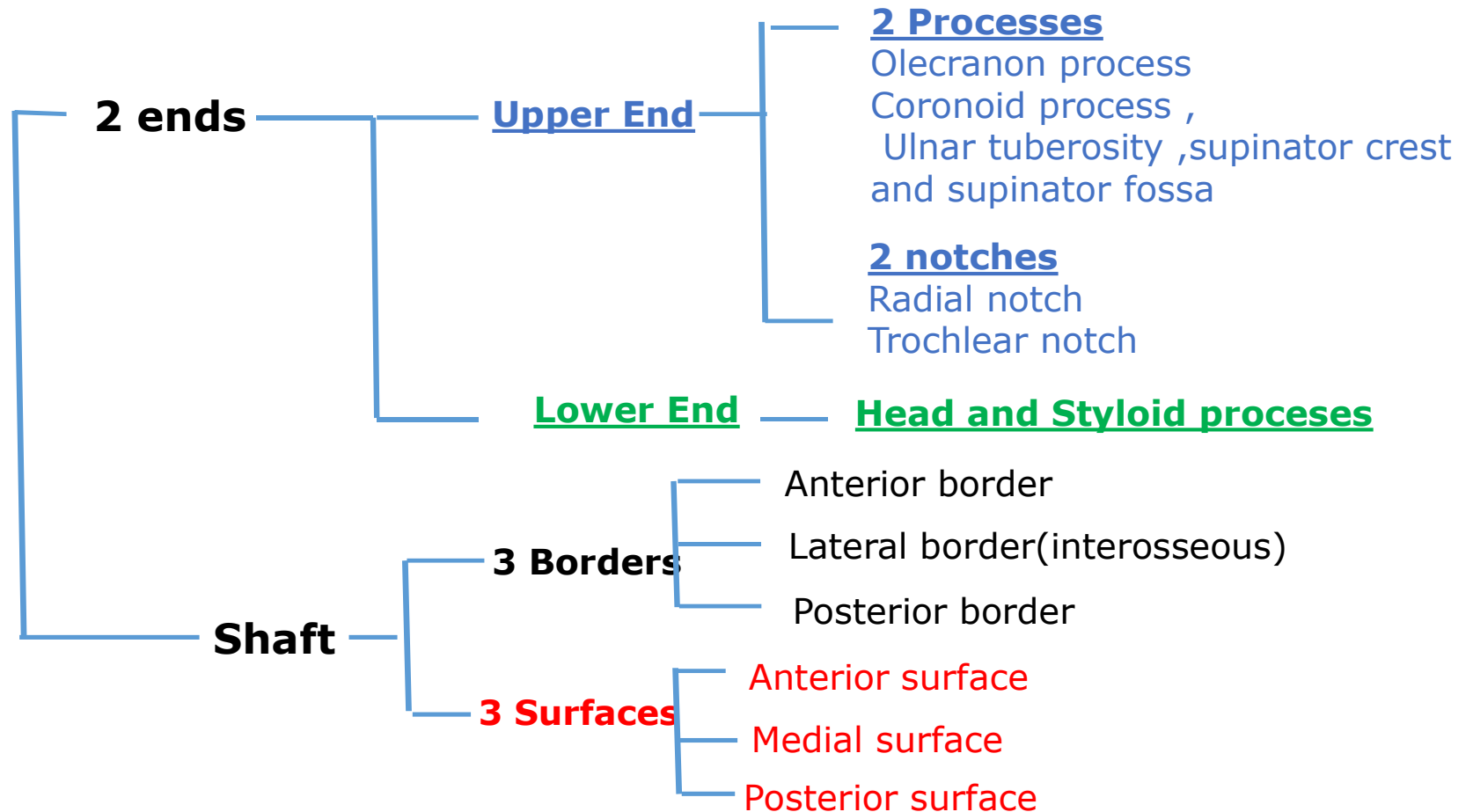
Ulna



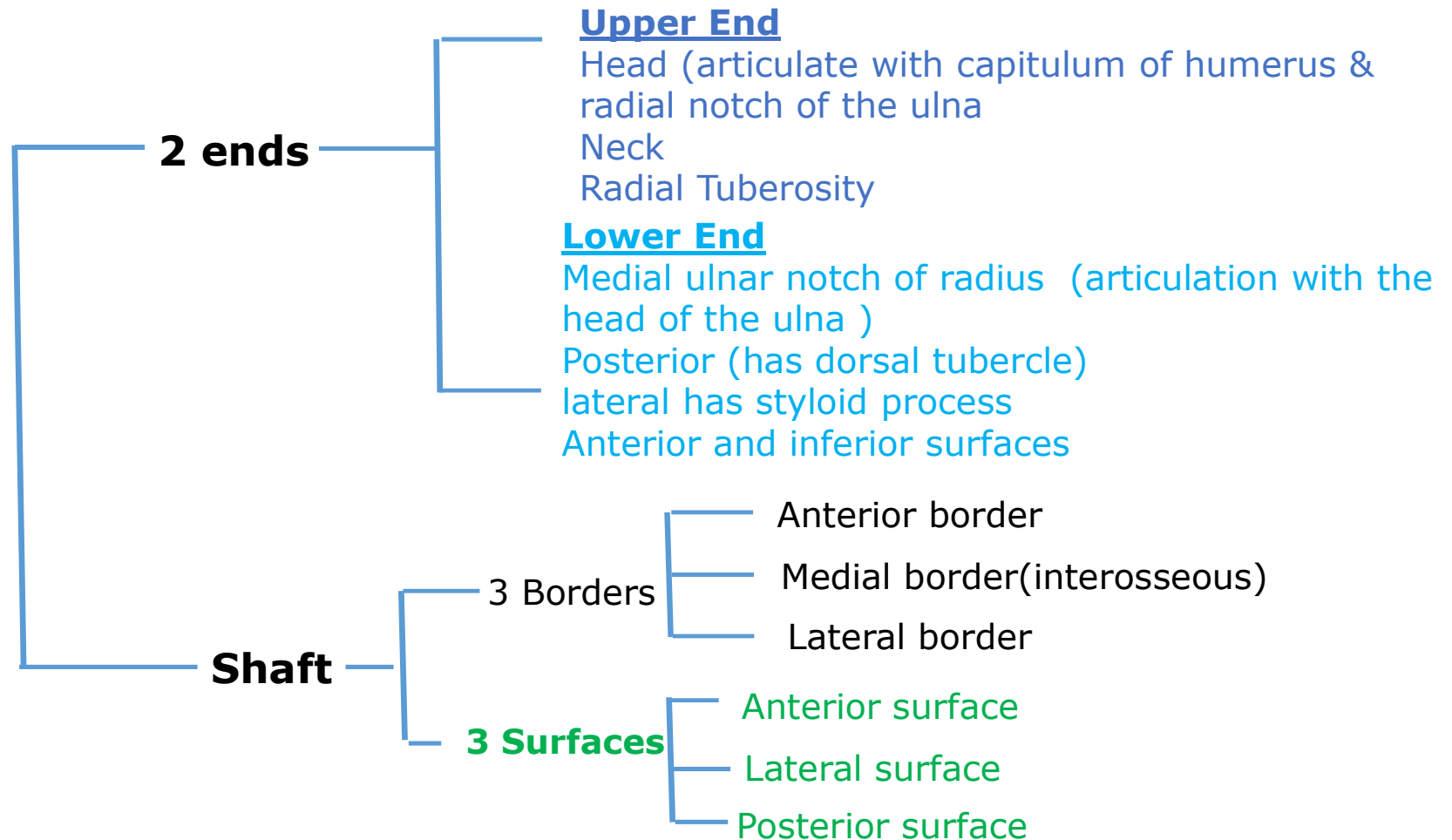
Radius



Ulna

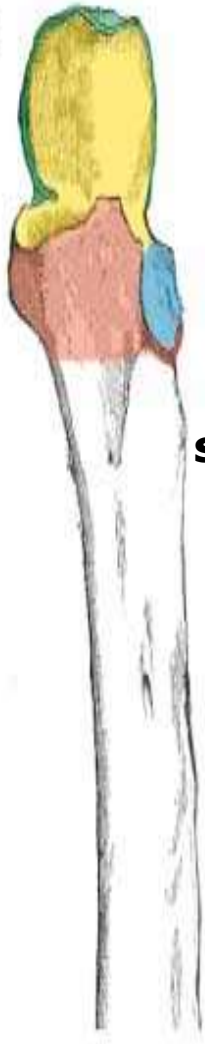

Radius

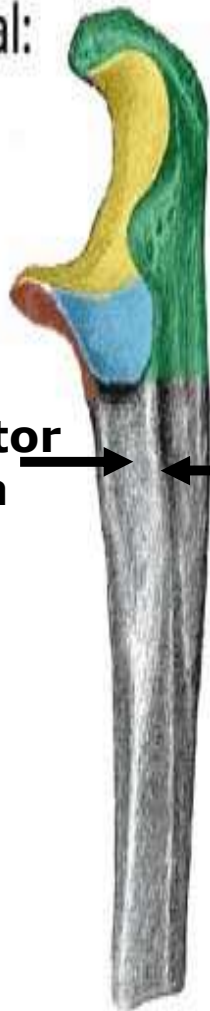




Ulna

Anterior:



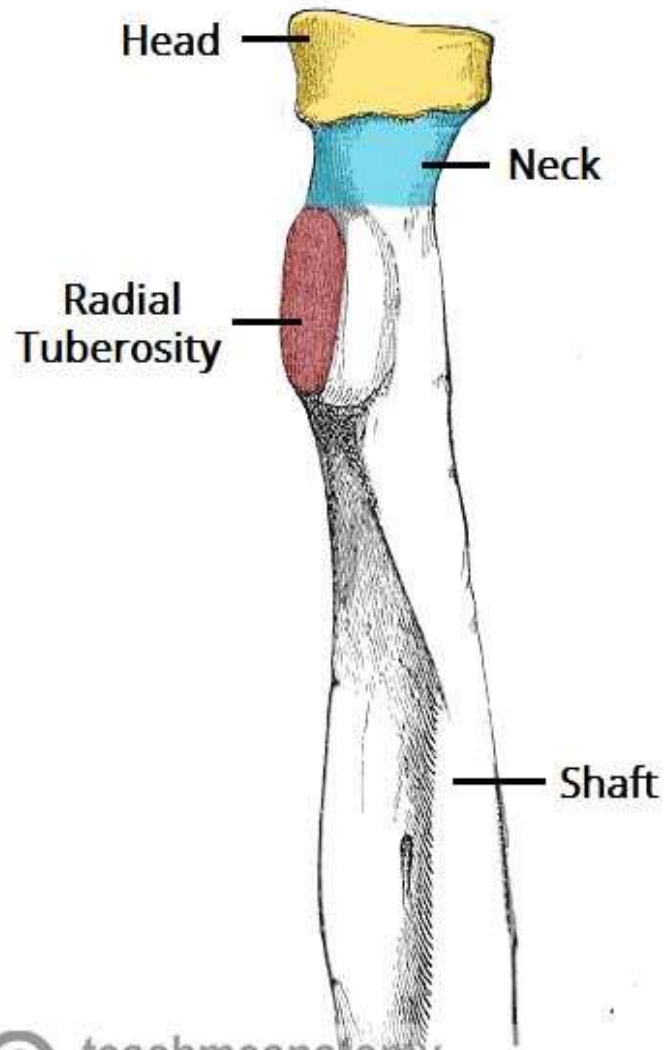
Lateral:

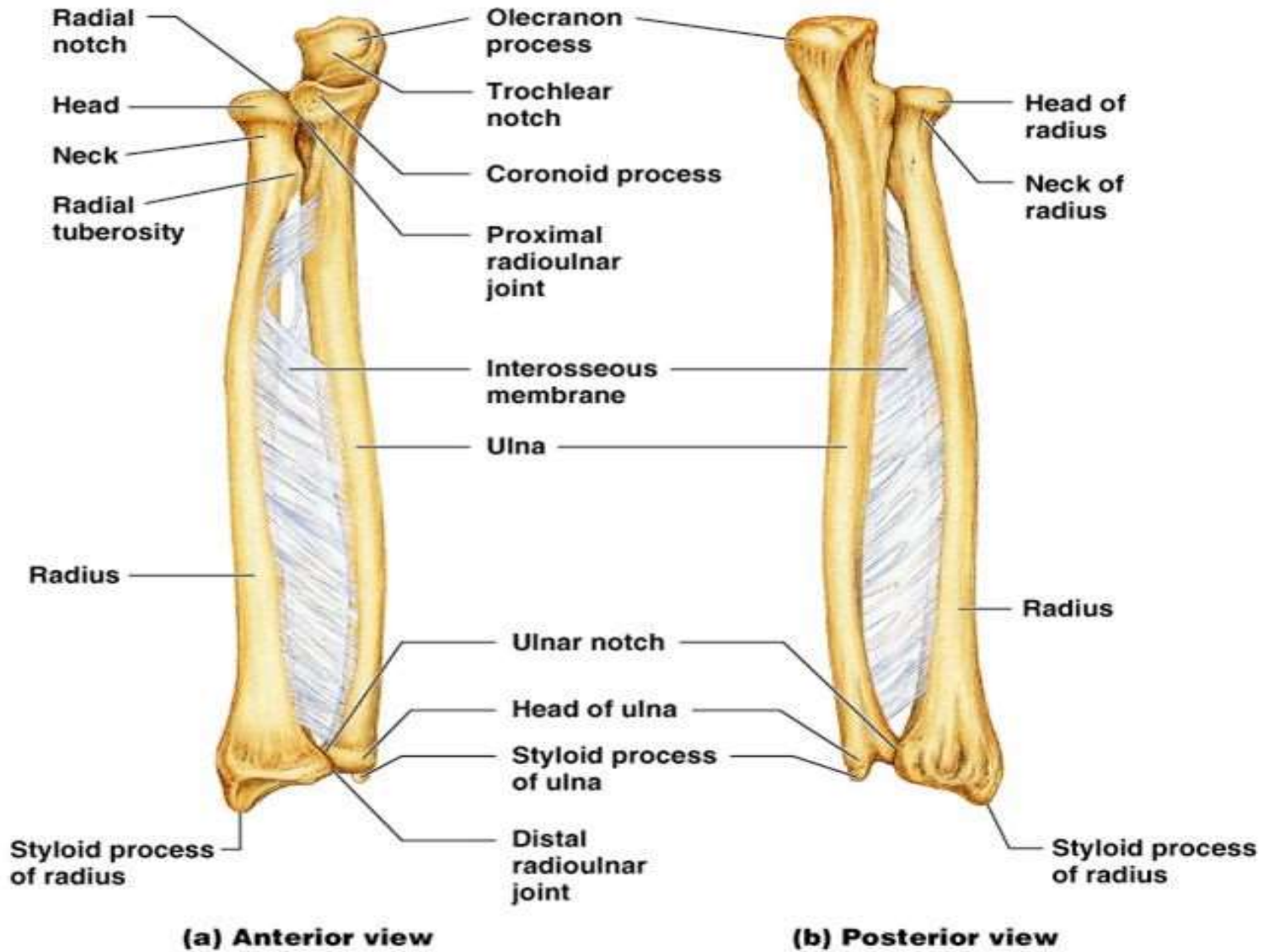
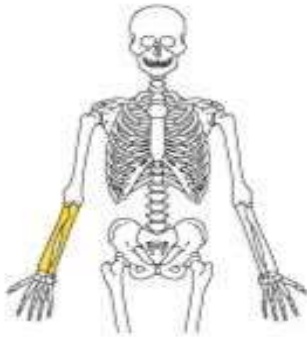

-  Olecranon
-  Coronoid Process
-  Trochlear Notch
-  Radial Notch

supinator
fossa

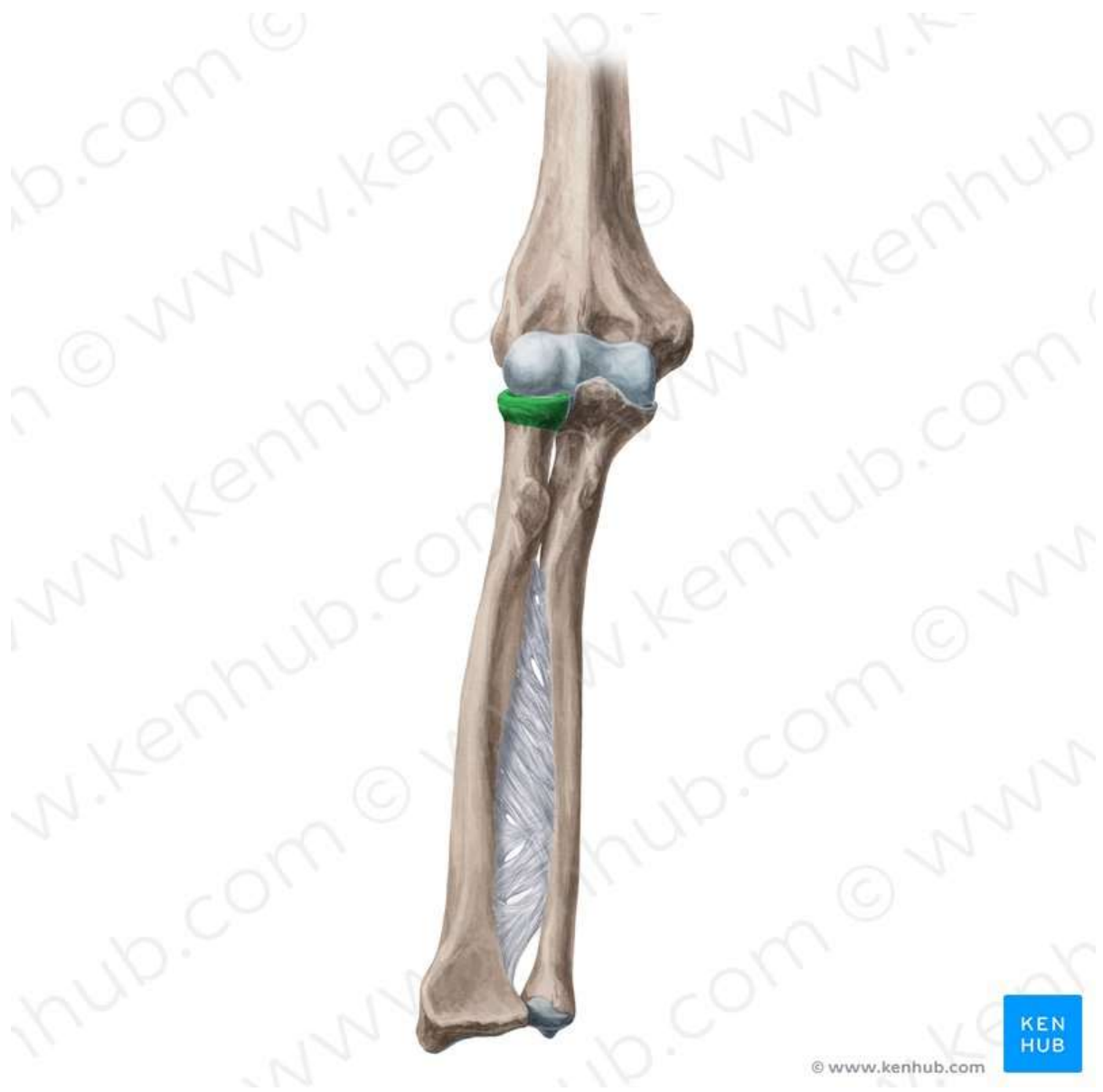supinator crest

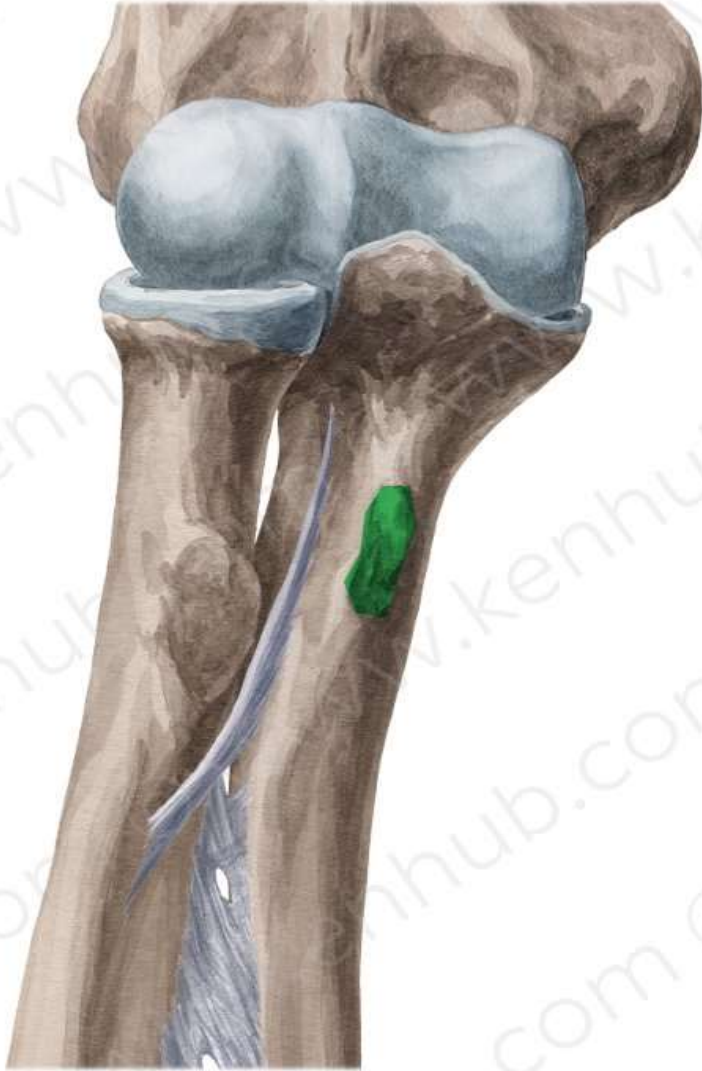

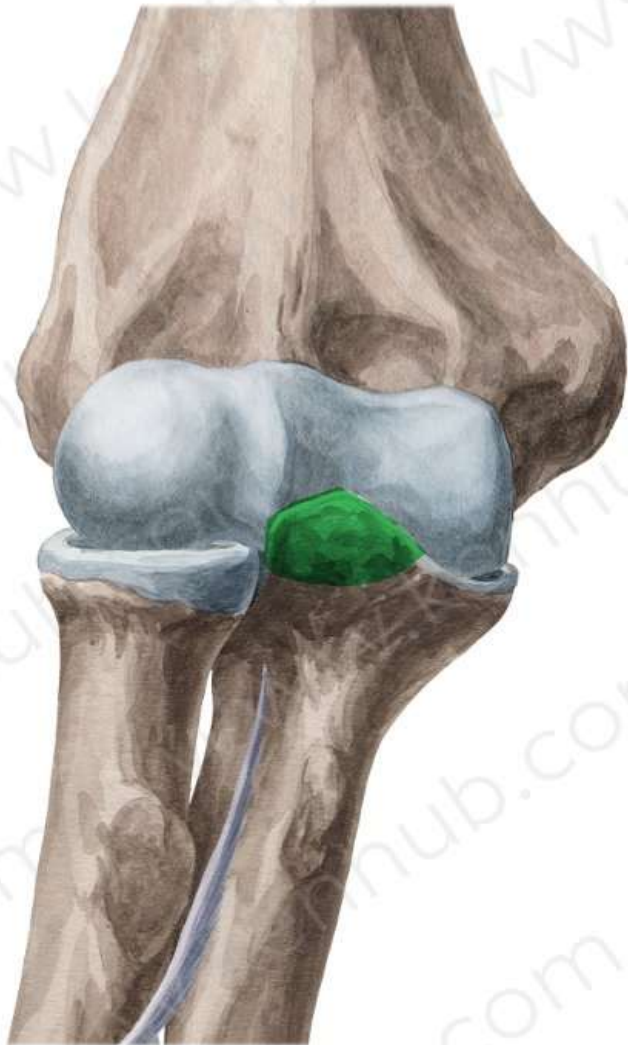


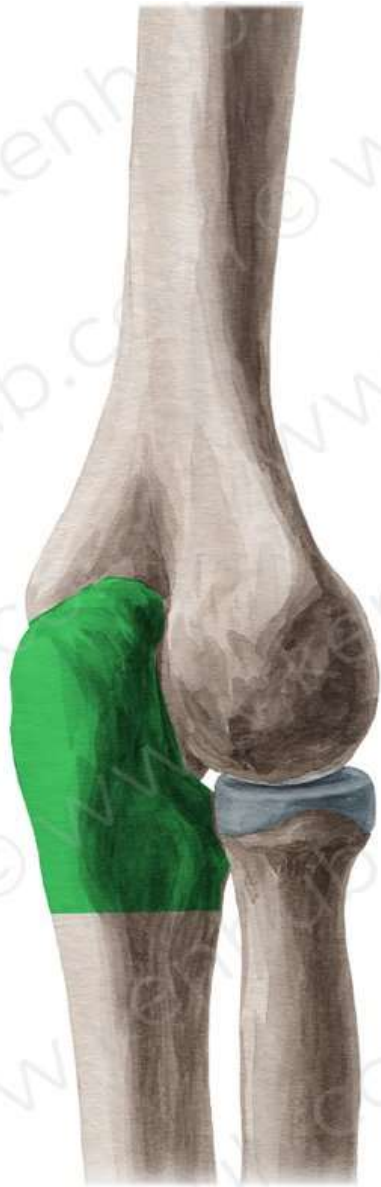TEST YOUR KNOELDGE

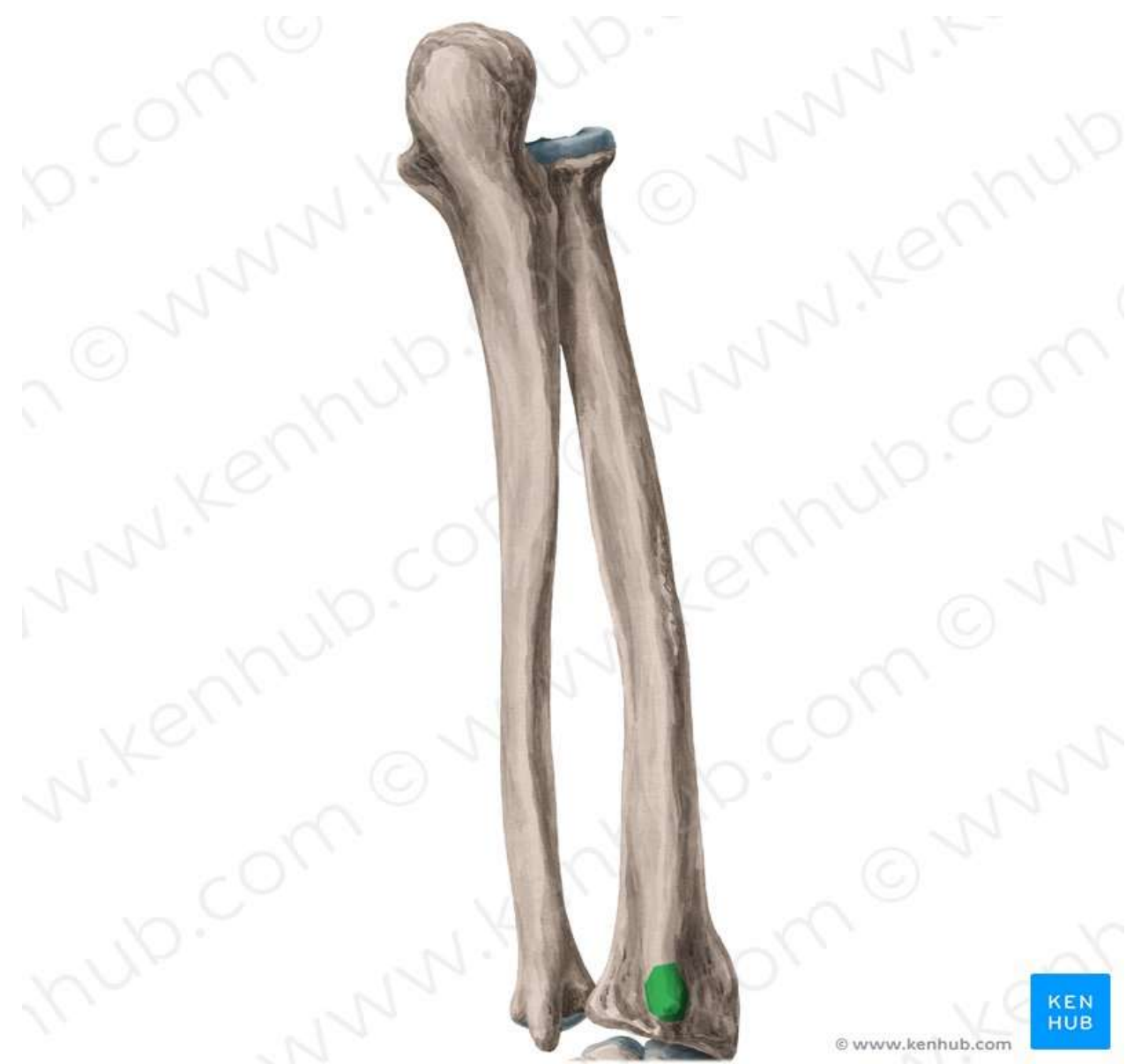https://www.youtube.com/watch?v=eofjk-hGZ_U&list=PLIDhP5E2cVJ2MEO0vCyMj71TraL7BkiZT&index=3

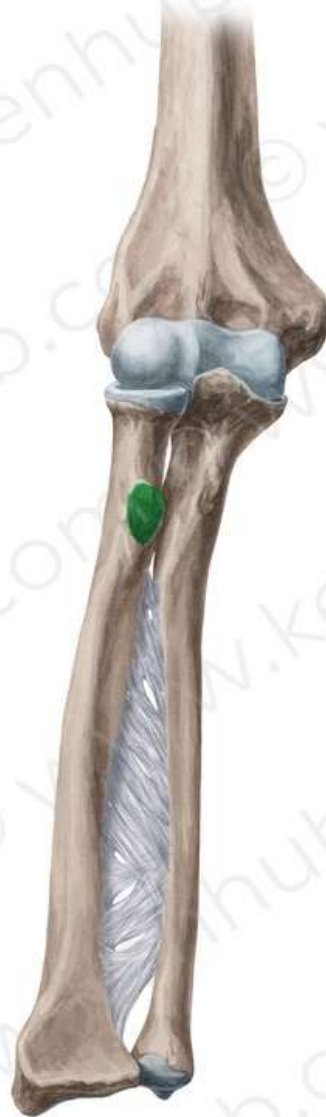


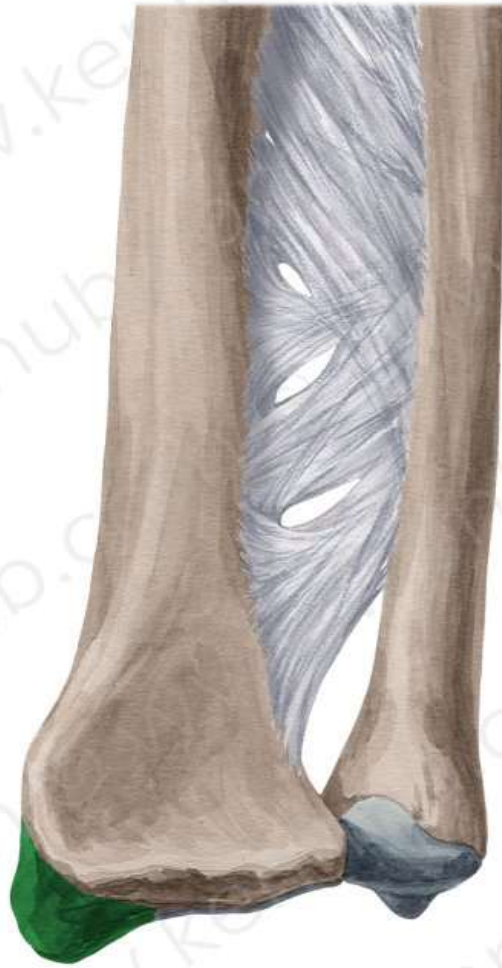


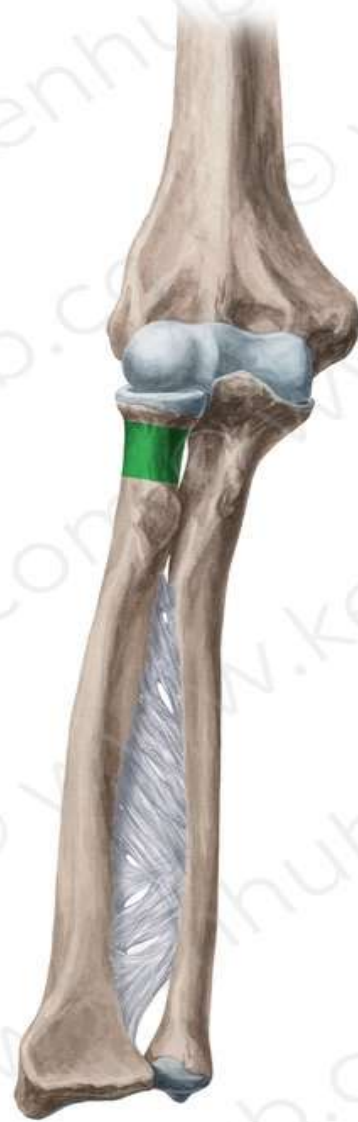




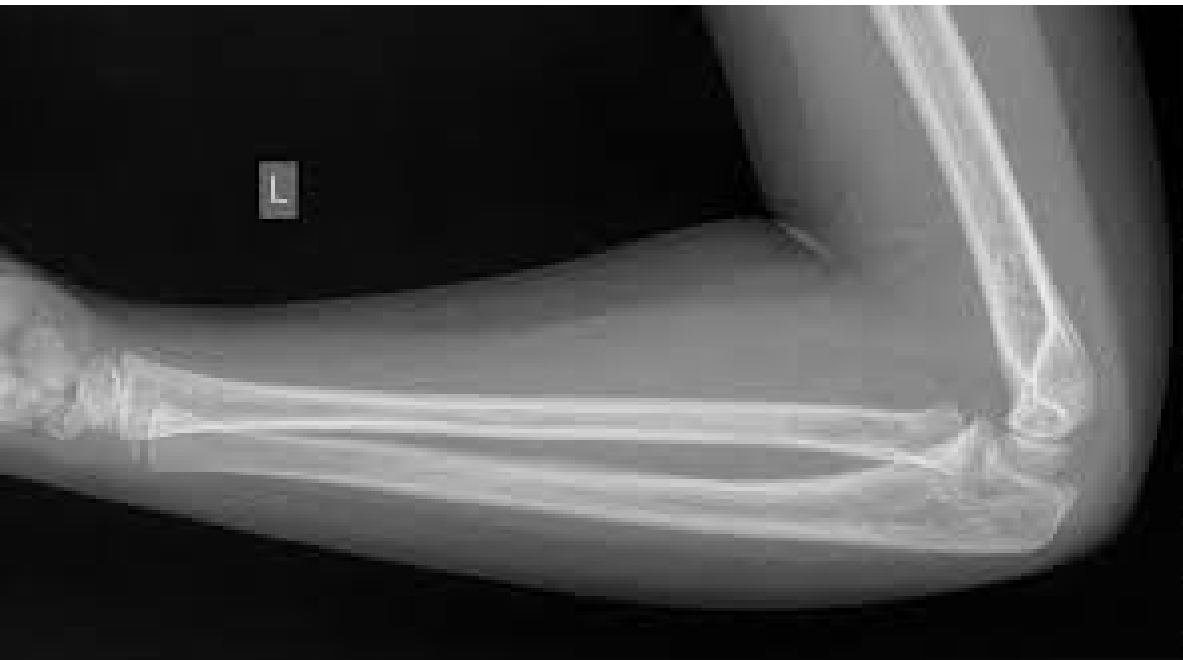




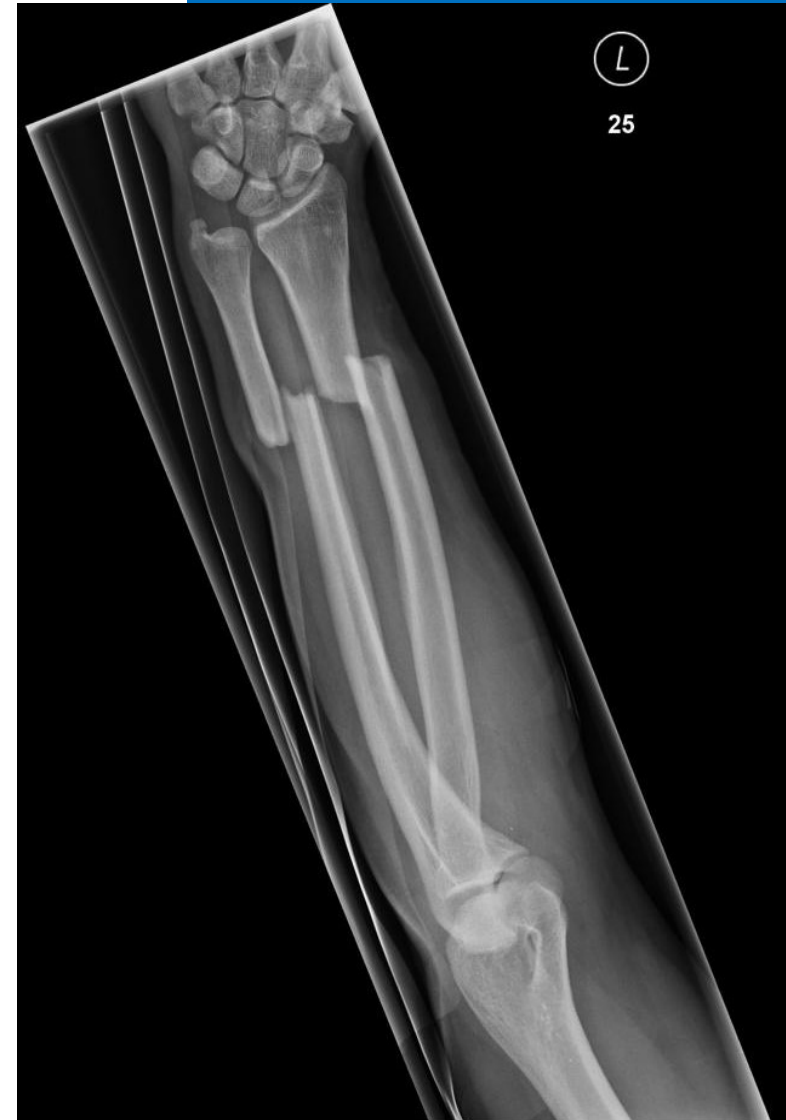X ray Normal



X ray Fracture



THANK YOU