



Bones of the hand ,Muscles of the anterior compartment of the Forearm and cubital fossa

DR.AHMED SALMAN

ASSOCIATE PROF. OF ANATOMY

5th Practical Checklist

Topics: Bones of the hand ,Muscles of the anterior compartment of the Forearm and cubital fossa

Know the origin ,insertion ,nerve supply and action of the following muscles

1- Muscles of anterior compartment of the Forearm

- Pronator teres
- Flexor carpi radialis
- Palmaris longus
- Flexor digitorum superficialis
- Flexor carpi ulnaris
- Flexor digitorum profundus
- Flexor pollicis longus
- Pronator Quadratus

2- Identify bones of hand

3- Identify the boundaries and contents of the cubital fossa

Bones of the hand

Carpal bones

The **proximal row** is formed of 4 bones from lateral to medial:

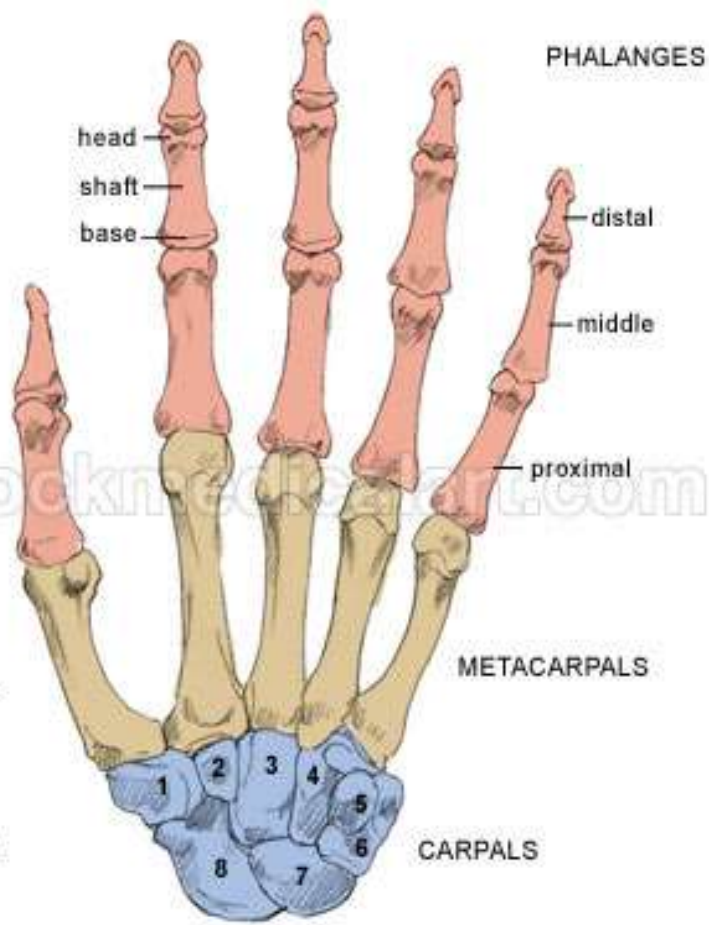
Scaphoid - lunate - triquetrum - **Pisiform.**

The **distal row** is formed of 4 bones from lateral to medial:

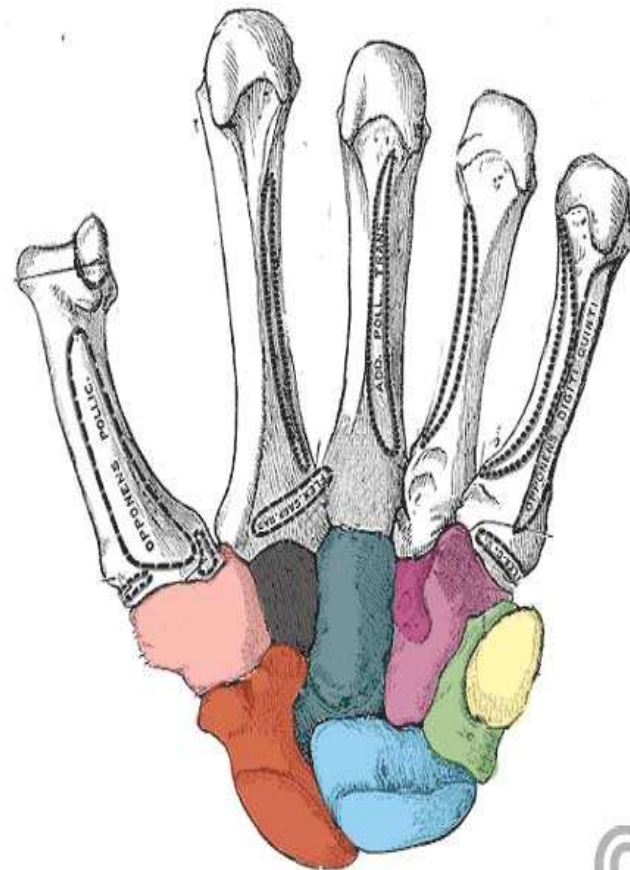
Trapezium - trapezoid - capitate - **Hamate**

5 Metecarpal

14 Phalanges



ANTERIOR VIEW (Palm)

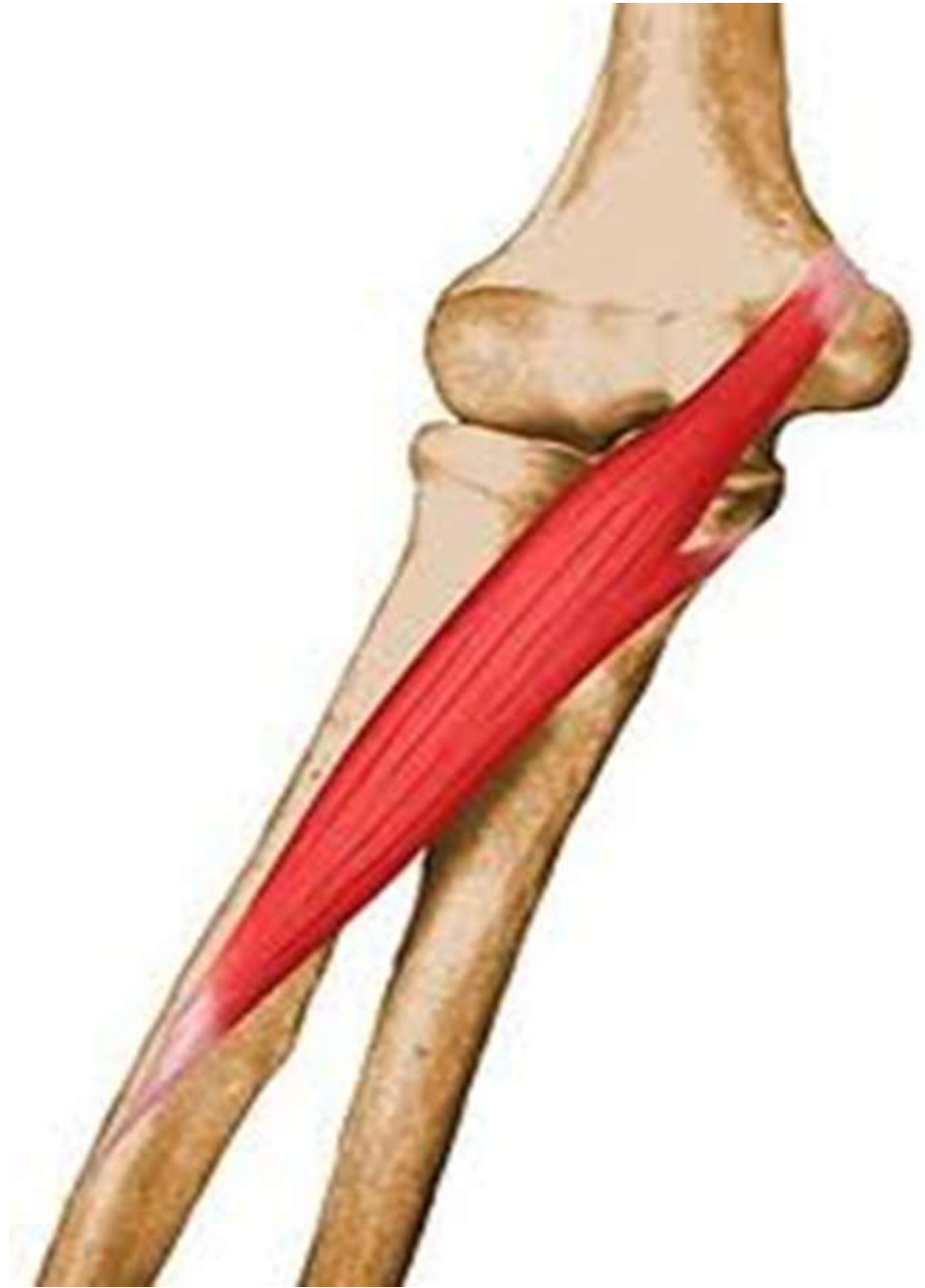

- Scaphoid
- Lunate
- Triquetrum
- Pisiform
- Trapezium
- Trapezoid
- Capitate
- Hamate

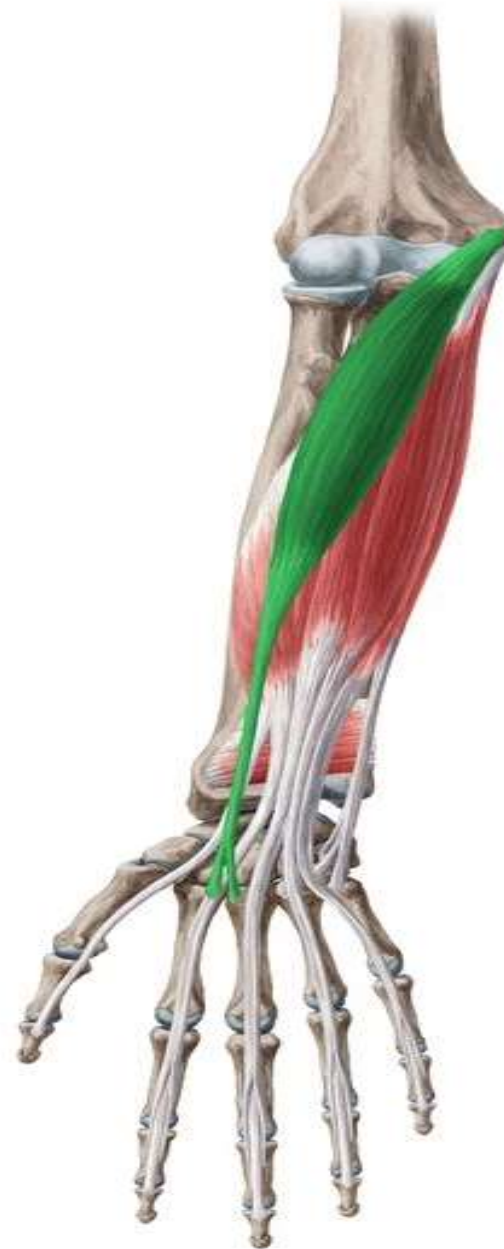Superficial Group

- 1- Pronator teres
- 2- Flexor carpi radialis
- 3- Palmaris longus
- 4- Flexor carpi ulnaris

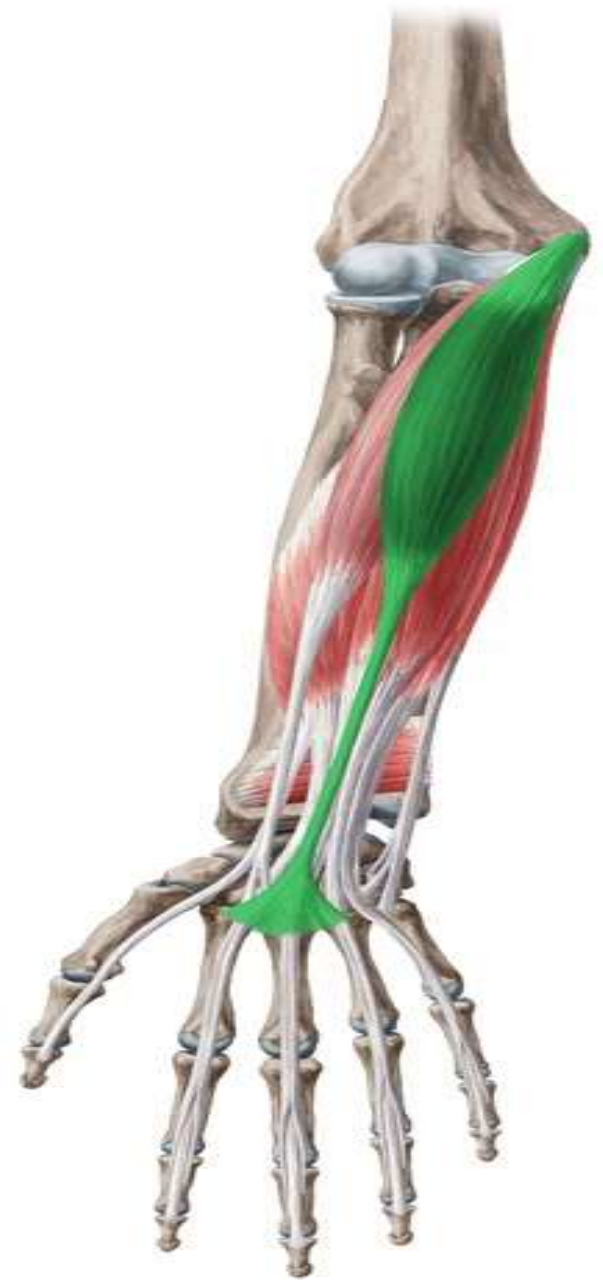Pronator teres



Flexor carpi radialis



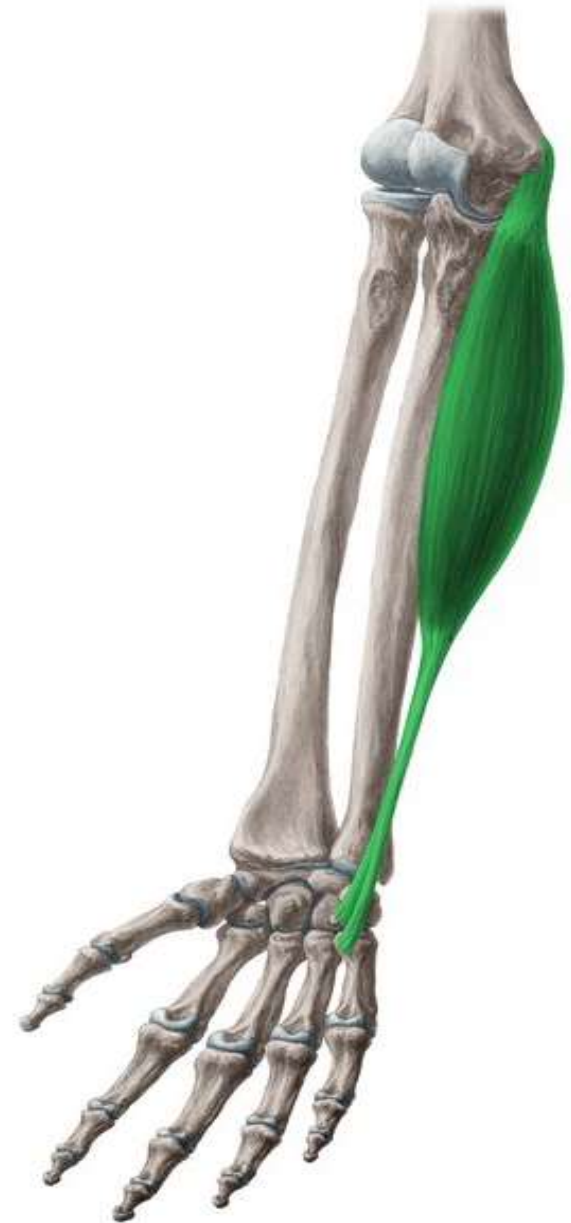Palmaris longus



Flexor digitorum superficialis



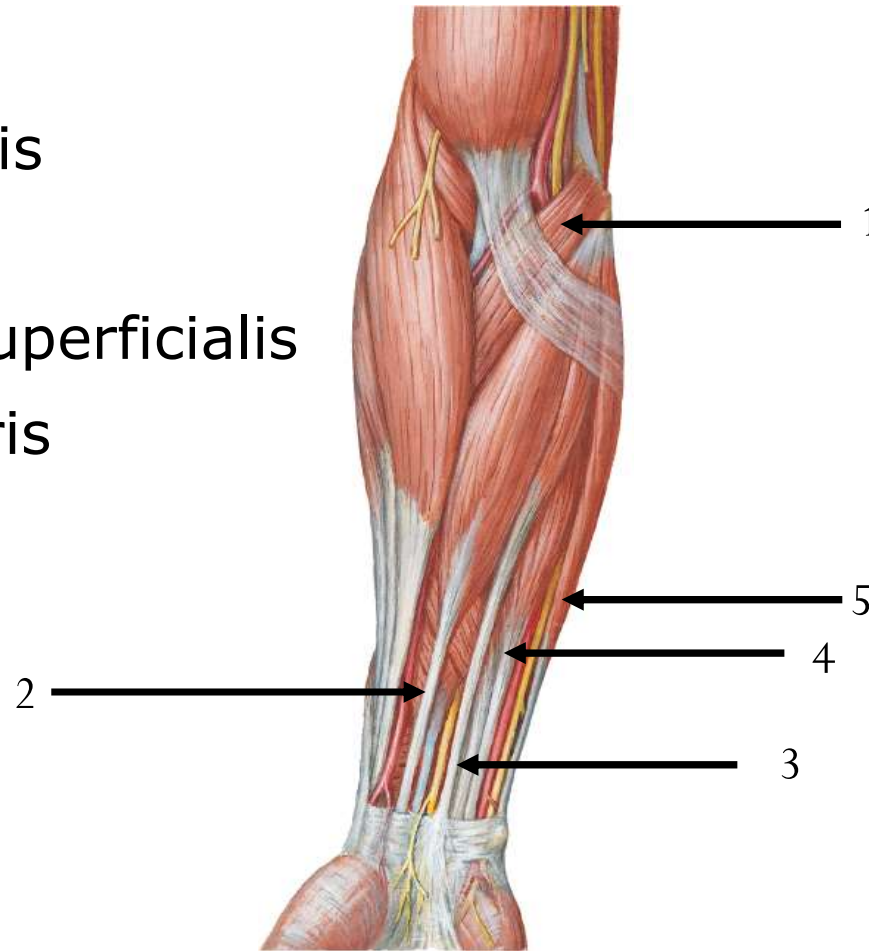
Flexor carpi ulnaris



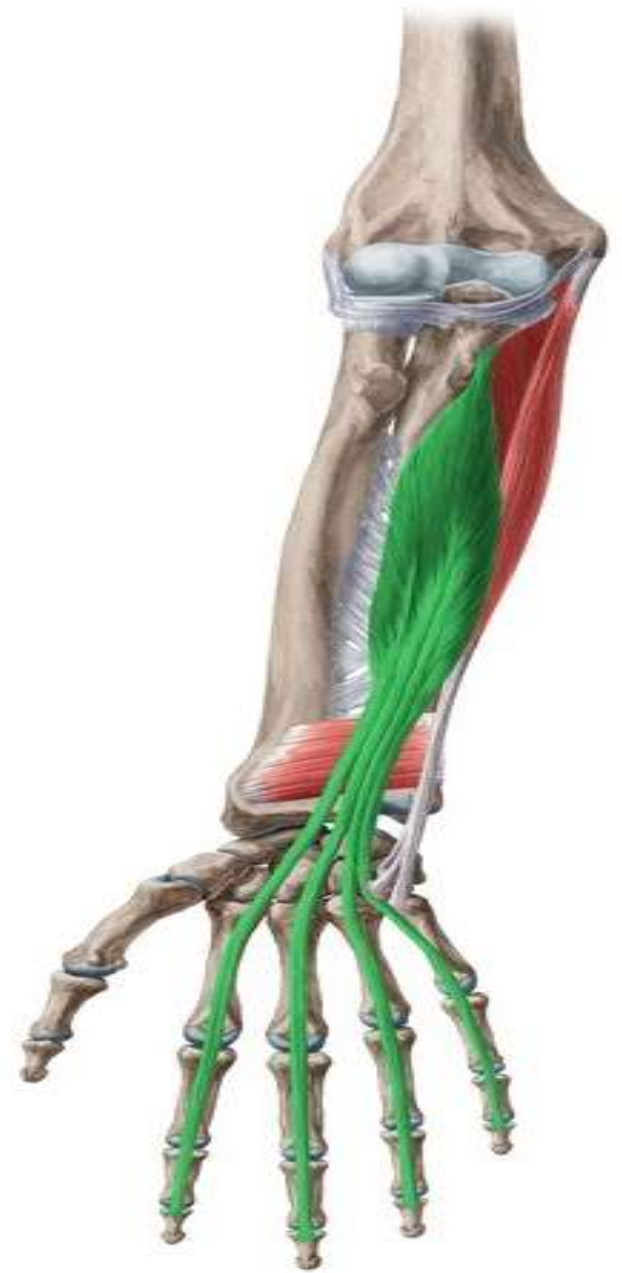Lateral

Medial

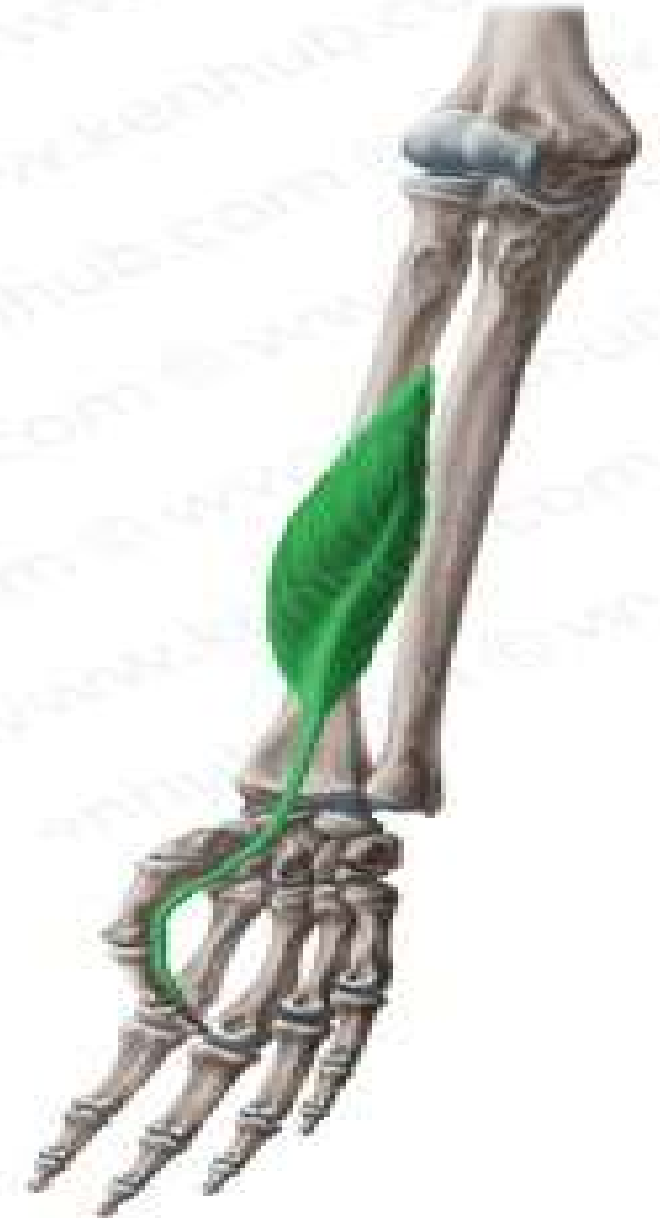- 1- Pronator teres
- 2-Flexor carpi radialis
- 3-Plmaris longus
- 4-Flexor digitorum superficialis
- 5- Flexor carpi ulnaris



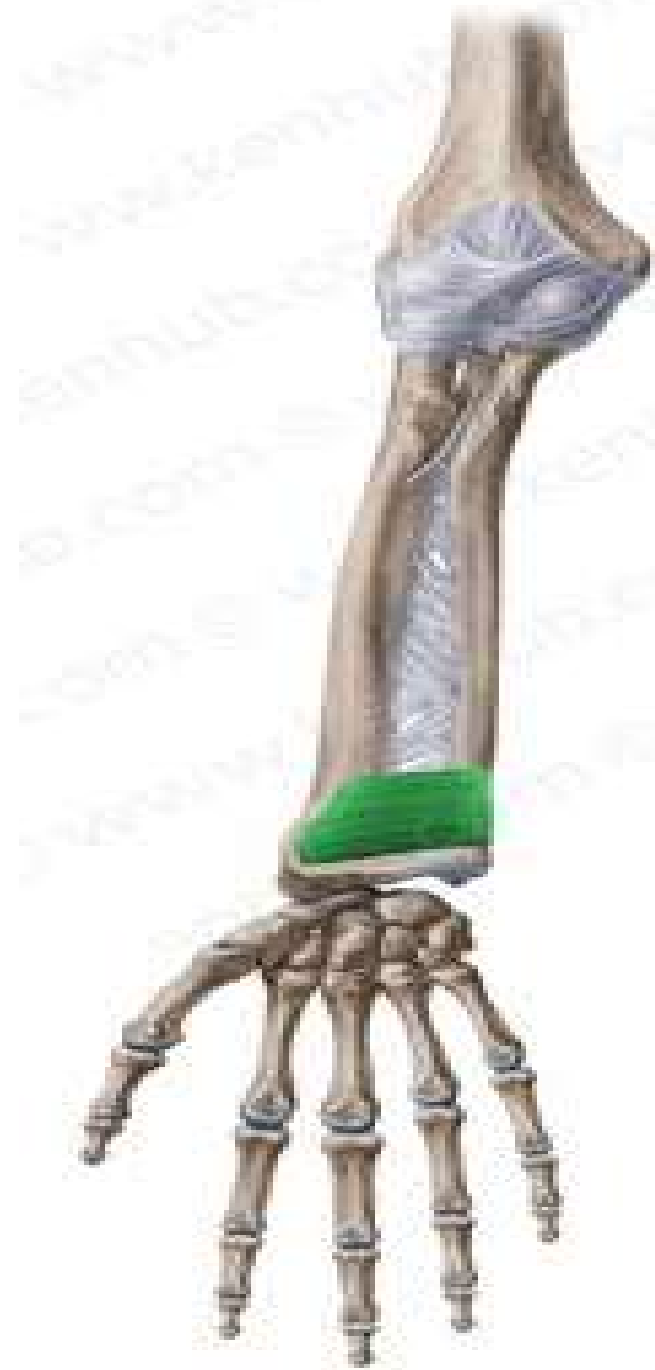Flexor digitorum Profundus



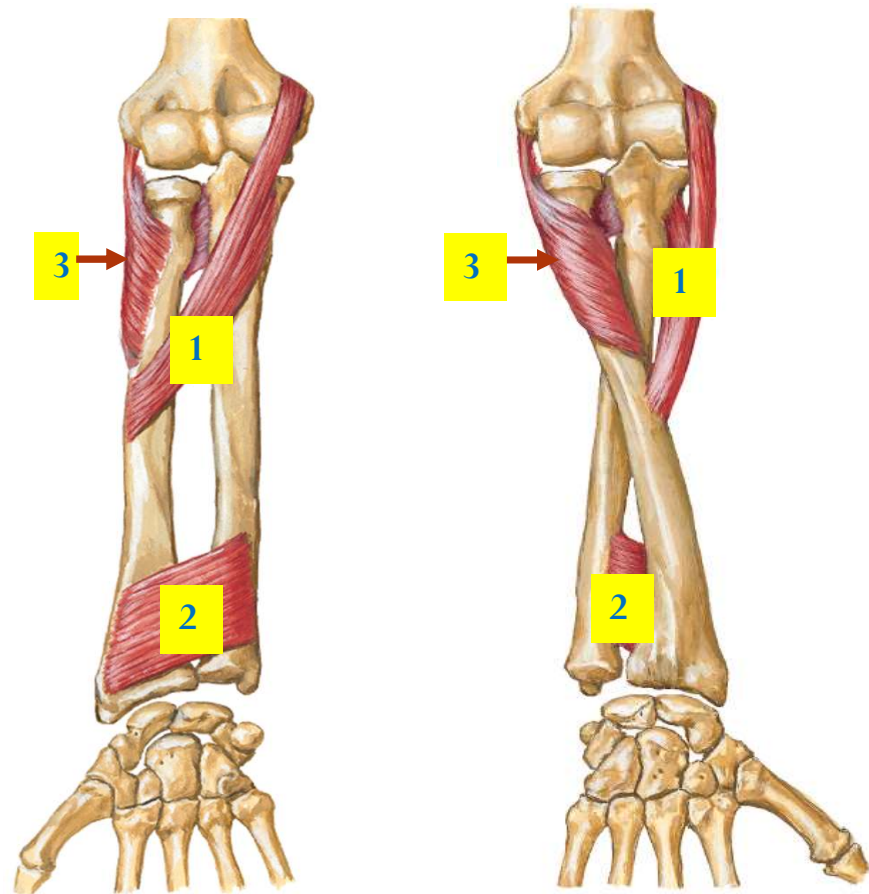
Flexor pollicis longus



Pronator Quadratus



- 1- Pronator teres
- 2- Pronator quadratus
- 3- Supinator



Supinated Forearm

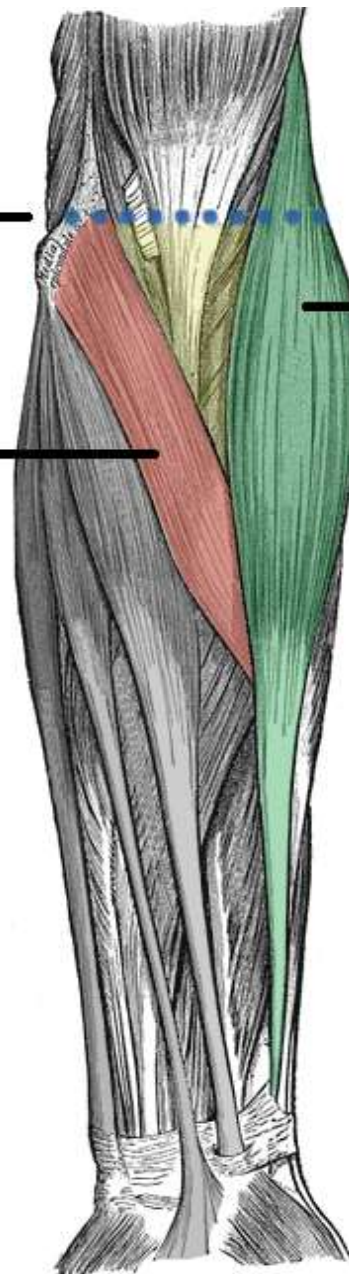
Pronated Forearm

Cubital fossa

Medial epicondyle
(superior border)

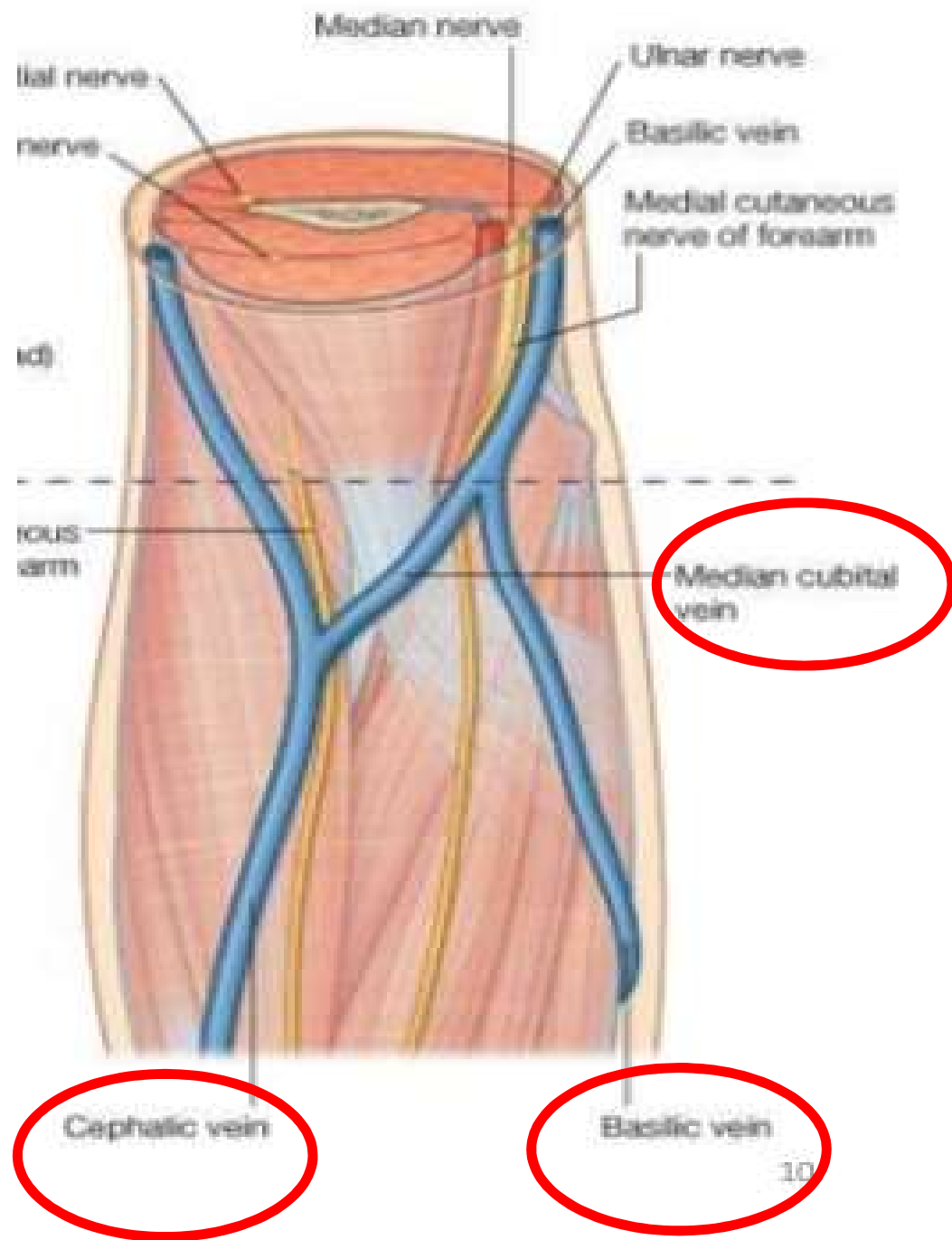
Pronator teres
(medial border)

Brachioradialis
(Lateral border)



Medial

Lateral



Contents

