

Flexor Retinaculum

It is a thickened strong fibrous crosses in front of the carpus and converts its anterior concavity into the carpal tunnel



dreamstime.com

Flexor Retinaculum Attachment

Lateral		Medial
Scaphoid		Pisiform
Trapezium		Os of Hamate

Structure pass superficial to Flexor Retinaculum

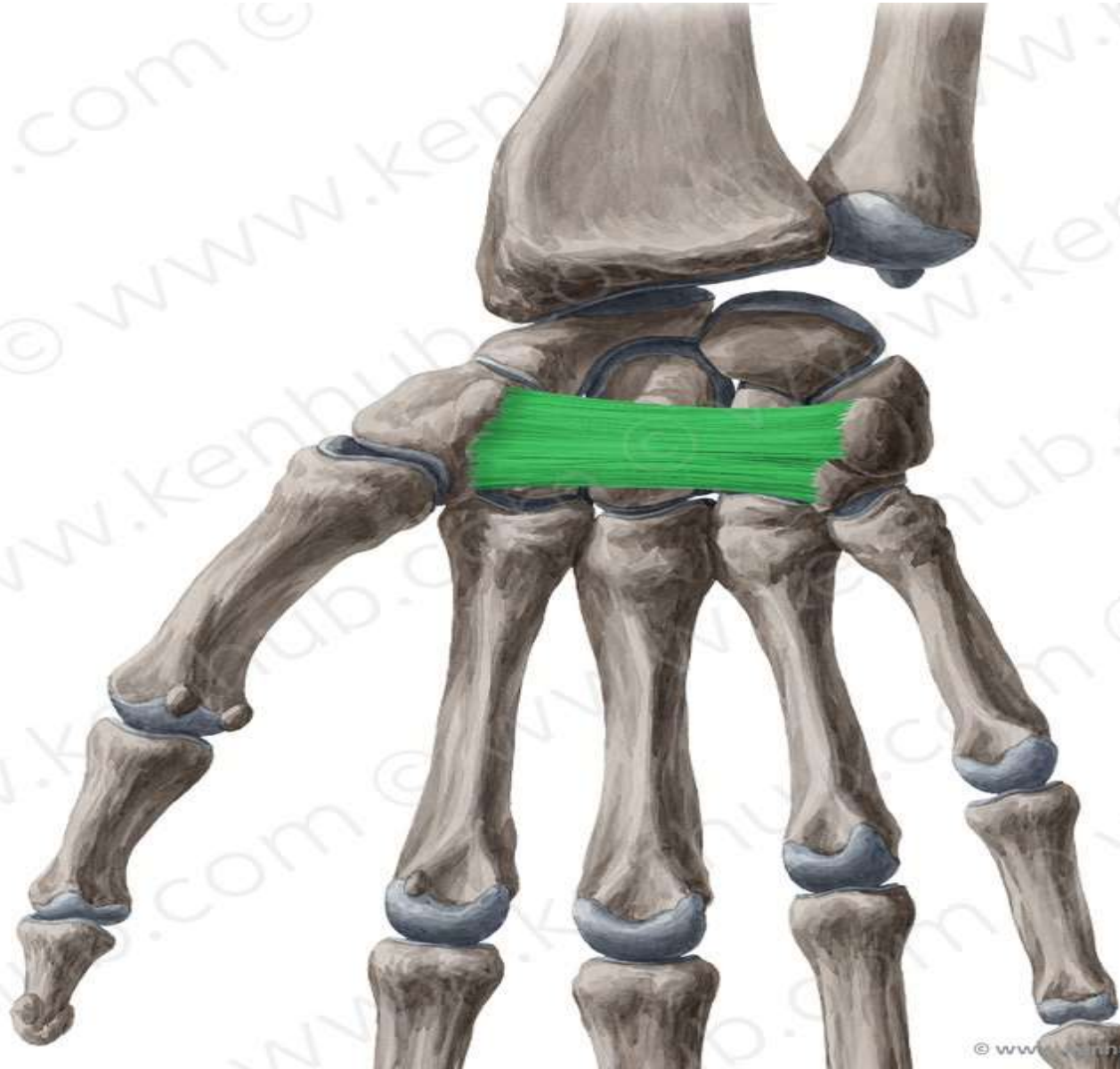- 1- Ulnar artery
- 2- Ulnar nerve
- 3- Palmar cutaneous branch of Ulnar nerve
- 4- Palmar cutaneous branch of median nerve
- 5- Palmaris longus

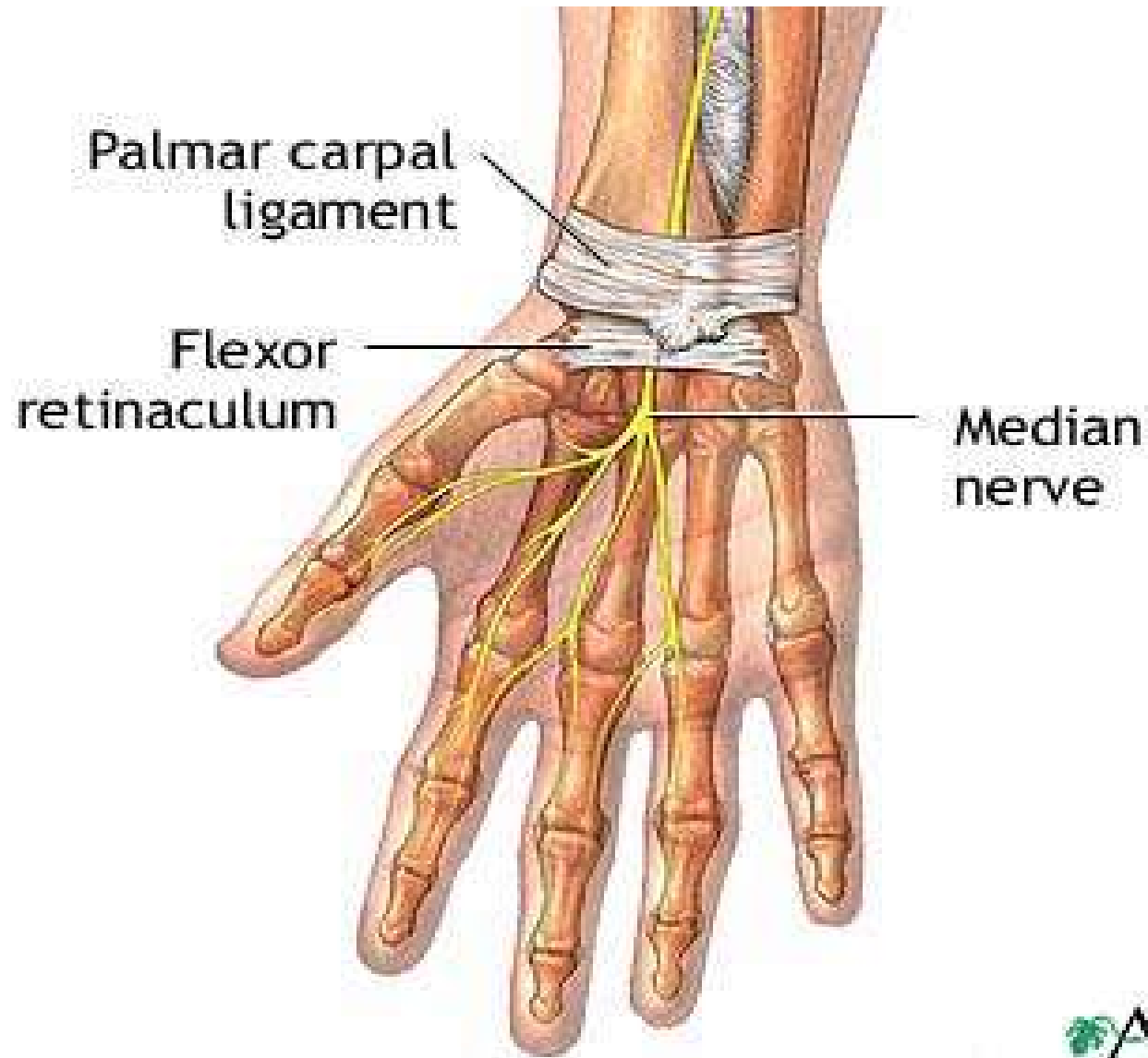
2U 3P

Structures pass deep to the retinaculum

(through the carpal tunnel)

1. Tendons of flexor digitorum superficialis.
2. Tendons of flexor digitorum profundus.
3. Common synovial sheath for the tendons of flexor digitorum superficialis and profundus.
4. Tendon of flexor pollicis longus and its synovial sheath.
5. Median nerve.
6. Tendon of flexor carpi radialis in **a special compartment**





Carpal Tunnel

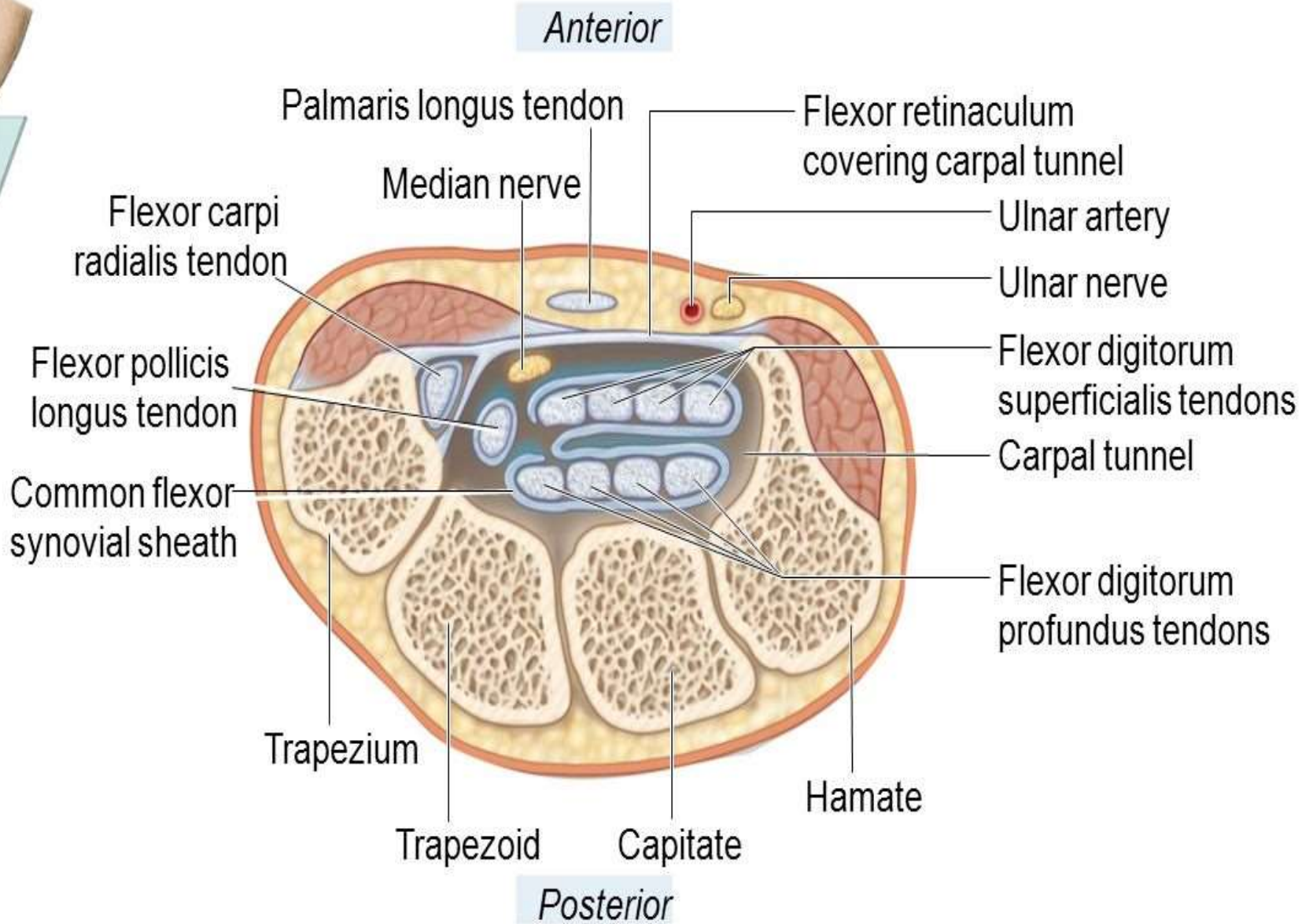
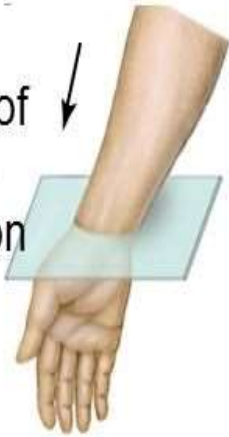Boundaries

Carpals bone concavity anteriorly
Flexor retinaculum covers it

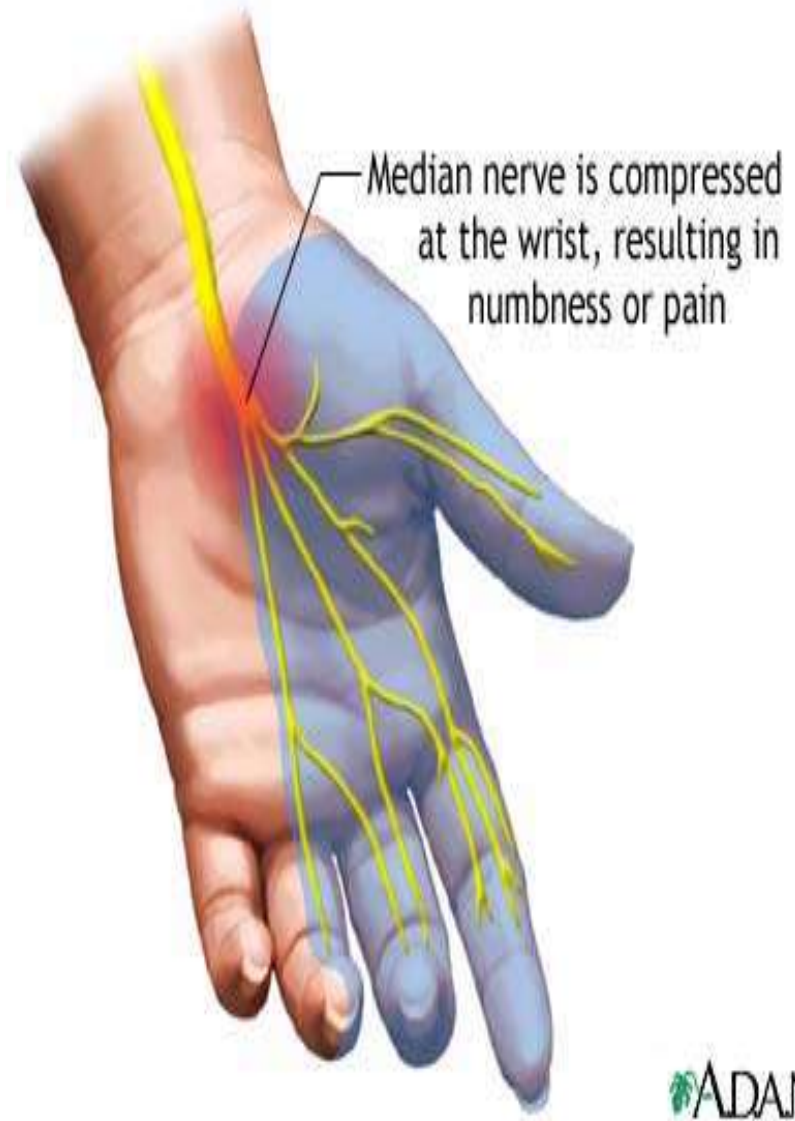
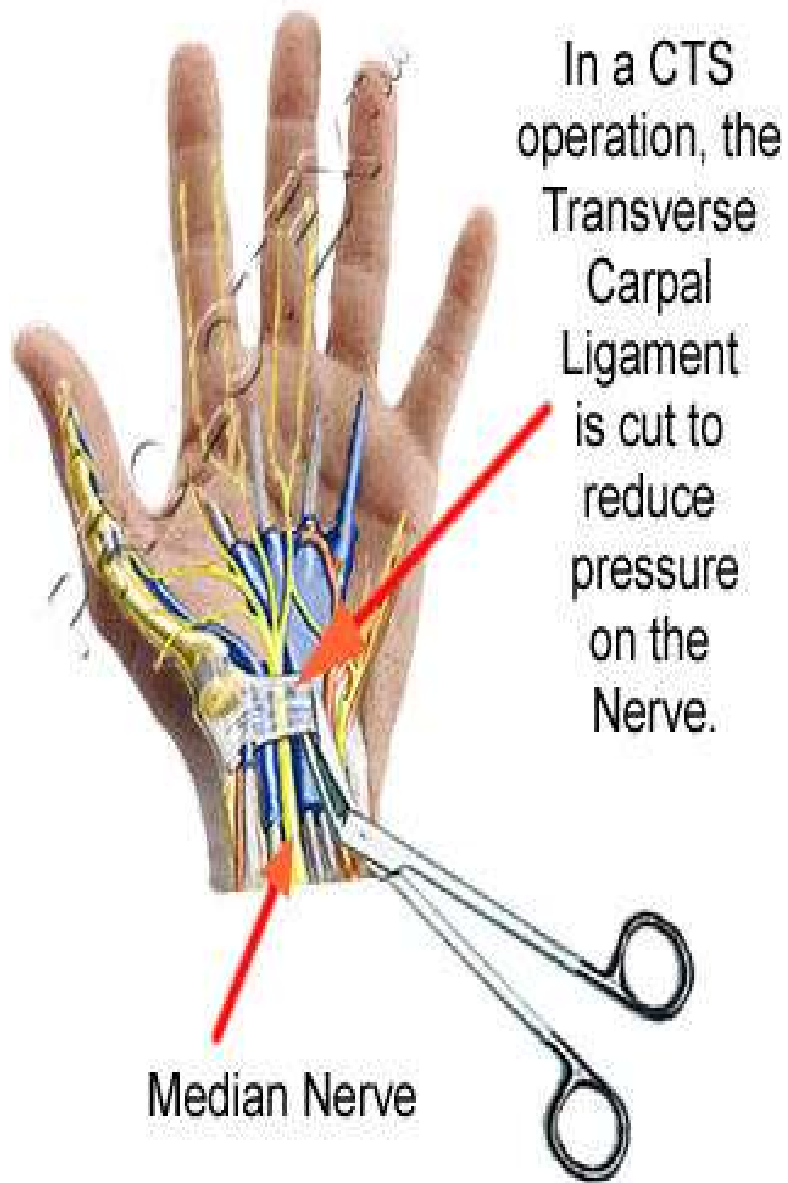
Content :

1. Tendons of flexor digitorum superficialis.
2. Tendons of flexor digitorum profundus.
3. Common synovial sheath for the tendons of flexor digitorum superficialis and profundus.
4. Tendon of flexor pollicis longus and its synovial sheath.
5. Median nerve.
6. Tendon of flexor carpi radialis in **a special compartment**

View of
cross
section



Carpal tunnel, transverse section



ADAM.



Muscles of The lateral and Posterior compartment of the forearm

By

Dr.Ahmed Salman

Associate Prof. of Anatomy

Learning Objectives

- 1-Identify Muscles of back of Forearm.
- 2- Know attachment ,nerve supply and action of back Forearm muscles
- 3-Demonstrate the hand movements

Muscles

Lateral compartment

- 1.Brachioradialis
- 2.Extensor carpi radialis longus.

Posterior compartment

Superficial

1. Extensor carpi radialis brevis.
- 2.Extensor digitorum.
3. Extensor digiti minimi.
4. Extensor carpi ulnaris.
5. Anconeus.

Deep

- 1.Supinator
- 2.Abductor pollicis longus.
- 3.Extensor pollicis brevis.
- 4.Extensor pollicis longus.
- 5.Extensor indicis.

General Rules (lateral and posterior forearm)

1- Supination means Lateral rotation of the forearm by movement of radius at radioulnar joint

2-Origin

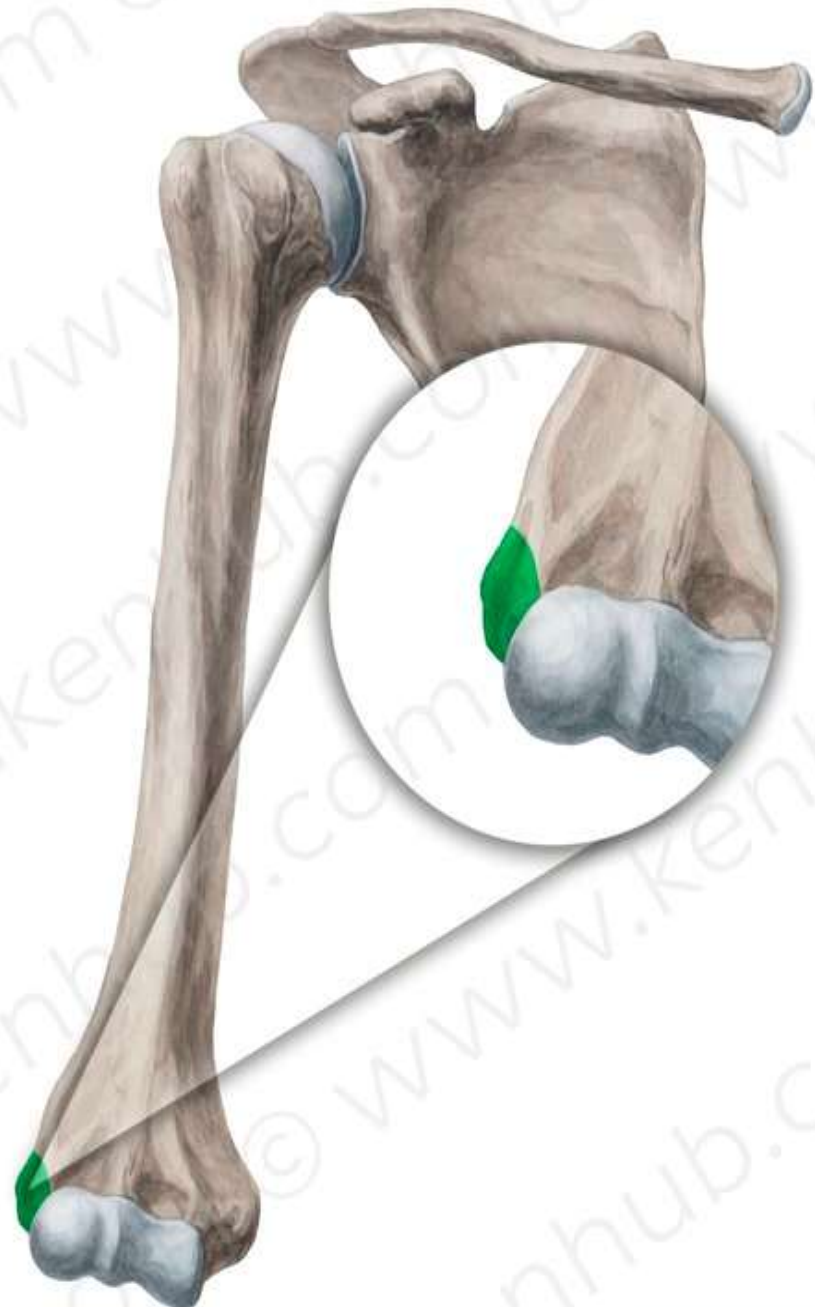
- All lateral compartment muscles originate from lateral supracondylar line
- **All superficial muscles of posterior compartment** take origin from the common extensor origin (*front of the lateral epicondyle*)
EXCEPT Anconeus (from back lateral epicondyle)

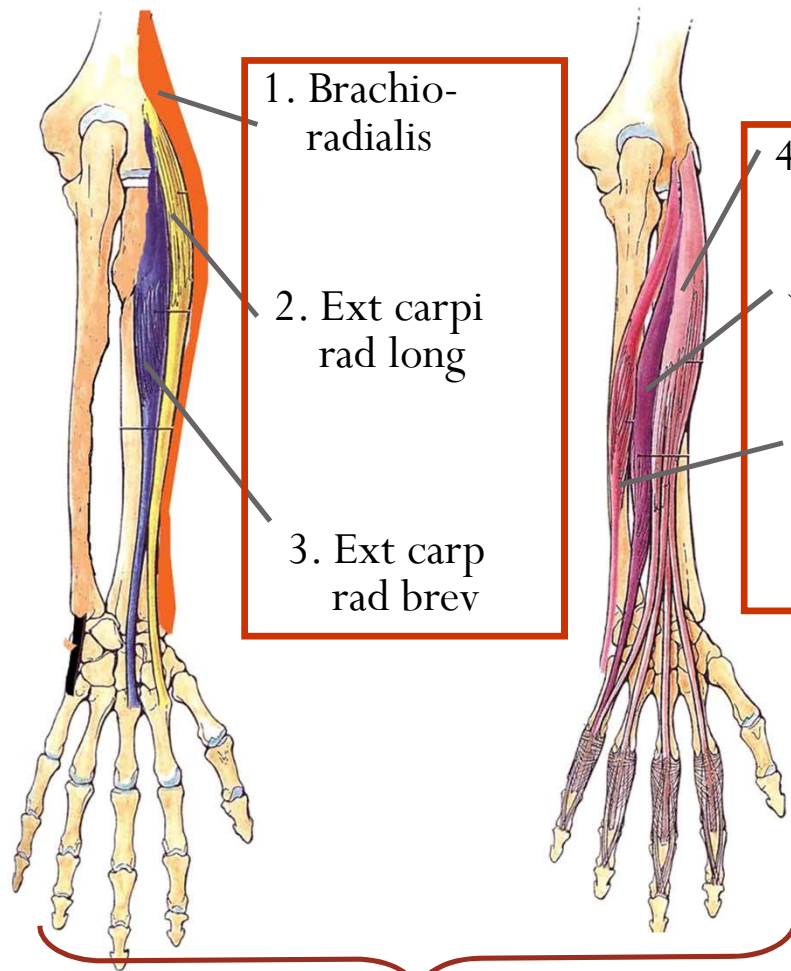
3-Action

Is mainly extension

4-Nerve Supply

- All **lateral compartment muscles** are supplied **radial nerve**
- All **posterior compartment muscles** are supplied by **deep branch of radial nerve** (posterior interosseous nerve) **EXCEPT Anconeus**
(**By radial nerve**)

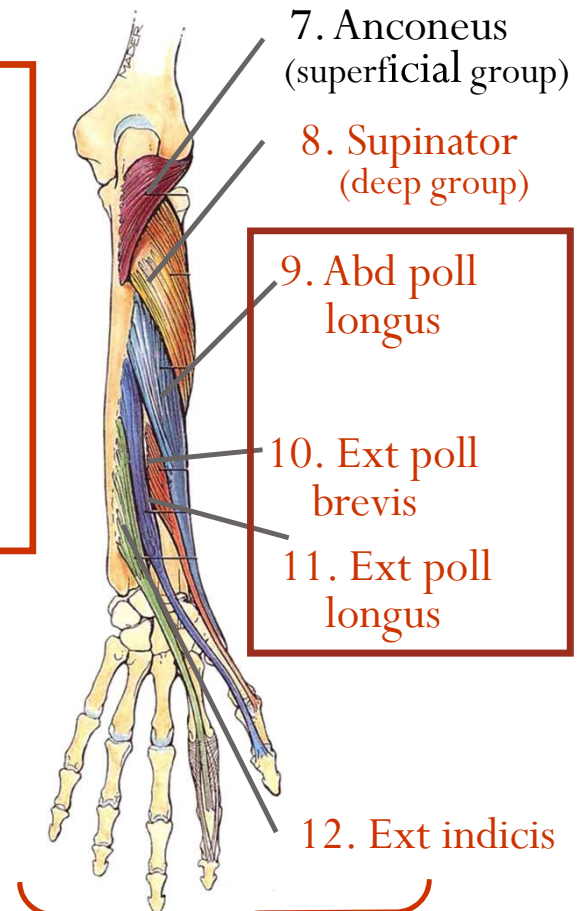




- 1. Brachio-radialis
- 2. Ext carpi rad long
- 3. Ext carpi rad brev

- 4. Ext dig
- 5. Ext digiti minimi
- 6. Ext carp ulnaris

Superficial group



- 7. Anconeus (superficial group)
- 8. Supinator (deep group)

- 9. Abd poll longus
- 10. Ext poll brevis
- 11. Ext poll longus

- 12. Ext indicis

Deep group

Triceps brachii

Anconeus

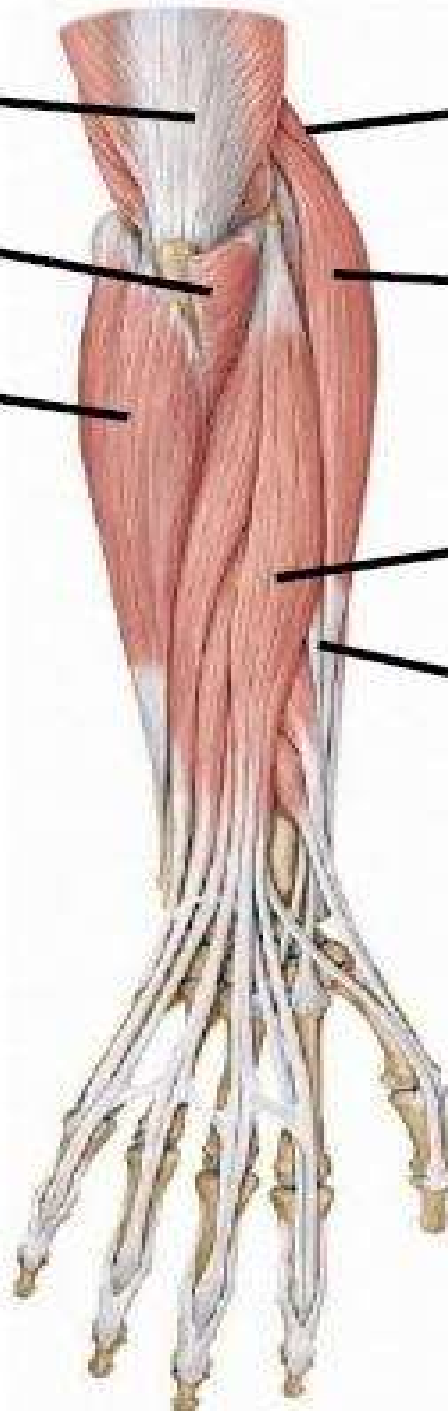
**Flexor carpi
ulnaris**

Brachioradialis

**Extensor carpi
radialis longus**

**Extensor
digitorum**

**Extensor carpi
radialis brevis**



Lateral compartment

1. Brachioradialis
2. Extensor carpi radialis longus.

Brachioradialis



Origin:

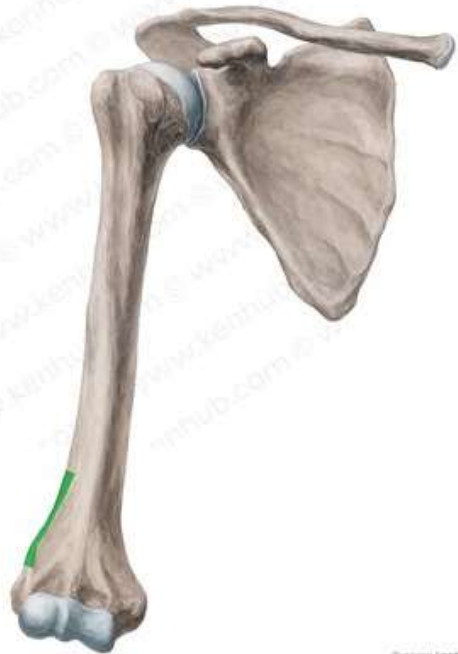Upper 2/3 of the lateral Supracondylar ridge.

Insertion

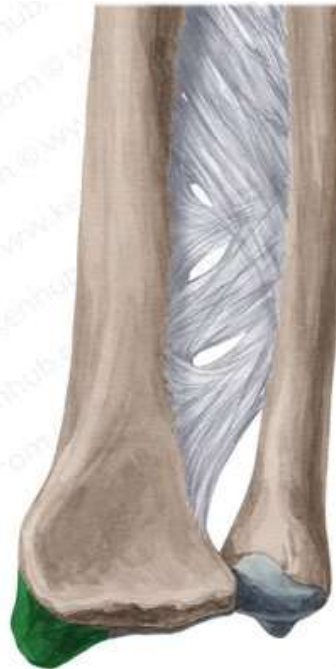Base of the styloid process of the radius.

Nerve supply:

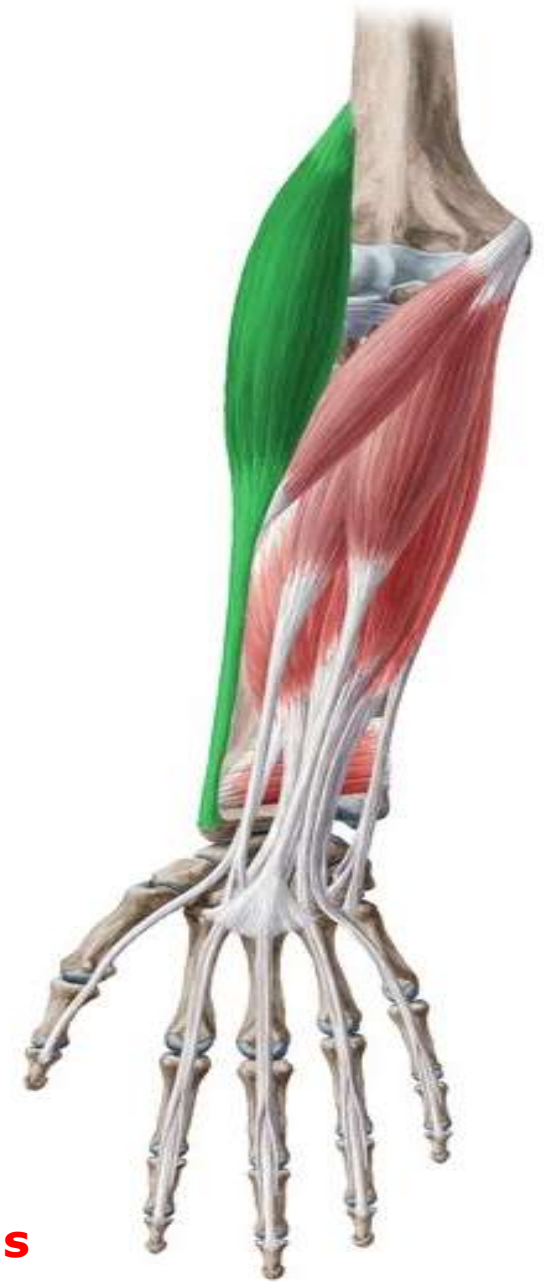Radial Nerve.



© www.kenhub.com



© www.kenhub.com



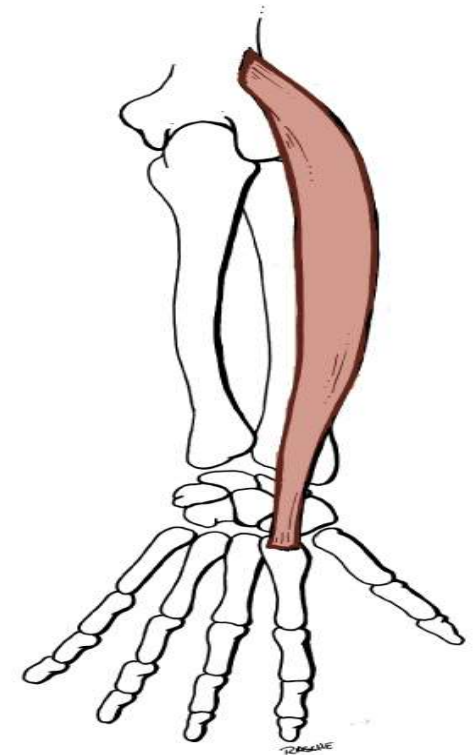
lateral Supracondylar ridge styloid process of the radius

Action:

1. Flexes the elbow joint when the forearm is in the midprone position.
2. Initiates pronation or supination of the forearm.



Extensor carpi radialis longus



Origin:

Lower 1/3 of the lateral supracondylar ridge.

Insertion

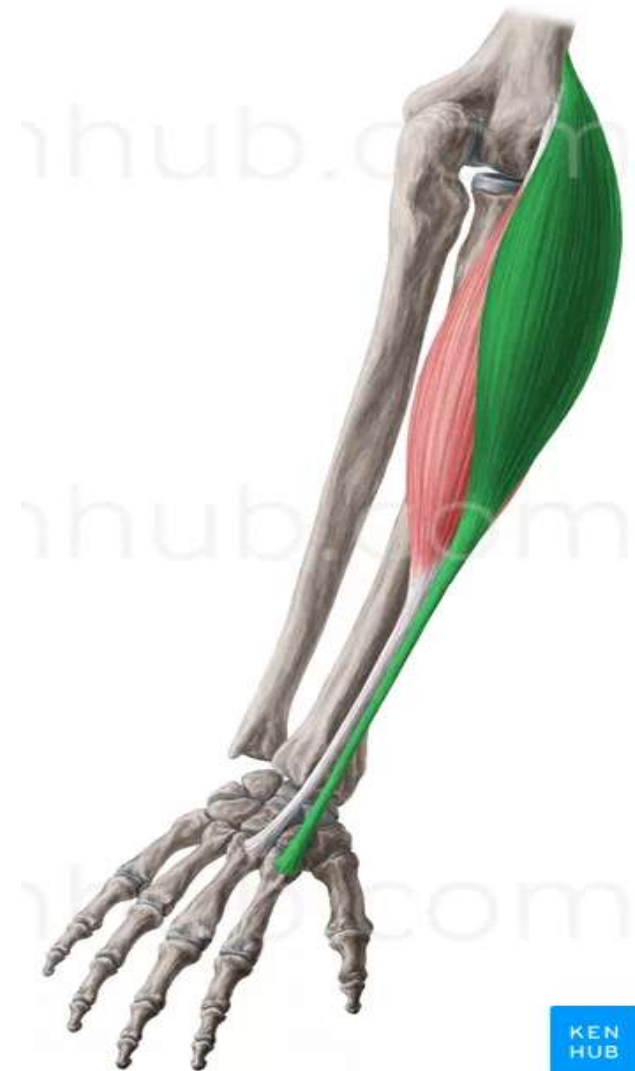Base of the 2nd metacarpal bone.

Nerve supply:

Radial Nerve.

Action:

- 1. Extension of the wrist.
- 2. Abduction of the hand



Superficial Group

1. Extensor carpi radialis brevis.
2. Extensor digitorum.
3. Extensor digiti minimi.
4. Extensor carpi ulnaris.
5. Anconeus.

Extensor carpi radialis Brevis

Origin:

Common extensor origin .

Insertion

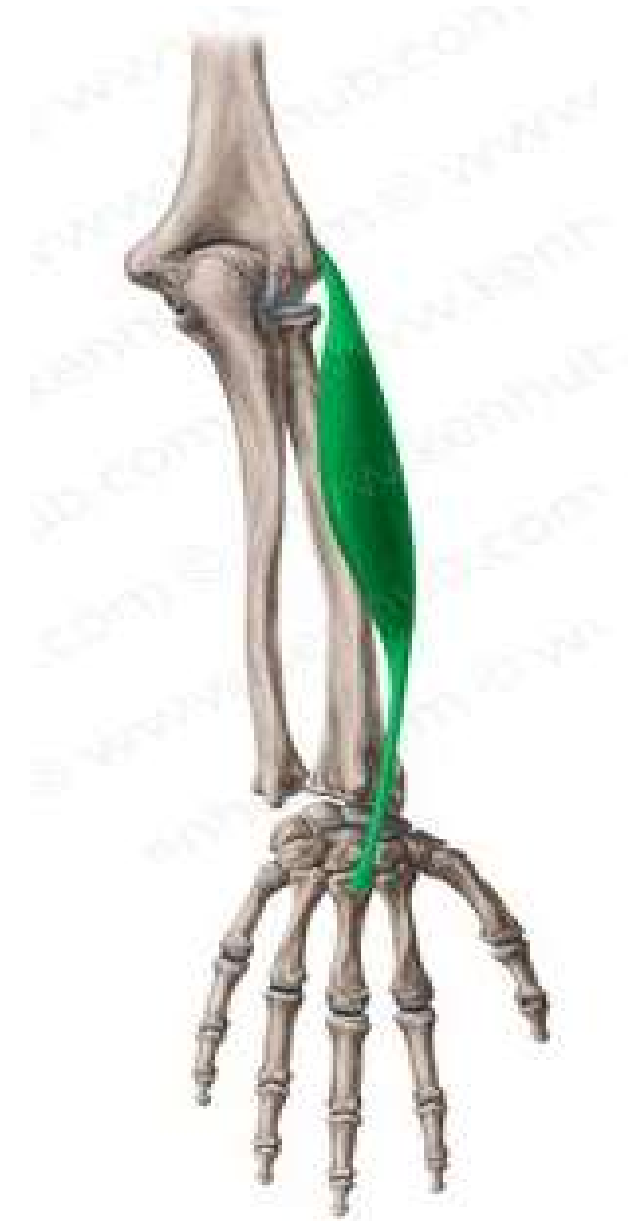Base of the 3rd metacarpal bone.

Nerve supply:

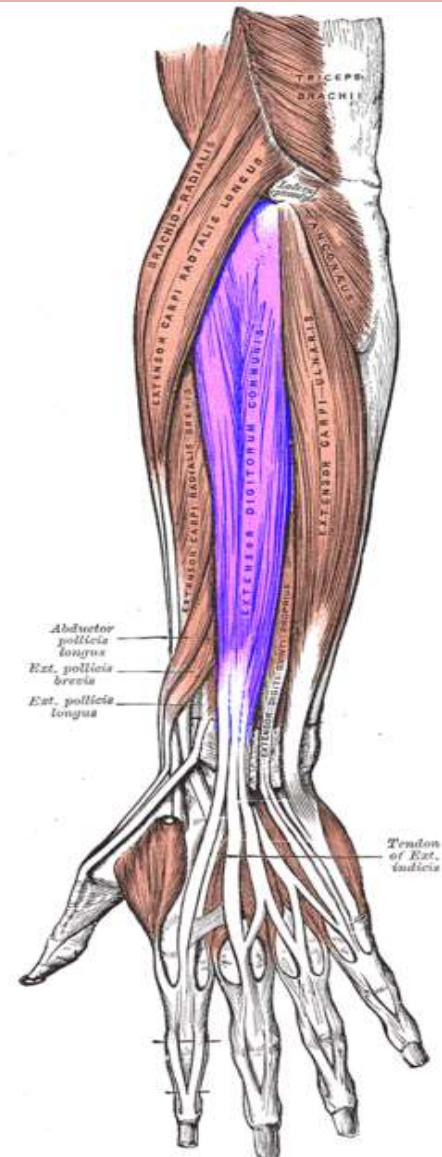
Deep branch of Radial Nerve.

Action:

- 1.Extension of the wrist.
- 2.Abduction of the hand.



Extensor Digitorum



Origin:

Common extensor origin .

Insertion

By 4 tendons which join the extensor expansion of the medial 4 fingers.

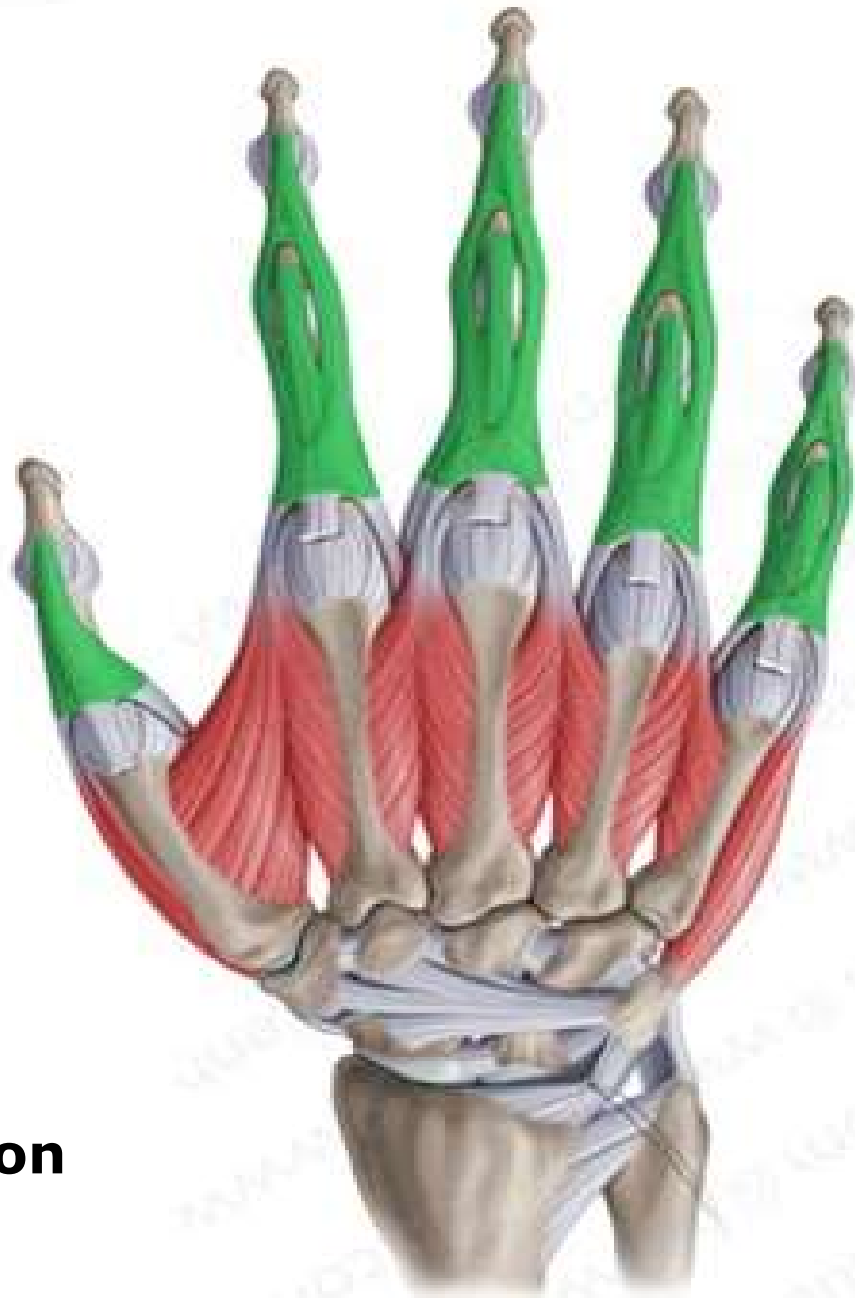Nerve supply:

Deep branch of Radial Nerve.

Action:

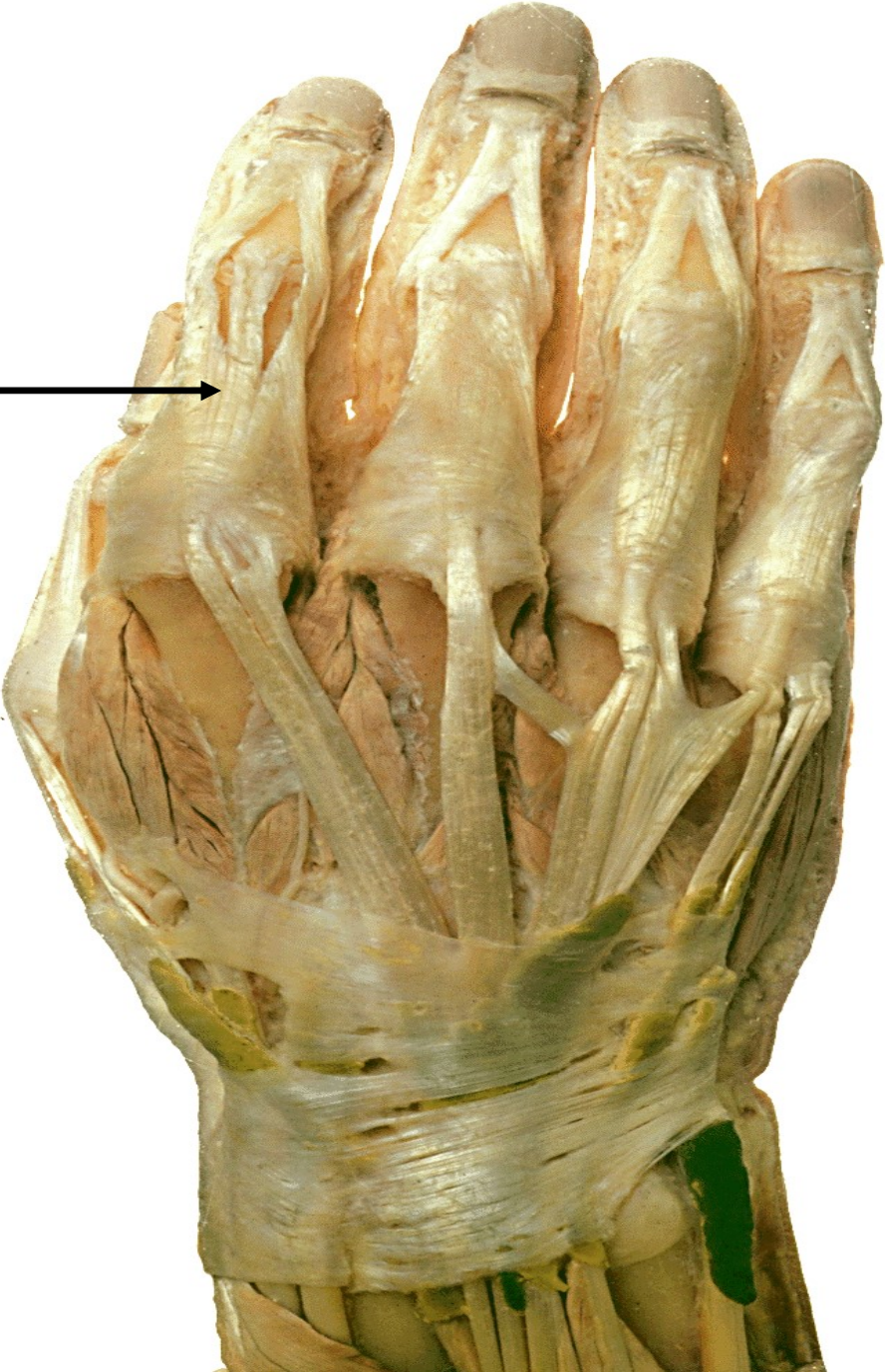- 1.It extends the metacarpophalangeal and the interphalangeal joints of the medial 4 fingers.
- 2.It helps in extension of the wrist.



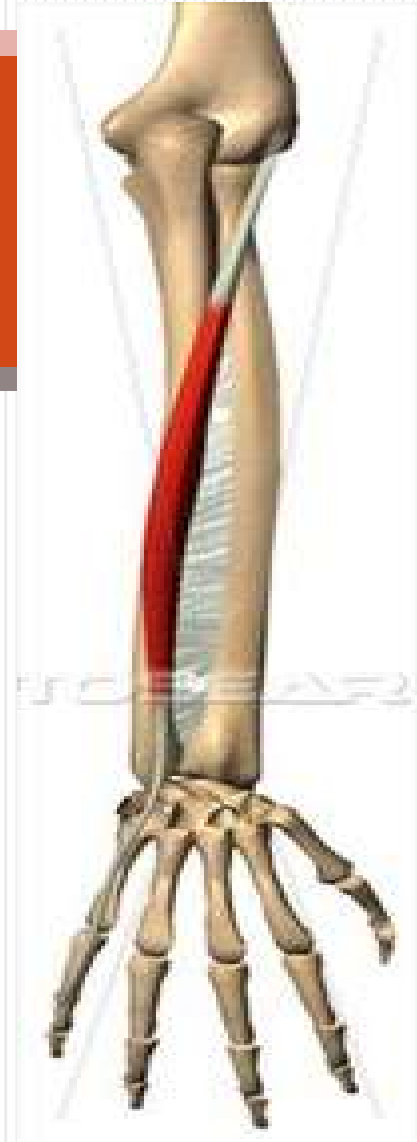

Extensor Expansion

Extensor Expansion →



Extensor Digiti Minimi



Origin:

Common extensor origin .

Insertion

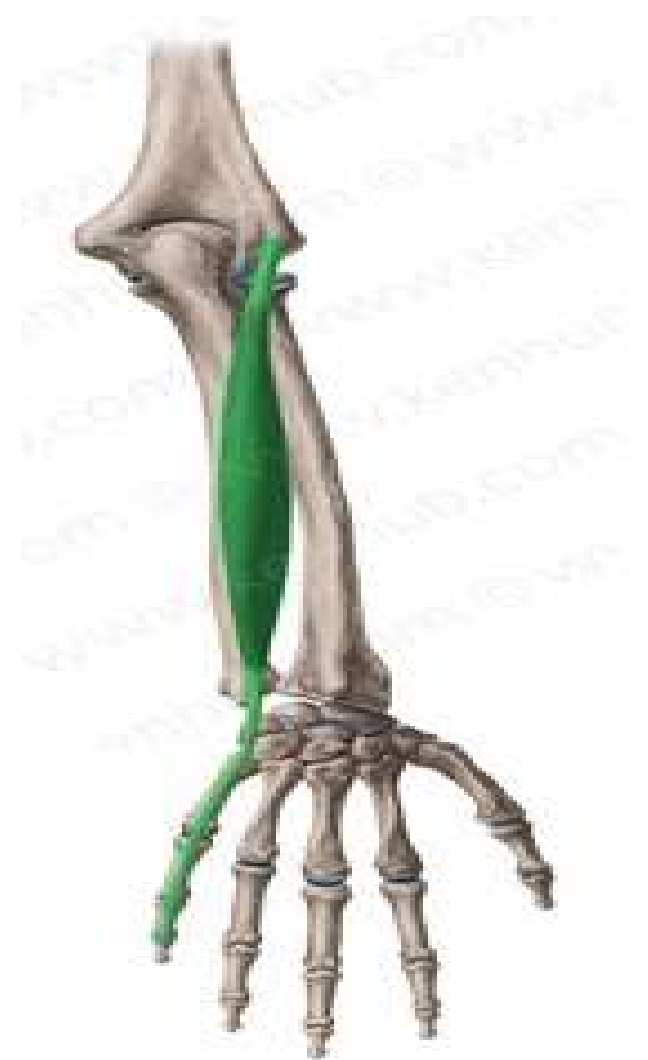The tendon join the extensor expansion of the little finger.

Nerve supply:

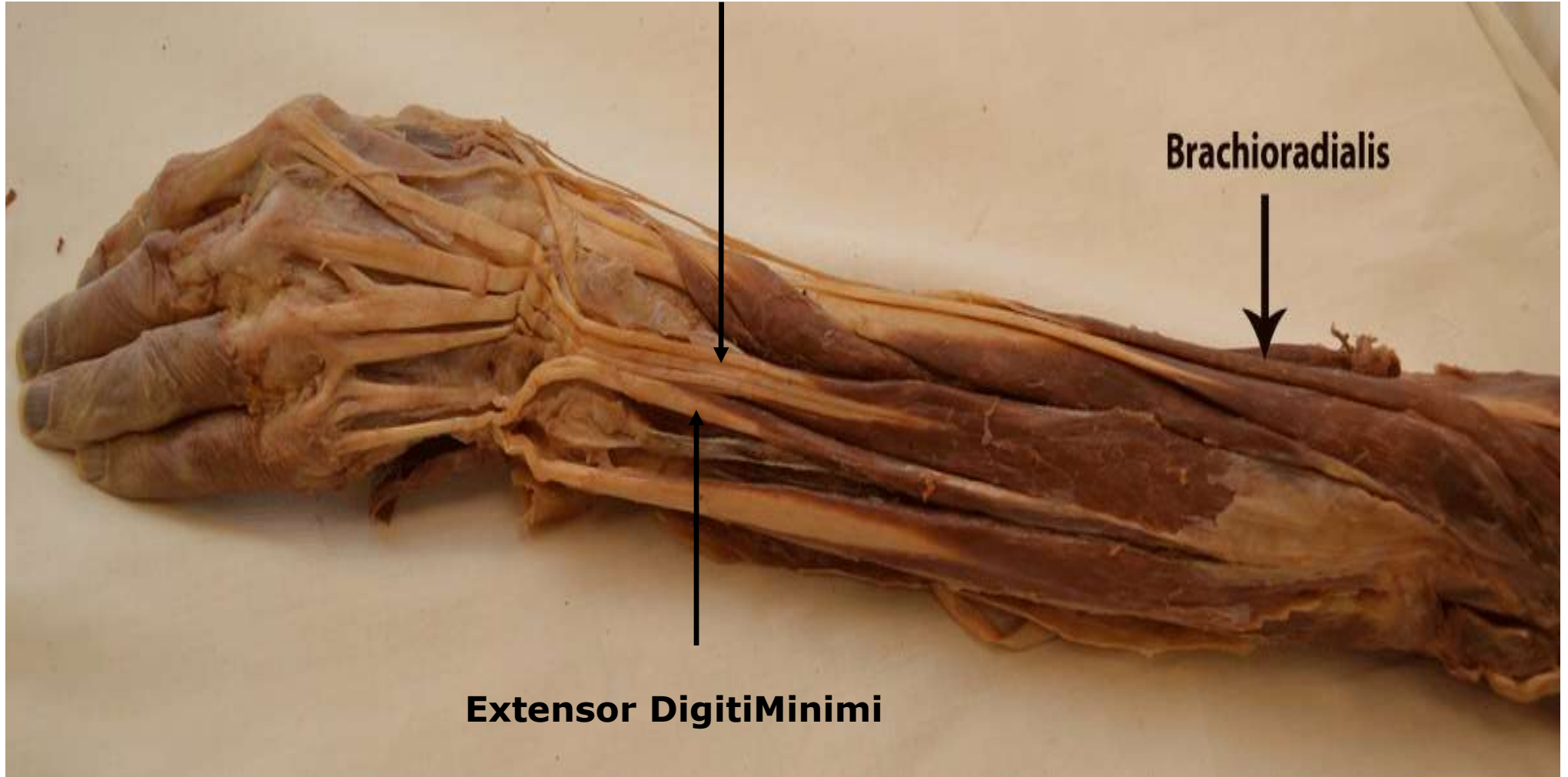
Deep branch of Radial Nerve.

Action:

- 1.It extends the metacarpophalangeal and the interphalangeal joints of little finger.
- 2.It helps in extension of the wrist.



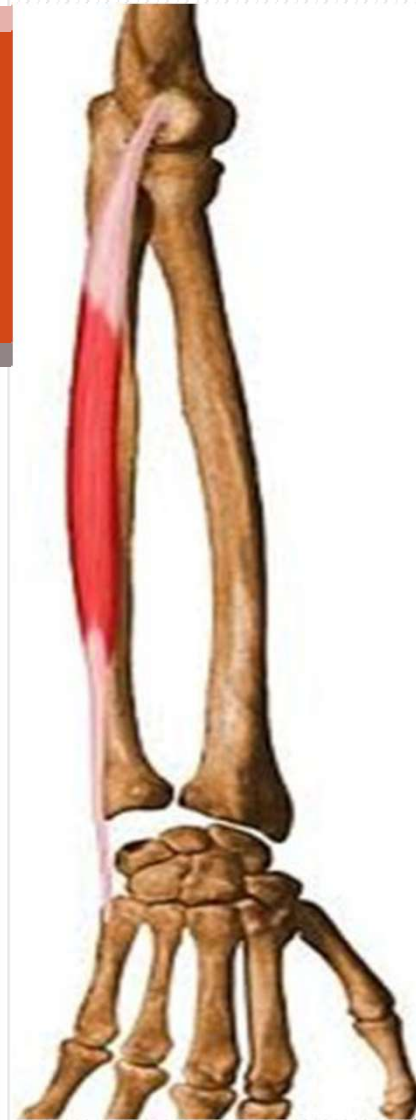
Extensor Digitorum



Brachioradialis

Extensor Digiti Minimi

Extensor Carpi Ulnaris



Origin:

Common extensor origin .

Insertion

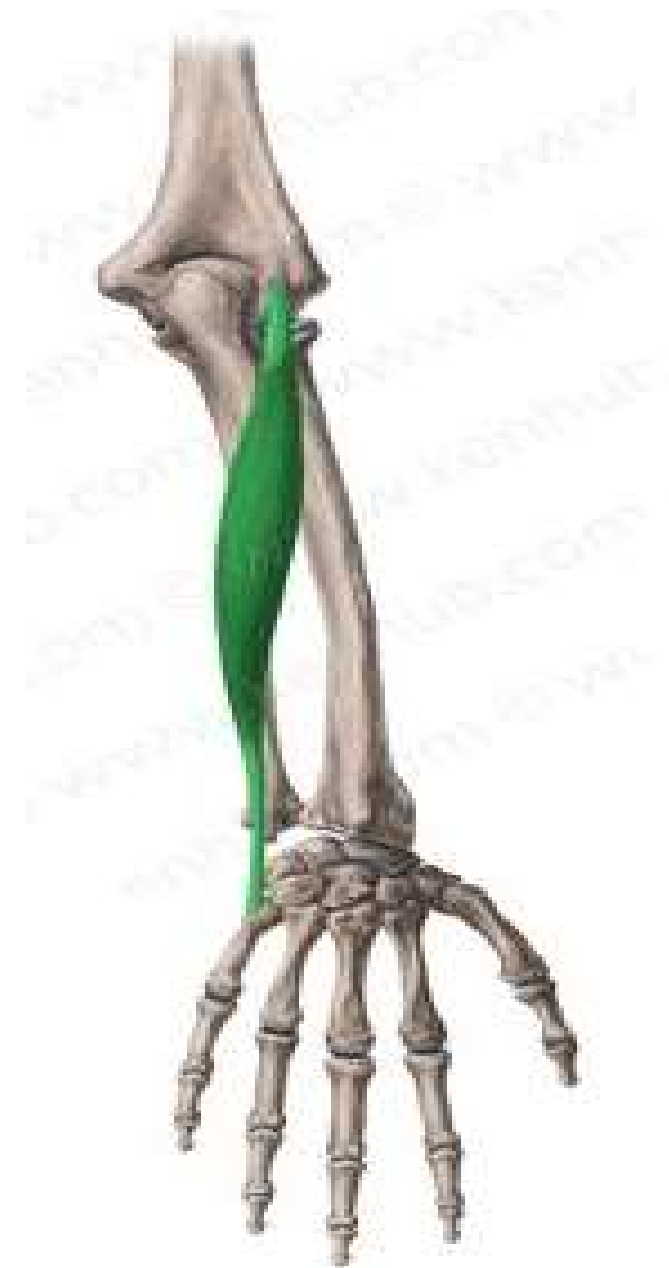Base of the 5th metacarpal bone.

Nerve supply:

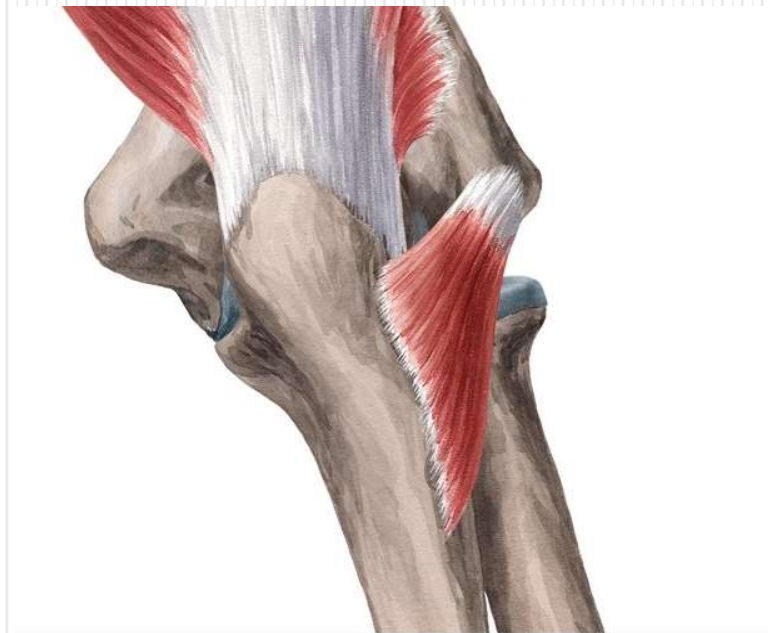Deep branch of Radial Nerve.

Action:

- 1.Extension of the wrist.
- 2.Adduction of the hand.



Anconeus



Origin:

Back of Lateral epicondyle of humerus.

Insertion

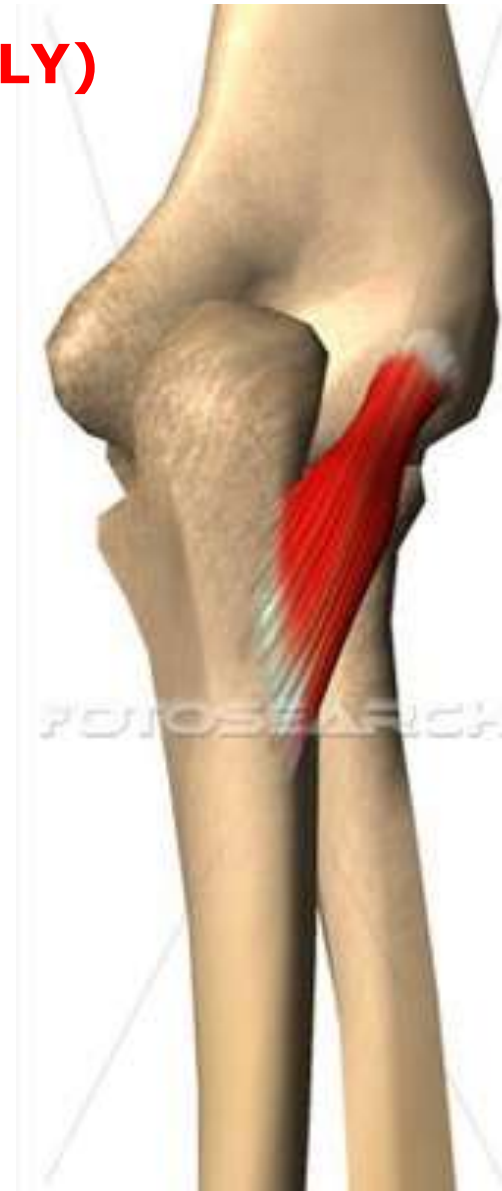Lateral surface of olecranon process of ulna. **(REED ONLY)**

Nerve supply:

Radial Nerve.

Action:

Helps triceps in extension of the elbow.



Rt. side

Brachioradialis

Ext carpi rad long

Common ext origin
(ext. carpi rad. br.
+ ext digitorum
+ ext dig minimi
+ ext carpi ulnaris
+ anconeus).

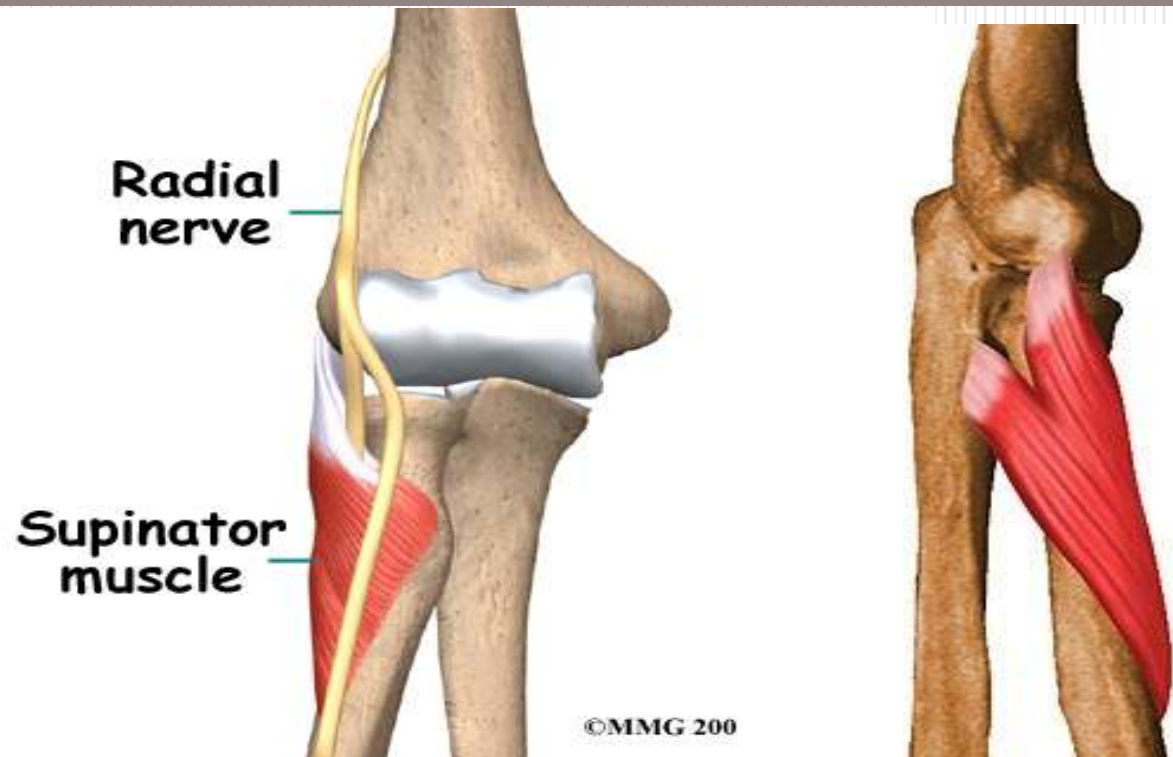


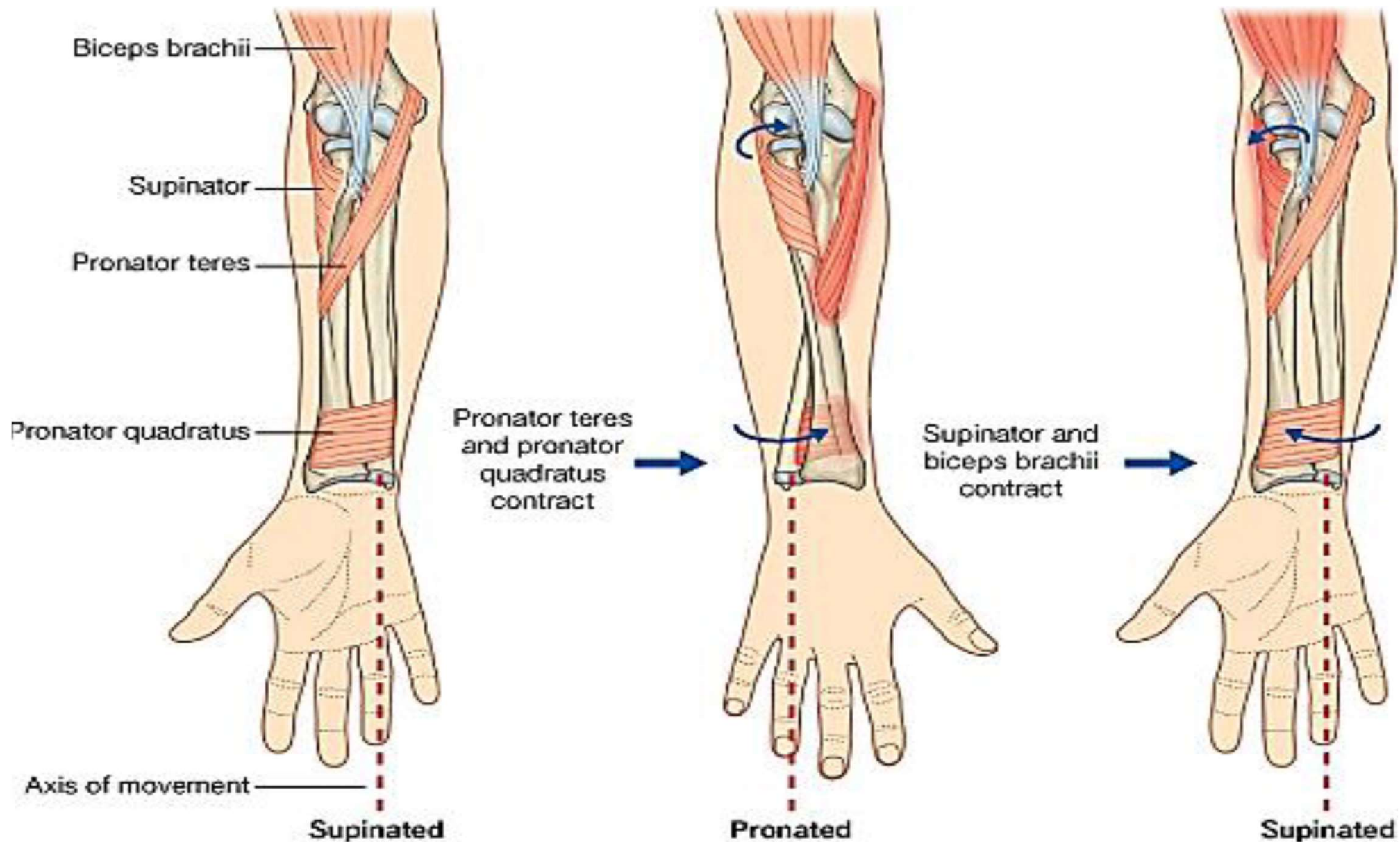
Deep Group

1. Supinator
2. Abductor pollicis longus.
3. Extensor pollicis brevis.
4. Extensor pollicis longus.
5. Extensor indicis.

ORIGIN IS NOT REQUIRED

Supinator





© Elsevier. Drake et al: Gray's Anatomy for Students - www.studentconsult.com

Origin:

1. Lateral epicondyle of humerus.
2. Radial collateral ligament of elbow joint.
3. Supinator fossa and supinator crest of the ulna.

Insertion

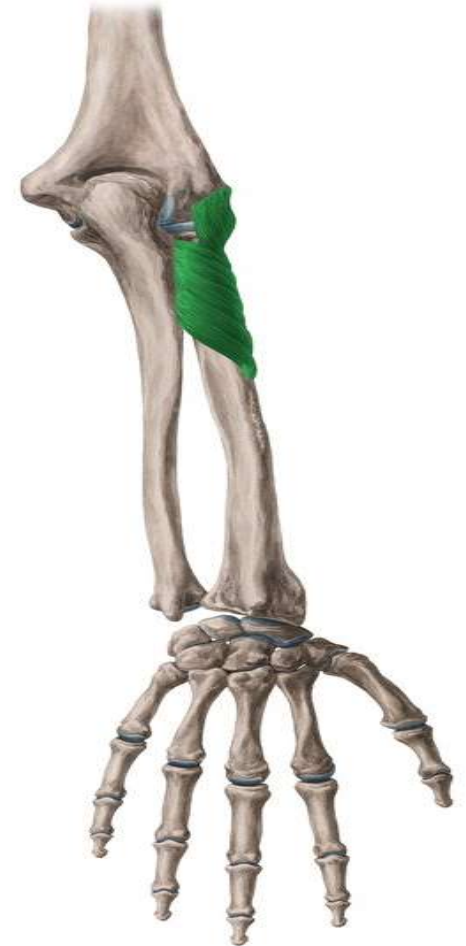Front and lateral and posterior surfaces of the upper 1/3 of the radius.

Nerve supply:

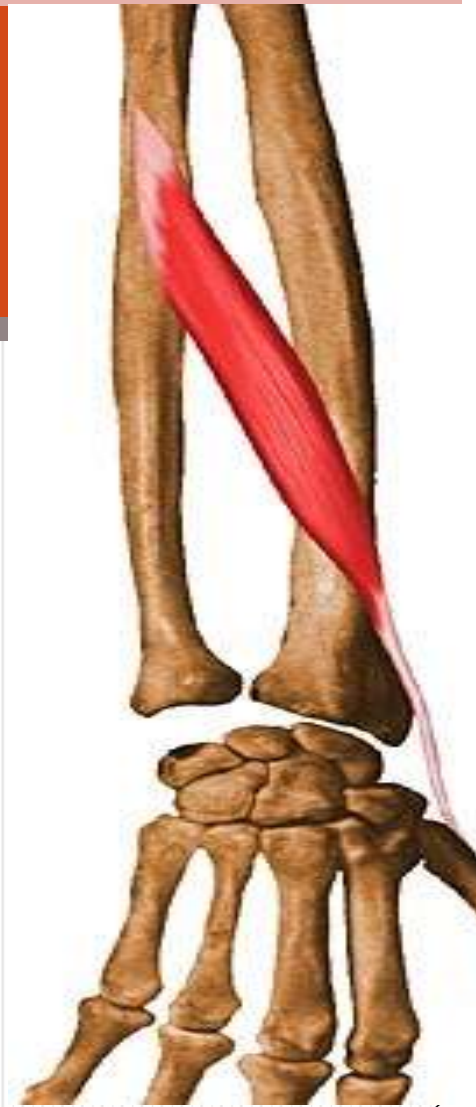Deep branch of Radial Nerve.

Action:

Supination the forearm



Abductor Pollicis Longus



Origin:

Posterior surface of shafts of radius and ulna.

Insertion

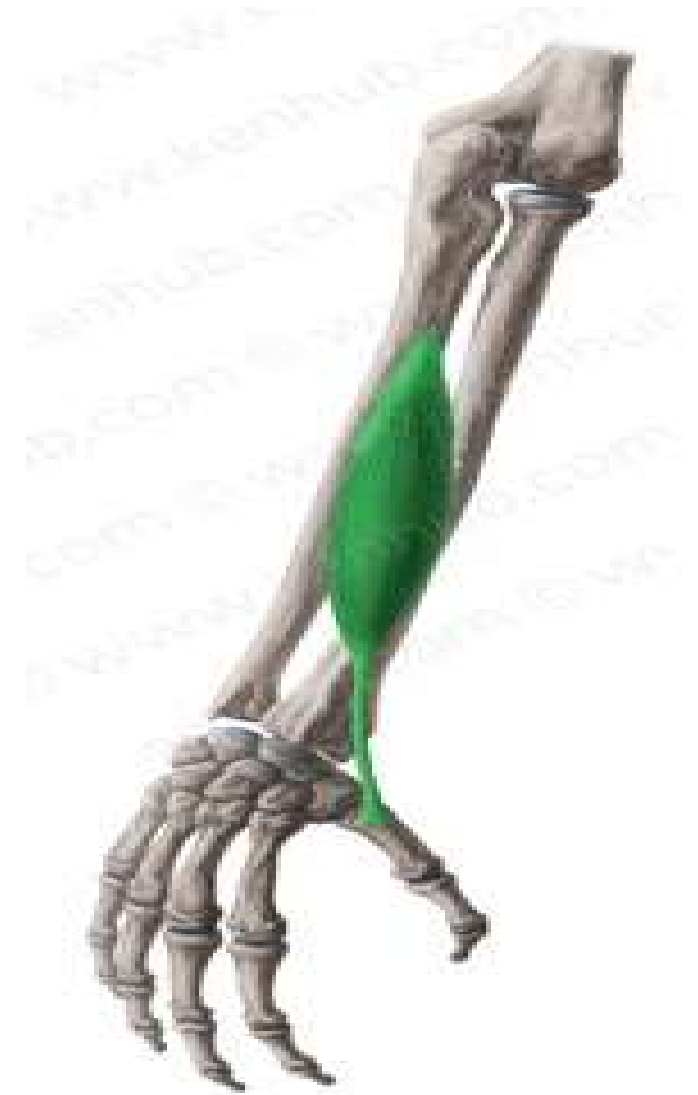Base of the 1st Metacarpal bone.

Nerve supply:

Deep branch of Radial Nerve.

Action:

Abducts and extends thumb



Extensor Pollicis Brevis

Origin:

Posterior surface of shafts of radius

Insertion

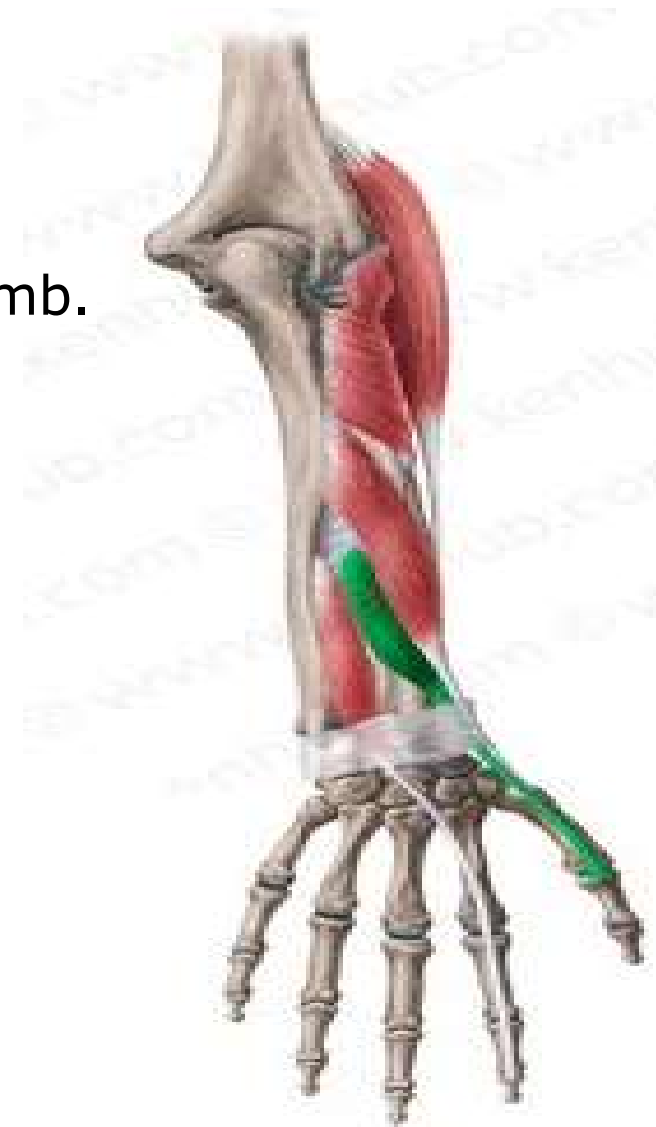Base of the proximal phalanx of the thumb.

Nerve supply:

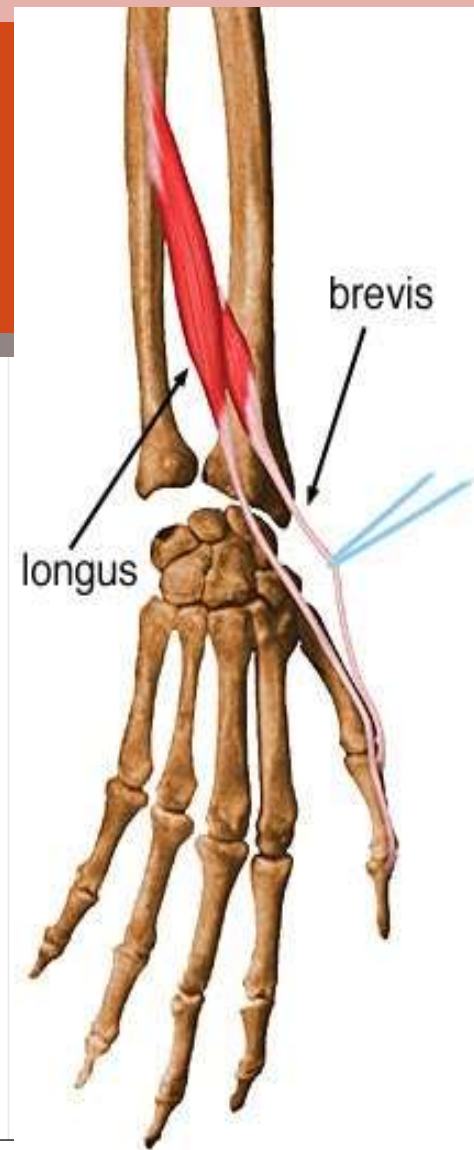
Deep branch of Radial Nerve.

Action:

Extends Metacarpophalangeal joint of the thumb.



Extensor Pollicis Longus



Origin:

Posterior surface of shafts of Ulna.

Insertion

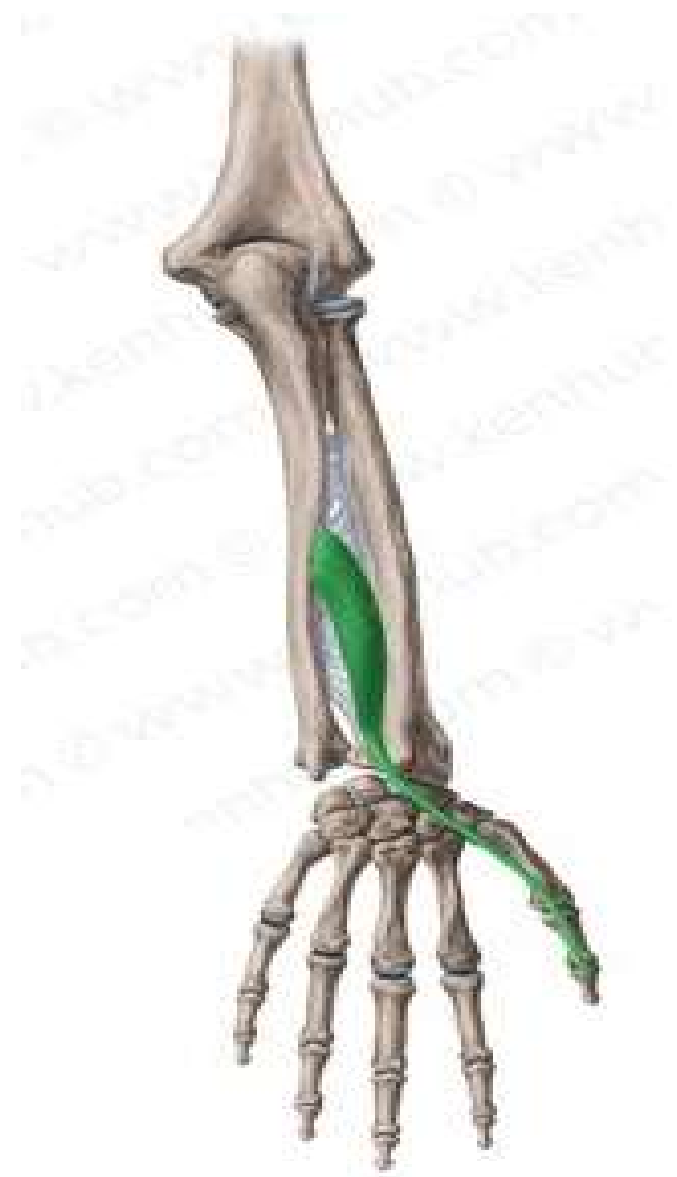Base of the distal phalanx of the thumb.

Nerve supply:

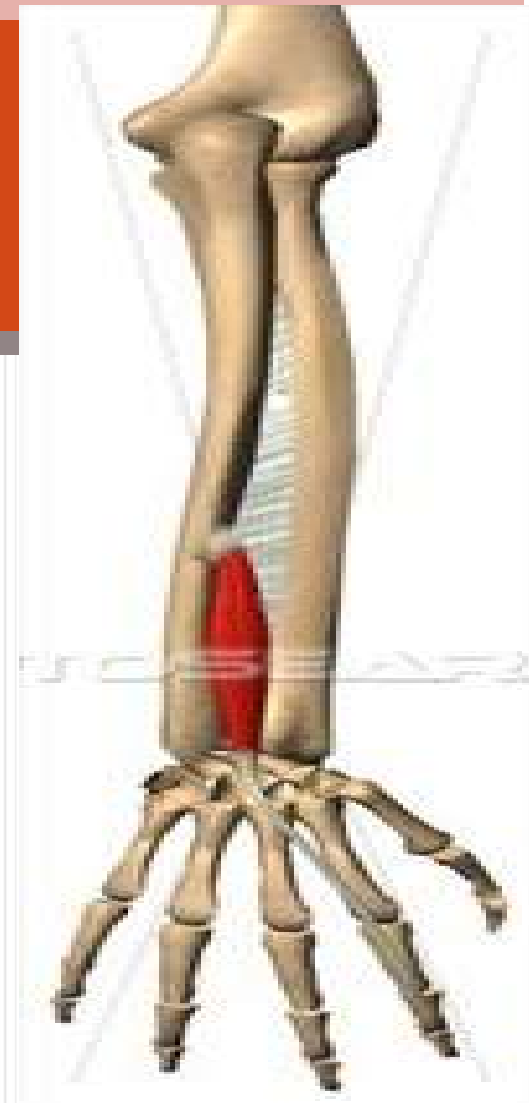Deep branch of Radial Nerve.

Action:

Extends the distal phalanx of the thumb.



Extensor indicis



Origin:

Posterior surface of shafts of Ulna.

Insertion

Its tendon joins the extensor expansion of the index finger.

Nerve supply:

Deep branch of Radial Nerve.

Action:

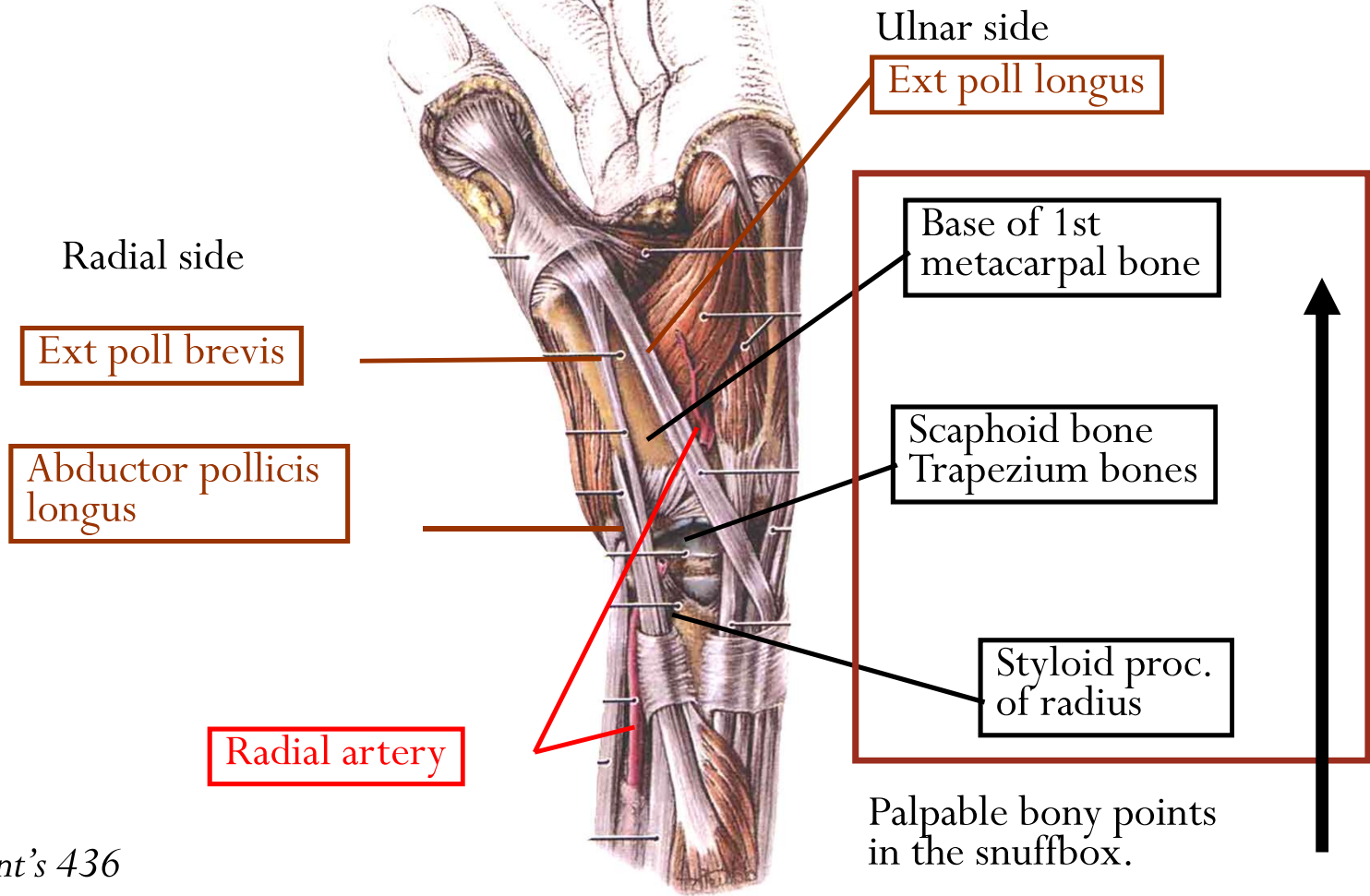
Extends all the joints of the index finger.



The anatomical snuff box

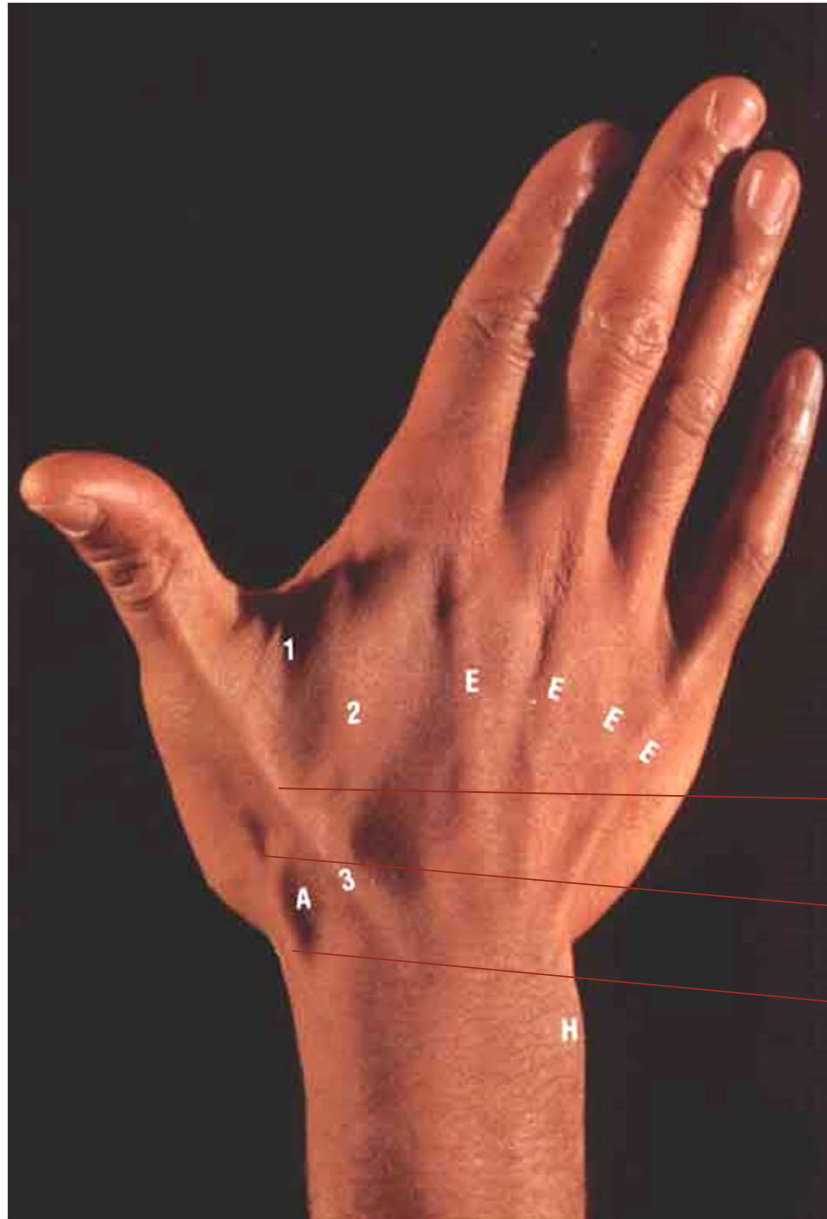
The anatomical snuff box

If thumb is fully extended, the snuffbox could be demonstrated



Grant's 436

Dr. Ahmed Salman



Anatomical snuff box

Extensor poll longus

Extensor poll brevis

Abductor poll longus

Grant's 436

Position: it is a hollow on the lateral part of the wrist.

Boundaries: can be identified when the thumb is abducted and extended.

Laterally (anteriorly): The tendons of abductor pollicis longus and extensor pollicis brevis.

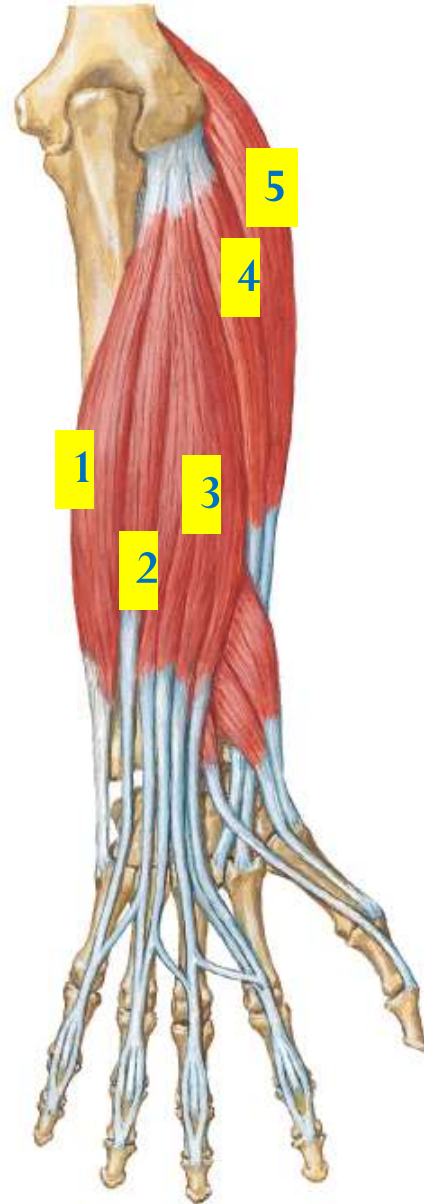
Medially (posteriorly): The tendon of extensor pollicis longus.

Floor:

Scaphoid and trapezium.

Content:

1. The radial artery
2. Beginning of the cephalic vein.
3. The superficial terminal branch of the radial nerve.



1. Extensor carpi ulnaris
2. Extensor digiti minimi
3. Extensor digitorum.
4. Extensor carpi radialis brevis
5. Extensor carpi radialis longus

Thank
you