# BONE TISSUE

# Bone

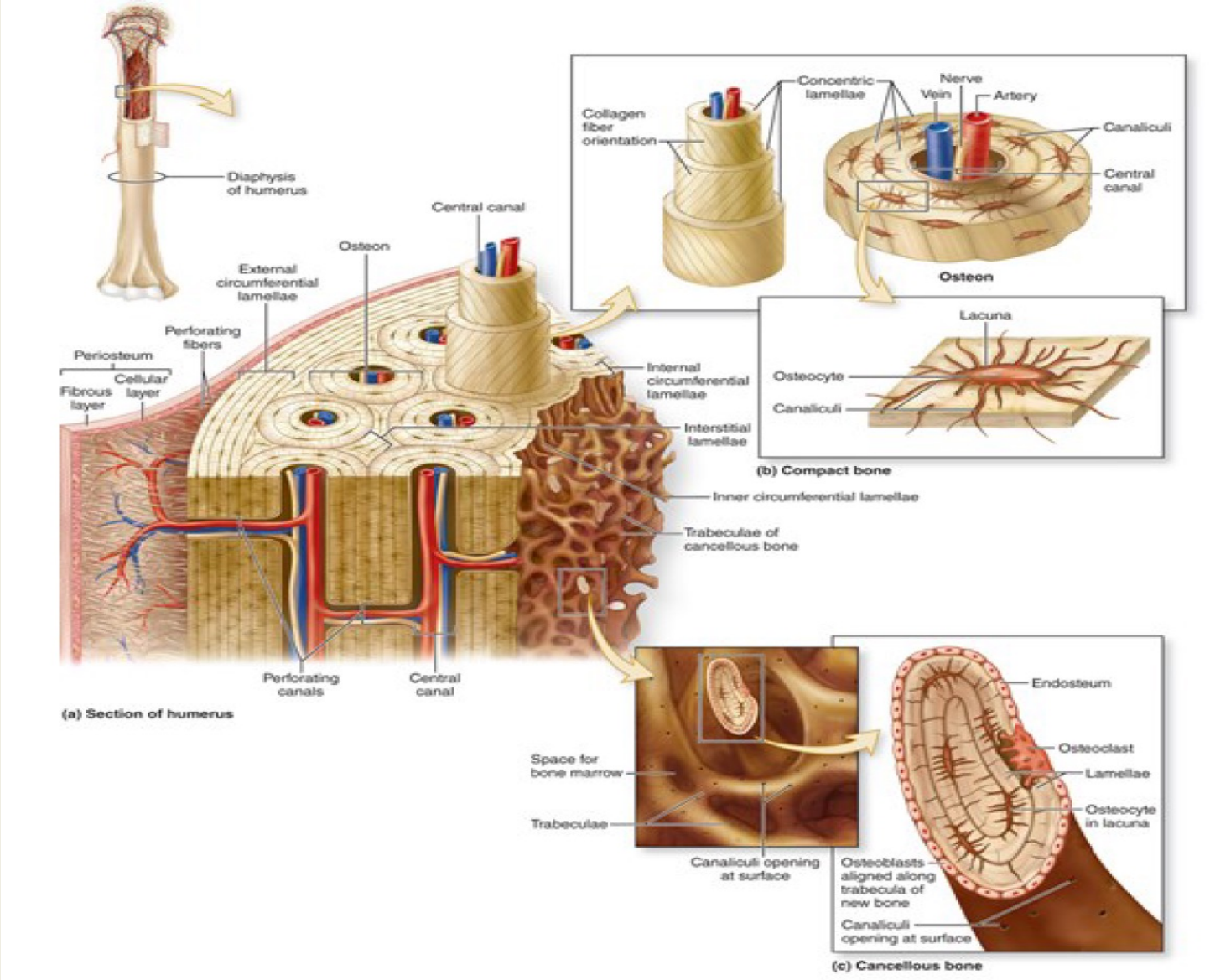
Diaphysis of humerus
Central canal
Osteon
External circumferential lamellae
Perforating fibers
Periosteum
Cellular layer
Fibrous layer
Internal circumferential lamellae
Interstitial lamellae
Inner circumferential lamellae
Trabeculae of cancellous bone
Perforating canals
Central canal
(a) Section of humerus
Collagen fiber orientation
Concentric lamellae
Nerve
Vein
Artery
Canaliculi
Central canal
Osteon
Lacuna
Osteocyte
Canaliculi
(b) Compact bone
Space for bone marrow
Trabeculae
Canaliculi opening at surface
Endosteum
Osteoclast
Lamellae
Osteocyte in lacuna
Osteoblasts aligned along trabecula of new bone
Canaliculi opening at surface
(c) Cancellous bone

# Functions

- Main constituent of the adult skeleton
- Provides solid support for the body, protects vital organs such as those in the cranial and thoracic cavities,
- Encloses internal (medullary) cavities containing bone marrow.
- Bone tissue also serves as a reservoir of calcium, phosphate, and other ions.

# Components

## Bone matrix

### Organic

- Collagen++
- Proteoglycans
- Glycoproteins

### Inorganic

- Calcium hydroxyapatite +++

## Cells

- Osteoblast
- Osteocytes
- Osteoclasts

# Bone cells

1. Osteoblast
2. Osteocytes
3. Osteoclasts

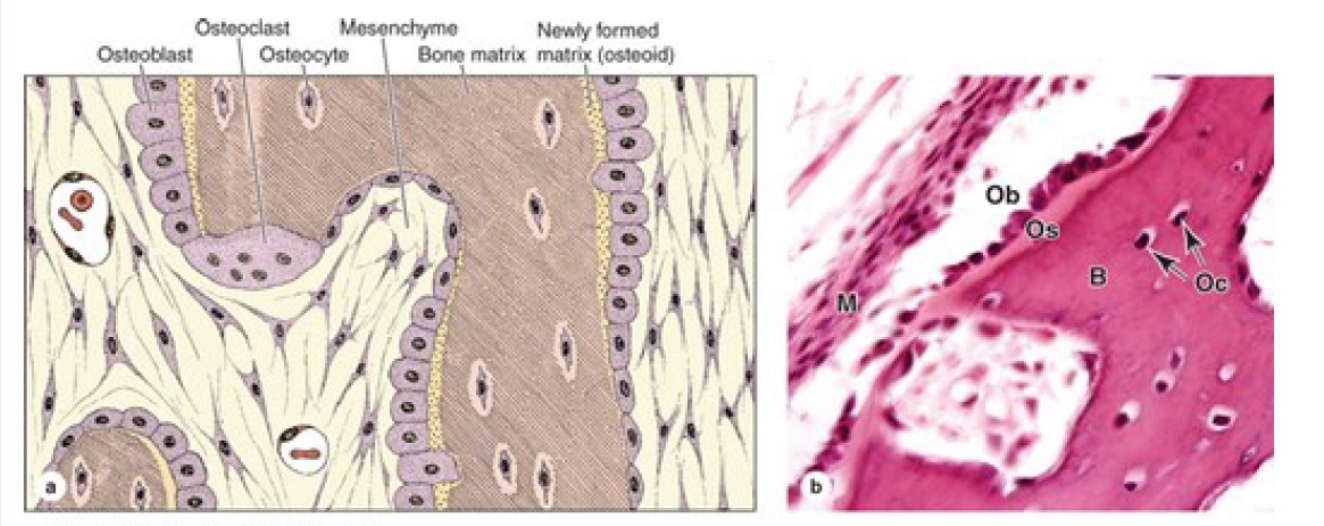

# Cells

- Osteocytes are found in cavities (lacunae) between bone matrix layers (lamellae), with cytoplasmic processes in small canaliculi that extend into the matrix.
- Osteoblasts growing cells which synthesize and secrete the organic components of the matrix
- Osteoclasts which are giant, multinucleated cells involved in removing calcified bone matrix and remodeling bone tissue

# Osteoblasts

- Originating from mesenchymal stem cells.
- Produce the organic components of bone matrix
- Located exclusively at the surfaces of bone matrix.
- Active ones are located exclusively at the surfaces of bone matrix (integrins)

# Osteoblasts

**When their synthetic activity is completed:**

- Some osteoblasts differentiate as osteocytes entrapped in matrix-bound lacunae.
- Some flatten and cover the matrix surface as bone lining cells
- The majority undergo apoptosis.

# Osteocytes

- Surrounded by the material they secrete and then differentiate as osteocytes.
- Processes in canaliculi 250-300 nm.

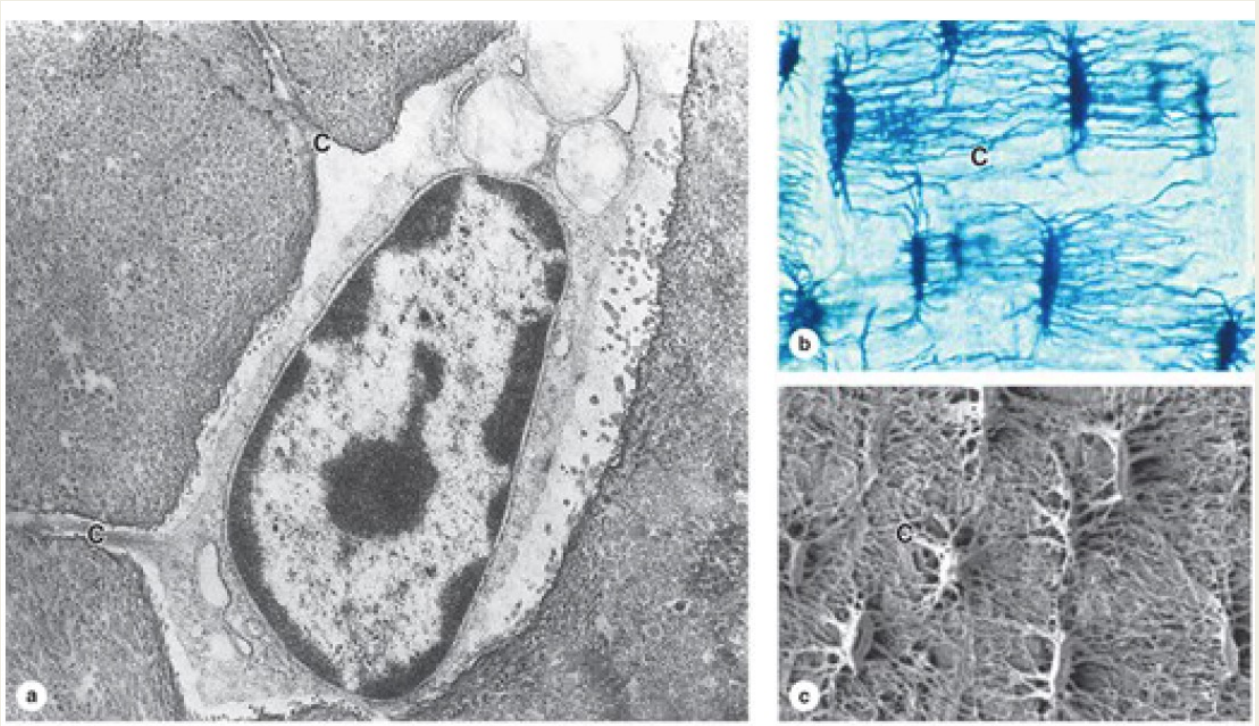

# Mineralization in bone matrix

- **Osteoid**

  Collagen I

  Glycoproteins

  proteoglycans

- **Osteocalcin**

  Vit. K-dependant polypeptid.

  Bine ca $^{2+}$

- **Matrix vesicles.**

  Alkaline phosphatase.

  Raises po4 $^{3-}$

  Formation of hydroxyapatite

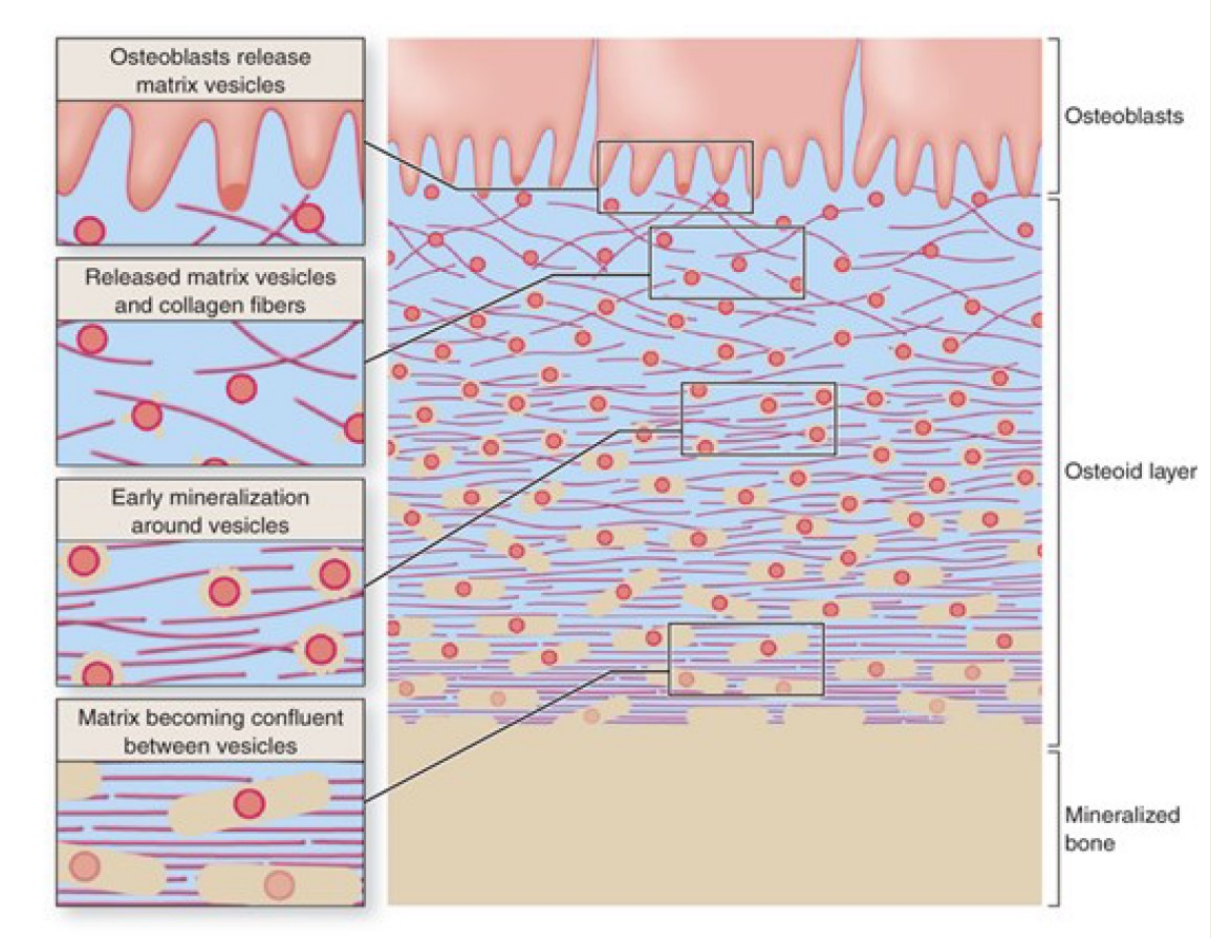

# OSTEOCLAST

Very large, motile cells with multiple nuclei

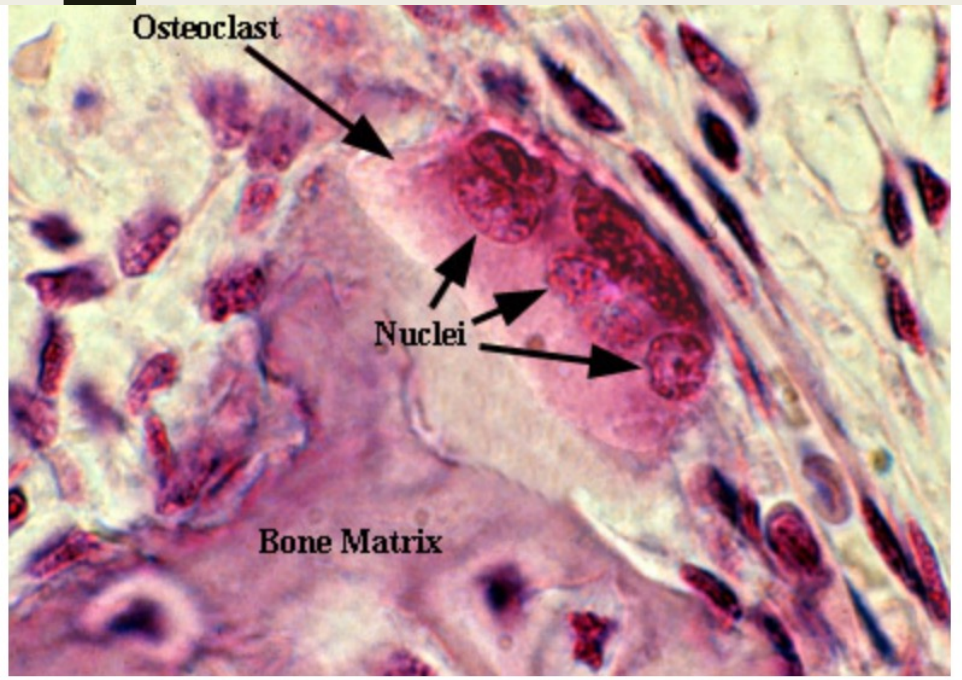


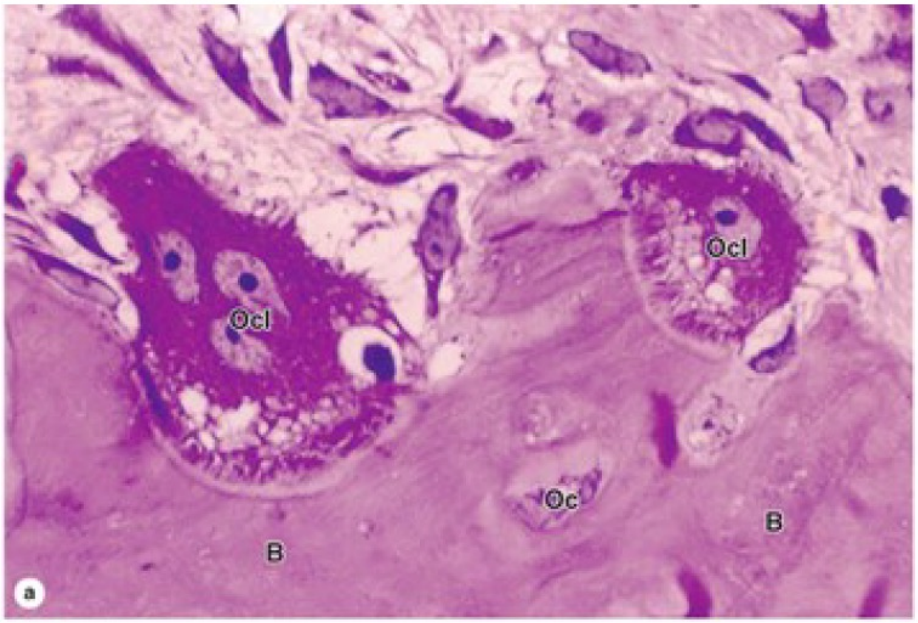

# Periosteum & Endosteum

- External and internal surfaces of all bones
- Periosteum is a dense connective tissue, containing mostly bundled type I collagen, but also fibroblasts and blood vessels
- Type I collagen (Fibrillar collagens types I, II, and III).
- Bone is vascularized by small vessels that penetrate the matrix from the periosteum.
- Endosteum covers all trabeculae around the marrow cavities.