

The University Of Jordan
Faculty Of Medicine
Anatomy Department



BONES OF THE UPPER LIMB

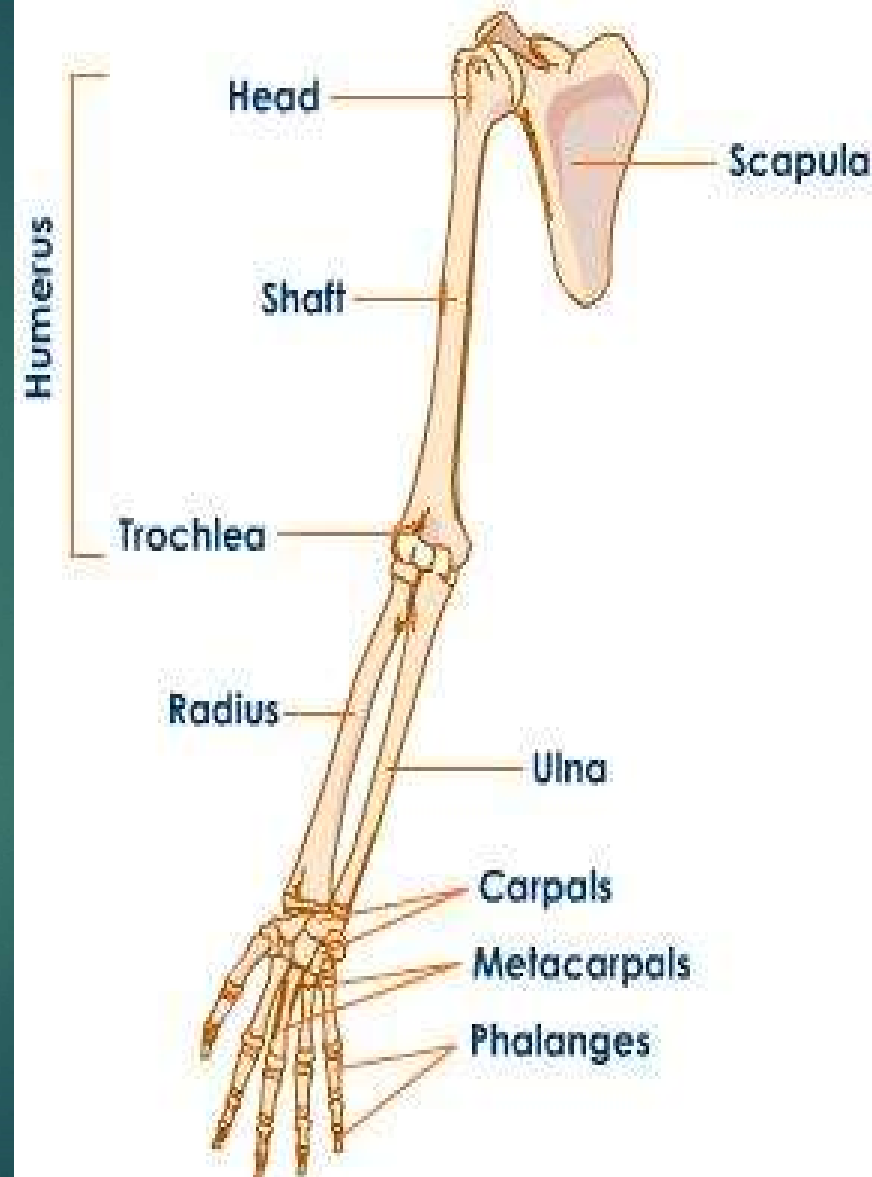
BY

DR. AHMED SALMAN

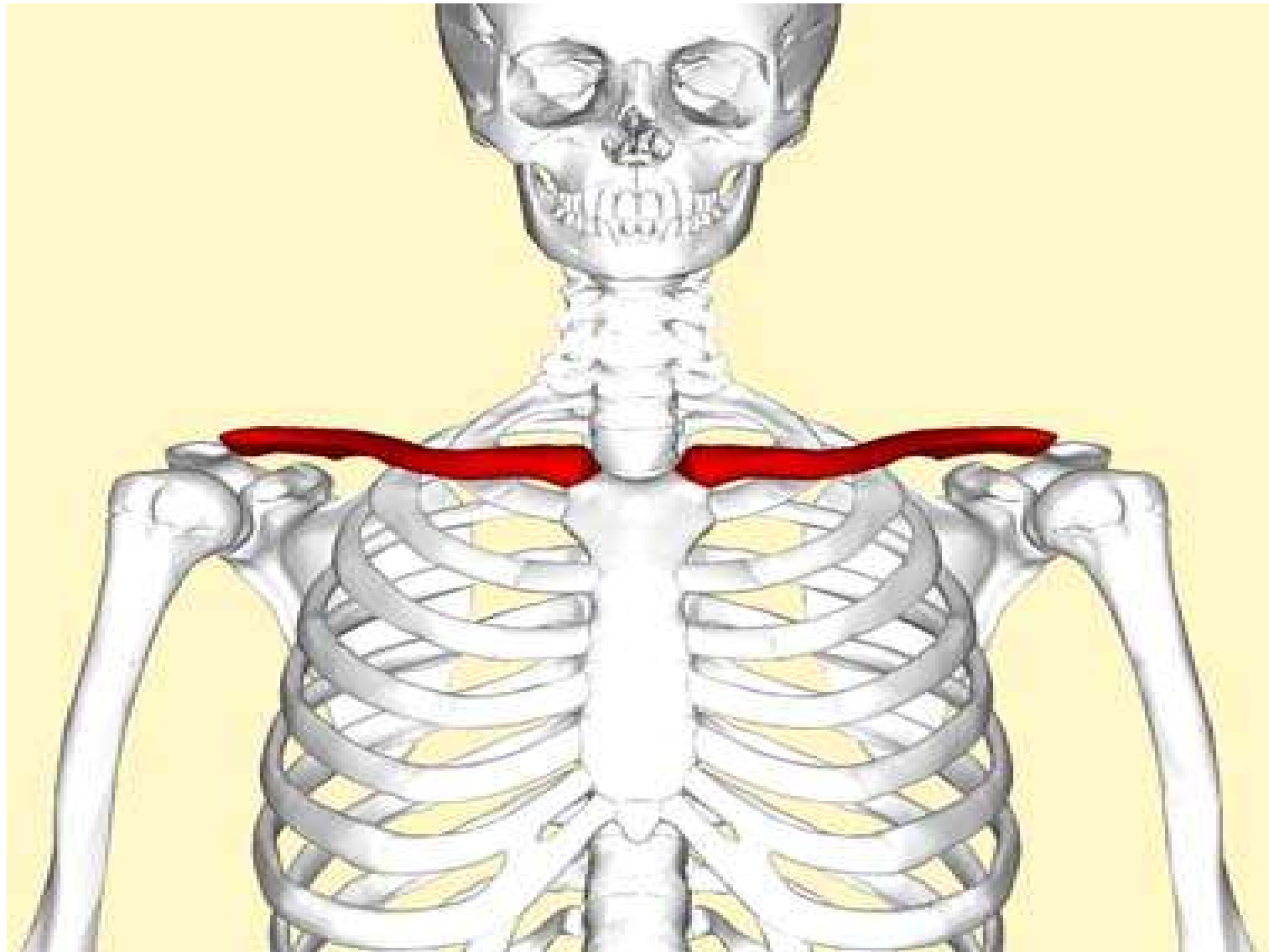
Associate professor of anatomy

The upper limb bones are

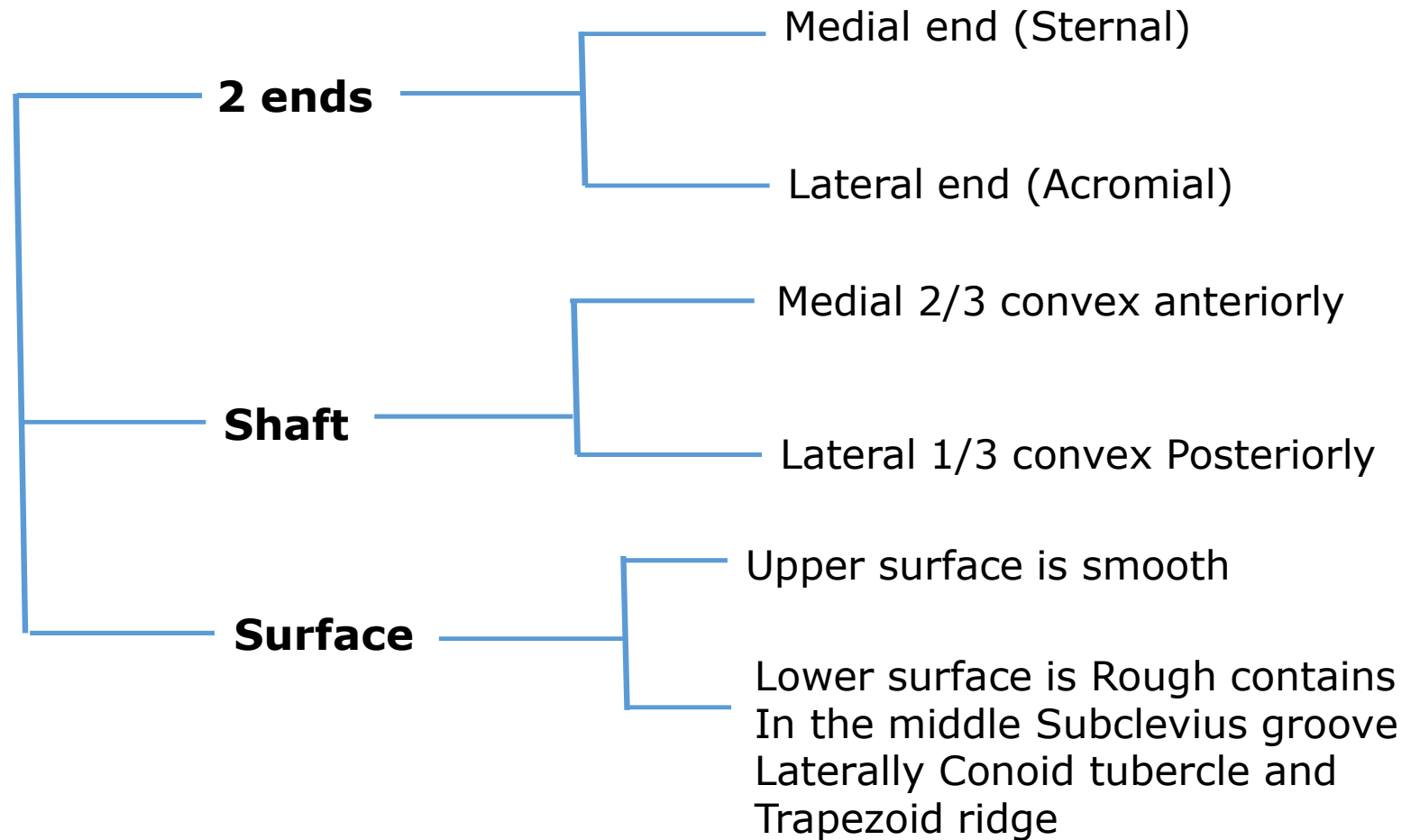
- 1- Clavicle
- 2- Scapula
- 3- Humerus
- 4- Ulna
- 5- Radius
- 6- Eight Carpal bones
- 7- Five Metacarpal
- 8- Fourteen Phalanges

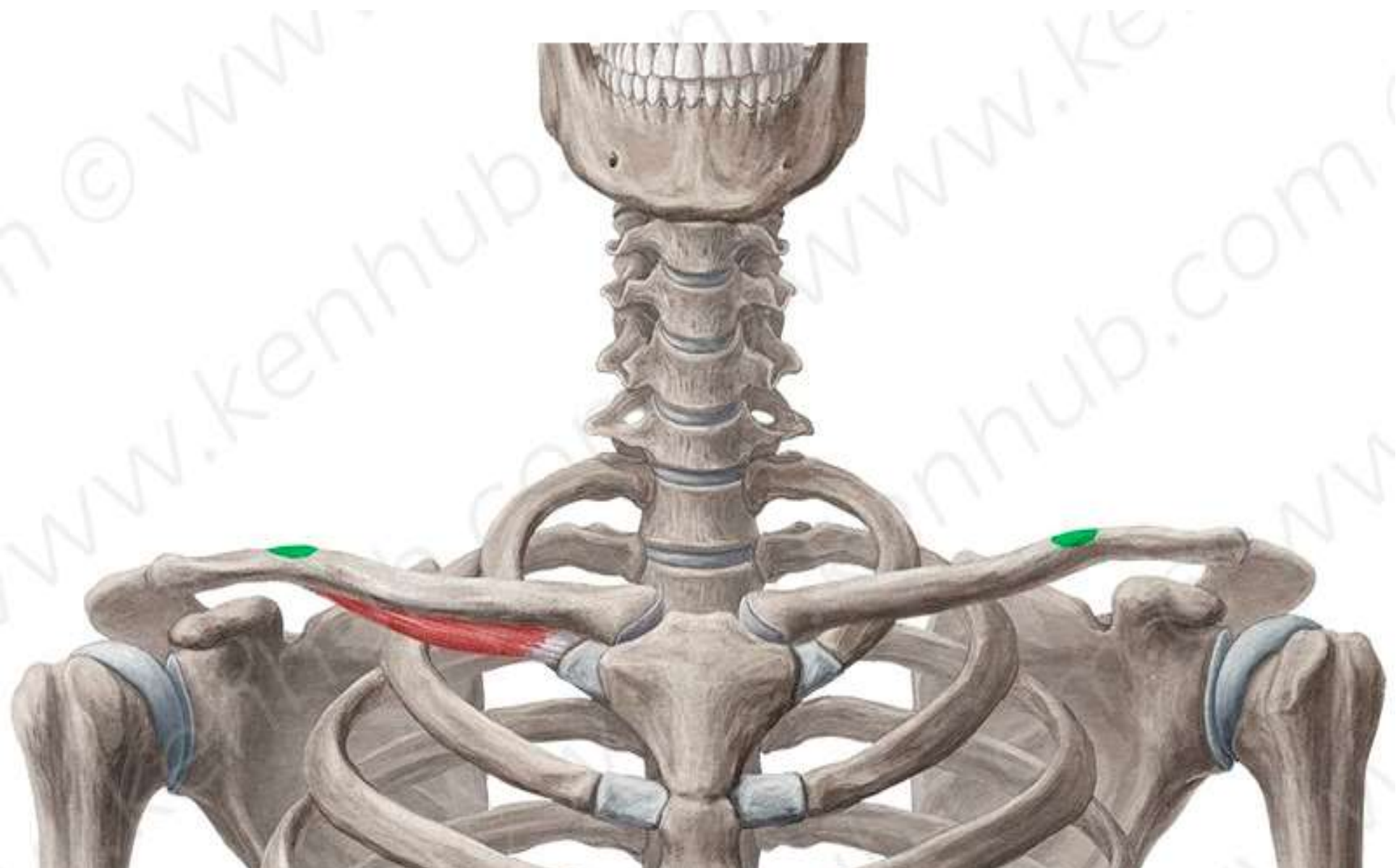


Clavicle



Clavicle





L

Anterior

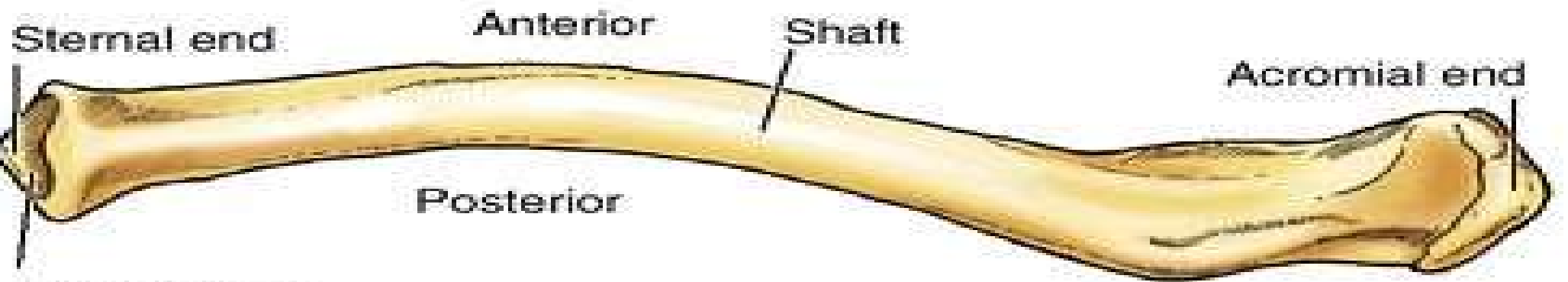
M

Posterior

Anterior

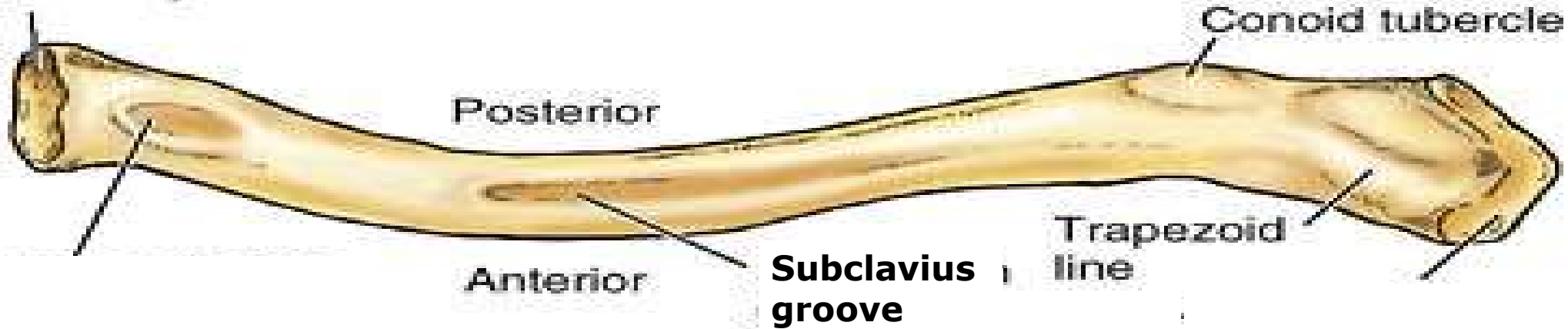
KEN
HUB

Right clavicle

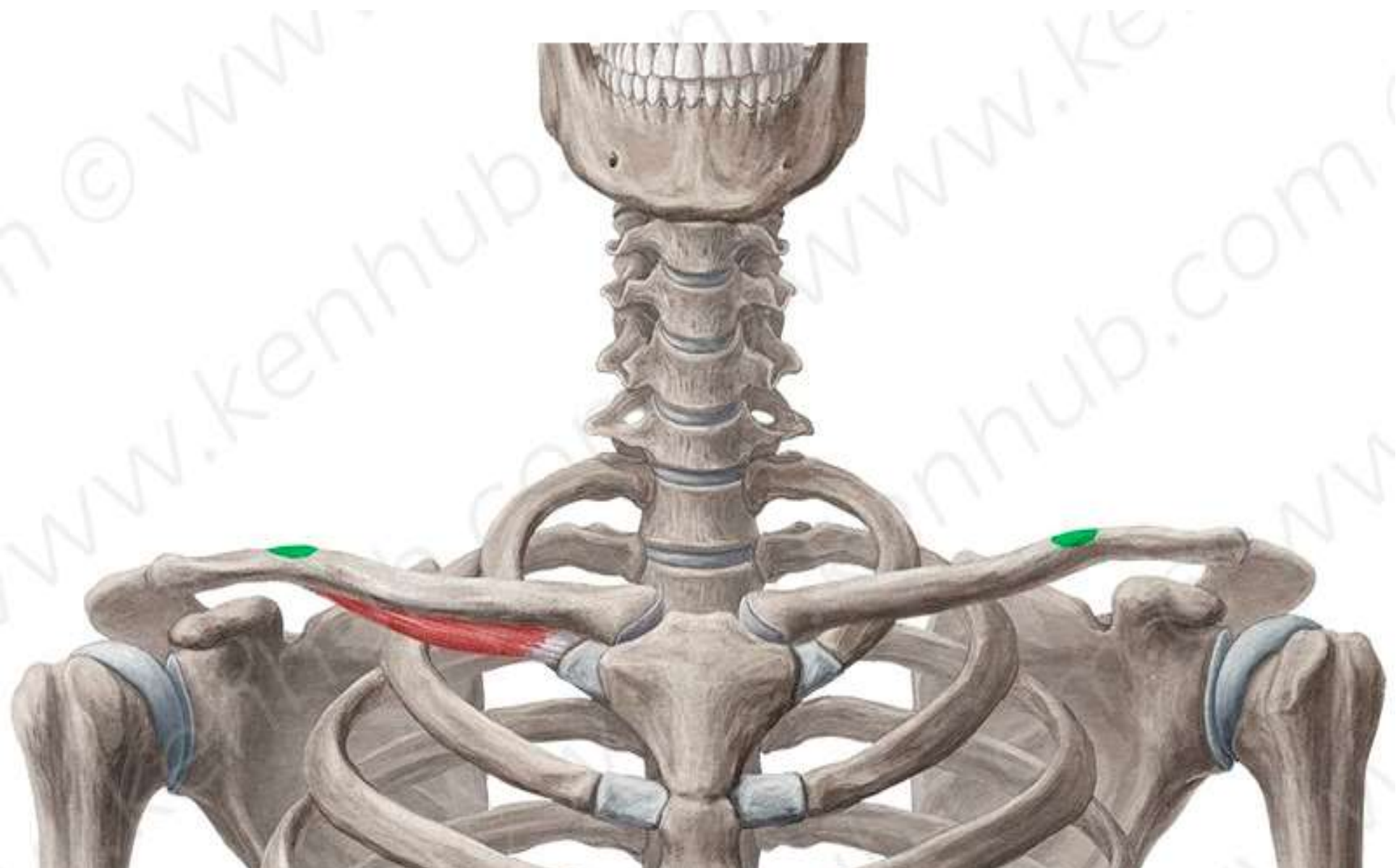


Sternal facet
(articular
surface)

Superior surface

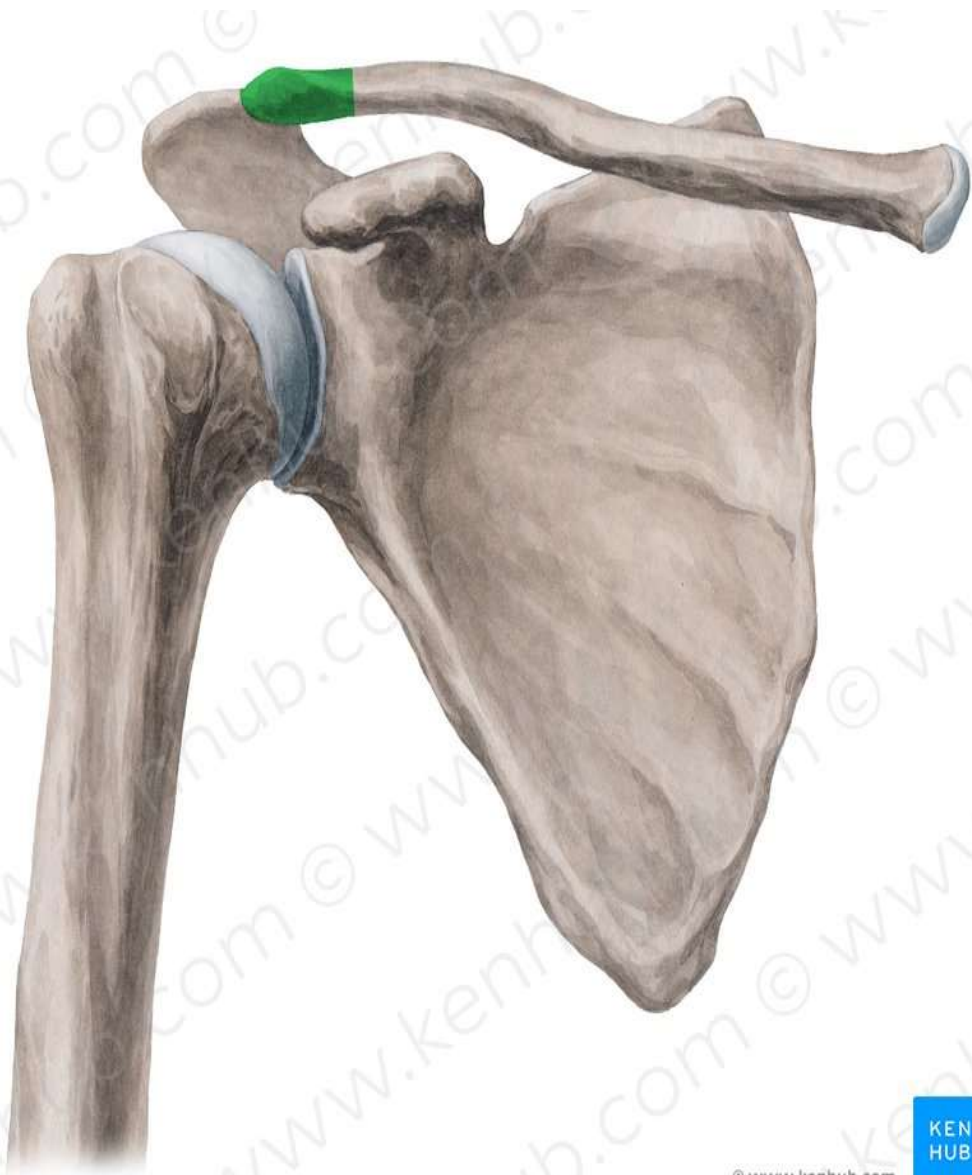


Inferior surface

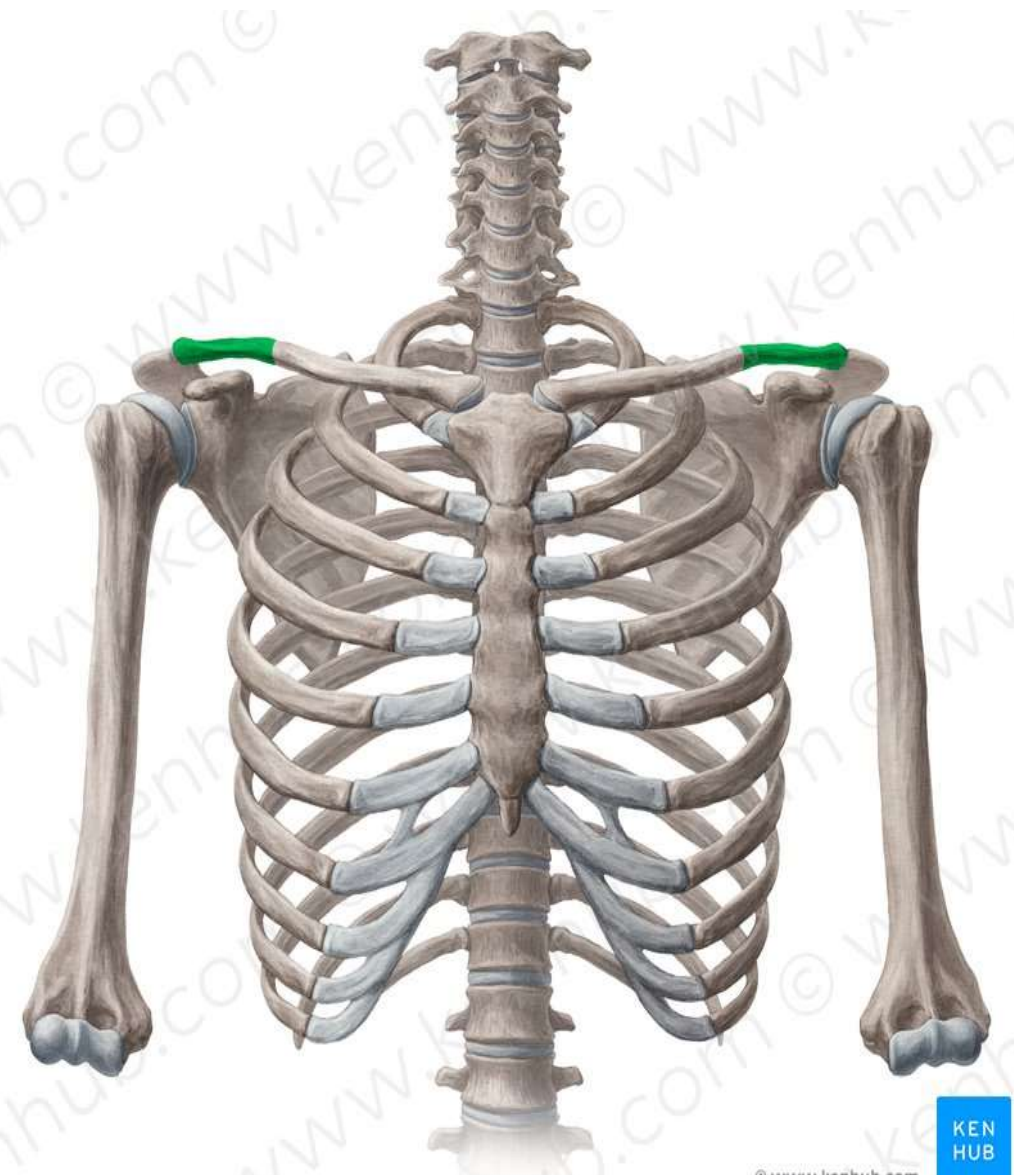




TEST YOUR KNOELDGE

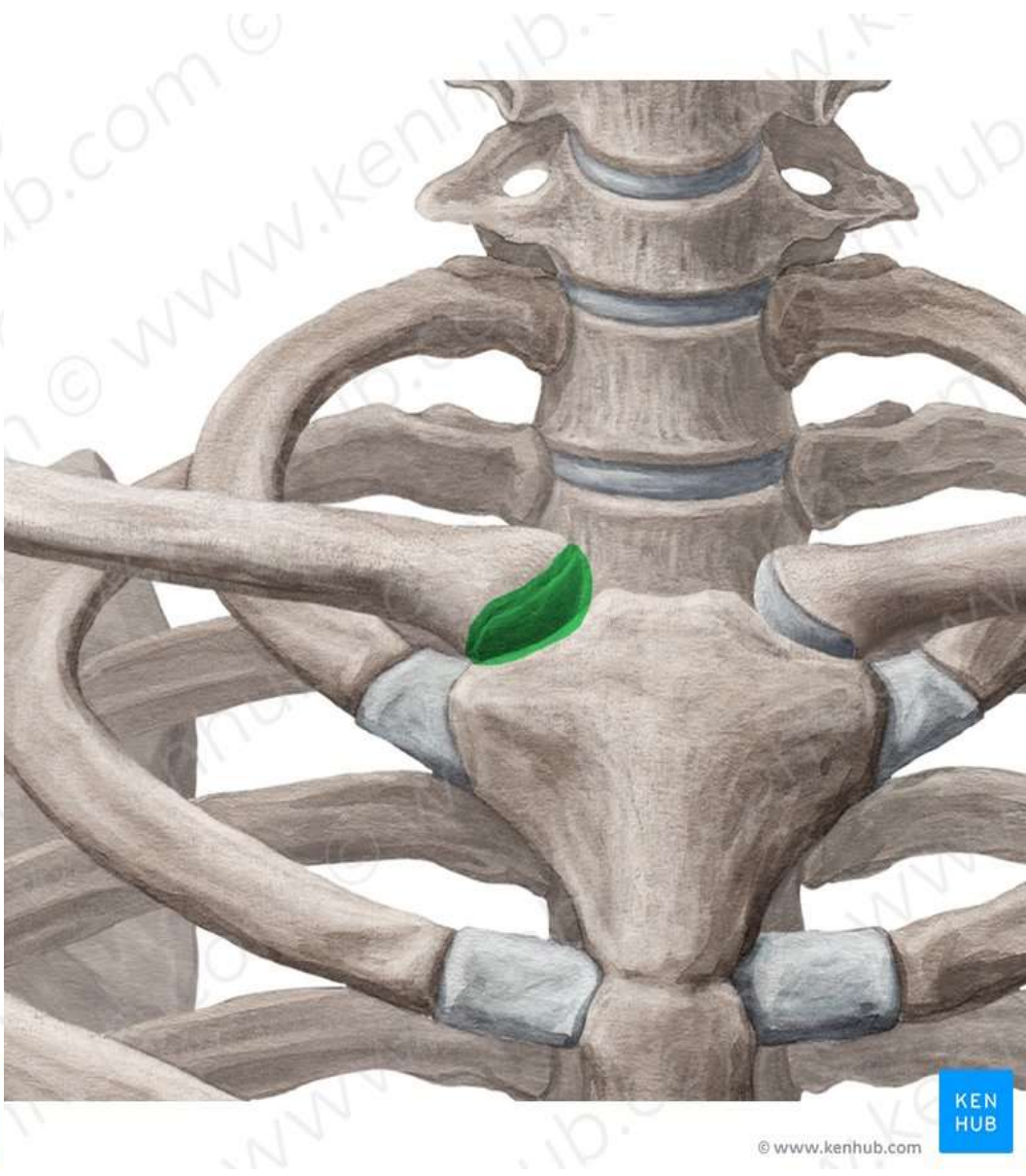
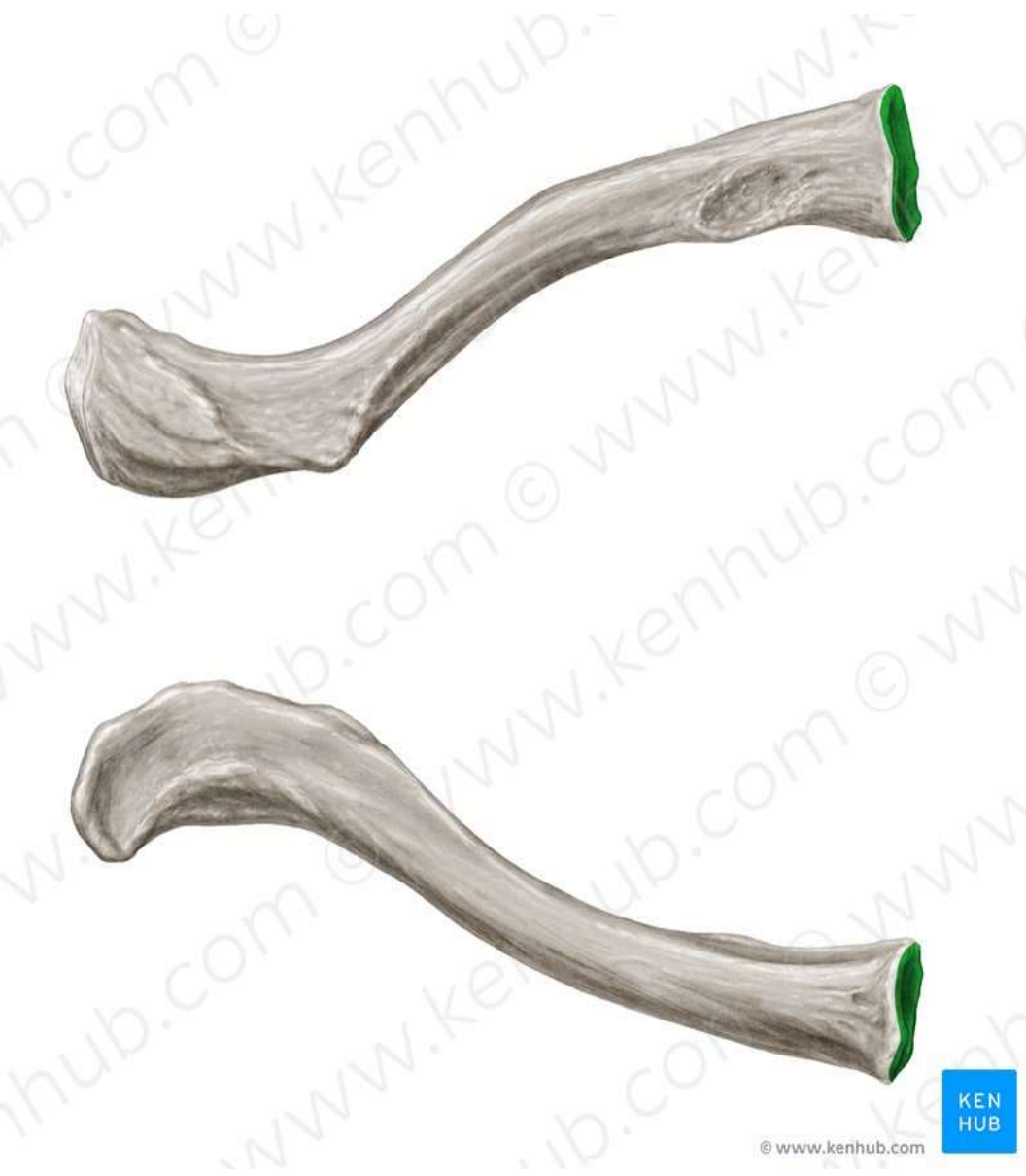

© www.kenhub.com



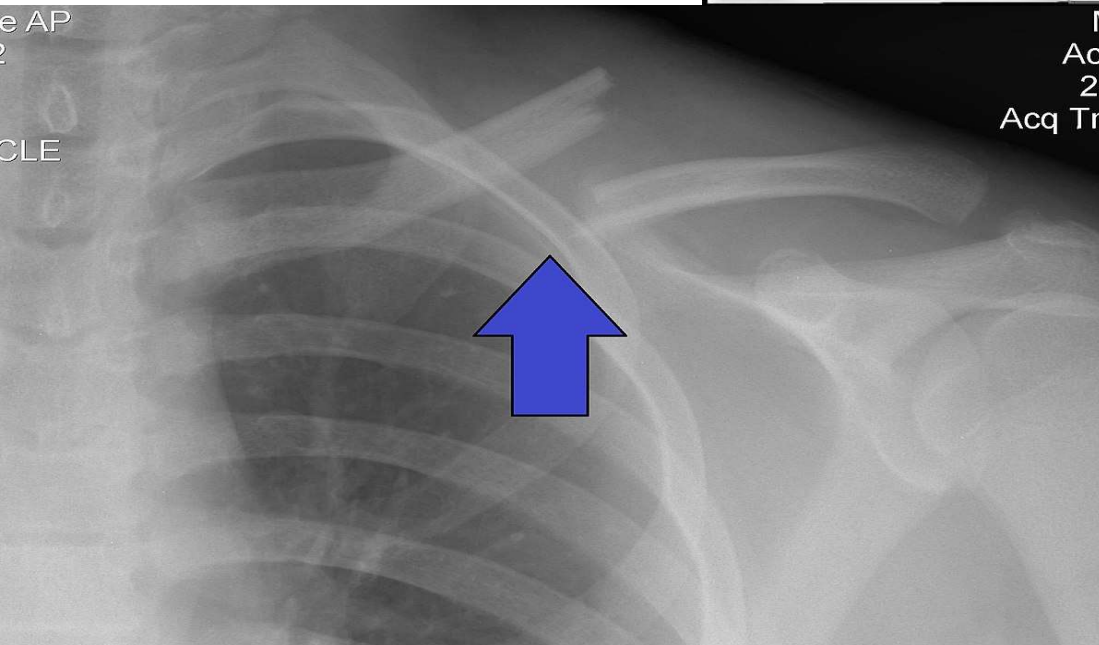
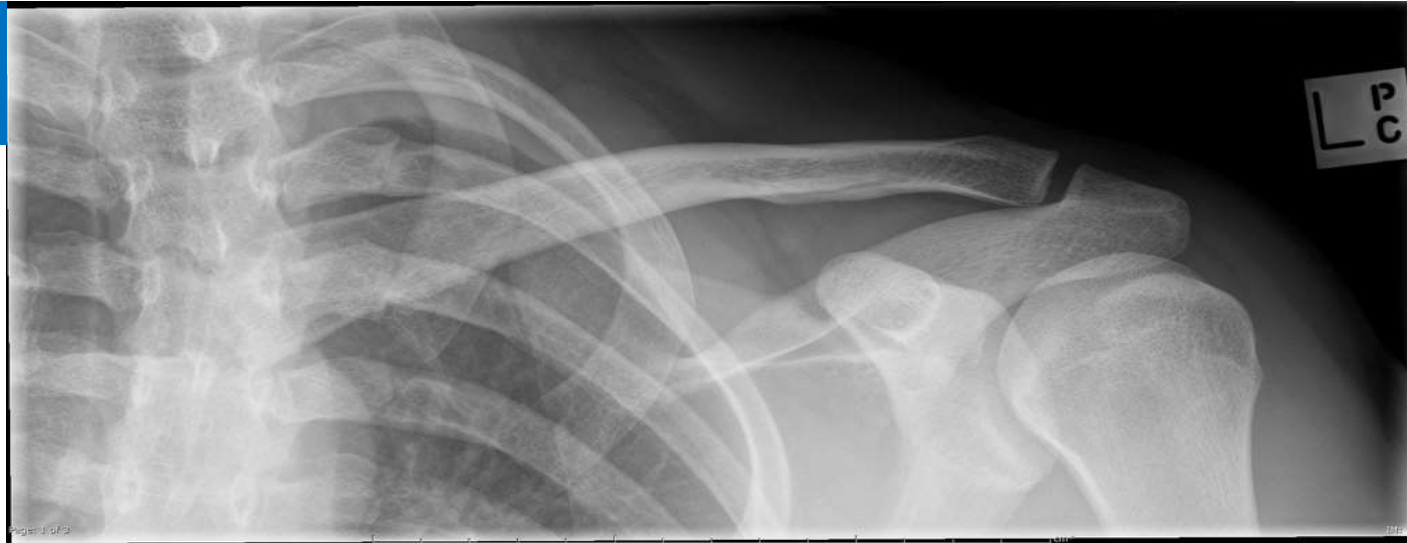© www.kenhub.com





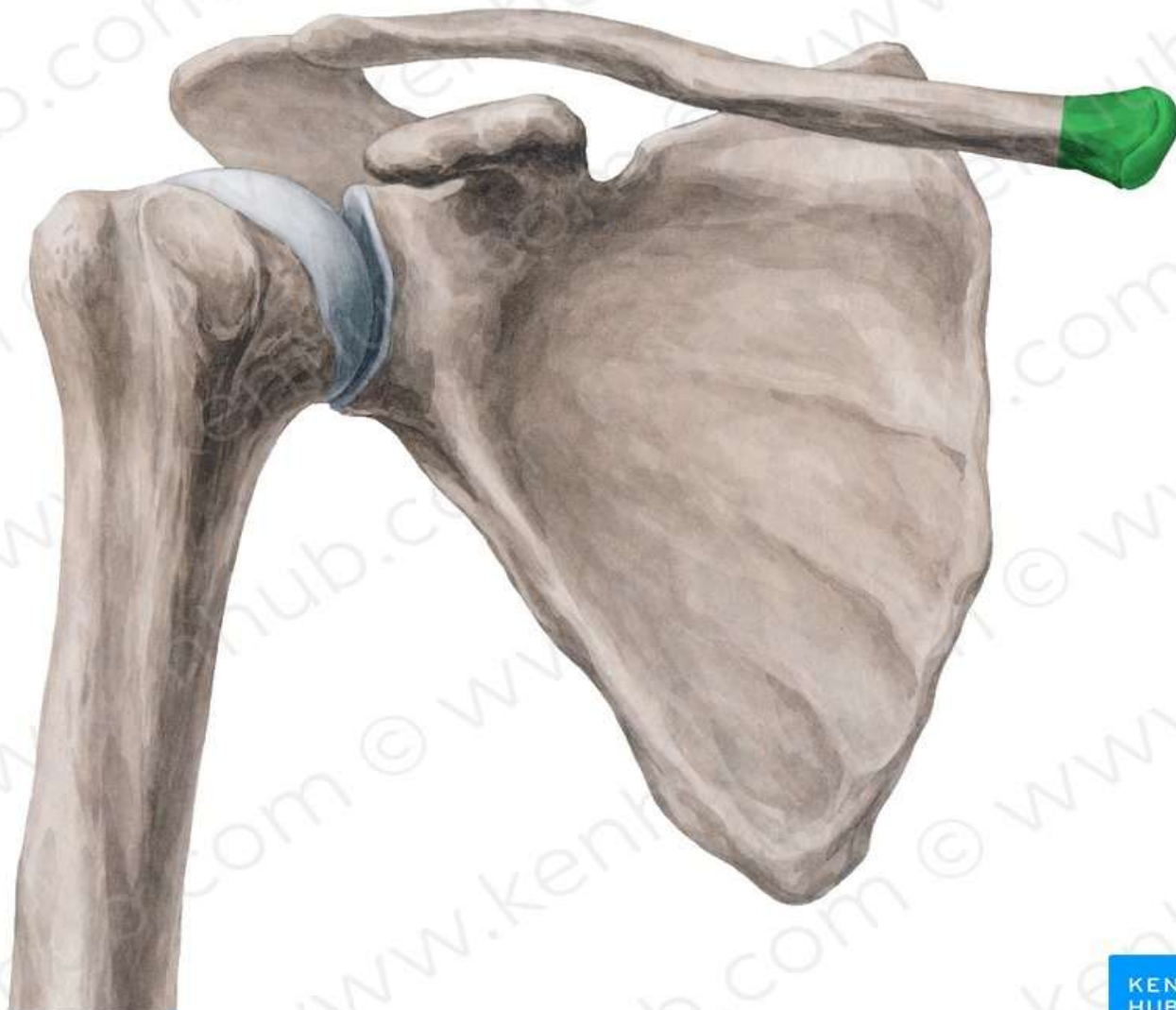


**X ray Normal
Clavicle**

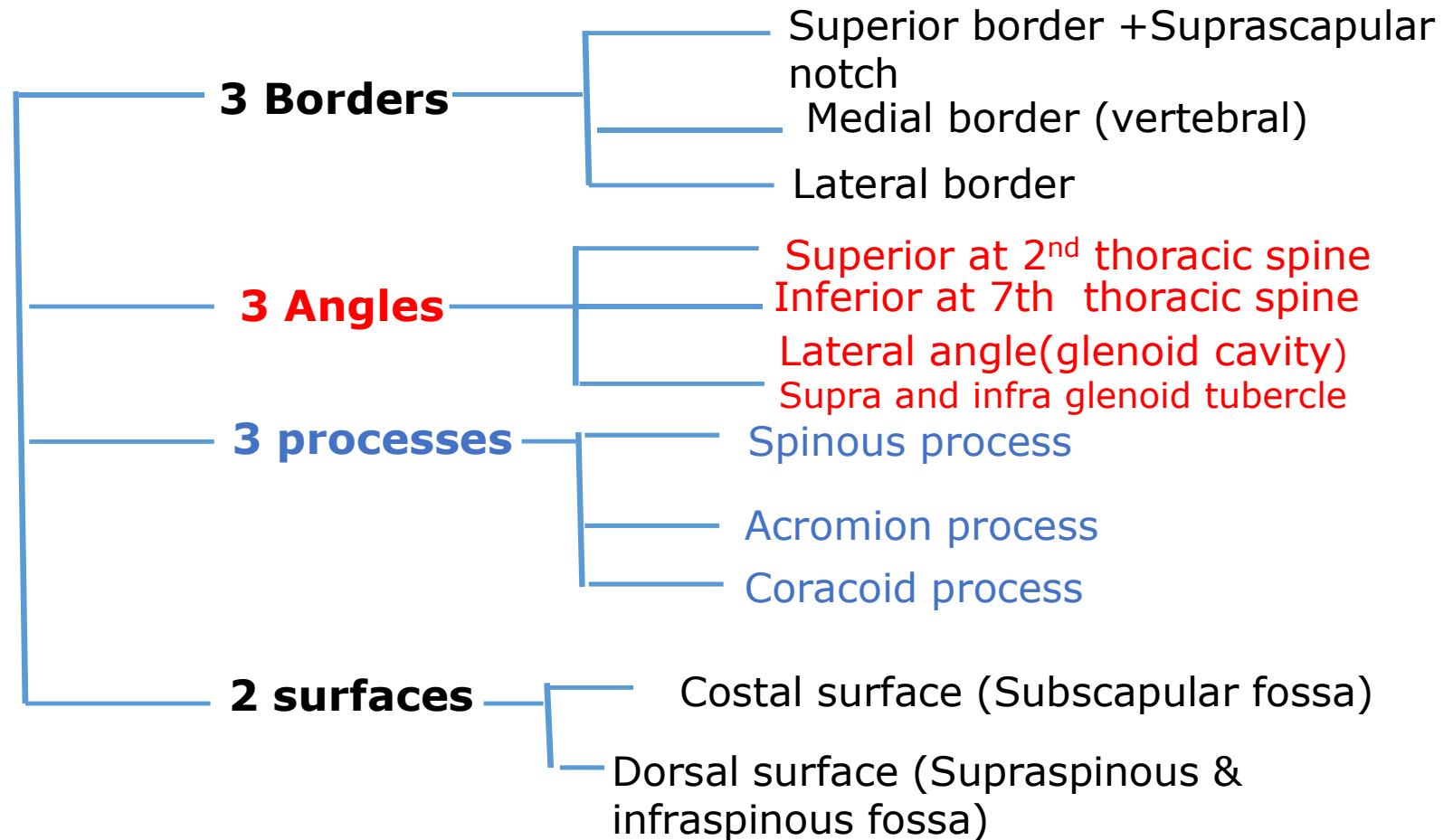


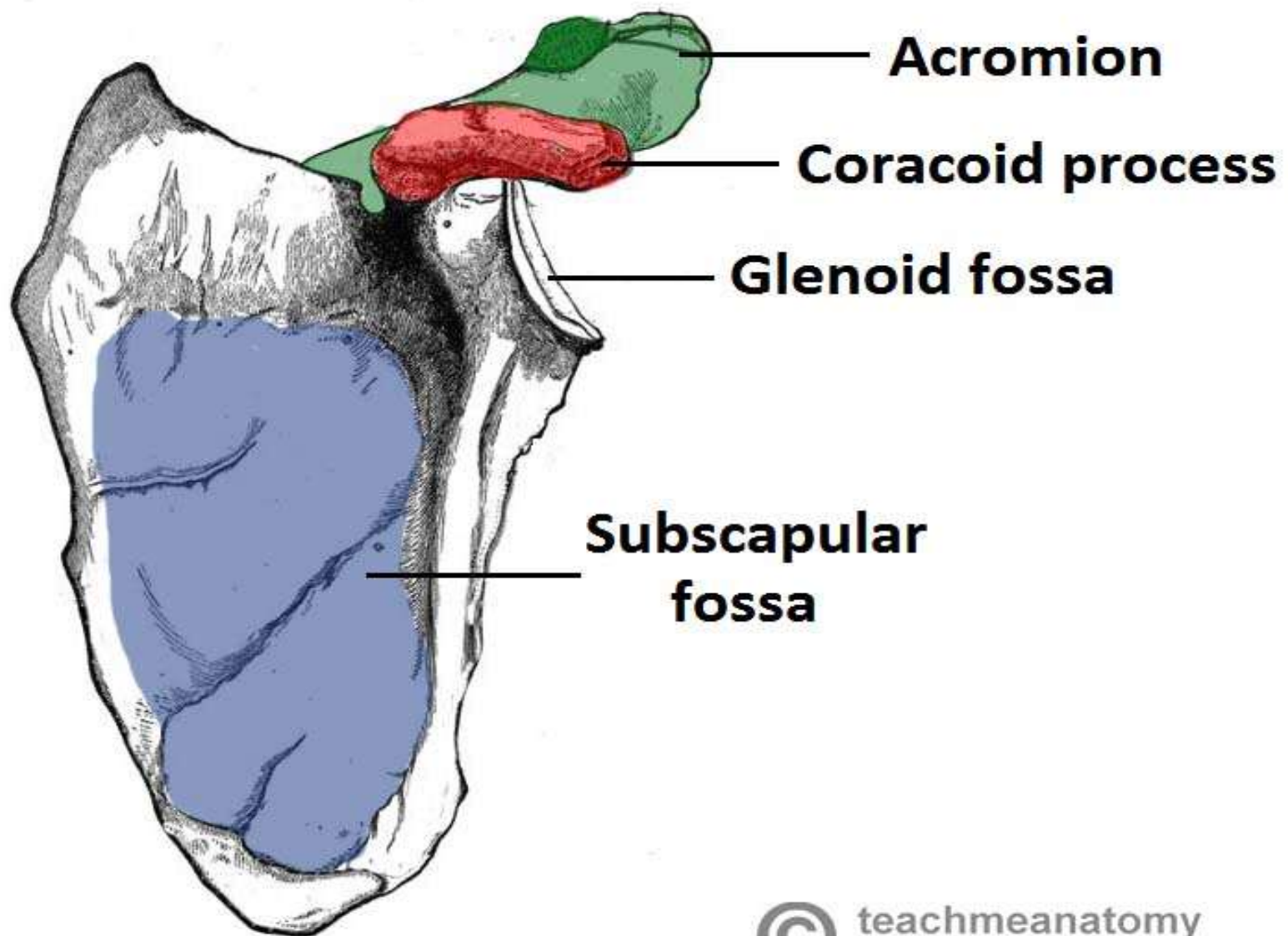
**X ray Fracture
Clavicle**

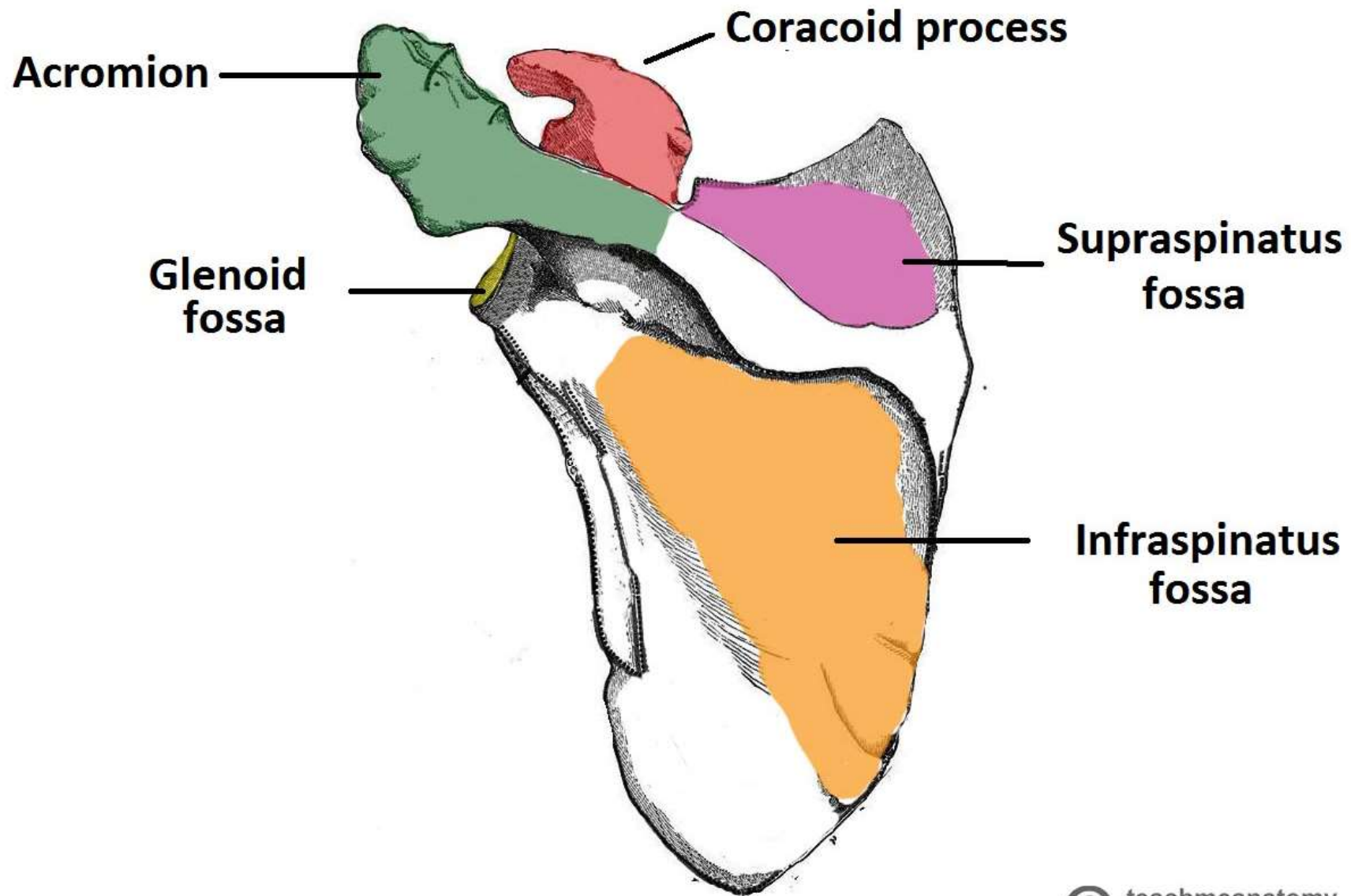
Scapula

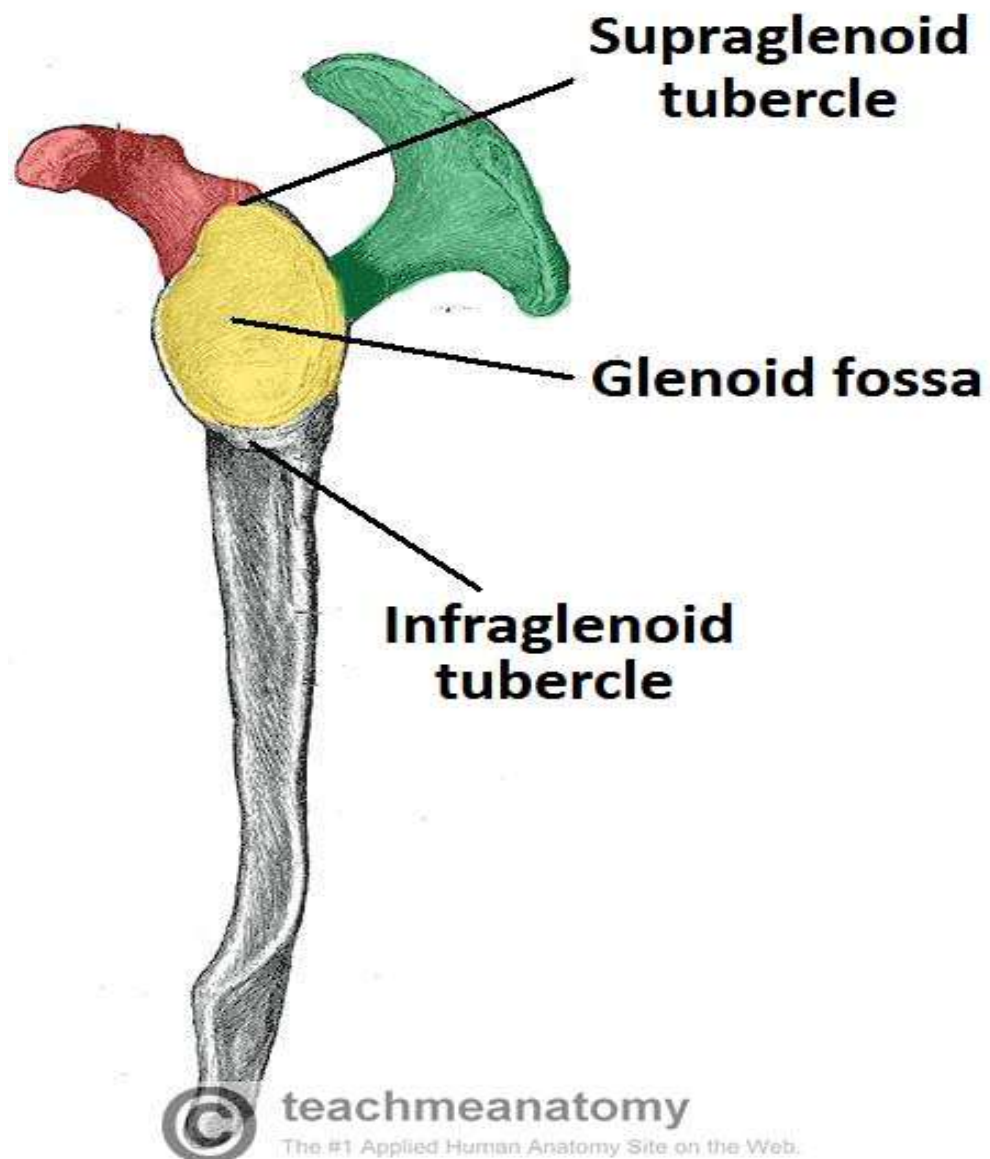


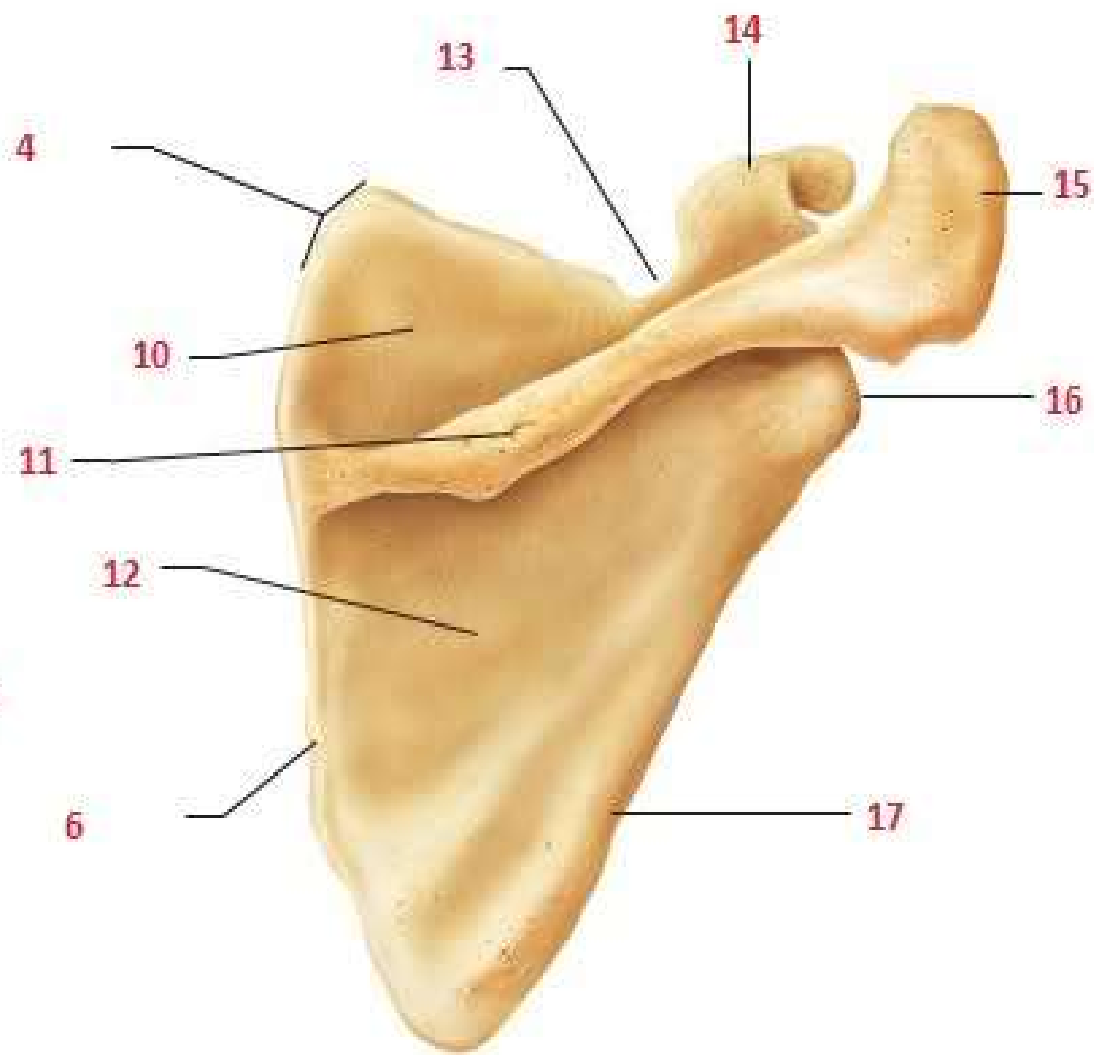
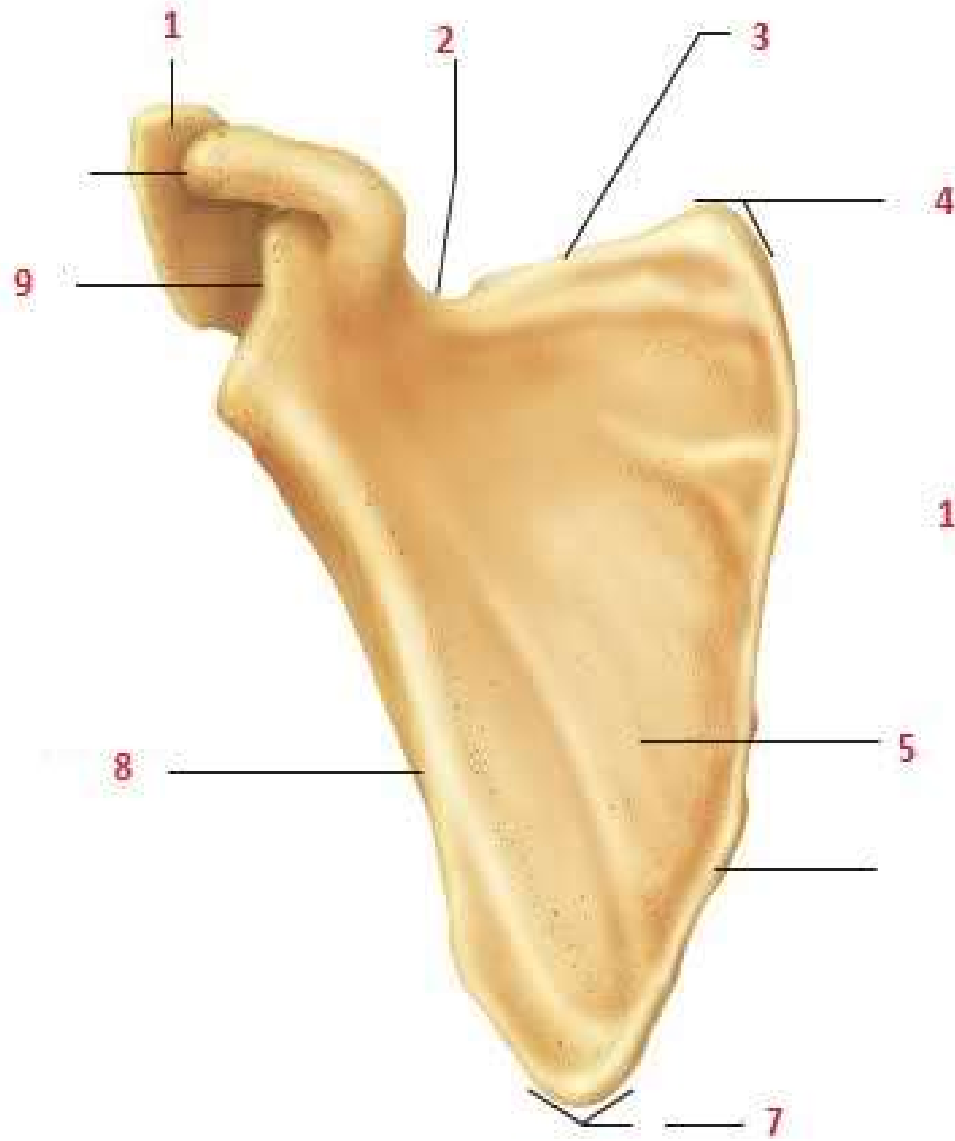
Scapula

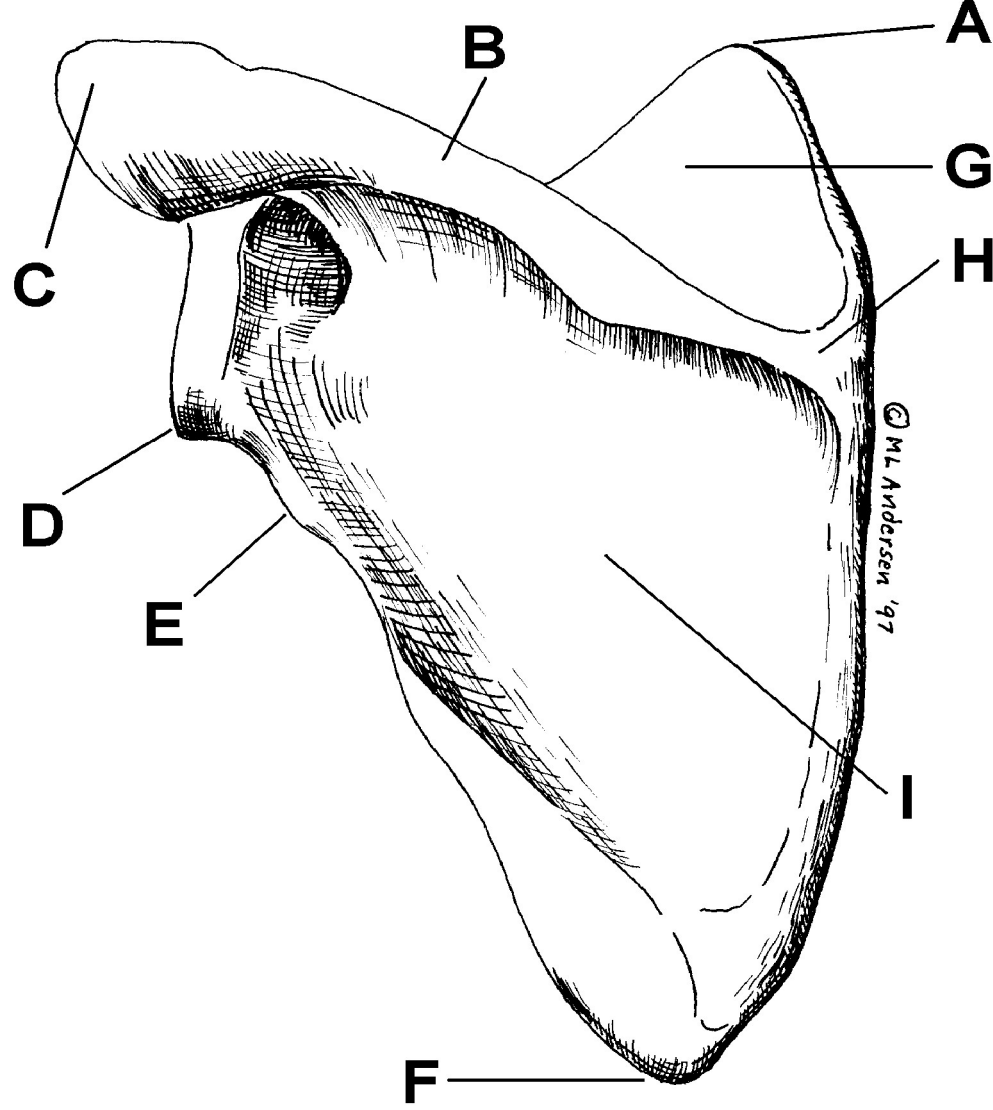
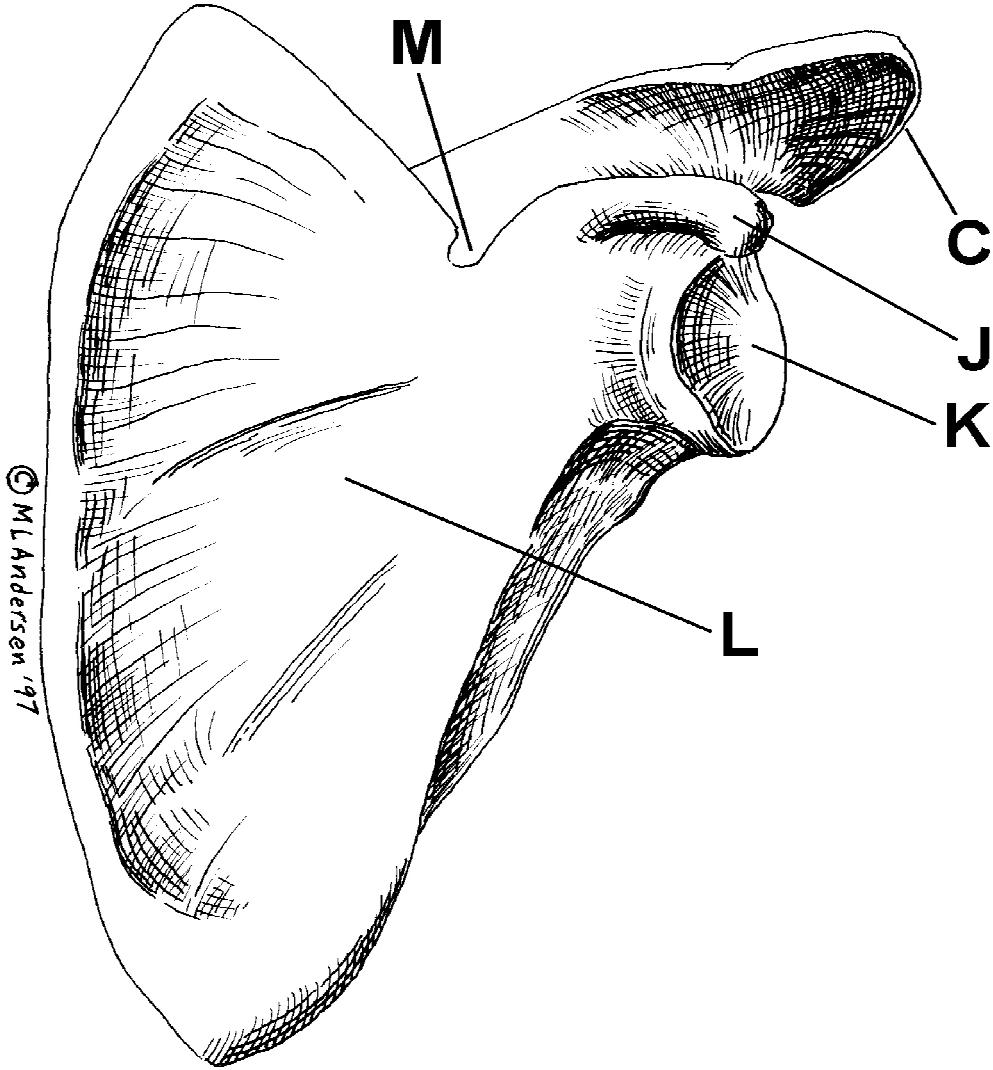


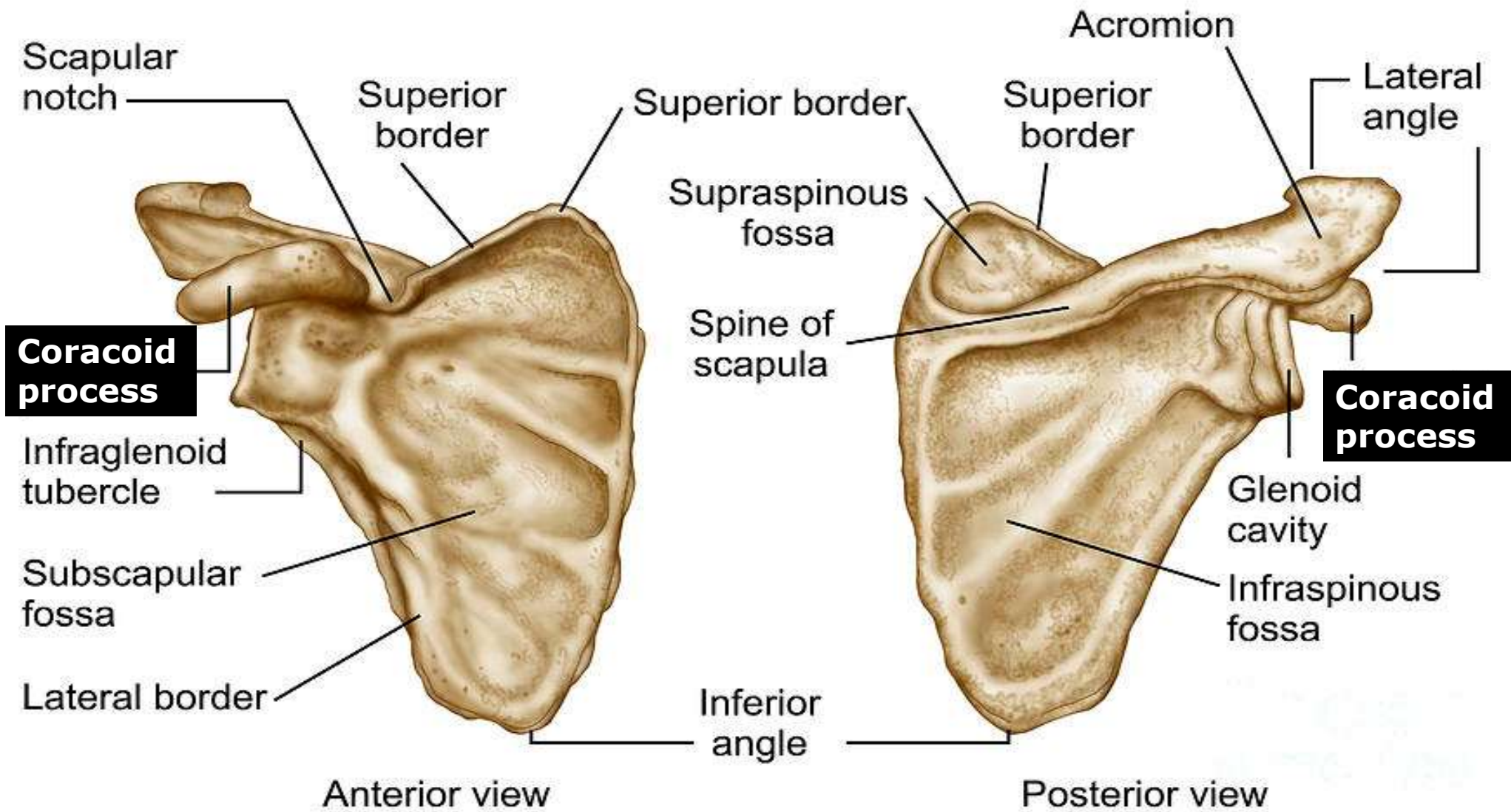






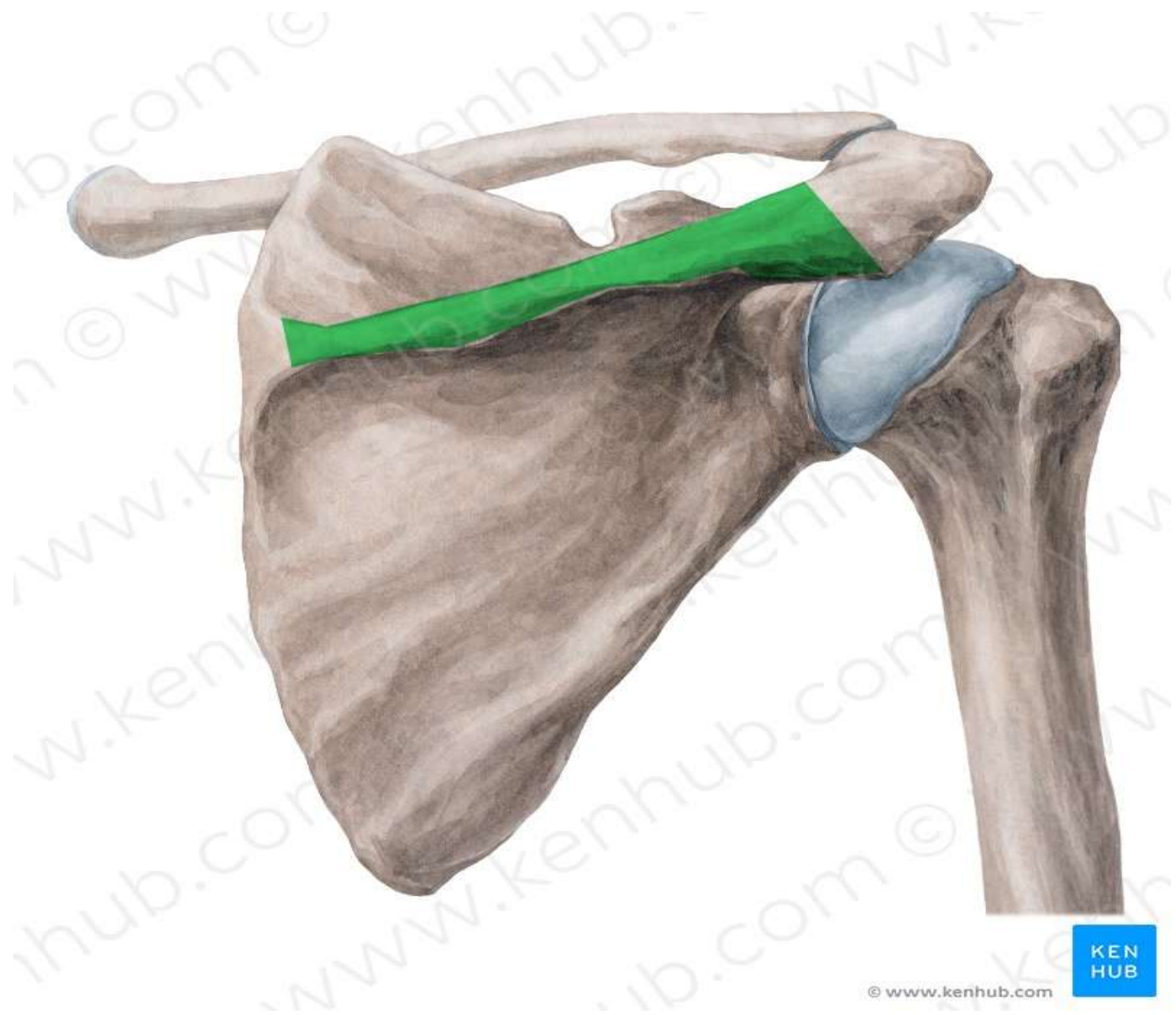


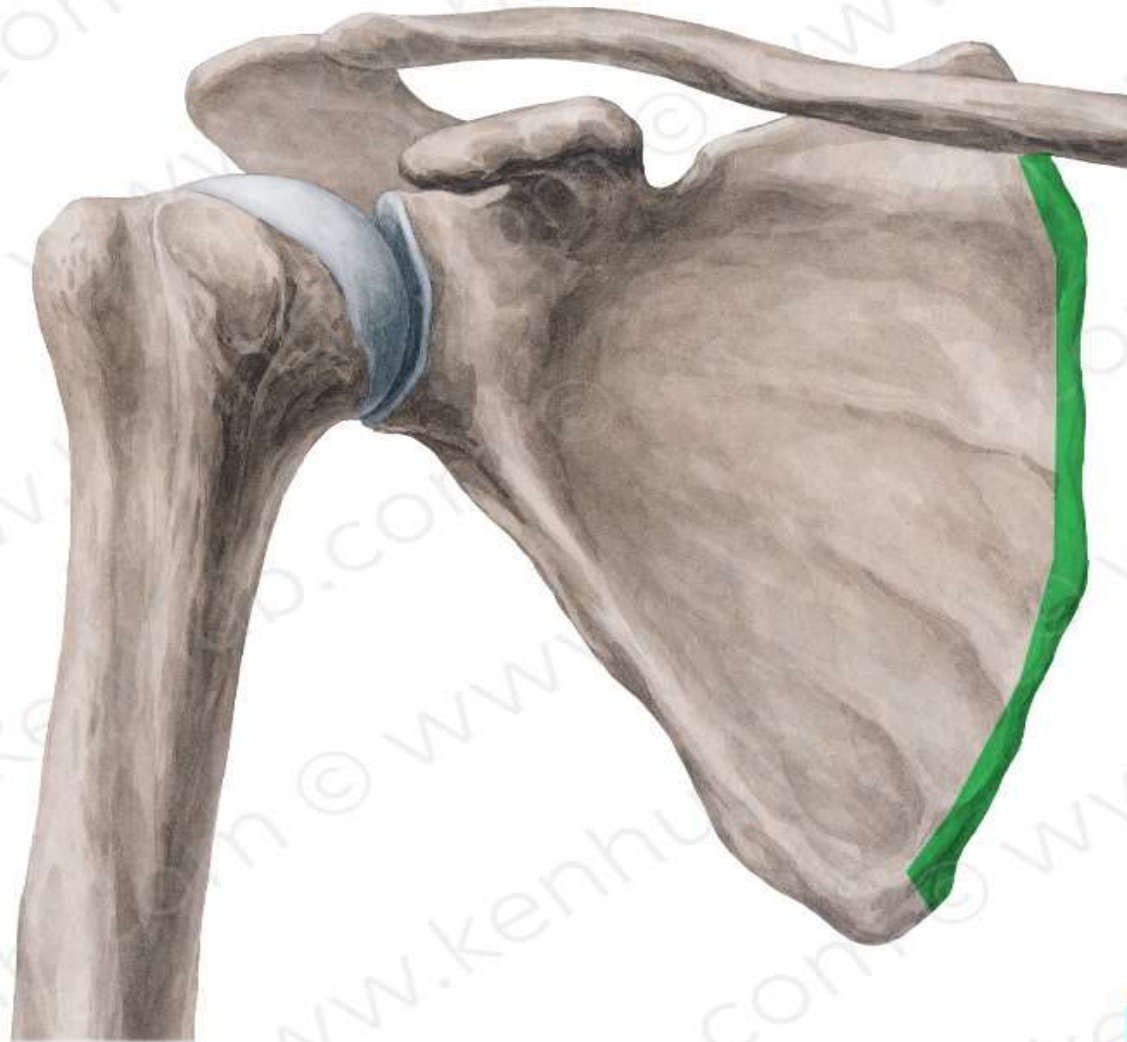


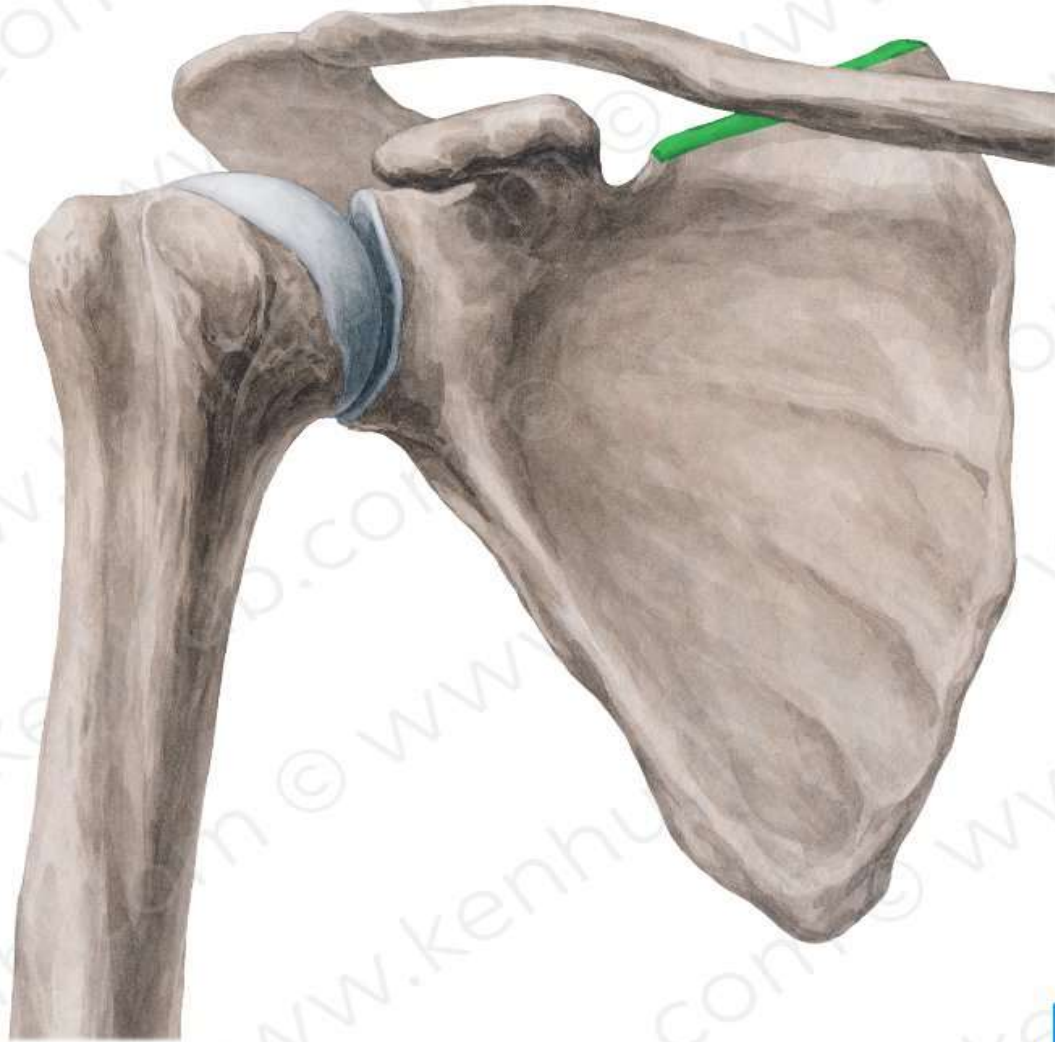


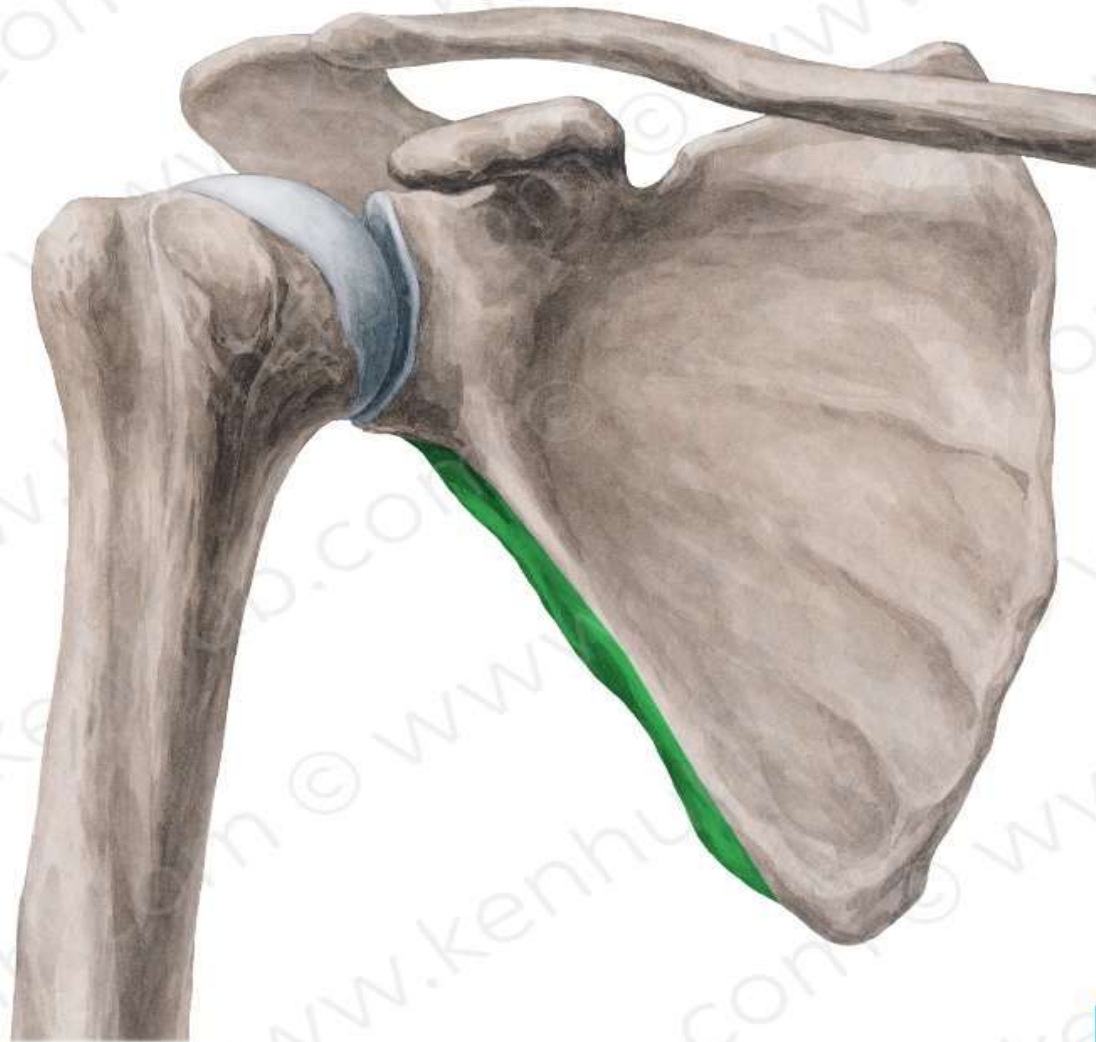


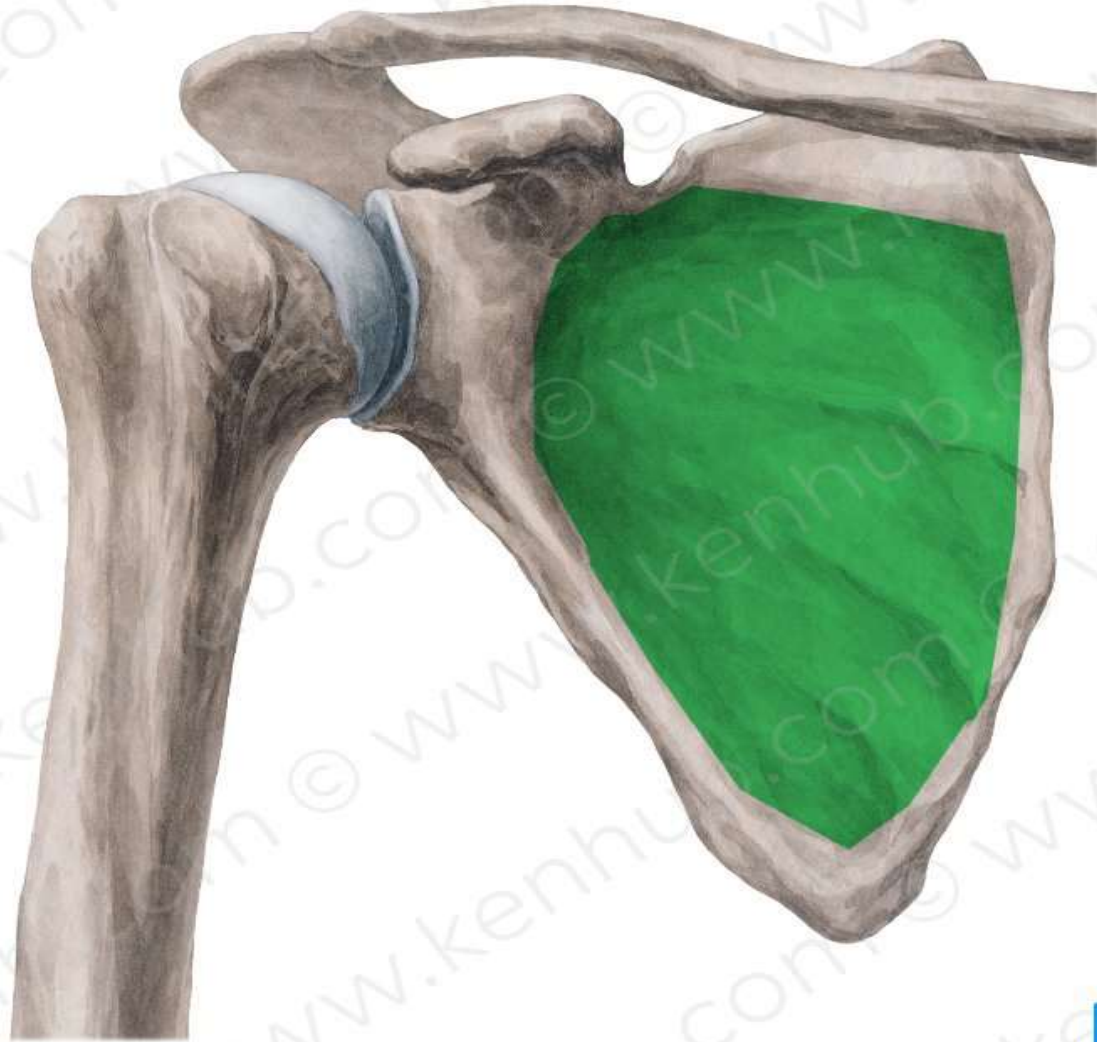
TEST YOUR KNOELDGE

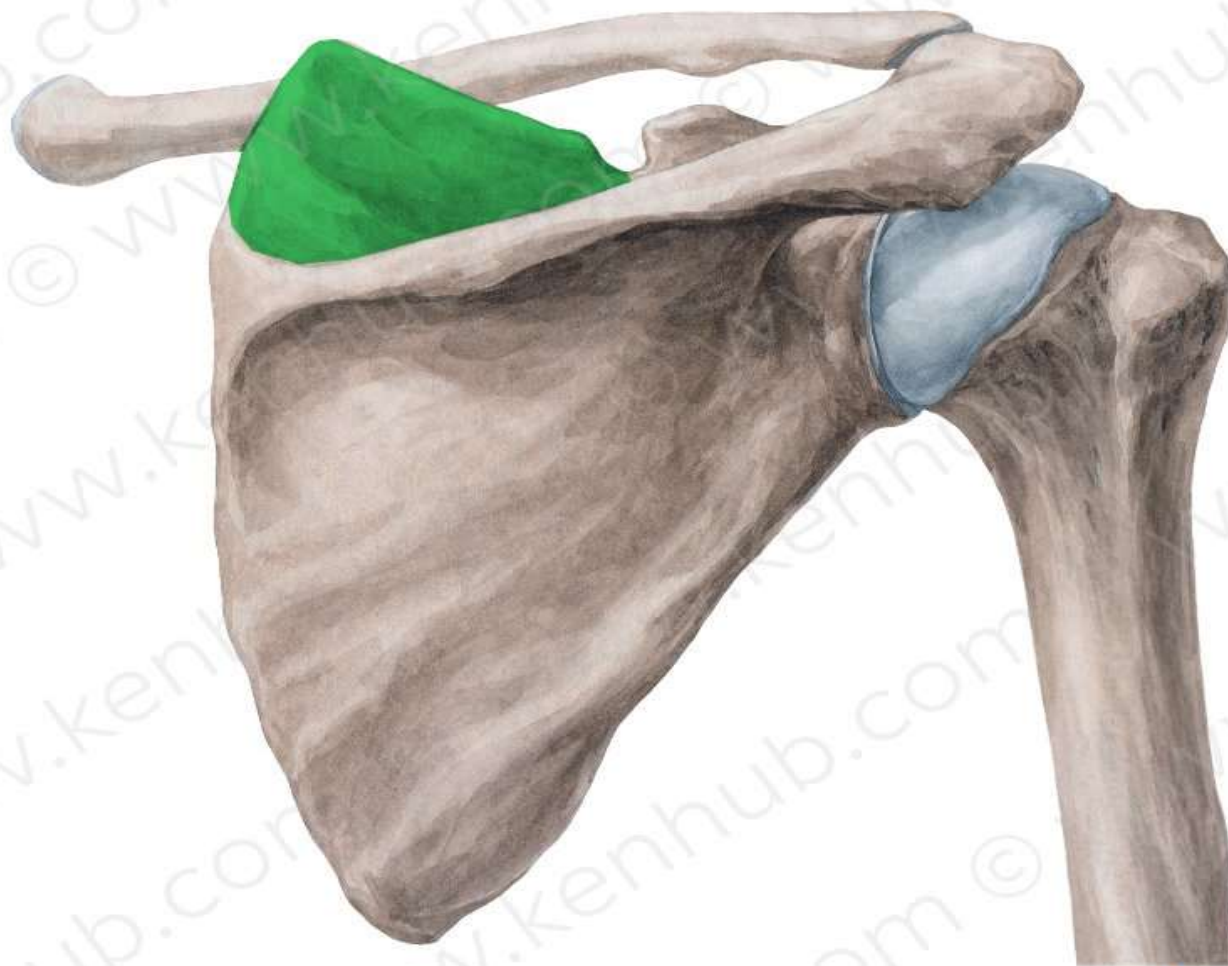


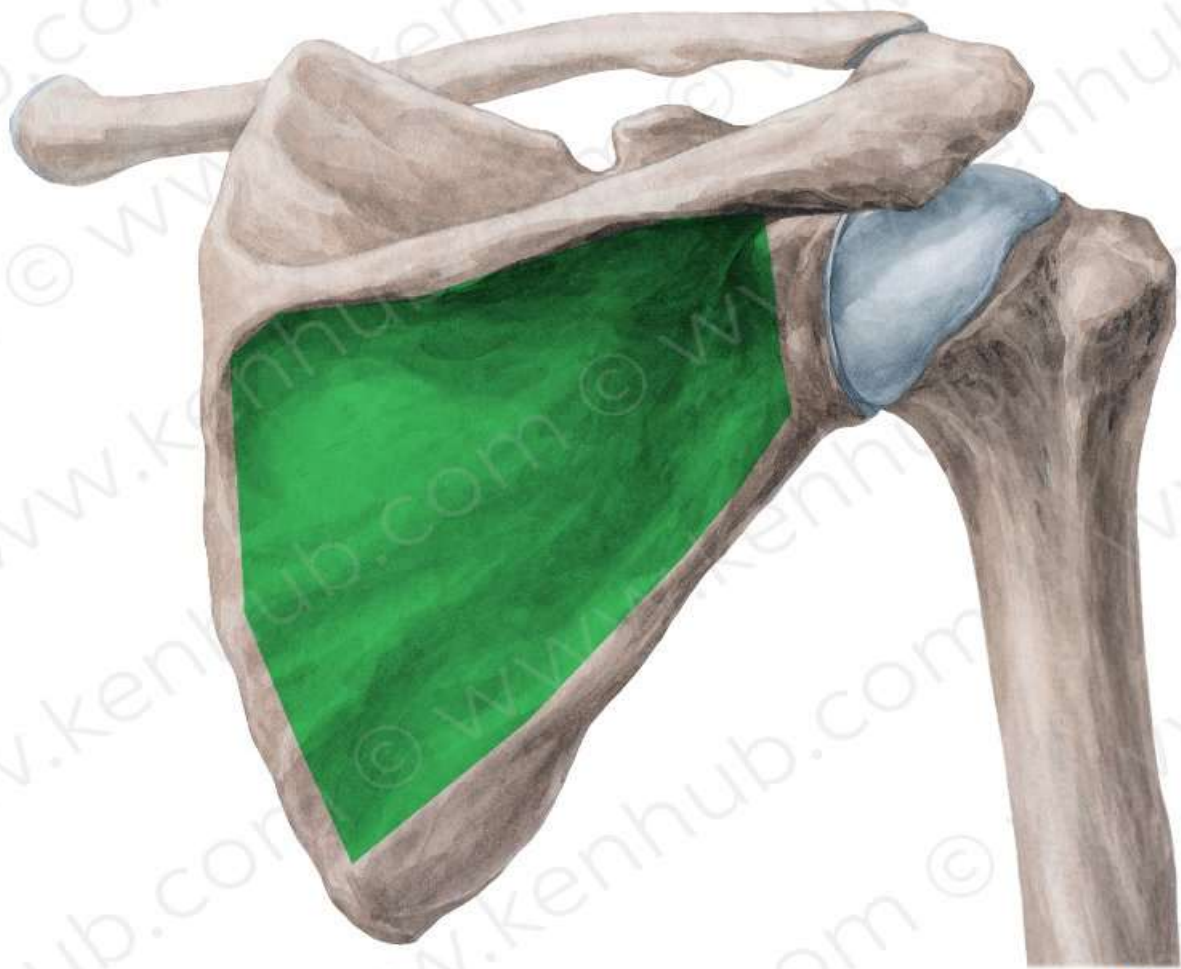


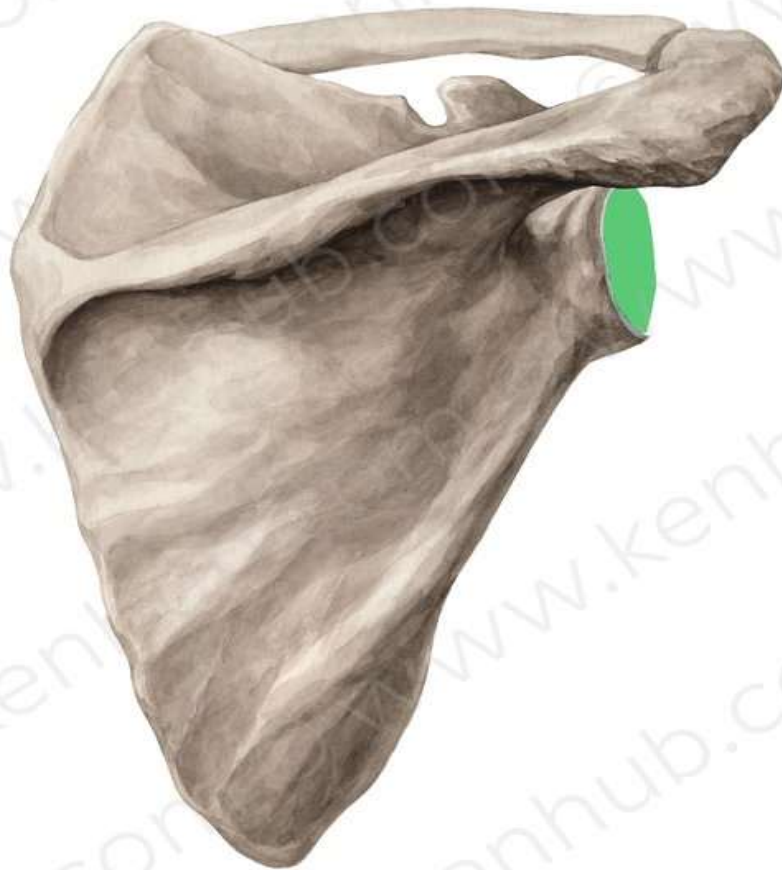


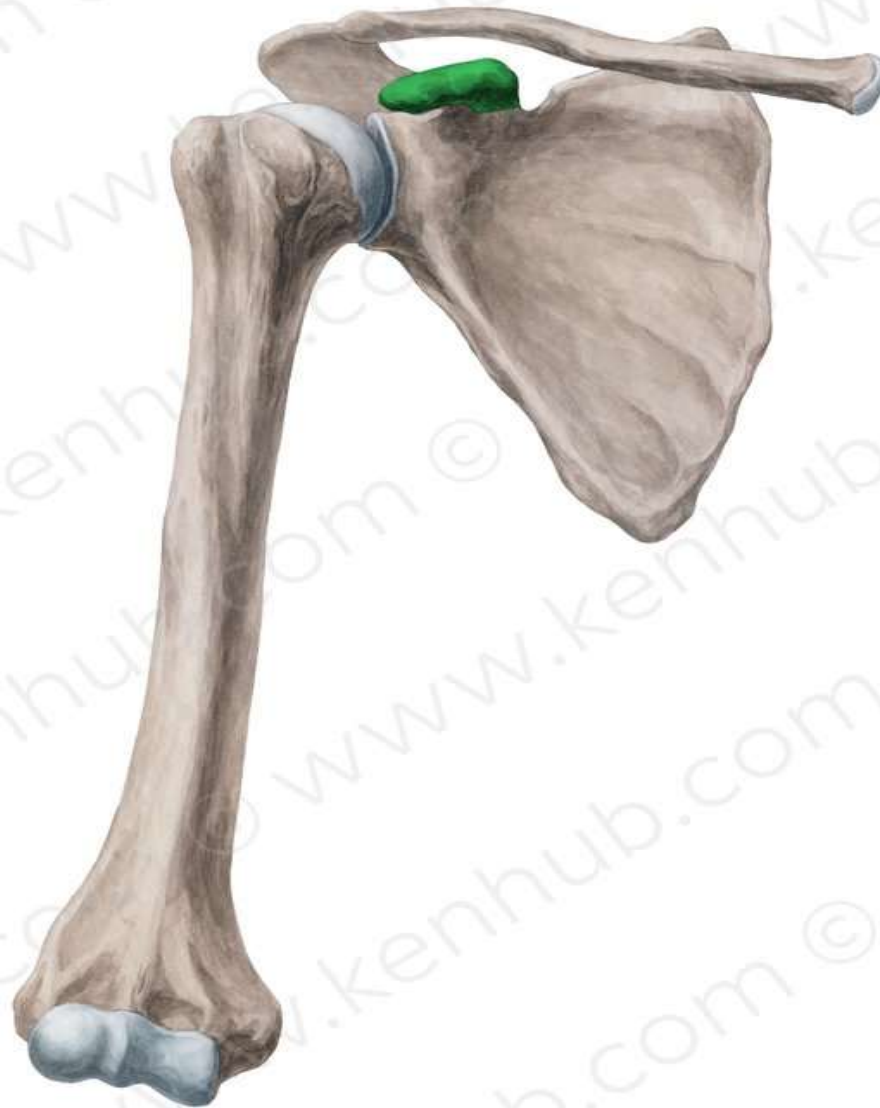














THANK YOU