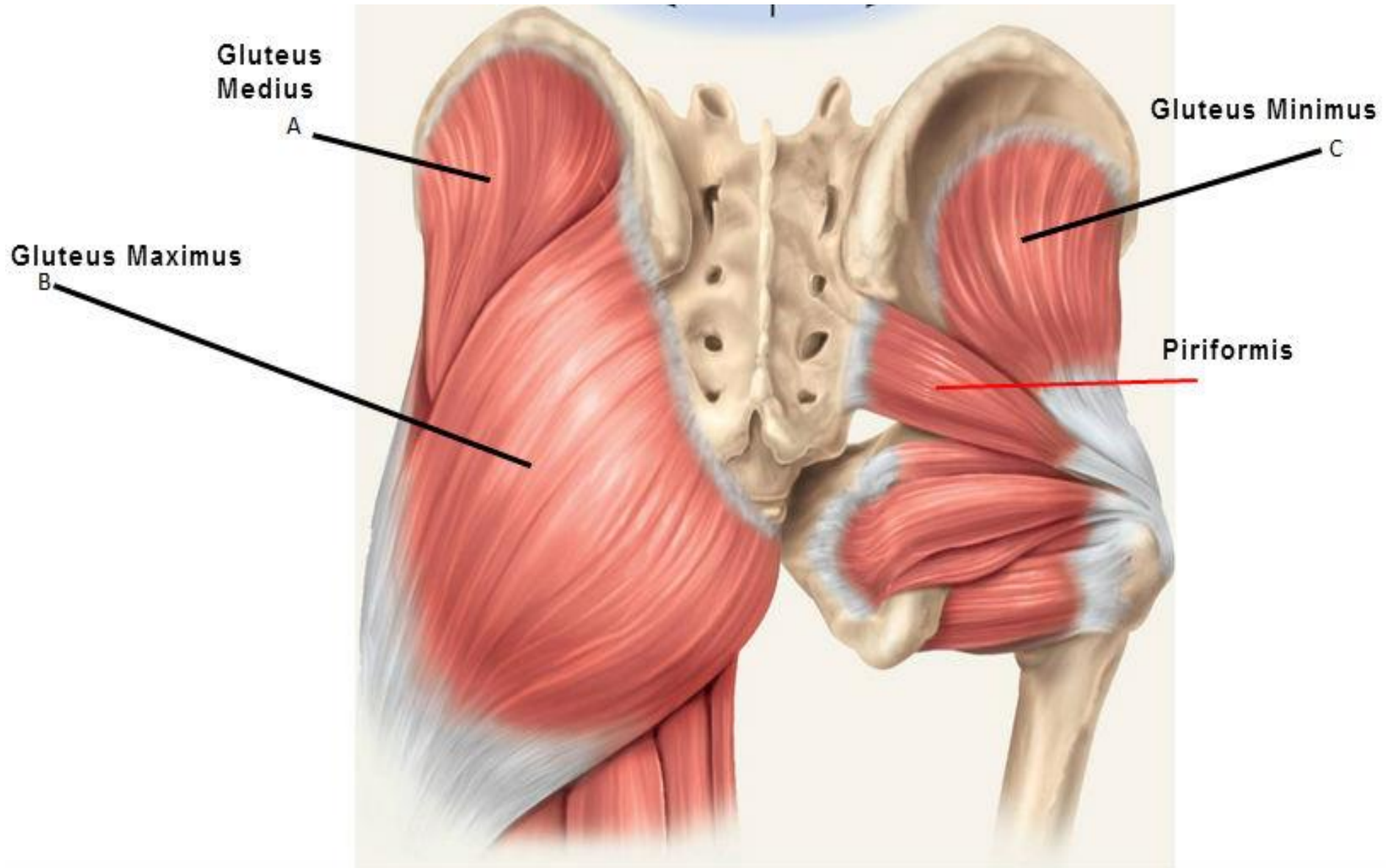


# **Gluteal region and Back of thigh (Lab 3 part 1)**

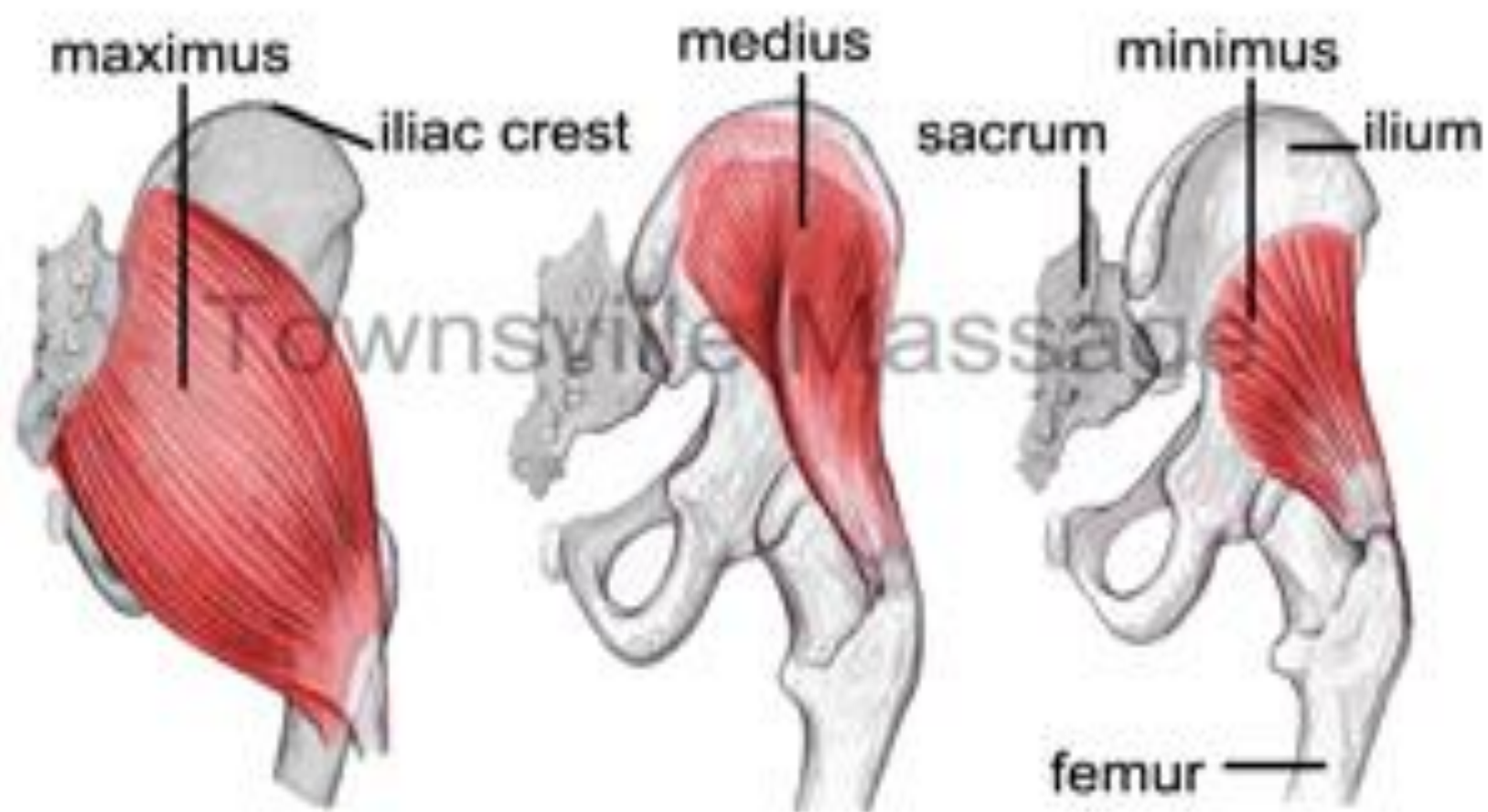**Dr. Maha ELBeltagy**

**Associate Professor of Anatomy, The University Of  
Jordan**

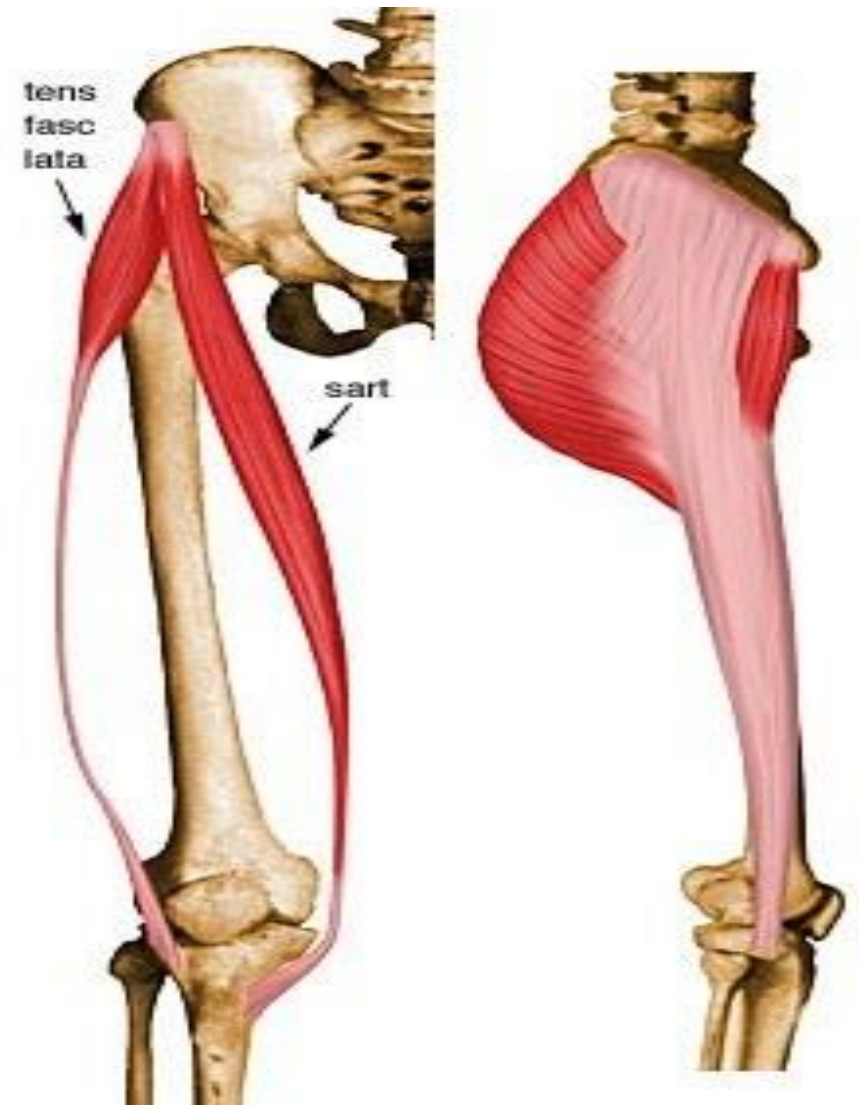
# Gluteal Region



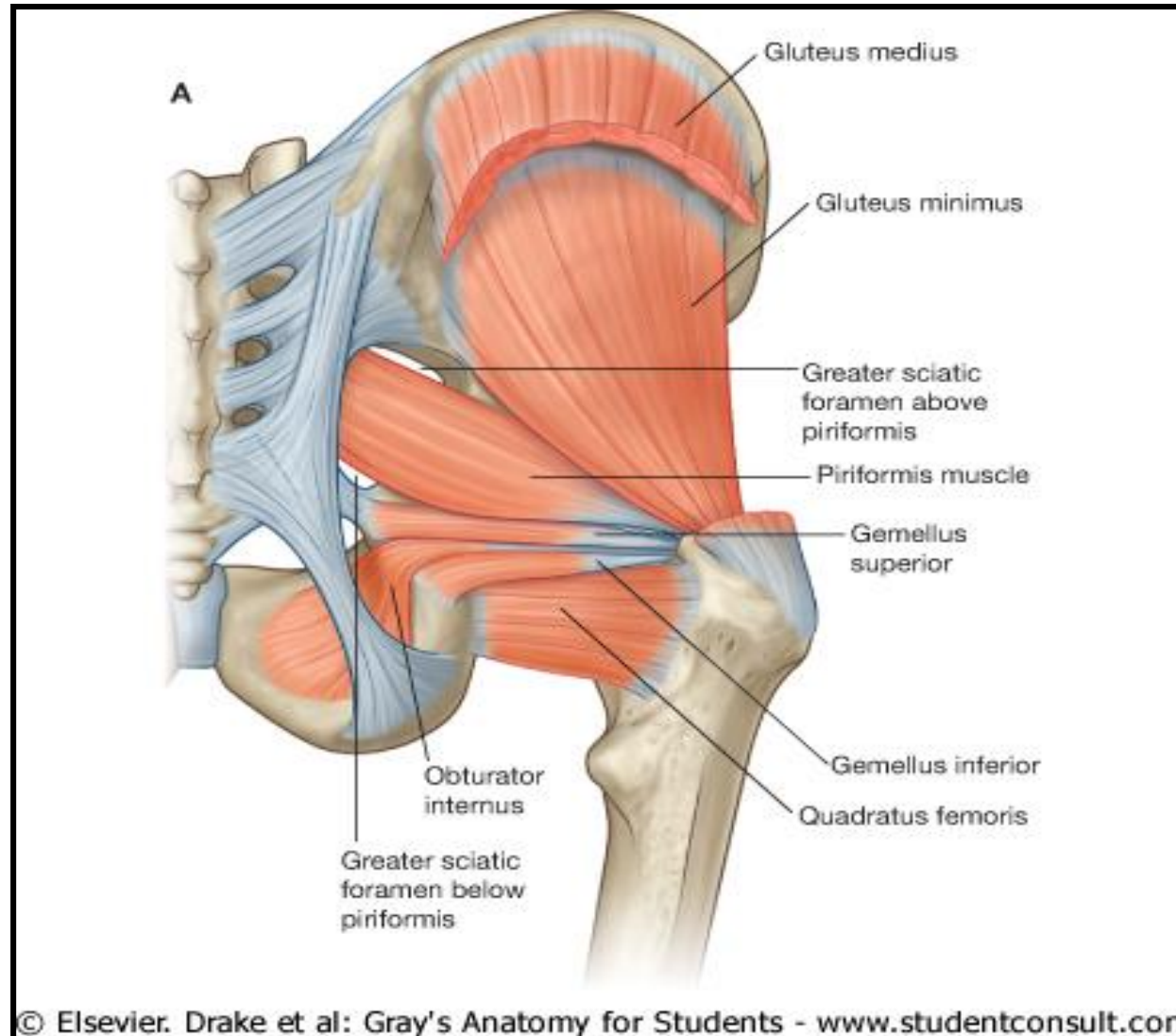
# Gluteal Muscles



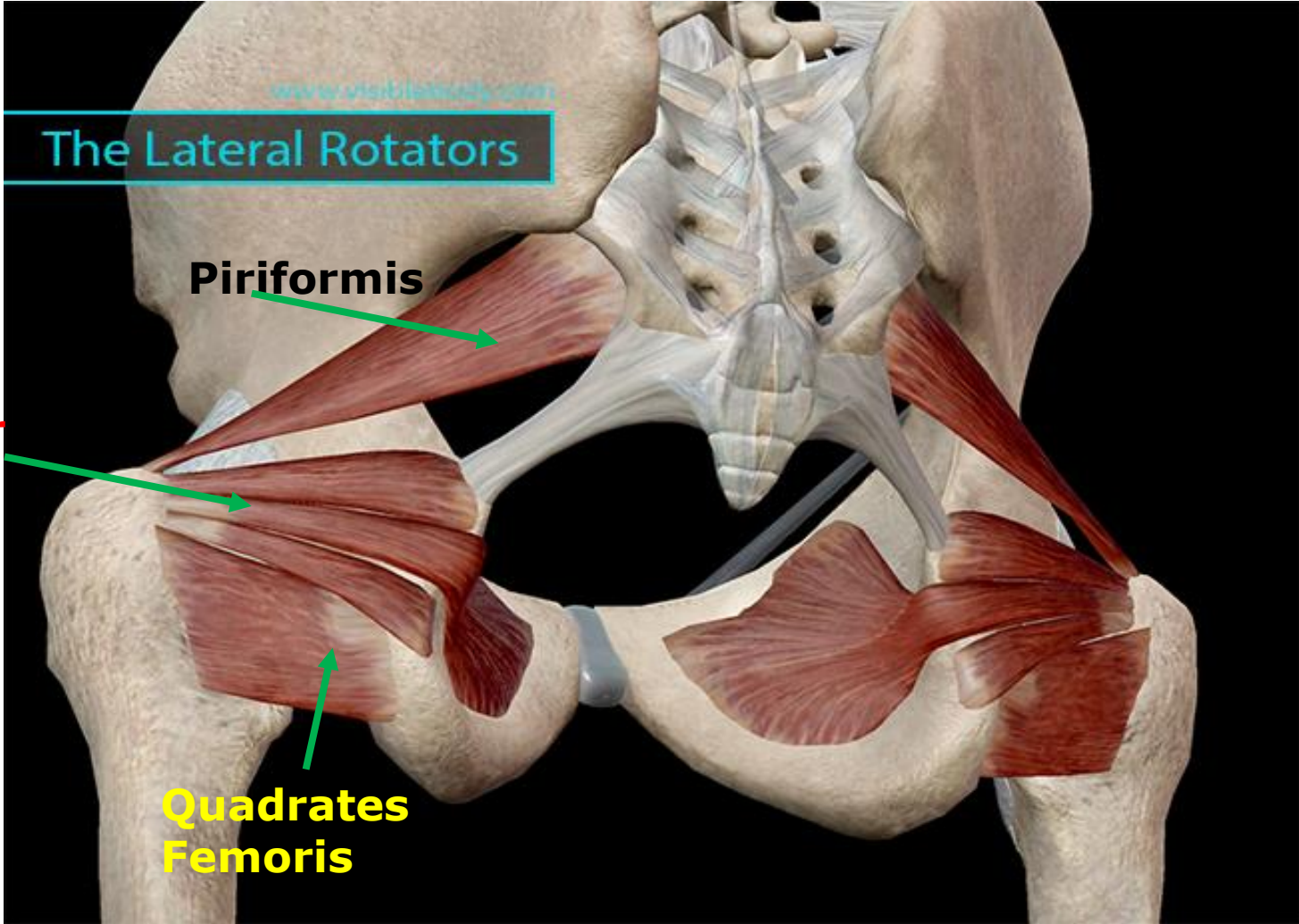
# Tensor fascia latae



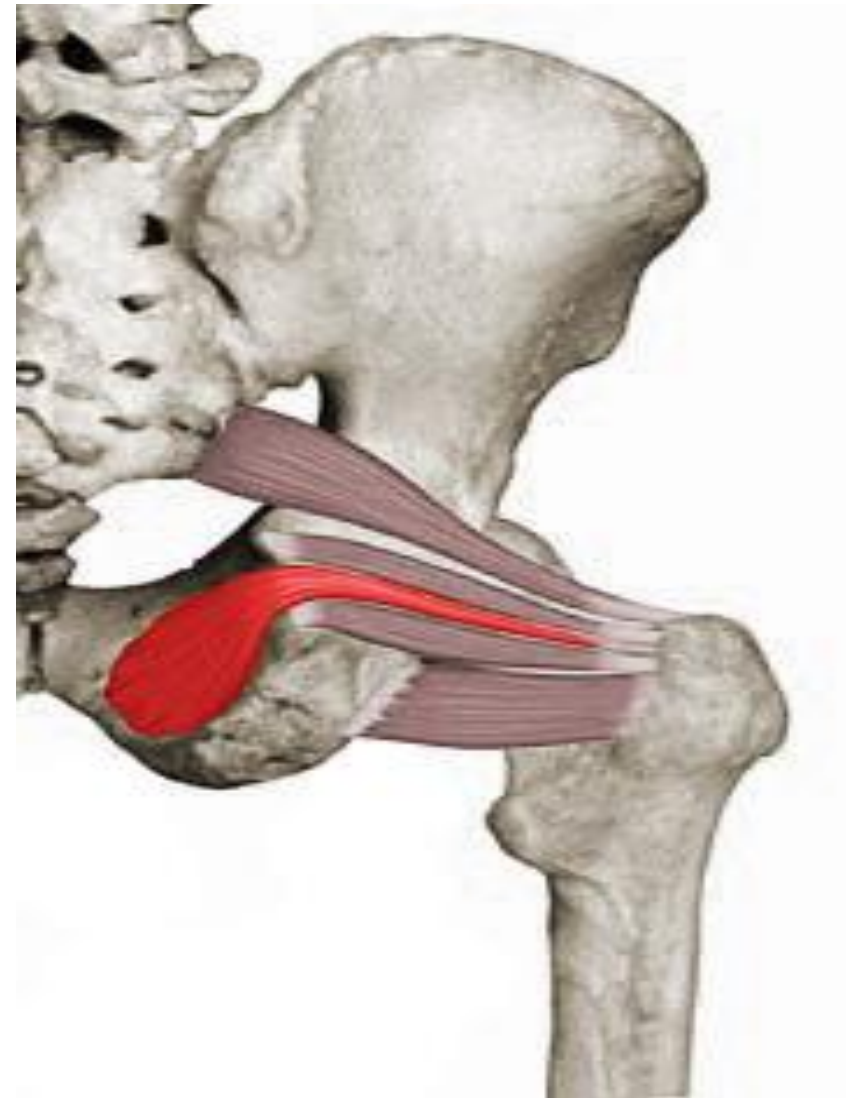
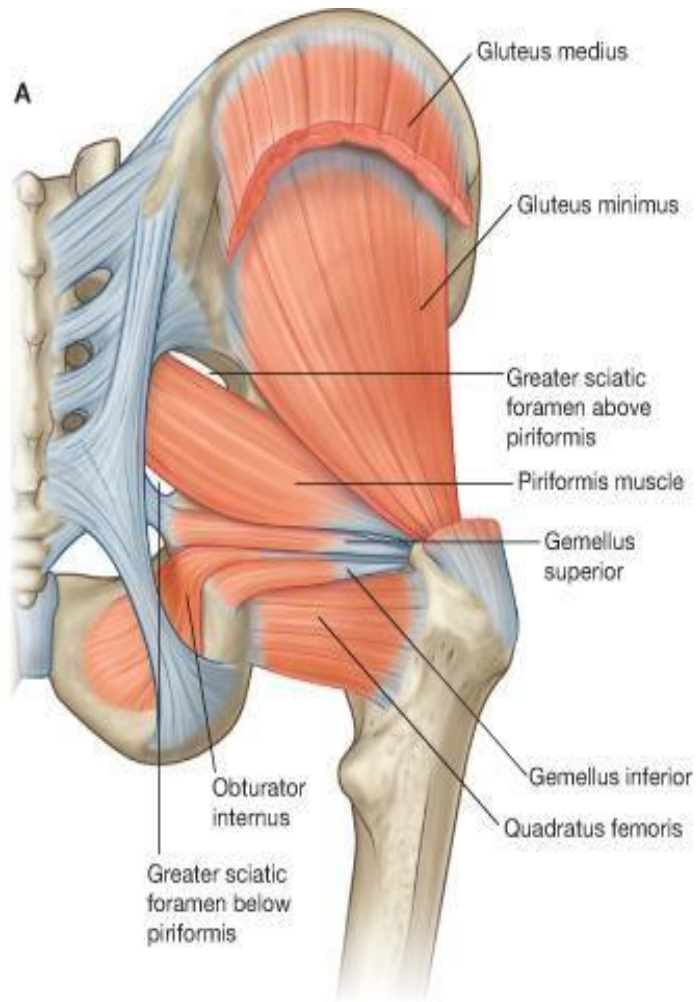
# Gluteus medius and minimus







# Lateral Rotators



## Identify the marked muscles and their nerve supply

A-

B-

C-

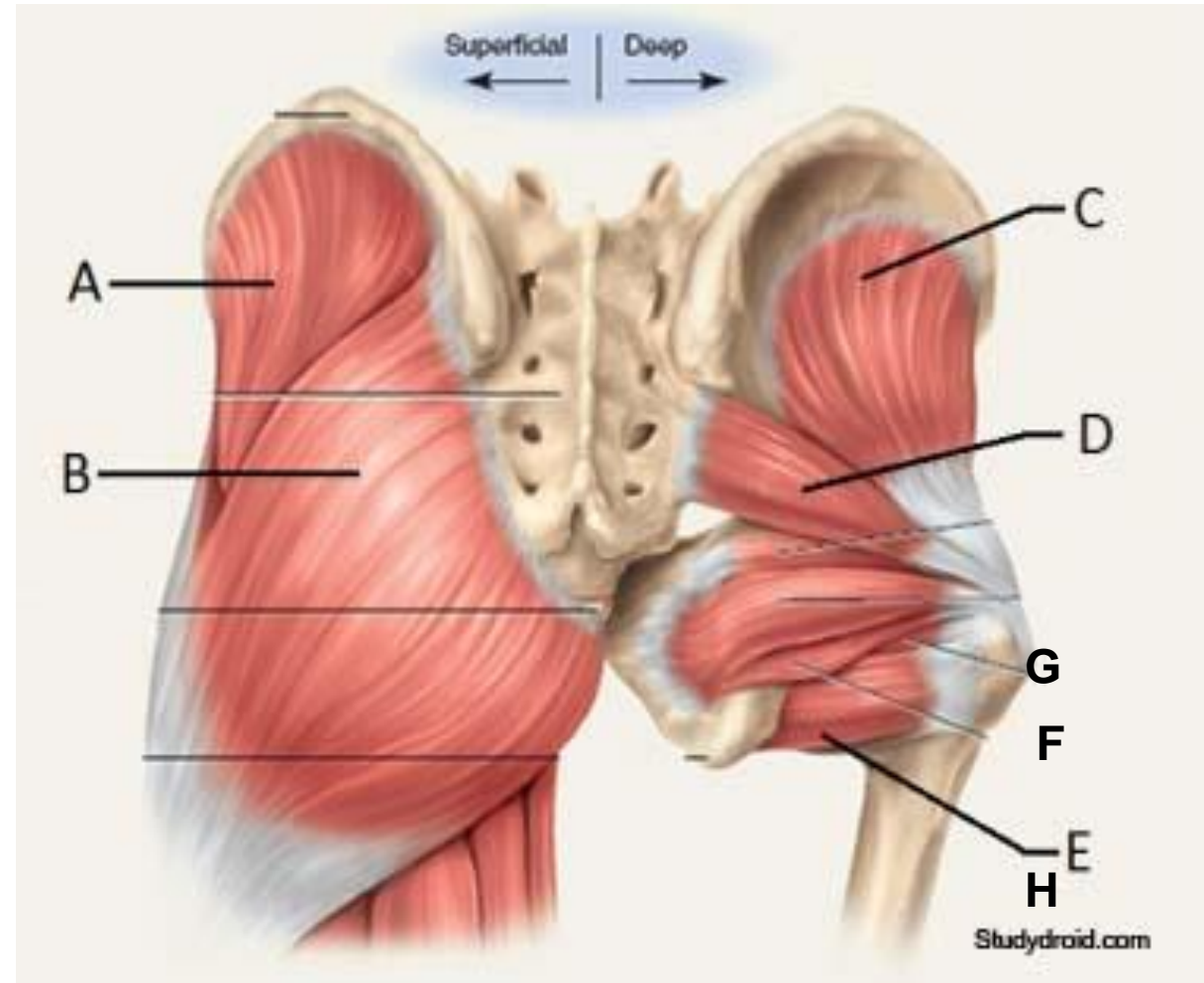
D-

E-

F-

G-

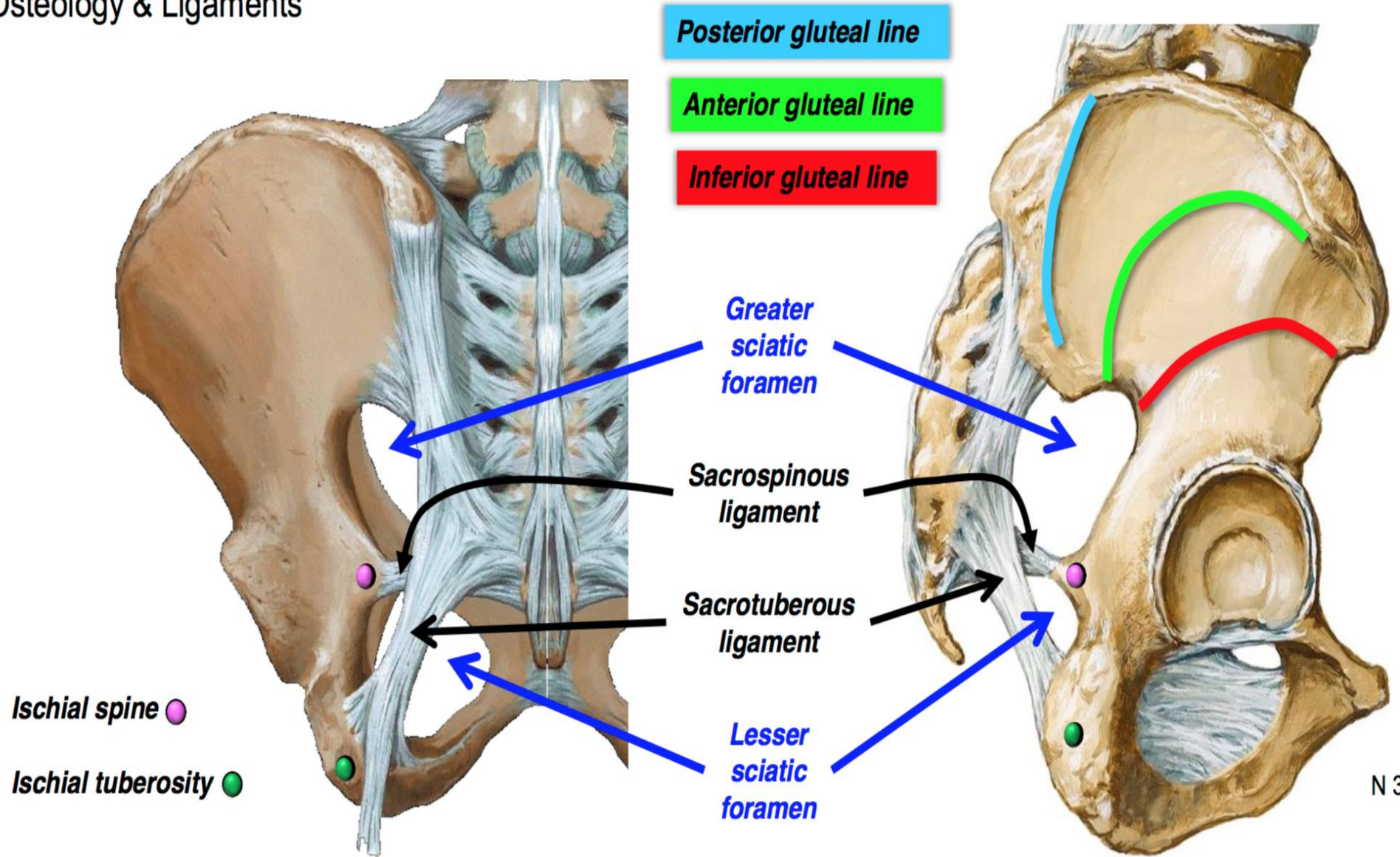
H-





# Greater and lesser sciatic foramens

Osteology & Ligaments



# Sciatic nerve

