

**The University Of Jordan
Faculty Of Medicine**

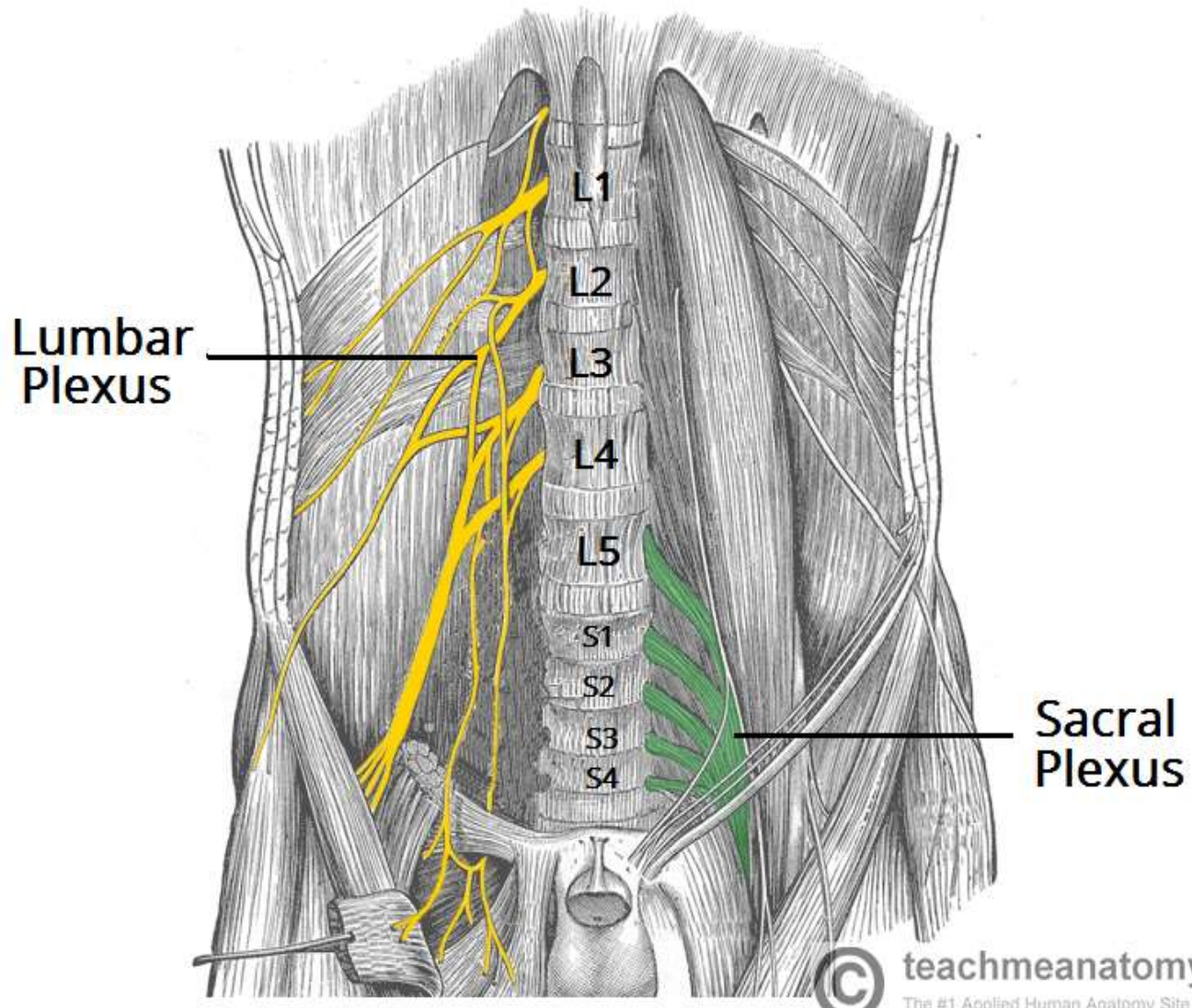


Nerves of the Lower limb

Dr.Ahmed Salman

Associate Professor of Anatomy

Lumbar and sacral Plexuses

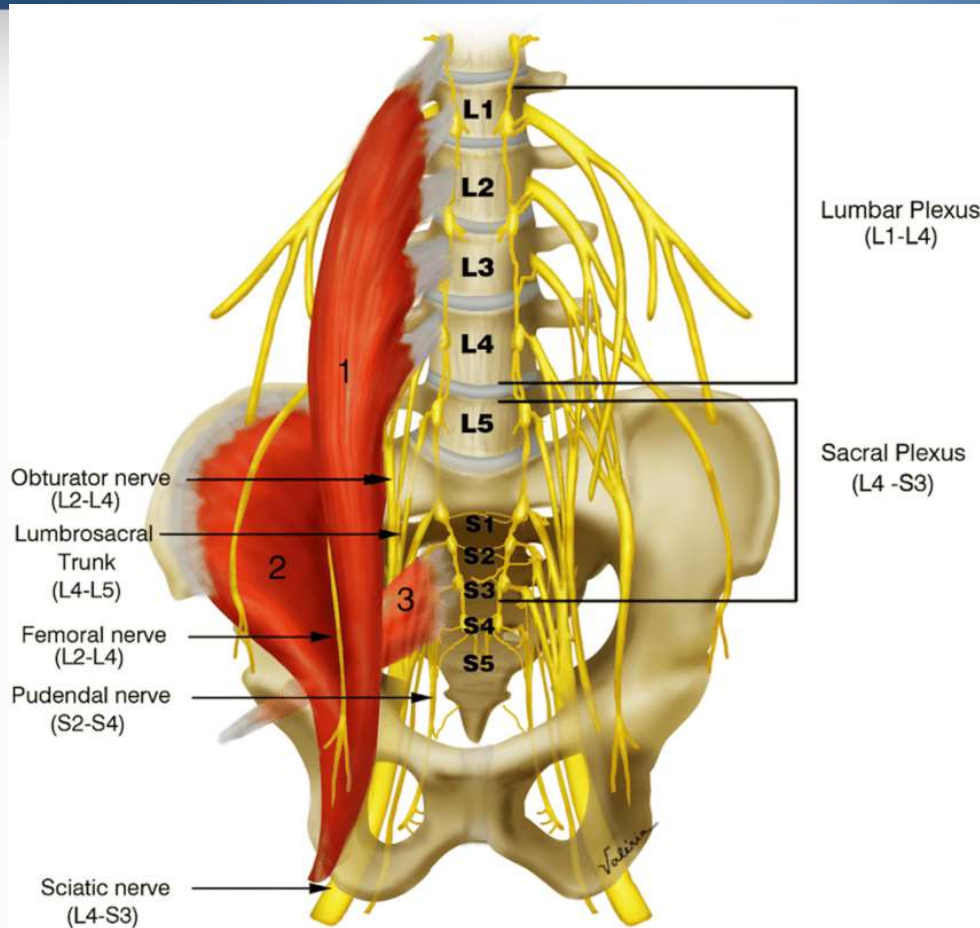


© teachmeanatomy
The #1 Applied Human Anatomy Site on the Web.

Dr Ahmed Salman

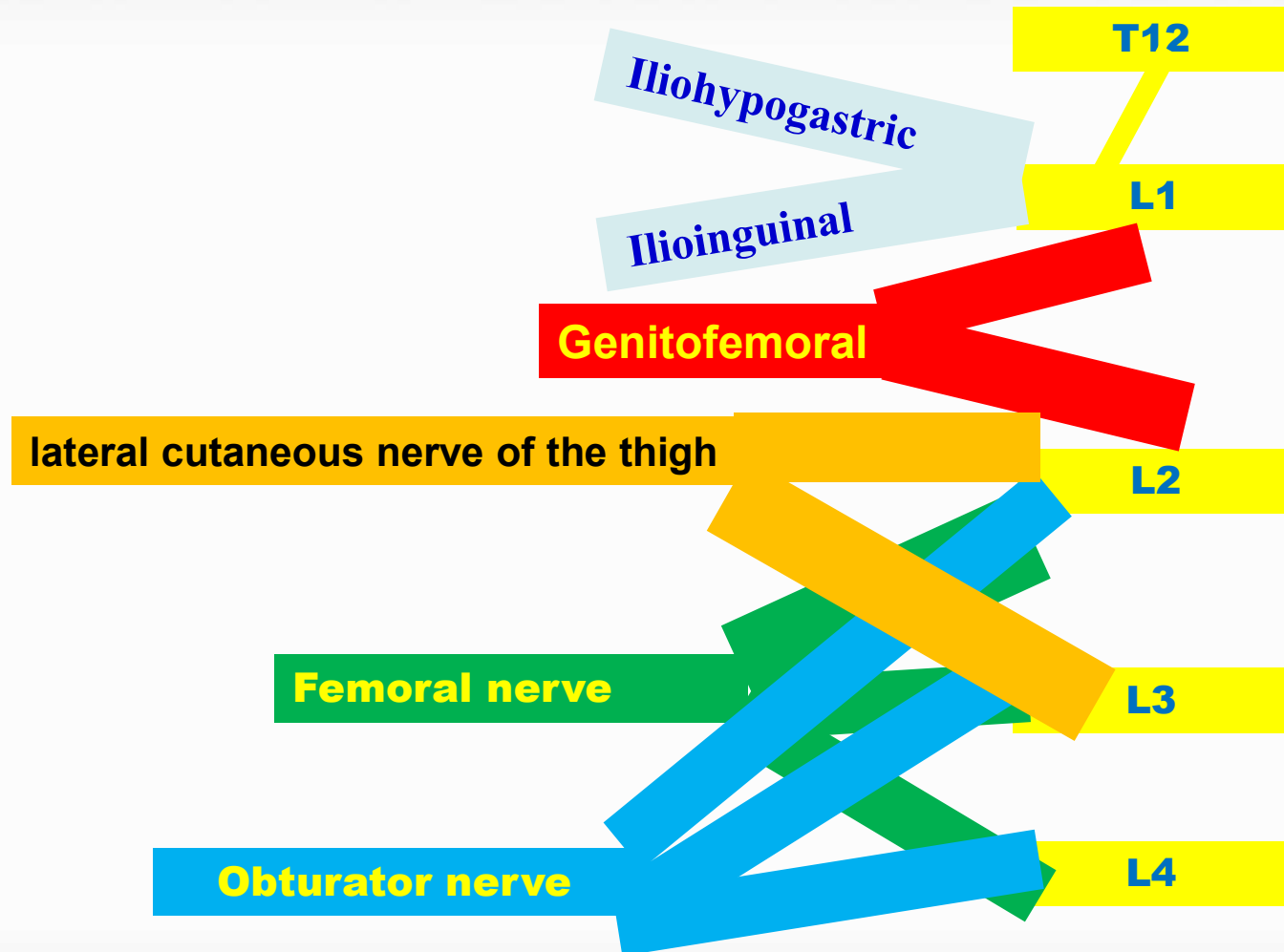
1-Lumbar Plexus

- Arises from ventral ramus of L1 - L4
- Lies within the psoas major muscle
- It receive a contribution from T12 (subcostal) nerve



Dr Ahmed Salman

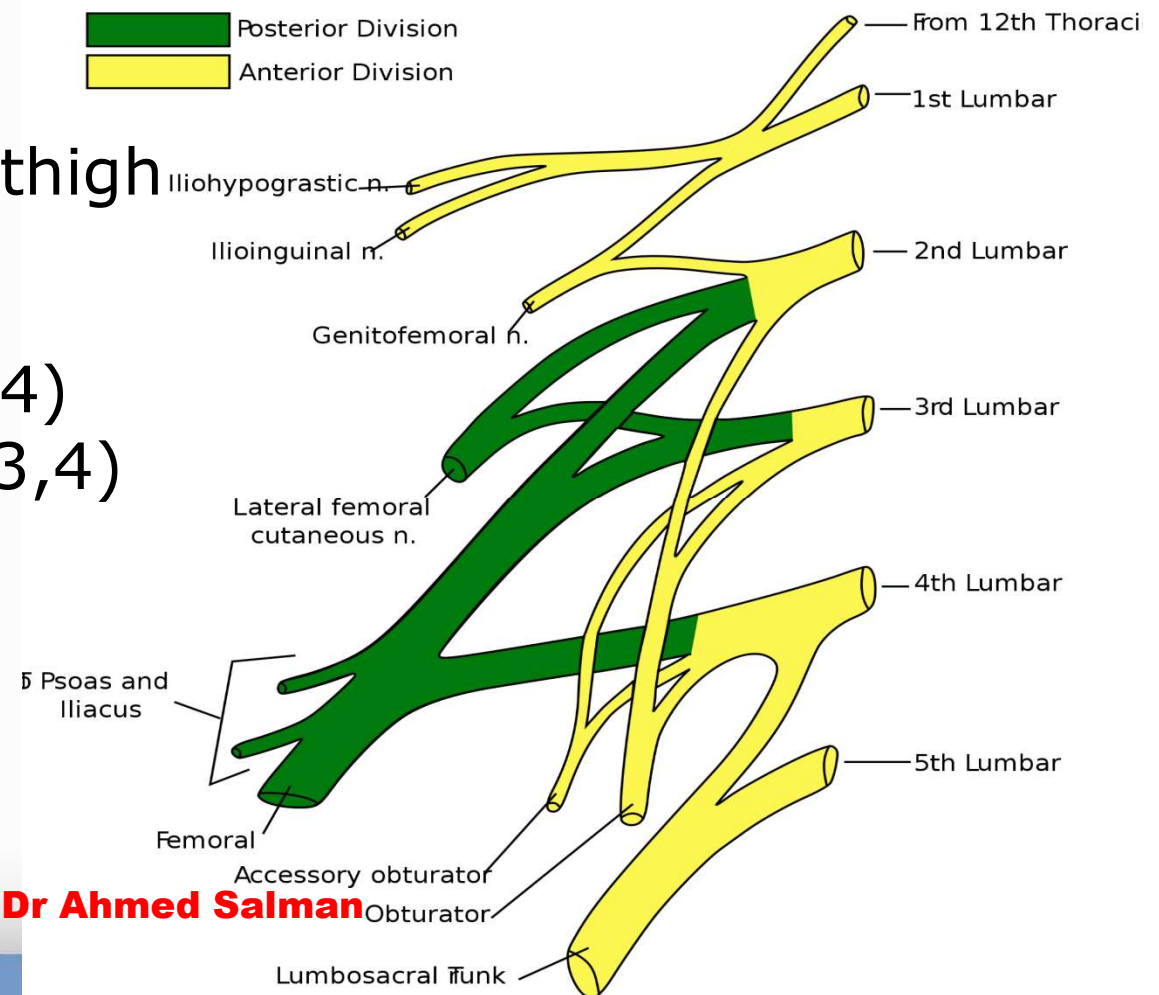
Formation of the Lumbar Plexus



Dr. Ahmed Salman

Branches of Lumbar Plexus

- 1-Ilio-hypogastric (L1)
- 2-Ilio-inguinal (L1)
- 3-Genitofemoral (L1,2)
- 4-Lateral cutaneous of thigh (L2,3)
- 5-Femoral nerve (L2,3,4)
- 6-Obturator nerve (L2,3,4)



Relation to Psoas Major Muscle

Lateral

1-Ilio-hypogastric

2-Ilio-inguinal

3-Lateral cutaneous of thigh

4-Femoral nerve

Medial

Obturator nerve

Anterior

Genitofemoral

Genitofemoral

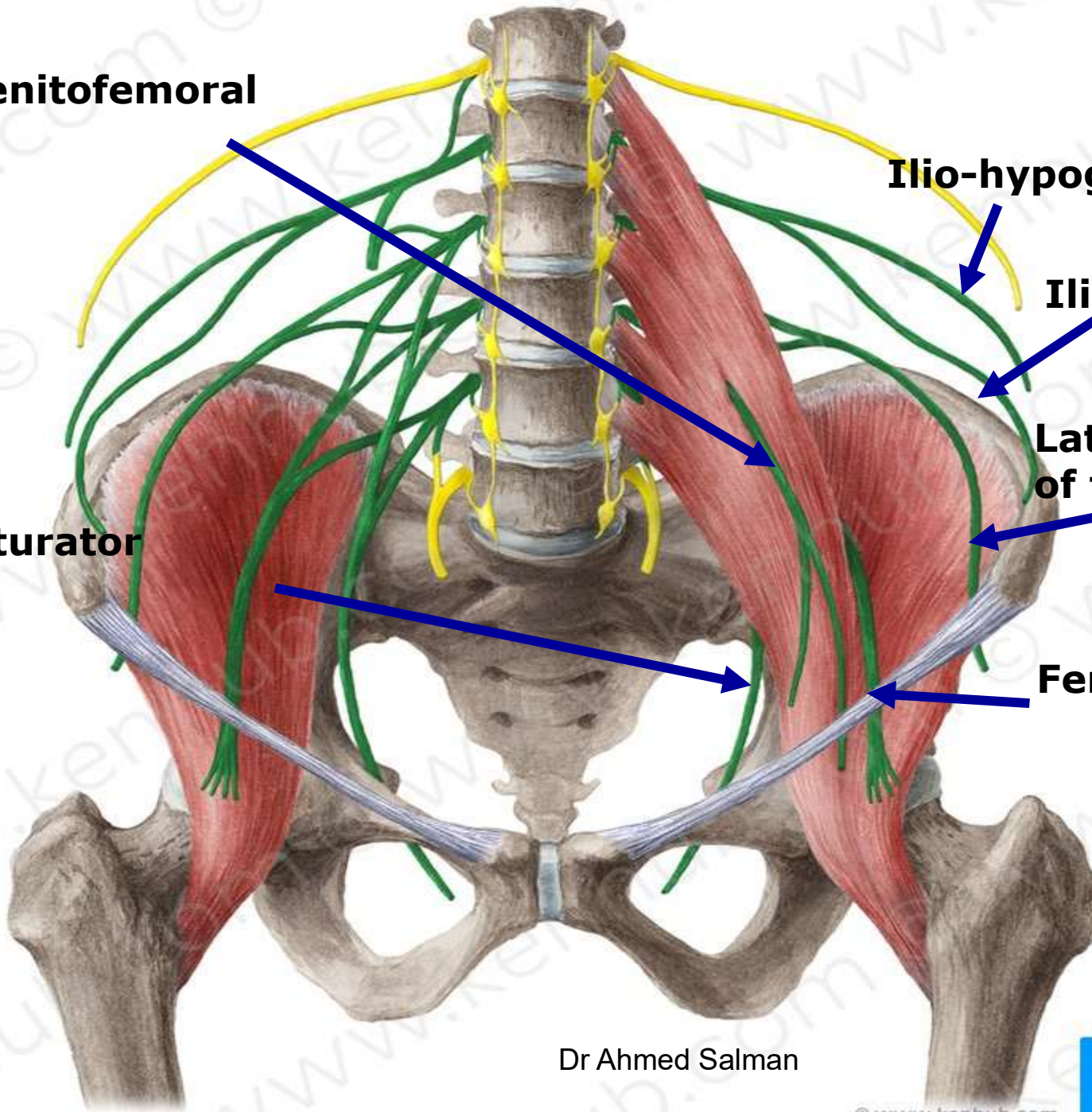
Ilio-hypogastric

Ilio-inguinal

**Lateral cutaneous
of thigh**

Obturator

Femoral

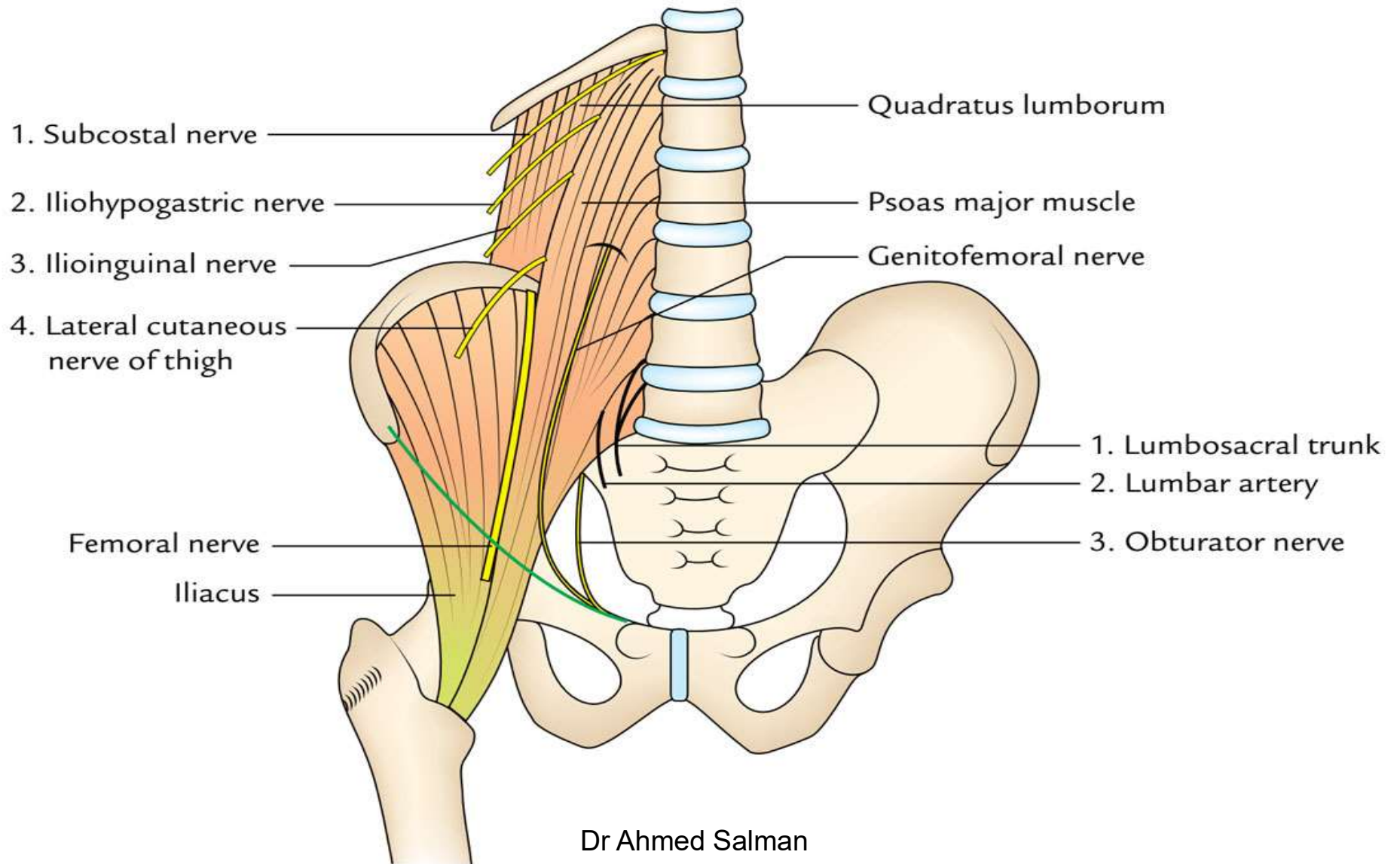


Dr Ahmed Salman

© www.kenhub.com



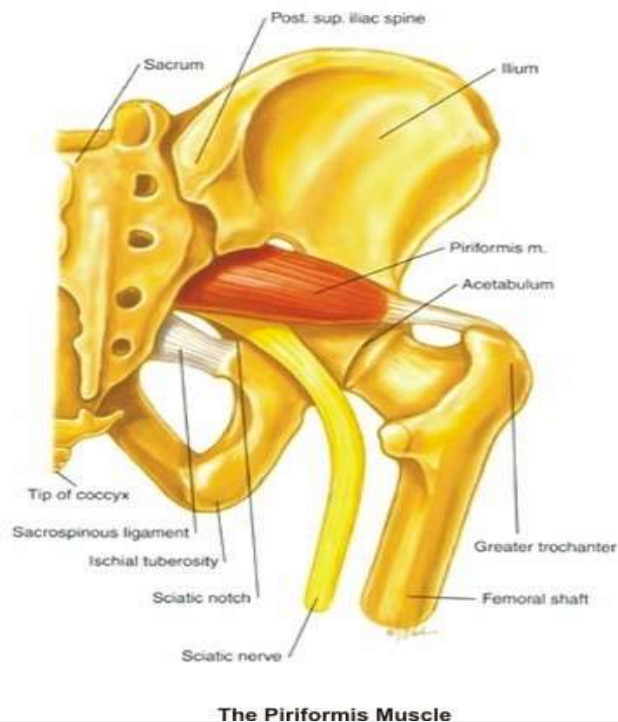
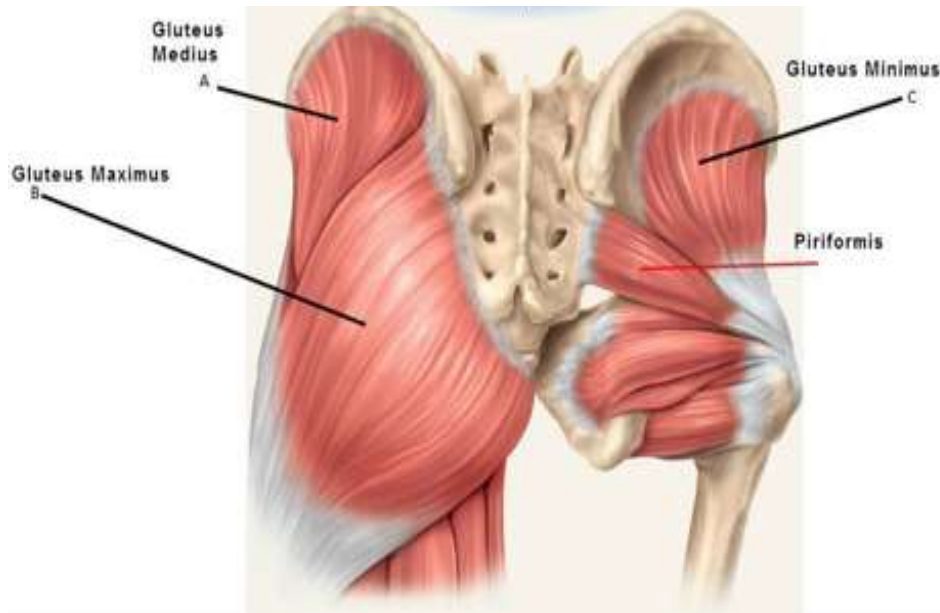
fppt.com



Dr Ahmed Salman

2- Sacral Plexus

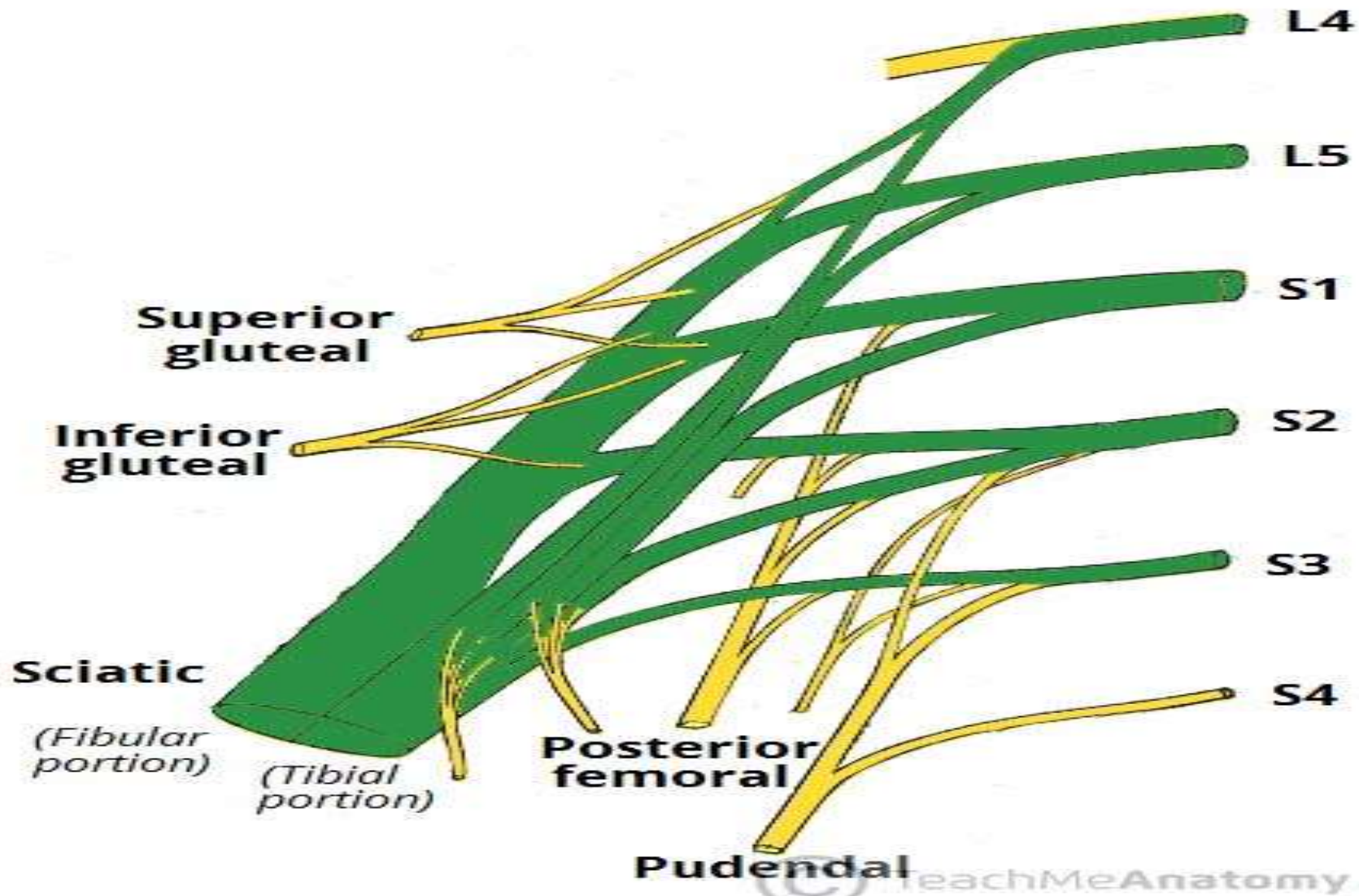
- Lies caudal to the lumbar plexus
- Formed by the lumbosacral trunk (L4,5) and ventral rami of S1 -S4
- Located on the anterior surface of piriformis muscle.
- The lumbosacral trunk is a thick nerve formed by the union of lower part of anterior primary ramus of L4 with the anterior primary ramus of L5



Branches of Sacral Plexus

- 1-Sciatic L4,L5,S1,2,3,S4
- 2-Superior gluteal Nerve L4, L5 and S1
- 3-Inferior gluteal nerve L5 and S1 and S2
- 4-Posterior cutaneous nerve of thigh S1,S2 and S3
- 5-Nerves to the piriformis
- 6-Nerve to the quadratus femoris
- 7-Nerve to obturator internus
- 8- Pudendal Nerve

Sacral Plexus



Mention the origin of the following nerves



Sciatic

Femoral nerve

Superior gluteal Nerve

Inferior gluteal nerve

Obturator nerve

Posterior cutaneous nerve of thigh

Lateral cutaneous of thigh

Nerves to the piriformis

Nerve to the quadratus femoris

Genitofemoral

Ilio hypogastric

Nerve to obturator internus muscle

Pudendal Nerve

Dr Ahmed Salman



**Thank
You!!!**