Muscle tissue

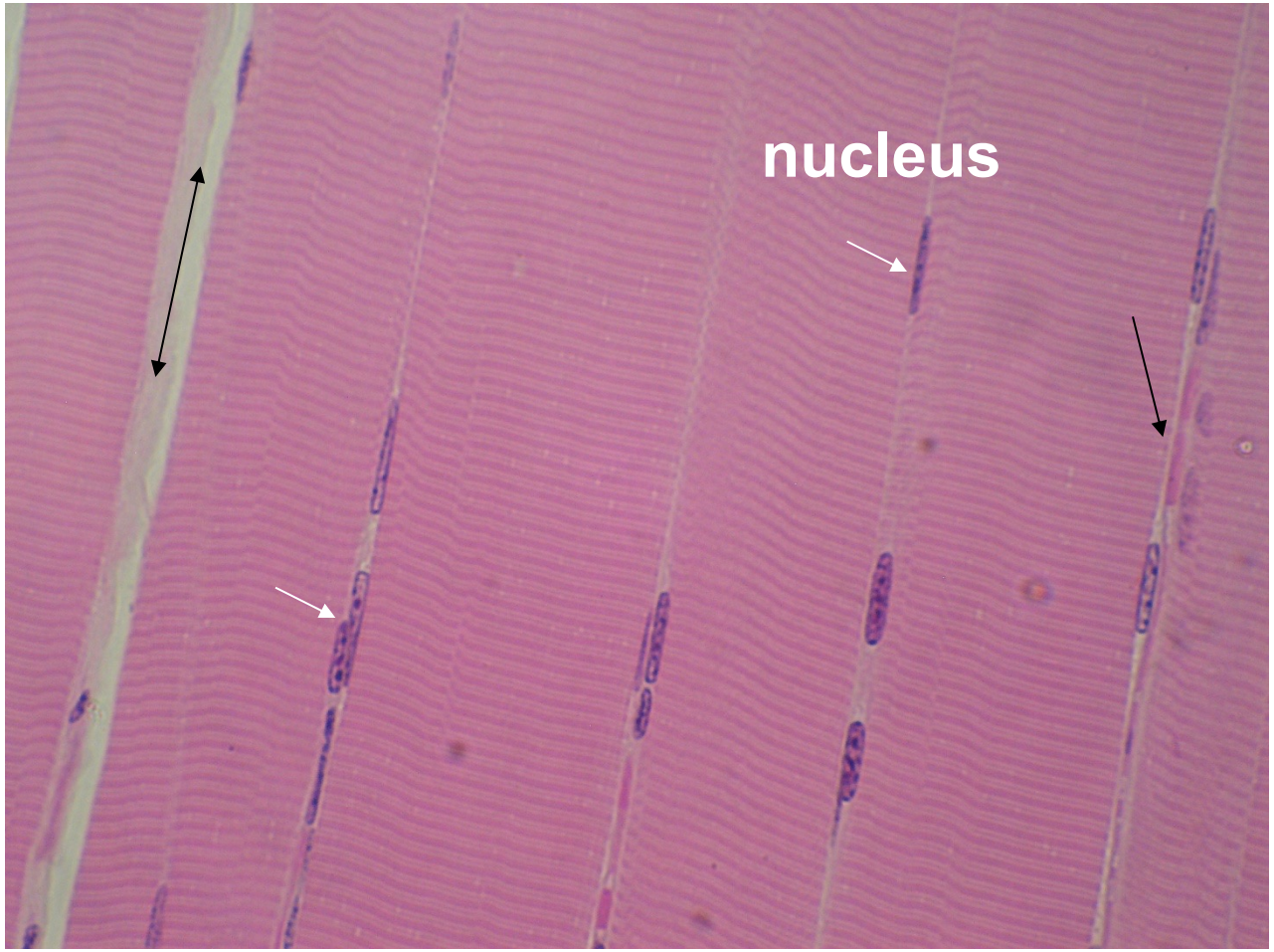
nucleus

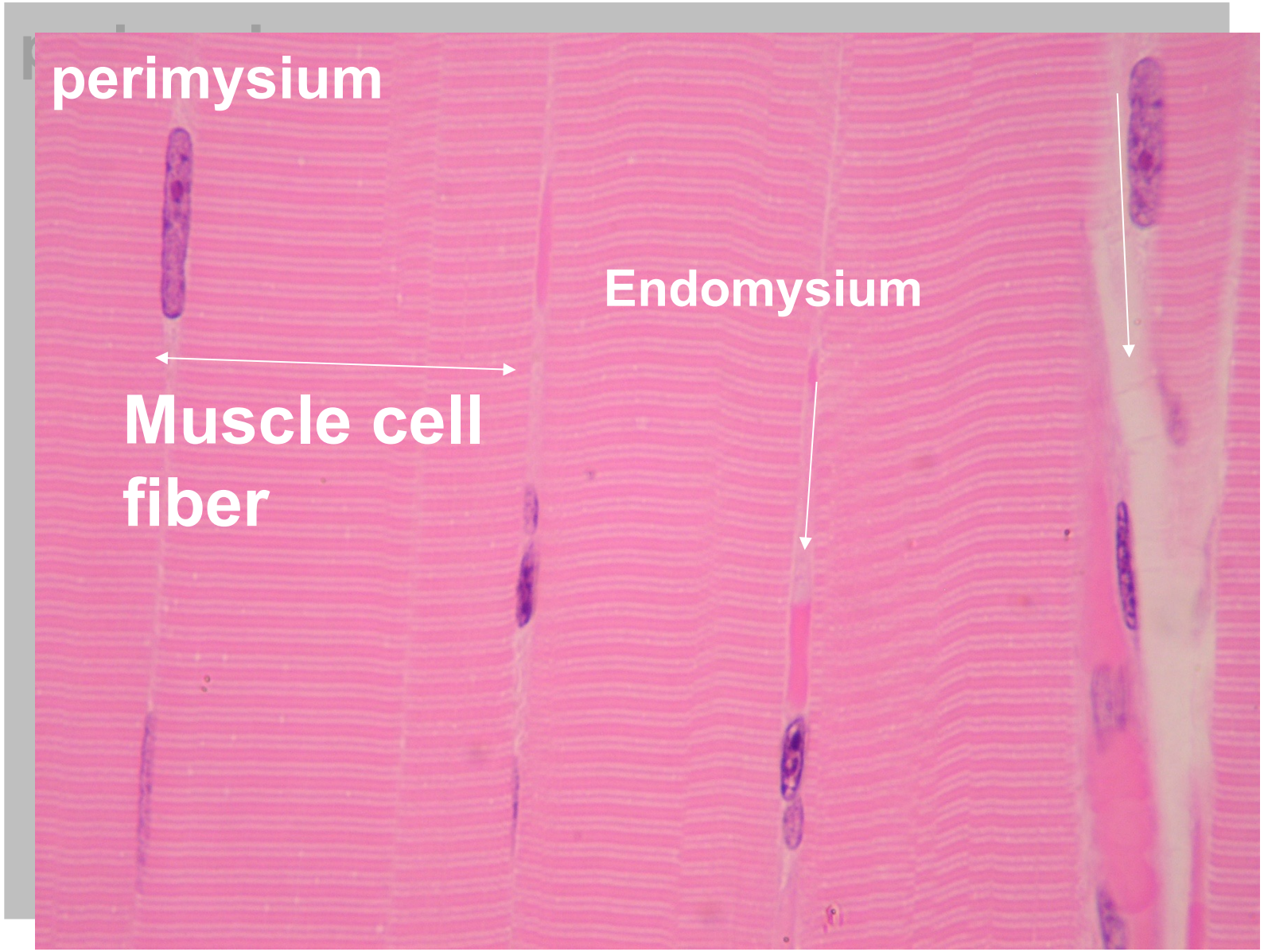
perimysium
Endomysium
Muscle cell
fiber

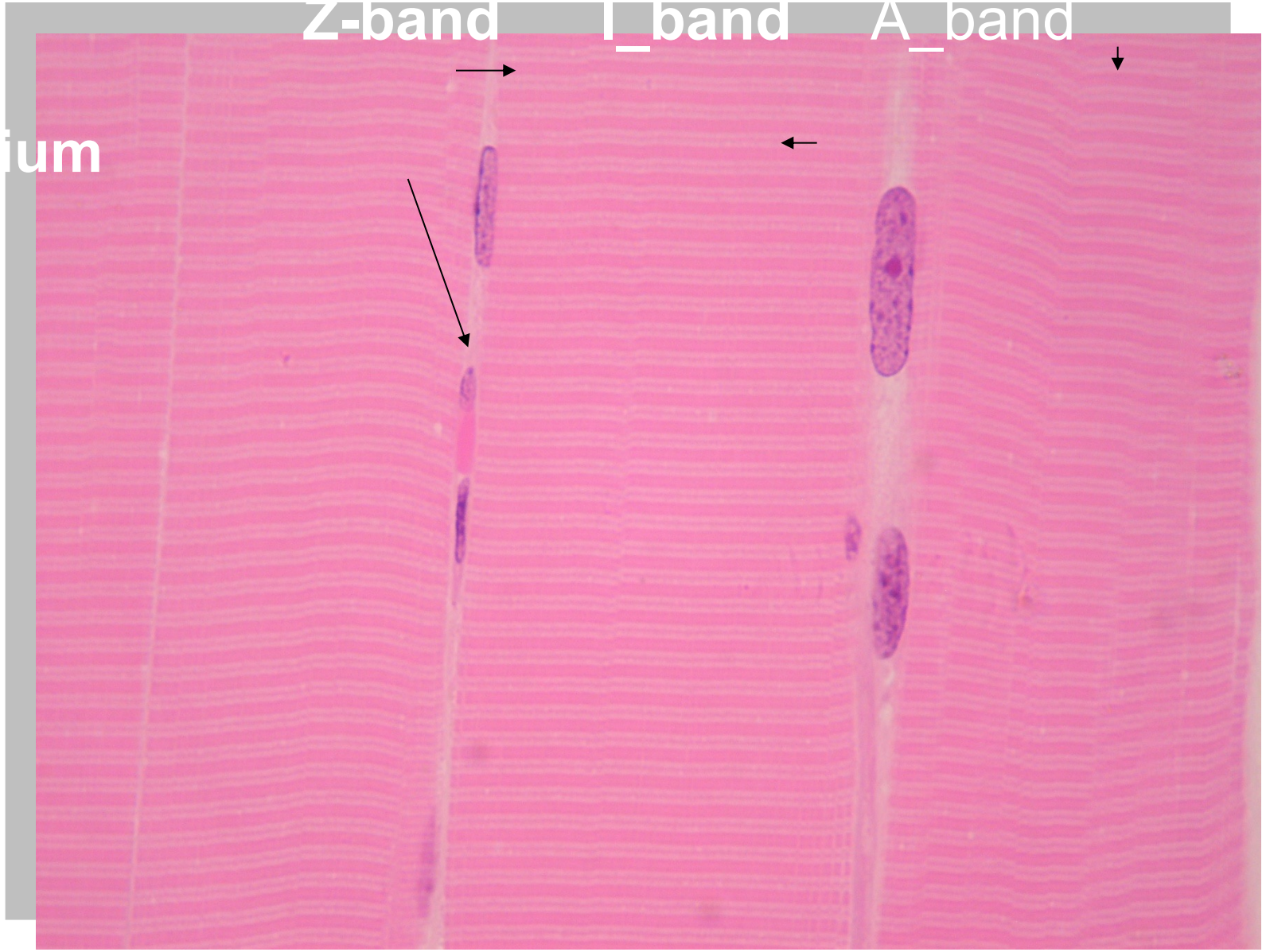
Z-band
I_band
A_band
ium



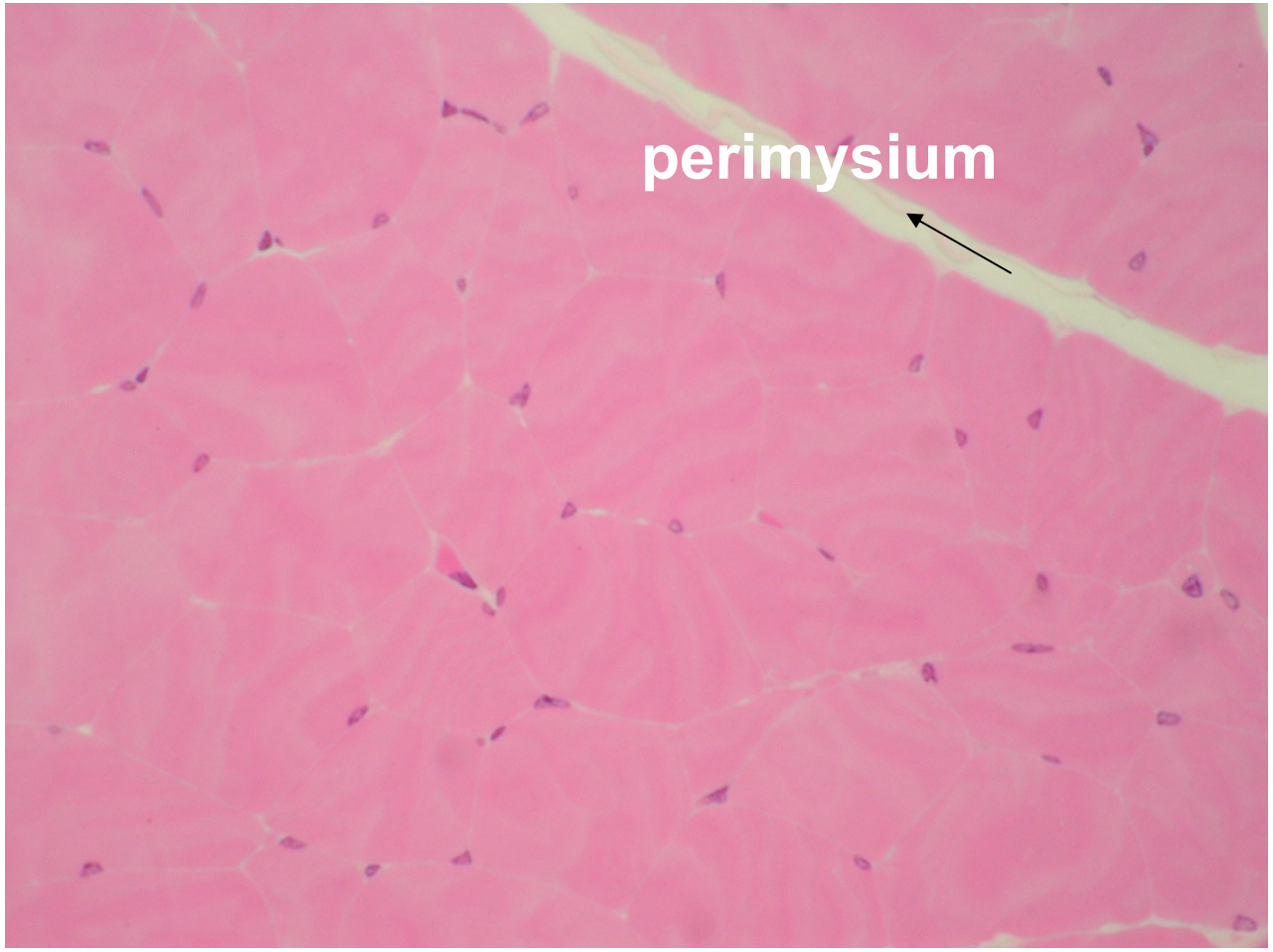
perimysium

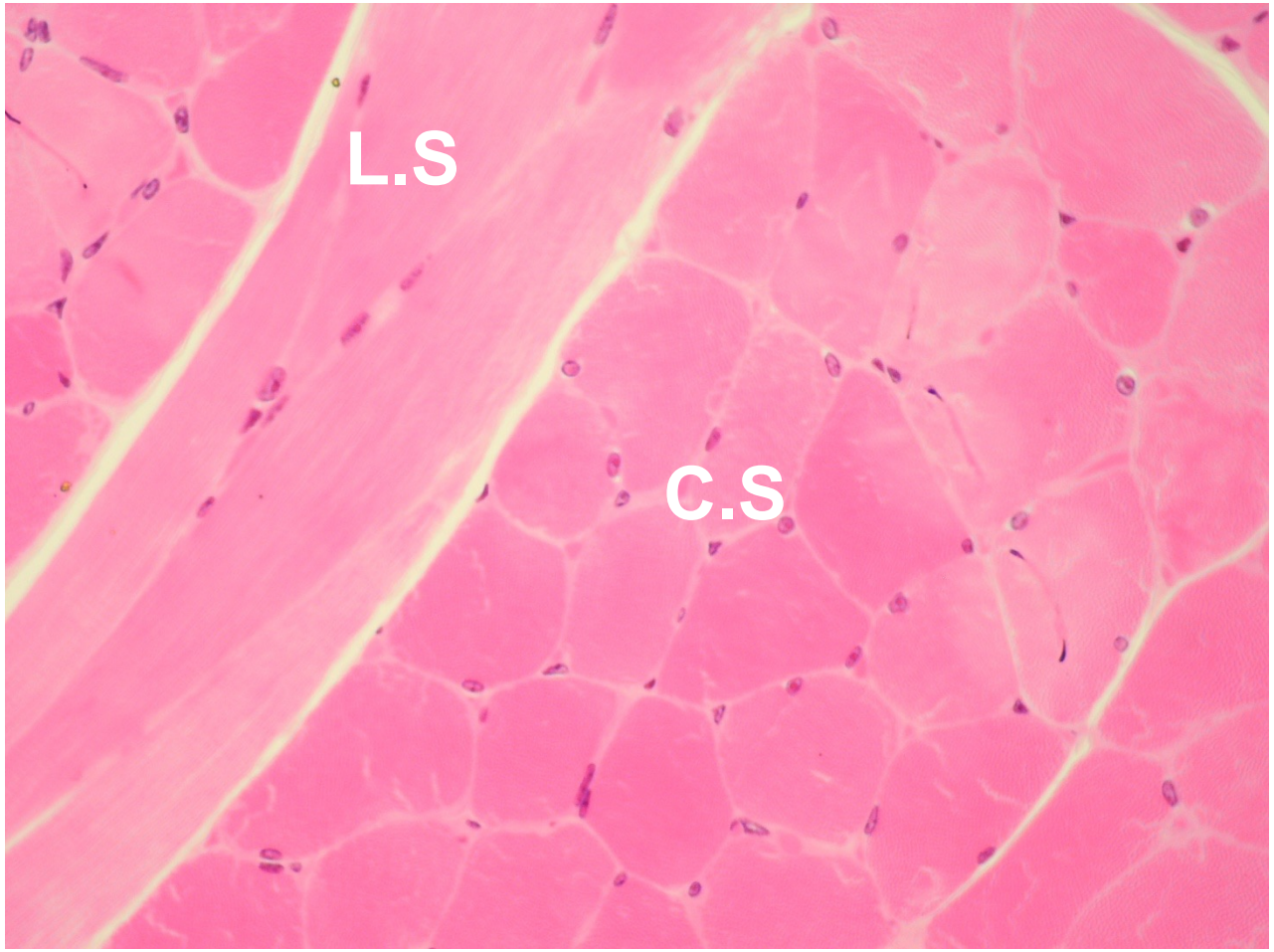
L.S
C.S

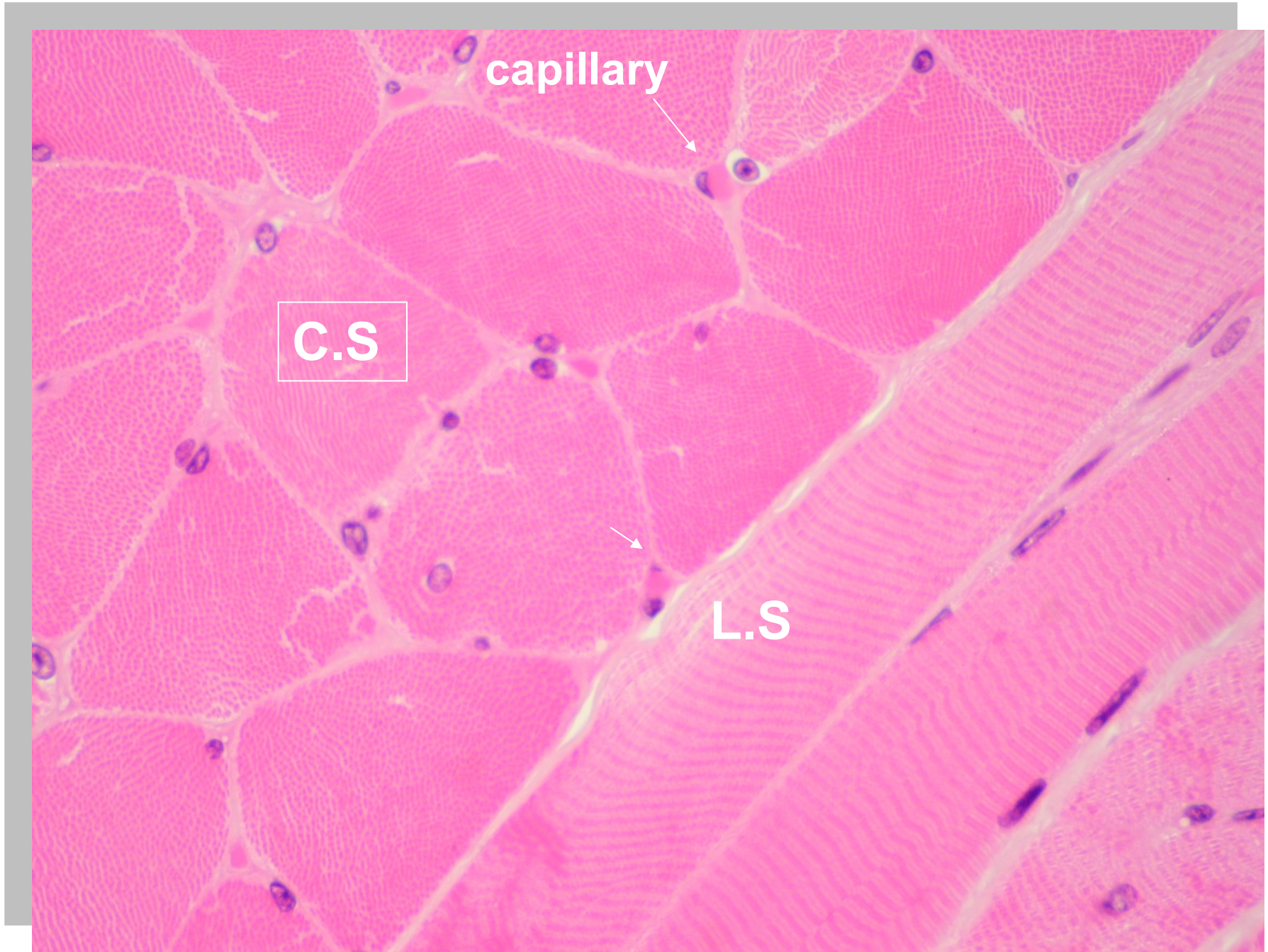
capillary
C.S
L.S

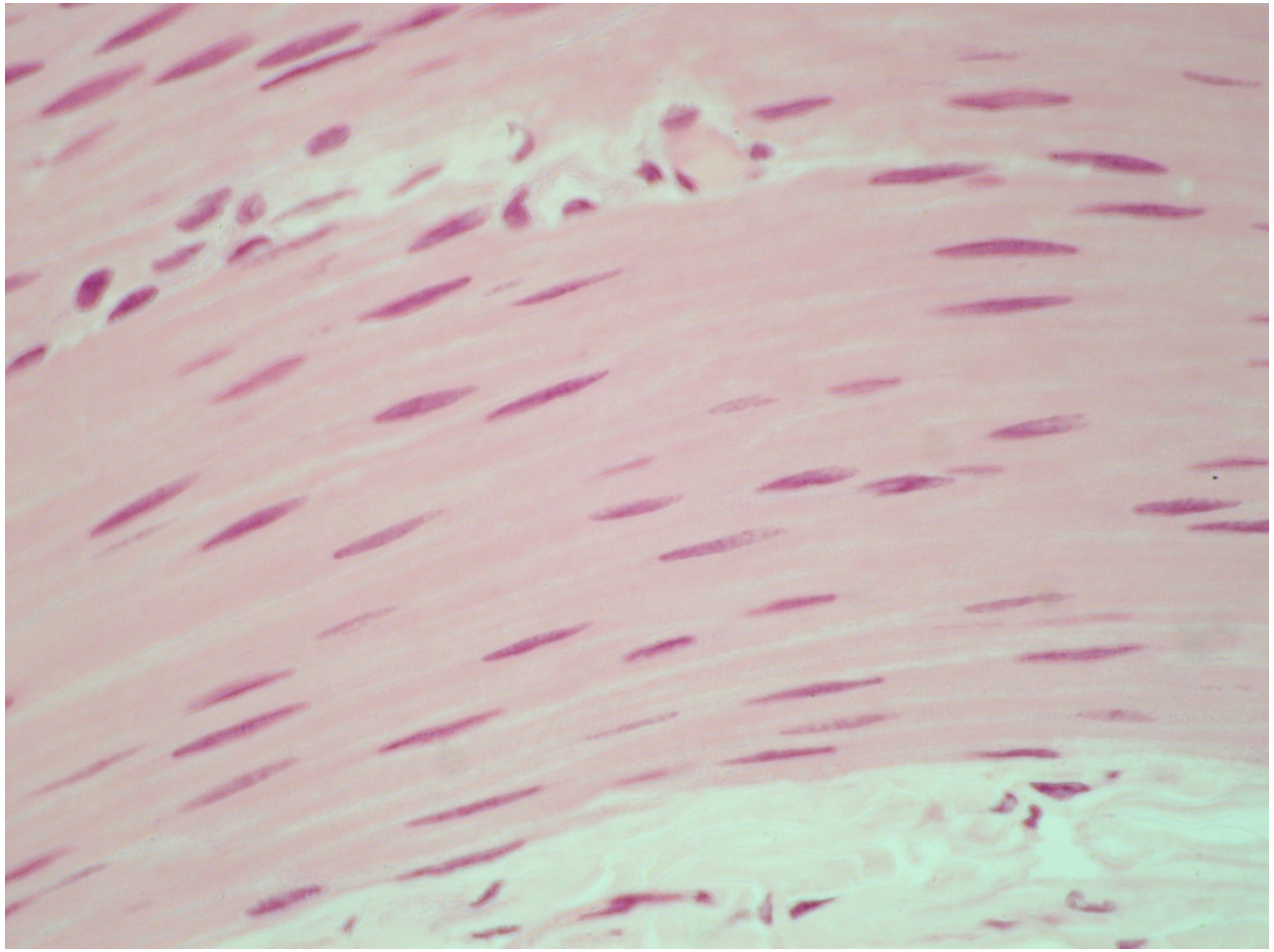

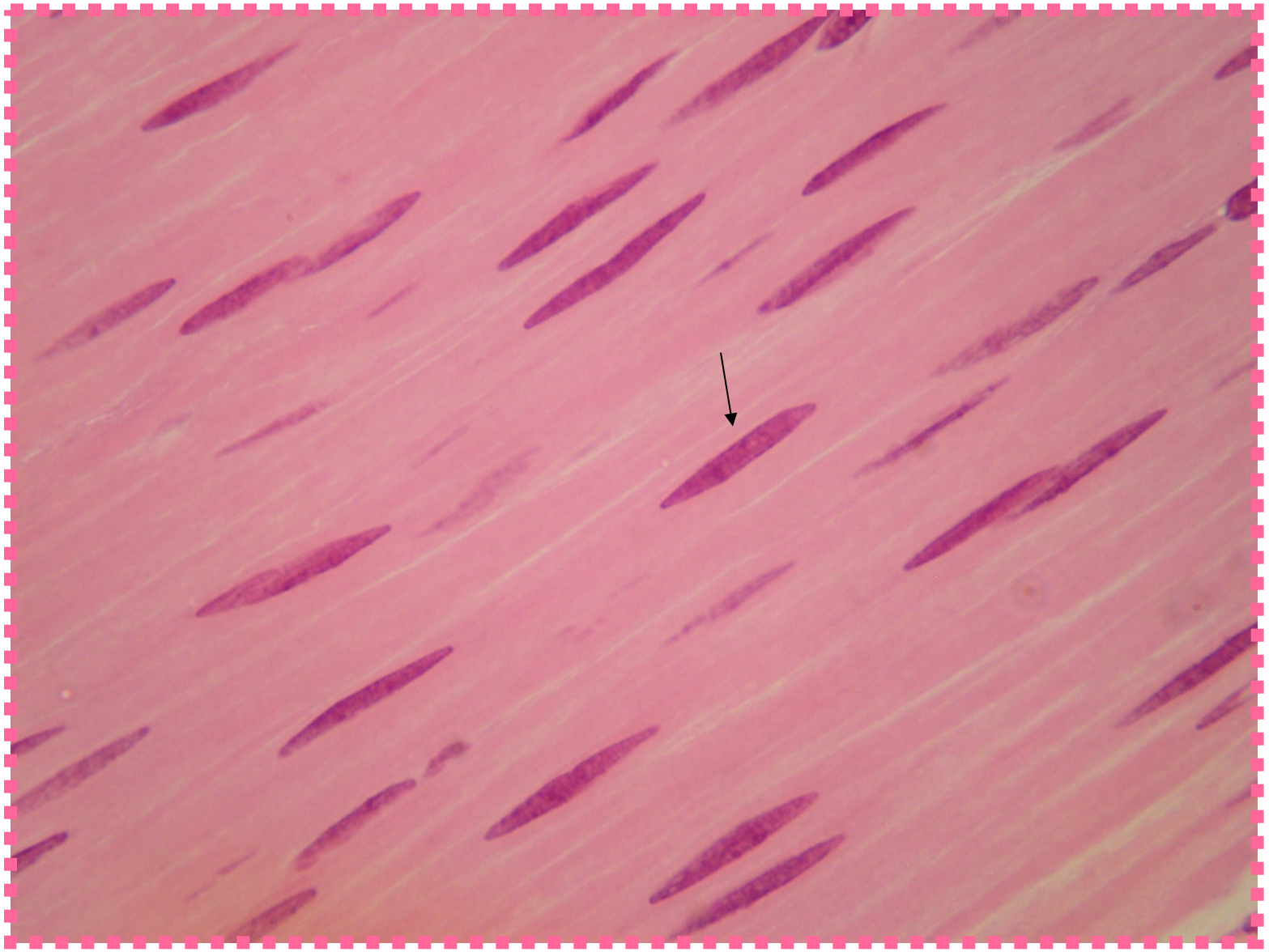

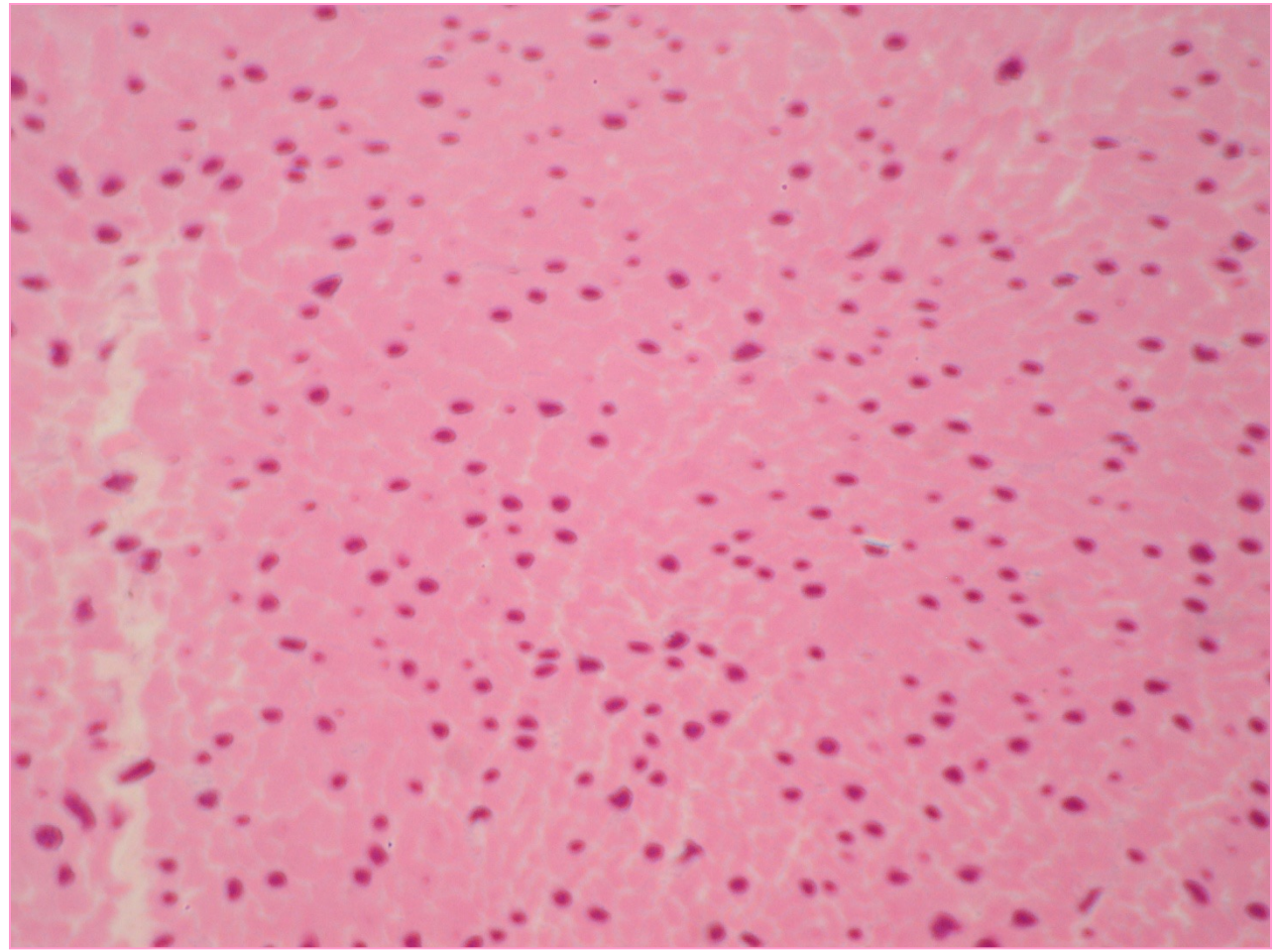


Transverse sec. of smooth muscle

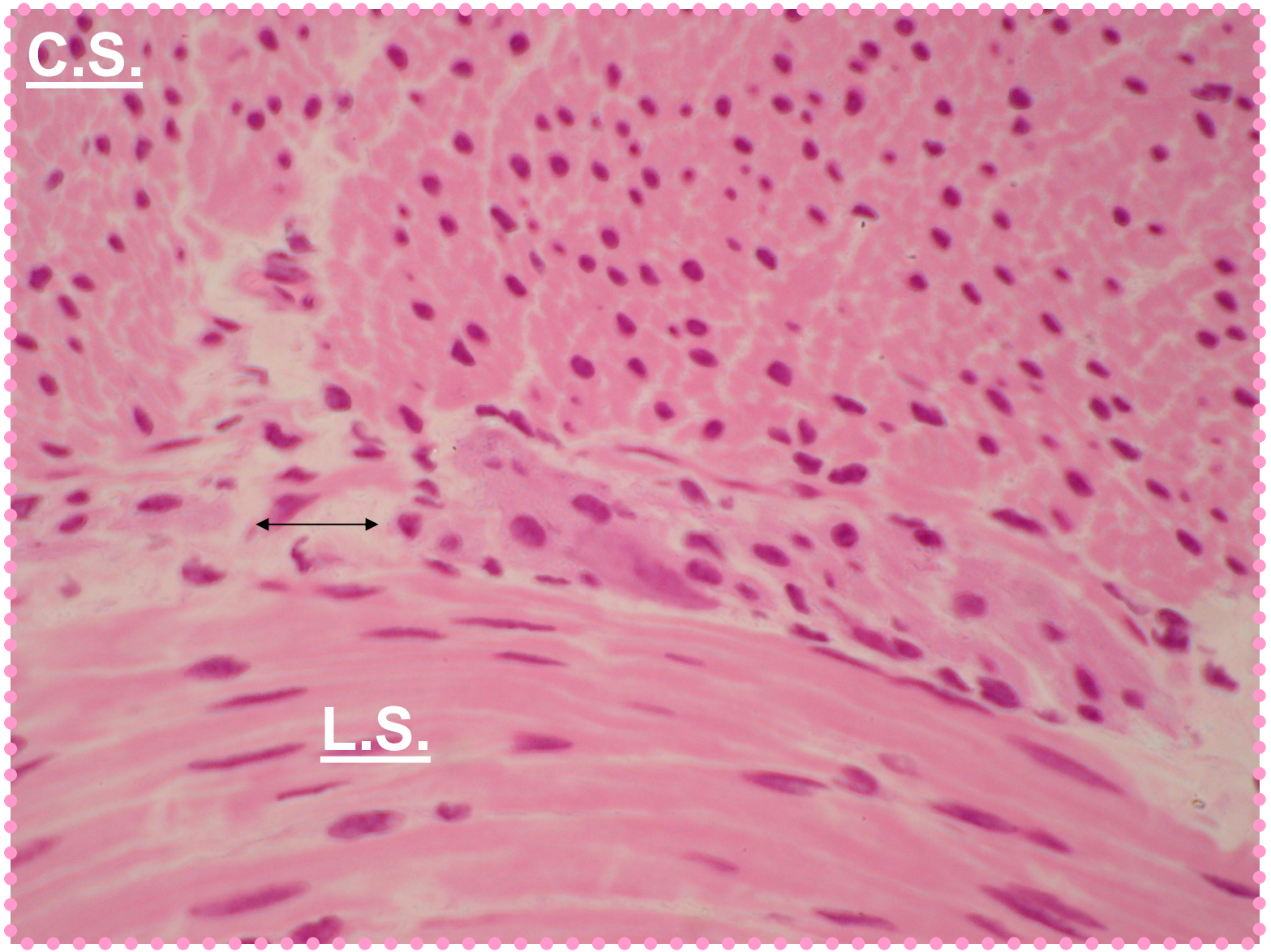
C.S.
L.S.

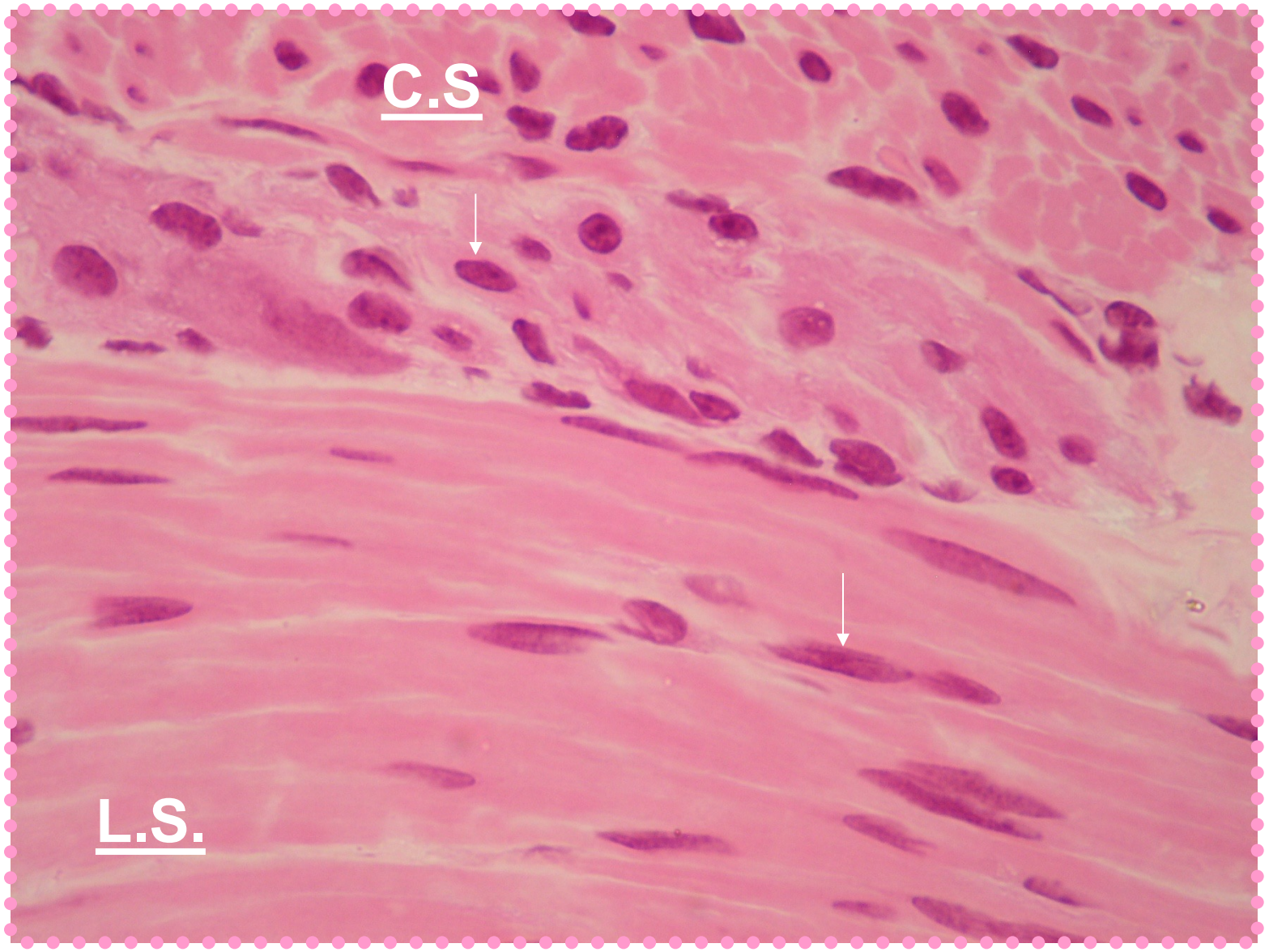
C.S
L.S.

Wall of blood vessel

vessel

Arrector pili

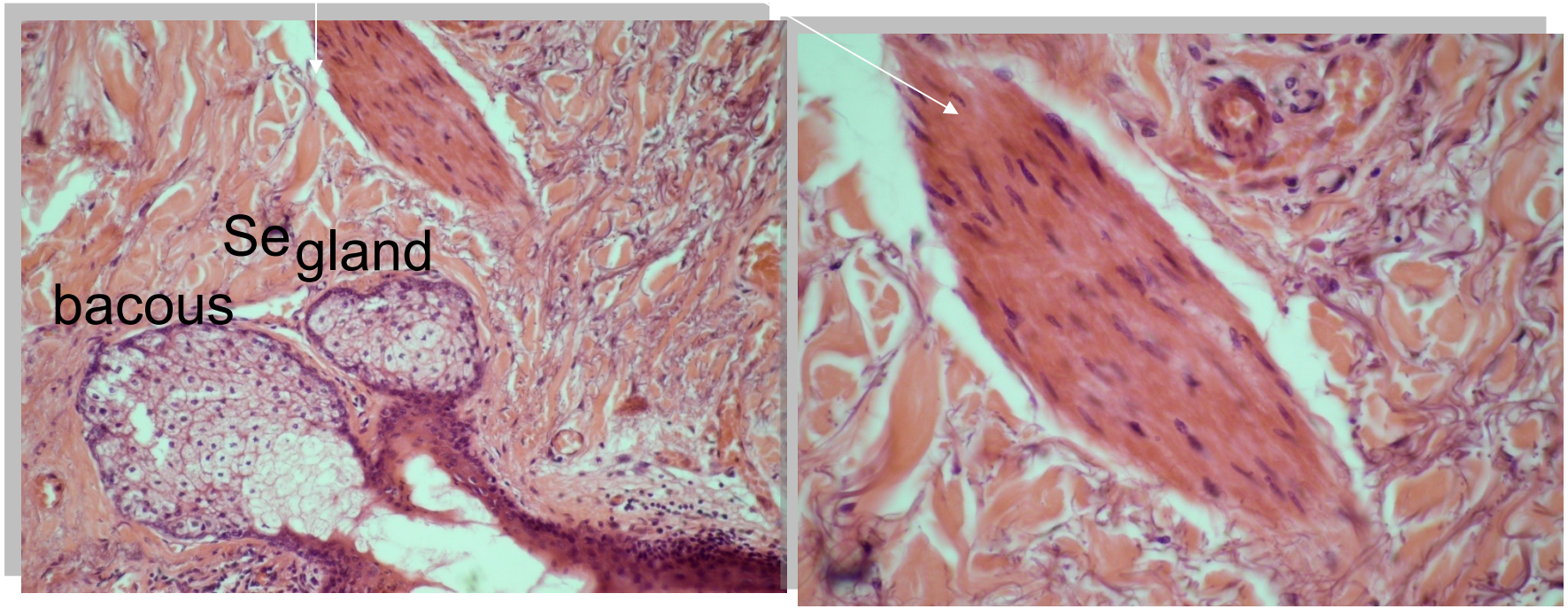

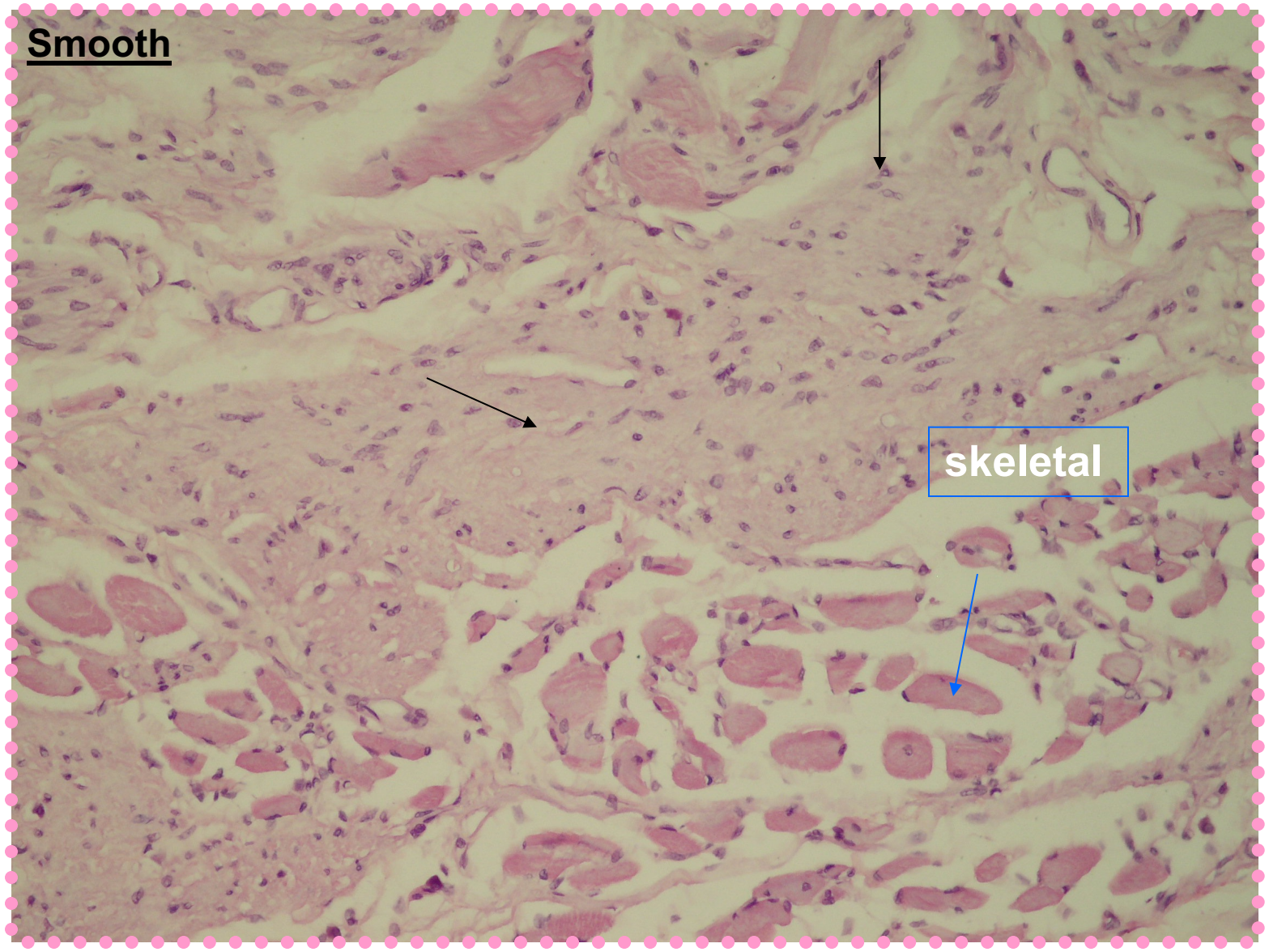
Smooth
skeletal

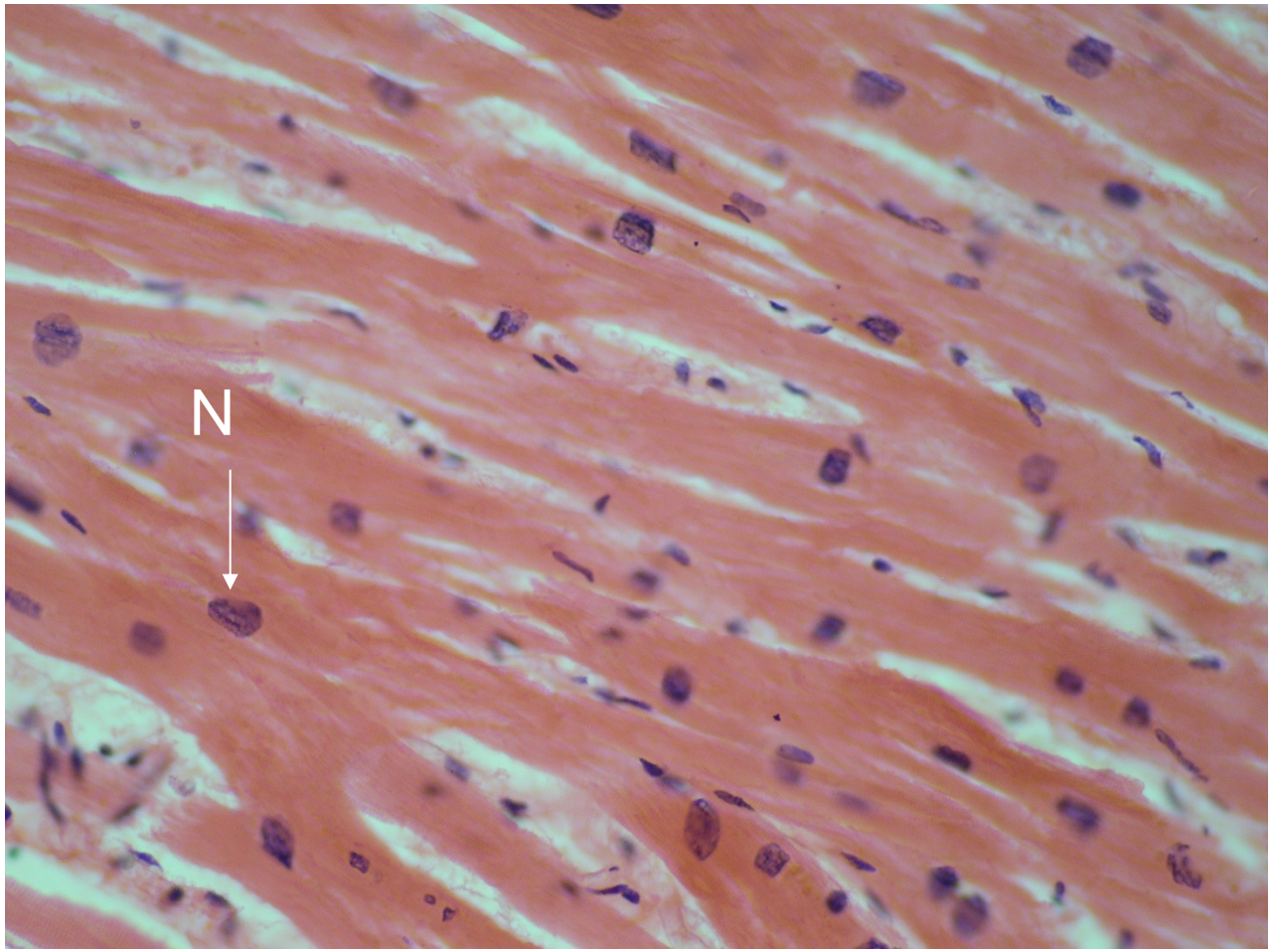
N

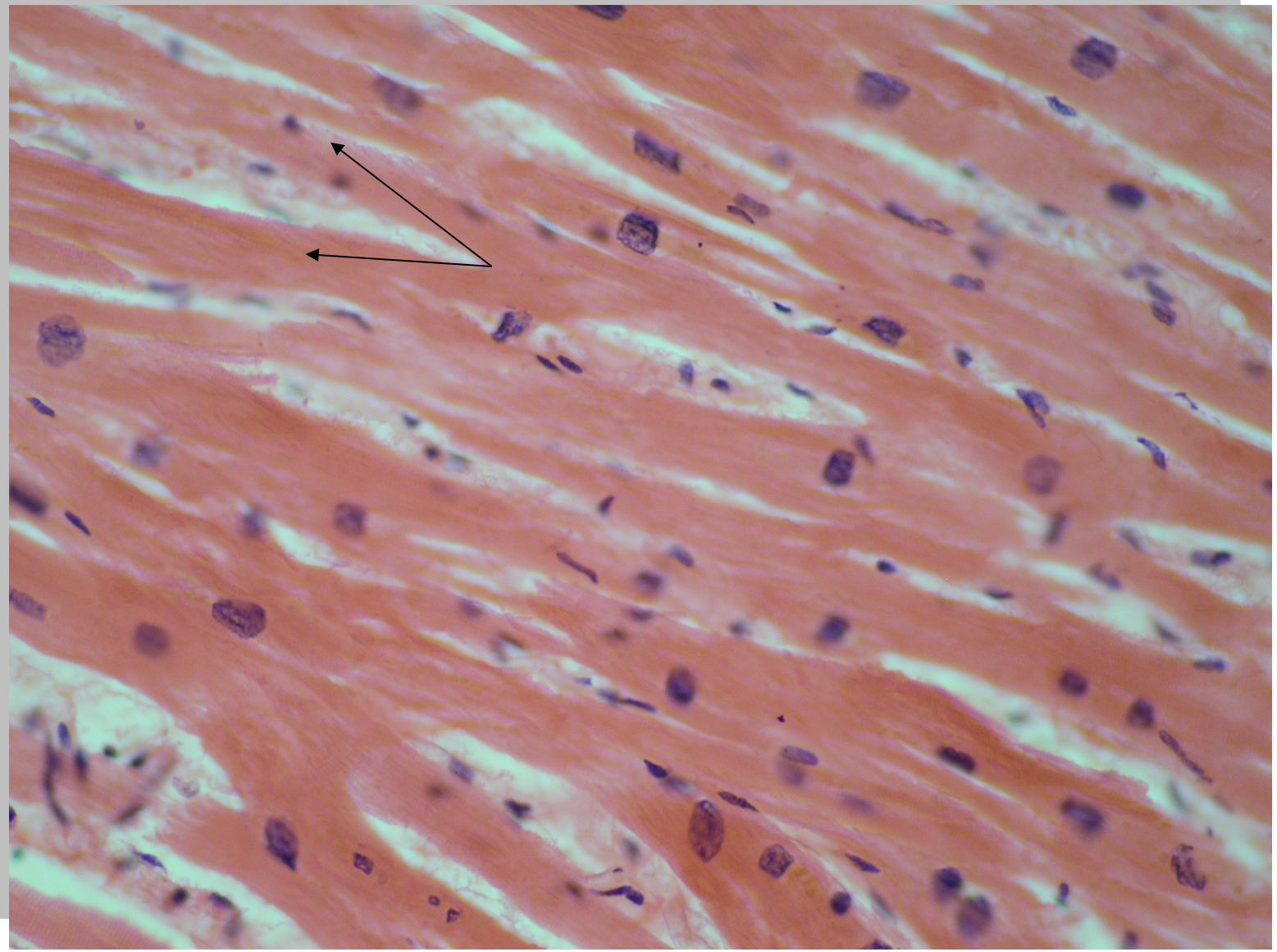

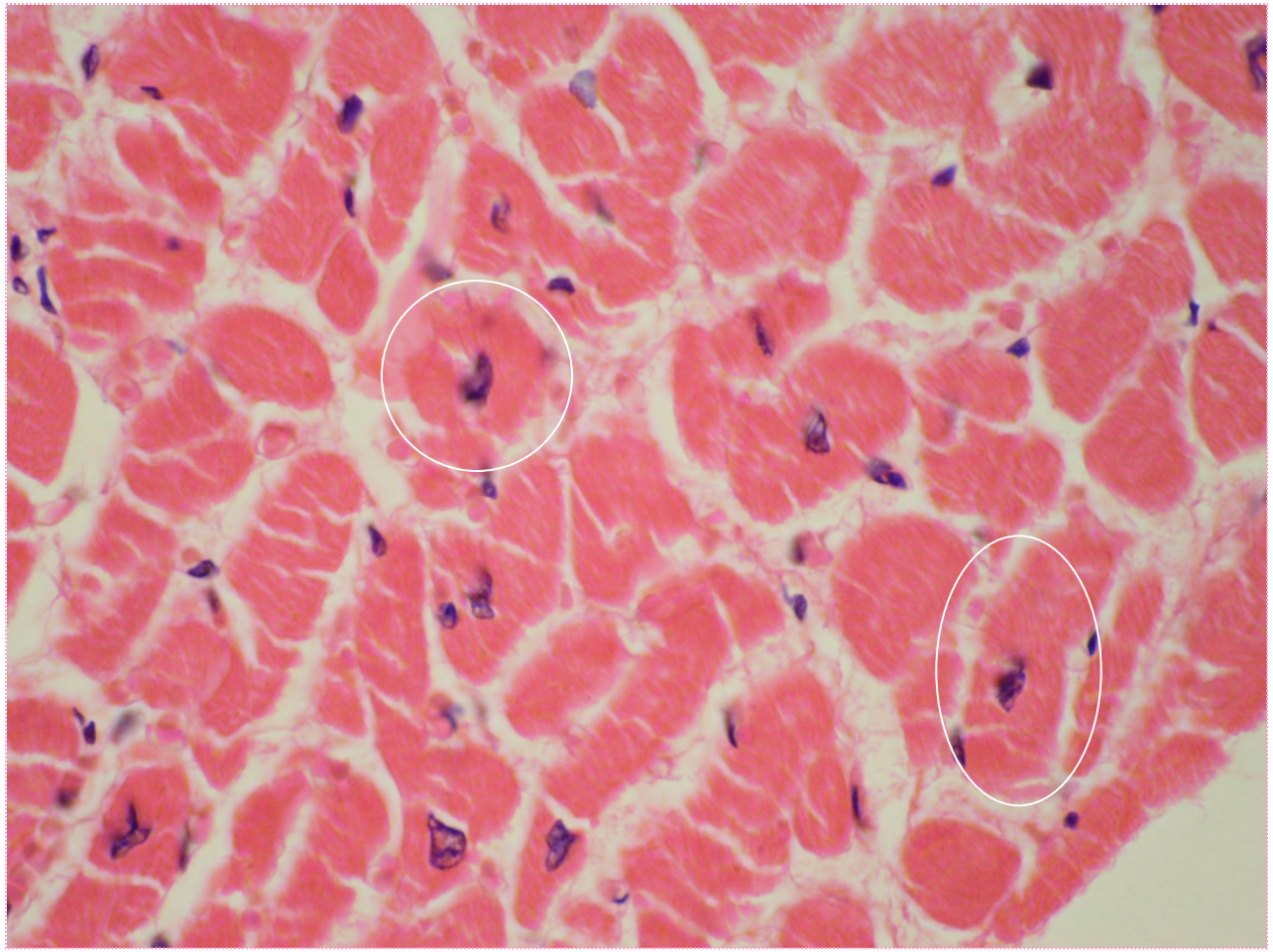

S. cardiac muscle

Nucieus

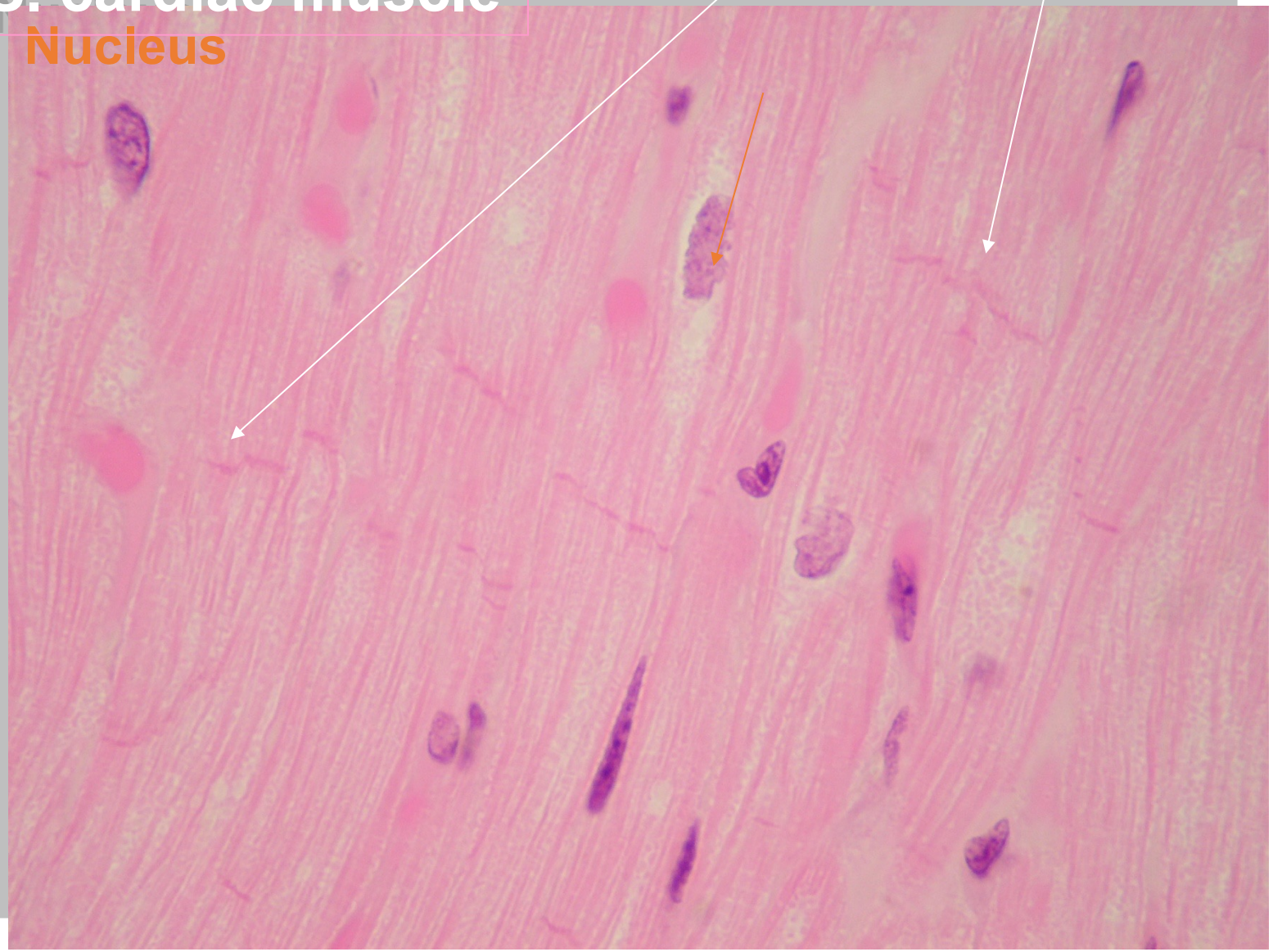

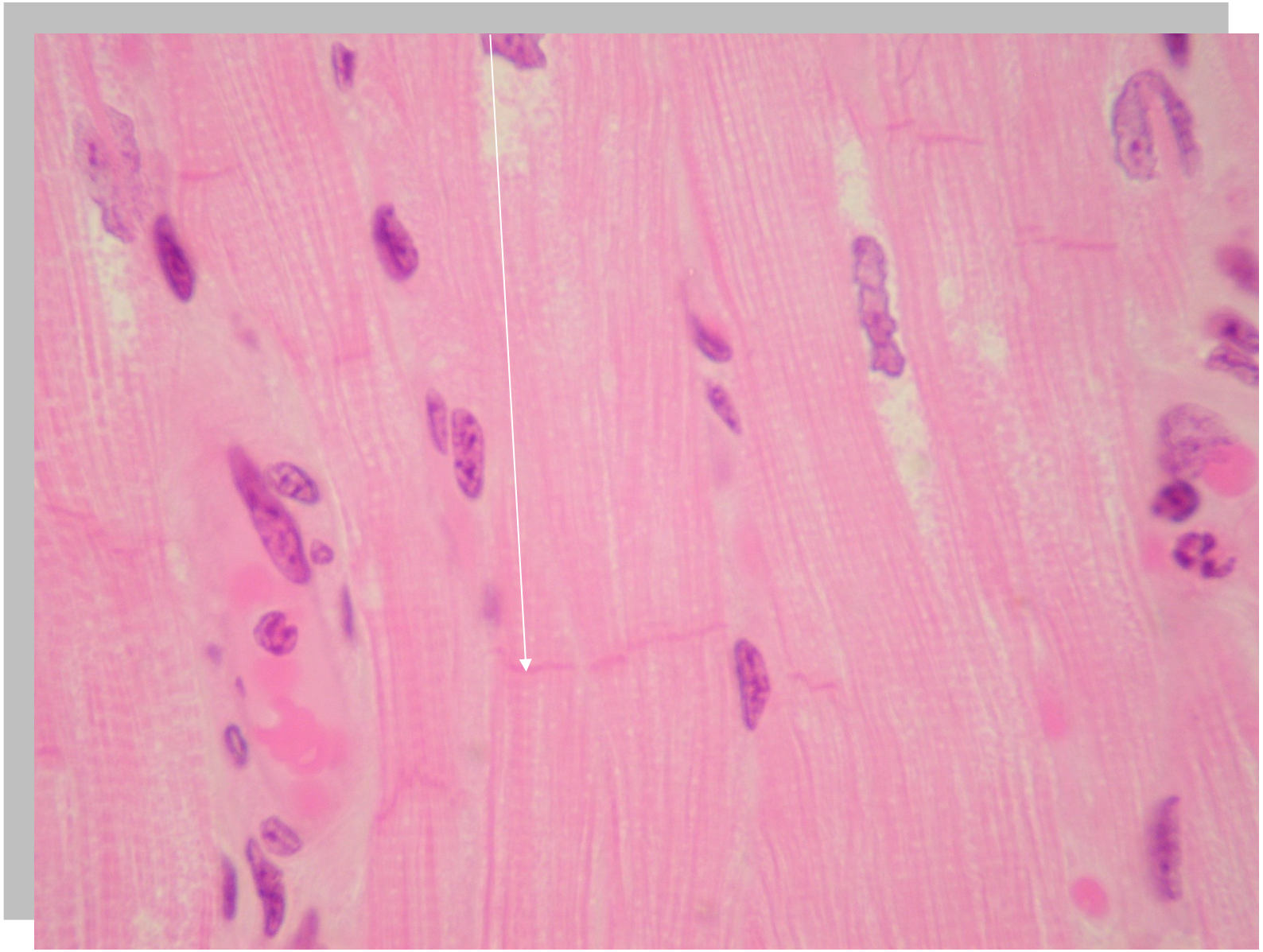

Nervous tissue

neuron:-soma=Nissl bodies

nucleous,nucleolus

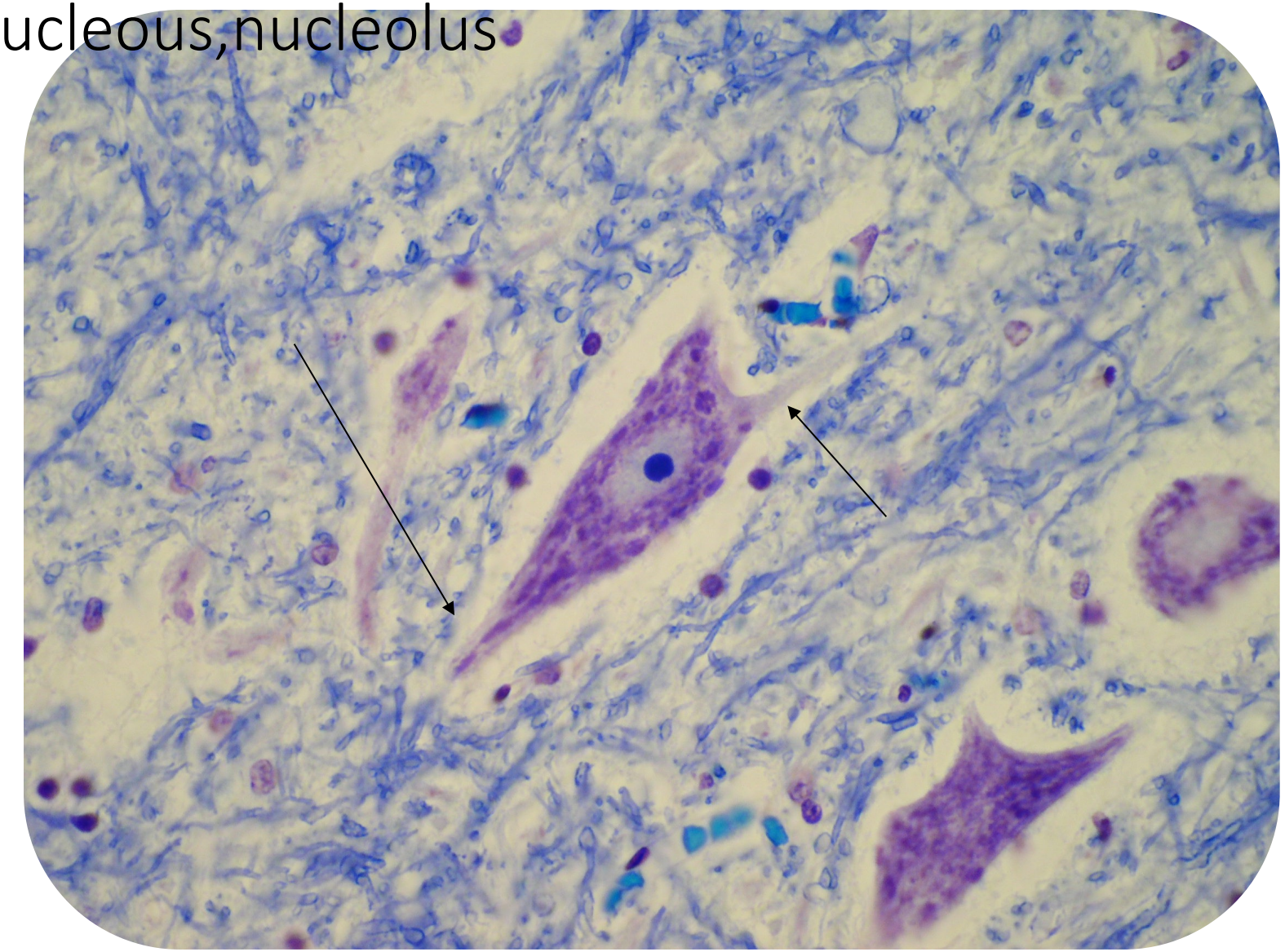

multipolar neuron (toluidine blue stain)

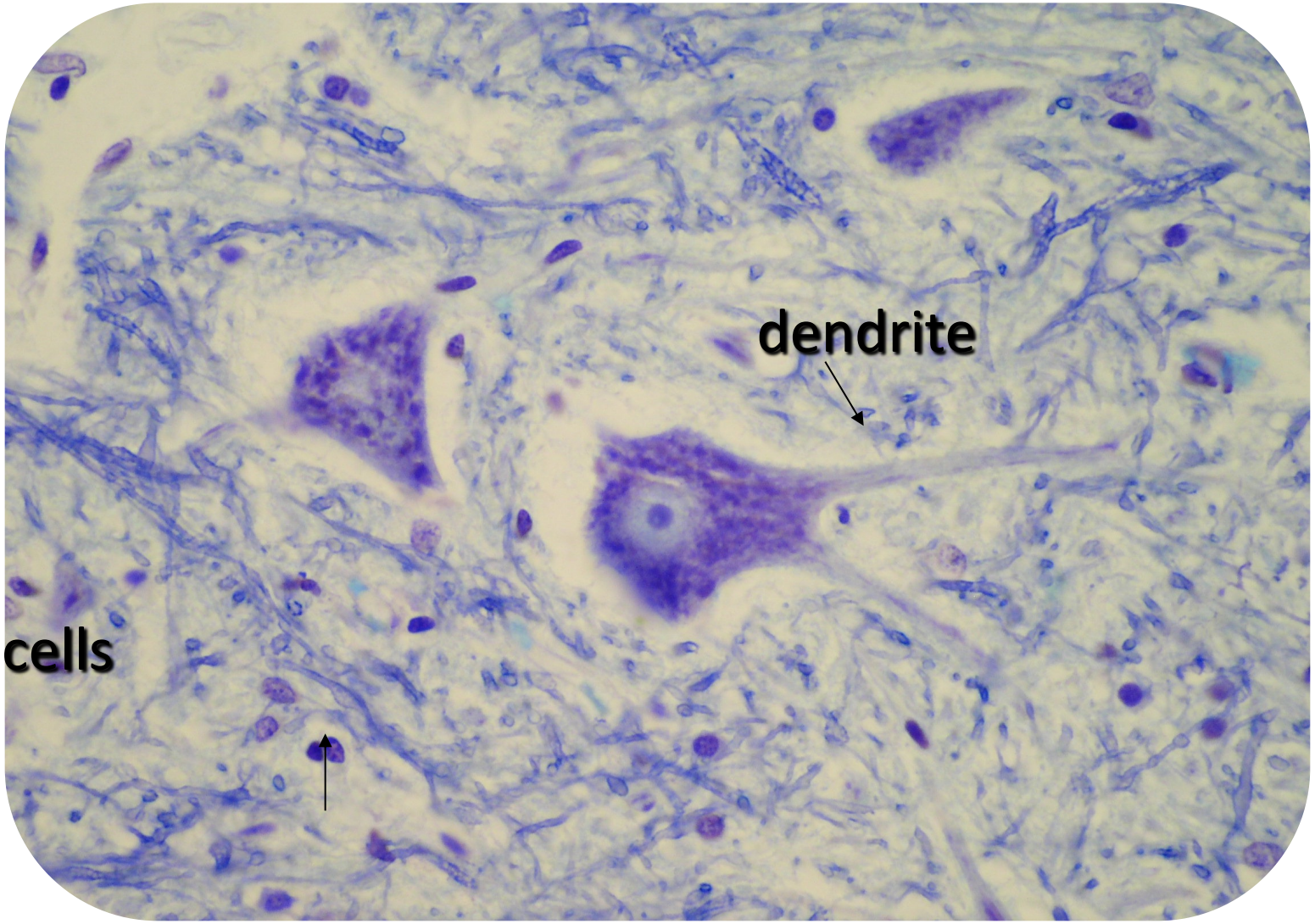

Sliver stain

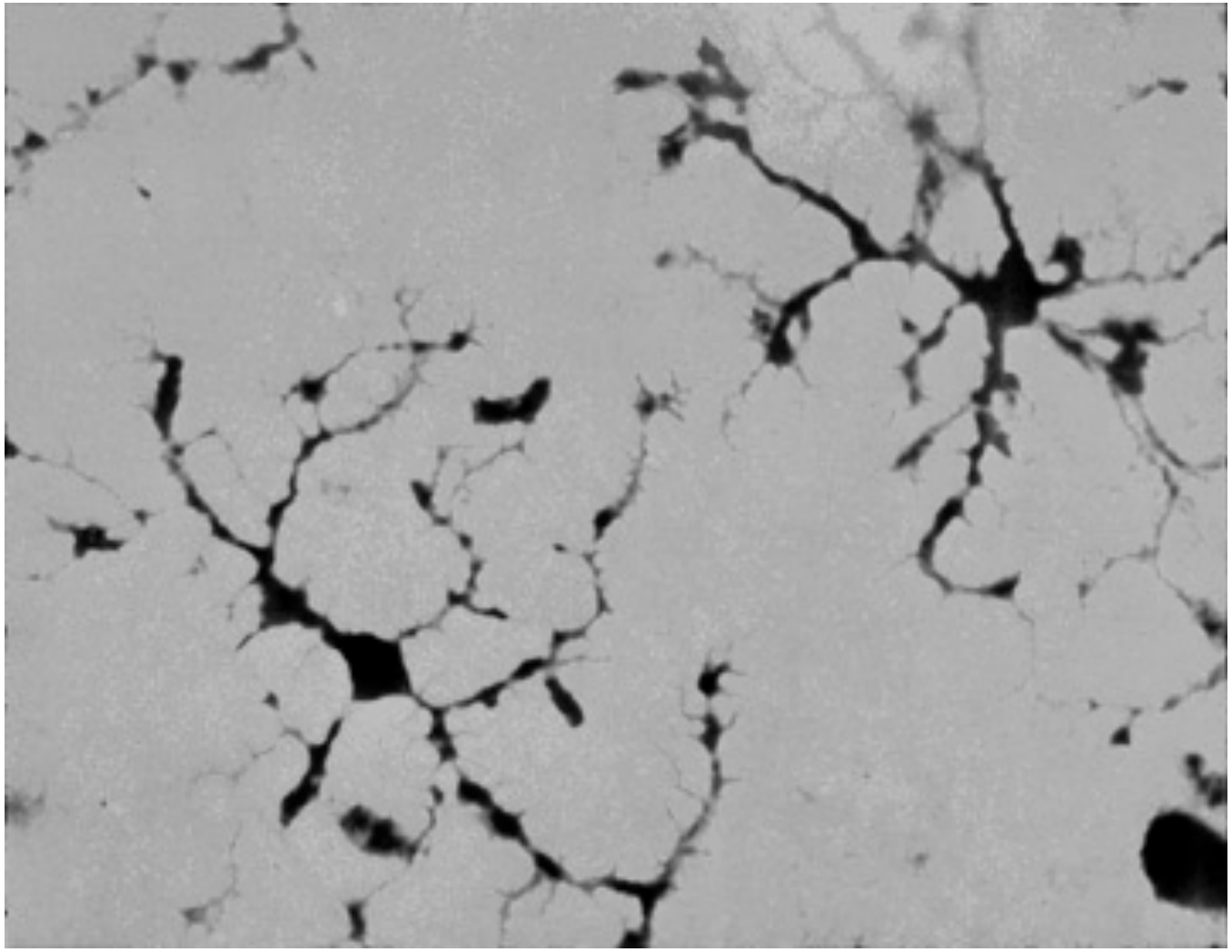

axon hillok of the axon

Neuropil: unmyelinated axons, dendrites and glial cell processes that forms a synaptically dense region containing a relatively low number of cell bodies

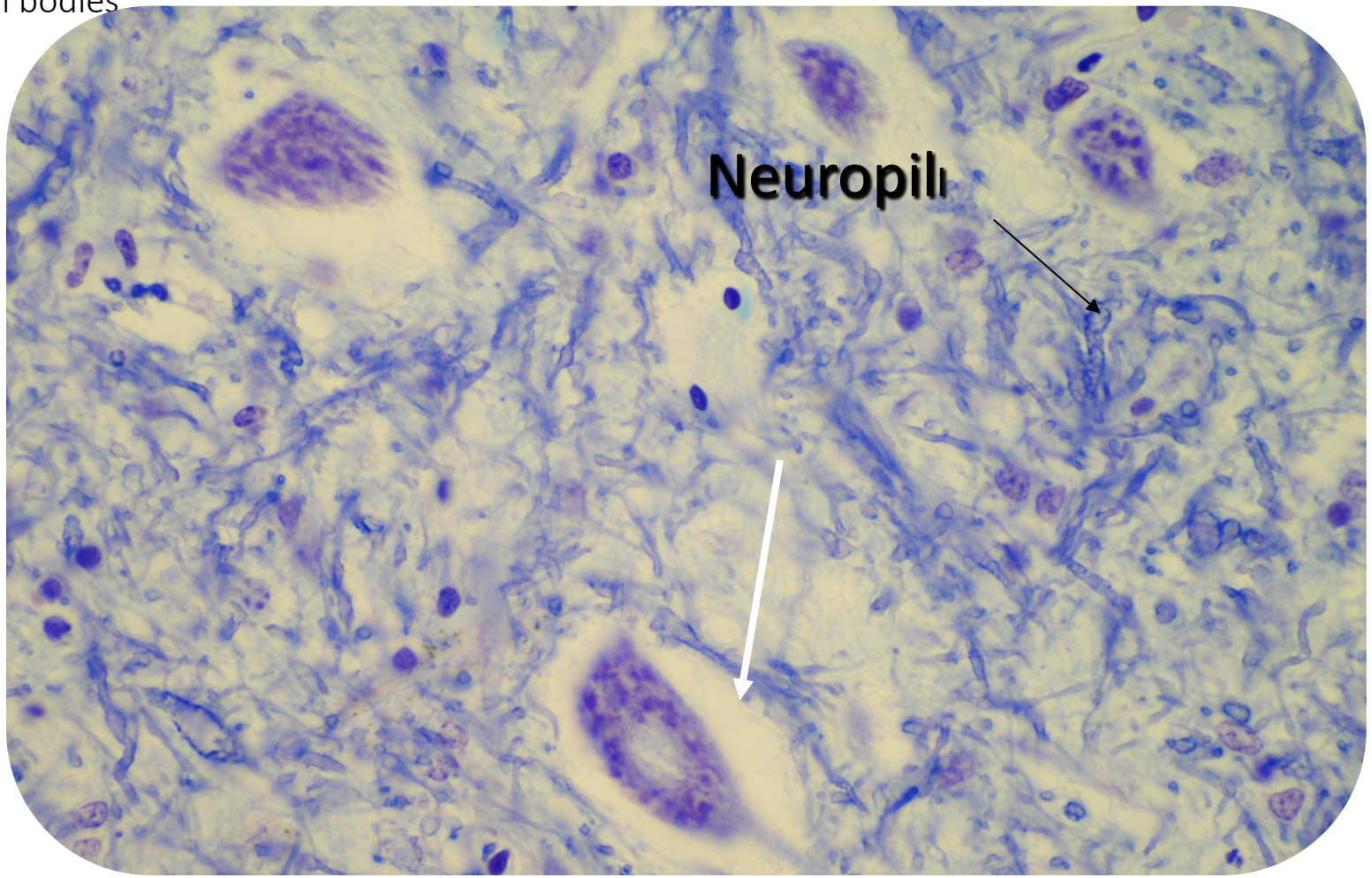

L.S. in nerve fibers -H&E stain

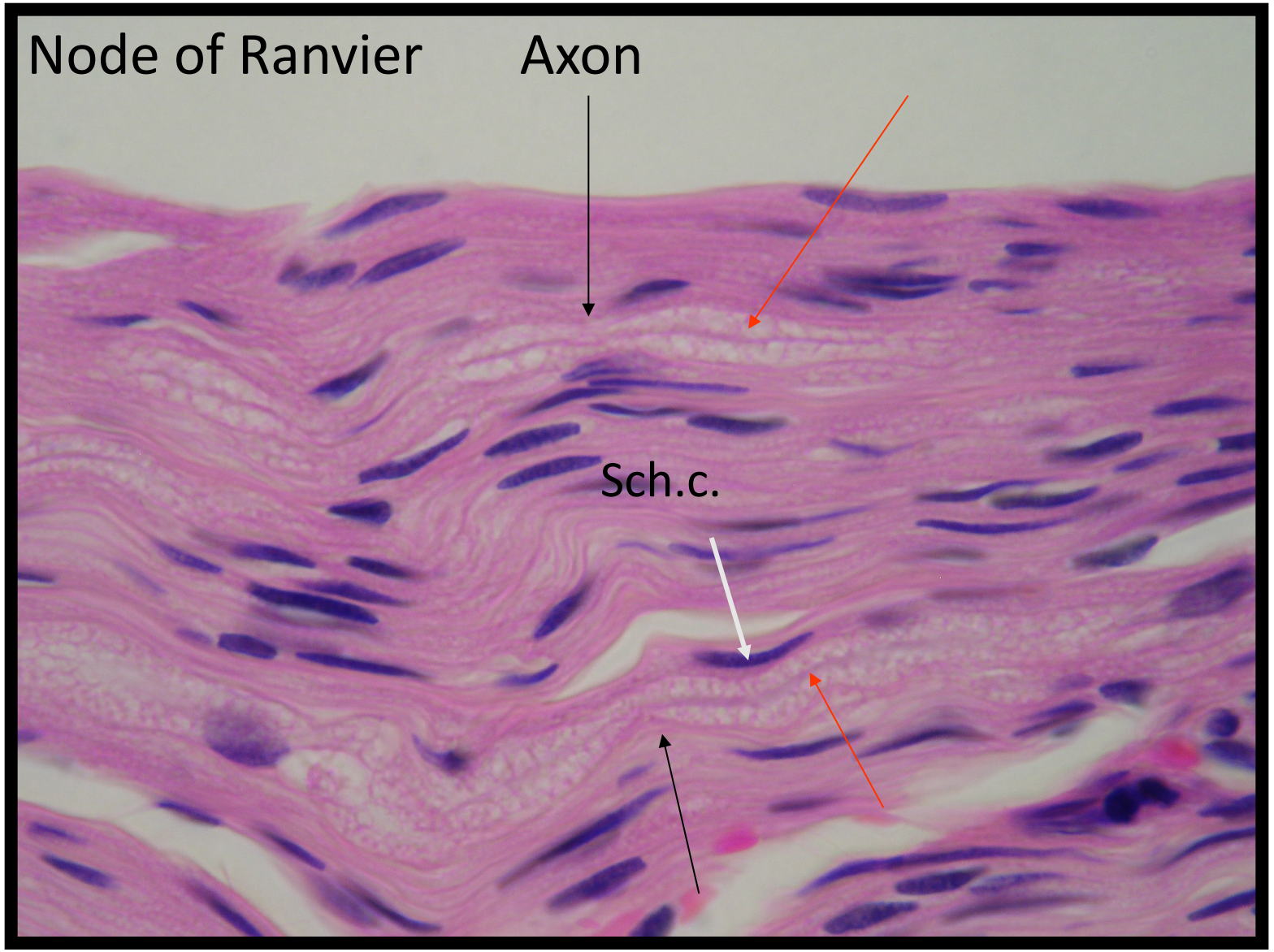

myelin- axon- Schwan cell

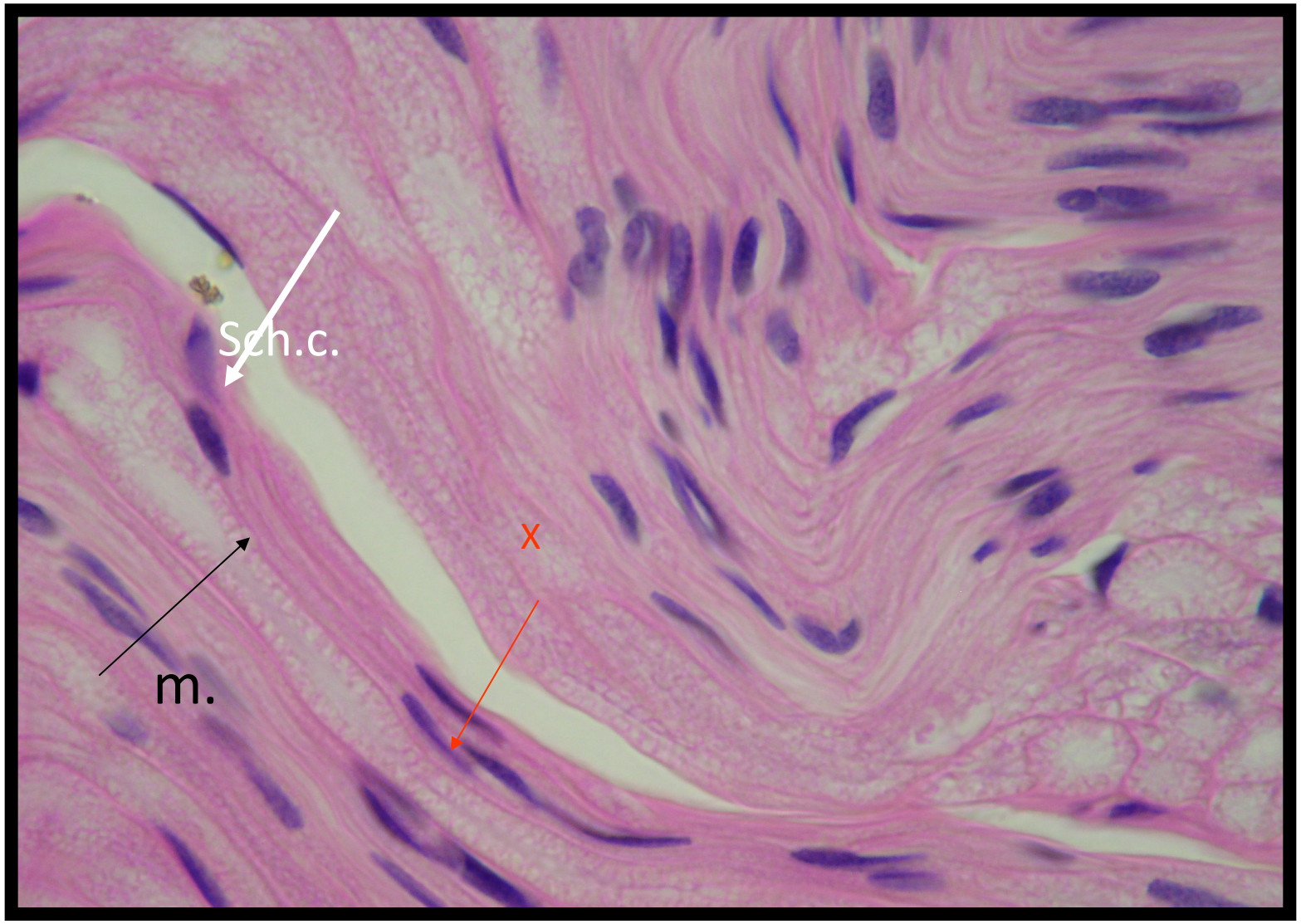

L.S. in nerve fibers (osmium tetraoxide) myelin- **Node of Ranvier**

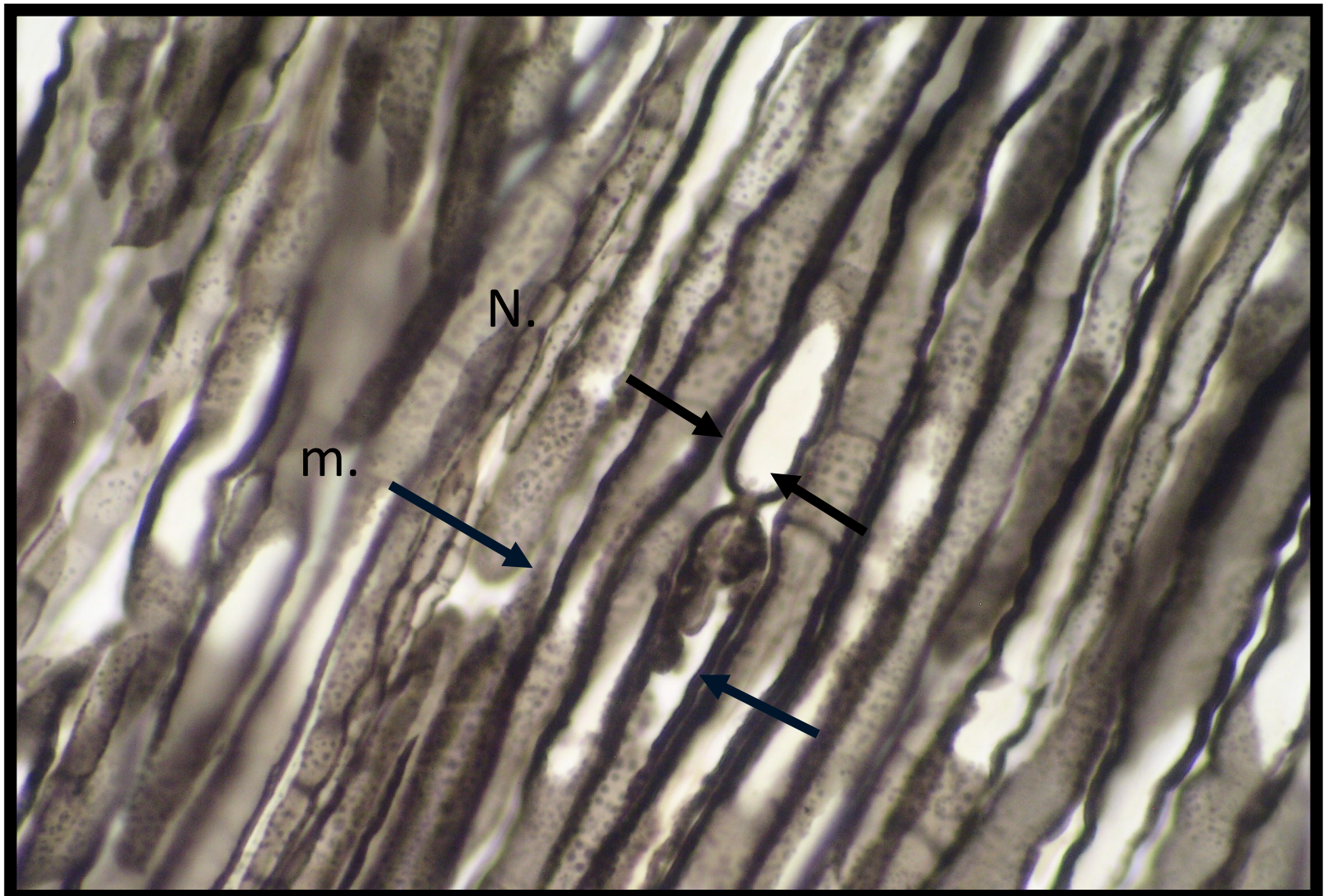

Axon cylinder

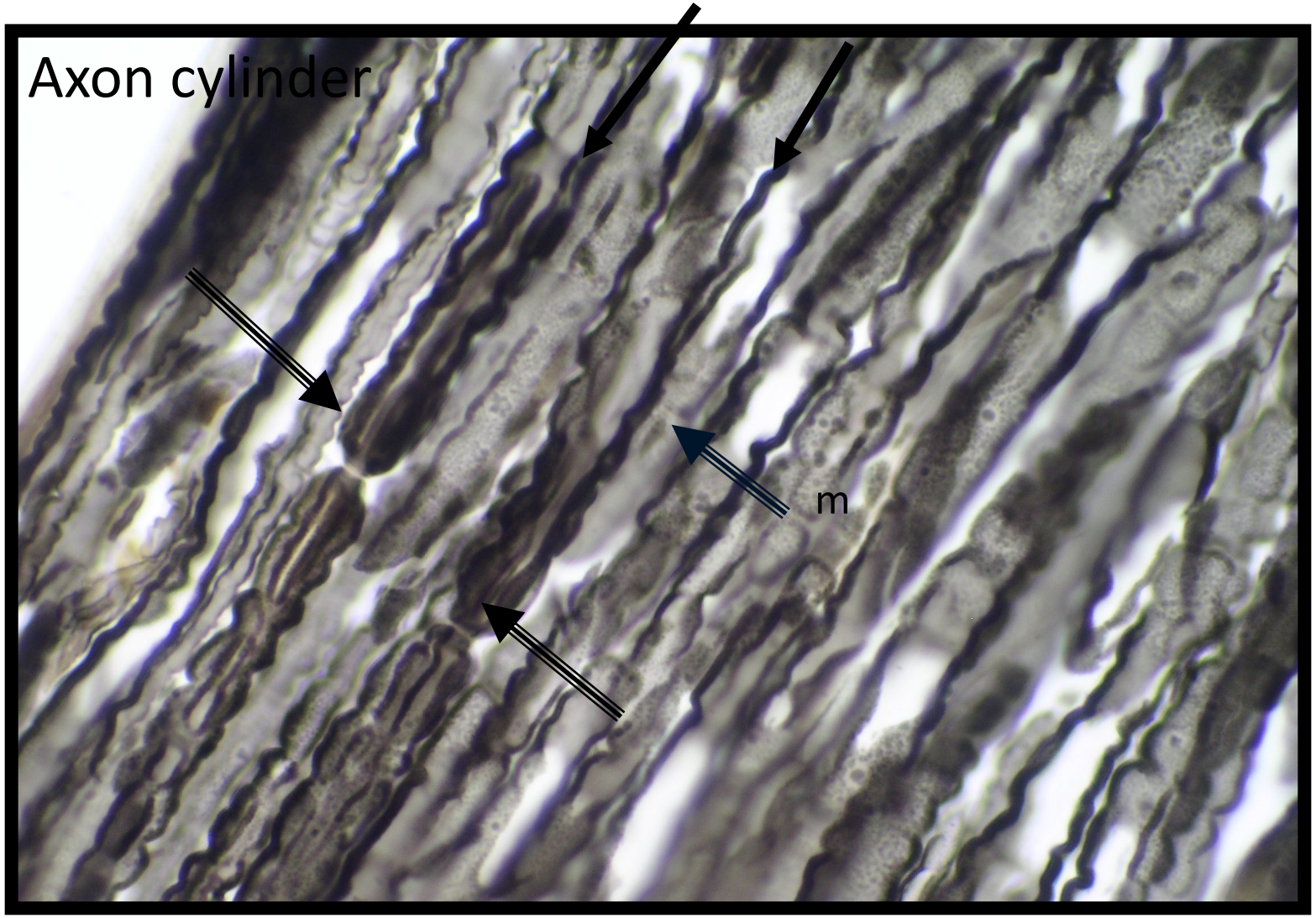

T.s.in nerve fibers

endoneurium perineurium

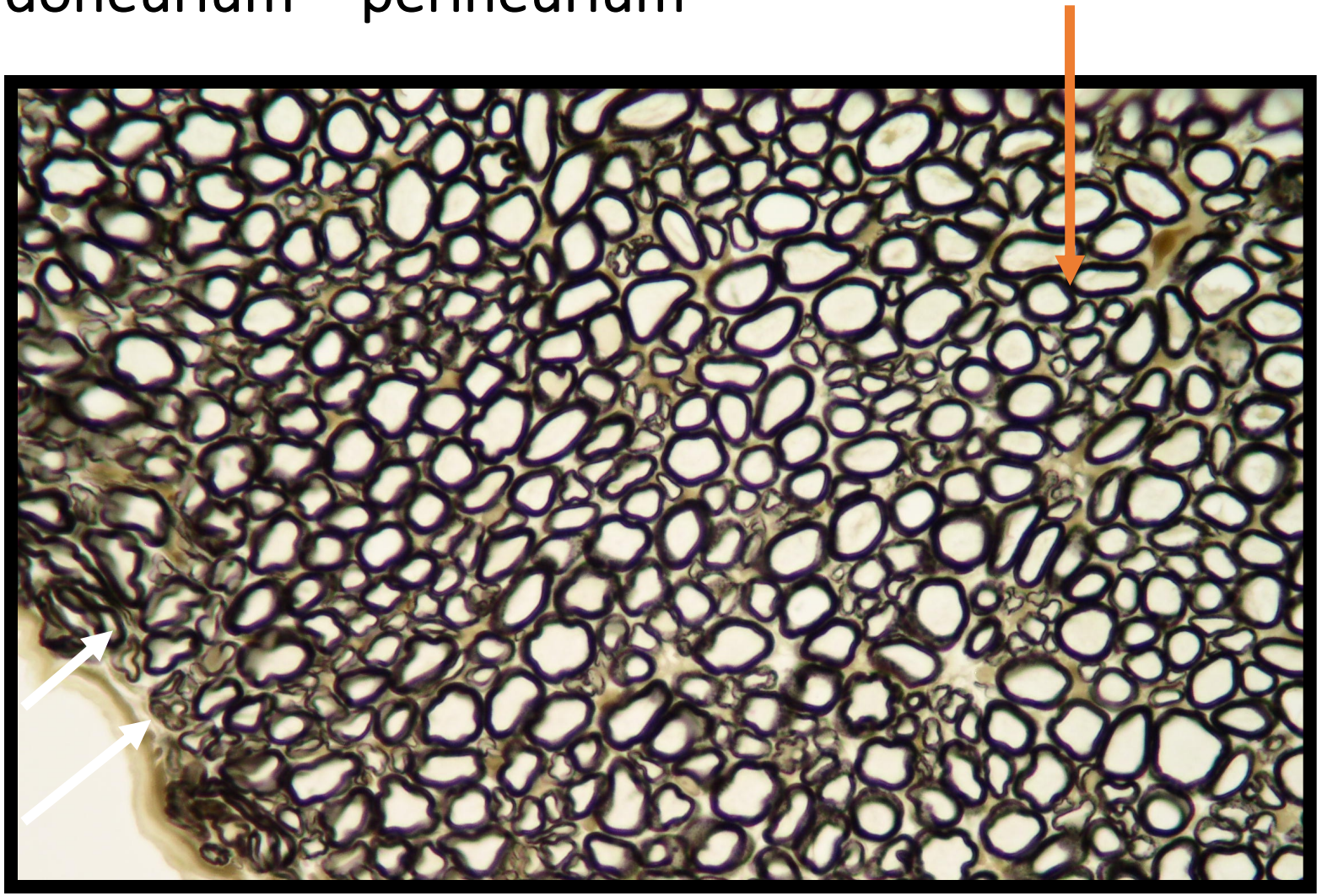

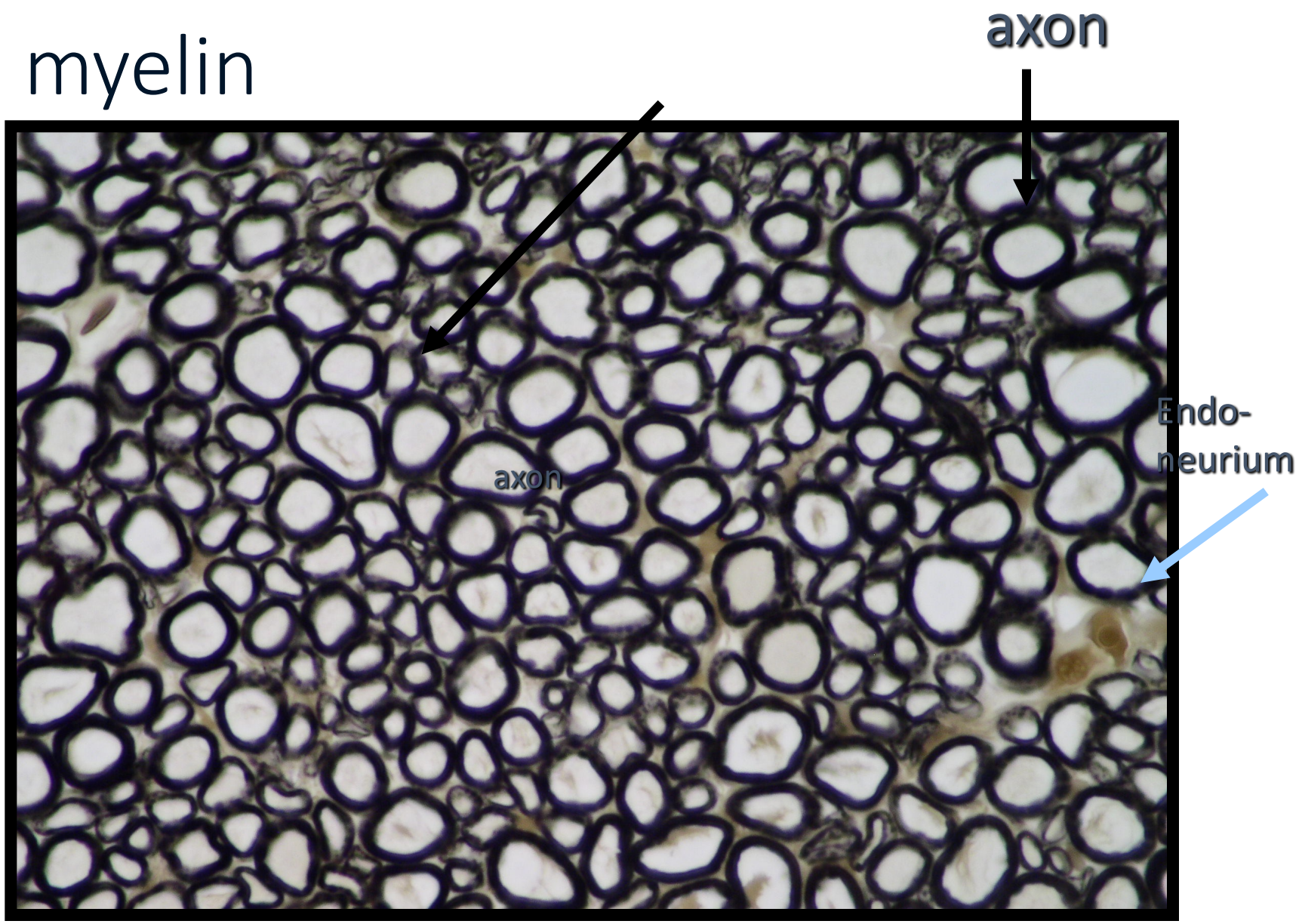
myelin
axon
axon
Endo-
neurium

H&E- Fascicles of nerve fibers

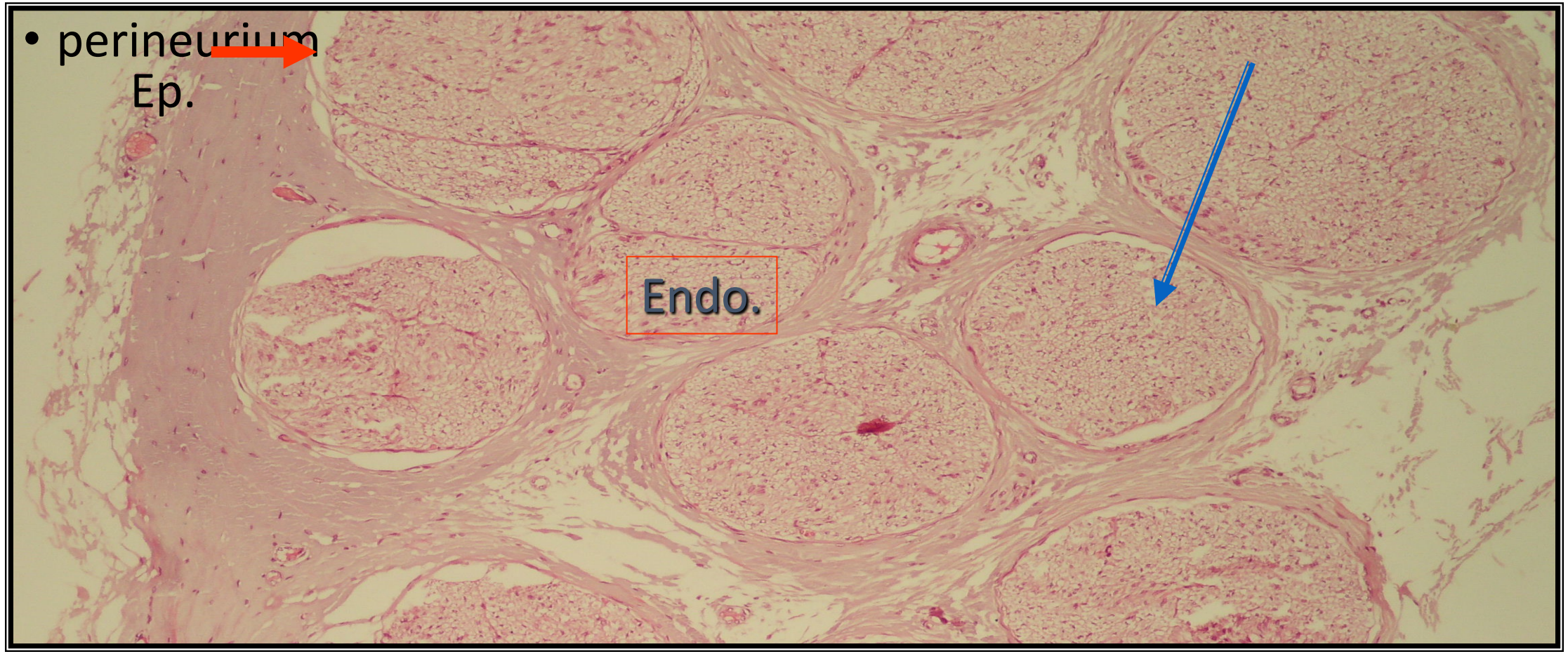

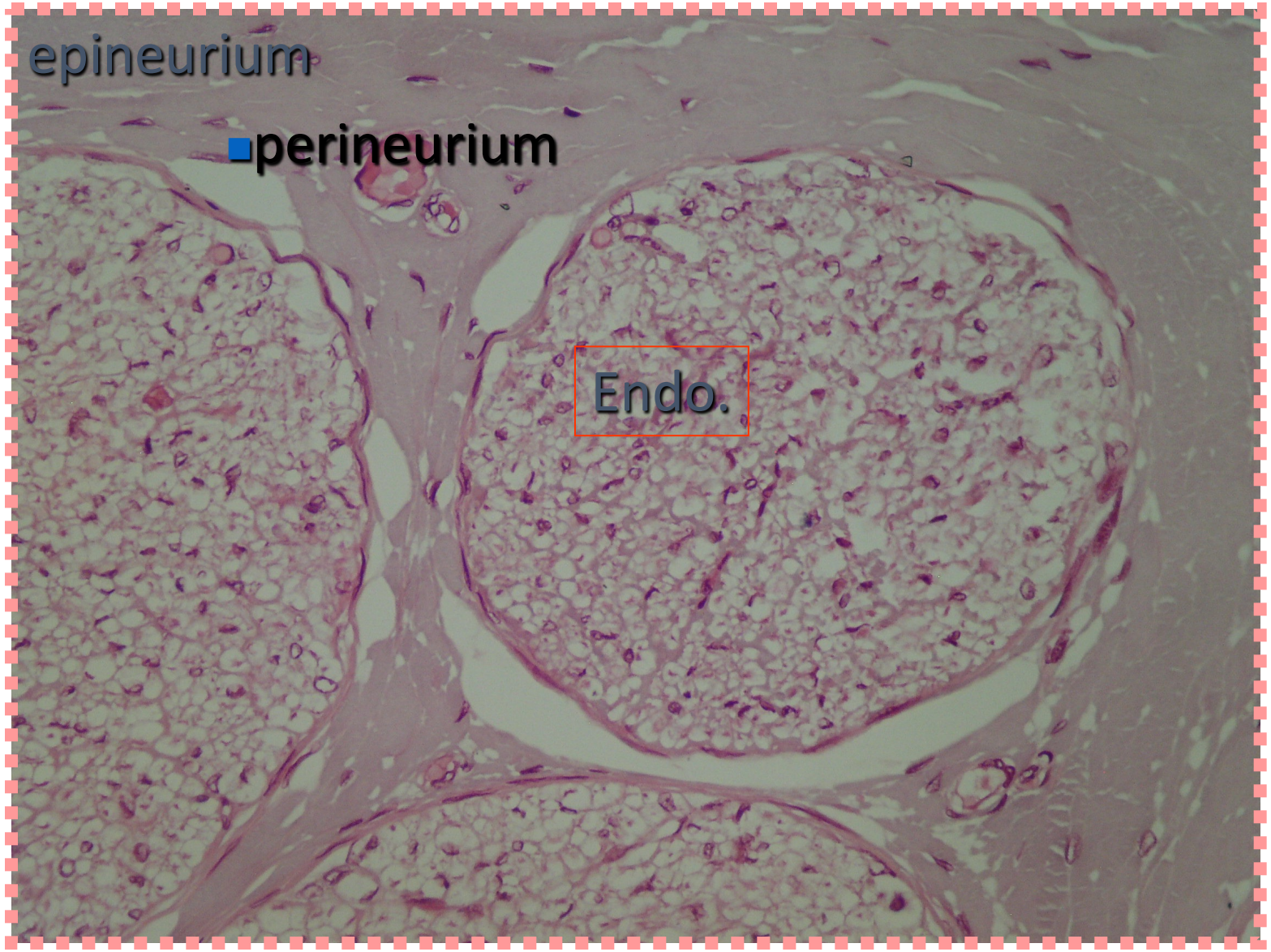
epineurium
perineurium
Endo.

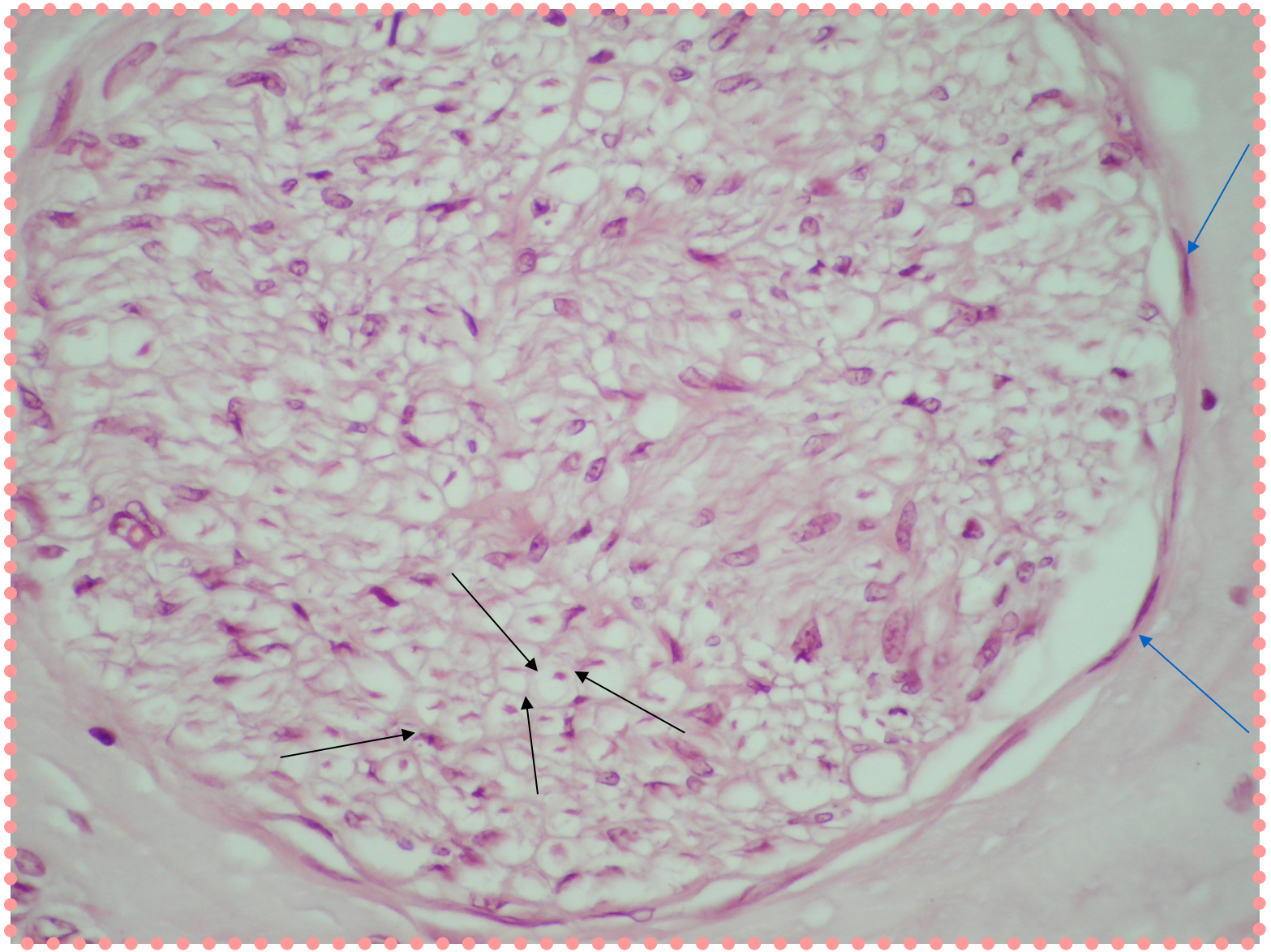

axon, myelin,schwan

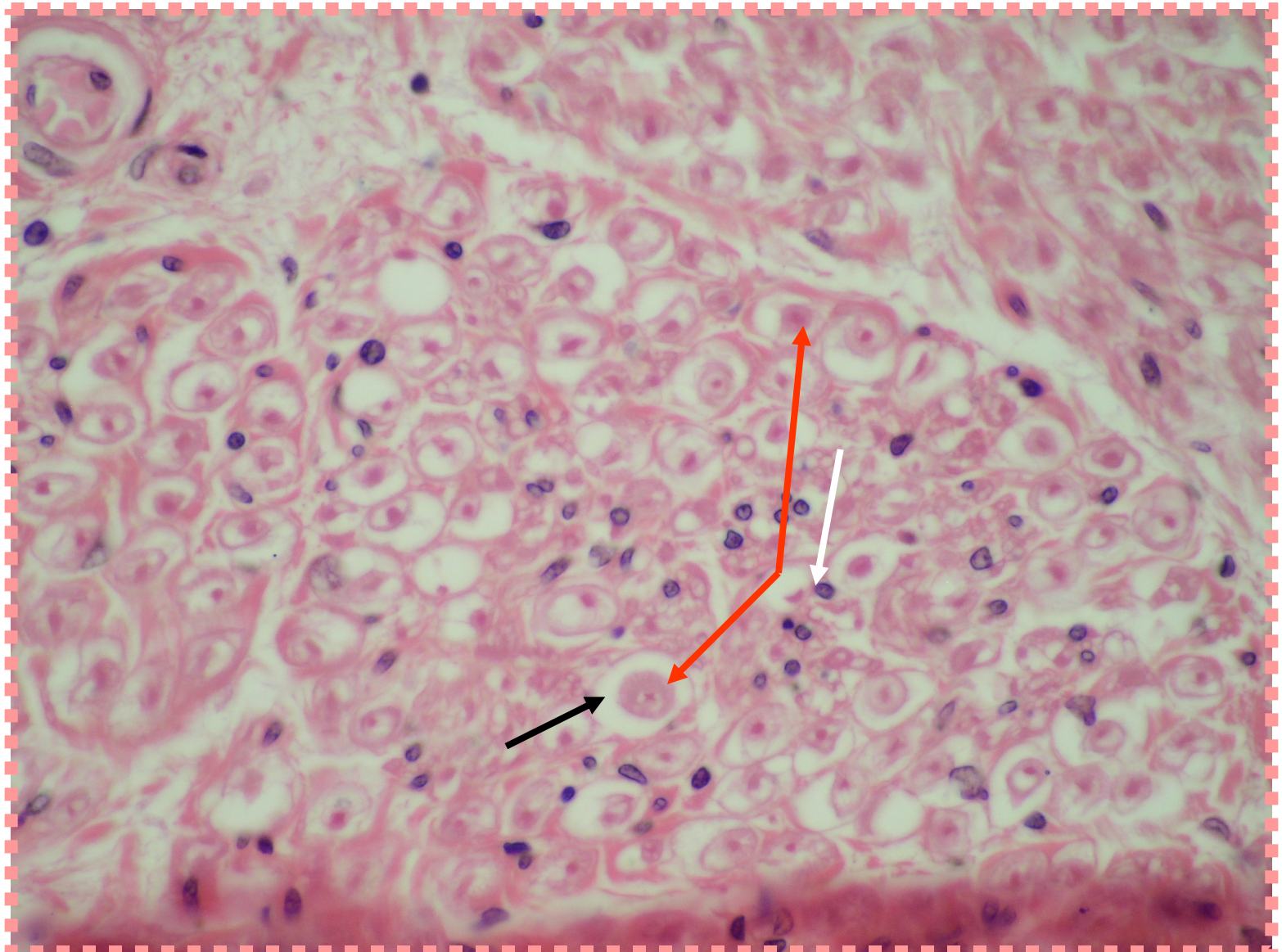

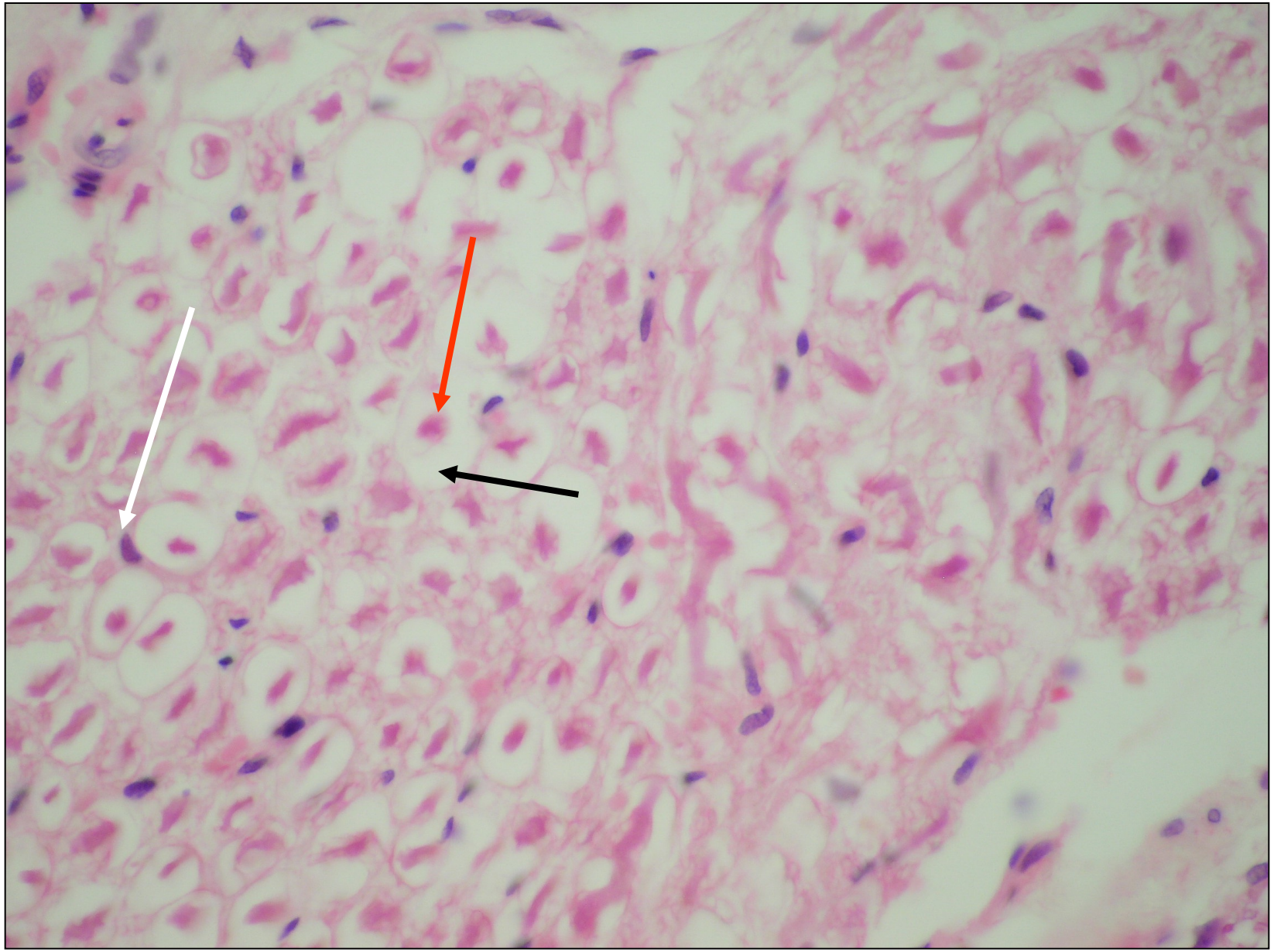

Spinal (dorsal) root ganglia

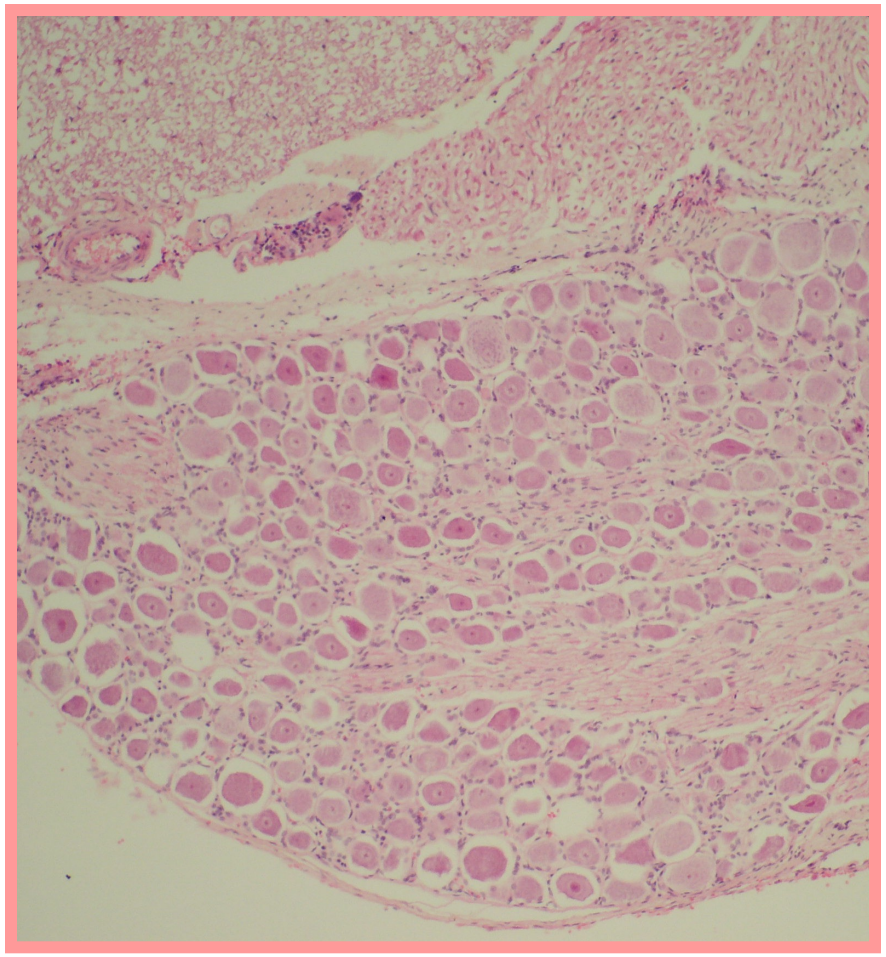

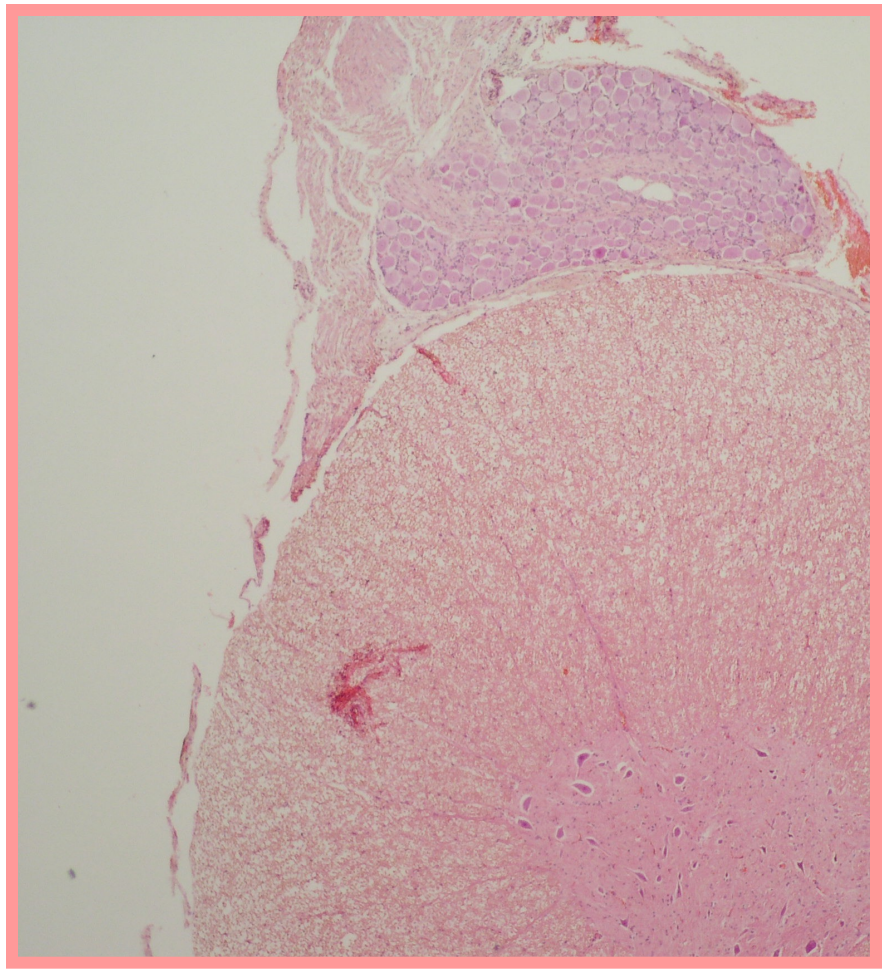

Sensory ganglion.
: neuronal cell bodies

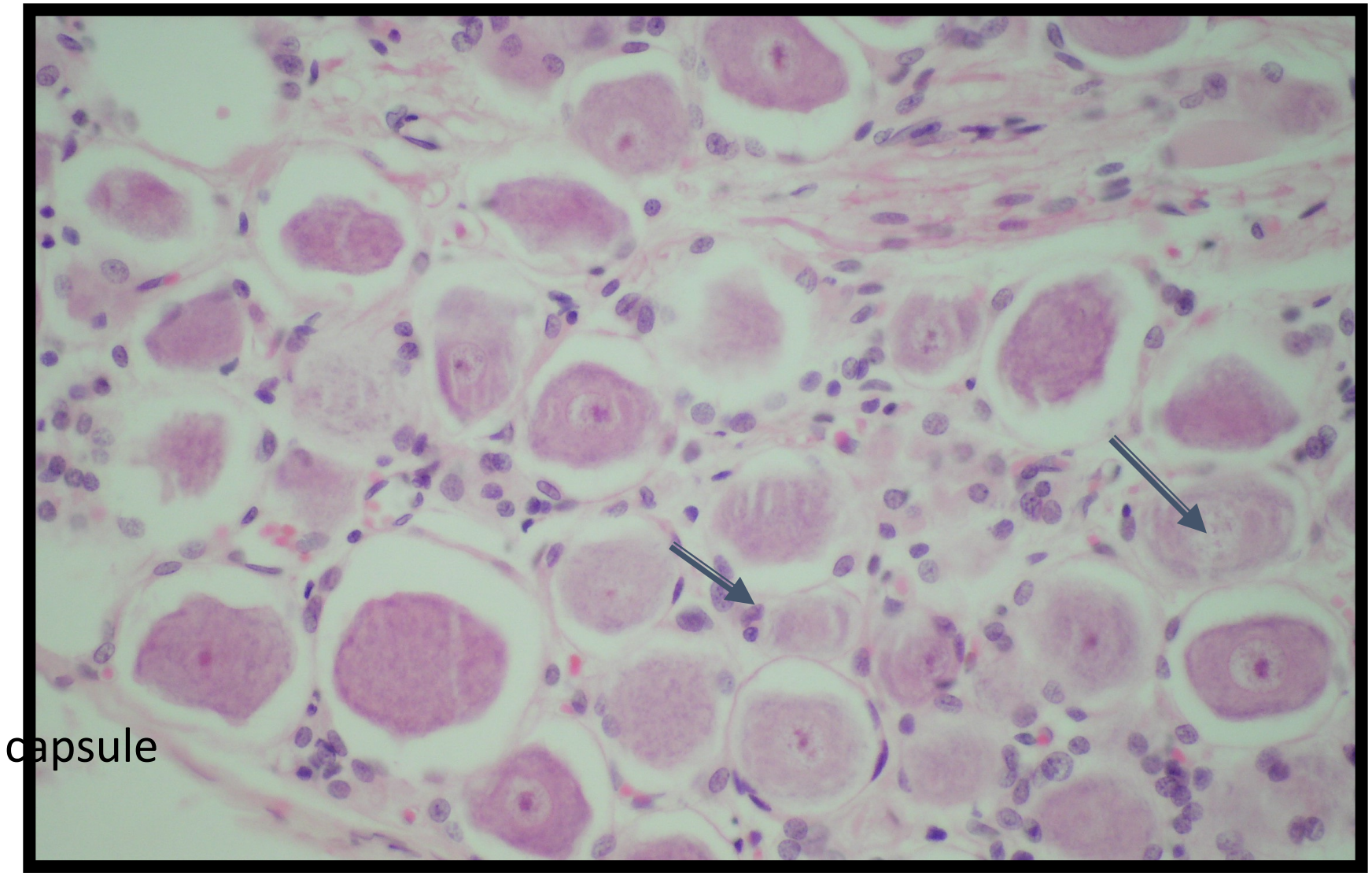

cell bodies satellite cells