

بسم الله الرحمن الرحيم

# Histology

Past papers for mid exam

Done by : Ola Nawafleh



## 1. The epidermis is

Stratified cuboidal

Simple squamous

stratified columnar

pseudostratified columnar

none of the above

2) Loose connective tissue is found

epidermis

throughout the dermis

under the gastrointestinal tract epithelial lining (lamina propria )

b +c

all of the above

3) On of the following about the fibroblast is correct ,except

Abundant cytoplasm

most common cells in connective tissue

rich in RER

large and darkly stained nucleus

proliferate spontaneously

4) The tendon is

loose connective tissue

dense irregular connective tissue

elastic connective tissue

dense regular connective tissue

reticular connective tissue

5) The oral mucosa (lining)

A stratified cuboidal in this idiom

pseudostratified columnar epithelium

keratinized stratified squamous epithelium

non keratinized stratified squamous epithelium

none of the above

6) What is the correct order for tissue staining steps

fixation /staining /cutting /embedding /processing /visualization (microscopy)

fixation /cutting /processing /embedding /visualization (microscopy)

fixation /cutting /staining /embedding /processing /visualization (microscopy)

fixation /processing /embedding /cutting /staining /visualization (microscopy)

none of the above

7) Epithelium is characterized by the following except

avascular

polarized

rests on basement membrane

presence of gap junctions

innervated

none of the above

8) Reticular connective tissue is present in

lymph nodes

bone marrow

liver

A&B

all of the above

9) kupfer cells are

monocytes

macrophage of the lungs

macrophages of the central nervous system

share the same precursor with osteoclasts

none of the above

10) Elastic connective tissue is seen in

heart walls

smooth muscles

lung tissue

large arteries

all of the above

11) Which of the following cells secrete histamine

lymphocytes

mast cells

RBC

B&C

Eosinophils

12) When you need to obtain a general idea about any tissue which of the following dyes will you use

hematoxylin and Eosin

silver stain

immunohistochemistry

Masson's trichrome

any of the above

13)

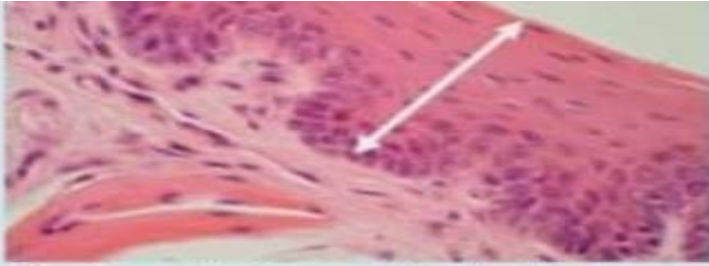


The black fibers (arrows) are-----  
-, and are stained with-----;

- a. Capillary, hematoxylin.
- b. Elastic fiber, hematoxylin.
- c. Reticular fiber, silver stain.
- d. Collagen, silver stain

[Clear my choice](#)

14)

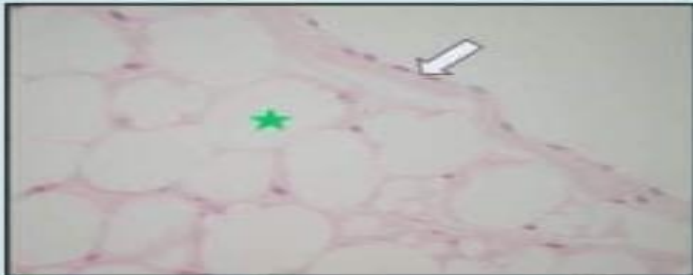

The tissue between the double arrow is present in the following locations, except:

- a. Oral cavity.
- b. Vagina.
- c. Esophagus.
- d. Trachea.

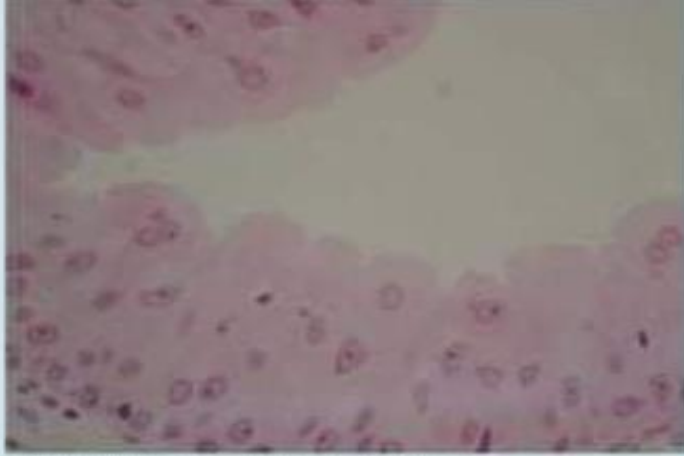
Clear my choice

15)



The arrow points at-----, and the star is in -----:

- a. Simple squamous epithelium and adipose tissue.
- b. Simple squamous epithelium and blood vessel.
- c. Simple cuboidal epithelium and simple squamous epithelium.
- d. Stratified squamous epithelium and bone.

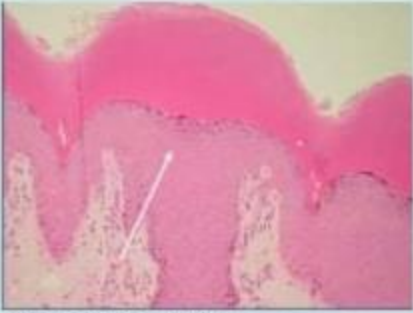


This tissue is taken from:

- a. Large intestine.
- b. Heart.
- c. Stomach.
- d. Urinary bladder.

16)

17)



This tissue (arrow) is-----,  
and located in-----:

- a. Simple cuboidal, respiratory tract.
- b. keratinized stratified squamous epithelium, skin.
- c. Simple columnar, respiratory tract.
- d. Stratifies columnar, gastrointestinal tract.

18)

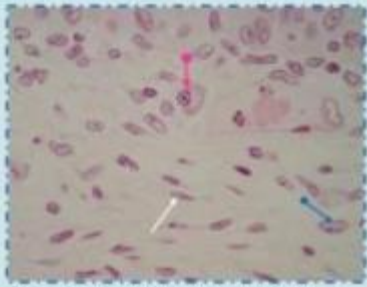


The arrow points at:

- a. Stratified cuboidal epithelium
- b. Simple columnar epithelium.
- c. Simple squamous epithelium.
- d. Simple cuboidal epithelium

Clear my choice





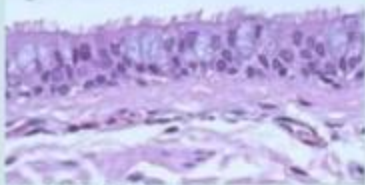
The white, pink, and blue arrows point at:

- a. Fibroblast, fibrocyte, and lymphocyte.
- b. Adipose cell, macrophage, and mast cell.
- c. Fibroblast, fibrocyte, and plasma cell.
- d. Fibrocyte, plasma cell, and fibroblast.

[Clear my choice](#)

19)

20)



All about this tissue is correct, except:

- a. Present in the trachea.
- b. Contains cells that secrete mucous.
- c. Can regenerate.
- d. Stratified.

[Clear my choice](#)

