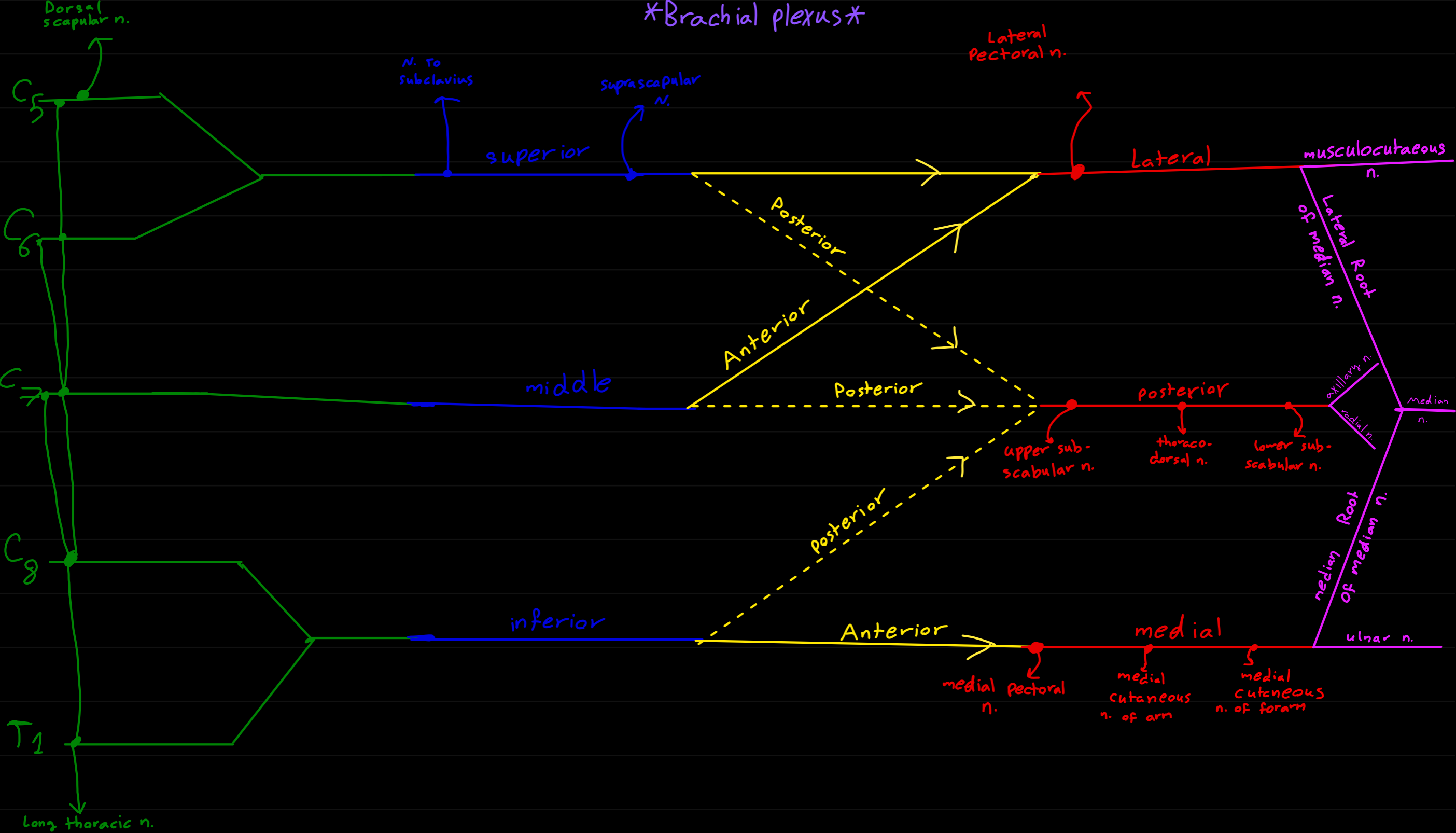


Brachial plexus




Roots

Trunks

Divisions

Cords

Branches



Origins

clavicale

pectoral major in medial 2/3

deltoid in anterior border of lateral shaft

scapula

Latissimus dorsi of inferior angle

deltoid — lower border of its spine
lateral border of scapion

supraspinatus of supraspinatus fossa

infraspinatus of infraspinatus fossa

Teres minor of upper 2/3 lateral border

Teres major of above inferior angle.

subscapularis of subscapularis fossa

coracobrachialis in coracoid

biceps — long is supraglenoid
short in coracoid

Triceps the long in infraglenoid.

Humerus

Brachialis of lower 1/2

Triceps of post. surface of later and medial border

Pronator teres of C.F.O

Flexor carbi Radialis of C.F.O

Palmaris of C.F.O

Flexor digitorum superficial of C.F.O

Flexor carbi ulnaris of C.F.O

Brachio radialis of upper 2/3 of lateral supercondylar ridge

Extensor carbi radialis longus of lower 2/3 of lateral supercondylar ridge

Extensor carbi radialis Brevis

+ Extensor digitorum

+ Extensor digiti minimi

+ Extensor carbi ulnaris

all in C.E.O

anconeus in back of lateral epicondylar

Supinator in lateral epicondylar

*C.F.O → front of medial epicondyle

*C.F.O → front of lateral epicondyle

Thorax

Pectoralis major — upper 6 costal cartilages
anterior surface of sternum

pectoralis minor of 3rd, 4th, 5th close to costal cartilages

serratus of upper 8 ribs

trapezius of all thoracic spines

Latissimus dorsi of spine of lower 6 thoracic vert.

Levator scapula of upper 6 cervical vert.

Rhomboides minor in spine of c7 and T1

Rhomboides major in T2, T3, T4, T5

Radius

F. digi. superficialis in ant. border

E.P. Brevis in post. surface

F. Pollicis longus in ant. surface

Supinator in Radial collateral ligament

Ulna

pronator teres in coronoid

F.C.U in olecranon

F.D profundus in anterior surface

Pronator quadratus in ant. surface

F.D. superficialis in coronoid

supinator in supinator fossa, crest

abd. pollicis longus in post. sur.

E. pollicis longus in post. sur.

E. indicis in posterior surface

Trapezius

external occipital protuberance

Ligamentum nuchea

latissimus dorsi

iliac crest of hip bone

*** insertions ***

Scapula

pectoralis minor in coracoid

serratus in ventral lip of medial border

Trapizus → upper border in spine
→ Post. " in lateral third
→ medial " in acromion

Lavator scapula in back of medial border

Rhomboids min. in spine

Rhomboids maj

Radius

biceps in radial tuberosity

Pronator teres in lateral surface

pronator quadratus in ant. surface

brachioradialis in styloid process

supinator in all surfaces **except** medial surface of upper 1/3

Humerus

pectoralis major in lateral lip of bicipital groove

Latissimus in front of bicipital groove

deltoid in deltoid tuberosity

supraspinatus in Greater tuberosity in upper impression

infraspinator in Greater tuberosity in middle impression

Teres minor Greater tuberosity in Lower impression

Teres major middle lip of bicipital groove

subscapularis in lesser tuberosity

coracobrachialis in middle of medial border

Thumb

F. pollicis longus terminal phalanx

abd. P. longus 2nd metacarpal

E. P. brevis proximal phalanx

E. P. longus distal phalanx

Hand

F.C.R in 2nd, 3rd metacarpal

Palmaris longus in palmar aponeurosis

F.D. superficialis in middle phalanx of medial 4 fingers

F.C.U in pisiform 5th metacarpal

F.D. profundus in distal phalanges of medial 4 fingers

E.C.R longus in 2nd metacarpal

E.C.R Brevis in 3rd metacarpal

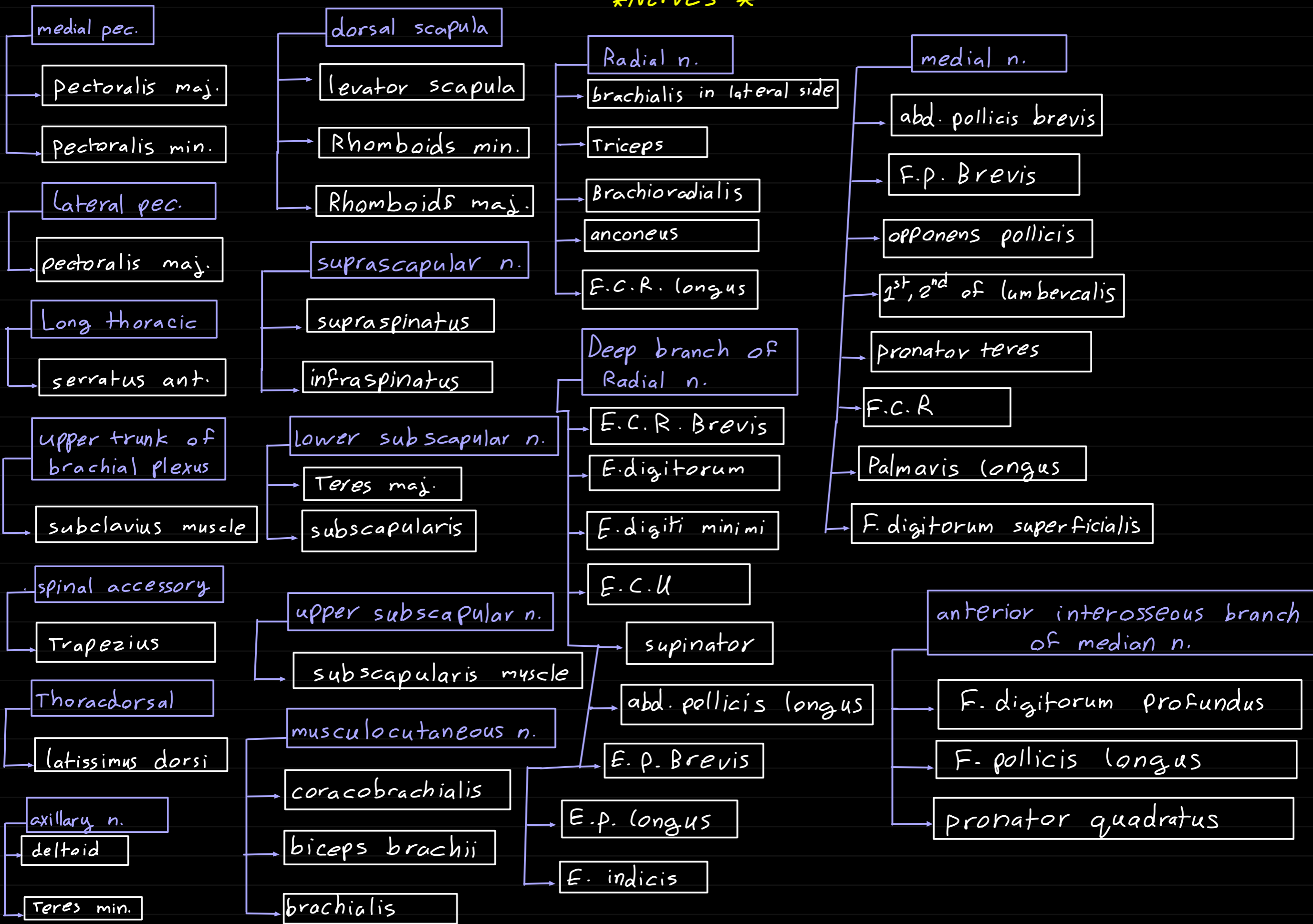
E. Digitorum in extensor expansion of medial 4 fingers

E. minimi in extensor expansion of little finger

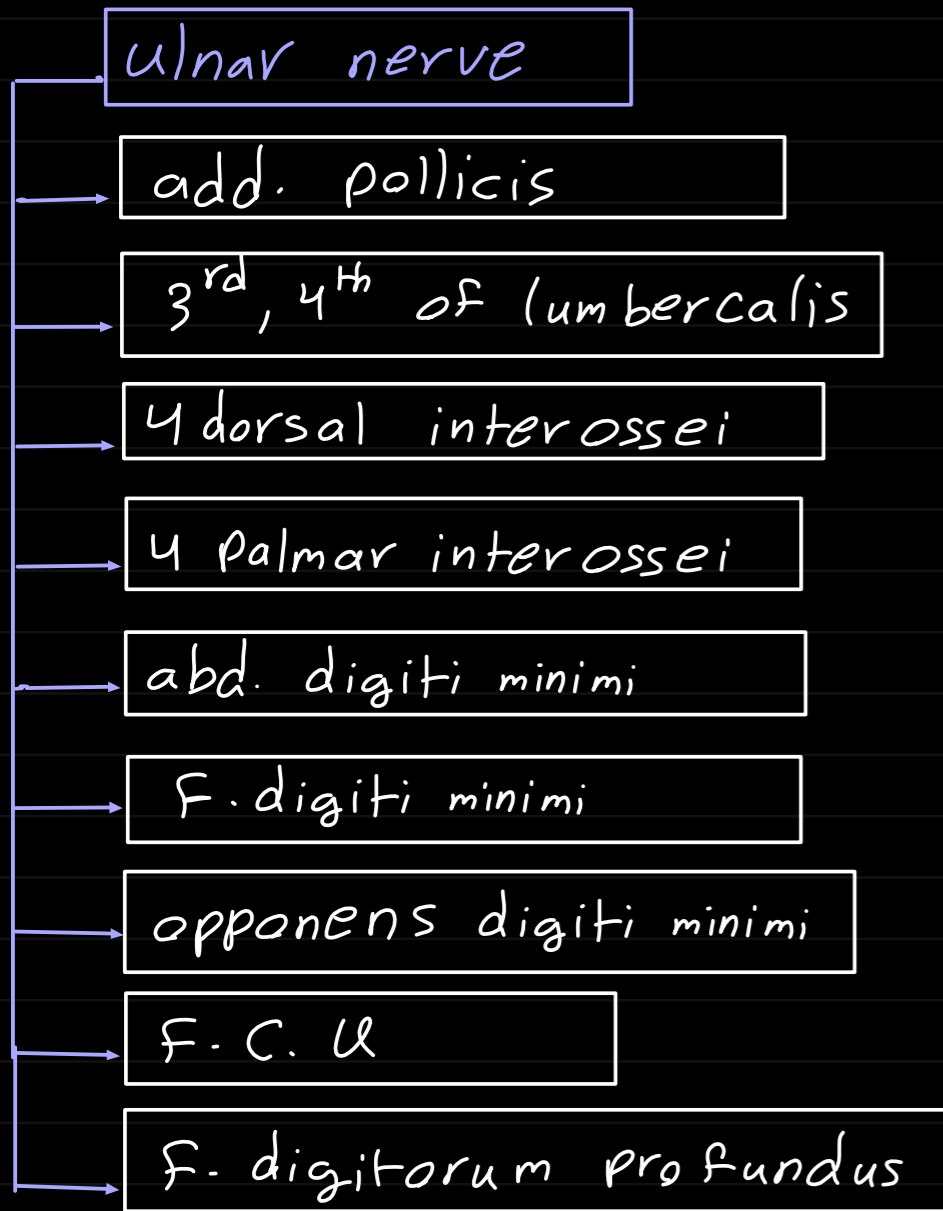
E.C.U in 5th metacarpal

E. indicis in extensor expansion in index

Nerves



Nerves



insertions

