Upper Limb practical

Clavicle

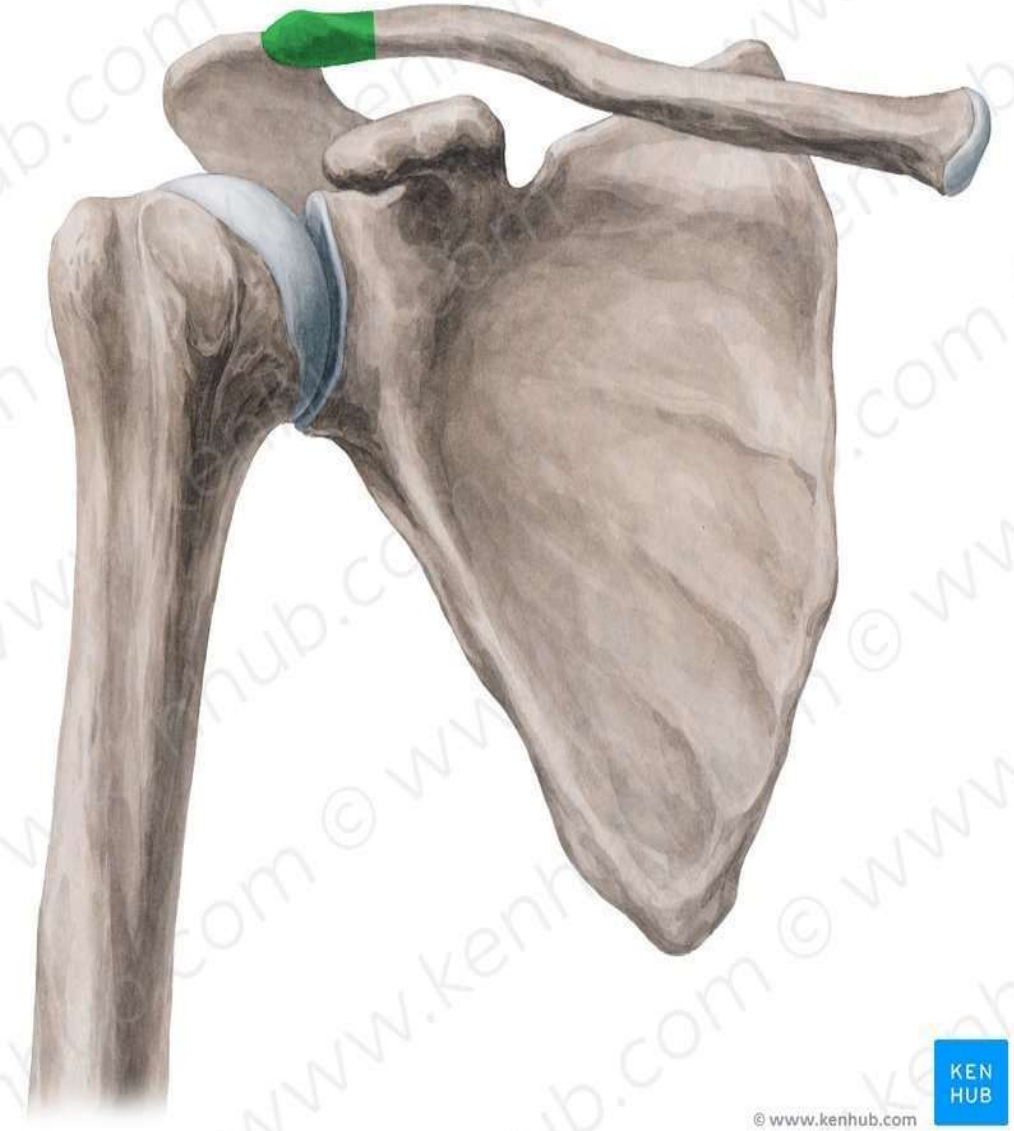

Lateral end (acromial)

Medial end (sternal)

Conoid tubercle

Scapula

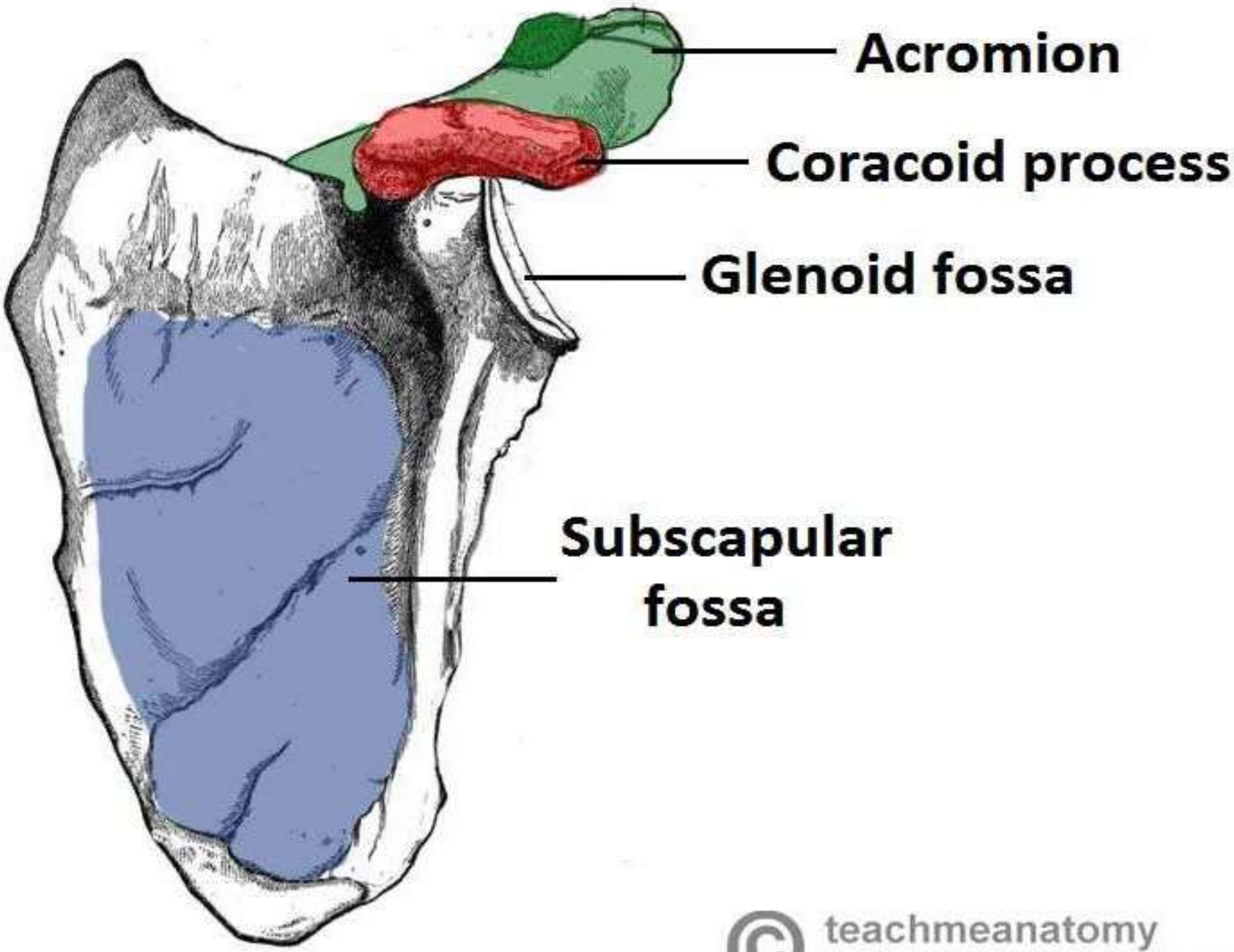

© teachmeanatomy
The #1 Applied Human Anatomy Site on the Web

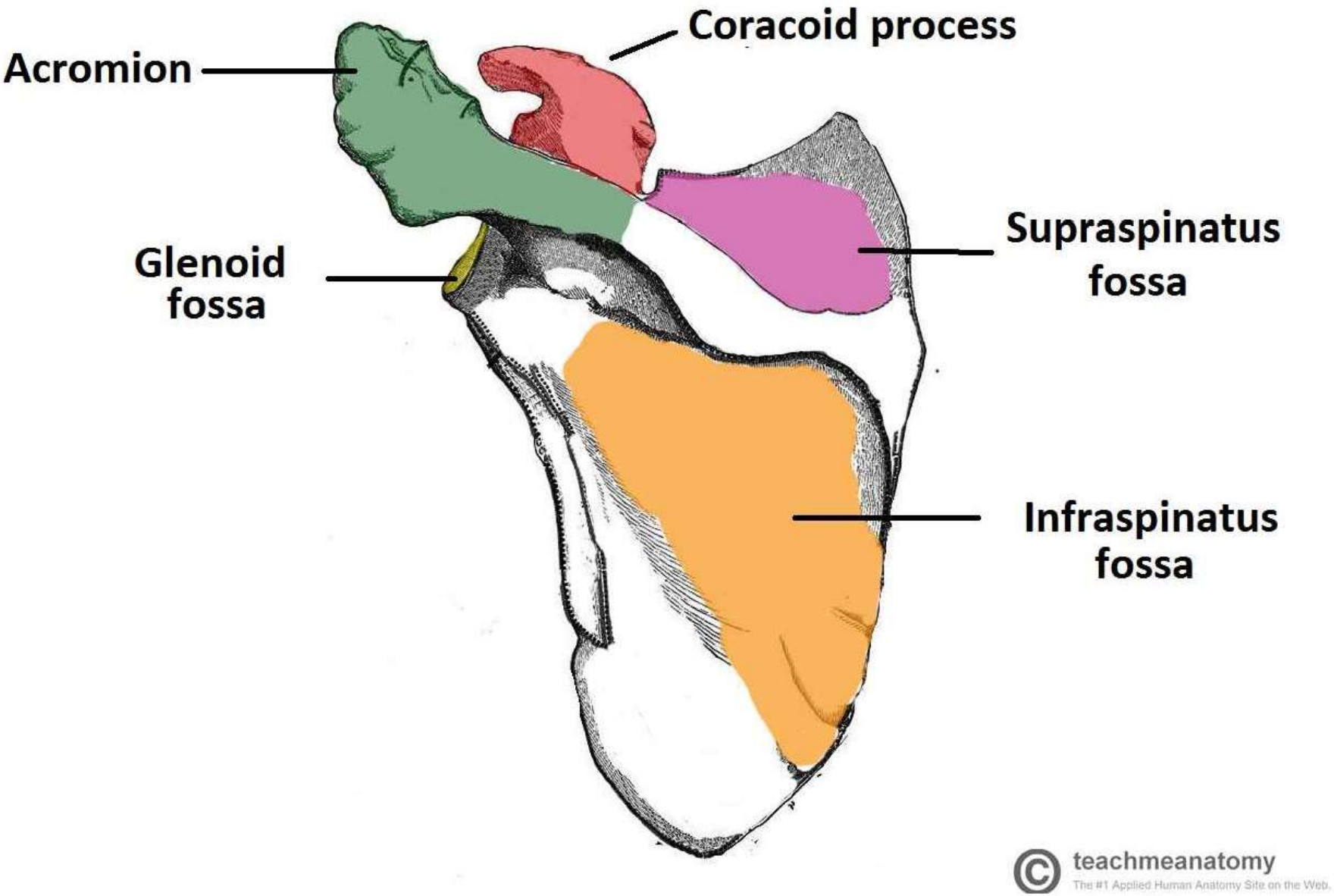
Acromion
Coracoid process
Glenoid fossa
Supraspinatus fossa
Infraspinatus fossa
© teachmeanatomy
The #1 Applied Human Anatomy Site on the Web.

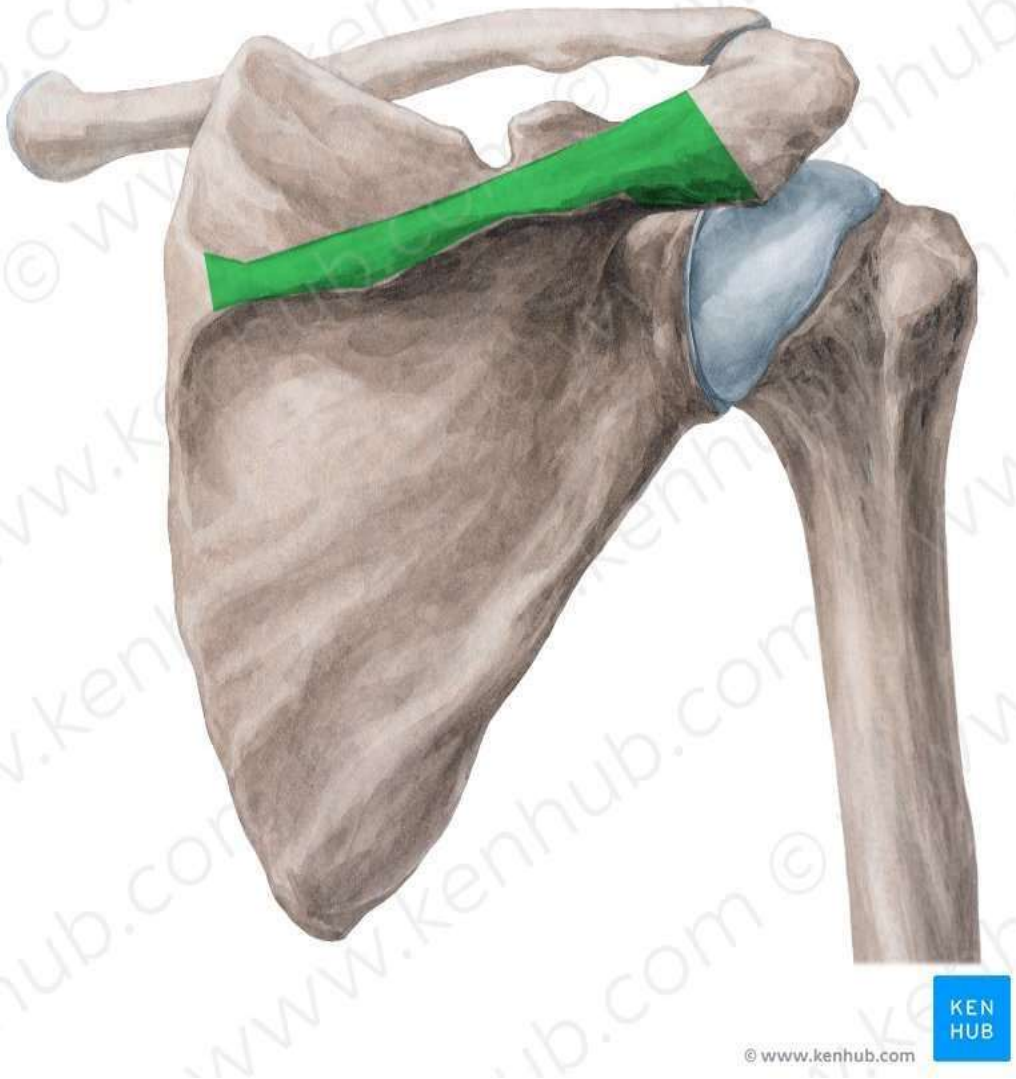

Coracoid process

Spinous process

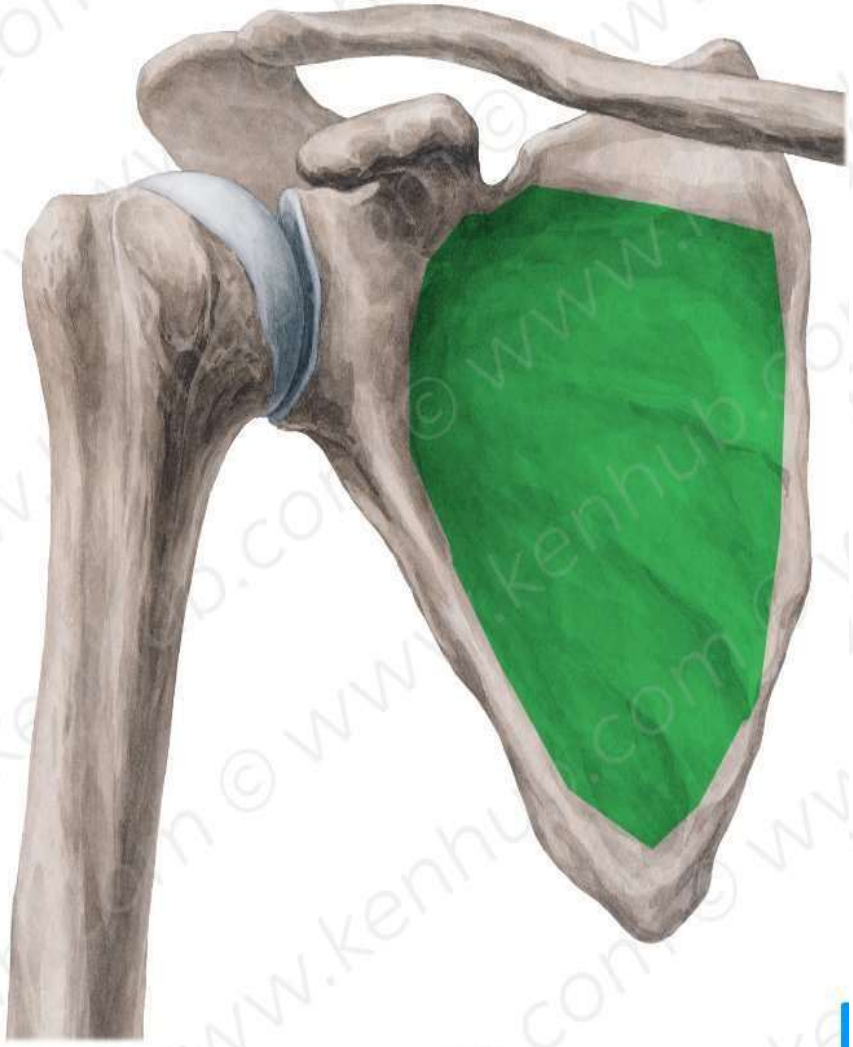

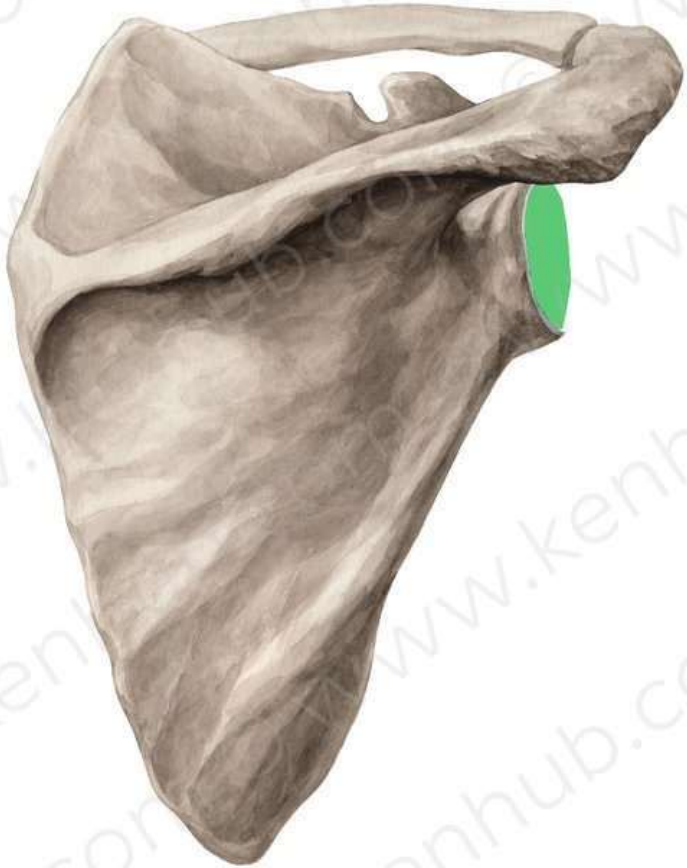

Subscapular fossa

Glenoid cavity

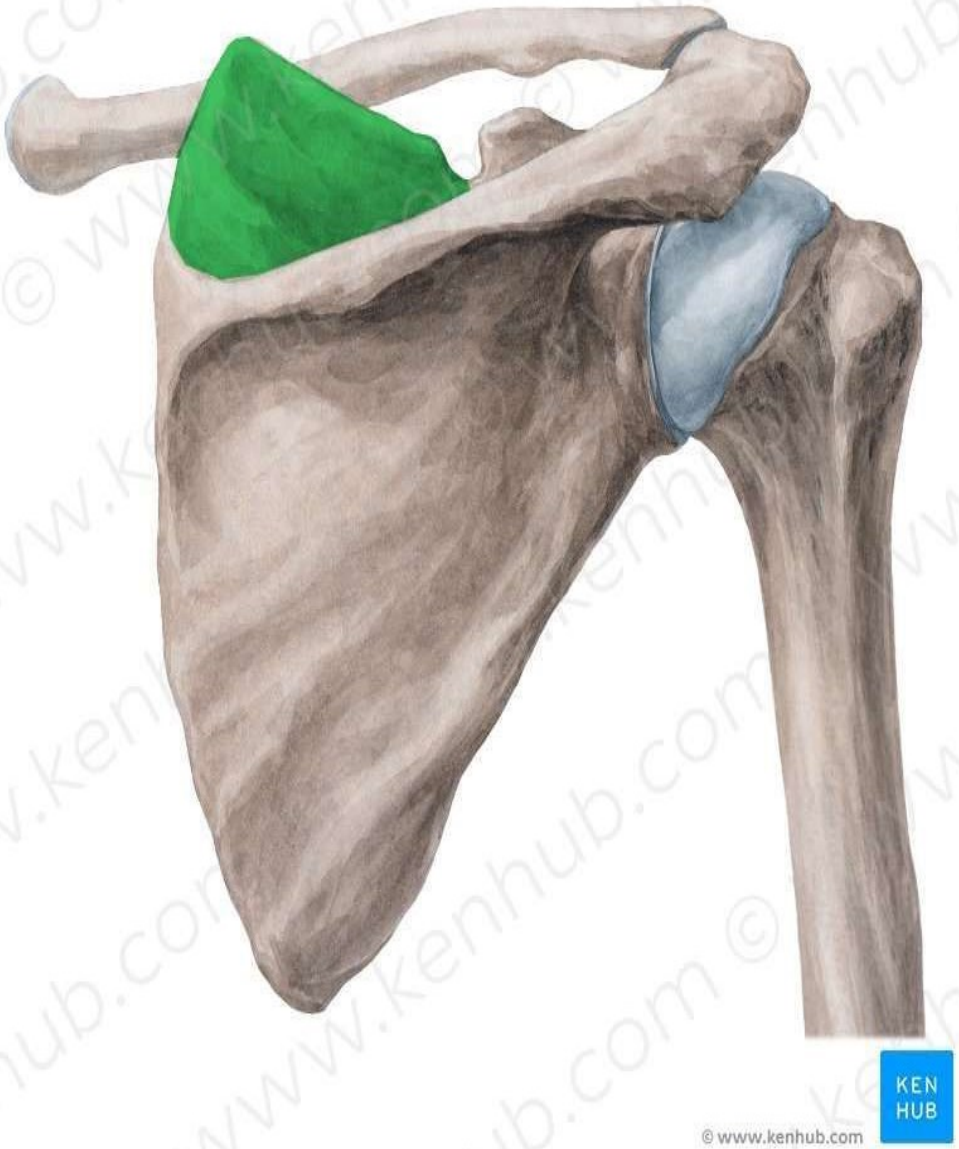

Supraspinous fossa

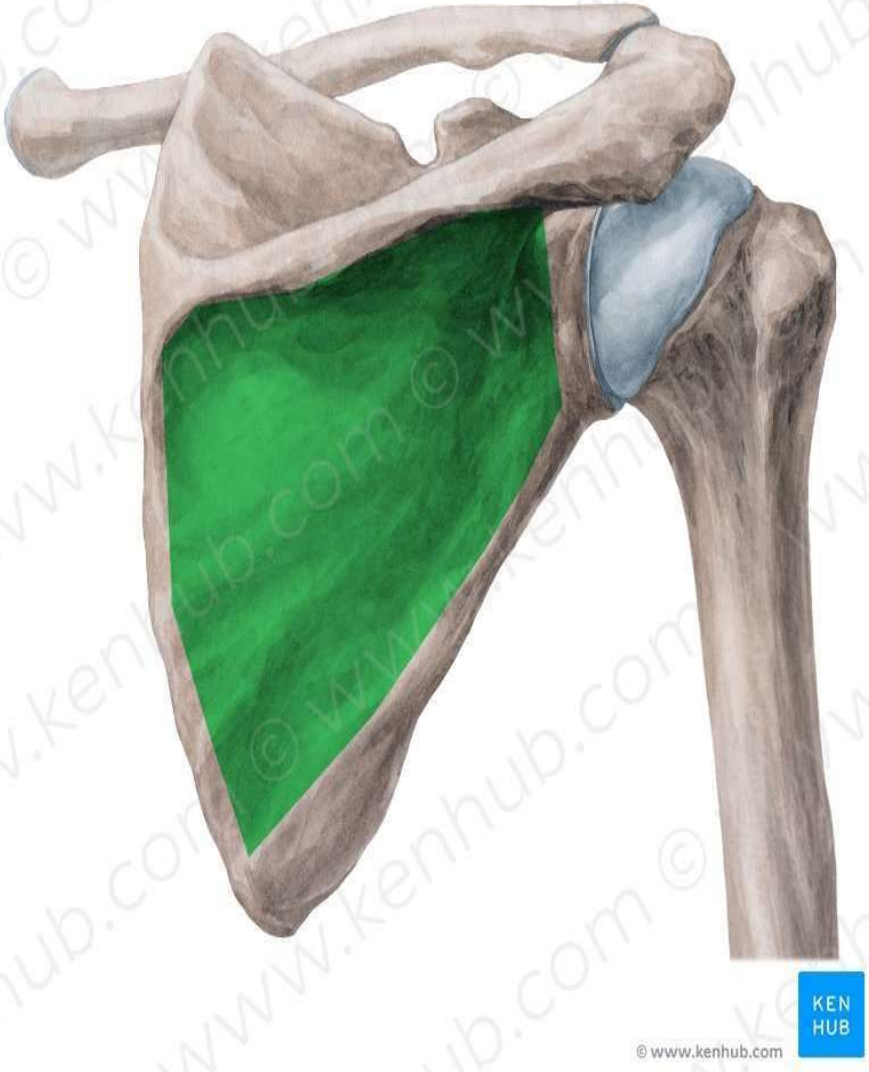

infraspinous fossa

Humerus

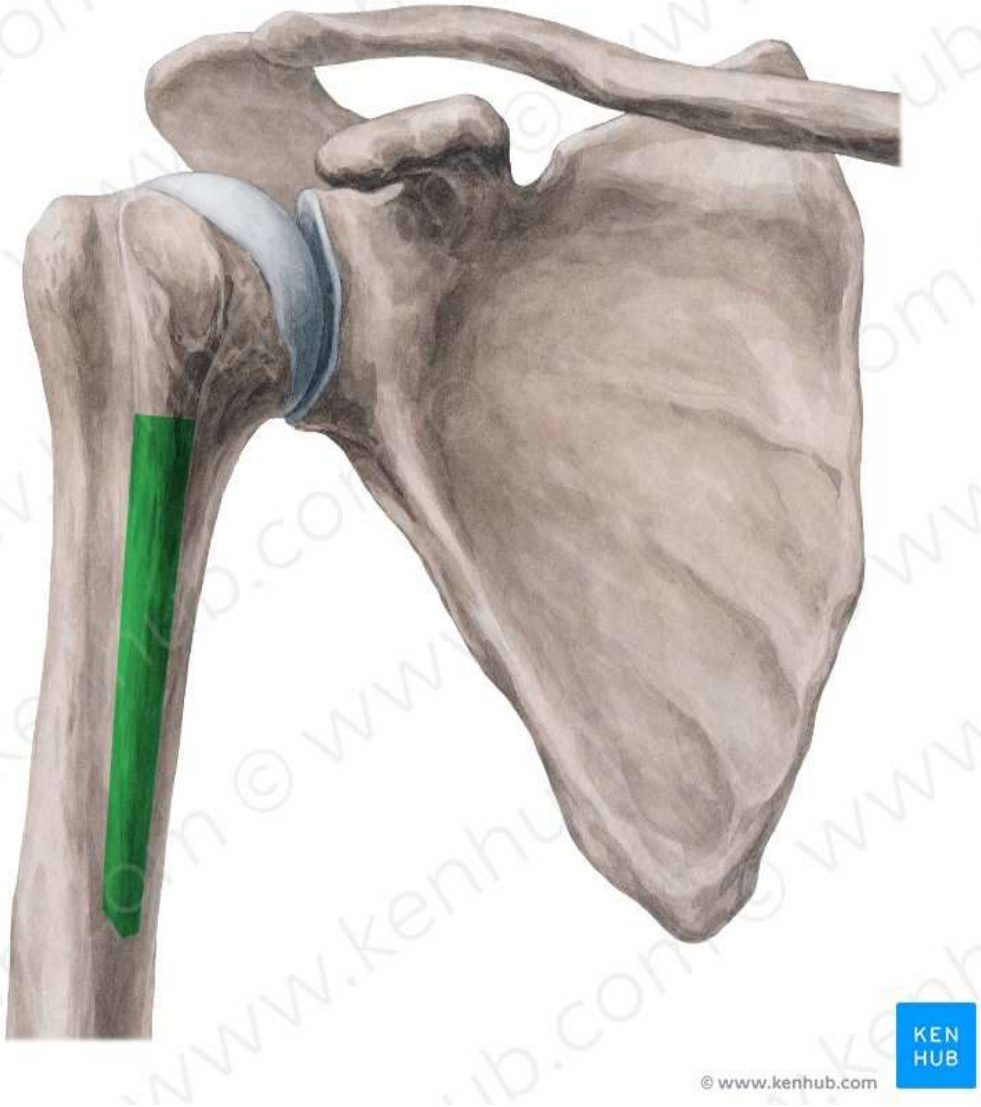

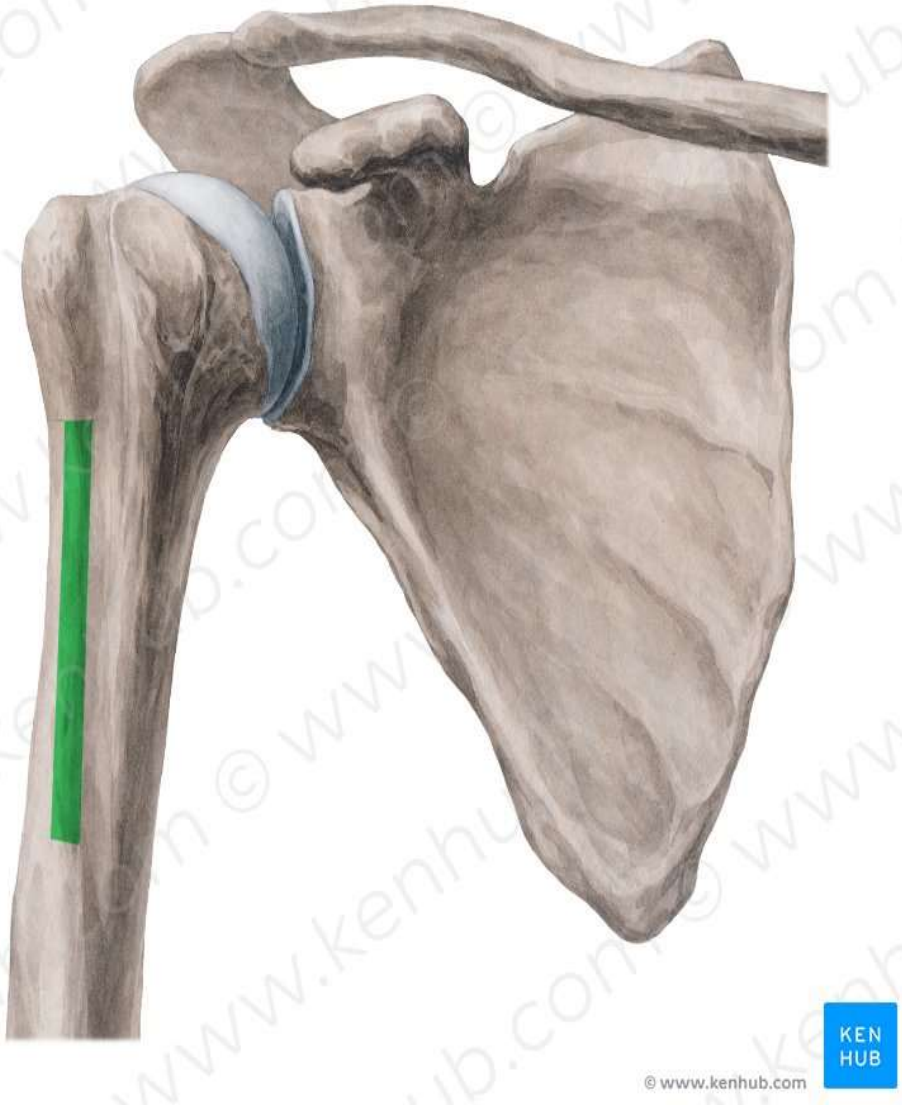

Medial lip of the Bicipital grove

Lateral lip of the Bicipital grove

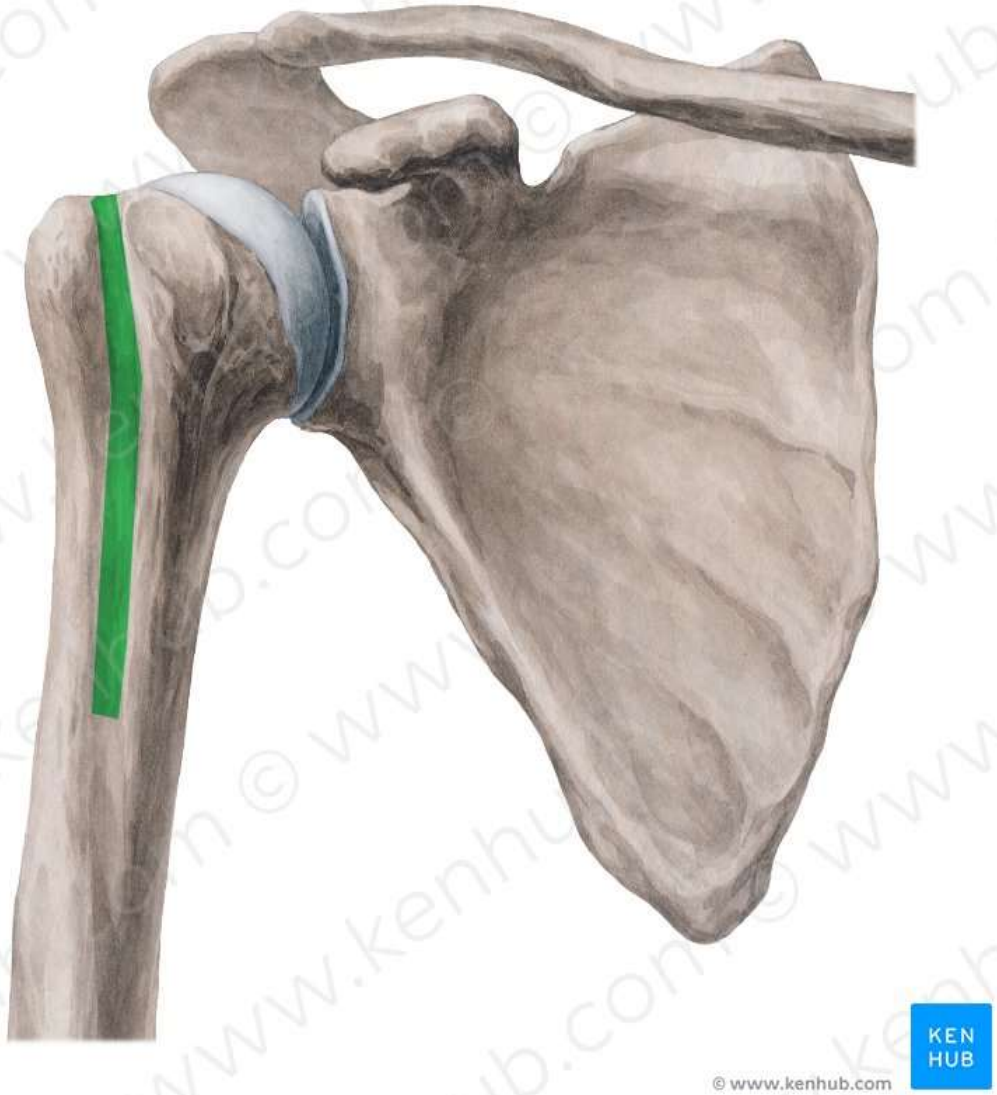

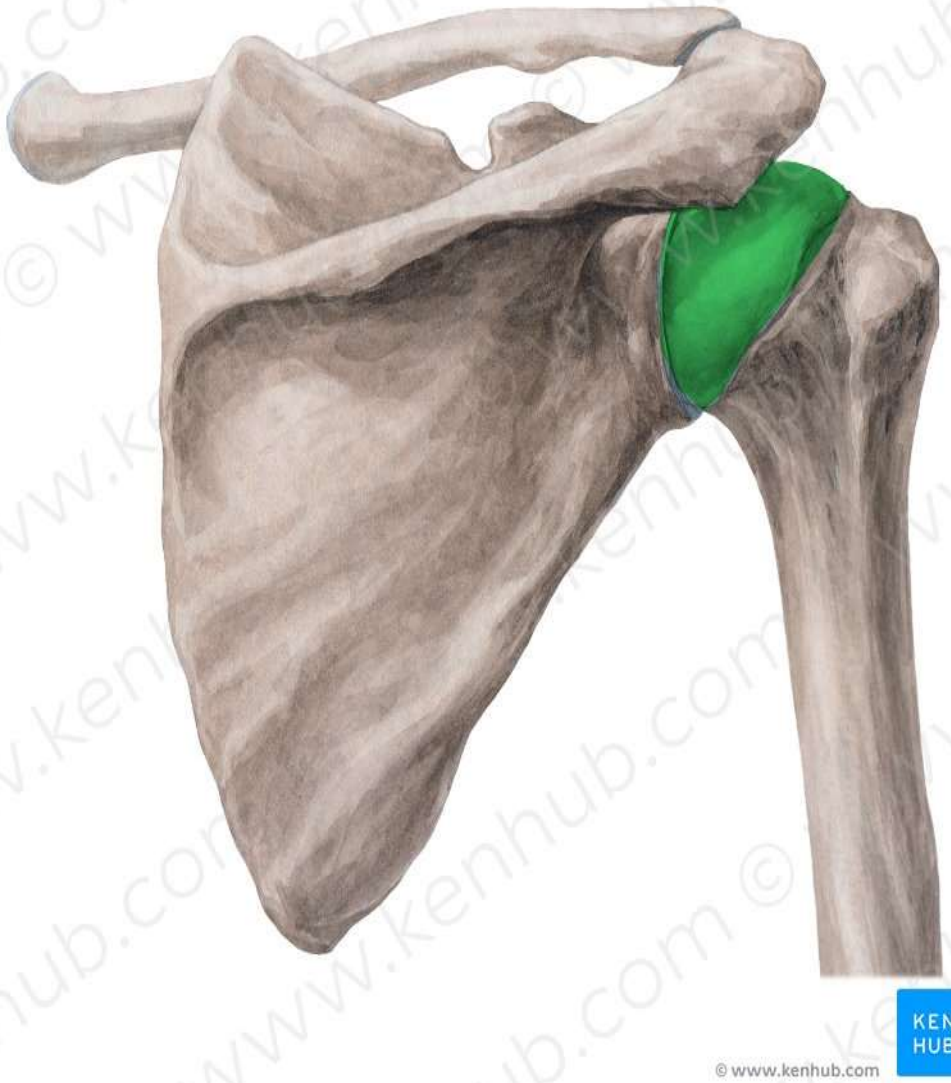

Floor of the Bicipital grove

Head of the Humerus

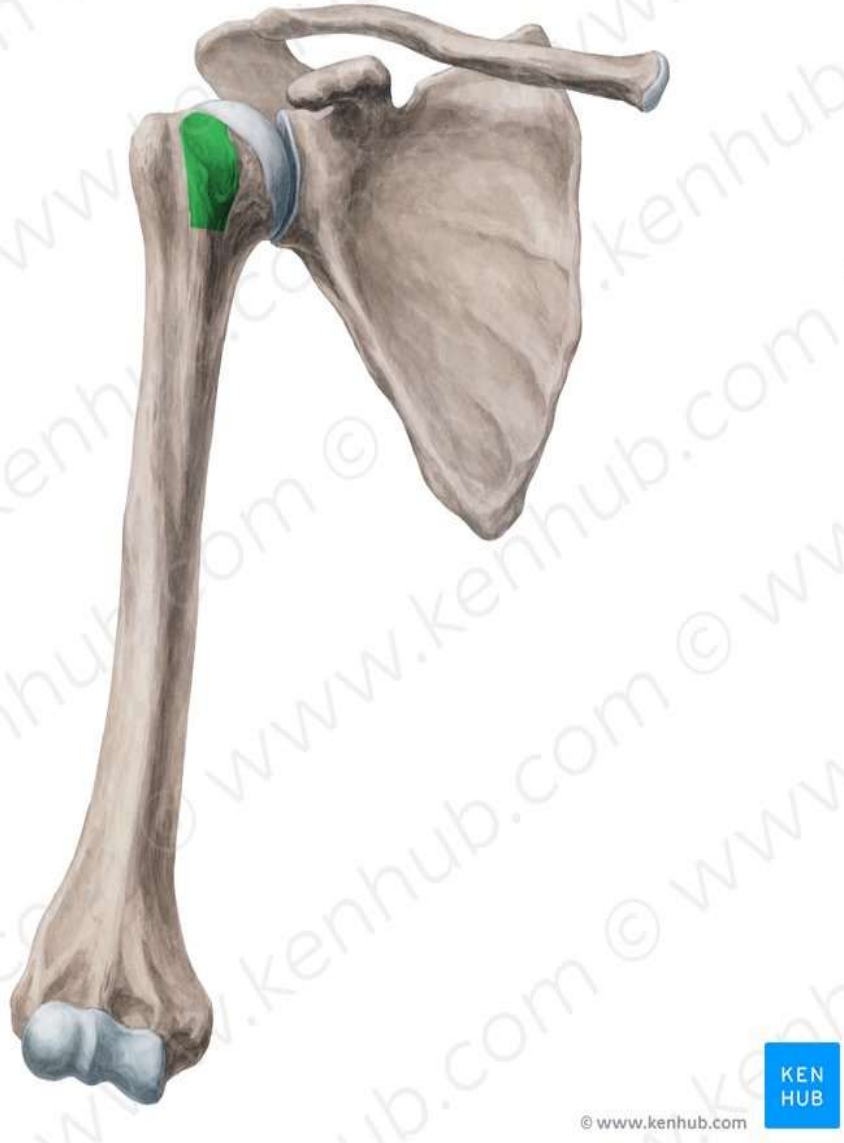

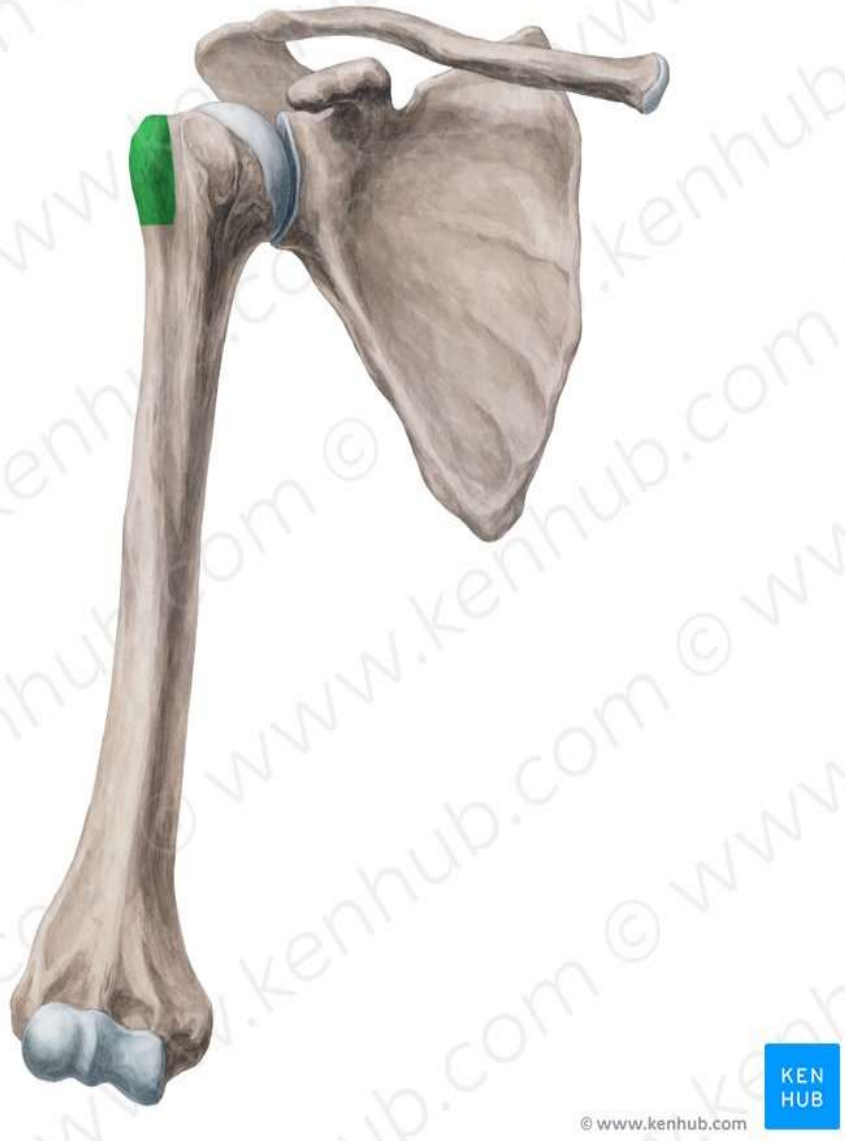

Lesser Tuberosity

Greater Tuberosity

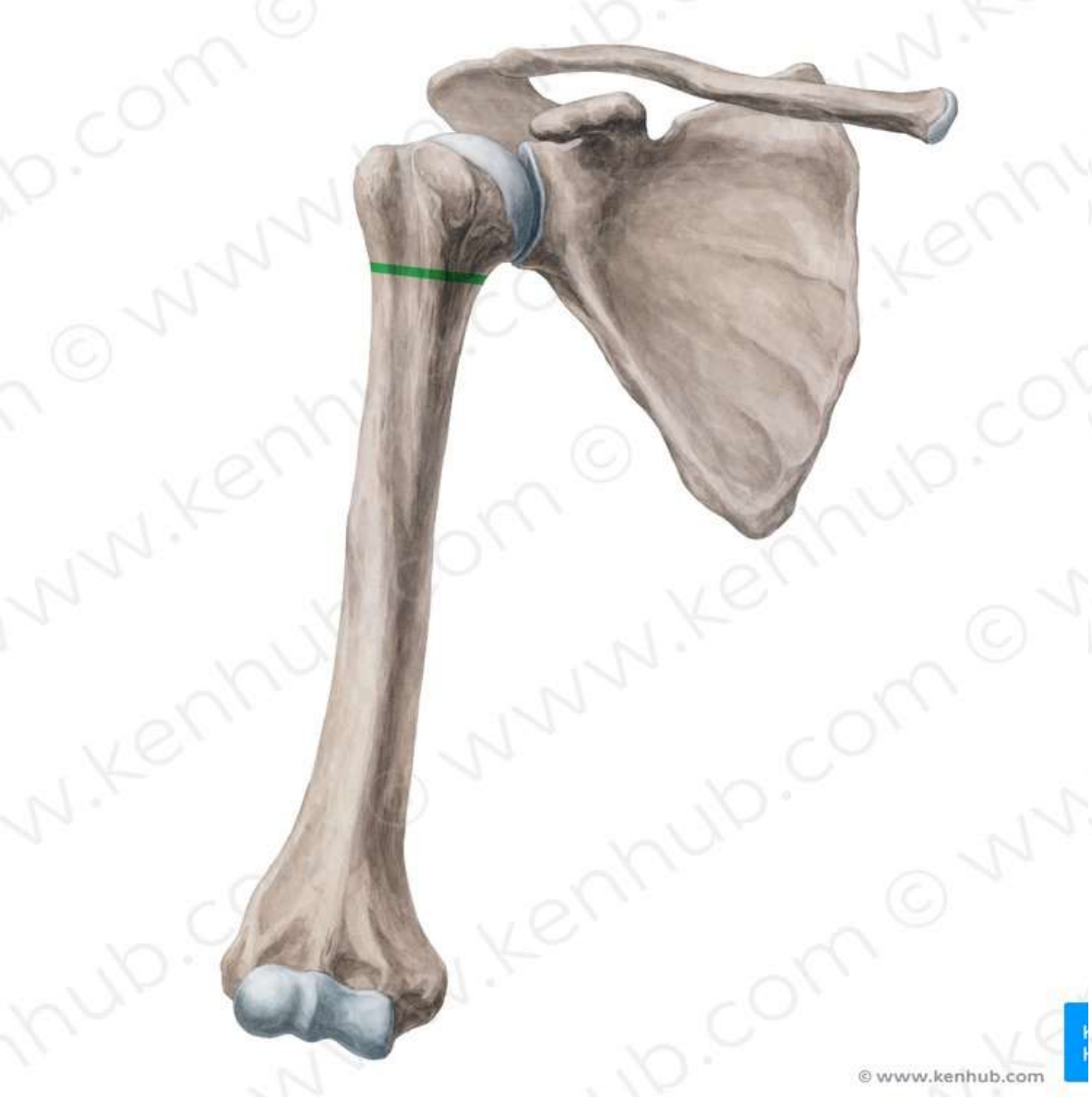

Surgical Neck of the Humerus

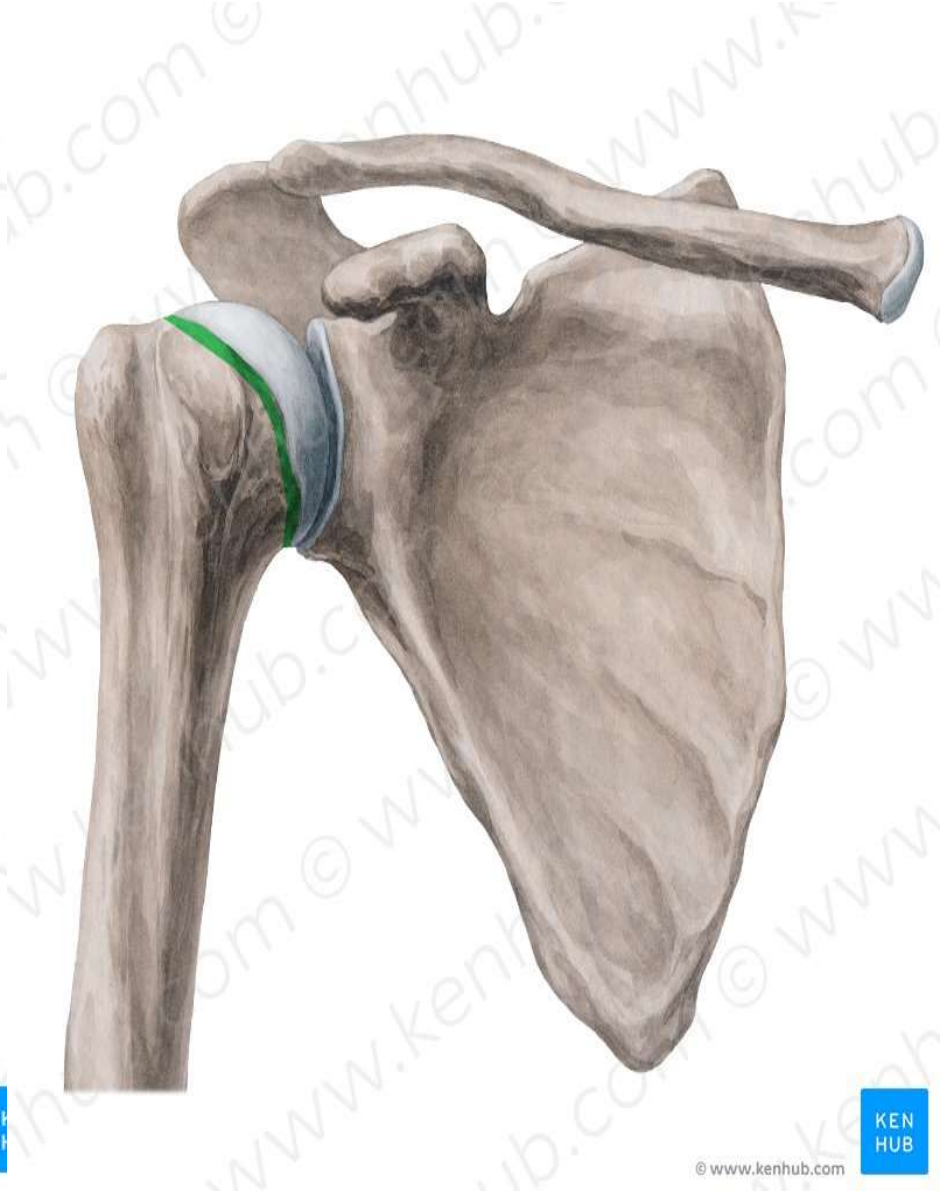

Anatomical Neck of the Humerus

trochlea

capitulum

olecranon fossa

radial fossa

© www.kenhub.com

coronoid fossa

Medial epicondyle

lateral epicondyle

Ulna and Radius

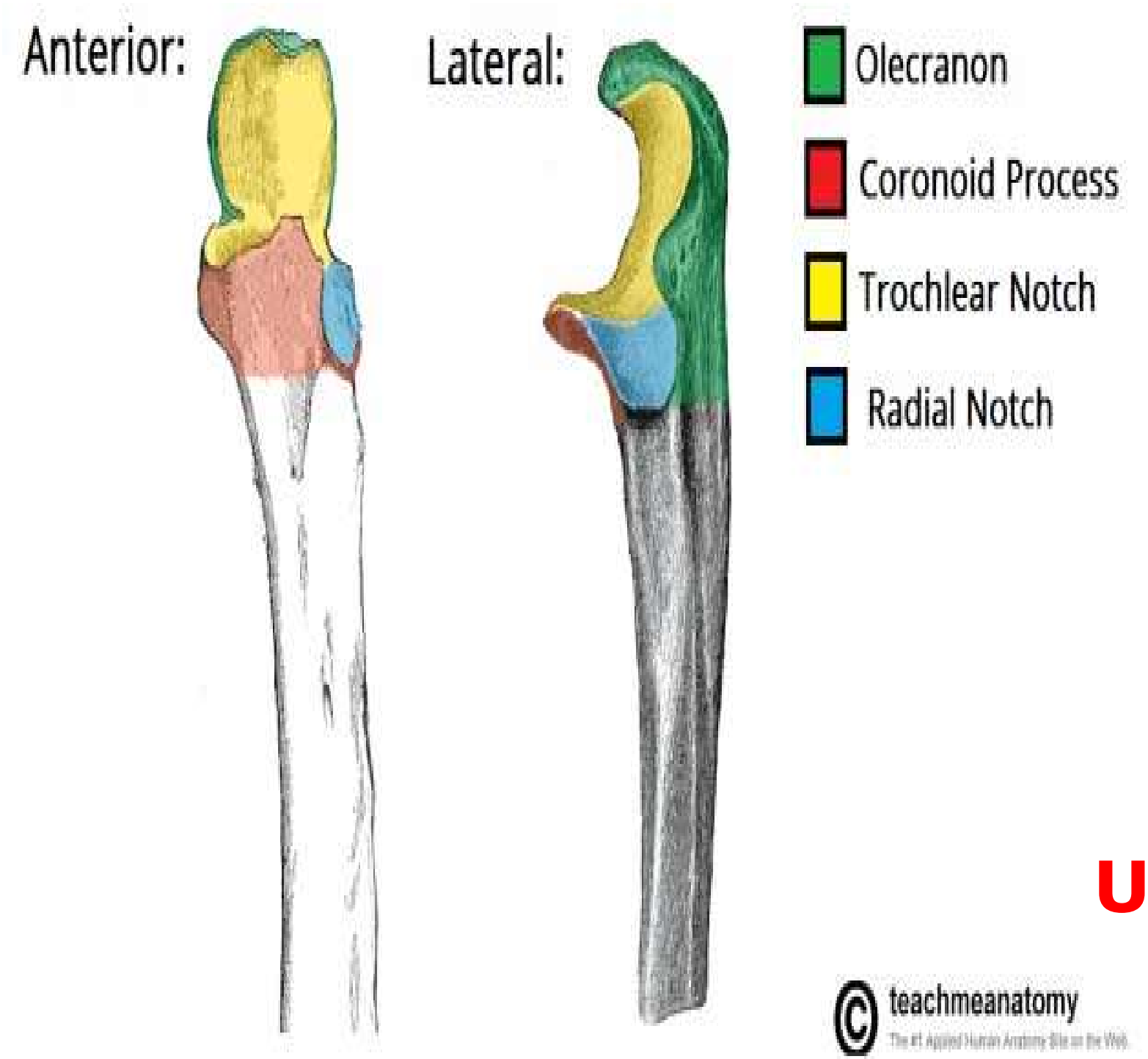
Anterior:
Lateral:
Olecranon
Coronoid Process
Trochlear Notch
Radial Notch
teachmeanatomy

Ulna

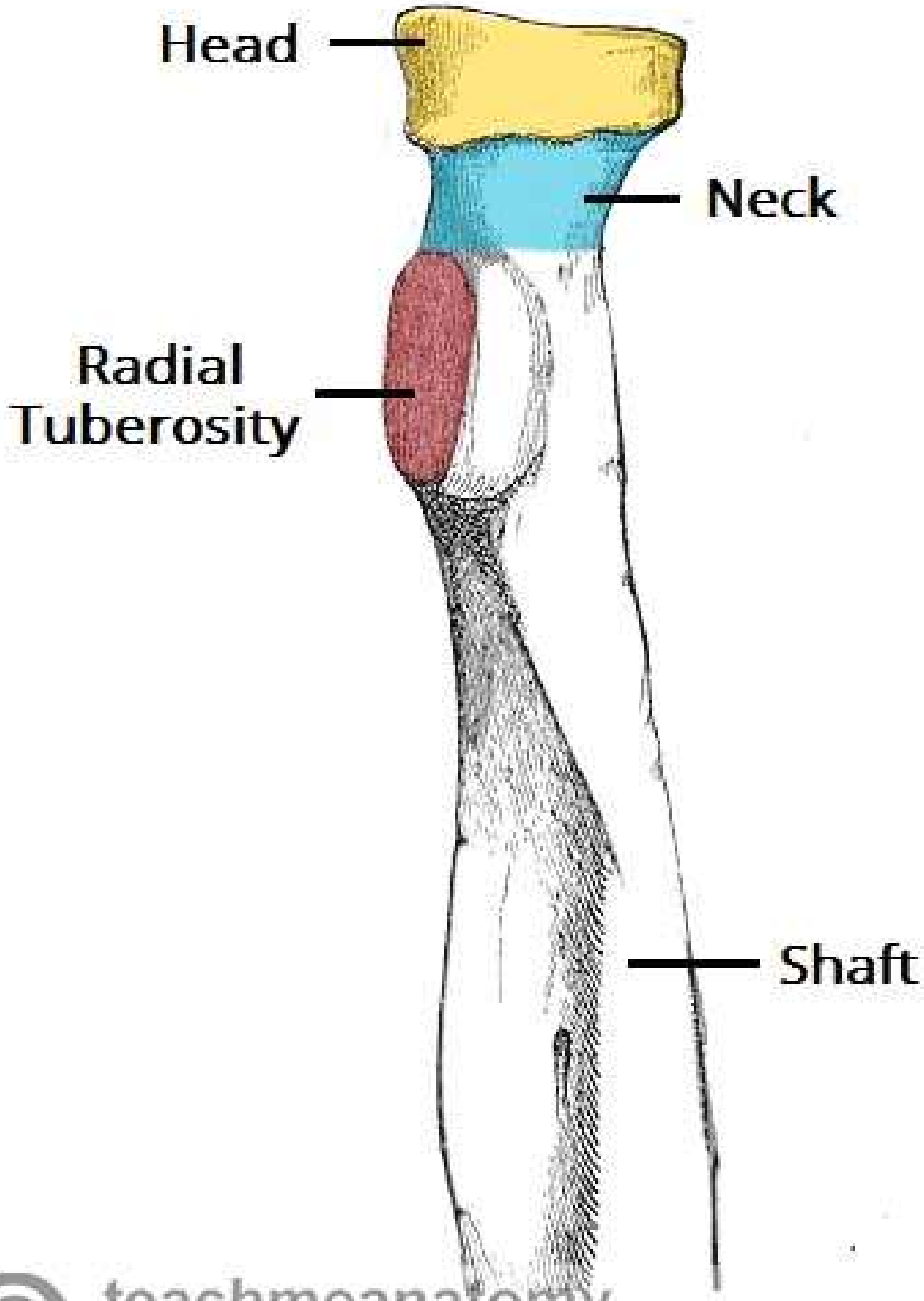

Radius

© teachmeanatomy
The #1 Applied Human Anatomy Site on the Web.

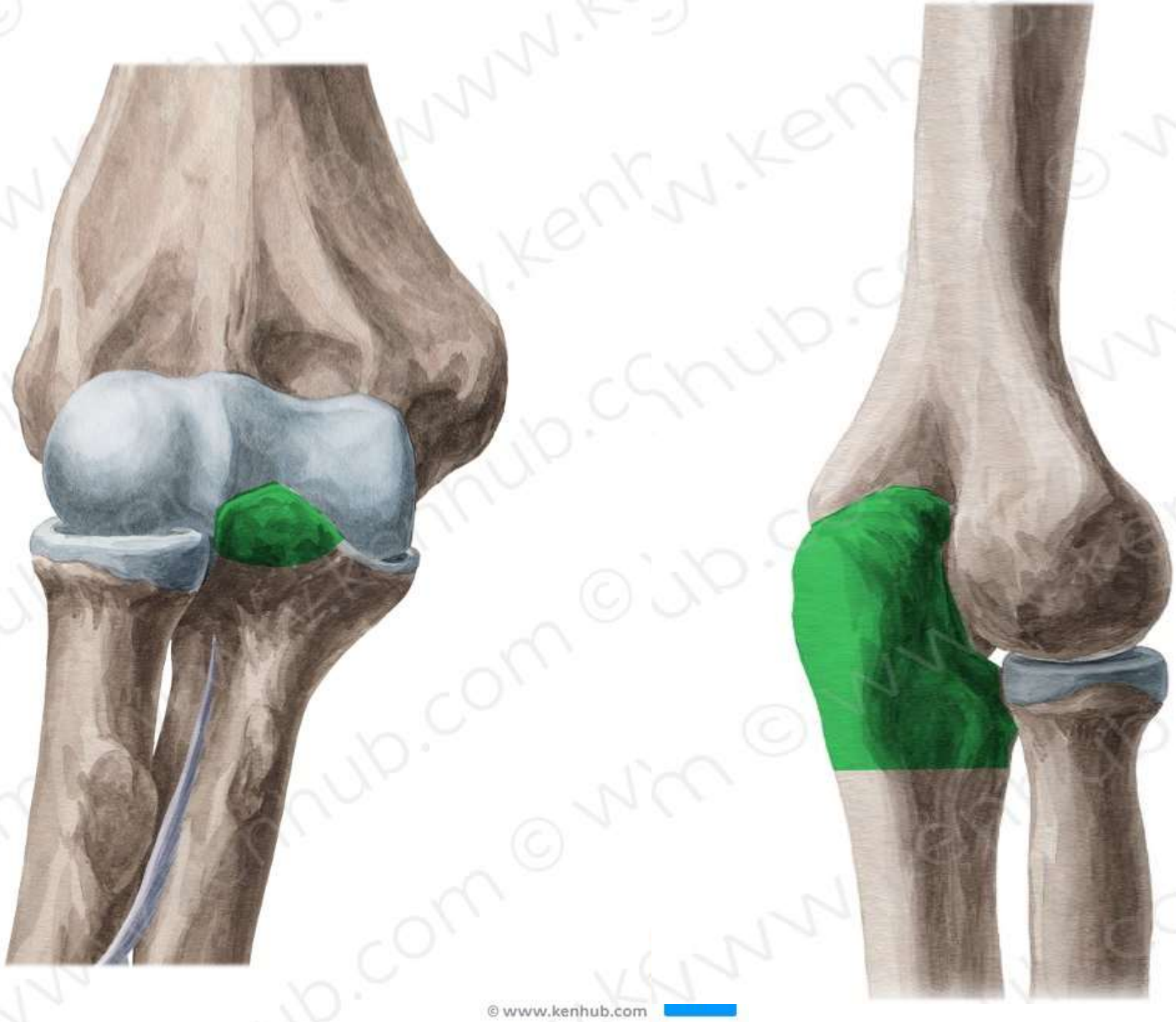

Olecranon process

Coronoid process of the ulna

Head of the Ulna

Styloid process of the Ulna

Head of the radius

Neck of the radius

Radial Tuberosity

styloid process of the radius

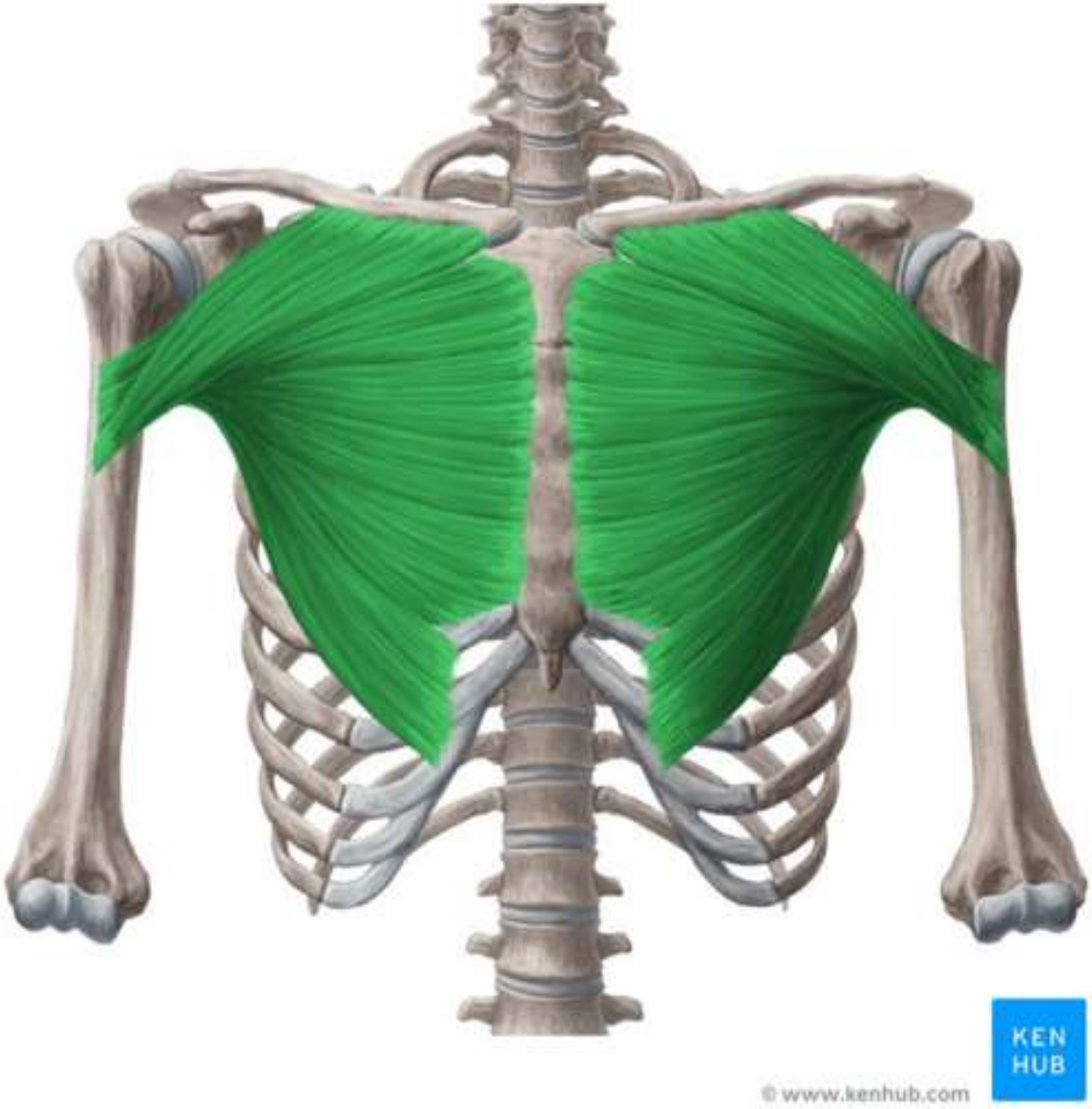

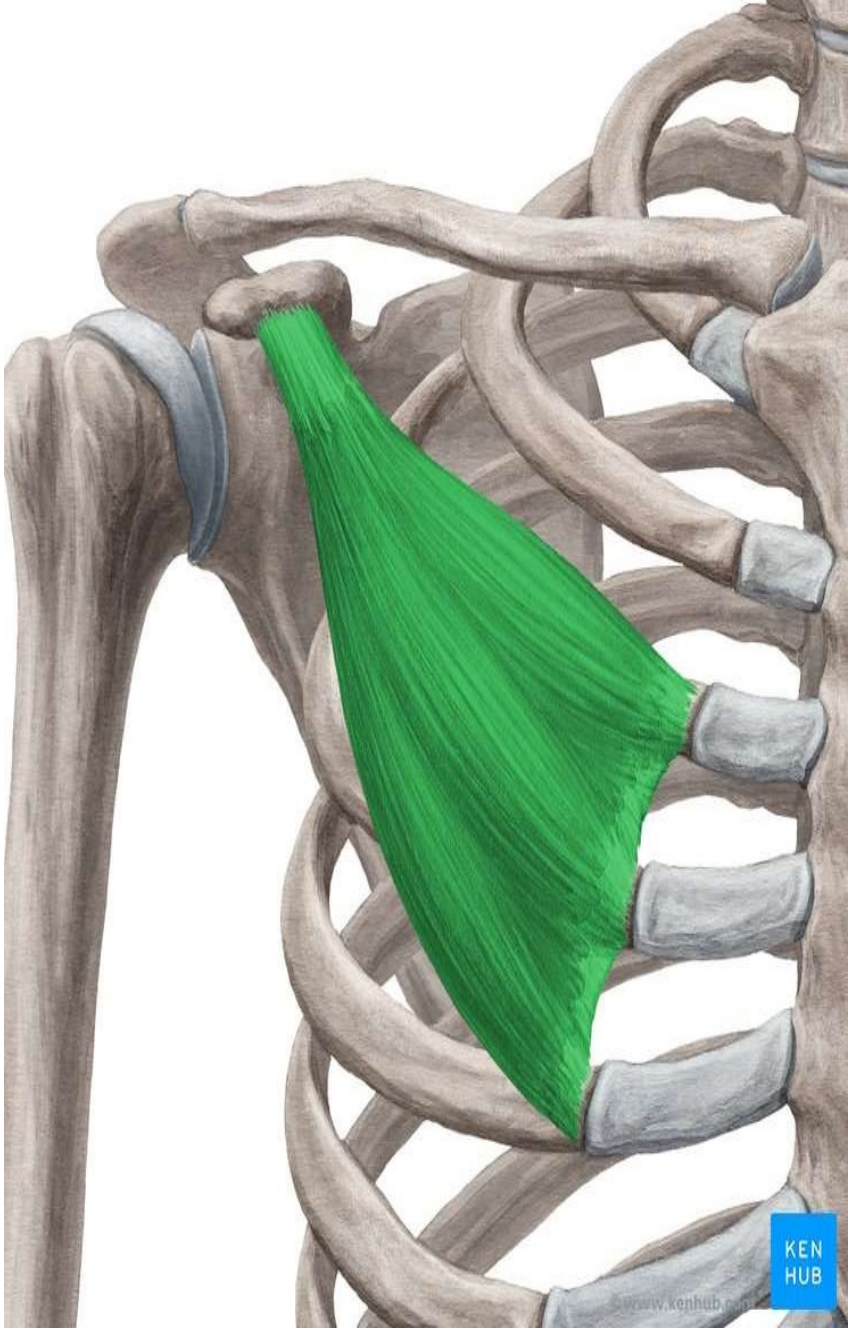

Pectoralis Minor

Pectoralis Major

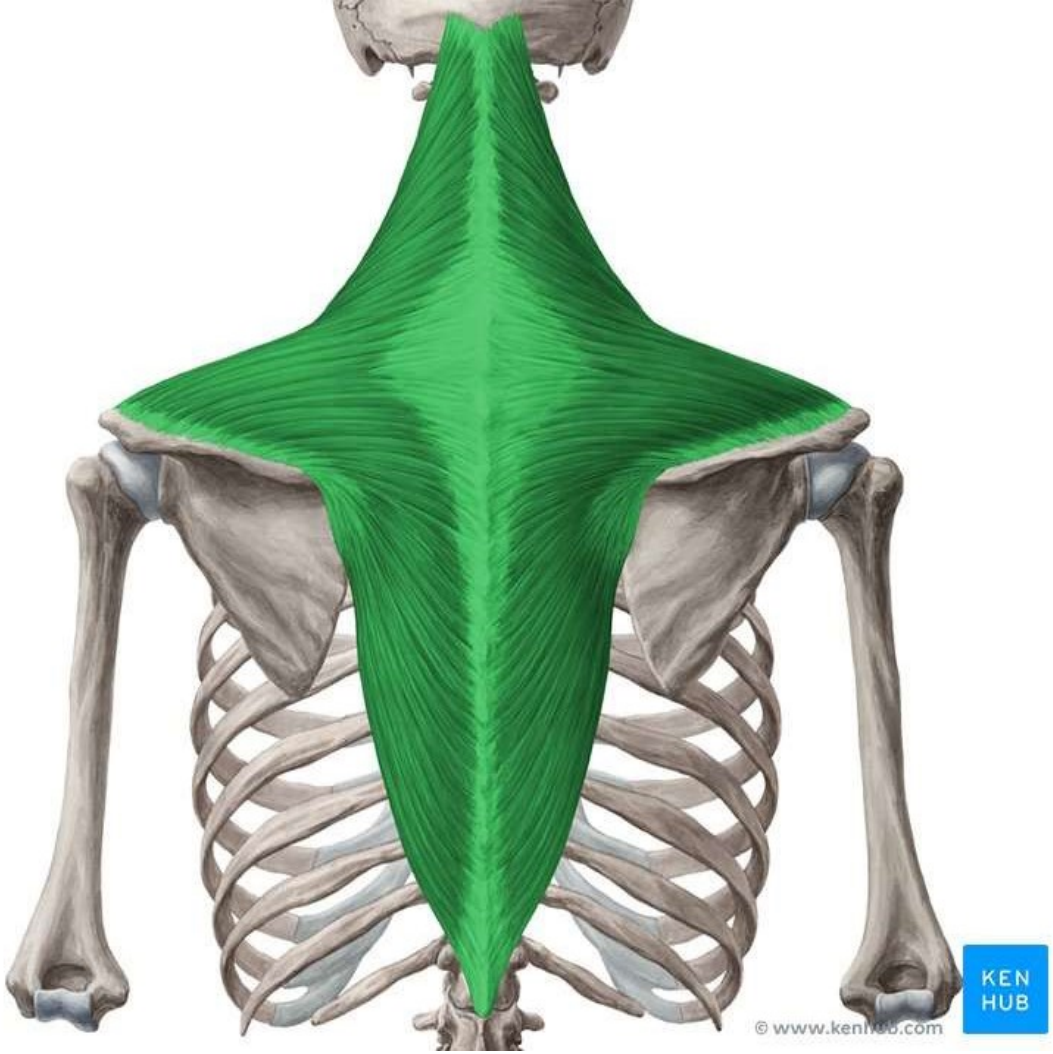

Trapezius

Serratus Anterior

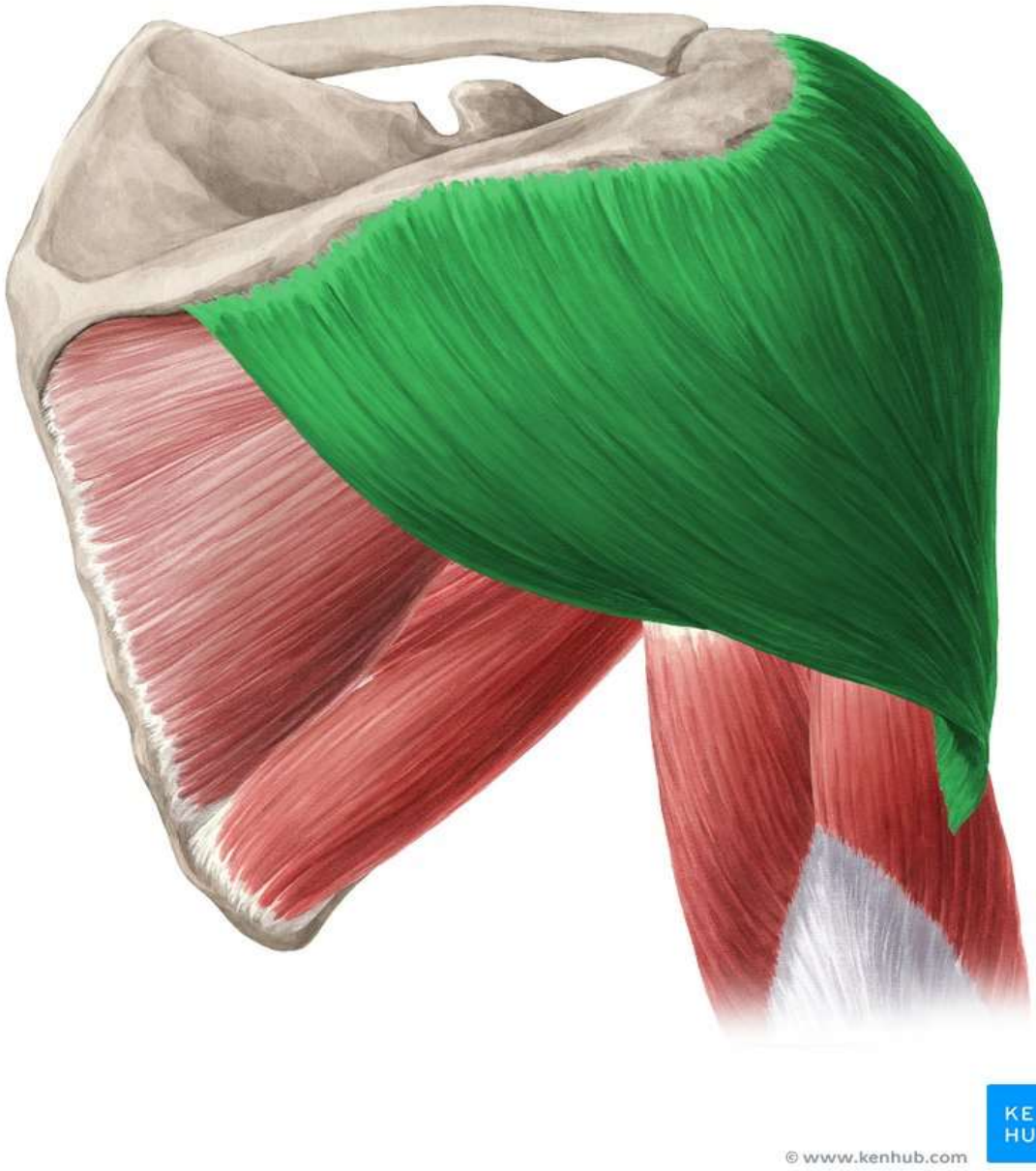

Latissimus dorsi

Deltoid (Green one)

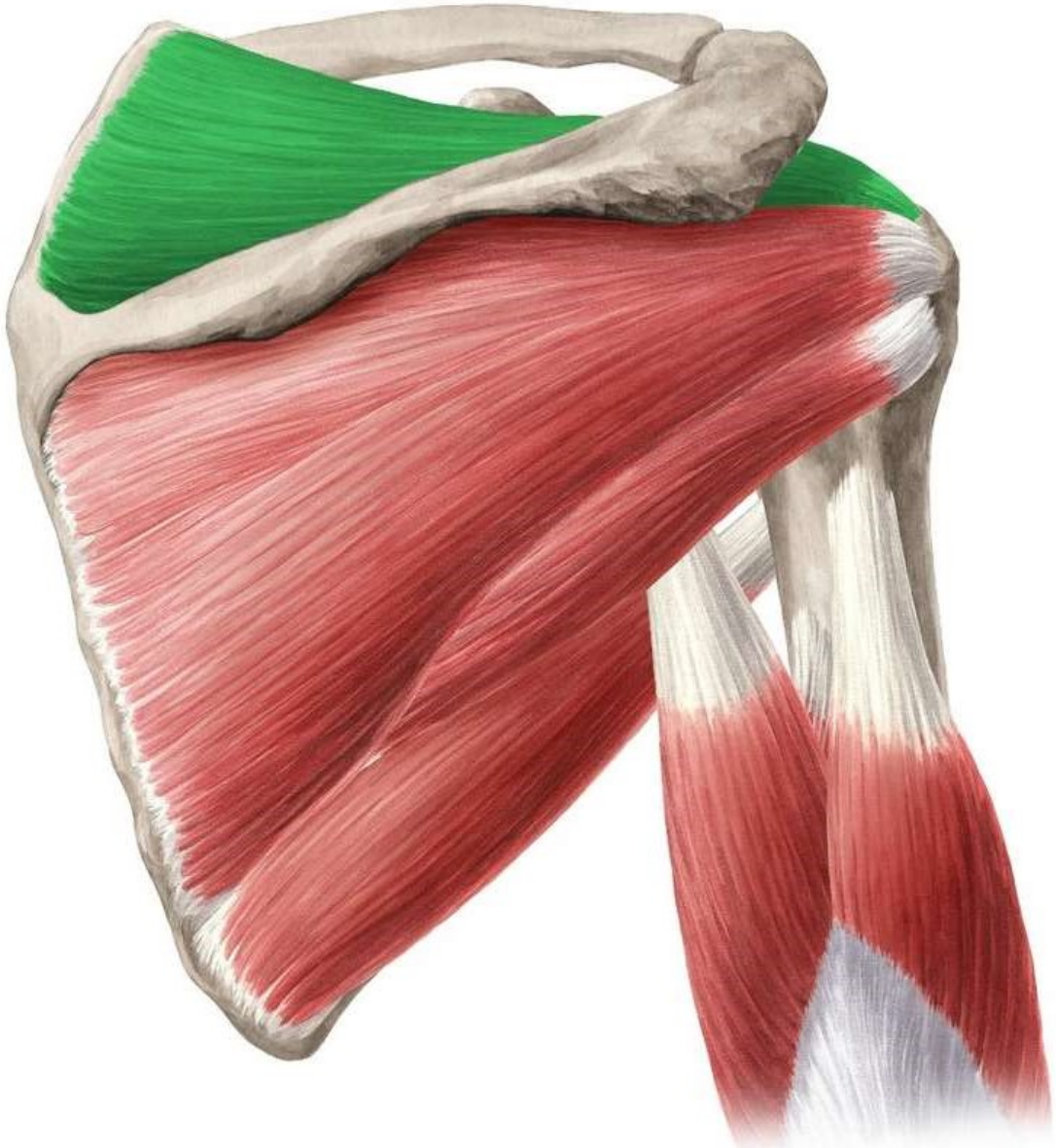

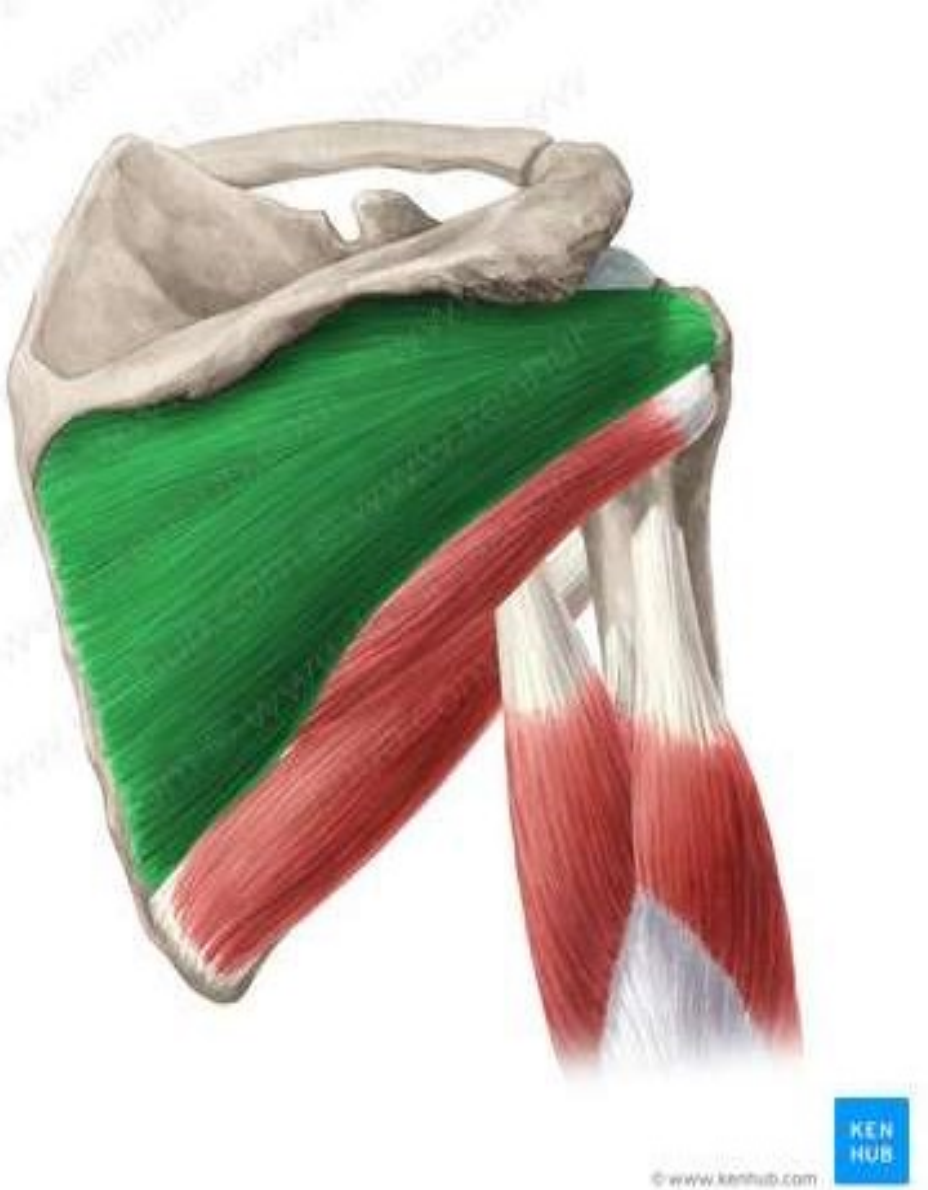

Infraspinatus (Green one)

Supraspinatus (Green one)

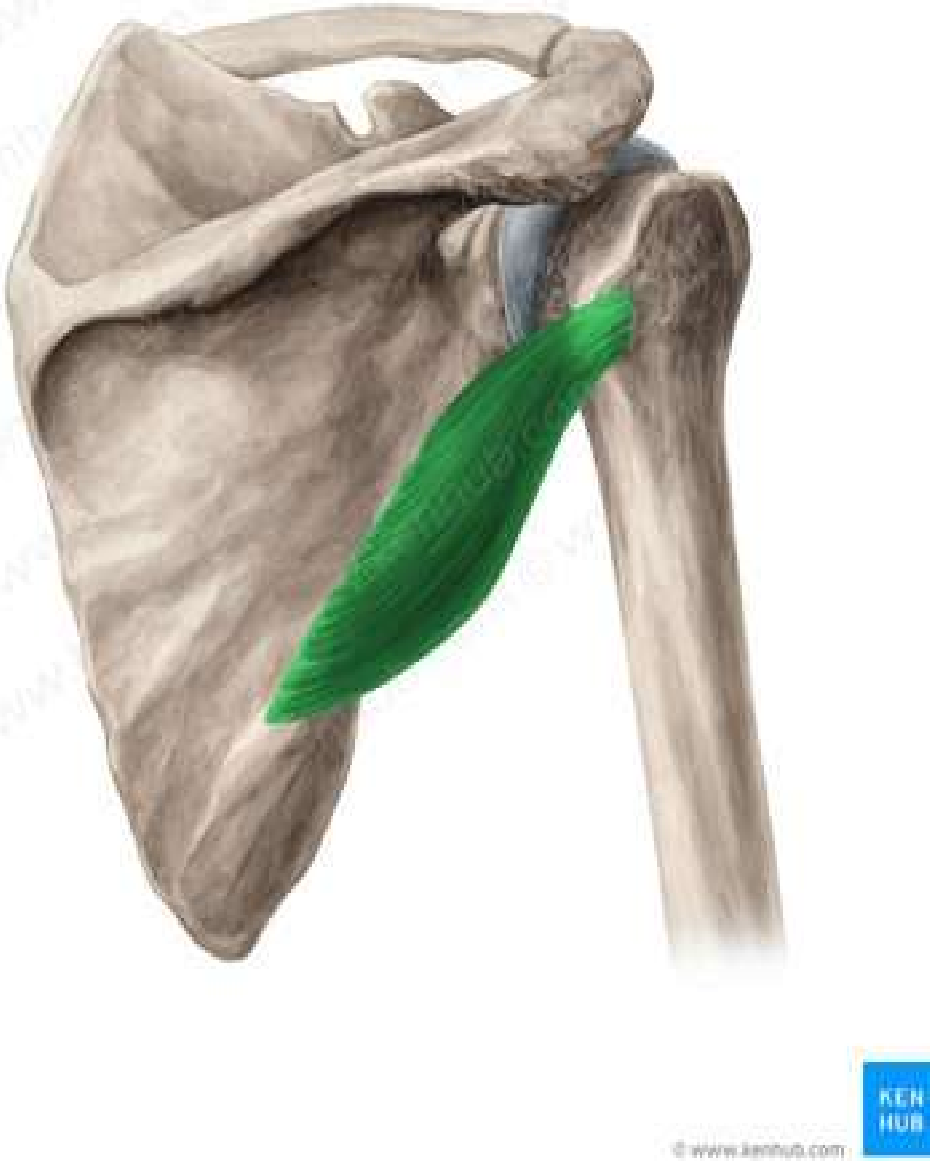

Teres minor

Teres major

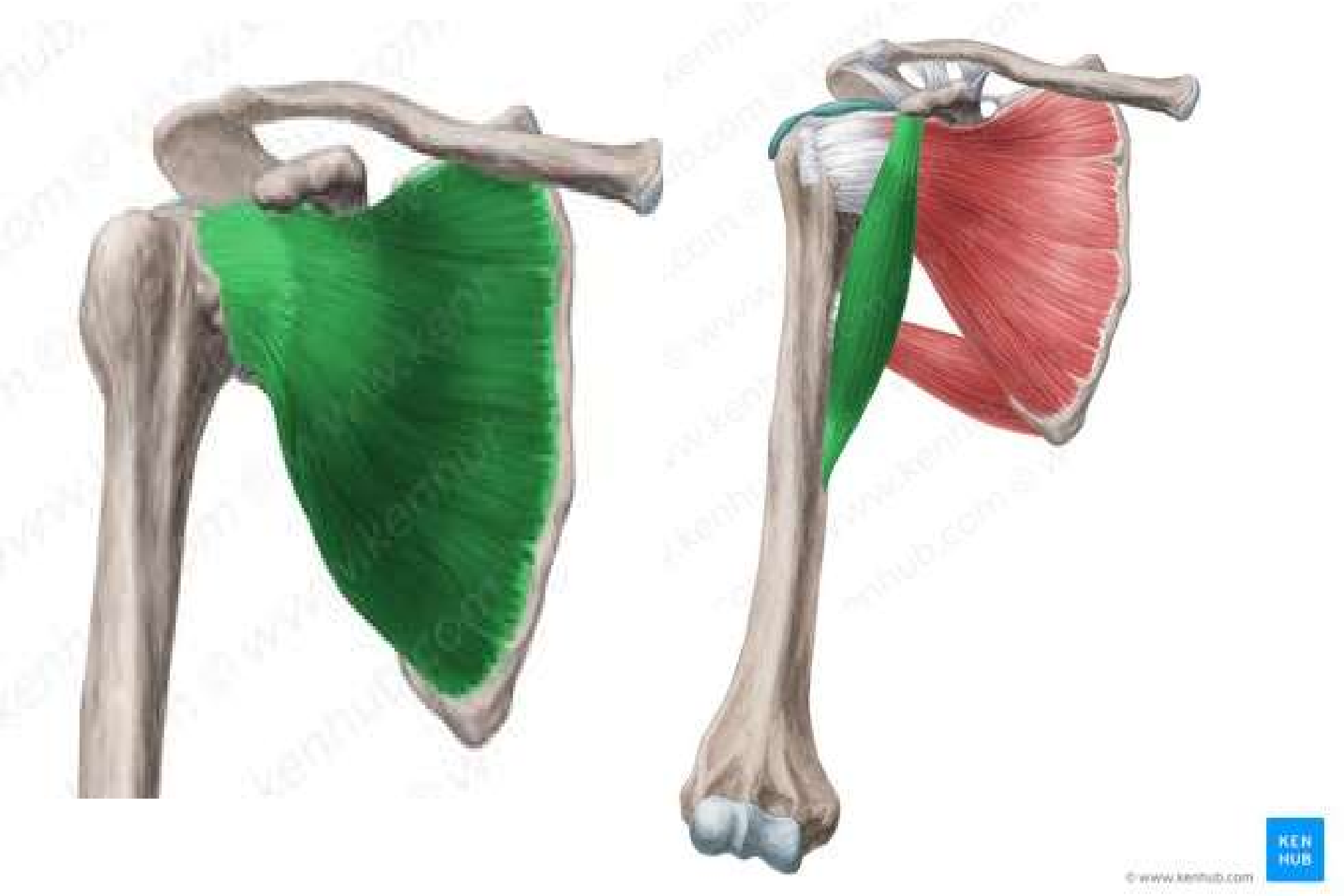

Subscapularis

Coracobrachialis (Green one)

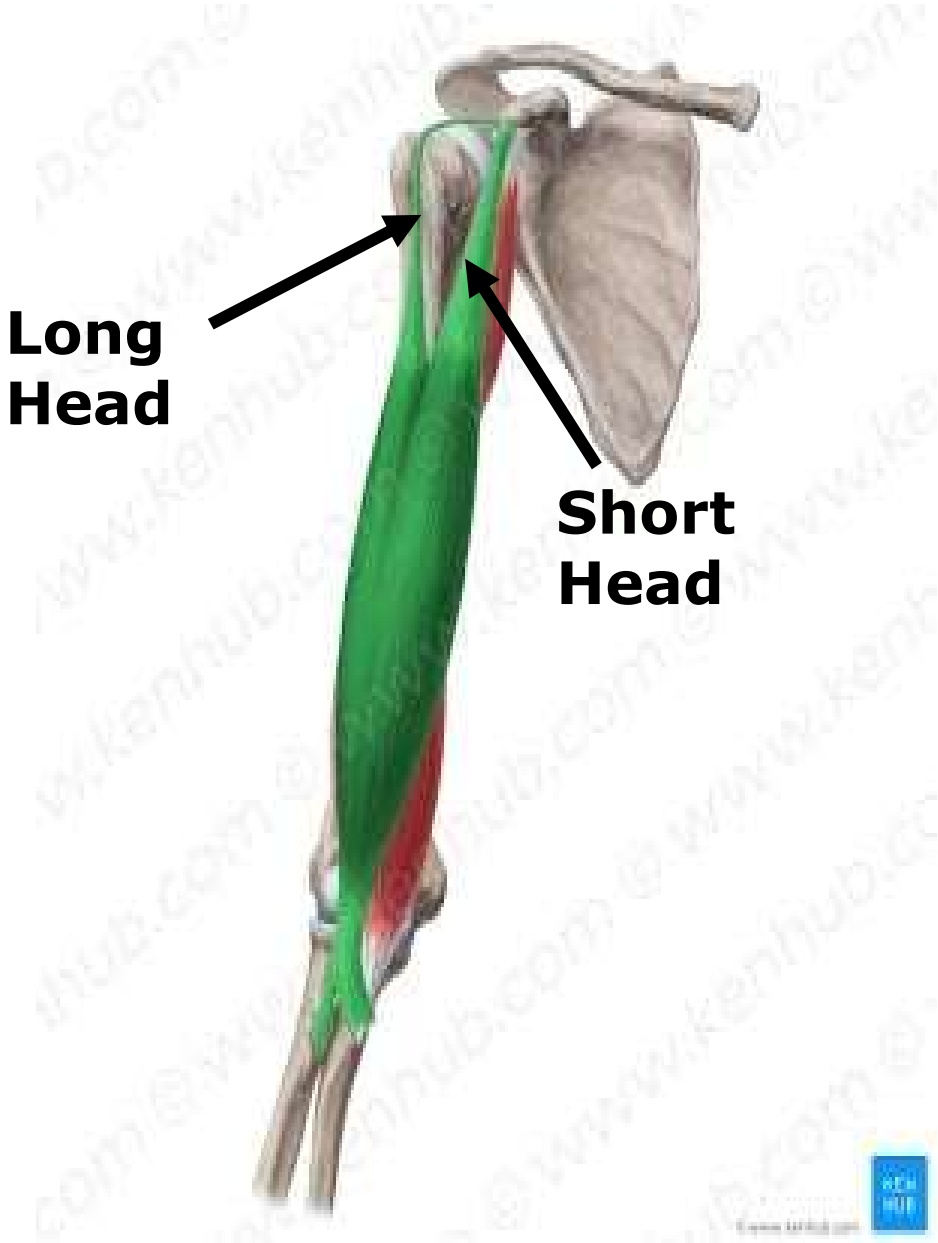

Biceps brachii (Green one)

Brachialis

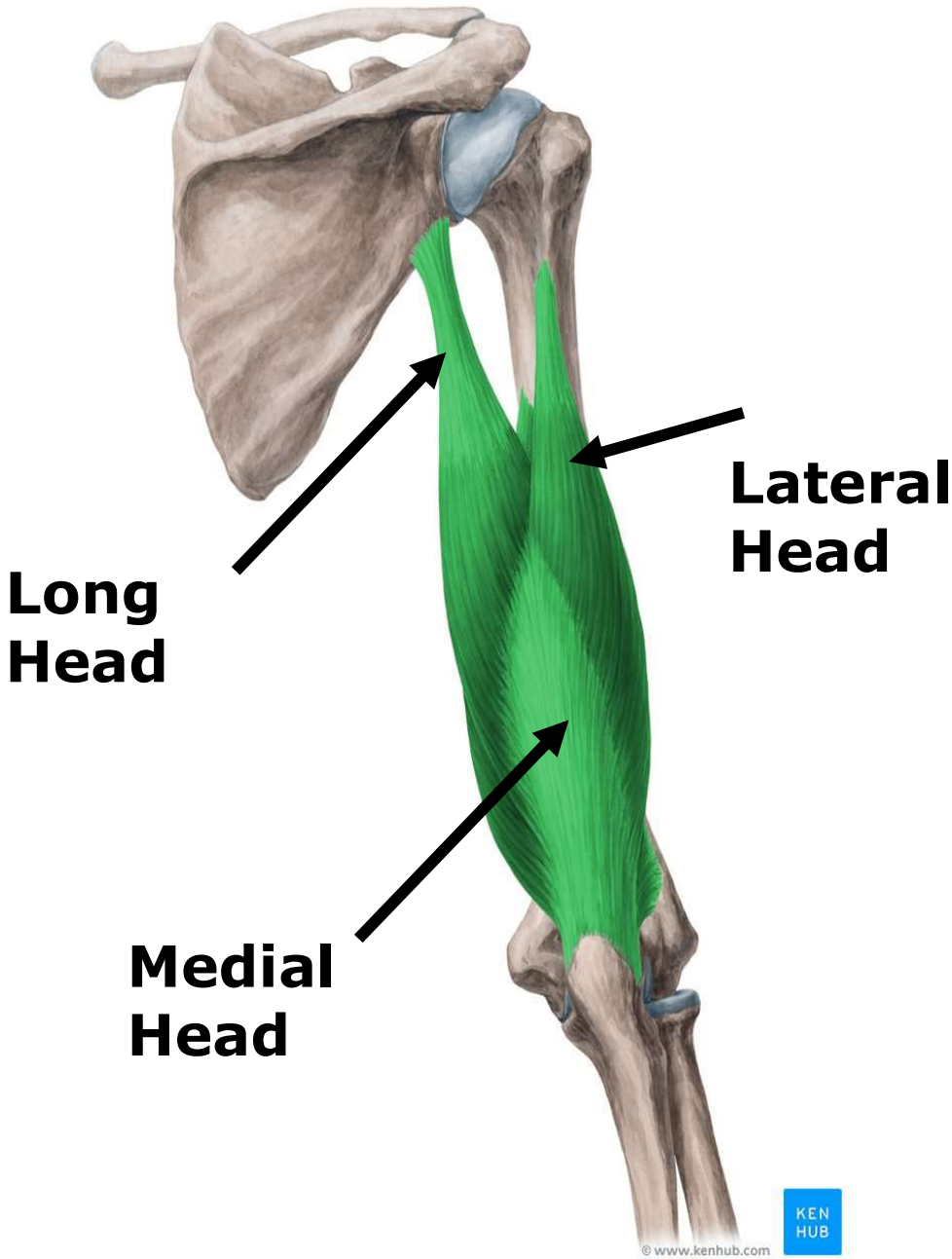

Triceps brachii

Pronator teres

Flexor carpi radialis
(Green one)

Plmaris longus
(Green one)

Flexor carpi ulnaris

Flexor digitorum Profundus

Flexor pollicis longus

Pronator Qudratus

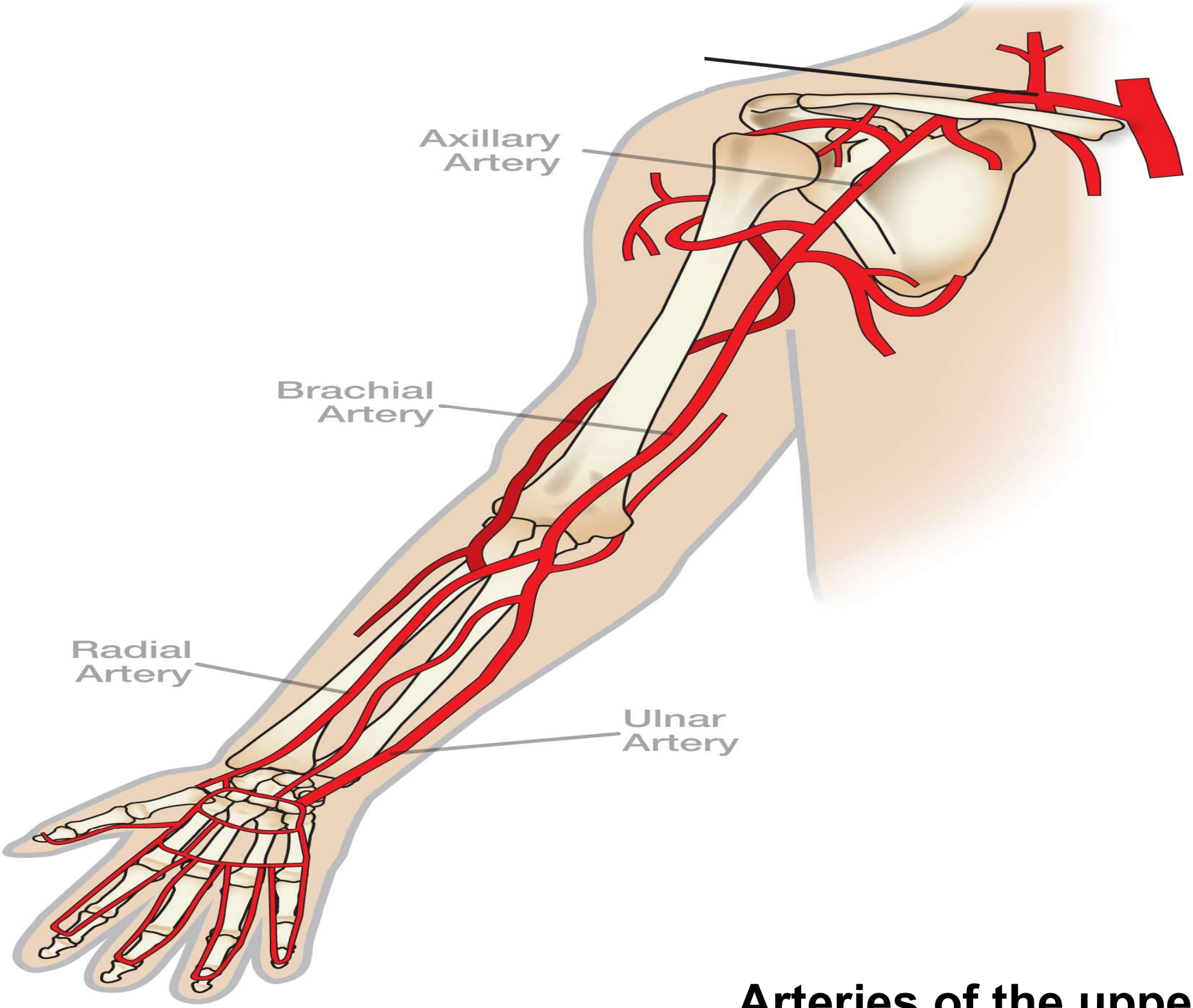

Arteries of the upper limb