


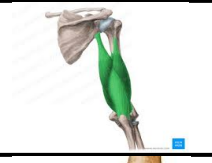












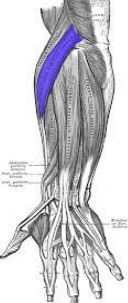


Arm	Anterior (flexor)	muscle		origin	insertion	Nerve	action	image
		Biceps brachii		Long:supraglenoid tubercle.(the capsule of the shoulder joint) Short: coracoid	Radial tuberosity	Musculo cotanious	-elbow & arm Flexion. - semiflexed forearm supinator.	
		brachialis		Lower ½ of humerus	Ulnar coronoid process	Musculo Cotanuos+ radial	-main flexor of the forearm	
		Coraco brachialis		Coracoid	Medial humerus	Musculo cotanous	-Flexion of the arm	
	Posterior (extensor)	triceps		Long: infraglenoid Medial&lateral:hu merus	Ulnar olecranon process	radial	-main extensor of the arm	
fore arm	Anterior (flexors)	superficial	Pronator teres	-cfo - ulnar coronoid process	radius	median	-forearm flexion -pronation	
			Flexor carpi radialis	cfo	2 nd & 3 rd metacarpals	median	-flexion -abduction	

			Plmaris longus	cfo	Palmar aponeurosis	median	-flexion -tensor on the palm fascia	
			Flexor carpi ulnaris	Cfo ++	5 th metacarpal bone	Ulnar	-adduction -flexion	
	inter mediate	Flexor digitoru m superficialis	-cfo -coronoid ++	Middle phalanx	median	-flexion		
	deep	Flexor digitoru m profundus	ulna	Distal phalanx	Medial part: ulnar Lateral: antrior interossious	-flexion		
		Flexor pollicis longus	radius	Thumb terminal phalanx	antrior interossious	-flexion		

			Pronator quadratus	ulna	radius	anterior interosseous	Main pronator of the radius among the radioulnar joint	
	posterior	superficial	Extensor carpi radialis brevis	CEO Front of the lateral epicondyle of the humerus	3 rd metacarpal bone	Posterior interosseous (deep branch of the radial)	-wrist abduction -wrist extension	
			Extensor digitorum	CEO	Extensor expansion for all middle fingers	Posterior interosseous (deep branch of the radial)	wrist+metacarpophalangeal+interphalangeal extension	
			Extensor digiti minimi	CEO	Extensor expansion for 5 th finger	Posterior interosseous (deep branch of the radial)	wrist+metacarpophalangeal+interphalangeal extension	

			Extensor carpi ulnaris	CEO	5 th metacarpal bone	Posterior interosseous (deep branch of the radial)	-wrist adduction -wrist extension	
			anconeus	Back of the lateral epicondyle	olecranon	radial	Helps the triceps with elbow extension	
		deep	Supinator		All surfaces except medial of the upper 1/3 radius	Posterior interosseous (deep branch of the radial)	Supination of the forearm	
			Abductor pollicis longus		1 st metacarpal bone	Posterior interosseous (deep branch of the radial)	-Abduction of the thumb -extension of the thumb	
			Extensor pollicis longus		Distal phalanx of the thumb	Posterior interosseous (deep branch of the radial)	-extends distal phalanx of the thumb	
			Extensor pollicis brevis		Proximal phalanx of the thumb	Posterior interosseous (deep branch of the radial)	-extension of metacarpophalangeal joint of the thumb	

			Extensor indicis		Extensor expansion of the index	Posterior interosseous (deep branch of the radial)	Extends all joints of the index	
	lateral	brachioradialis		Upper 2/3 of the supracondylar line	Styloid process of the radius	radial	-initiate pronation and supination to the midprone. -extends midprone forearm.	 
		Extensor carpi radialis longus		Lower 1/3 of the supracondylar line	2 nd metacarpal bone	radial	-wrist extension. -wrist abduction.	 

-ghada barakat

