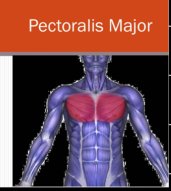
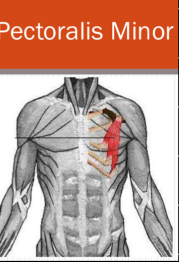
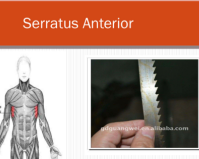
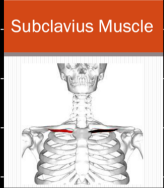
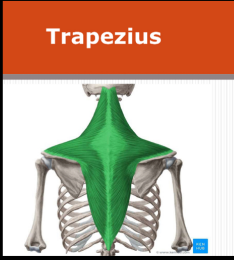


	origin	insertion	nerve supply	Action
pectoralis major 	1) clavicular head anterior of the medial 2/3 of the clavical 2) sternocostal head a) anterior surface of the sternum b) upper 6 costal cartilage	Lateral lip of the bicipital groove	medial & lateral pectoral nerves	1) Adduction of the arm & medial rotation 2) Flexion of the arm 3) sternocostal head (the arm raised and fixed, can raise the trunk as in climbing)
pectoralis minor 	From outer surface of the 3 <sup>rd</sup> , 4 <sup>th</sup> , 5 <sup>th</sup> ribs close to their costal cartilages	coracoid process of the scapula	medial pectoral nerve	1) protraction of the scapula 2) depresses the shoulder 3) if the scapula is fixed, it elevates the ribs
Serratus anterior 	outer surface of the upper 8 ribs	ventral lip of the medial border of the scapula	(long thoracic nerve) nerve to serratus anterior	1) protraction of the scapula 2) Rotate the scapula upward during raising the arm above the head.
subclavius muscle 	—	—	nerve to subclavius from upper trunk of Brachial plexus	1) Depresses the clavical 2) steadies the clavical during movements of the shoulder girdle

muscle connecting upper limb with vertebral column

	insertion	origin
Trapezius	<ol style="list-style-type: none"> <li>1) posterior border of the lateral third of the clavical</li> <li>2) medial border of acromion</li> <li>3) upper border of the spine</li> </ol>	<ol style="list-style-type: none"> <li>1) External occipital protuberance</li> <li>2) Ligaments nucha</li> <li>3) All the thoracic spines</li> </ol>
	Nerve supply:	Action
	spinal accessory Nerve	elevates, retract and rotates the scapula

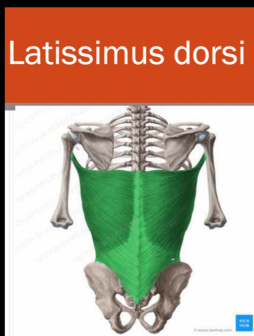

origin

insertion

- Latissimus dorsi
- 1) spines of the lower 6 thoracic vertebra
  - 2) iliac crest of hip bone
  - 3) inferior angle of the scapula

the floor of the bicipital groove



nerve supply

Action

Thoracodorsal nerve  
(C5/7/8)

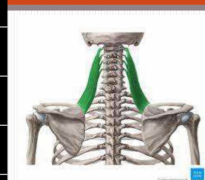
Adduction & medial rotation  
Extension of the arm

nerve supply      action

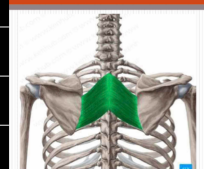
Dorsal scapular nerve

These muscles, retract of the scapula

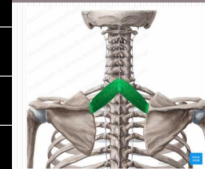Levator Scapula



Rhomboidei major



Rhomboidei minor



Levator scapulae, elevates the scapula and when shoulder is fixed, it laterally flexes of the neck

Doaa A/Retaie