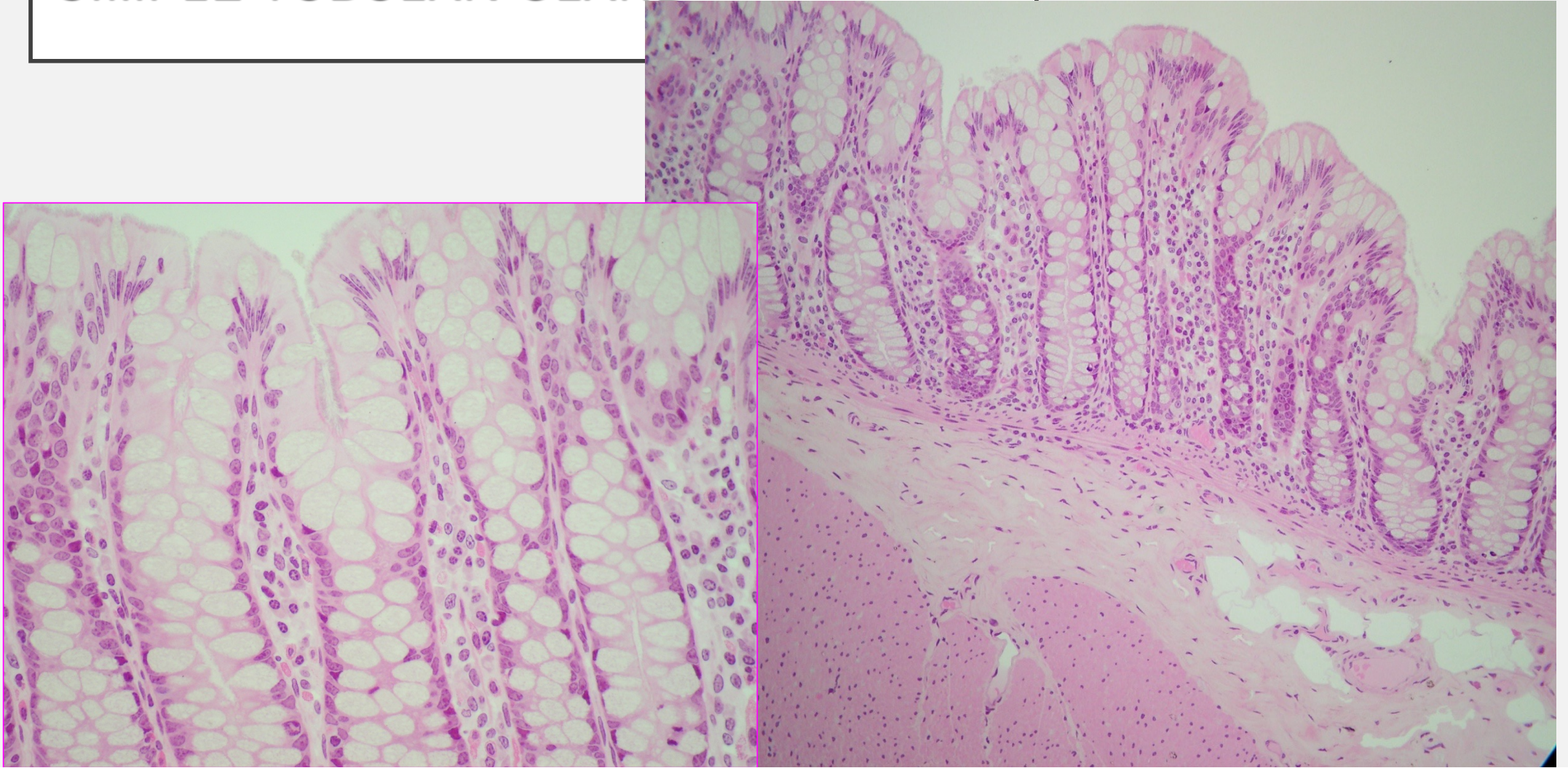
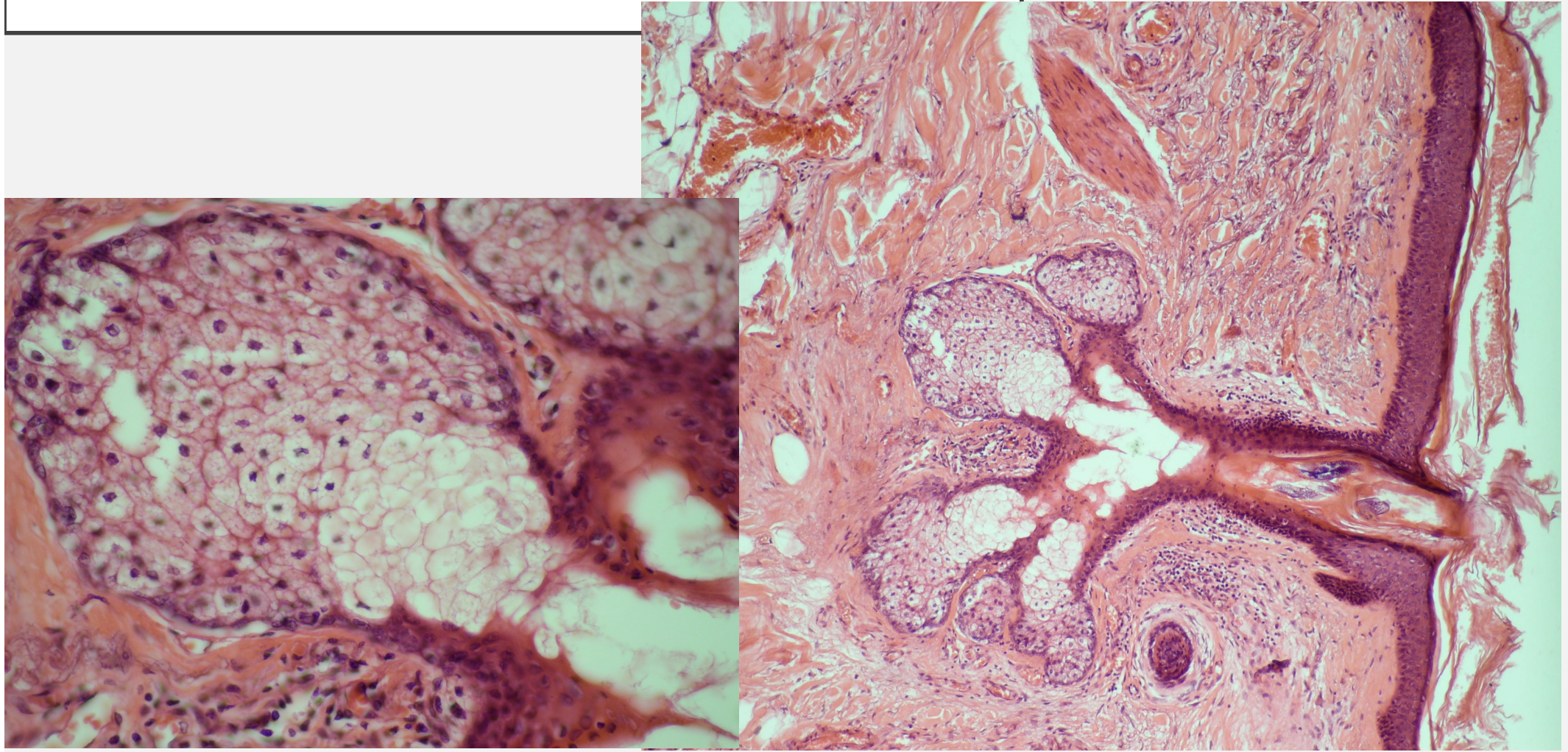


GLANDS

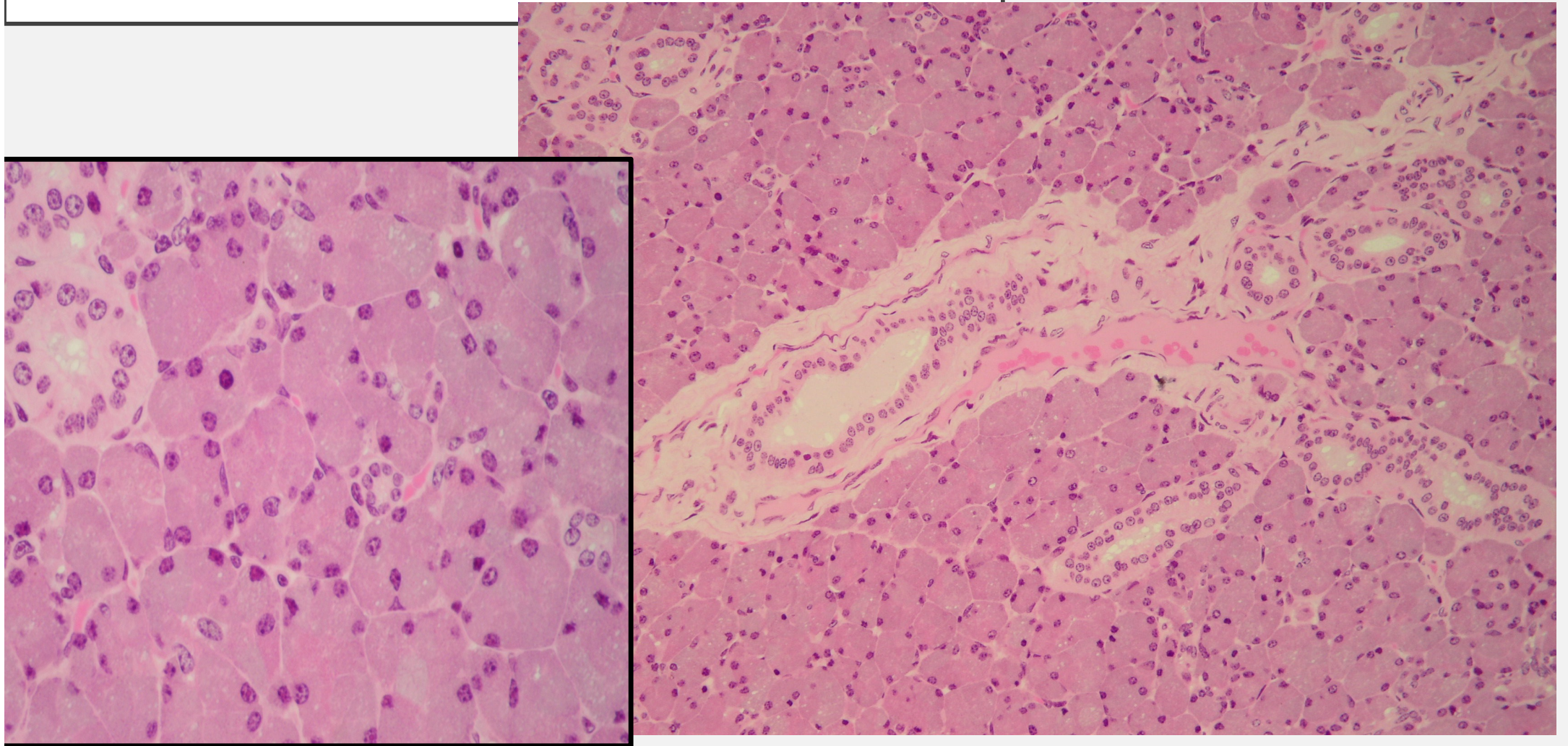
SIMPLE TUBULAR GLAND



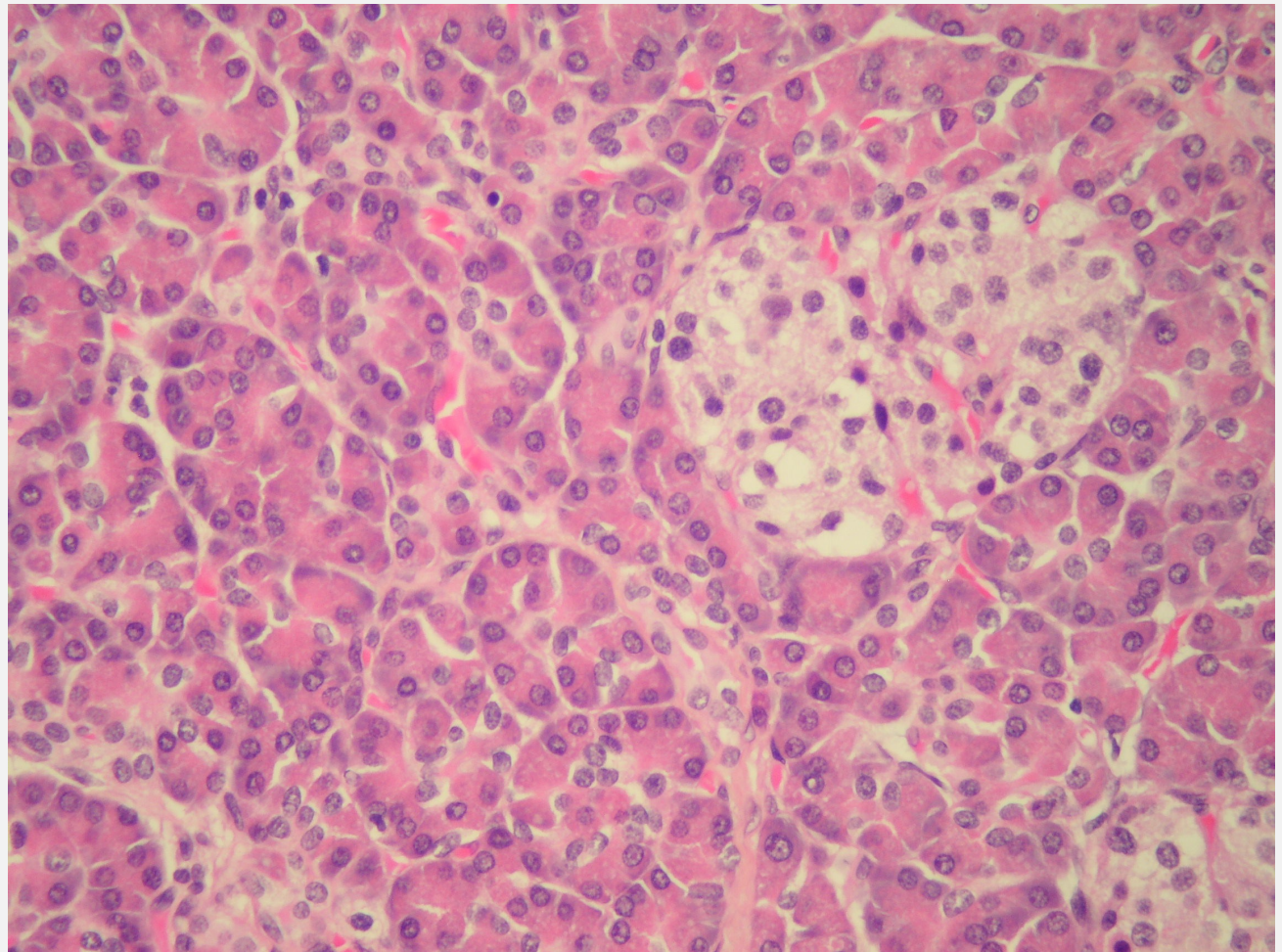
SEBACEOUS GLAND



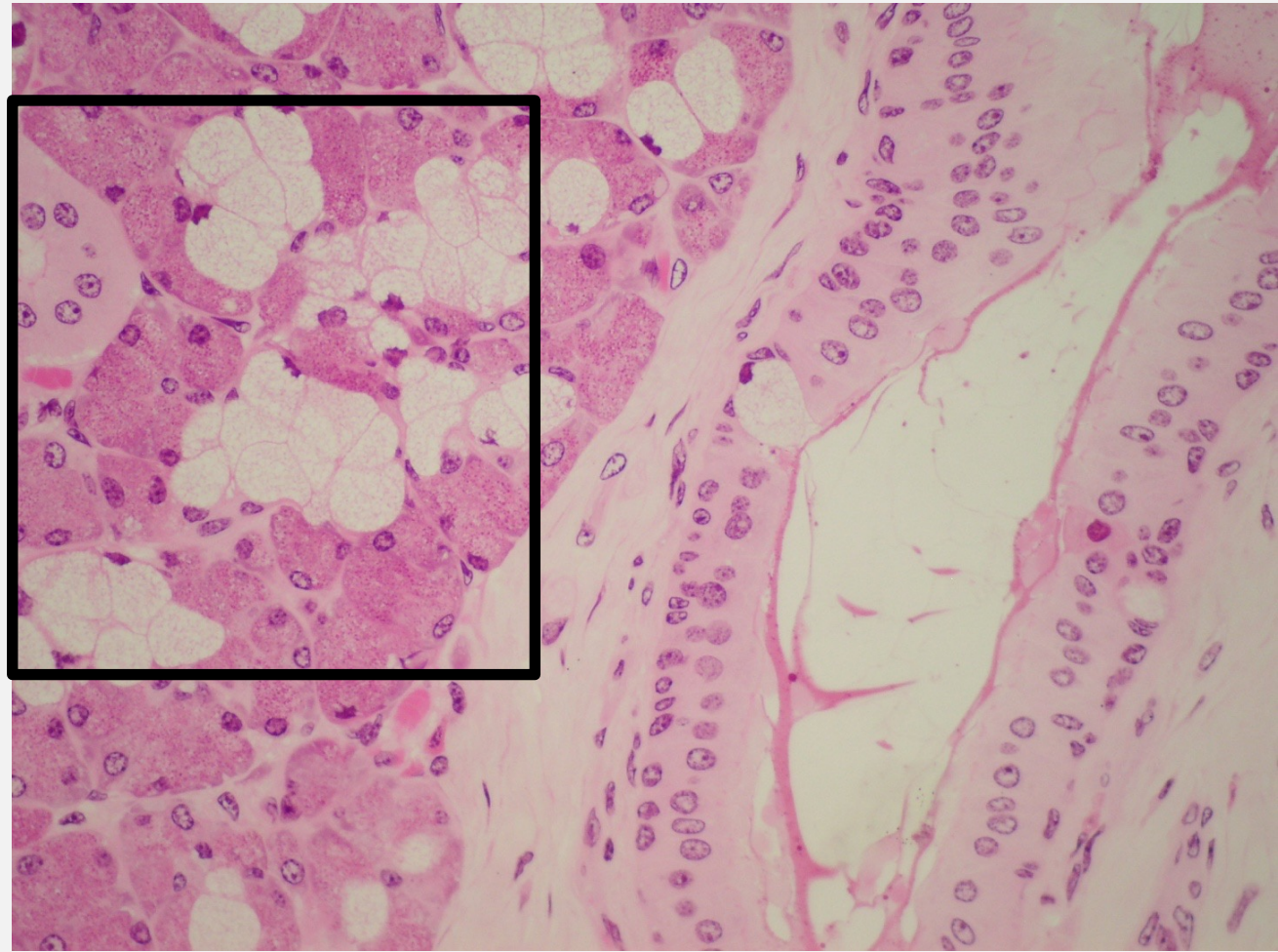
PAROTID GLAND



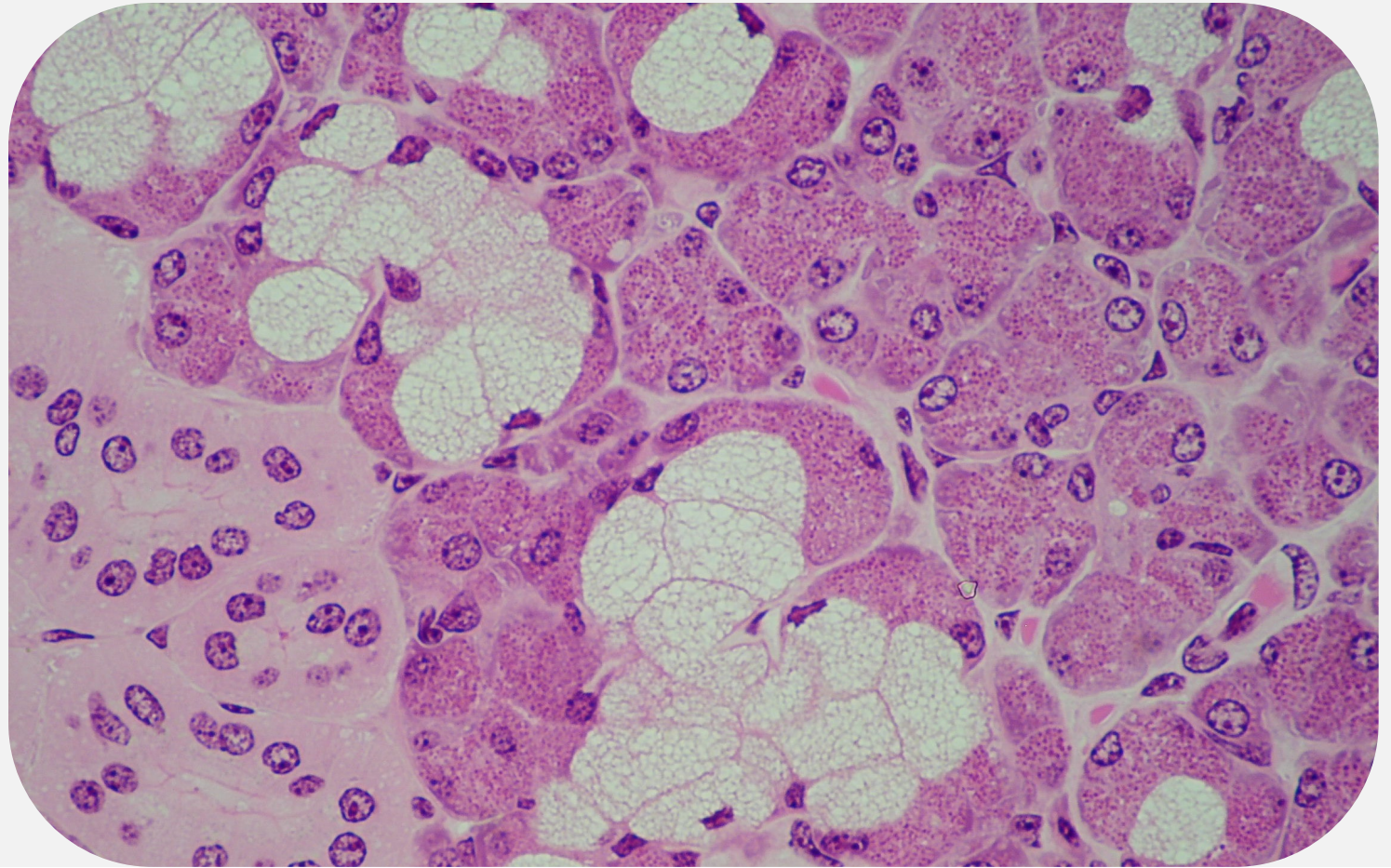
PANCREAS



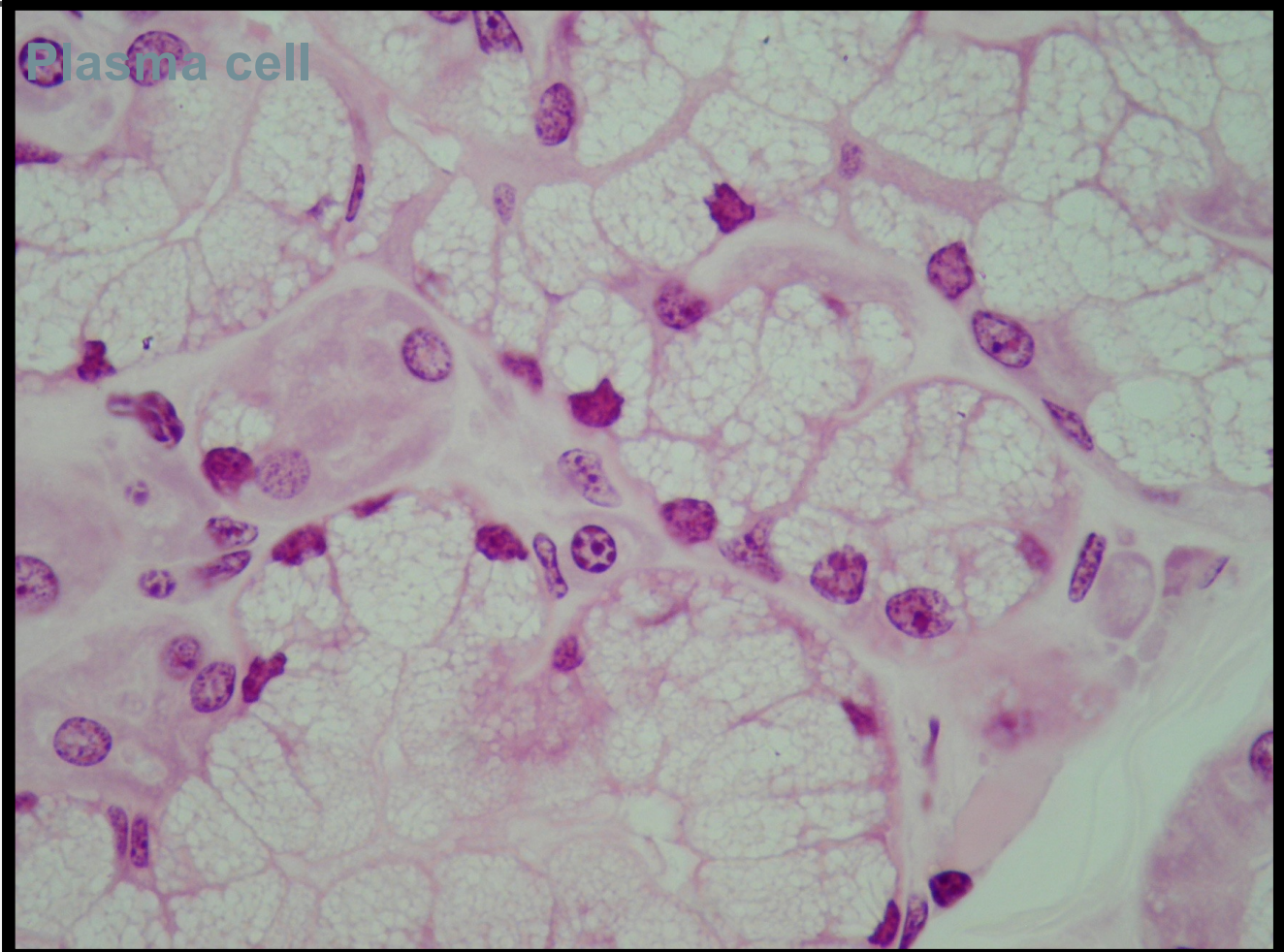
COMPOUND TUBULOALVEOLAR

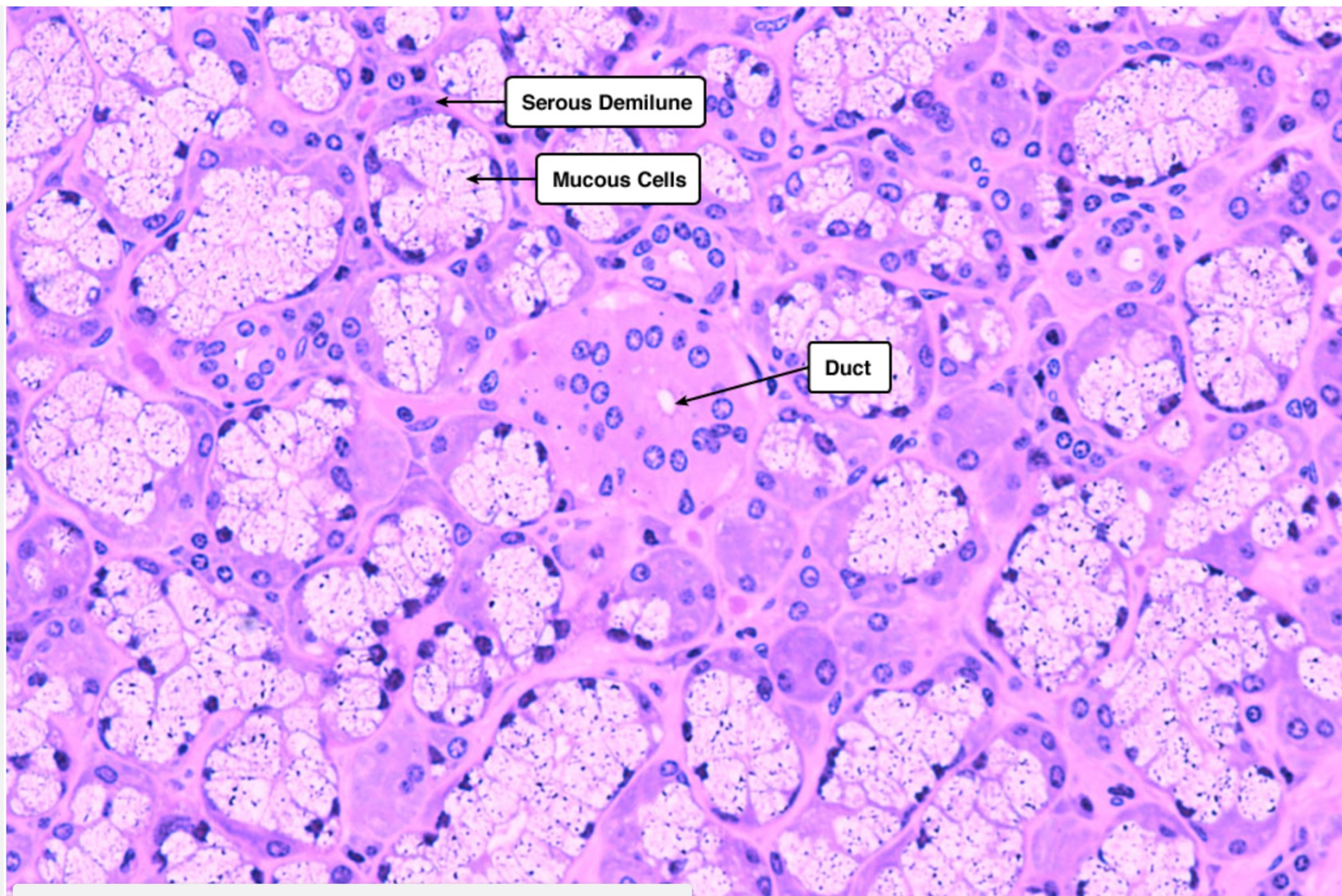


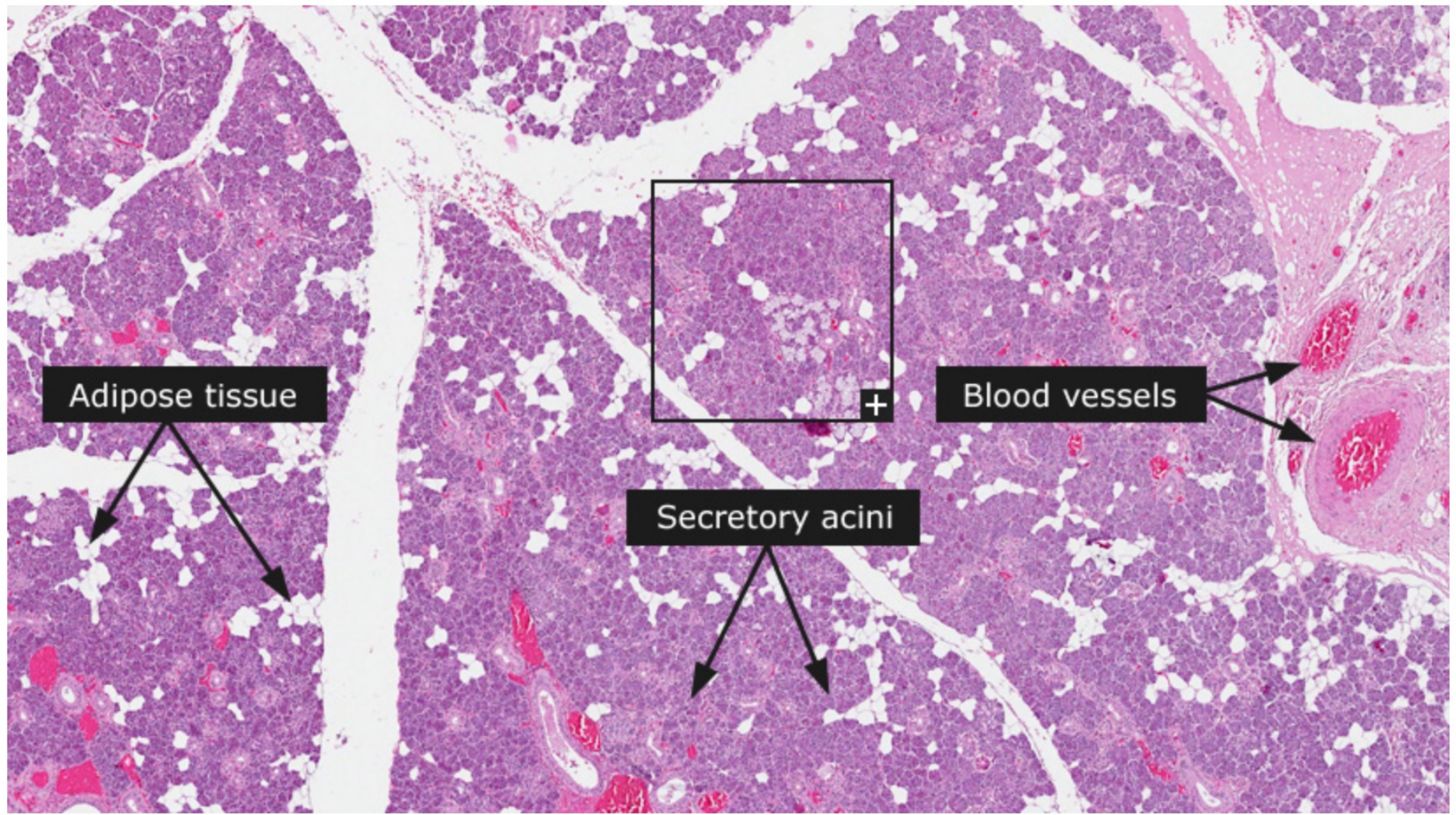
COMPOUND TUBULOALVEOLAR



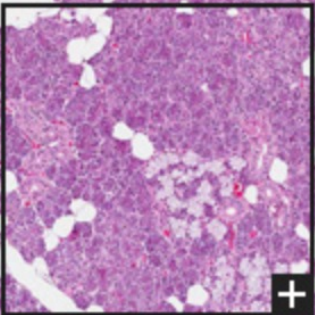
COMPOUND TUBULAR







Adipose tissue

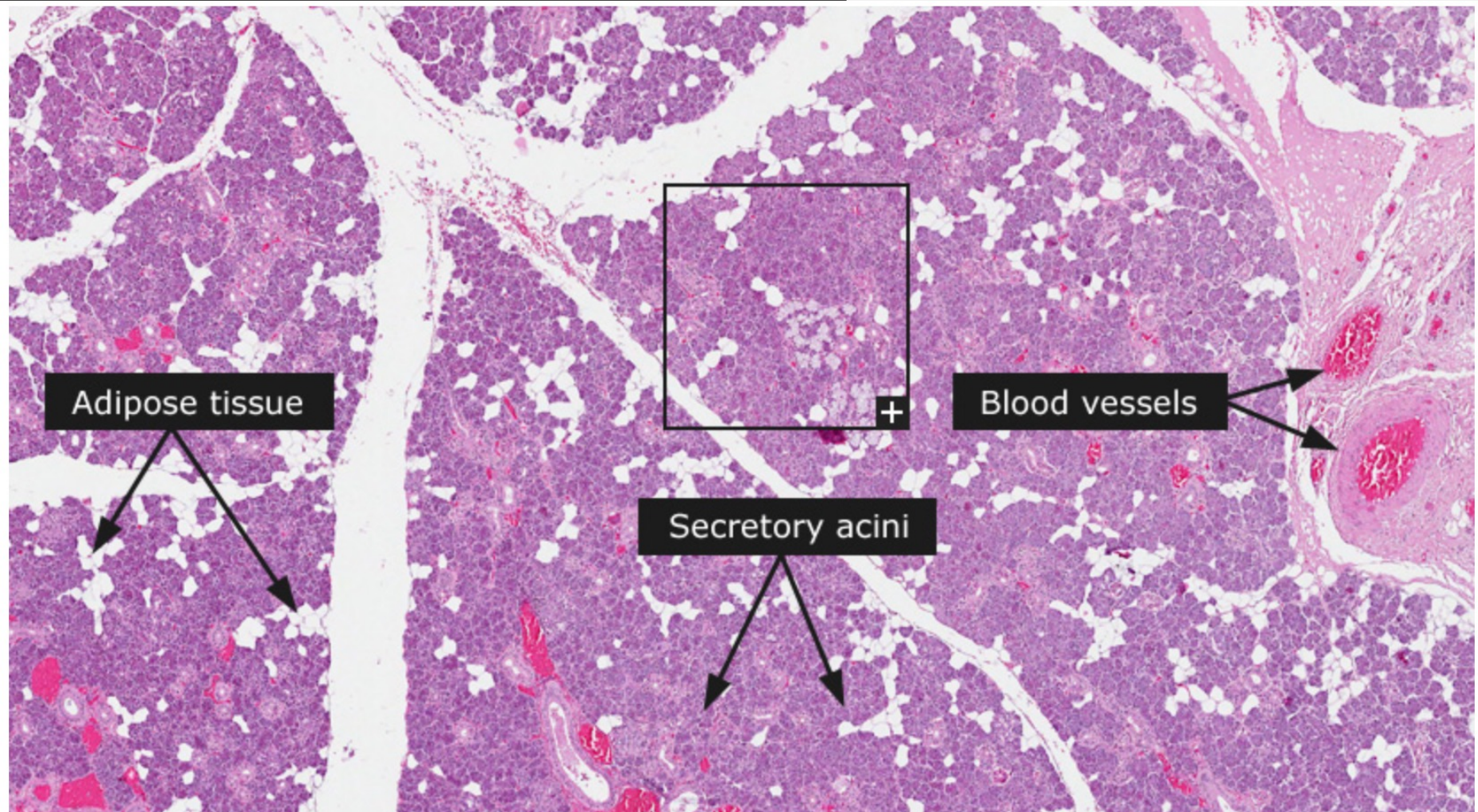


Blood vessels

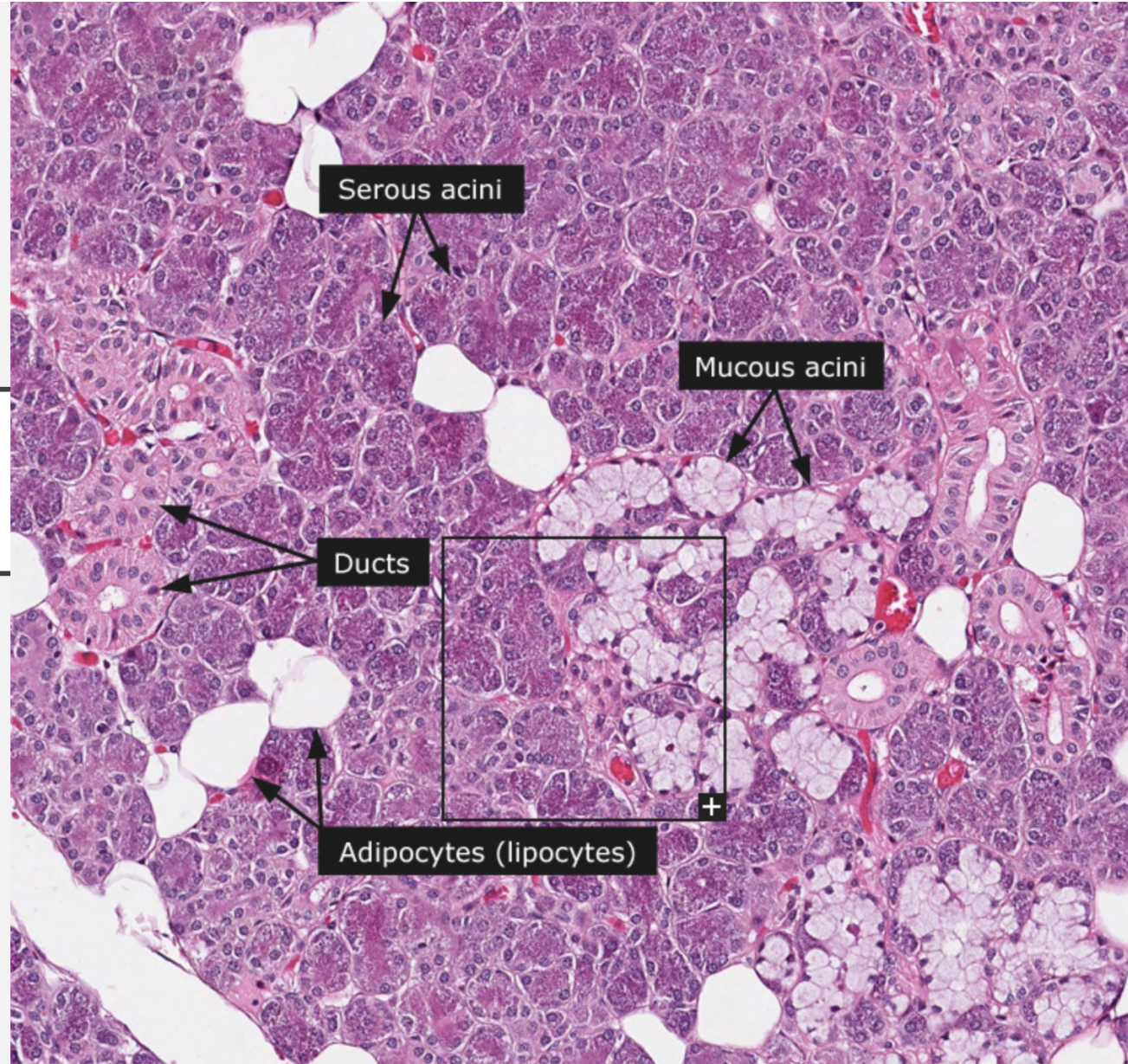
Secretory acini



SUBMANDIBULAR GLAND



SUBMANDIBULAR GLAND



SUBMANDIBULAR GLAND

