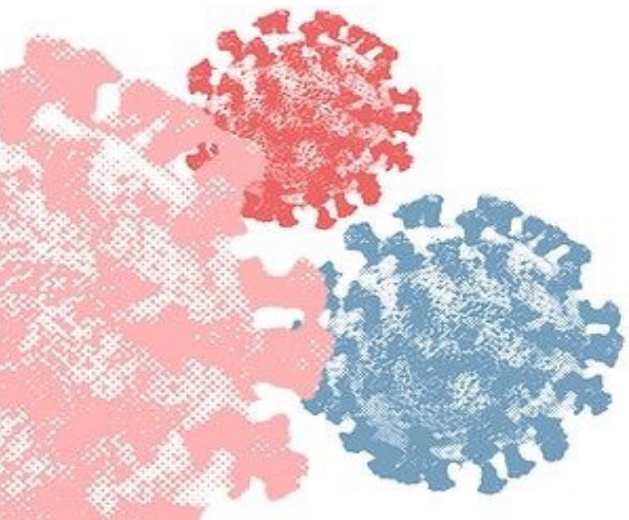




# Pathology lecture 9

Done by : Mais Salman



**1- One of the following sentences is correct :**

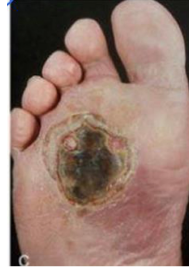- a. Tissues with better blood supply heal more slowly
- b. Healing process is affected by one factor only
- c. Taking steroid drugs will delay tissue repair
- d. The presence of foreign bodies enhances repair process

**2- Which of the following is true about bed ulcers:**

- a. Always fatal
- b. Impossible to deal with
- c. preventable
- d. Appear as an intact epithelial surface under the microscope

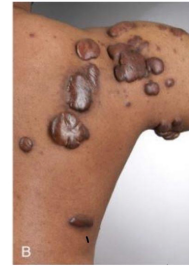**3- this picture is:**

- a. Deep ulcer with atherosclerosis
- b. non healing gangrene with fungal infection
- c. Wound dehiscence
- d. Inflamed leg with dilated blood vessels



**4- The following picture is:**

- a. keloid scar
- b. Arterial ulcer
- c. Hypertrophic scar
- d. Diabetic ulcer



**5- Which one of the following factors will significantly delay healing of a surgical wound ?**

- a. ingestion of oral antibiotics as prophylaxis
- b. a patient with severe atherosclerosis
- c. taking oral pain killers for pain control
- d. early post-operative immobilization
- e. A patient with prior cholecystectomy

# Answers

Q	1	2	3	4	5
	C	C	A	A	B

قال الله تعالى: "أَمْ حَسِبْتُمْ أَنْ تَدْخُلُوا الْجَنَّةَ وَلَمَّا يَأْتِكُمْ مَثَلُ الَّذِينَ خَلَوْا مِنْ قَبْلِكُمْ مَسْتَهْمِ الْبِئْسَاءِ وَالضَّرَّاءِ وَزَلْزَلُوا حَتَّى يَقُولَ الرَّسُولُ وَالَّذِينَ آمَنُوا مَعَهُ مَتَى نَصُرُ اللَّهُ أَلَا إِنَّ نَصْرَ اللَّهِ قَرِيبٌ"

## 6- In which of the following scenarios the risk for post- operative wound dehiscence would be high?

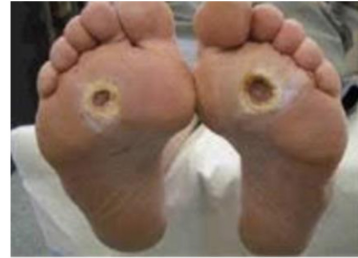- a. transabdominal open colon cancer resection in 65 year old male patient who is obese and chronic smoker
- b. we don't see this complication anymore with modern medicine
- c. valvular heart replacement surgery requiring open thoracotomy in a 59 years Old female patient who is a heavy chronic smoker
- d. tooth root canal surgery for a 75 year old obese male patient
- e. laparoscopic choleystectomy for a 63 year old male patient with morbid obesity and chronic smoking history

## 7- Bed "pressure" sores are best described as?

- a. Diabetic foot ulceration with superadded infection
- b. Serous-type inflammation with complicating infection
- c. avoidable ulcer due to bad nursing/home care
- d. stress ulcer from severe chronic diseases
- e. mild superficial ulcers that are easy to heal

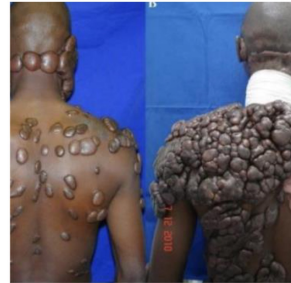## 8- choose the correct :

- a. Severe ischemia due to atherosclerosis
- b. Friction burn of skin and subcutaneous tissue
- c. radiation injury for squamous cell carcinoma of the leg
- d. traumatic serous inflammation of the skin and subcutaneous tissue
- e. varicose veins of lower limbs



## 9- choose the correct :

- a. Abnormal excessive repair and the scar formation
- b. side effect of using see certain type of surgical sutures
- c. occurs in patients with a pre-existing atherosclerosis
- d. lateral genic result due to bad surgical technique
- e. Wound dehiscence



## 10- A 70 year old man with emphysema, his weight is 150 kg, will undergo abdominal surgery for a large small bowel mass, the best description for the case:

- a. there's no risk
- b. complicated surgery with high risks that needs hospitalization
- c. very easy surgery, Assure him
- d. there might be some risk, not too complicated
- e. very high risk, and he might die, advise him not to do it

## Answers

Q	6	7	8	9	10
	A	C	A	A	B

يقتلون، يسرقون، يُقسَّمون البلاد إلى كانتونات وكيبوتسات، يرفعون الجُدران، يَلِصُّون القمح، ويبعثون الجراد، وينعقون كالغريبان، وتنضجُ كلماتهم بالحقْد والموت، وتريدون منَّا بعدَ ذلك أن نصمت، لا يصمتُ إلاَّ الموتى أيَّها الموتى.

كلما دعيتك نفسك إلى معصية، تذكر أن أمتك  
جريحة تنتظر من يحمل همها، ويتلمس طريق  
عزتها، ومعصيتك وغفلتك تجعلك عبئاً جديداً  
على أمتك!

" إن ينصركم الله فلا غالب لكم "

اللهم انصر إخواننا المسلمين في فلسطين  
اللهم سلم غزه وأهلها وأرضها ومن عليها  
واحفظهم بحفظك اللهم كن لهم عوناً ومعيناً

اللهم يا ربّ إنّ لنا أهل وأحبّة، يشهدون لك بالوحدانيّة،  
اللهم كن لأهلنا في قطاع غزّة الصّامد، واجزه الخير  
عن هذا الصّمود الطّويل، انصرهم على من عاداهم،  
وعلى من خذلهم يا ربّ العرش العظيم.