

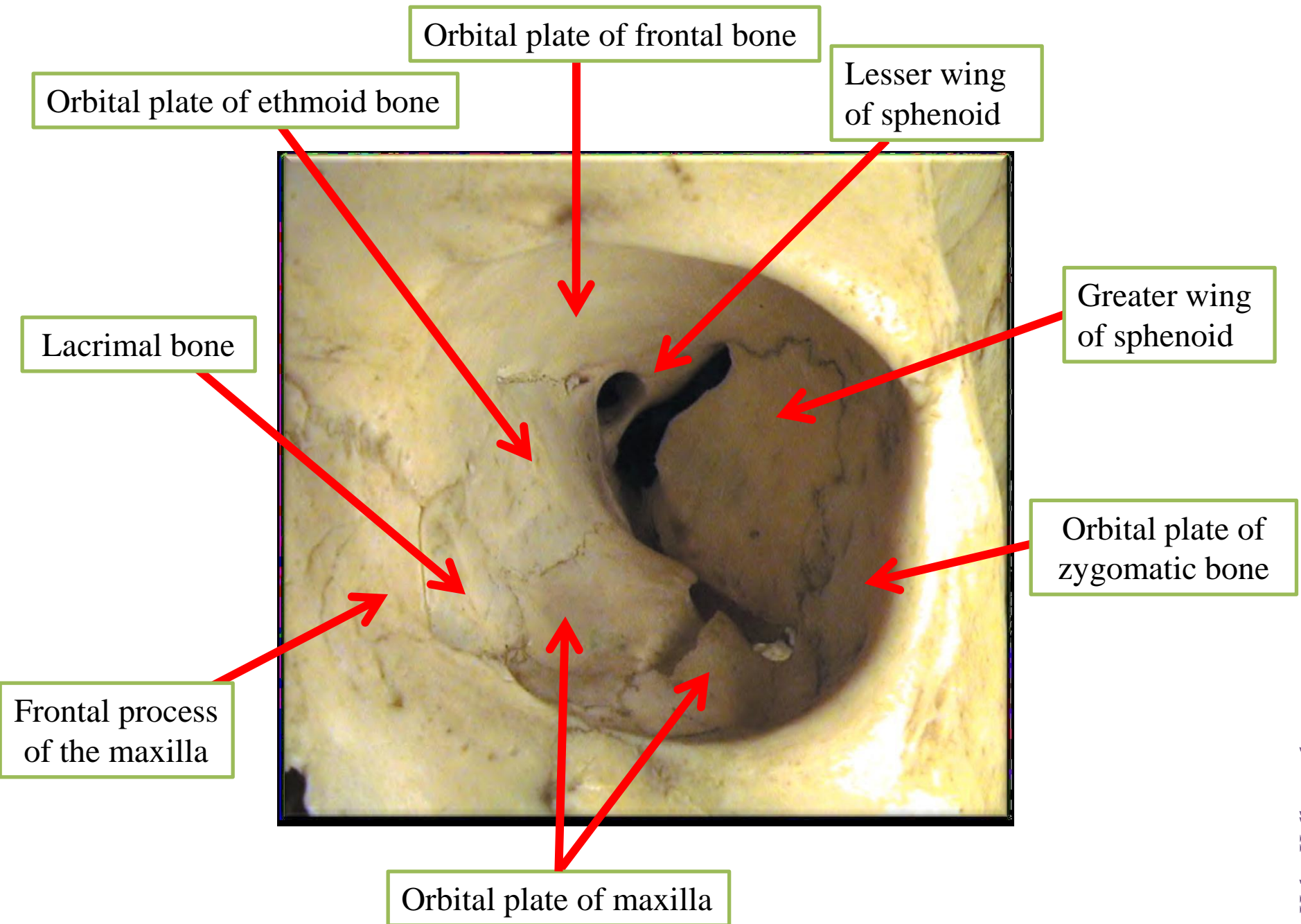


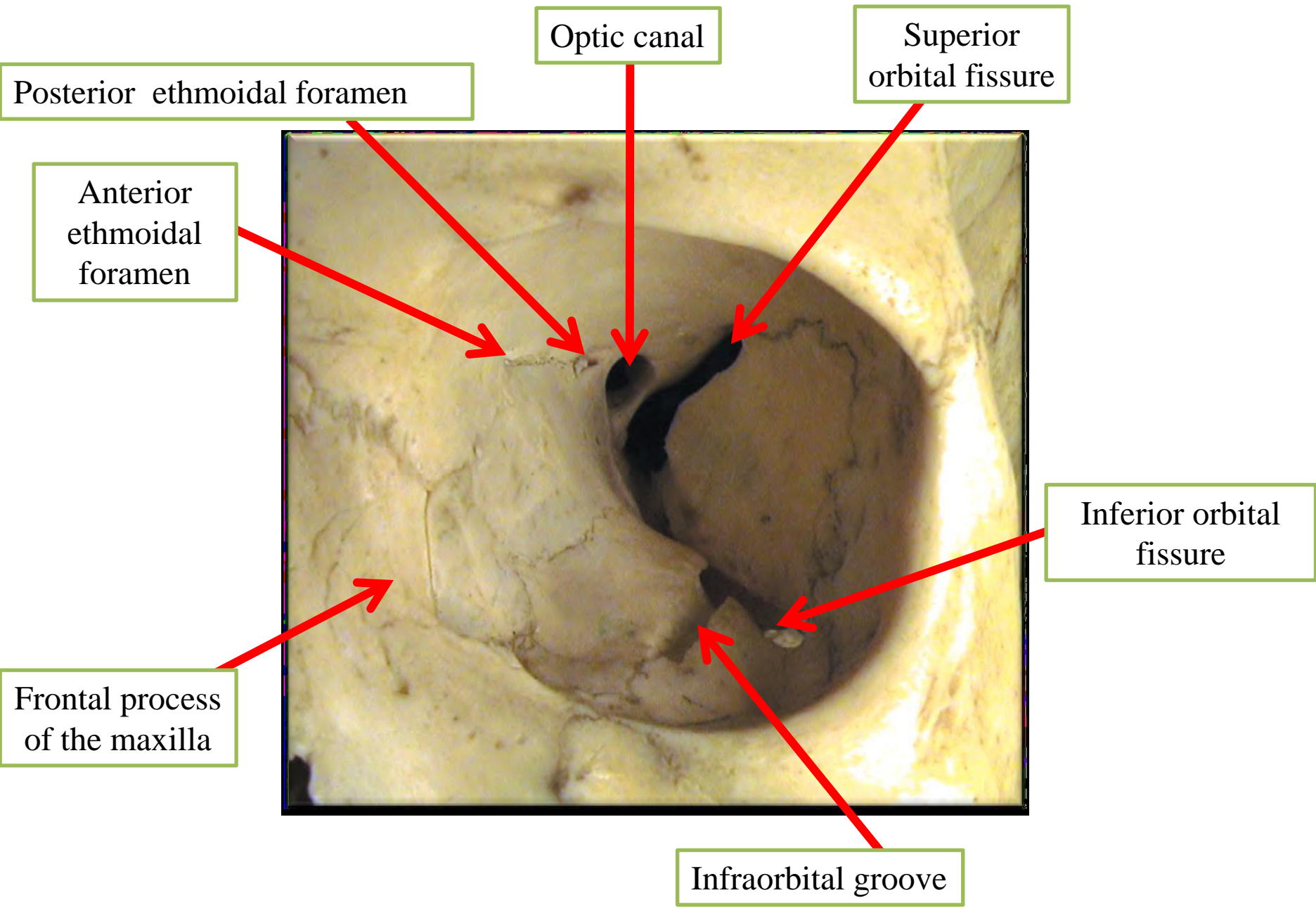
The Orbit-1

Dr. Heba Kalbouneh

DDS, MSc, DMD/PhD

Professor of Anatomy, Histology and Embryology





Orbital plate of frontal bone

Lesser wing of sphenoid

Greater wing of sphenoid

Orbital plate of ethmoid bone

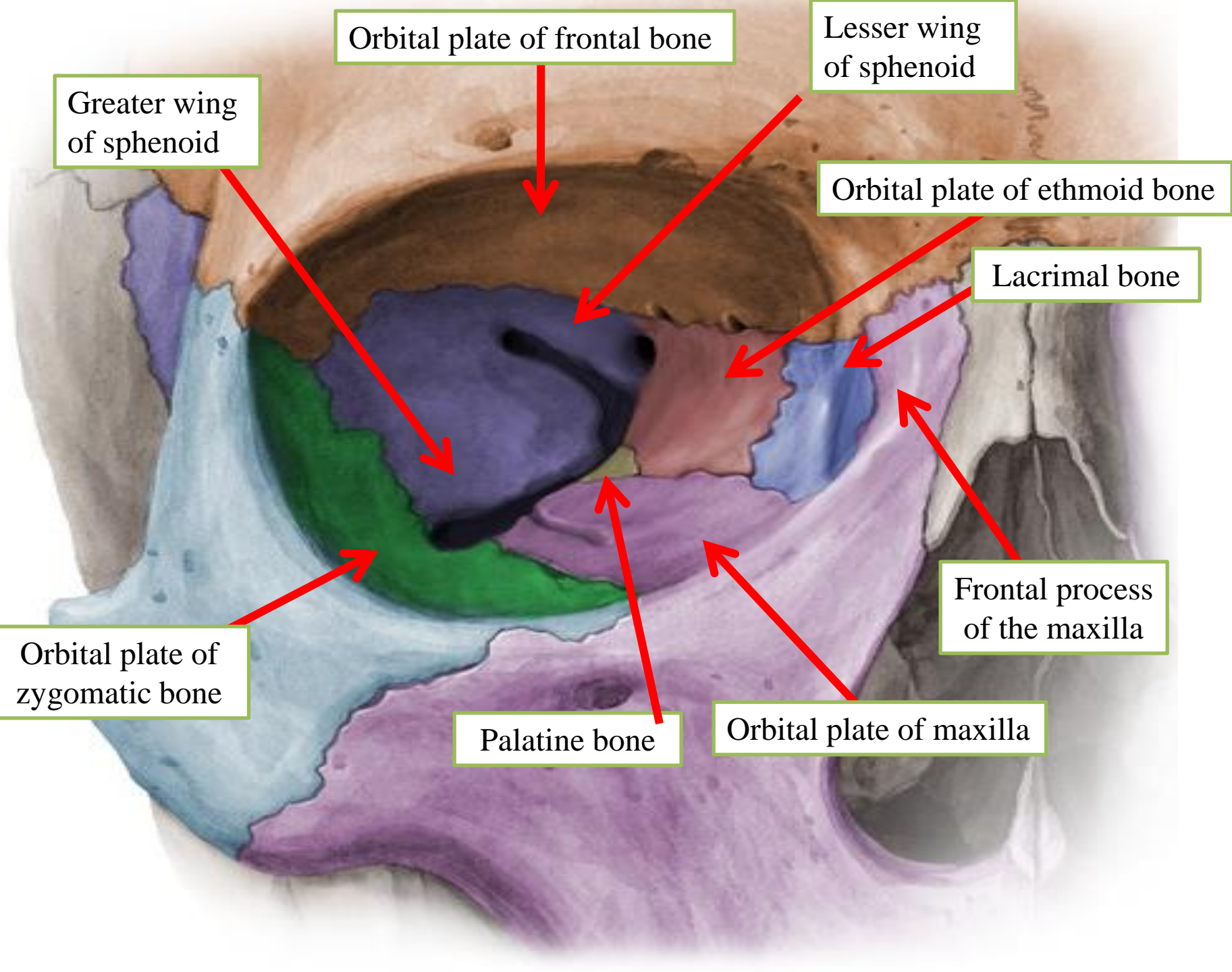
Lacrimal bone

Orbital plate of zygomatic bone

Frontal process of the maxilla

Palatine bone

Orbital plate of maxilla



Orbit

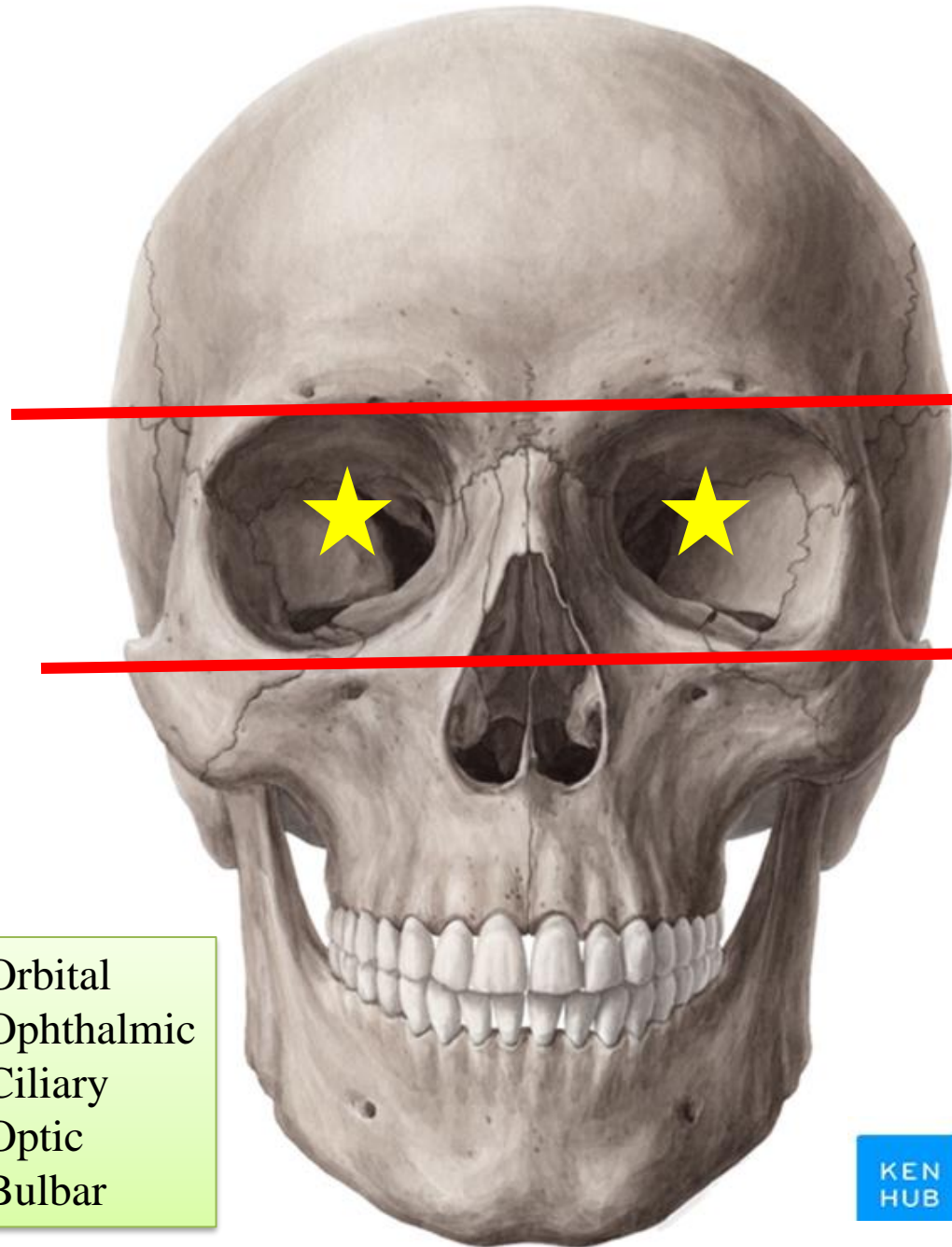
The orbits are bilateral structures below the anterior cranial fossa and anterior to middle cranial fossa

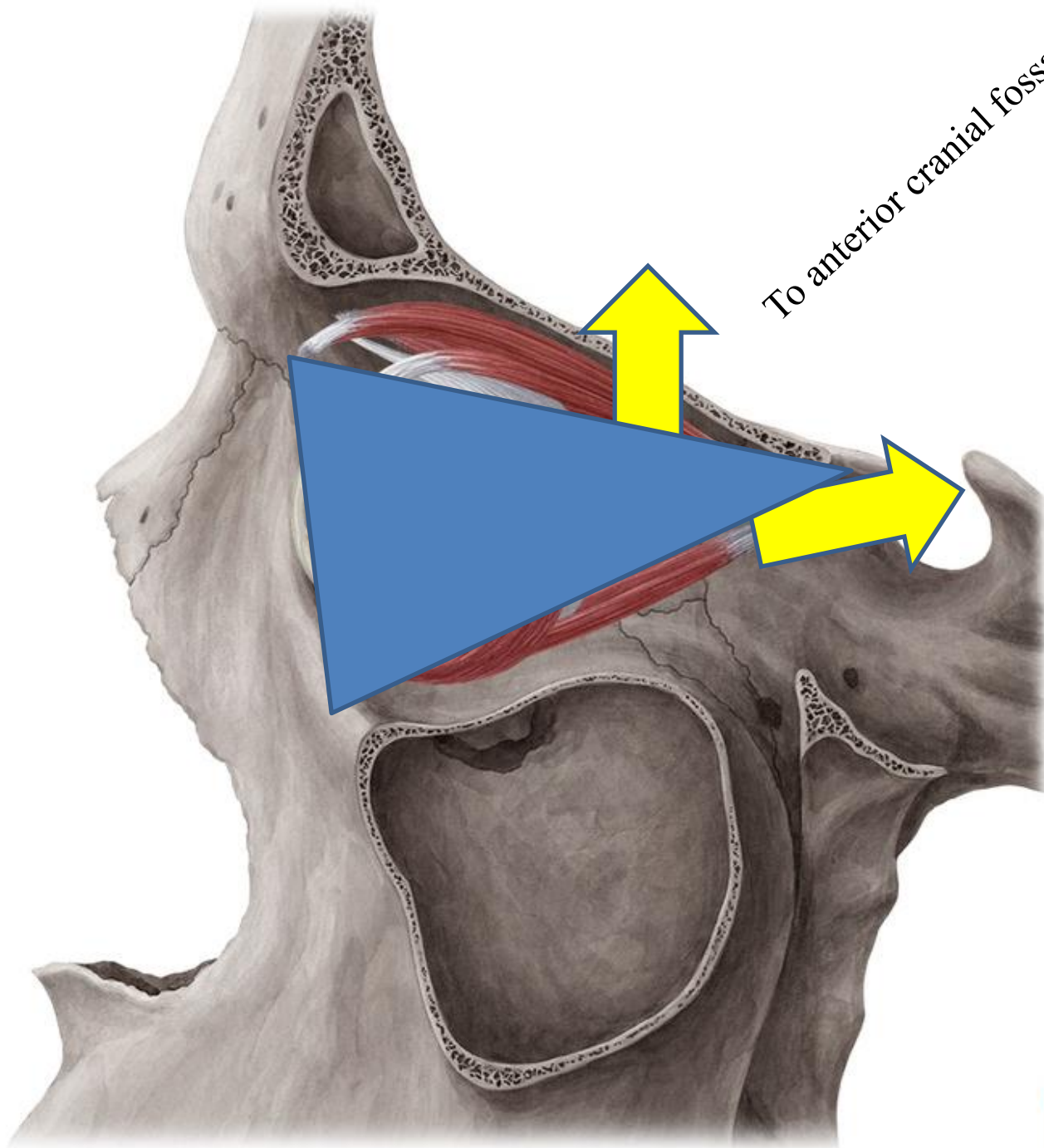
The bony orbit is pyramidal in shape, with its base opening anteriorly onto the face and its apex extending in a posteromedial direction

Has medial, lateral, superior (roof), inferior (floor) walls

The apex of the pyramid is the **optic foramen**, whereas the base is the orbital rim

Orbital
Ophthalmic
Ciliary
Optic
Bulbar



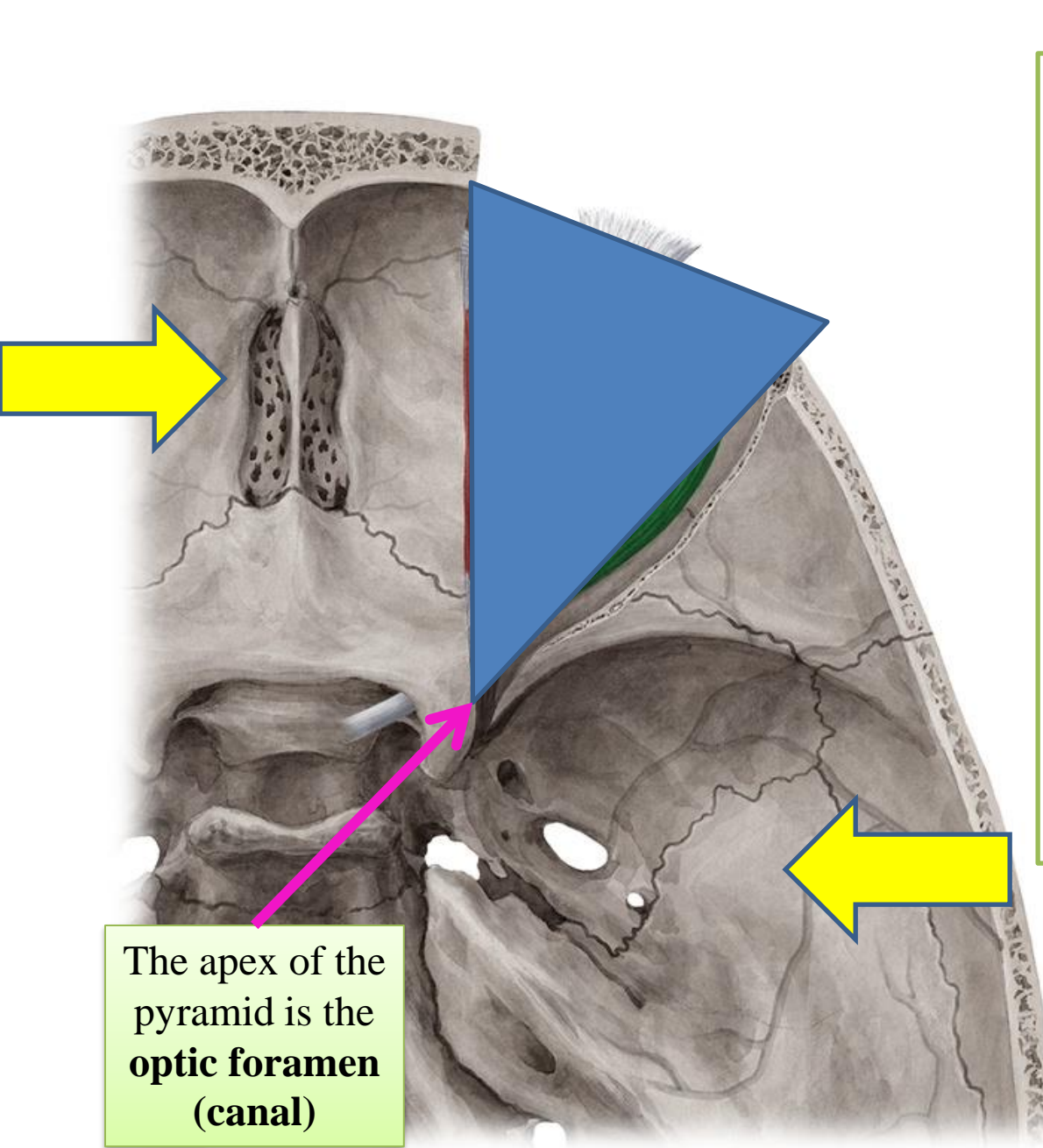


To anterior cranial fossa

To middle cranial fossa

Contents of the orbit:

1. Eyeball
2. Extraocular muscles
3. Intraocular muscles
4. Nerves: Optic, branches of ophthalmic, branches from maxillary, divisions of oculomotor, trochlear, abducent, sympathetic fibers and ciliary ganglion
5. Ophthalmic artery and veins
6. Lacrimal apparatus
7. Fat

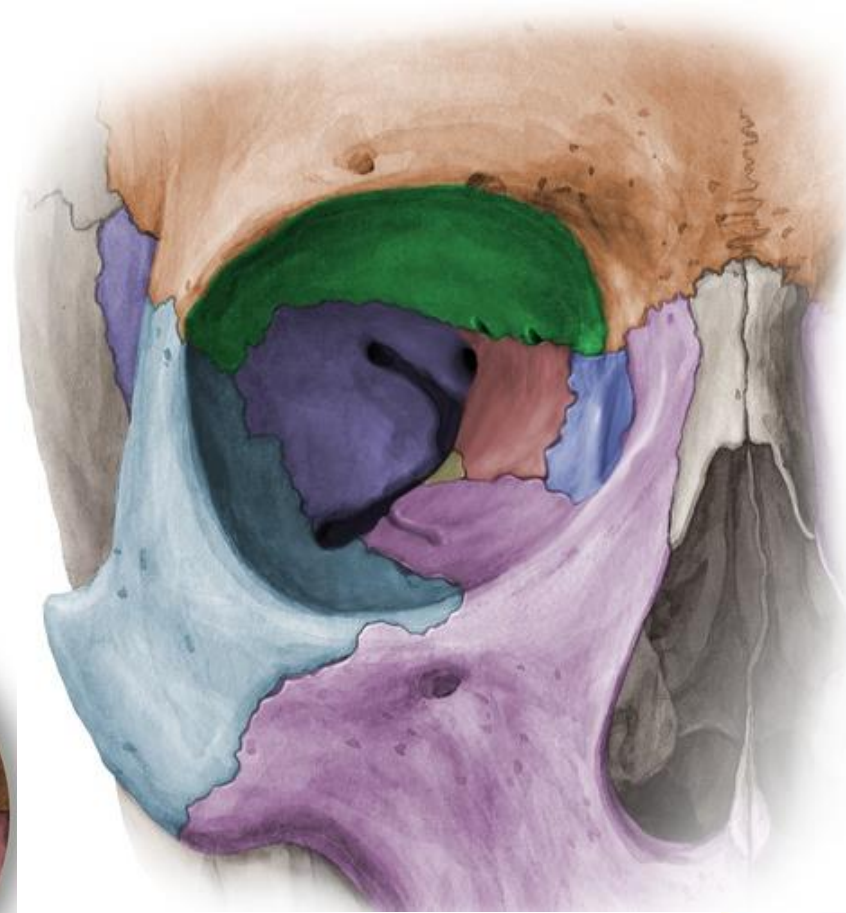


The apex of the pyramid is the **optic foramen (canal)**

Roof:

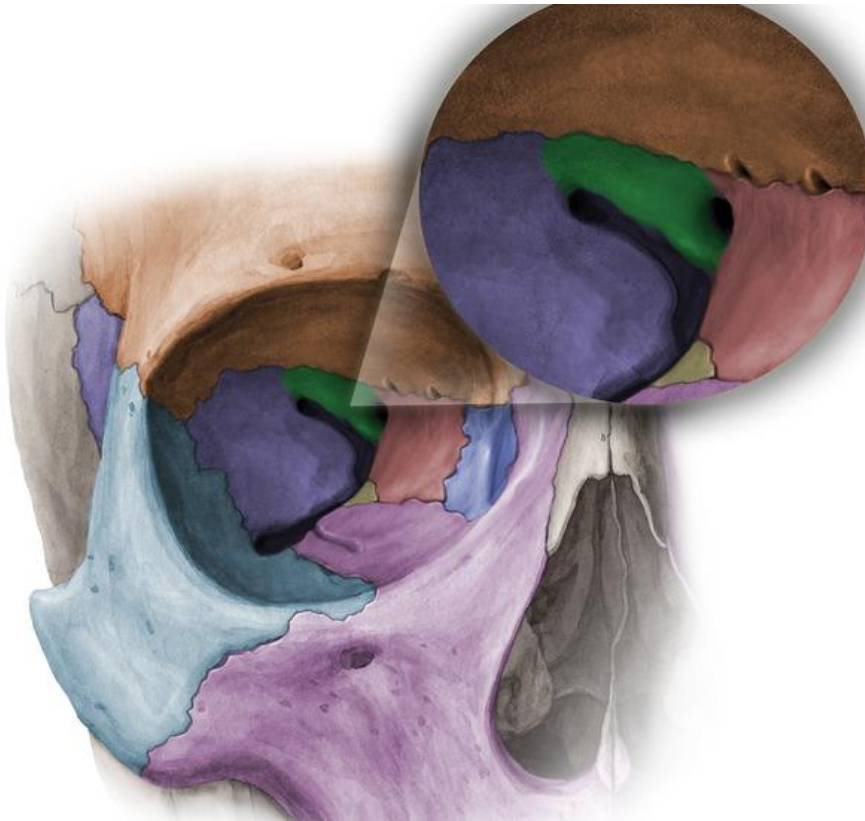
Formed by:

1- The orbital plate of frontal bone, which separates the orbital cavity from the anterior cranial fossa and the frontal lobe of the cerebral hemisphere



KEN
HUB

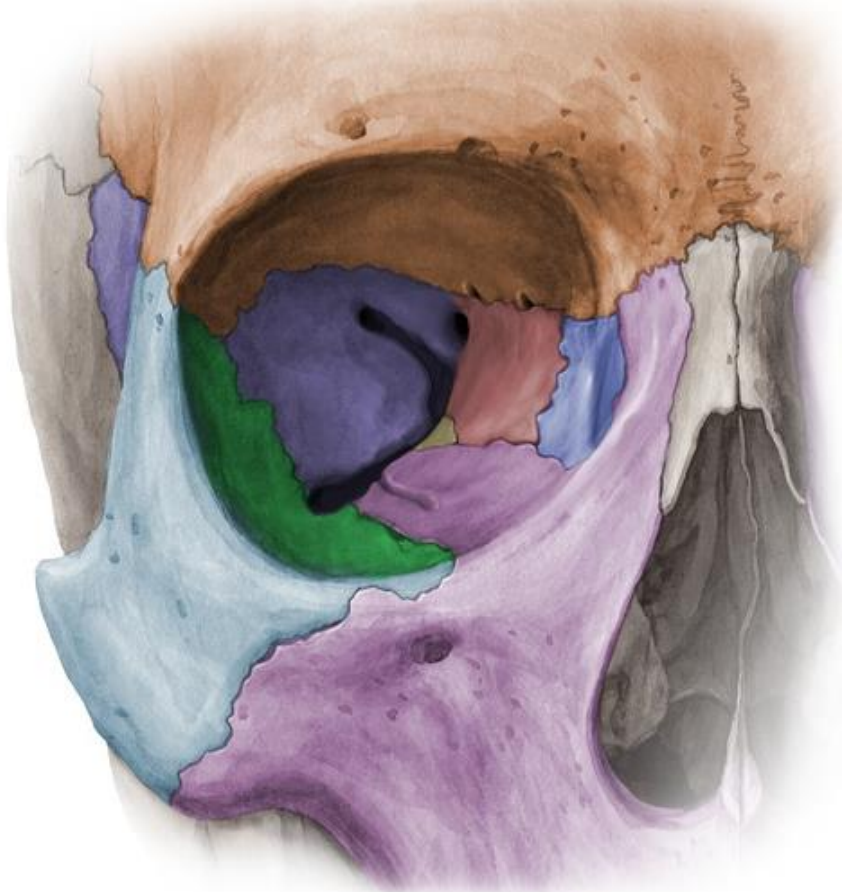
2- The lesser wing of sphenoid



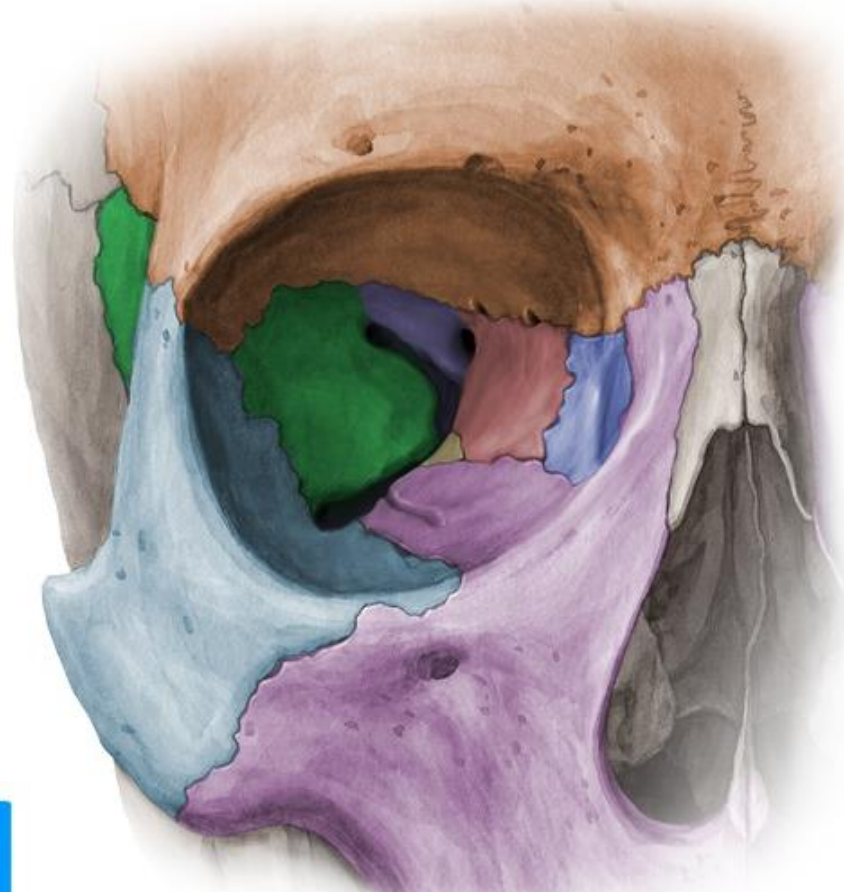Lateral wall:

Formed by:

1- The orbital plate of zygomatic bone



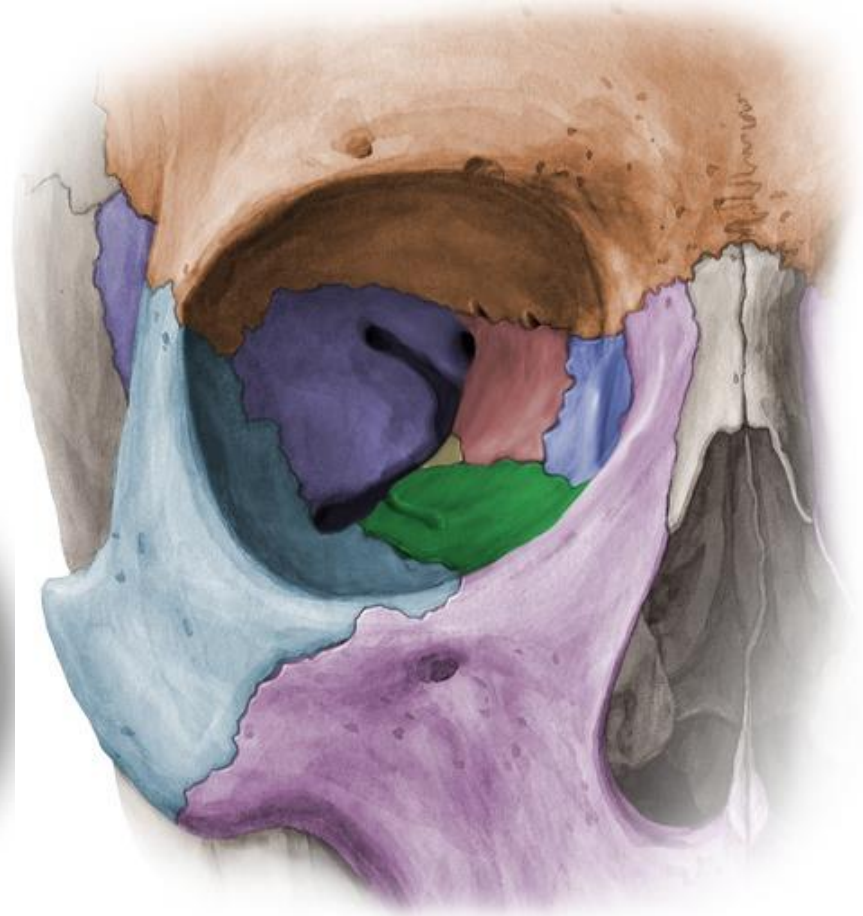
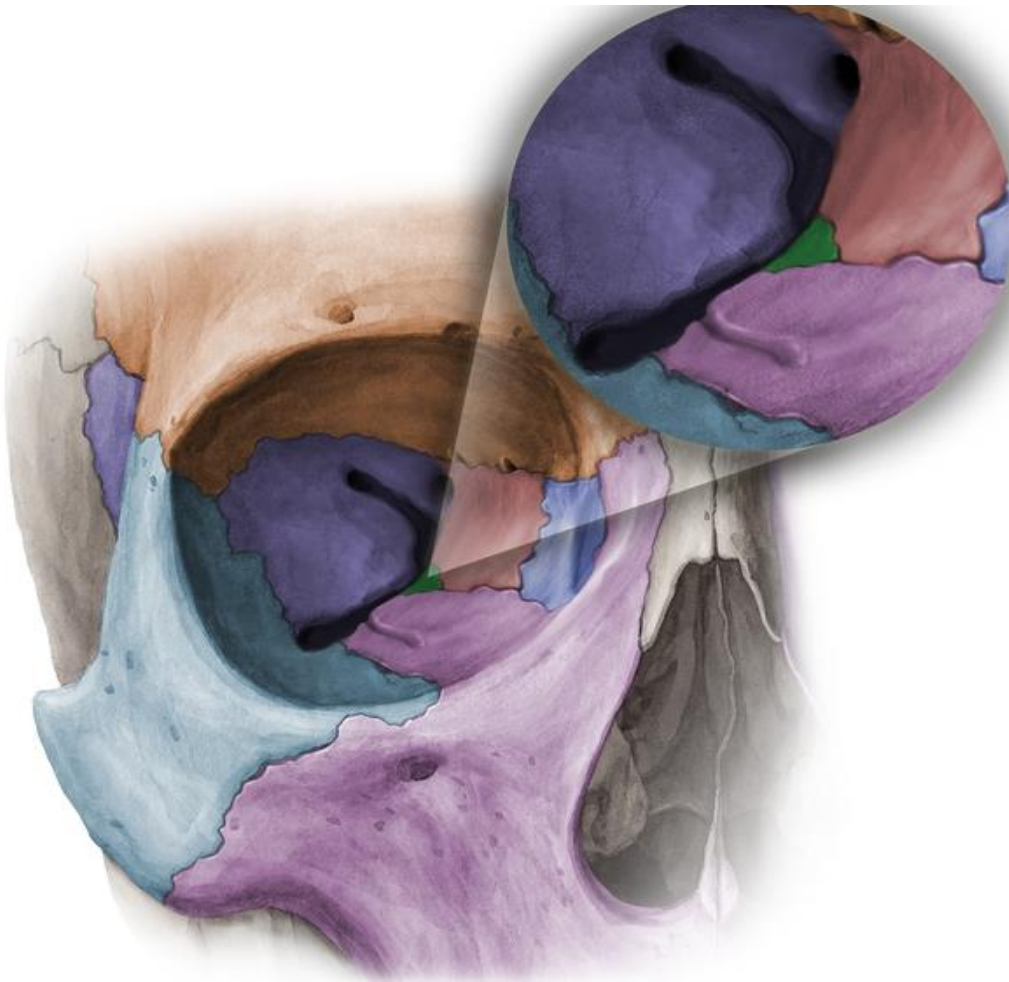
2- The greater wing of sphenoid



Floor:

Formed by:

1- The orbital plate of maxilla: separates the orbital cavity from the maxillary sinus



KEN
HUB

2- Palatine bone

Palatine bone

Participates in the floor of the orbit

Forms the medial wall of pterygopalatine fossa

Vertical plate

Horizontal plate

Participates in the hard palate

PTERYGOMAXILLARY FISSURE

PTERYGOPALATINE FOSSA

Sphenopalatine foramen

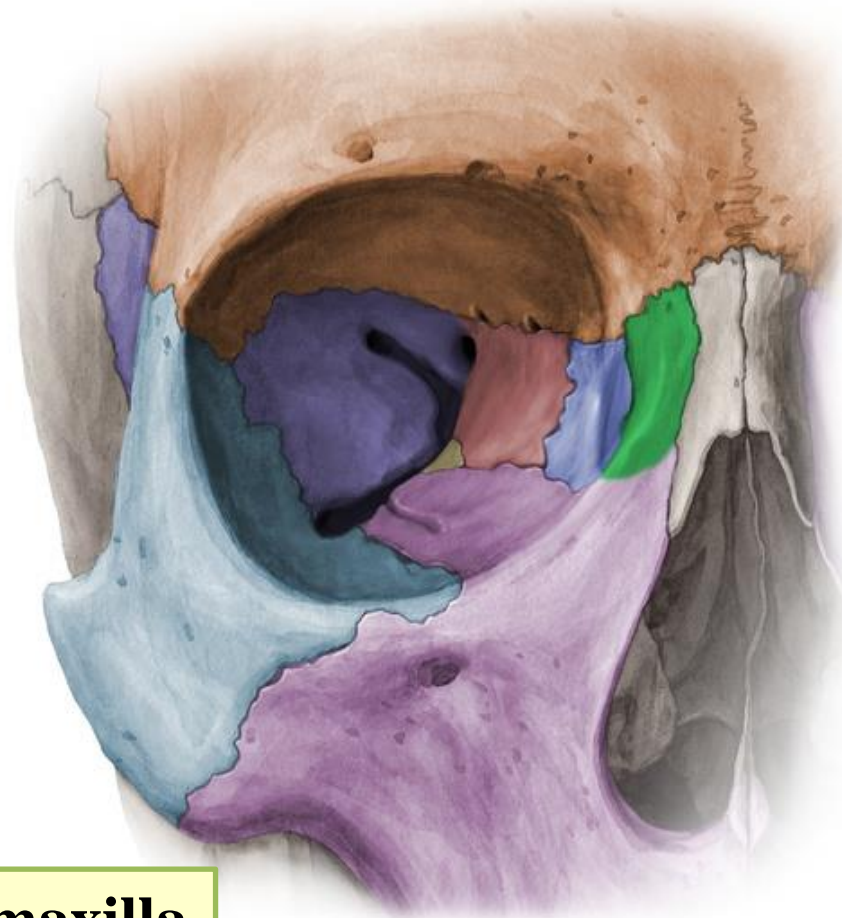
F. Netter M.D. © IGV

Medial wall:

Formed from before backward by:

- 1. The frontal process of maxilla**
- 2. The lacrimal bone**
- 3. The orbital plate of ethmoid**

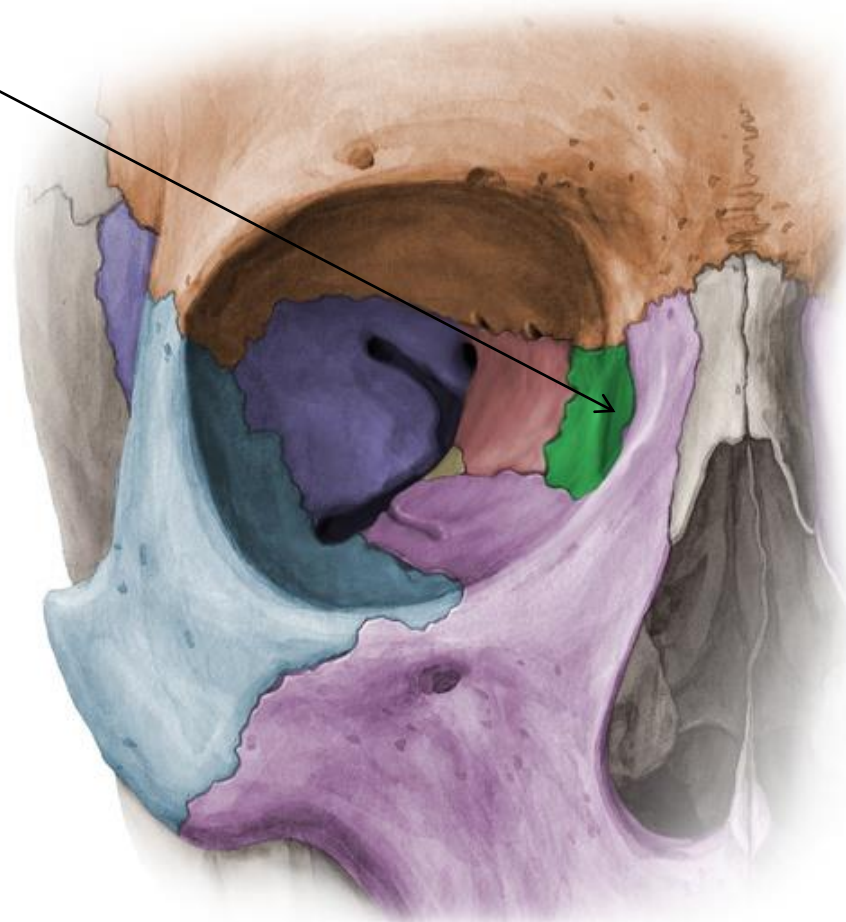
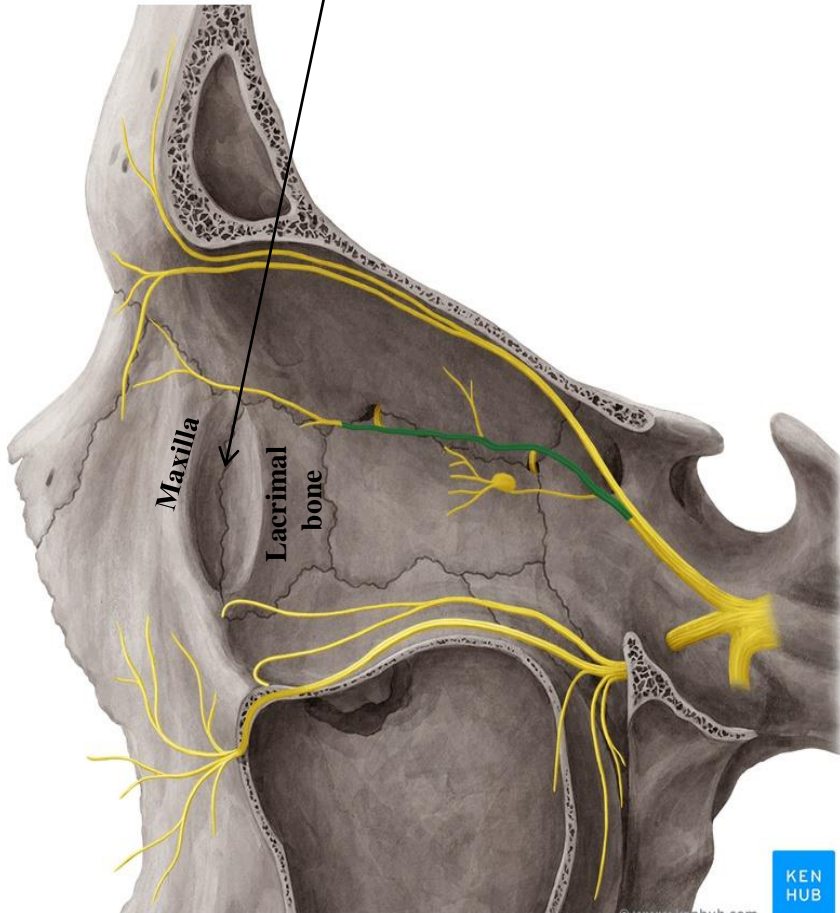
Medial walls are parallel to each other



- 1. The frontal process of maxilla**

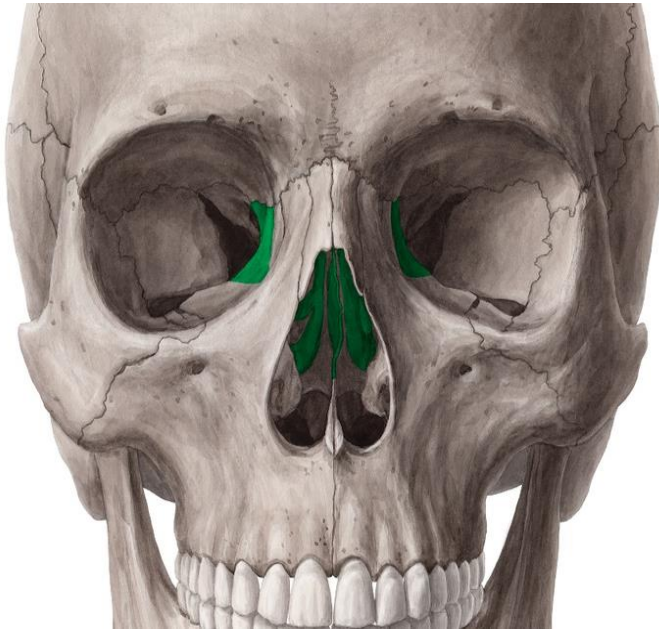Fossa for the lacrimal sac
(Lacrimal groove)

2. The lacrimal bone

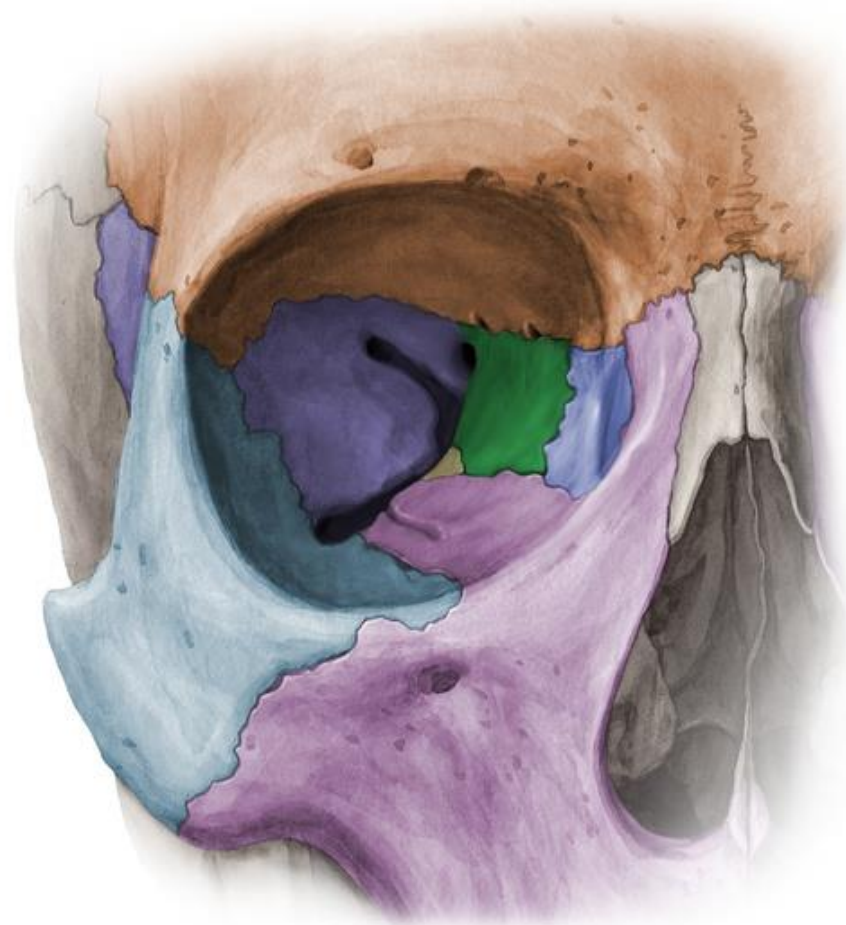


3. The orbital plate of ethmoid

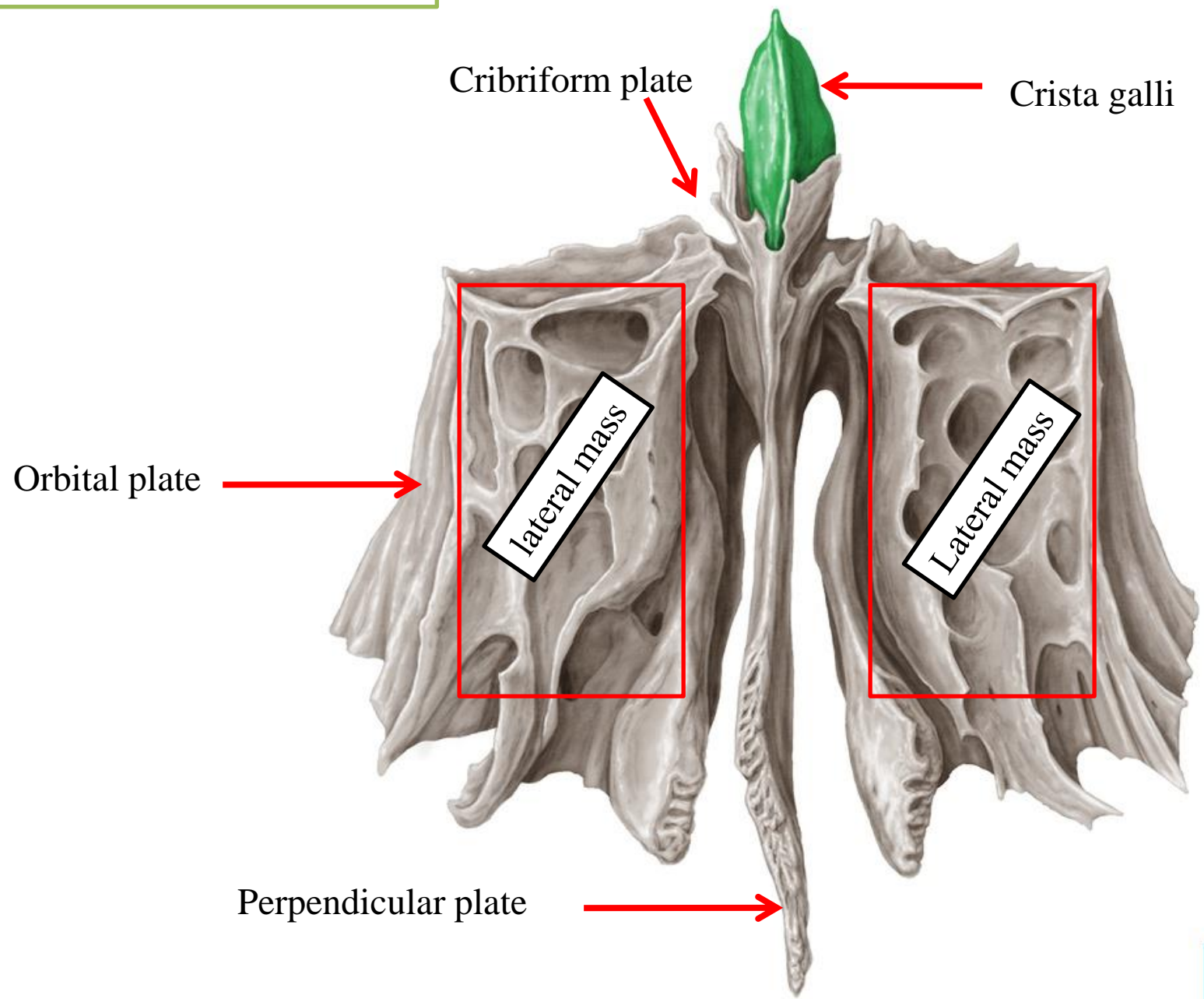
- The orbital plate of ethmoid separates the orbital cavity from the ethmoidal air sinuses
- It is a very thin wall



Ethmoid bone

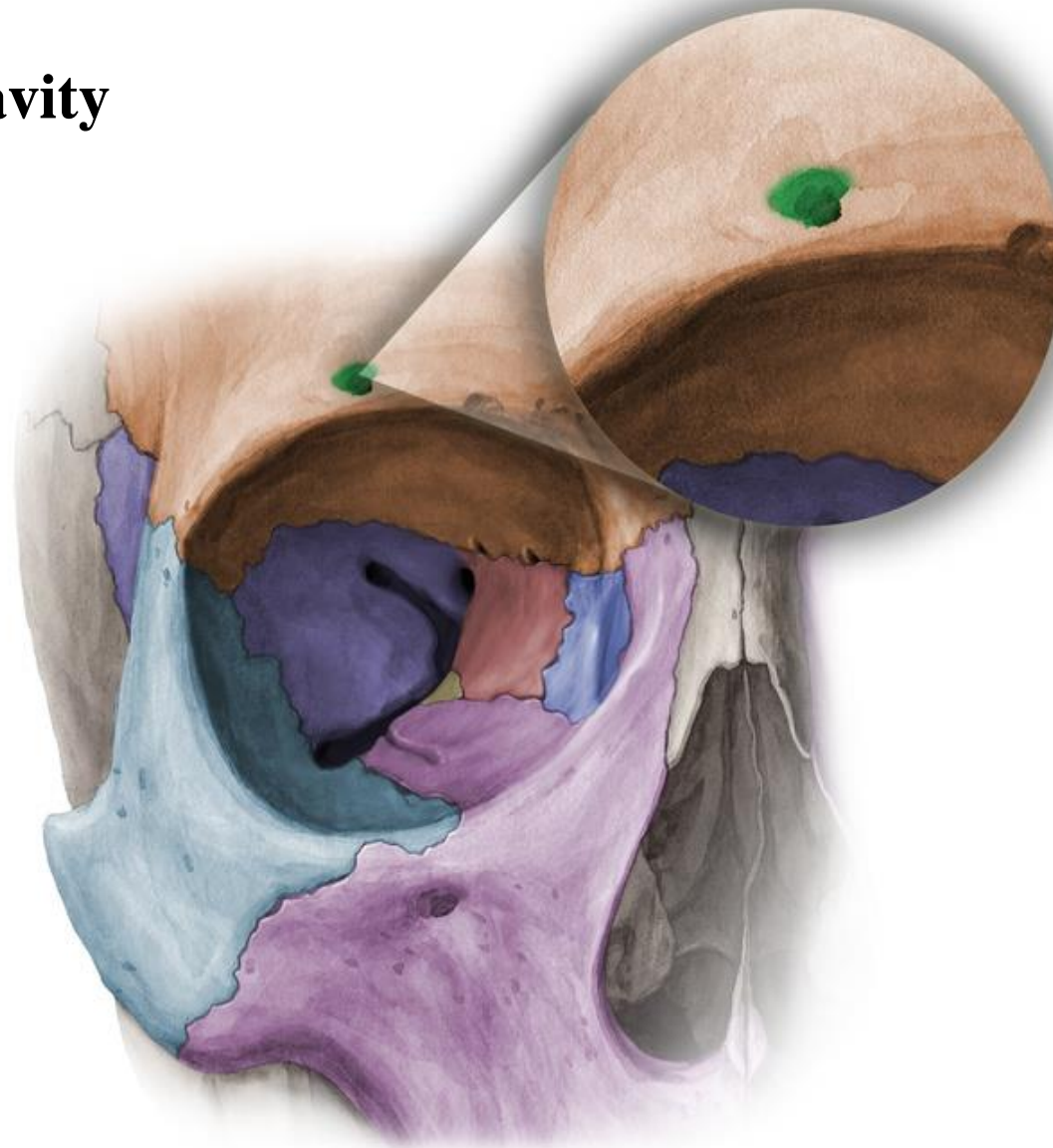


Ethmoid bone



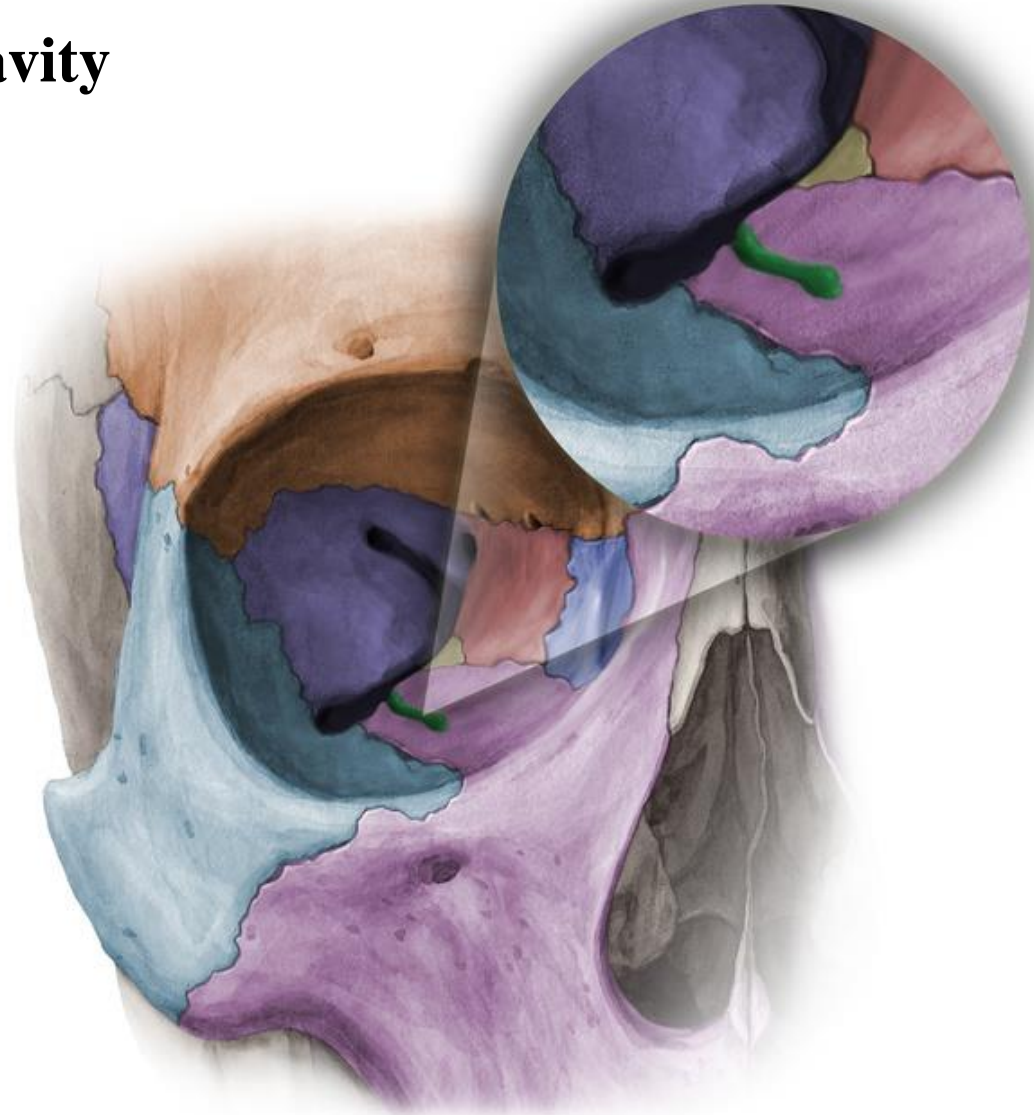
Openings Into the Orbital Cavity

1- **Supraorbital notch (Foramen)**: transmits the supraorbital nerve and blood vessels



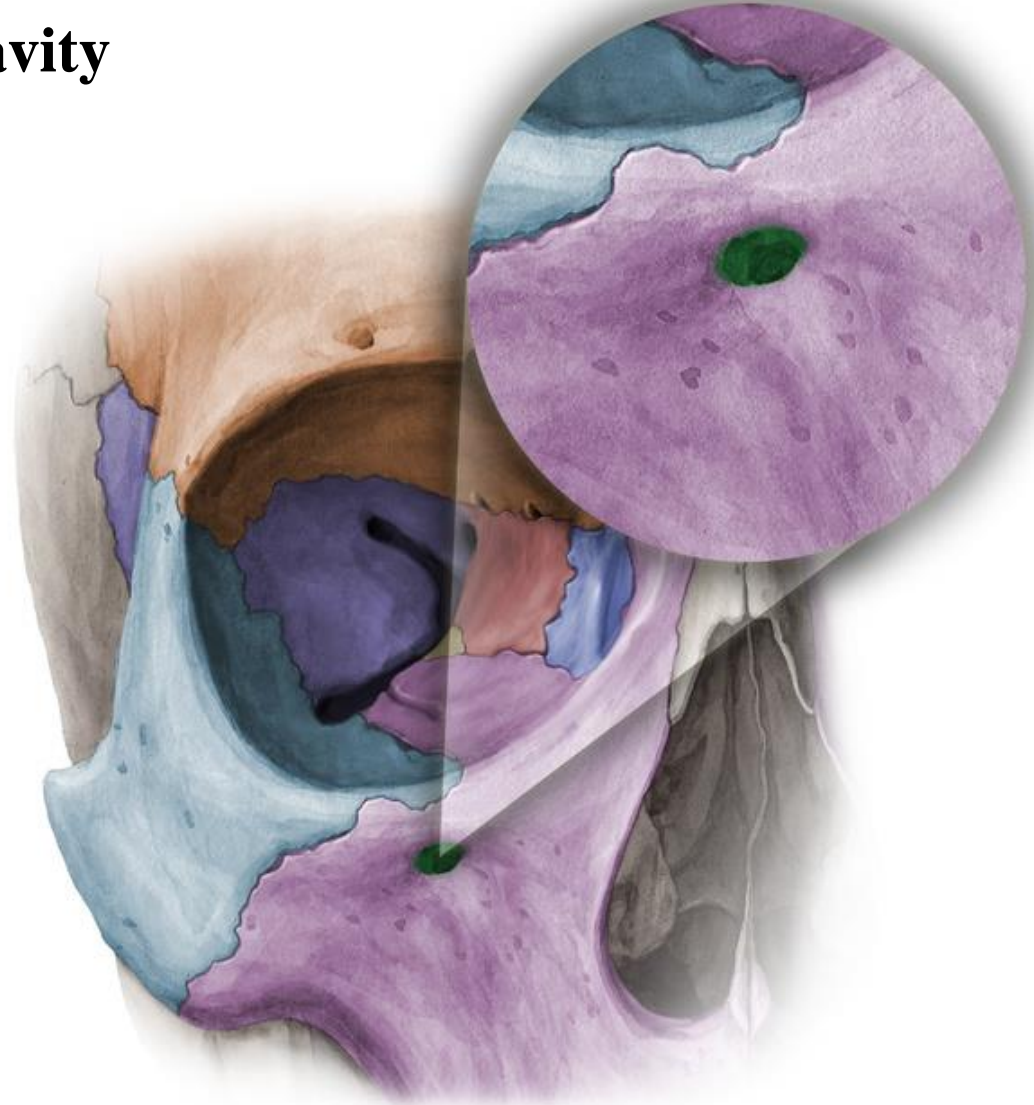
Openings Into the Orbital Cavity

2-Infraorbital groove and canal: Situated on the floor of the orbit
of the orbit
They transmit the
infraorbital nerve (a
continuation of the
maxillary nerve) and blood
vessels



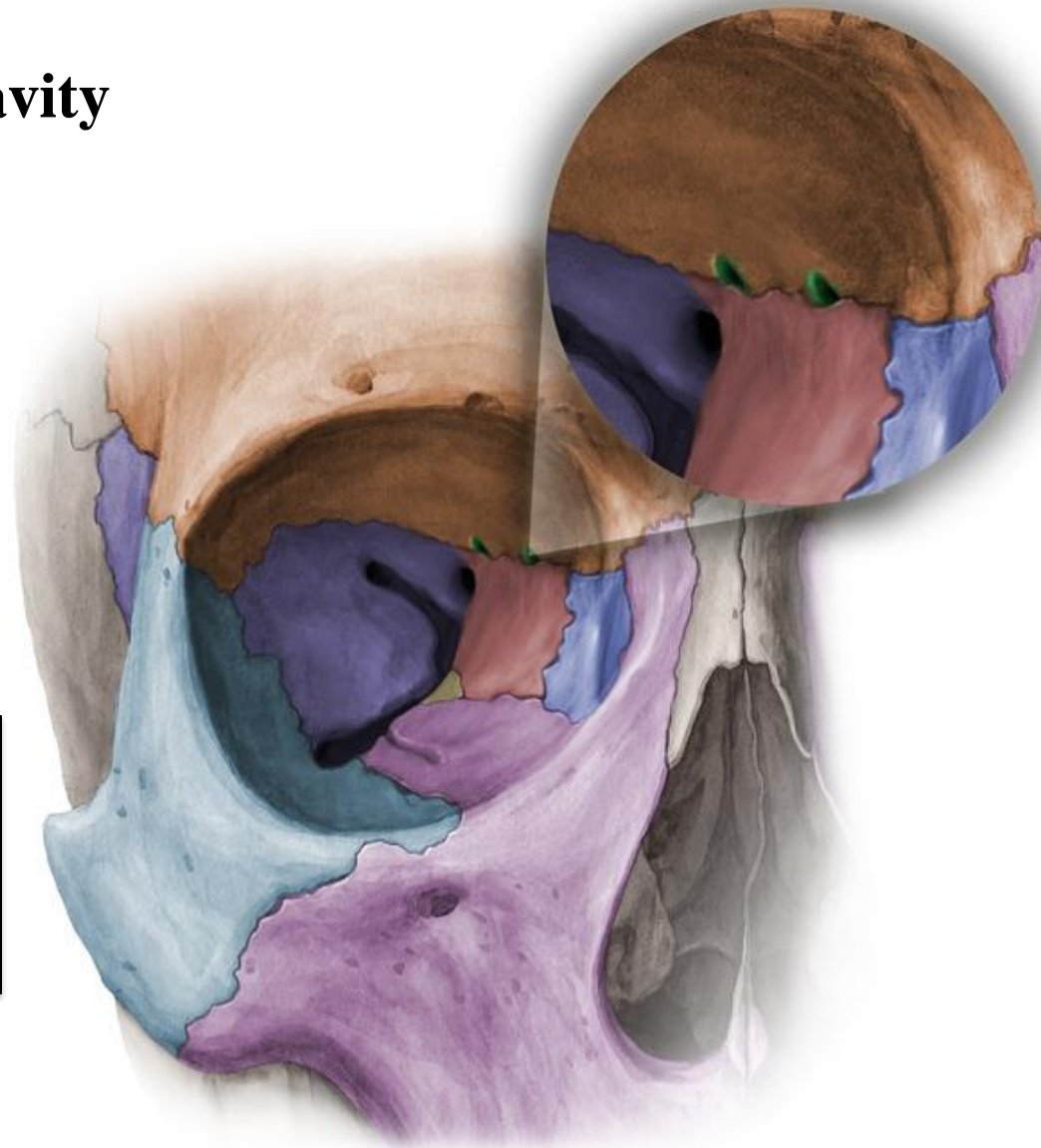
Openings Into the Orbital Cavity

3-Infraorbital foramen:
transmits the infraorbital
nerve (a continuation of
the maxillary nerve) and
blood vessels



Openings Into the Orbital Cavity

5- Anterior and posterior ethmoidal foramina:
transmit anterior and posterior ethmoidal nerves and vessels



Remember:

Anterior and posterior ethmoidal nerves are branches of nasociliary nerve (ophthalmic nerve)

Note: Anterior and posterior ethmoidal foramina are located between the roof and the medial wall

Openings Into the Orbital Cavity

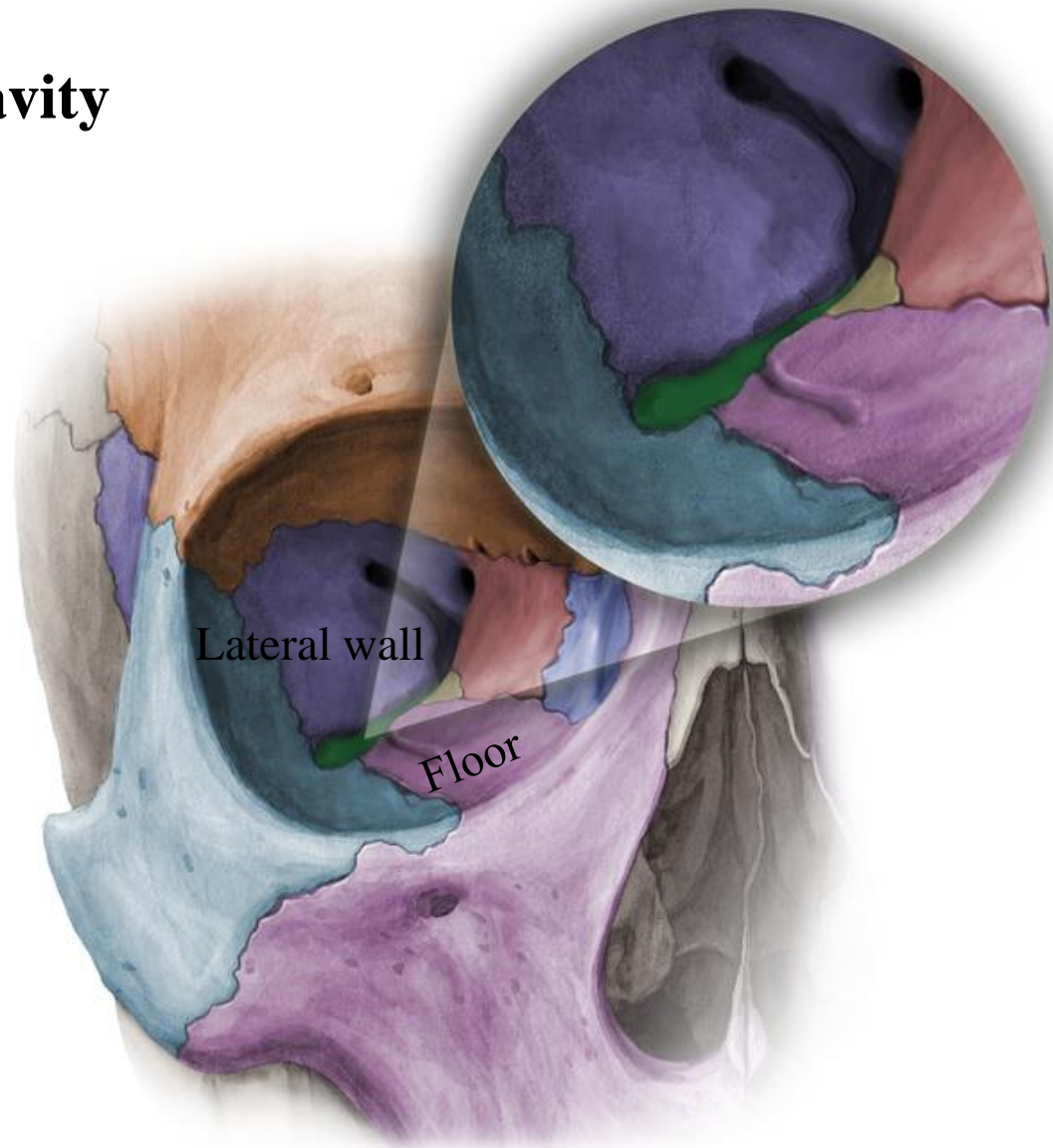
6-Inferior orbital fissure:

Located posteriorly between the maxilla and the greater wing of sphenoid

It communicates with the infratemporal and pterygopalatine fossae.

It transmits

- 1-Maxillary nerve and its zygomatic branch
- 2-Infraorbital vessels
- 3- Inferior ophthalmic vein (or a vein communicating with pterygoid plexus of veins)

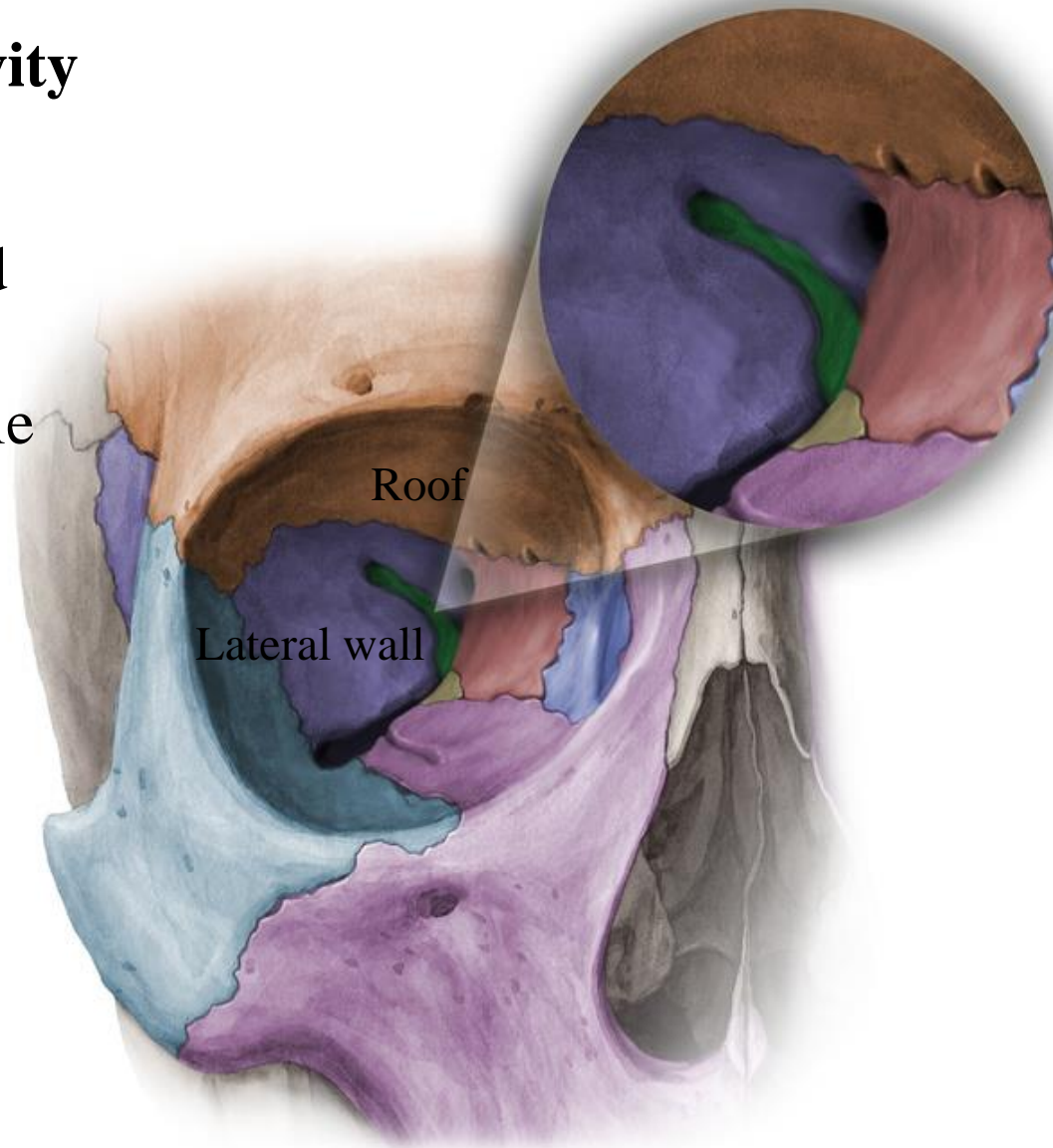


Note: **inferior orbital fissure** is located between the floor and the lateral wall

Openings Into the Orbital Cavity

7- Superior orbital fissure:

- Located between the greater and lesser wings of sphenoid
- It communicates with the middle cranial fossa.
- It transmits
 - Lacrimal nerve
 - Frontal nerve
 - Trochlear nerve
 - Oculomotor nerve (upper and lower divisions)
 - Abducent nerve
 - Nasociliary nerve
 - Superior ophthalmic vein



Note: **superior orbital fissure** is located between the roof and the lateral wall

Note the **superior orbital fissure** opens anteriorly into orbit and posteriorly into middle cranial fossa

Note the **inferior orbital fissure** opens anteriorly into orbit and posteriorly into two fossae: one big (infratemporal fossa) and one small (Pterygo-palatine fossa)

Use the wire within each of the skull fissures to determine precisely the communications of superior and inferior orbital fissures

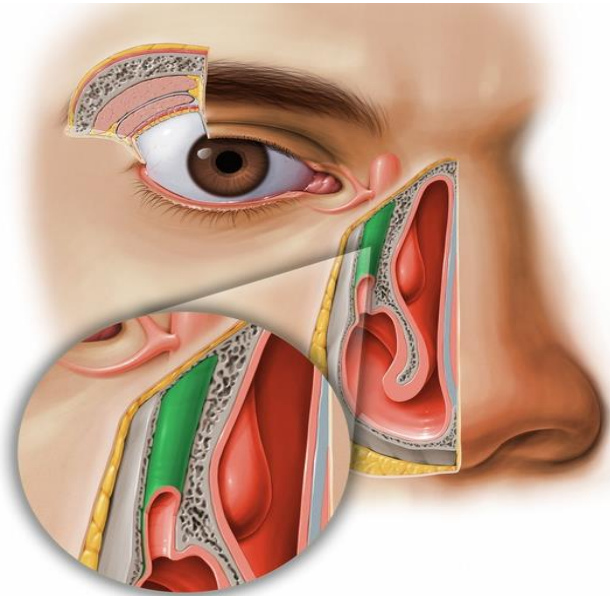
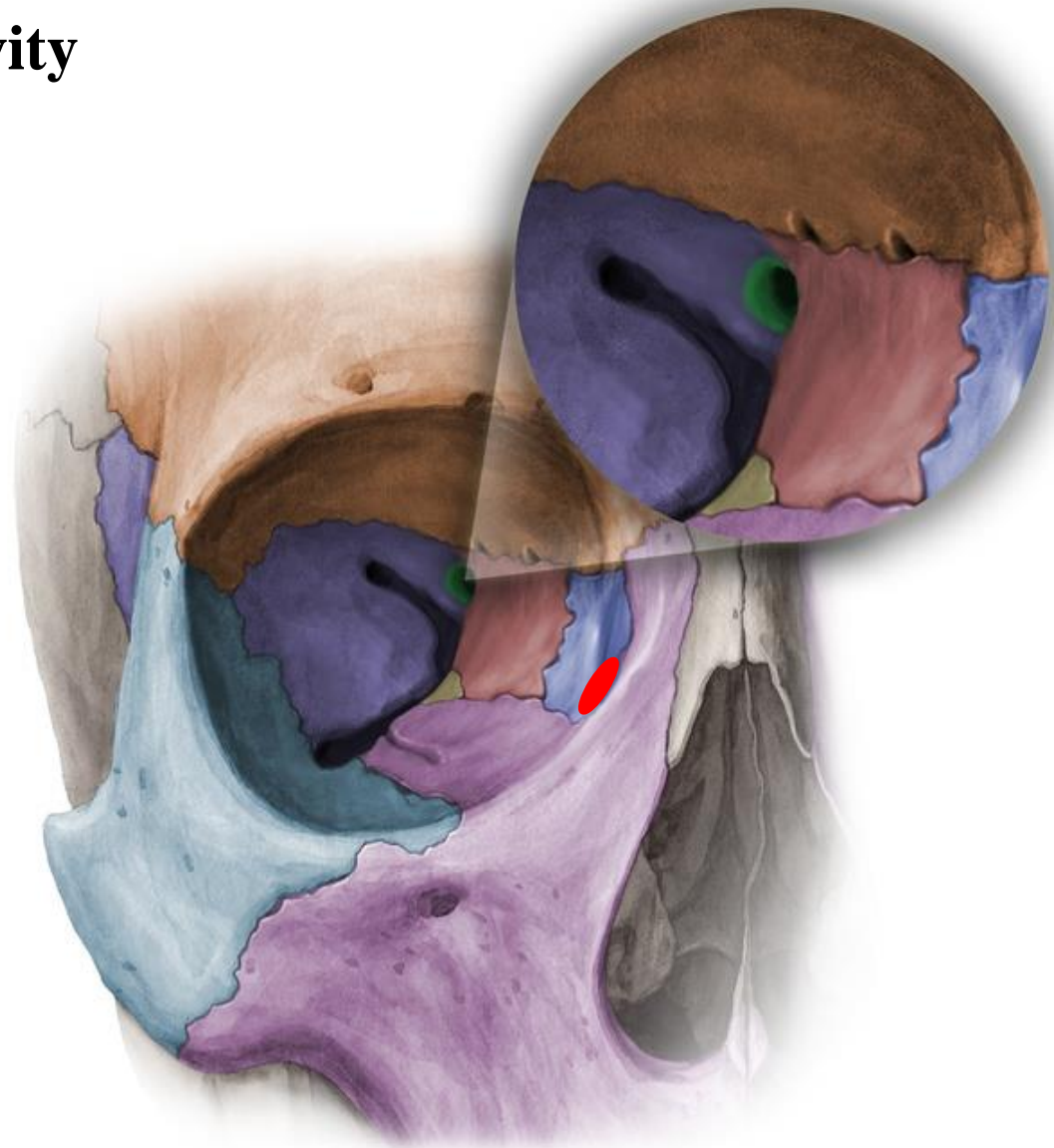
Openings Into the Orbital Cavity

8-Optic canal:

- Located in the lesser wing of the sphenoid (at the junction with the body)
- It communicates with the middle cranial fossa.
- It transmits the optic nerve and the ophthalmic artery

9-Nasolacrimal canal:

Located anteriorly on the medial wall; it communicates with the nose
It transmits the nasolacrimal duct.



MUSCLES OF THE EYE

There are two groups of muscles within the orbit:

1-Extrinsic muscles of eyeball (extra-ocular muscles) involved in **movements of the eyeball or raising upper eyelid**

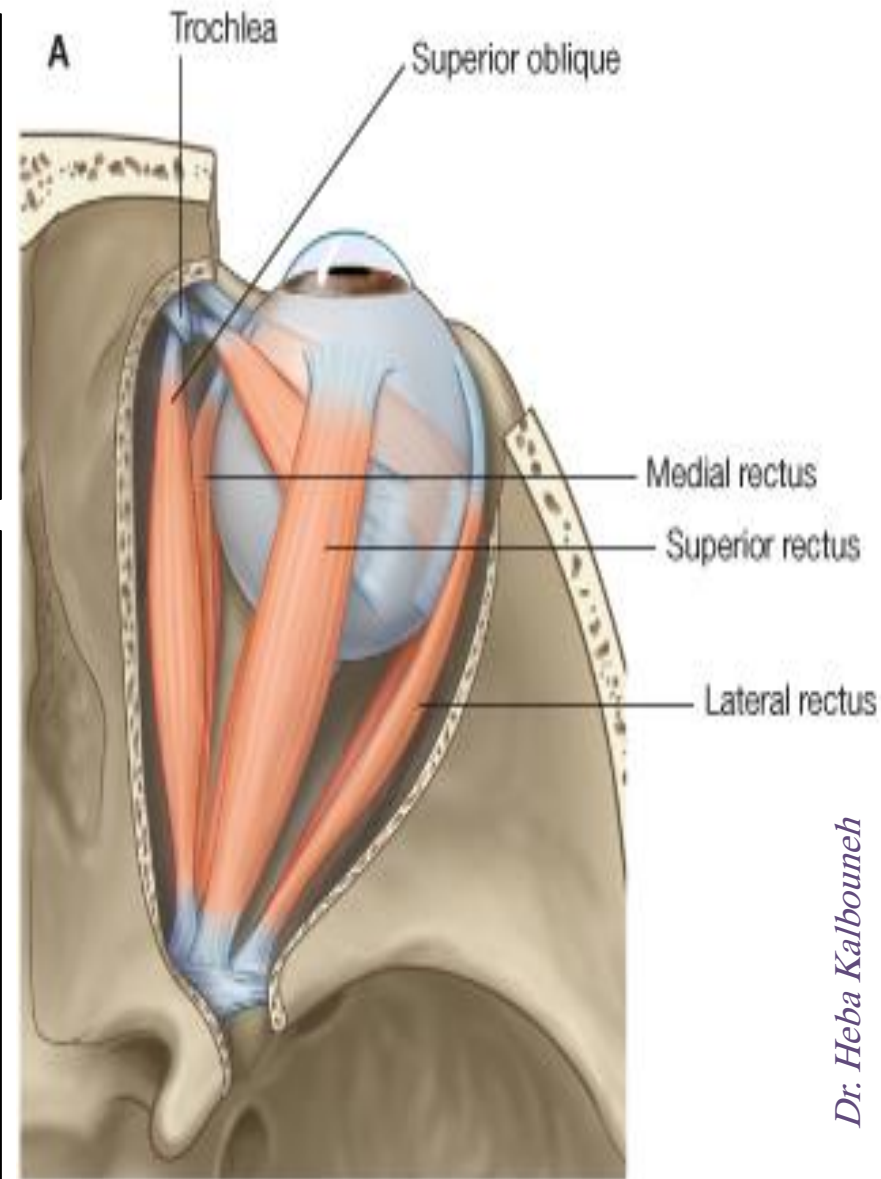
2-Intrinsic muscles (intra-ocular muscles) within the eyeball, which control **the shape of the lens and size of the pupil.**

The extrinsic muscles include

1. SUPERIOR RECTUS
2. INFERIOR RECTUS
3. MEDIAL RECTUS
4. LATERAL RECTUS
5. SUPERIOR OBLIQUE
6. INFERIOR OBLIQUE

7. LEVATOR PALPEBRAE SUPERIORIS

4 recti muscles
2 oblique muscles

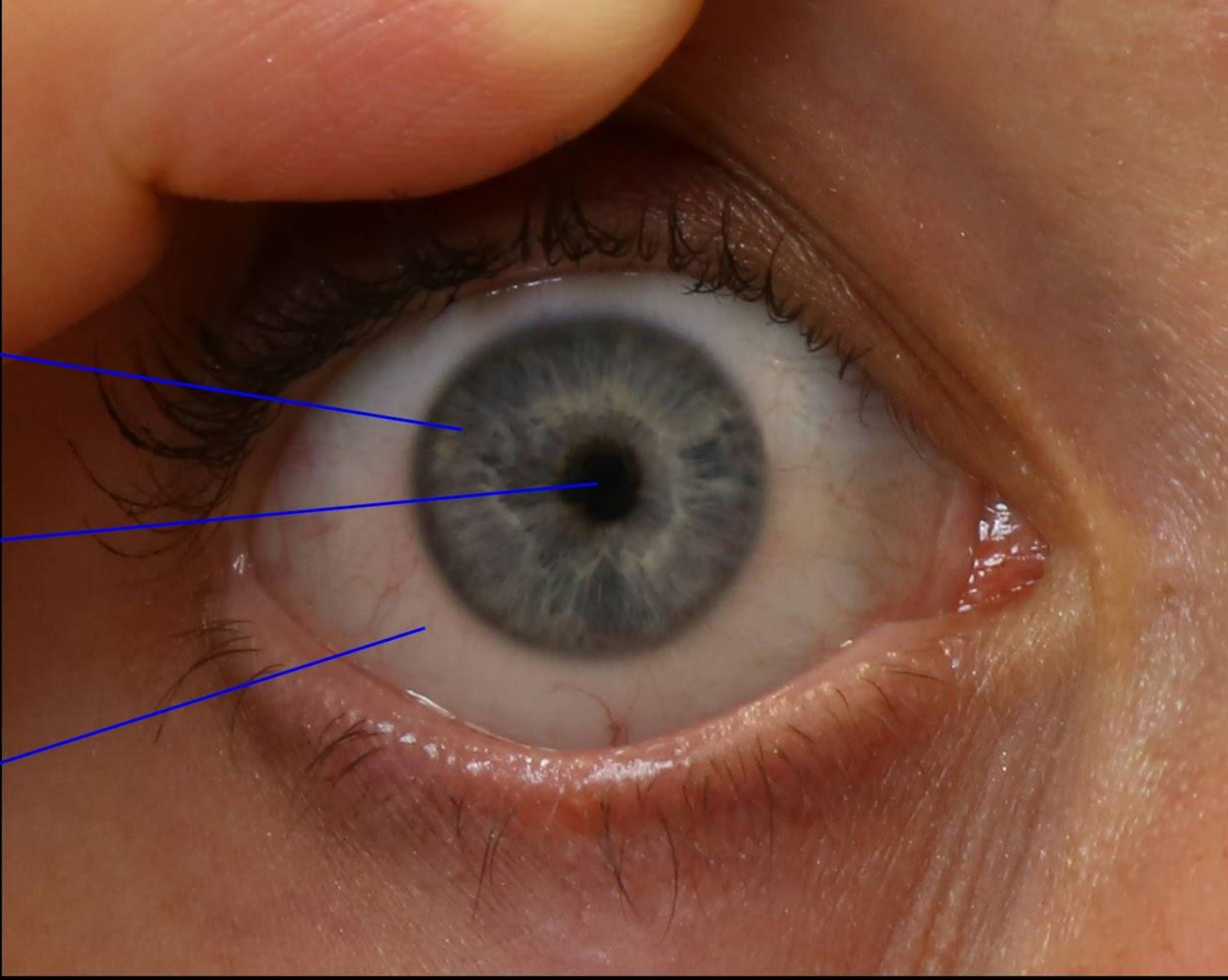


The intrinsic muscles (intraocular muscles) include: 1- Ciliary muscle 2- Sphincter pupillae 3- Dilator pupillae

Iris

Pupil

Sclera



Orbital region, anterior

Movements of the eyeball

Elevation-moving the pupil/cornea superiorly

Depression-moving the pupil/cornea inferiorly

Abduction-moving the pupil/cornea laterally

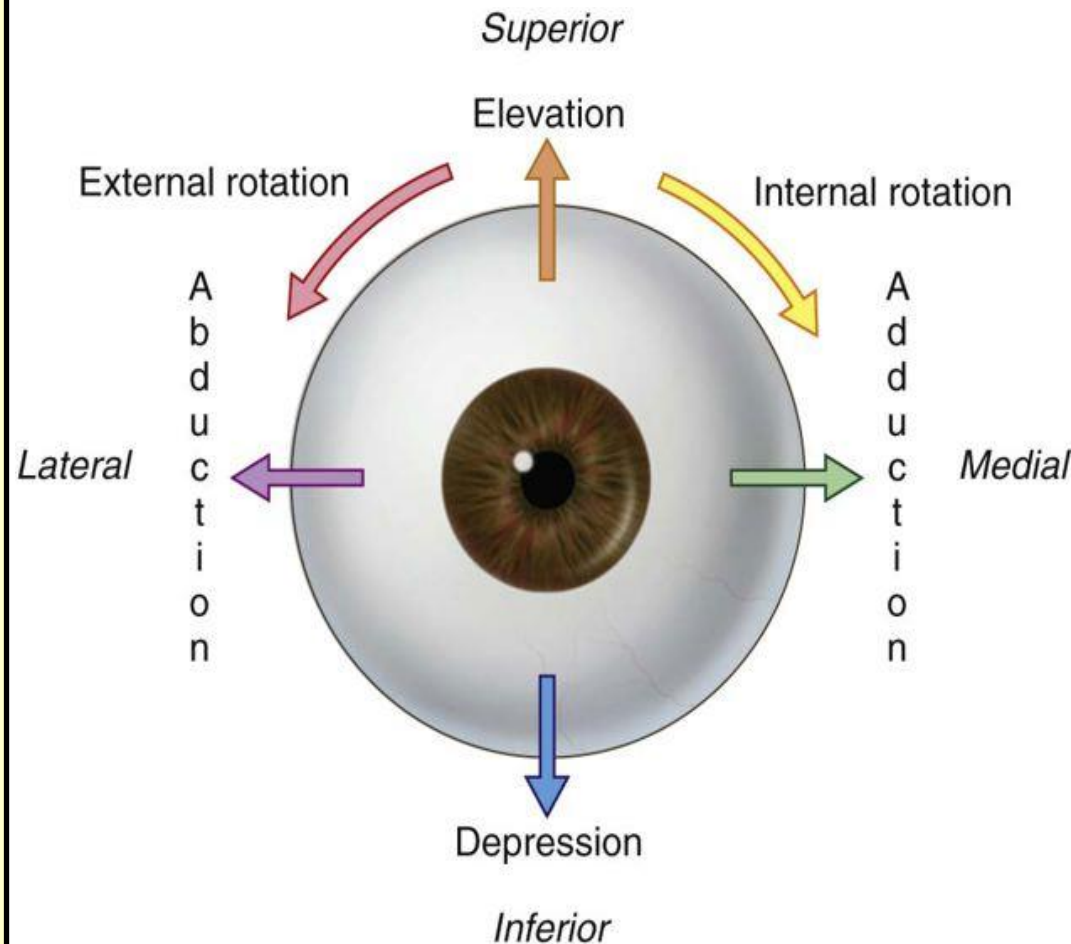
Adduction-moving the pupil/cornea medially

Internal rotation-rotating the upper part of the pupil/cornea medially (or towards the nose)

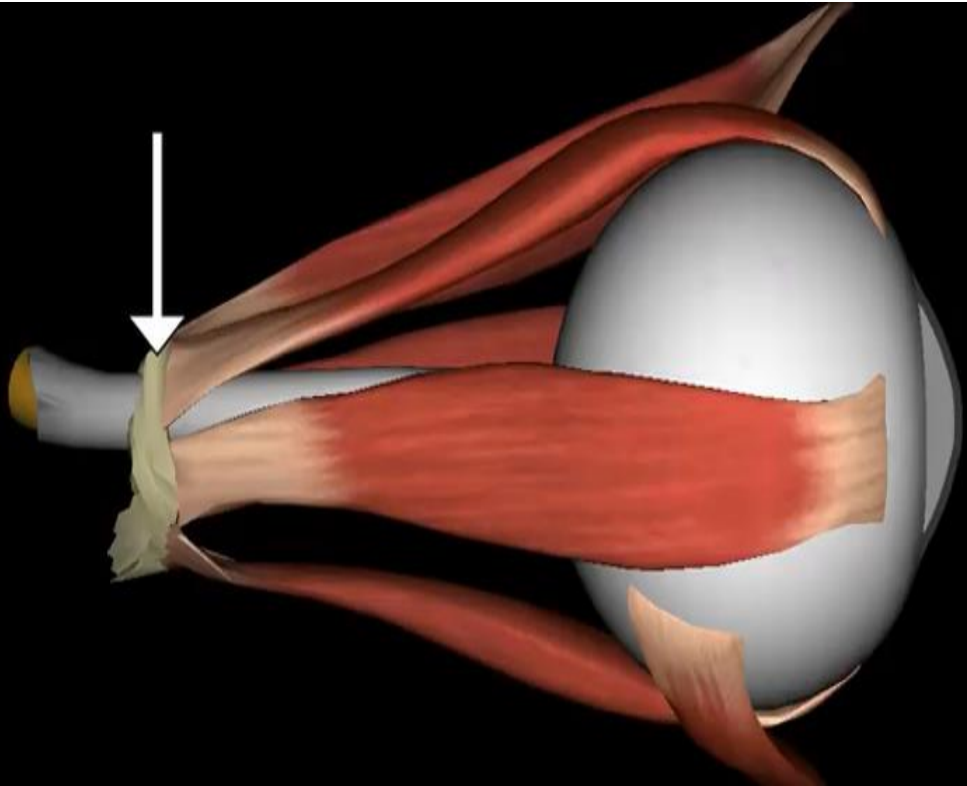
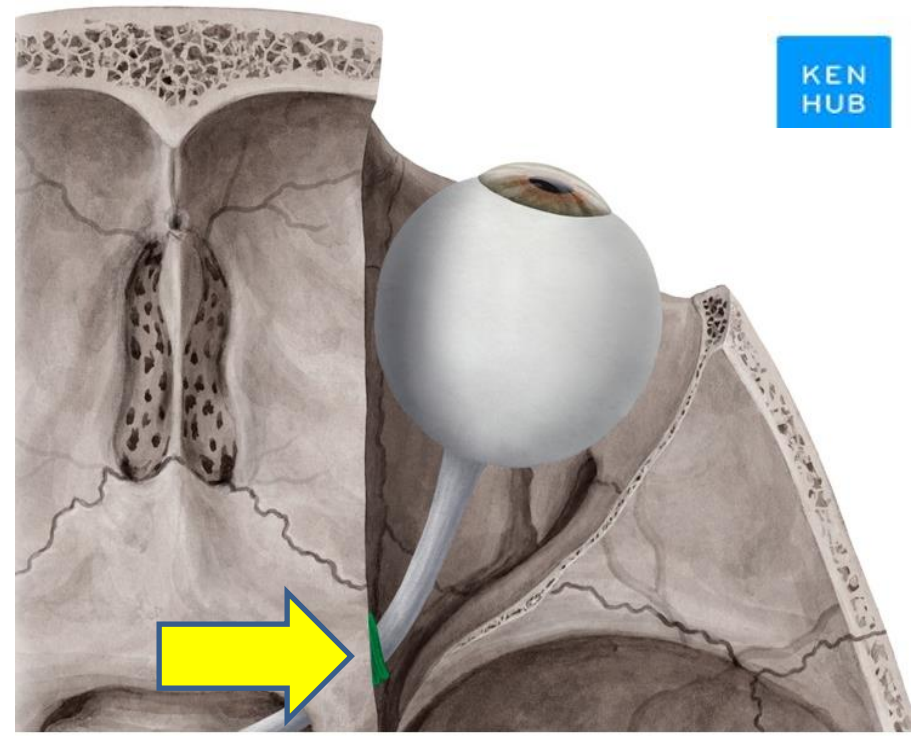
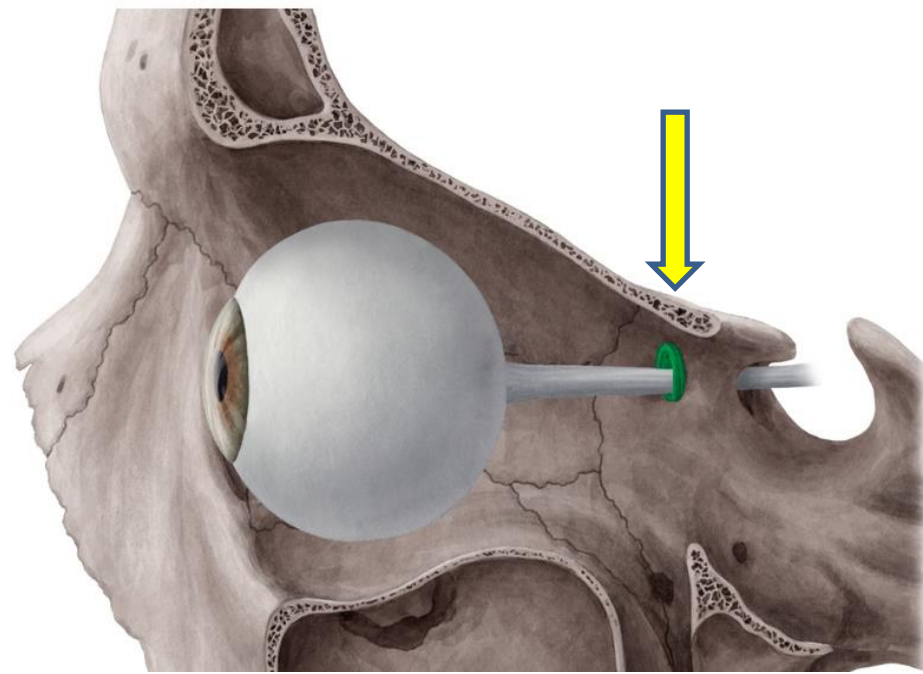
Intorsion

External rotation-rotating the upper part of the pupil/cornea laterally (or towards the temple)

Extorsion



Common tendinous ring is a fibrous ring which surrounds the optic canal and part of the superior orbital fissure at the apex of the orbit. It is the common origin of the four recti muscles



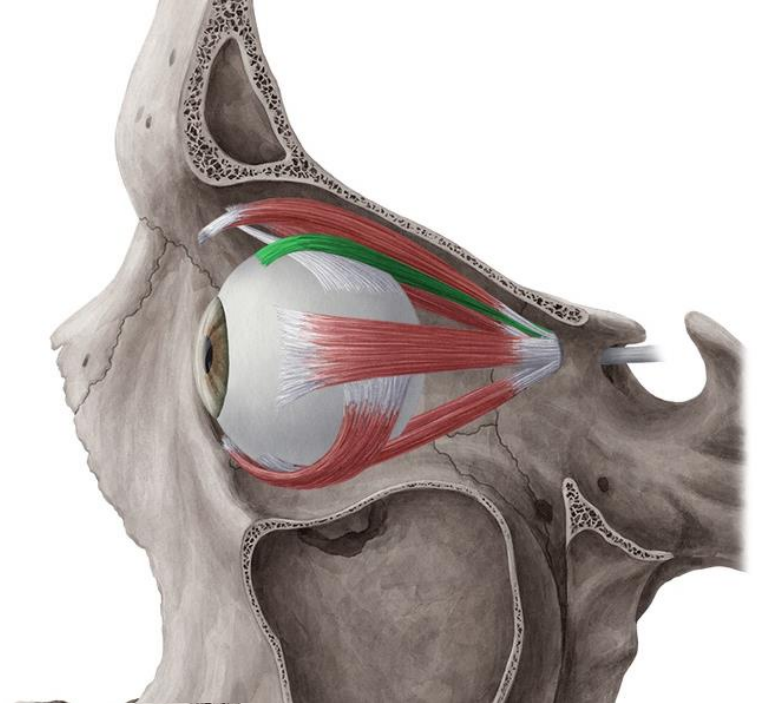
1-Superior rectus

Origin: Superior part of common tendinous ring

Insertion: Anterior half of eyeball superiorly (*in front of the equator*)

Nerve supply: Oculomotor nerve[III]/ superior division

Action: Elevation, adduction (Raises cornea upward and medially)



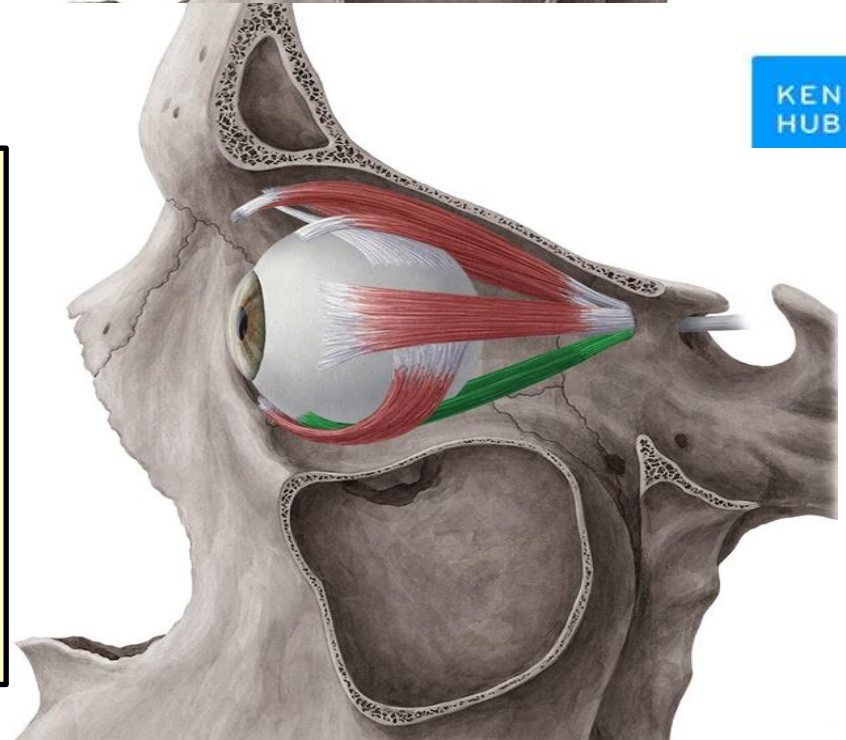
2-Inferior rectus

Origin: Inferior part of common tendinous ring

Insertion: Anterior half of eyeball inferiorly (*in front of the equator*)

Nerve supply: Oculomotor nerve[III]/ inferior division

Action: Depression, adduction (Depresses cornea downward and medially)



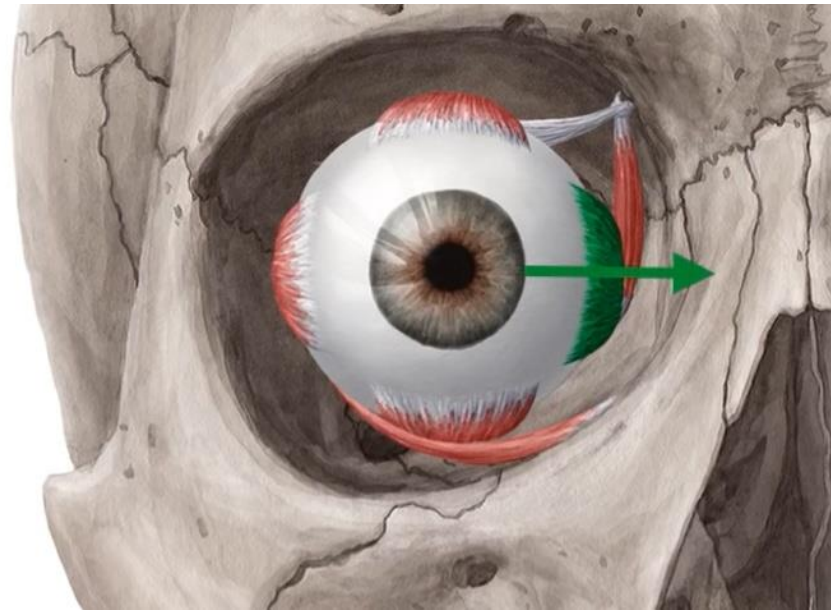
3-Medial rectus

Origin: Medial part of common tendinous ring

Insertion: Anterior half of eyeball medially (*in front of the equator*)

Nerve supply: Oculomotor nerve [III]/ inferior division

Action: Adduction ((Rotates eyeball so that cornea looks medially))



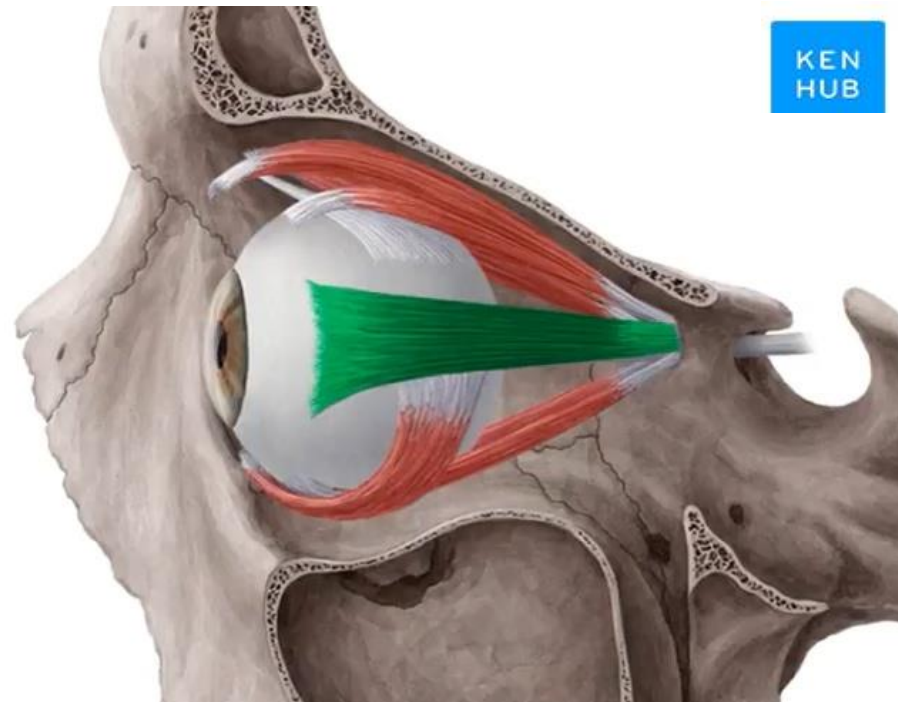
4-Lateral rectus

Origin: Lateral part of common tendinous ring

Insertion: Anterior half of eyeball laterally (*in front of the equator*)

Nerve supply: Abducent nerve [VI]

Action: Abduction (Rotates eyeball so that cornea looks laterally)



5-Superior oblique

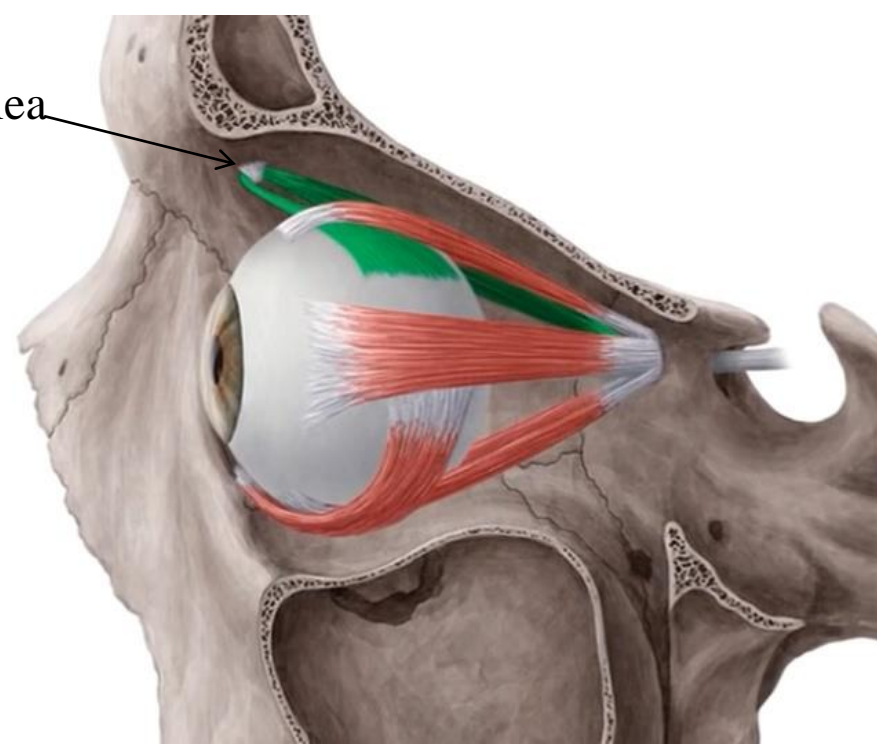
Origin: Posterior part of the roof

Insertion: Passes through pulley (trochlea) and is attached to lateral posterior half of eyeball (*behind the equator*)

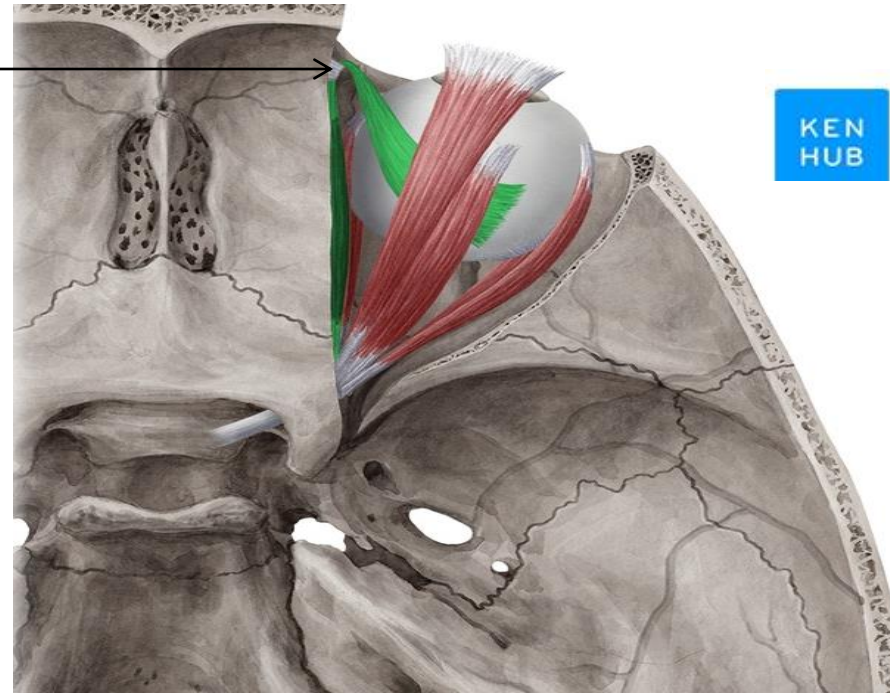
Nerve supply: Trochlear nerve [IV]

Action: Depression, abduction, intorsion (Rotates eyeball so that cornea looks downward and laterally)

Trochlea



Trochlea

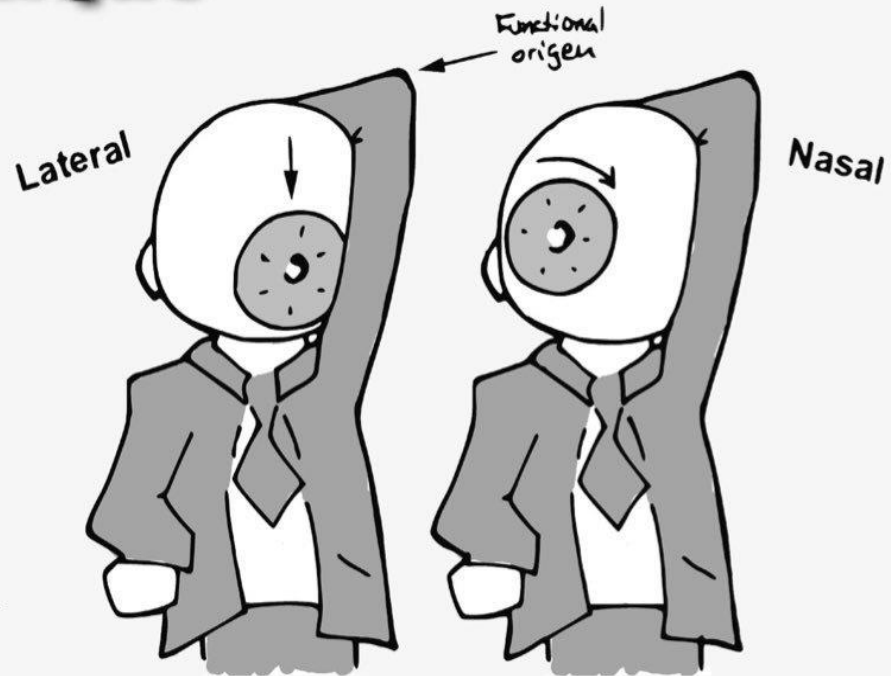


(Rotates eyeball so that cornea looks downward and laterally) **AS IF YOU ARE LOOKING TO YOUR SHOULDER**

The Superior Oblique

To simulate the action of the superior oblique, you can pretend that your head is a large eyeball. Throw an arm up and wrap it around the back of your head.

Your elbow becomes the trochlear pulley ... if you pull your arm, you're whole head should twist. The direction of head movement, either up-down or rotational, will depend upon which direction you're looking when you start pulling.



6-Inferior oblique

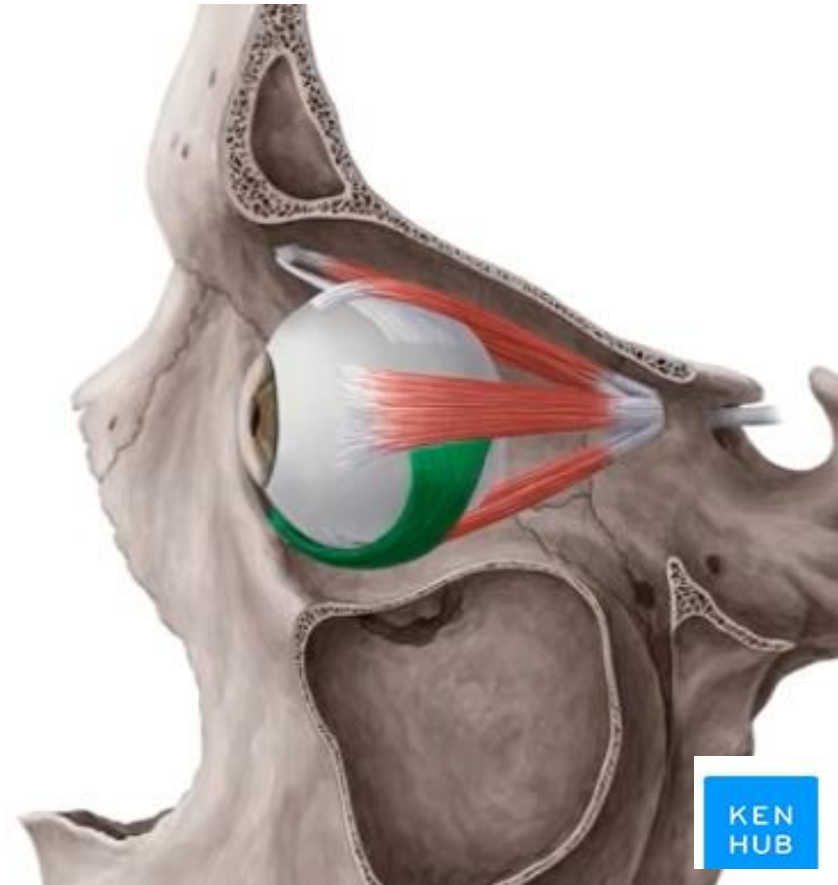
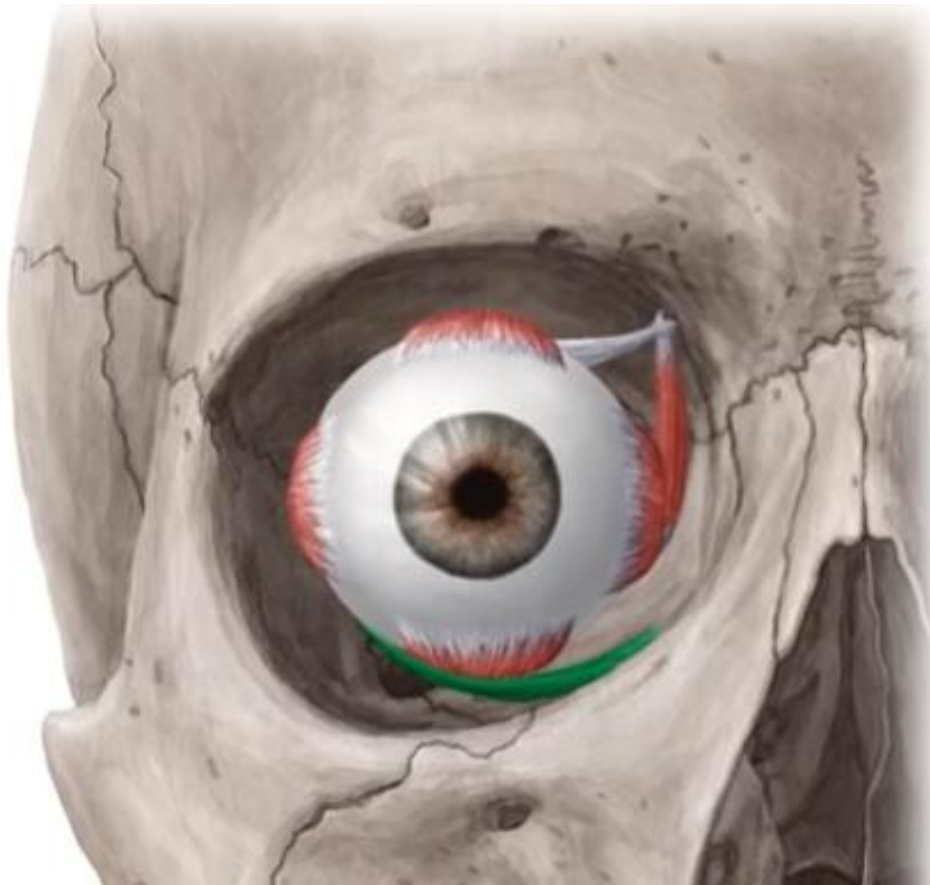Origin: medial part of the floor (anteriorly)

Insertion: lateral posterior half of eyeball (*behind the equator*)

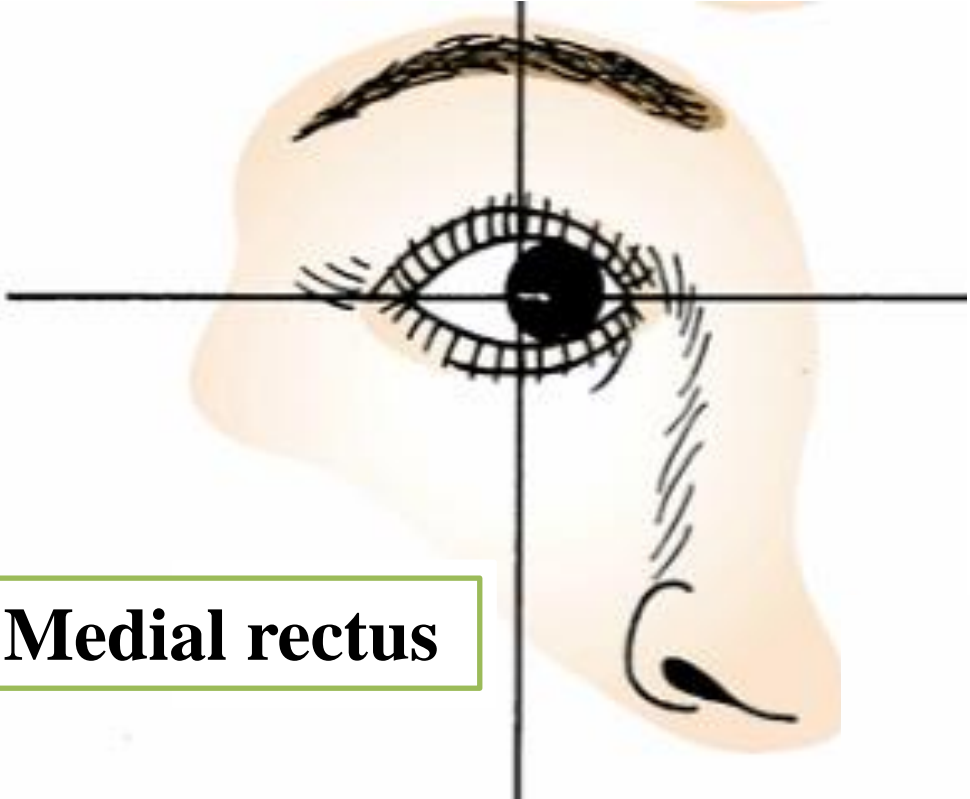
Nerve supply: Oculomotor nerve [III]/ inferior division

Action: Elevation, abduction, extorsion

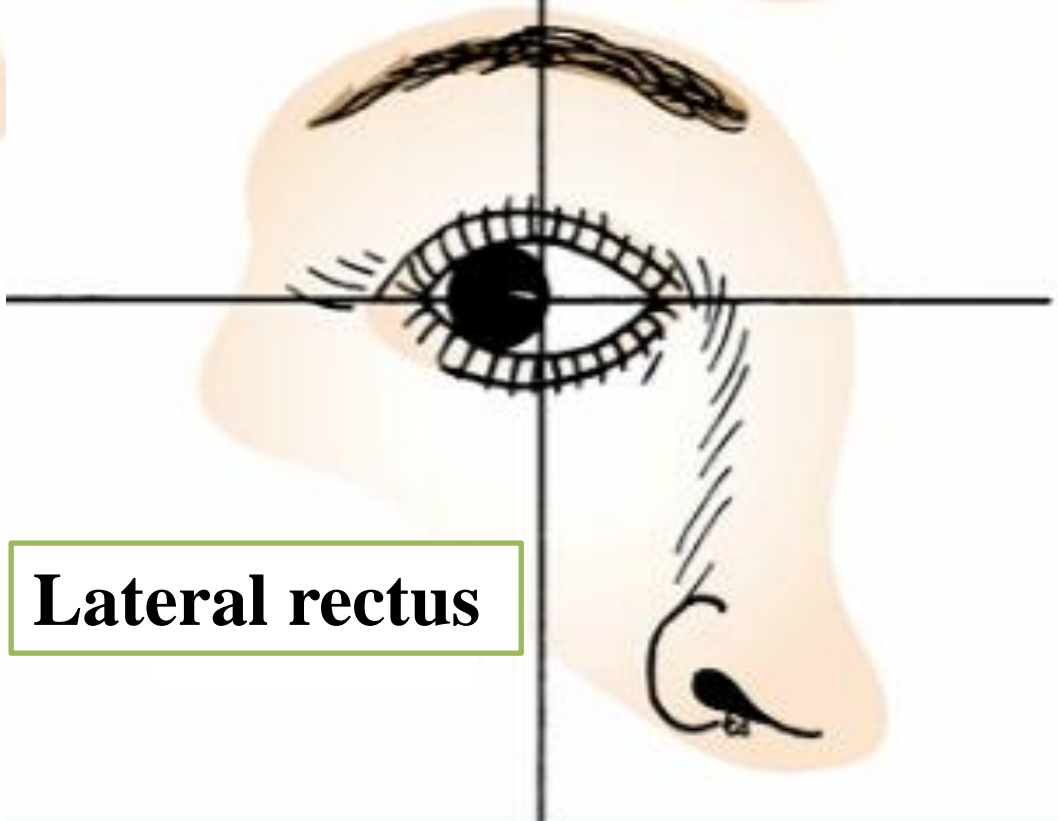
(Rotates eyeball so that cornea looks upward and laterally)

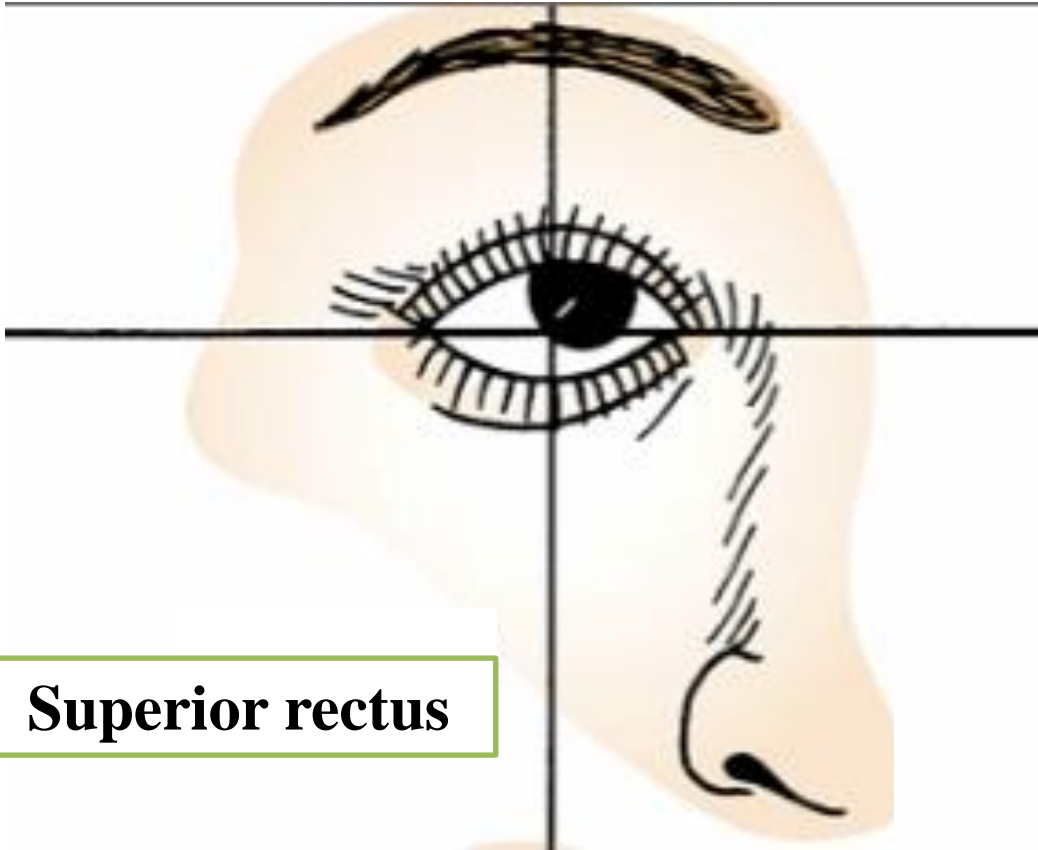


Medial rectus

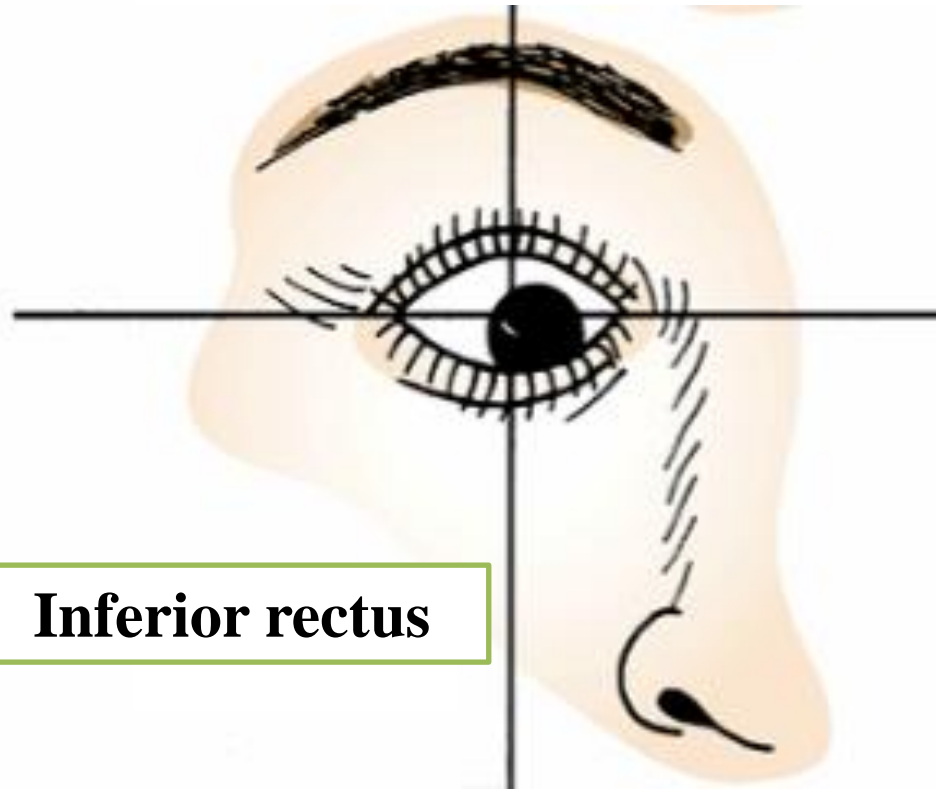


Lateral rectus

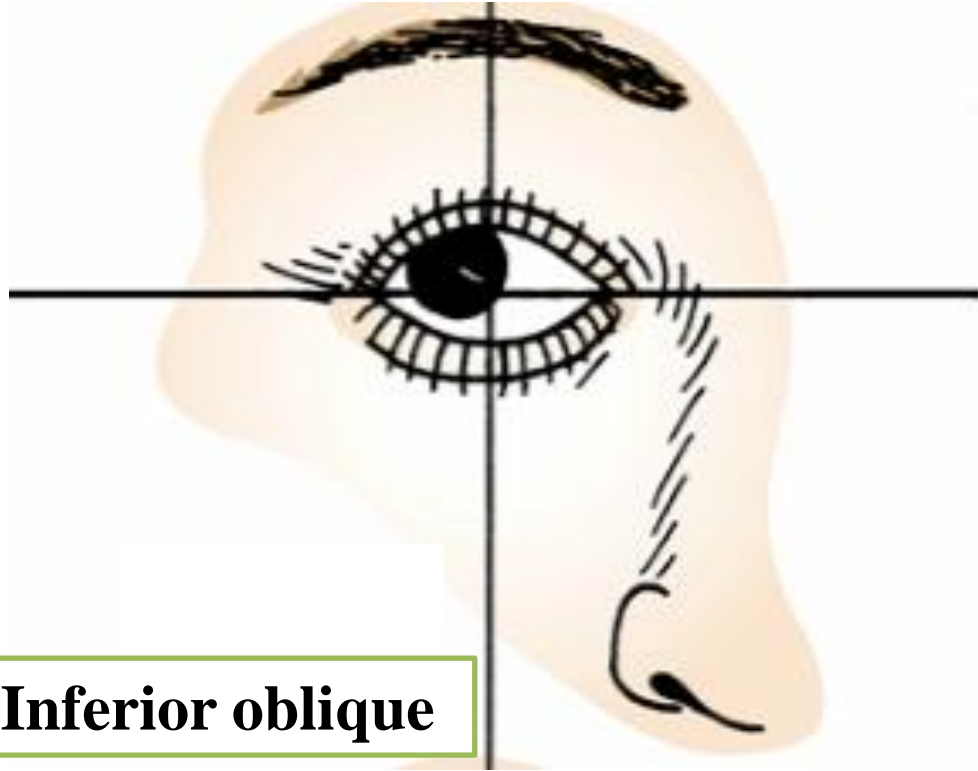




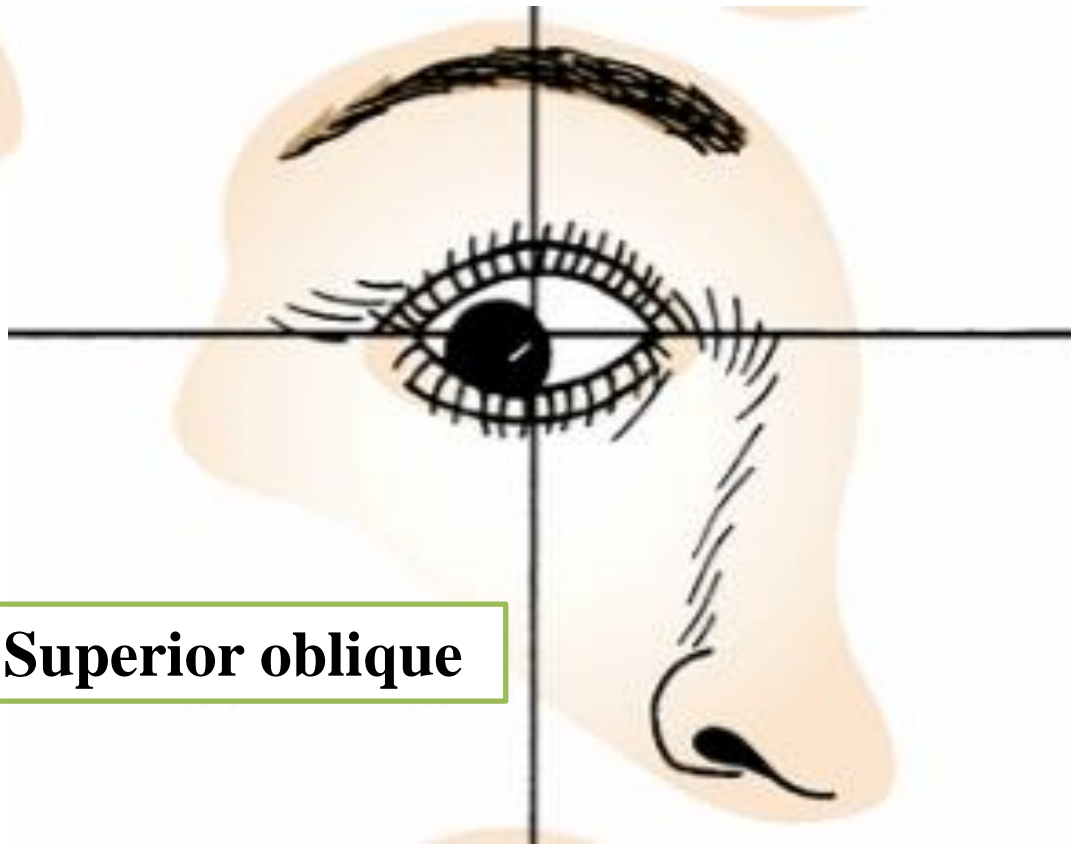
Superior rectus



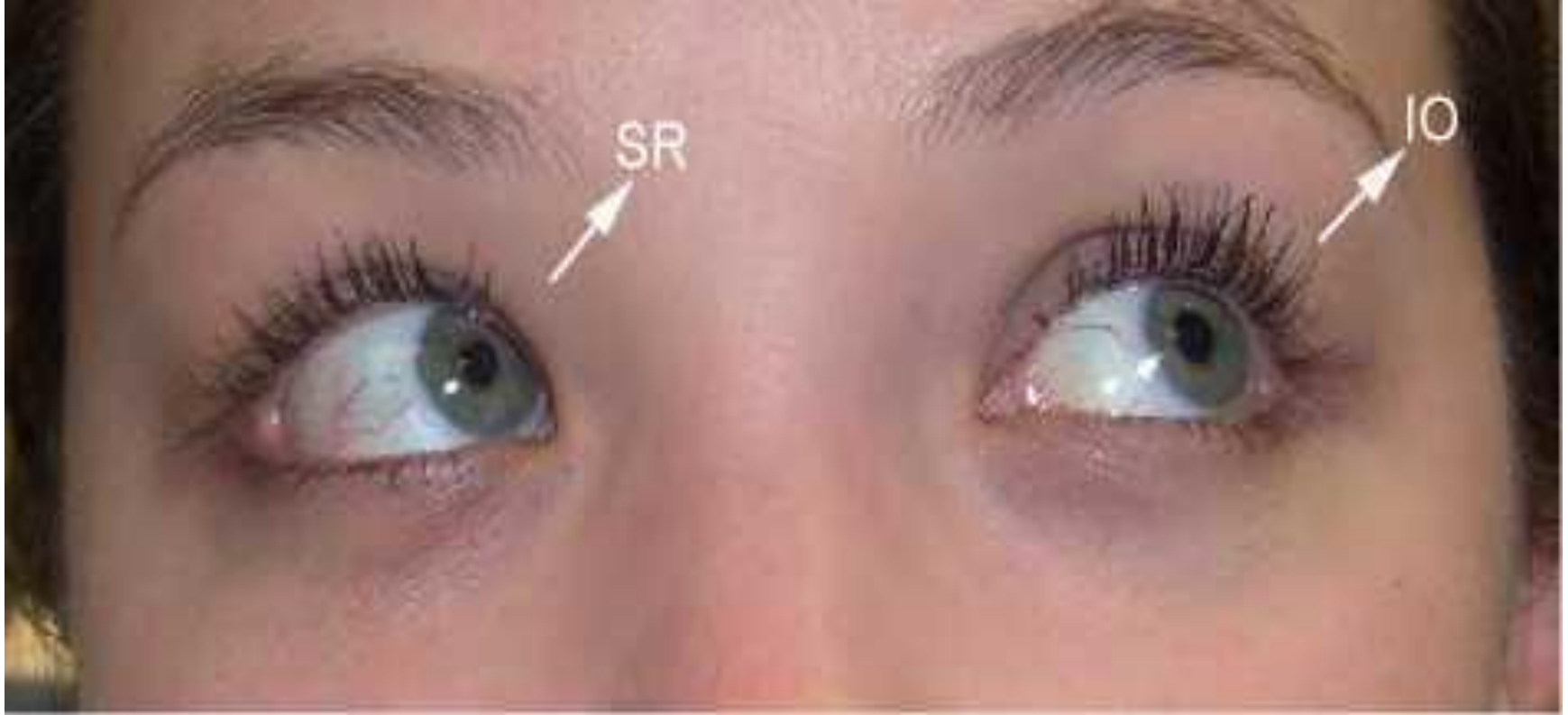Inferior rectus



Inferior oblique



Superior oblique



The extraocular muscles do not act in isolation. They work as teams of muscles in the coordinated movement of the eyeball to position the pupil as needed

For example, although the lateral rectus is the muscle primarily responsible for moving the eyeball laterally, it is assisted in this action by the superior and inferior oblique muscles

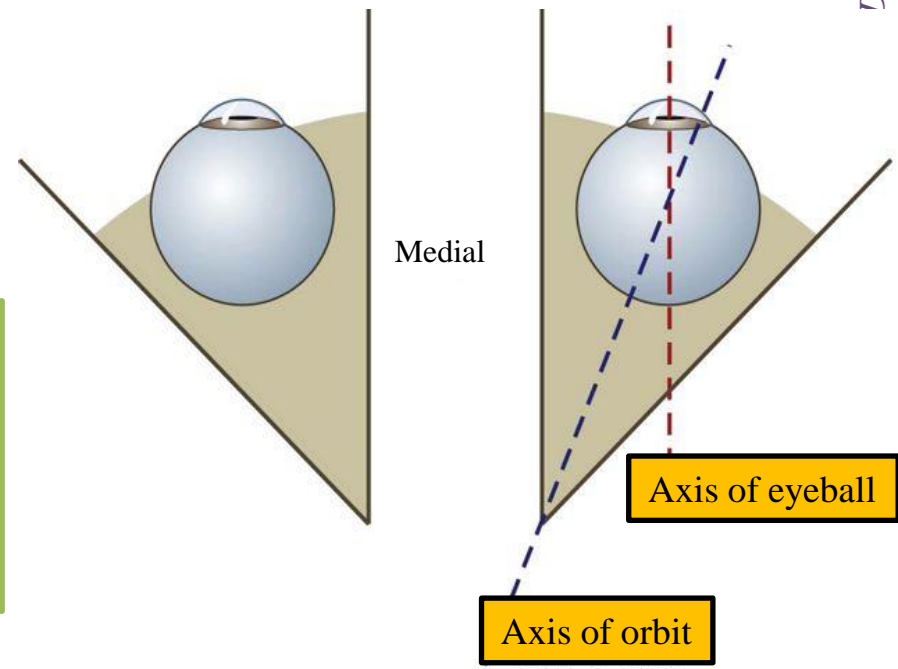
The origins of the superior and inferior recti are situated about 23° medial to their insertions, and, therefore, when the patient is asked to turn the cornea laterally, these muscles are placed in the optimum position to raise (superior rectus) or lower (inferior rectus) the cornea

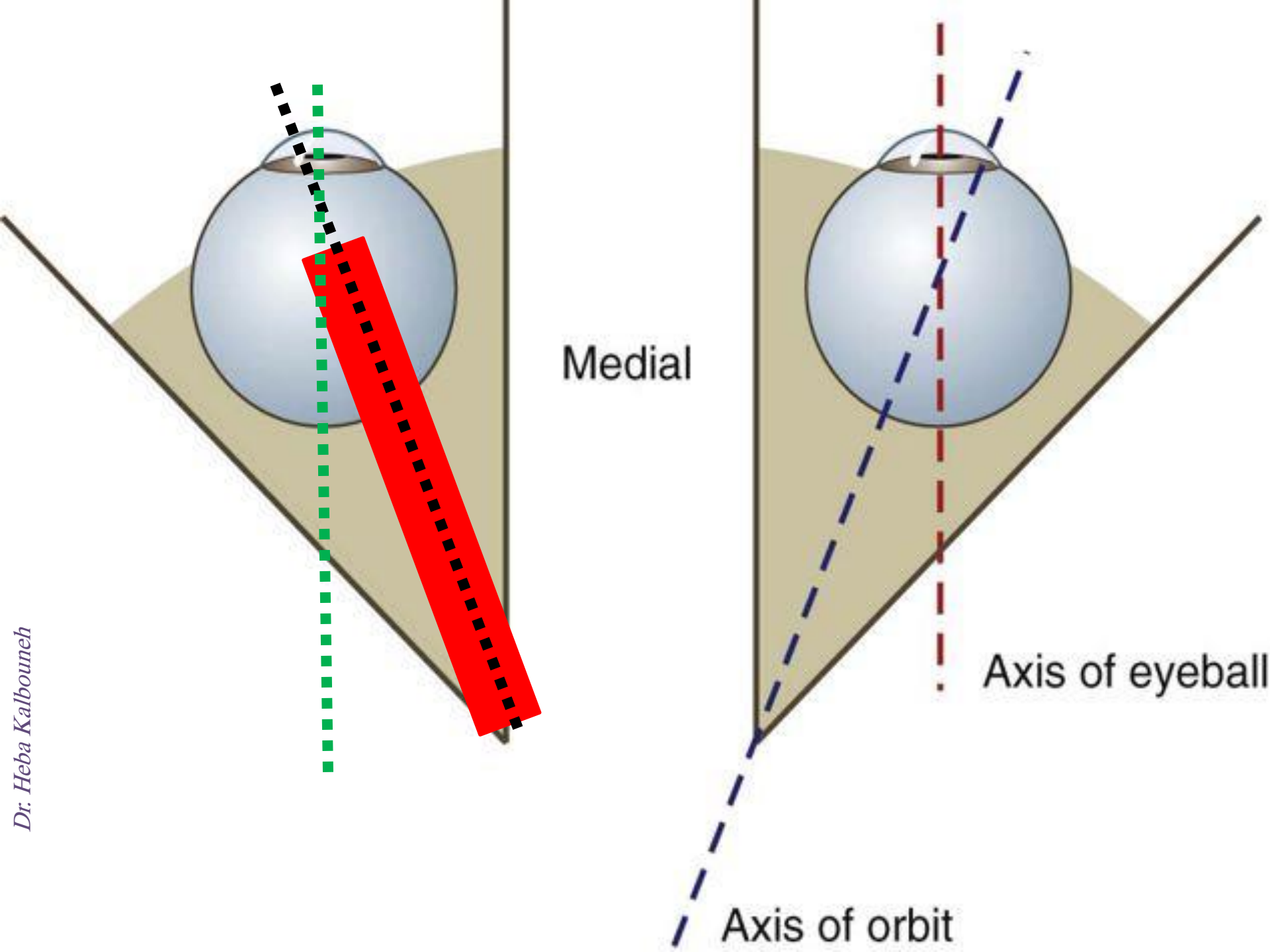


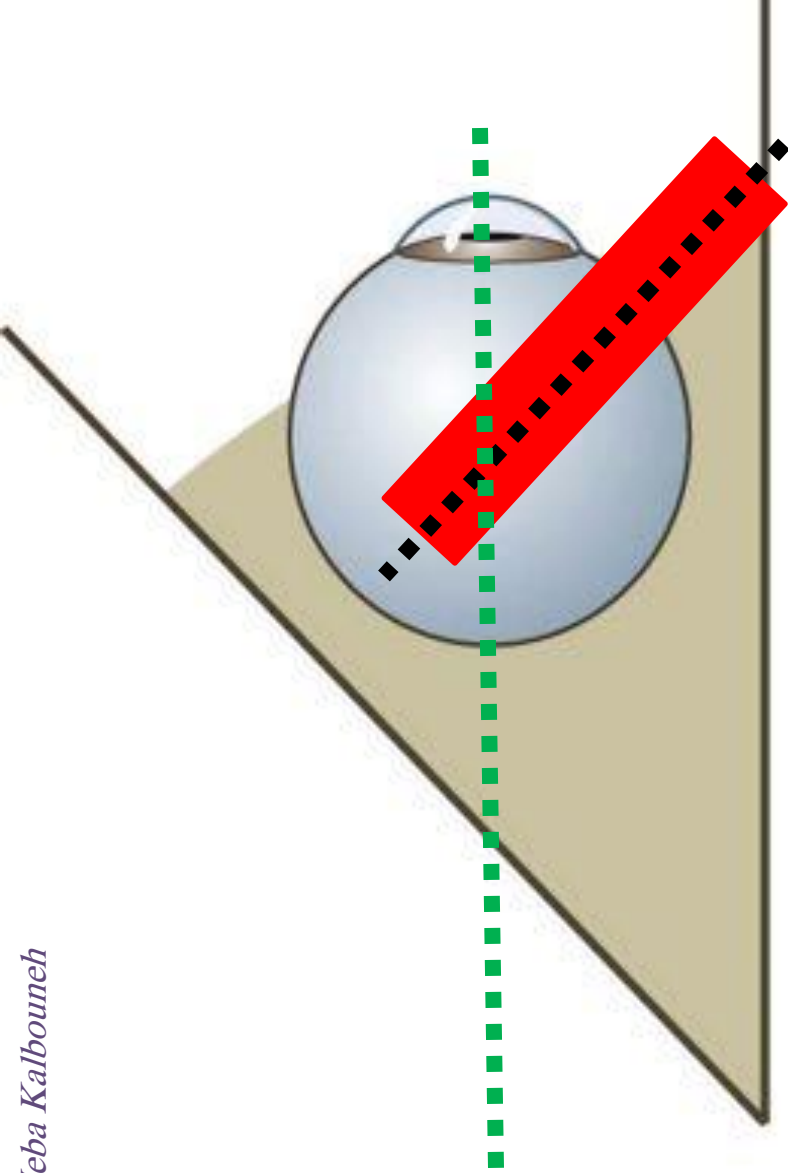
The superior and inferior oblique muscles can be tested. The pulley (trochlea) of the superior oblique and the origin of the inferior oblique muscles lie medial and anterior to their insertions. The physician tests the action of these muscles by asking the patient first to look medially, thus placing these muscles in the optimum position to lower (superior oblique) or raise (inferior oblique) the cornea

Because the lateral and medial recti are simply placed relative to the eyeball, asking the patient to turn his or her cornea directly laterally tests the lateral rectus and turning the cornea directly medially tests the medial rectus

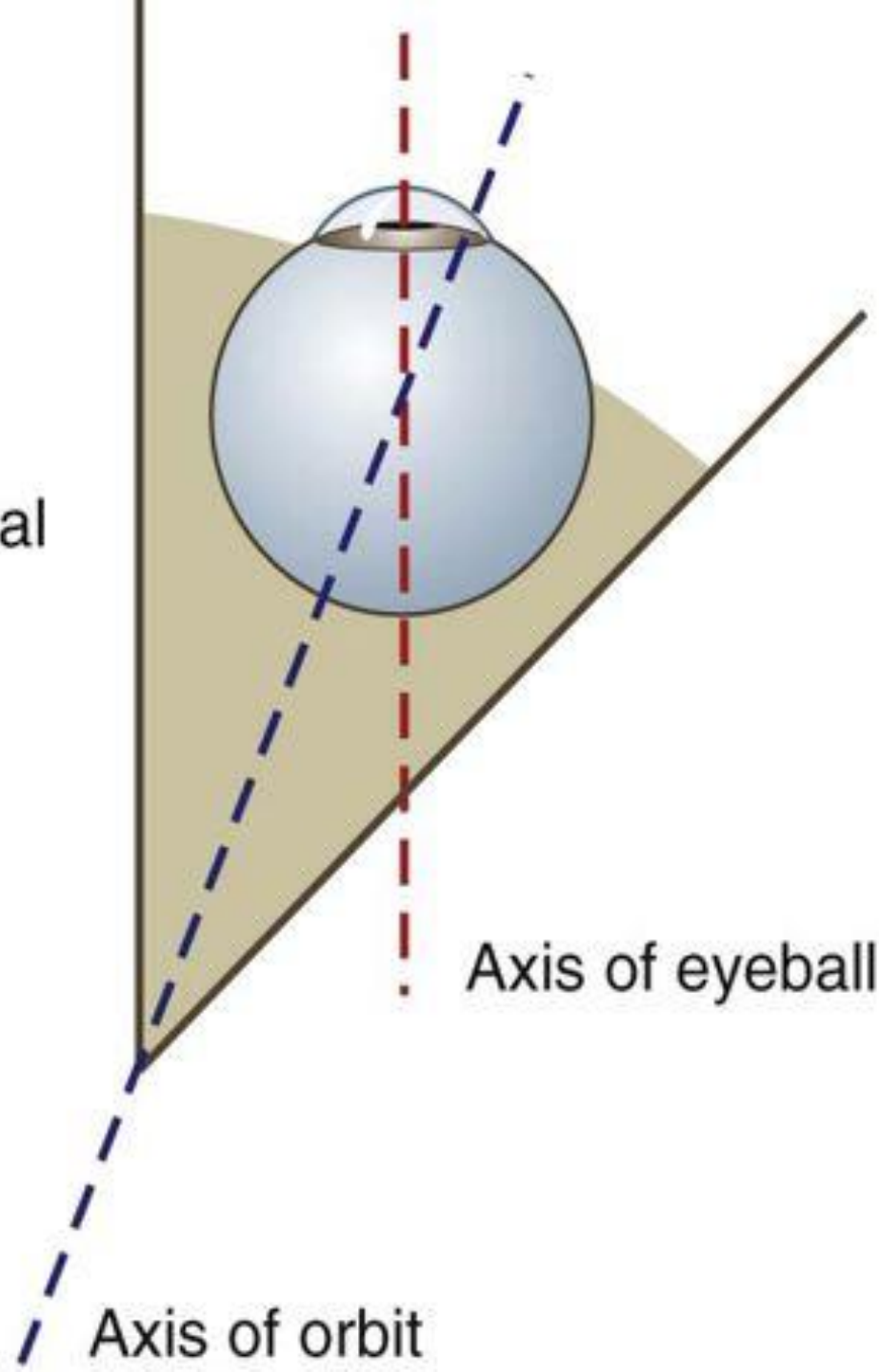
Directions to move the eye when testing the extraocular muscles





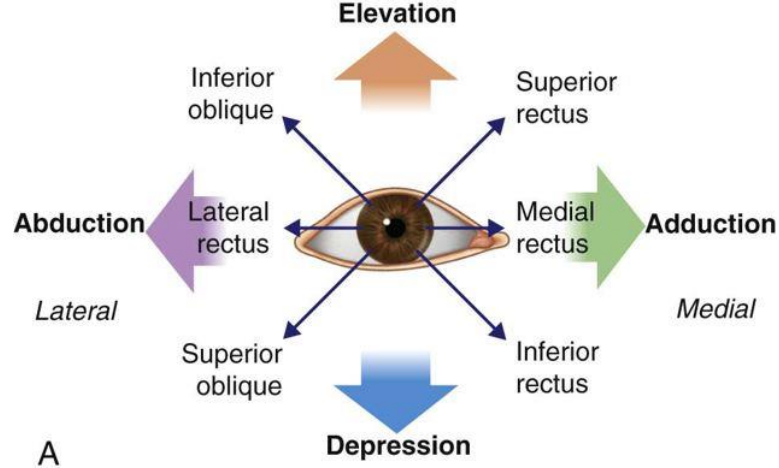


Medial



Axis of eyeball

Axis of orbit



A

Muscle tested		Direction to move eye when testing muscle
Superior rectus		Look laterally and upward
Inferior rectus		Look laterally and downward
Lateral rectus		Look laterally
Medial rectus		Look medially
Inferior oblique		Look medially and upward
Superior oblique		Look medially and downward

B

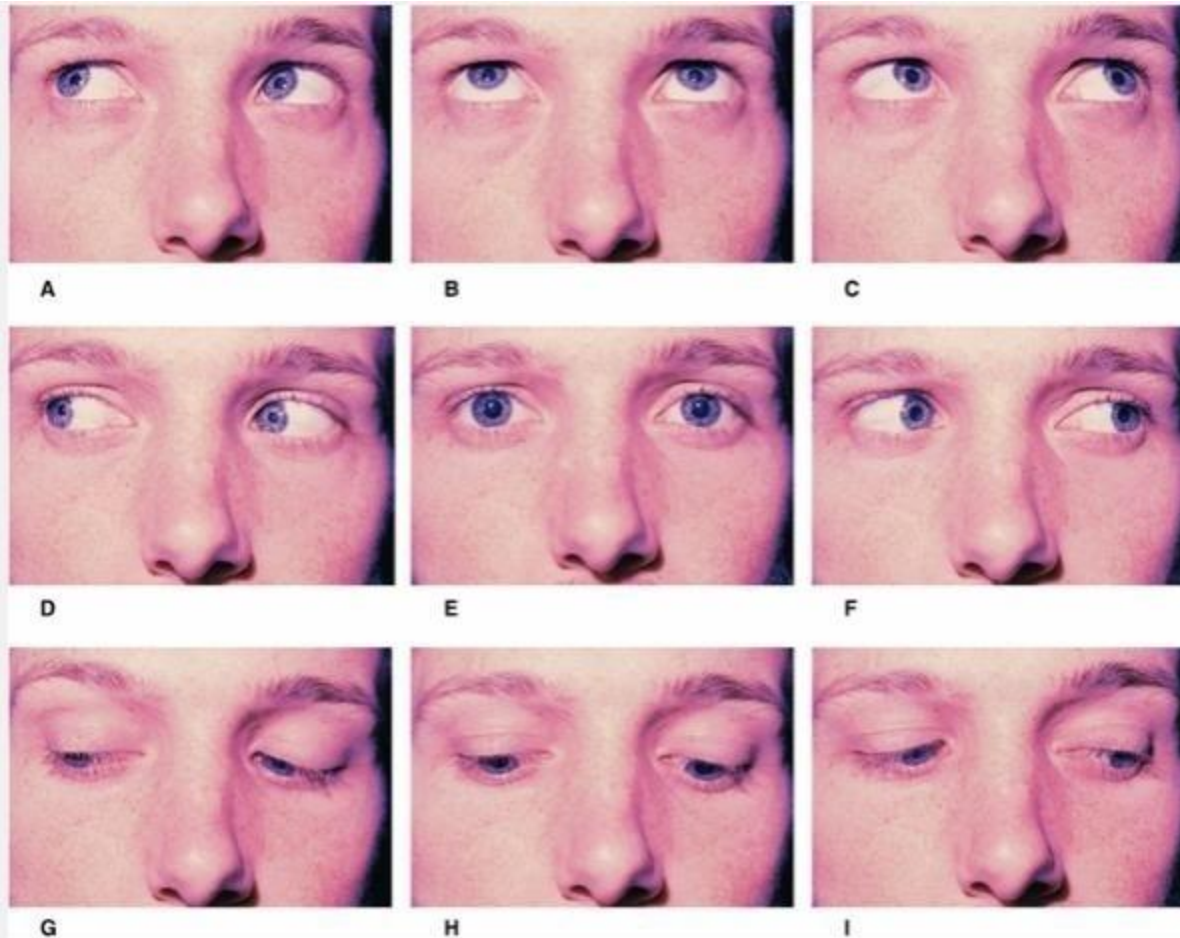
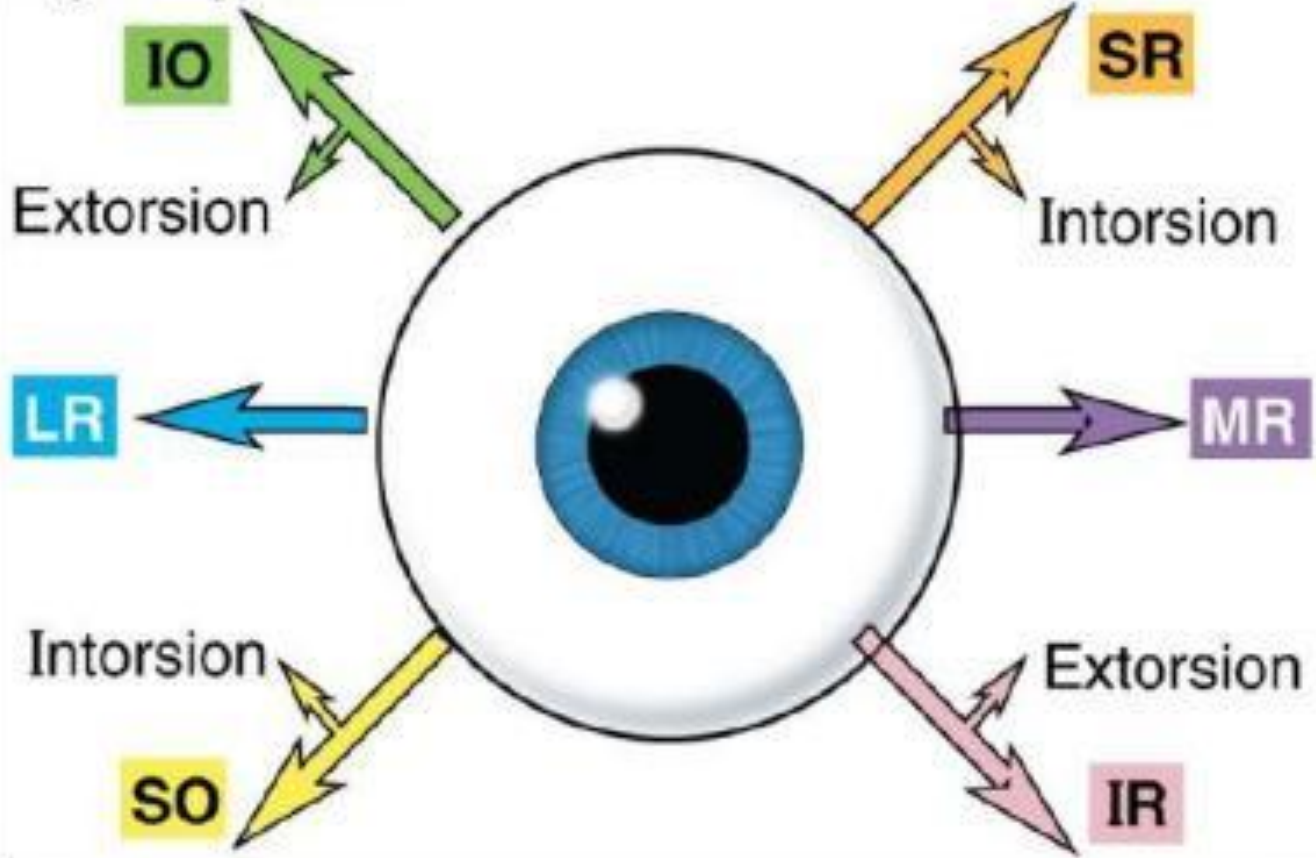


Figure 11-24 The cardinal positions of the right and left eyes and the actions of the recti and oblique muscles principally responsible for the movements of the eyes. **A.** Right eye, superior rectus muscle; left eye, inferior oblique muscle. **B.** Both eyes, superior recti and inferior oblique muscles. **C.** Right eye, inferior oblique muscle; left eye, superior rectus muscle. **D.** Right eye, lateral rectus muscle; left eye, medial rectus muscle. **E.** Primary position, with the eyes fixed on a distant fixation point. **F.** Right eye, medial rectus muscle; left eye, lateral rectus muscle. **G.** Right eye, inferior rectus muscle; left eye, superior oblique muscle. **H.** Both eyes, inferior recti and superior oblique muscles. **I.** Right eye, superior oblique muscle; left eye, inferior rectus muscle.

Right eyeball:



Inferior muscles-----Extorsion
Superior muscles----- Intorsion

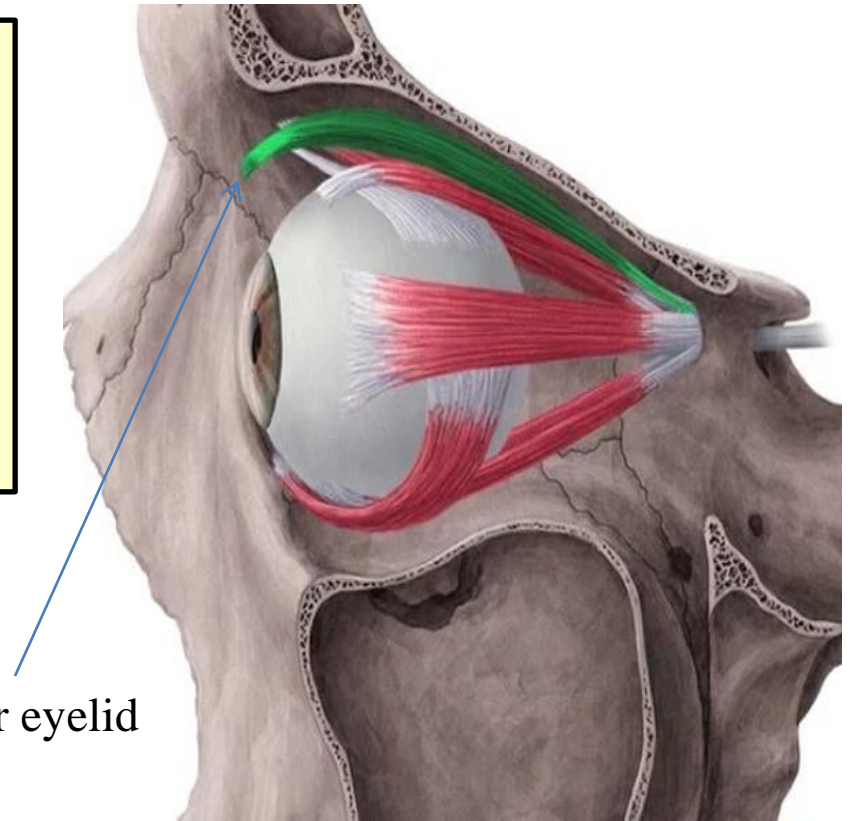
LEVATOR PALPEBRAE SUPERIORIS

Origin: Posterior part of the roof

Insertion: Anterior surface and upper margin of superior tarsal plate, skin of upper eyelid

Nerve supply: Oculomotor nerve/
superior branch

Action: Elevation of upper eyelid



Into upper eyelid

Nerves of orbit

Motor

1. **Oculomotor**
2. **Trochlear**
3. **Abducent**

Sensory

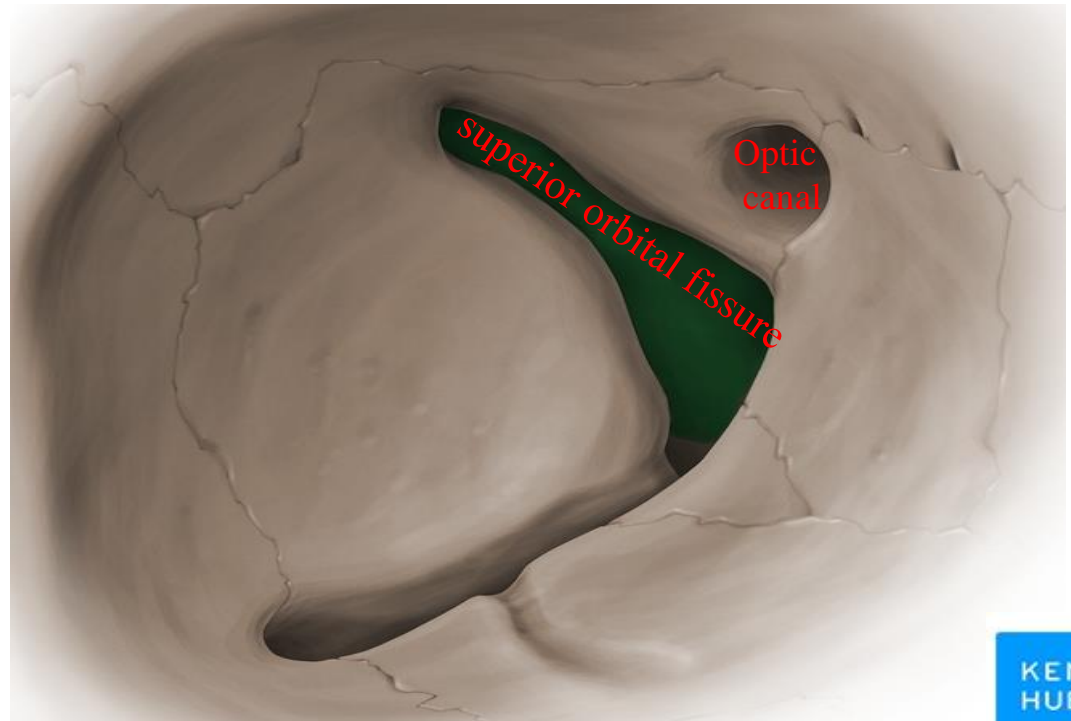
1. **Ophthalmic**
(General sensations)
2. **Optic**
(Special sensations)

Lacrimal

Frontal

Nasociliary

SO4LR6



LEVATOR PALPEBRAE SUPERIORIS

Superior rectus

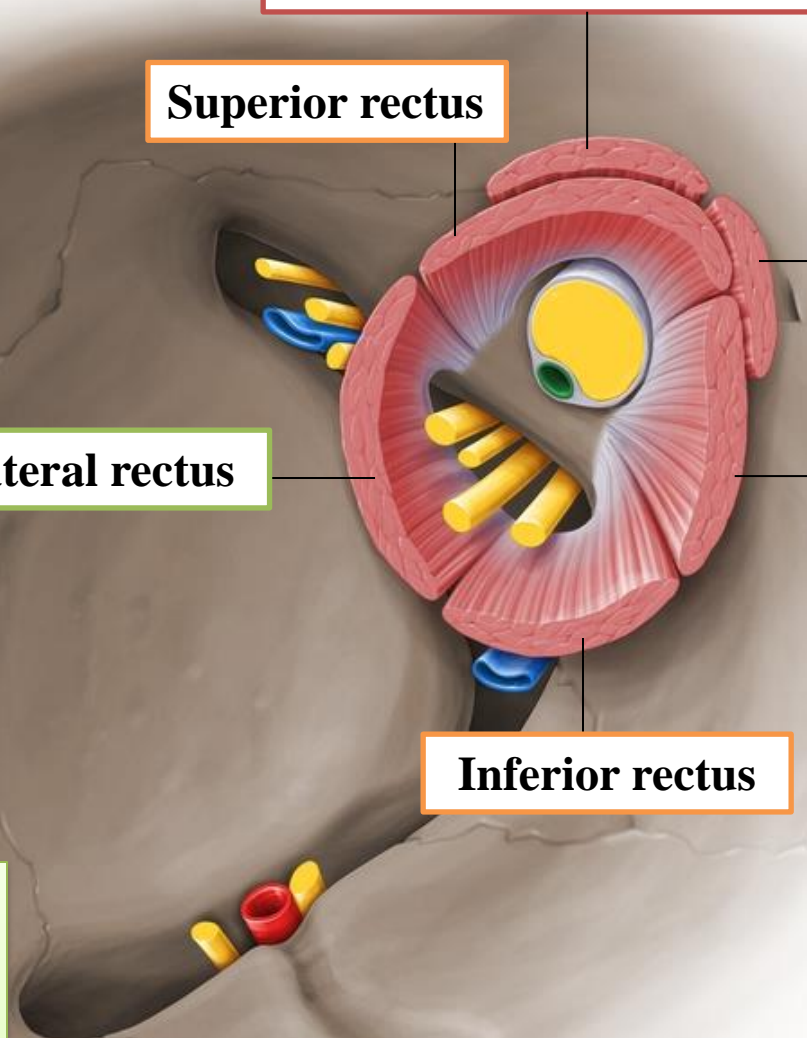
Superior oblique

Lateral rectus

Medial rectus

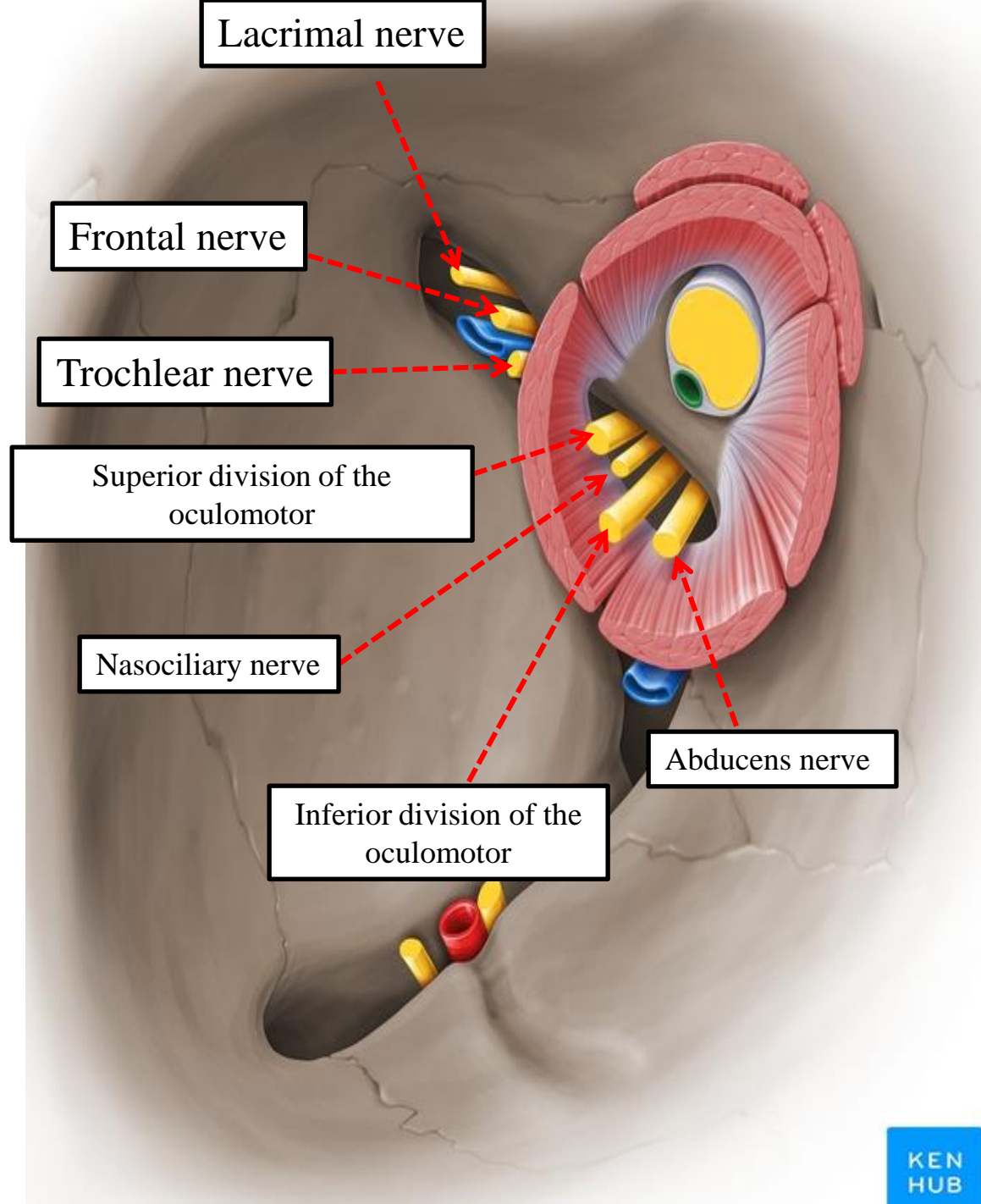
Inferior rectus

The tendinous ring surrounds the optic canal and the medial margin of superior orbital fissure




Nerves of orbit

Live
Free
To
See
No
Insult
At All



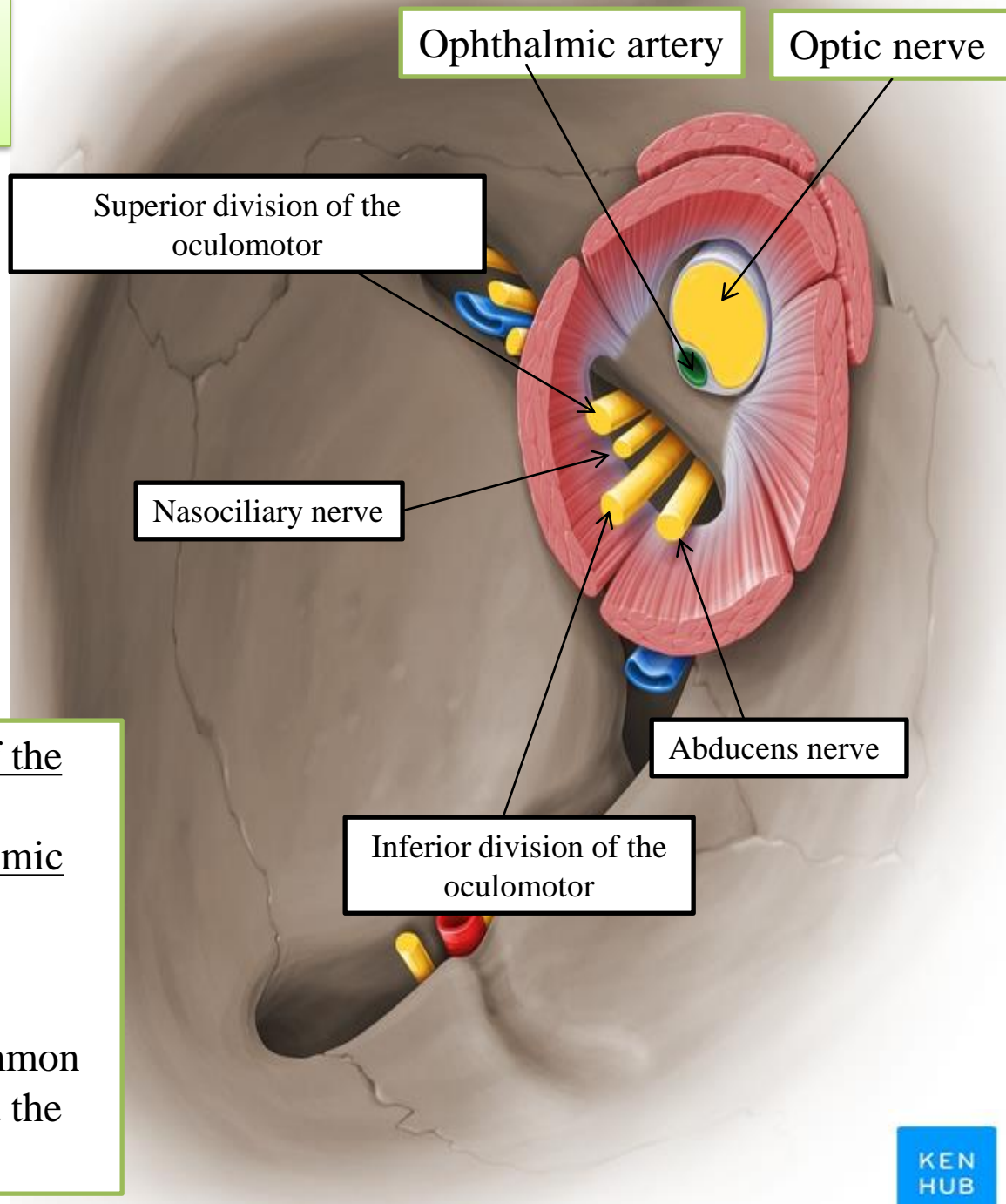
Lie within the common tendinous ring



Optic nerve
Ophthalmic artery
enter the orbit via the **optic canal**, and so lie **within** the common tendinous ring

Superior and inferior divisions of the oculomotor nerve
Nasociliary branch of the ophthalmic nerve
Abducens nerve

also enter the orbit **within** the common tendinous ring, but they do so via the **superior orbital fissure**

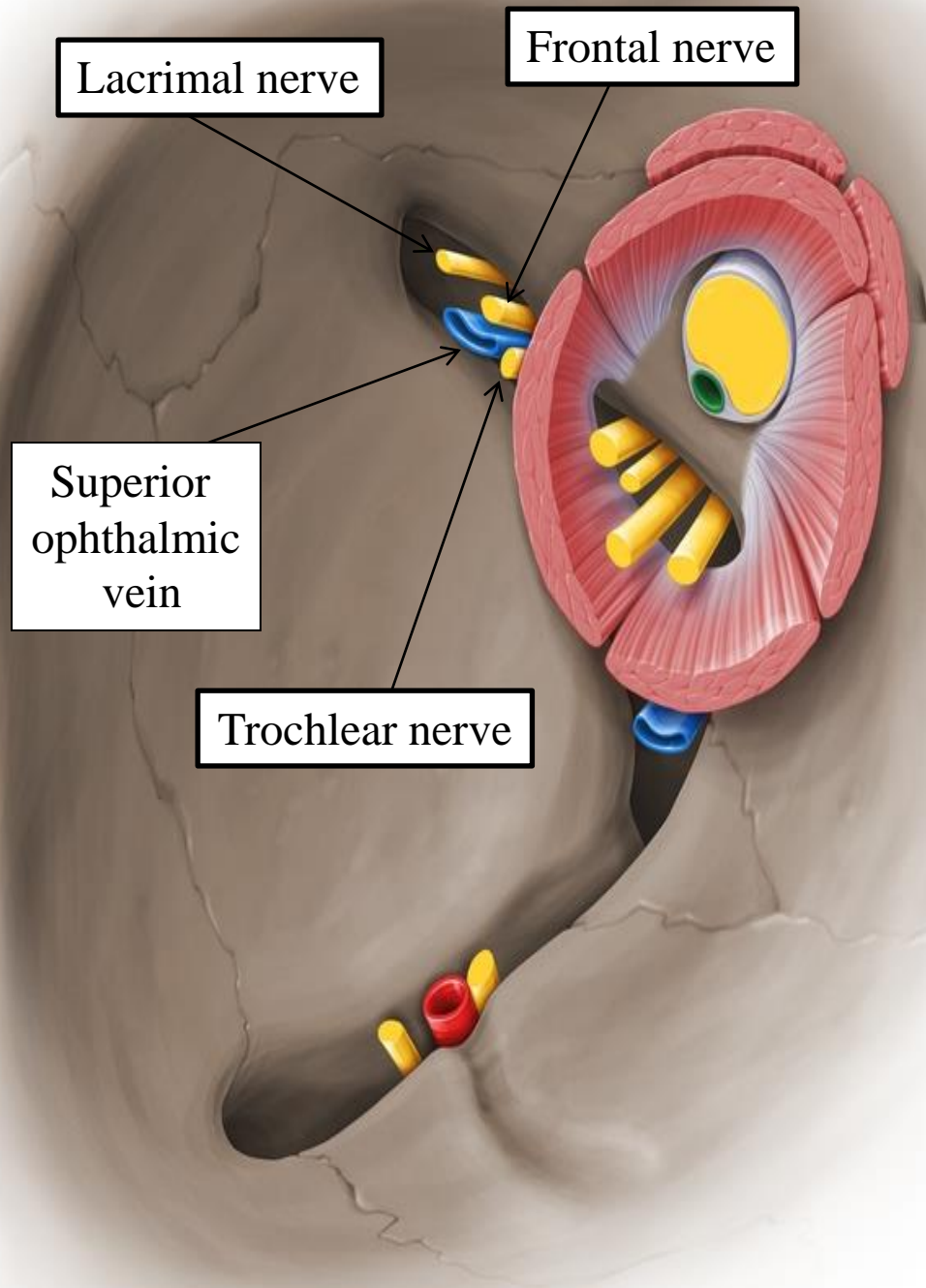


Lie outside the common tendinous ring



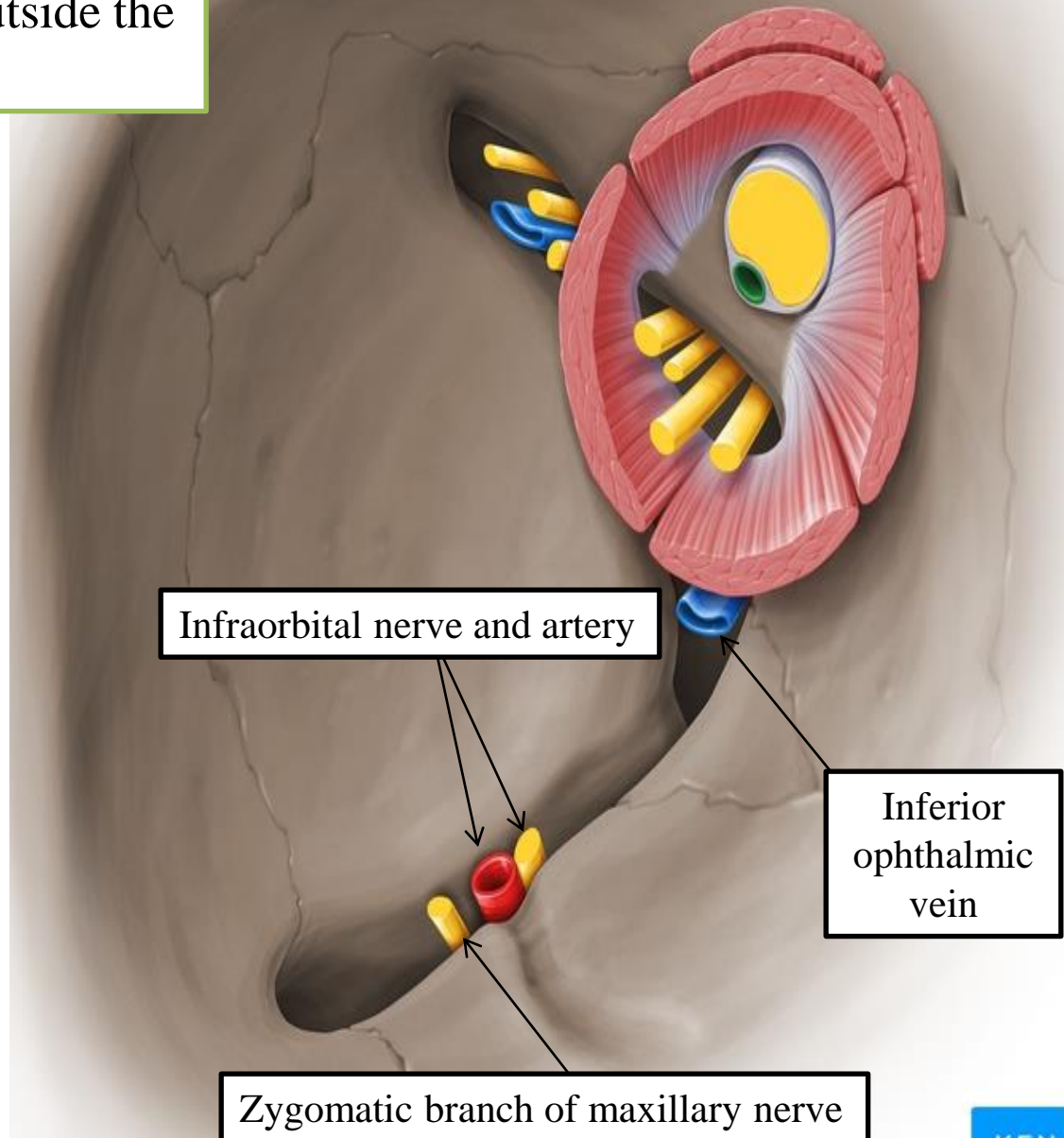
Trochlear nerve
Frontal branch of ophthalmic nerve
Lacrimal branch of ophthalmic nerve
Superior ophthalmic vein

all enter the orbit through the **superior orbital fissure** but lie **outside** the common tendinous ring



Structures which enter the orbit through the **inferior orbital fissure** lie outside the common tendinous ring.

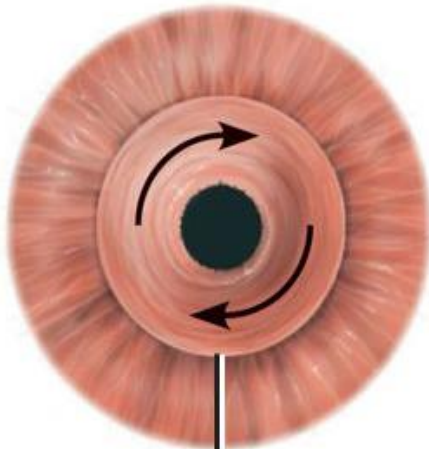
The close anatomical relationship of the optic nerve and other cranial nerves at the orbital apex means that lesions in this region may lead to a combination of visual loss from optic neuropathy and ophthalmoplegia from multiple cranial nerve involvement



The **intrinsic** muscles include
CILIARY MUSCLE
SPHINCTER PUPILLAE
DILATOR PUPILLAE

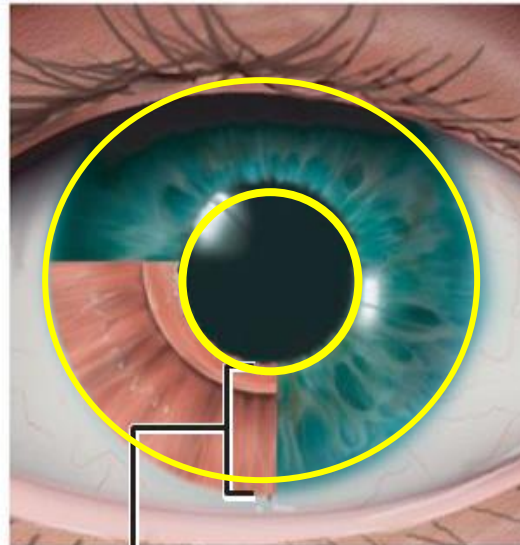
Ciliary muscle: Controls the shape of lens; in accommodation, makes lens more globular
Supplied by Parasympathetic via oculomotor nerve

Parasympathetic +



Sphincter pupillae


Constricts pupil



Iris (two muscles)

- Sphincter pupillae
- Dilator pupillae

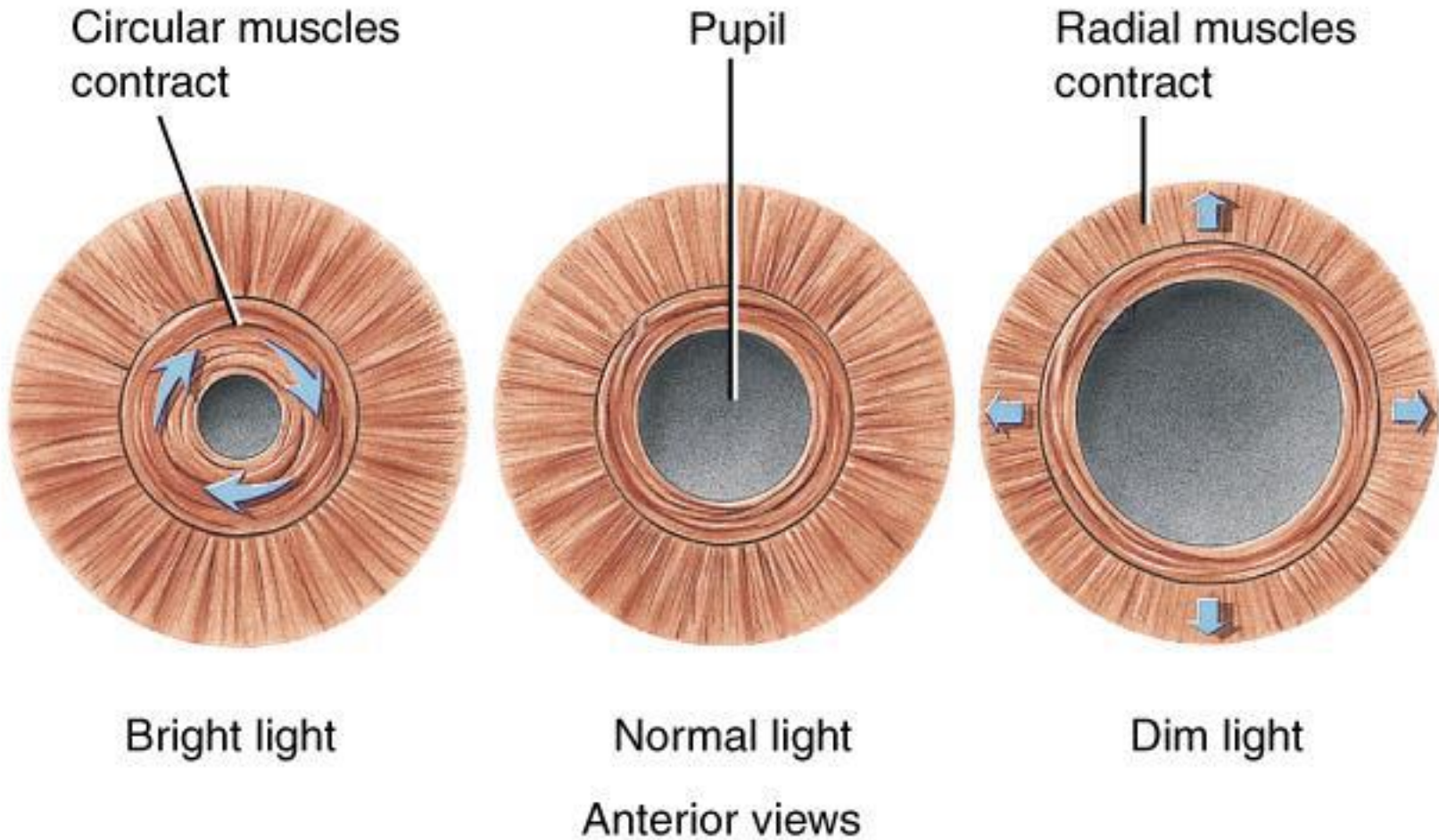
Sympathetic +



Dilator pupillae

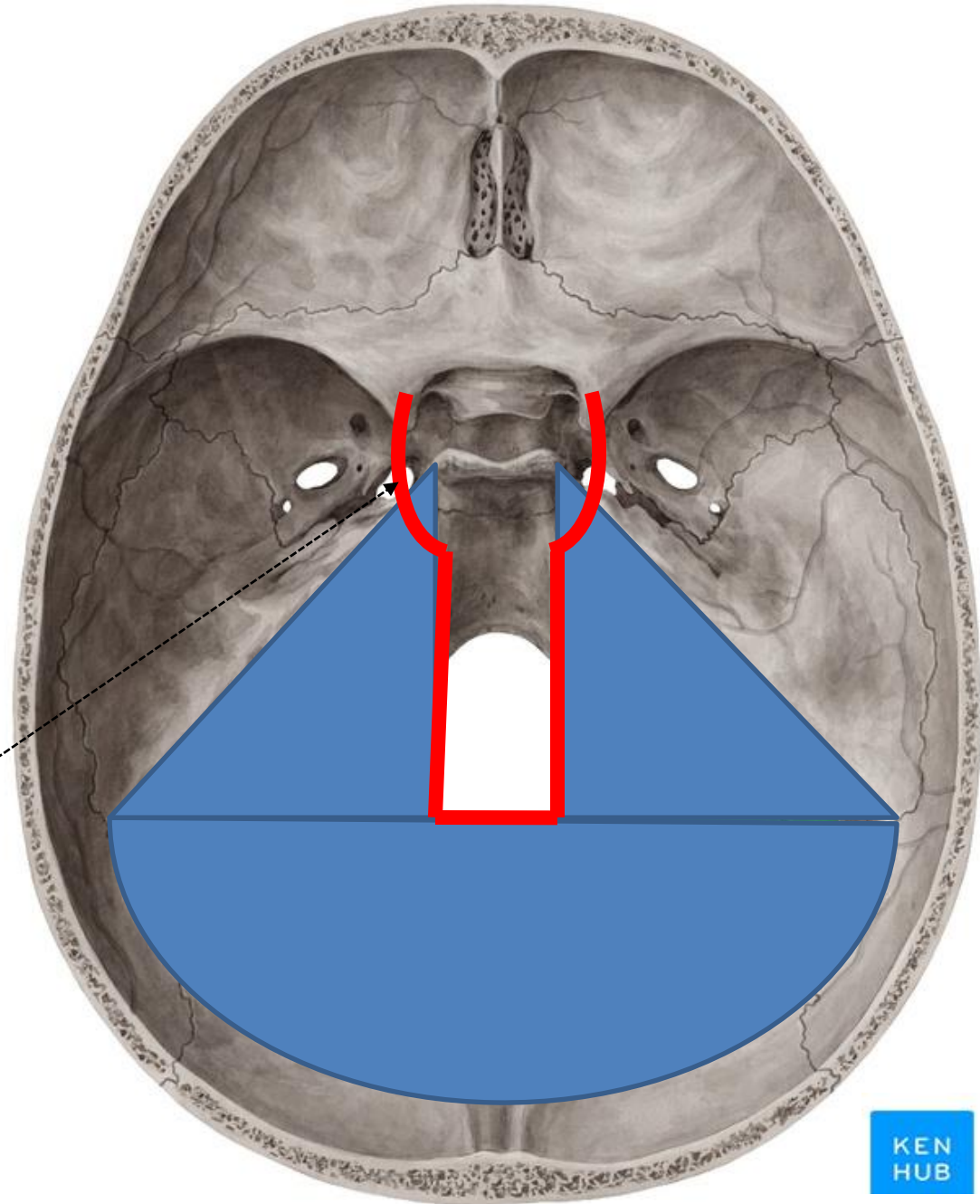
Dilates pupil

Intrinsic Eye Muscles and their response to light

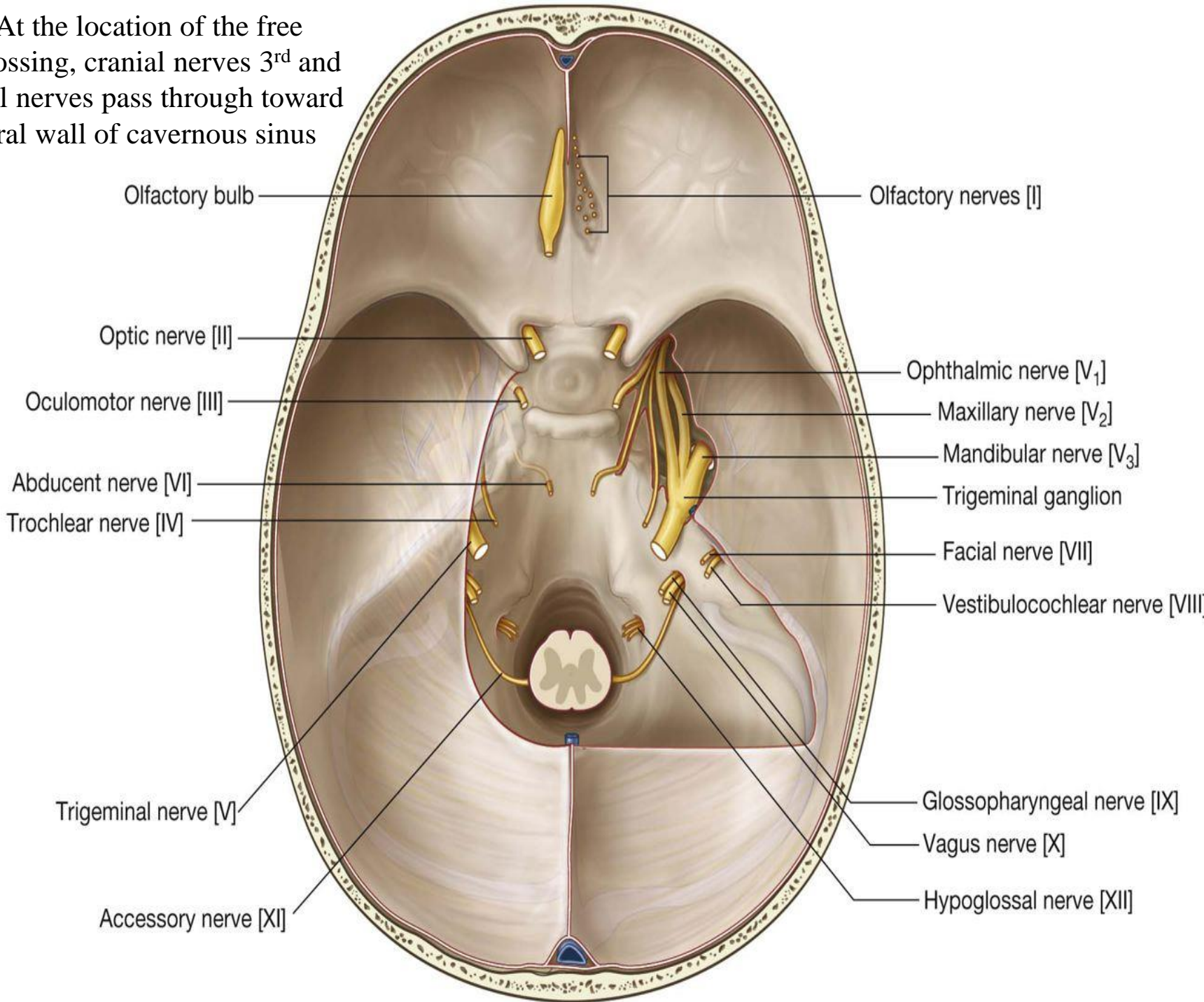


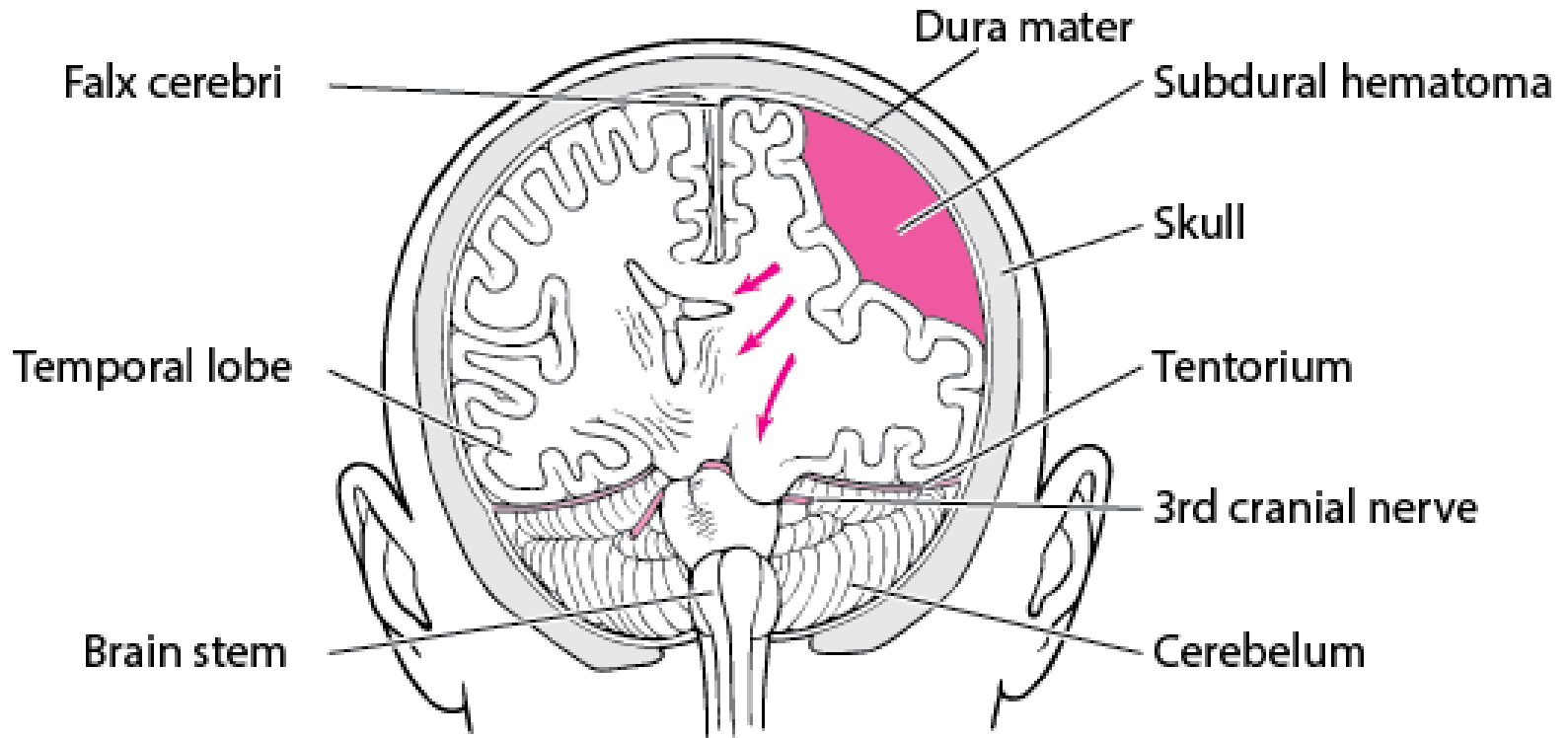
At the apex of petrous bone, the free border of tentorium cerebelli crosses over the attached border

At this point, the third and fourth cranial nerves pass forward to enter the lateral wall of the cavernous sinus



Note: At the location of the free border crossing, cranial nerves 3rd and 4th cranial nerves pass through toward the lateral wall of cavernous sinus






Tentorial Herniation

Because the skull is rigid after infancy, intracranial masses or swelling may increase intracranial pressure, sometimes causing protrusion (herniation) of brain tissue through one of the rigid intracranial barriers (tentorial notch, falx cerebri, foramen magnum).

For example,
Epidural Hemorrhage
May Cause

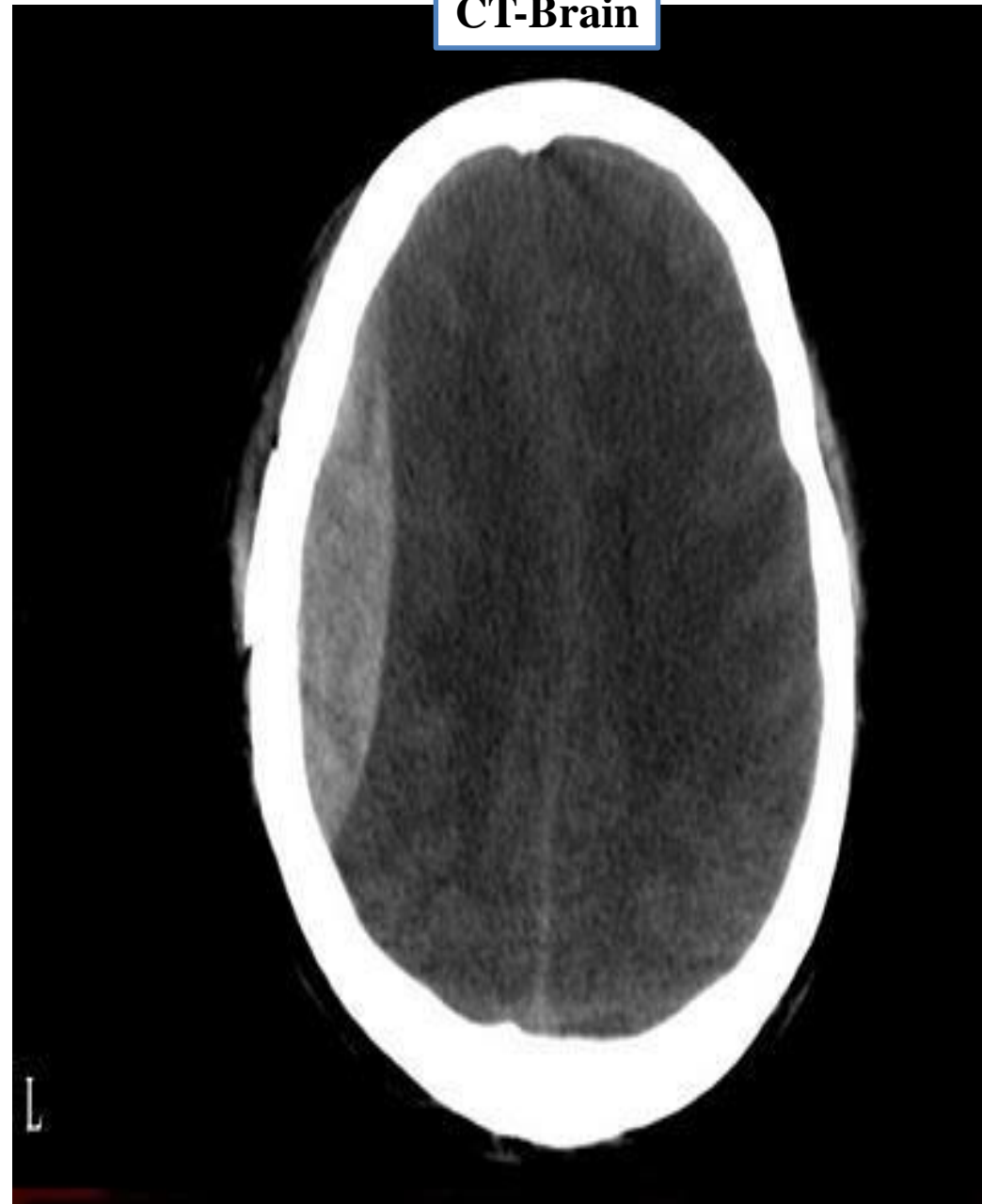


Temporal Lobe Herniation


As blood accumulates, it starts to compress intracranial structures, which may impinge on the third cranial nerve, causing a fixed and dilated pupil on the side of the injury.

The eye will be positioned down and out

due to unopposed innervation of the fourth and sixth cranial nerves



Remember that the dura is a tough structure and its tentorium as well, thus one should think about it as a real septa

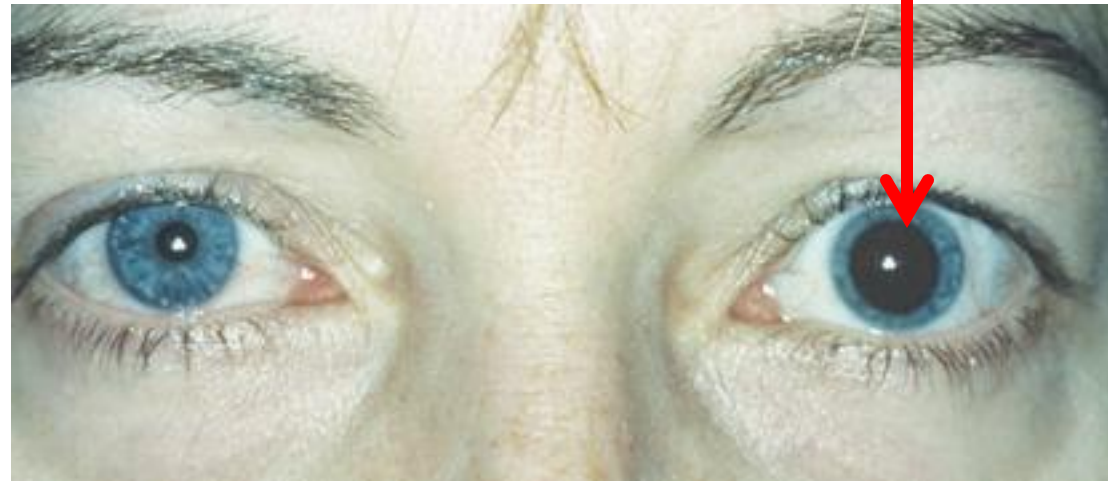

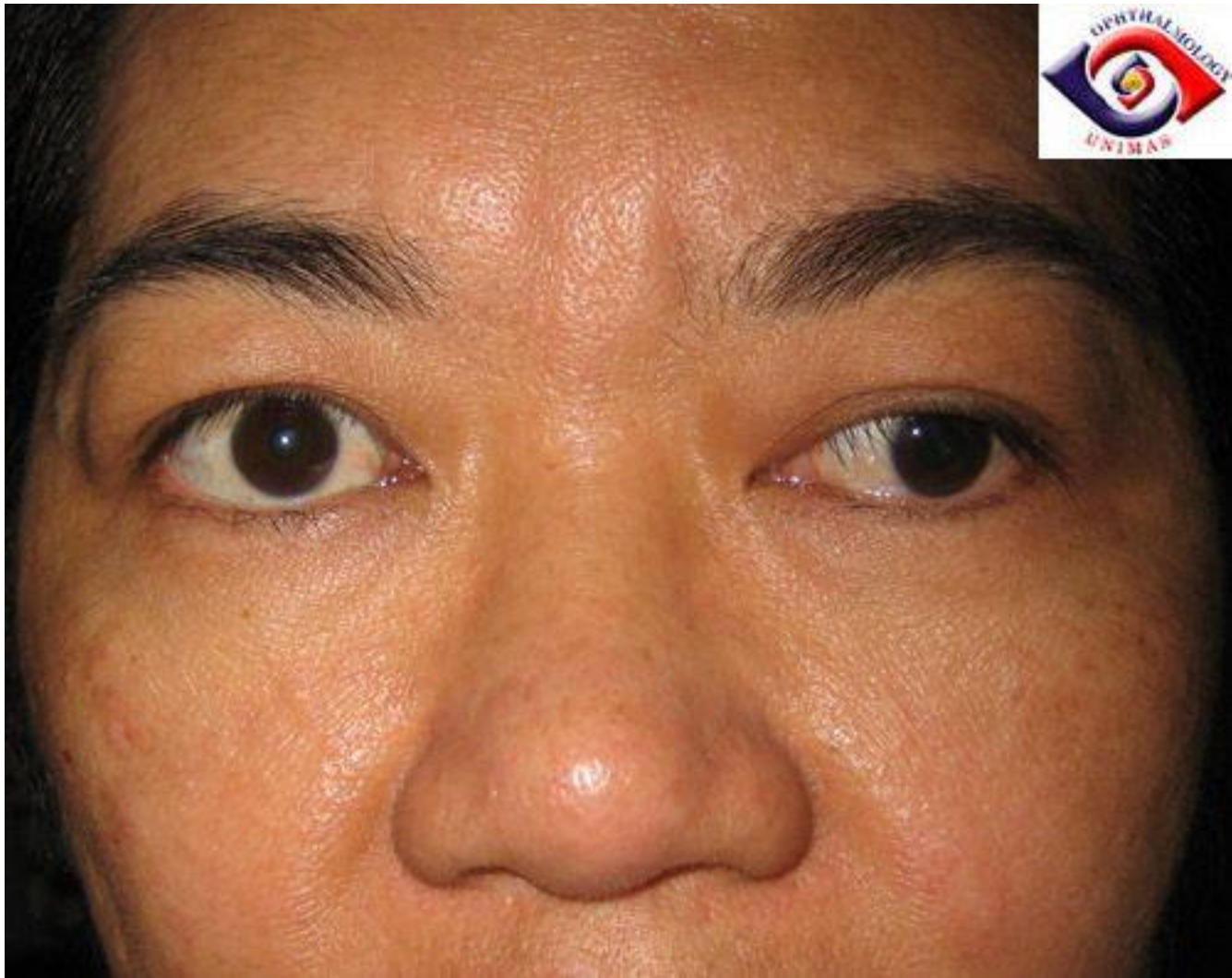Any intracranial mass inside the skull (tumor, bleeding...) may force its neighboring structures to herniate

Compression of oculomotor nerve (III) is the first clinical sign

ipsilateral pupil dilation

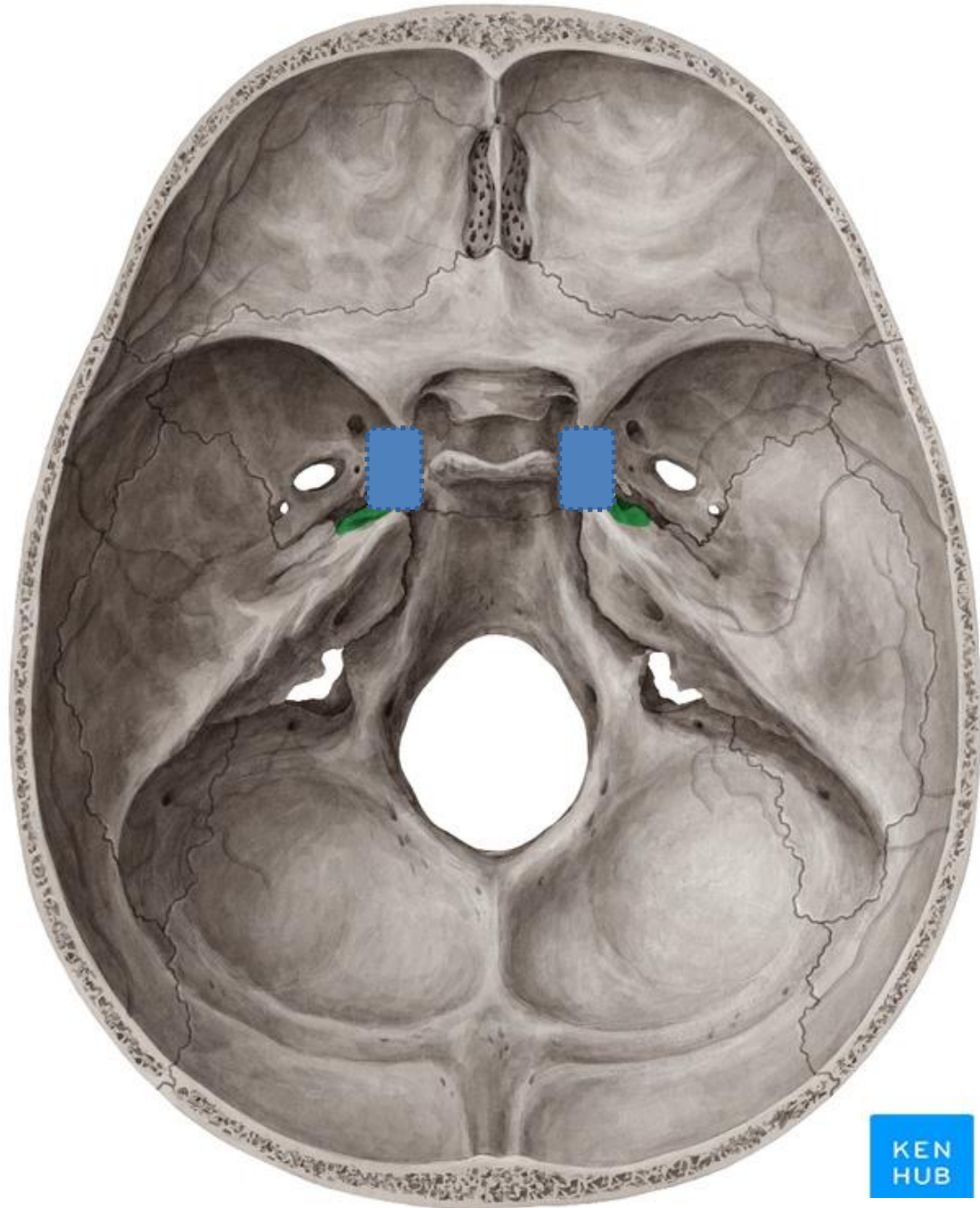
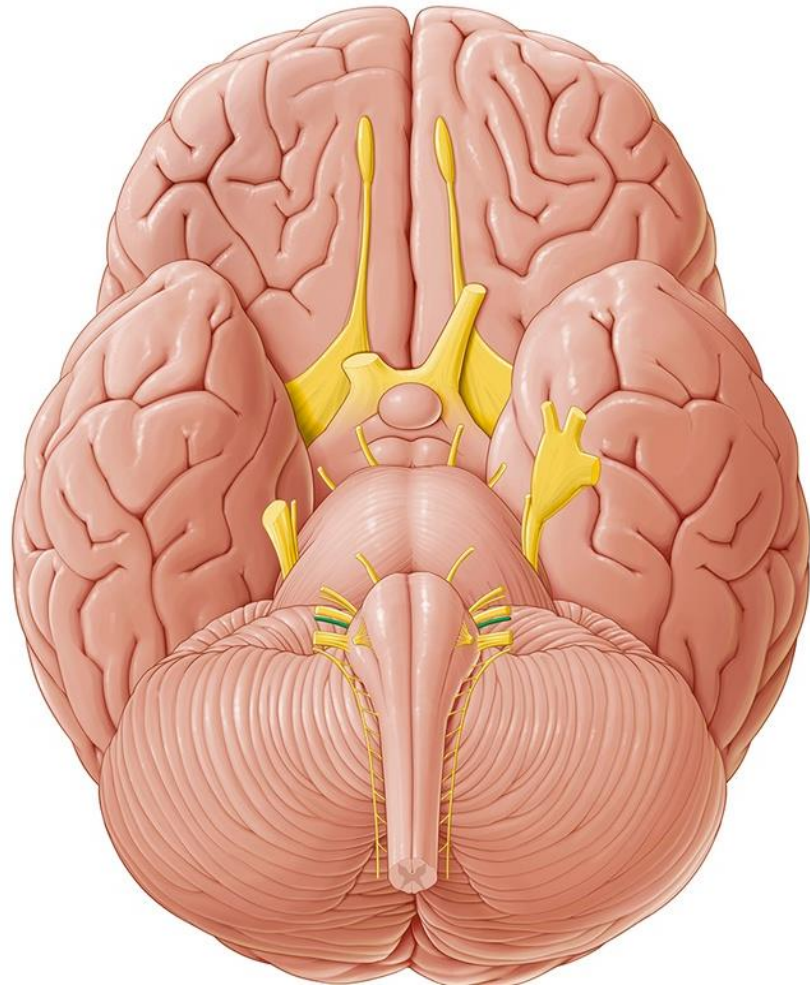
since the parasympathetic fibers that supply the constrictor pupillae are located on the outside of the nerve and are inactivated first by compression



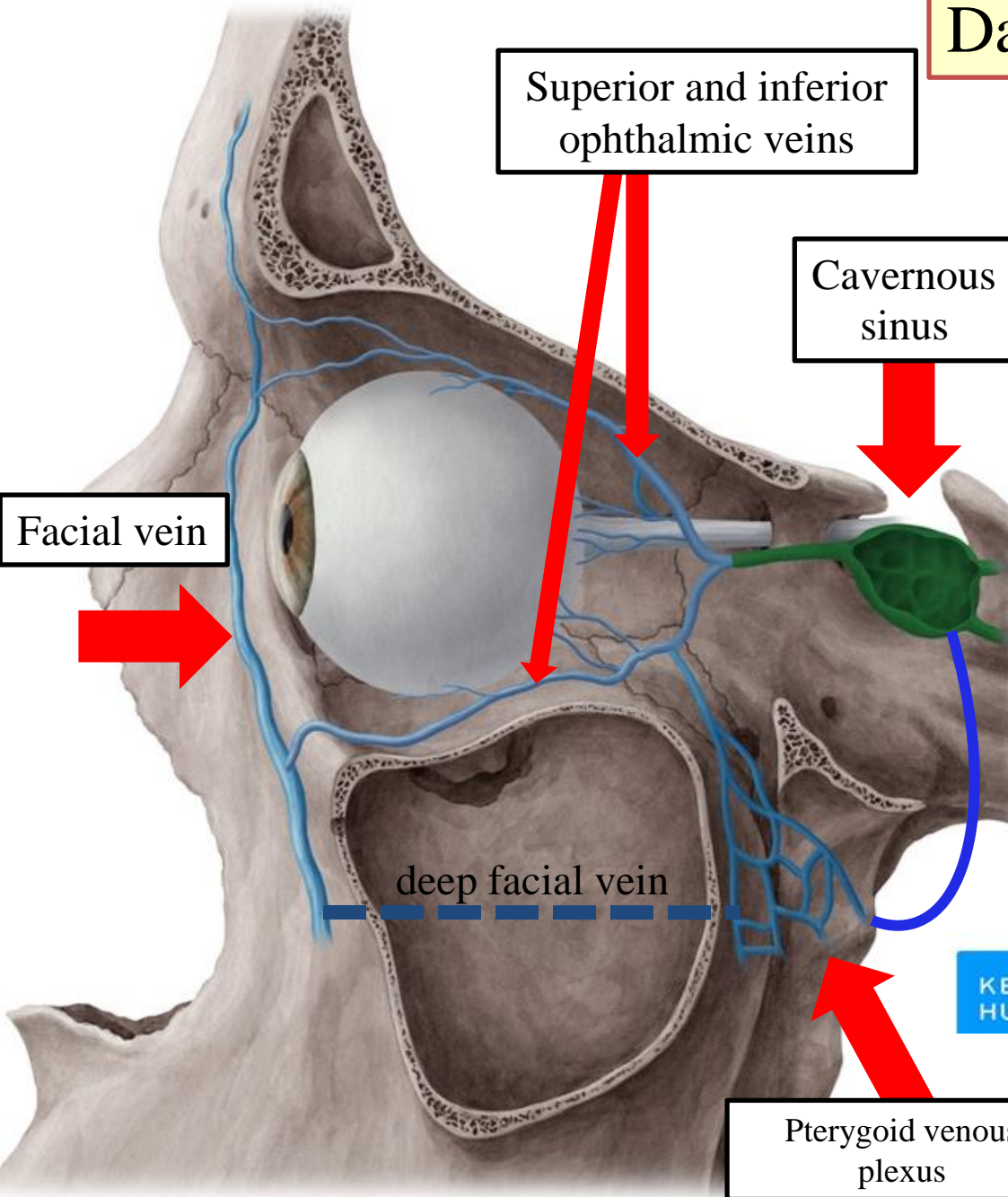


*Mydriasis:
dilation of the pupil*

CN III (Oculomotor) Palsy is a complication of Epidural Hematoma that will present with "down and out" eyes and mydriasis due to compression of the Oculomotor Nerve via herniation



Danger triangle of the face



Superior and inferior ophthalmic veins

Cavernous sinus

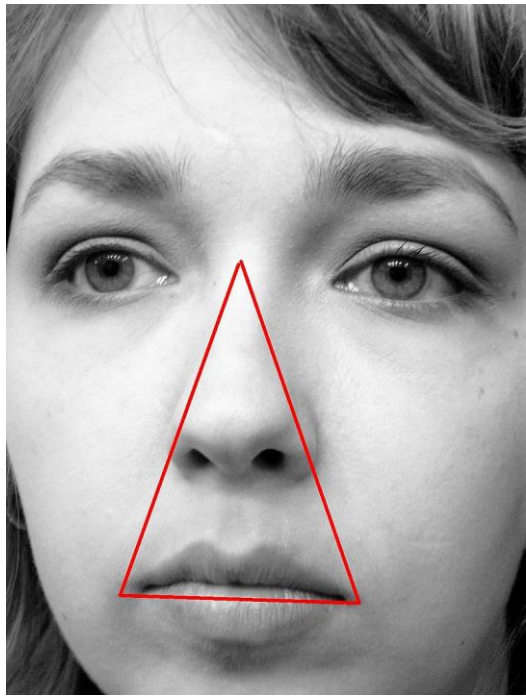
Facial vein

deep facial vein

Pterygoid venous plexus

KEN HUB

Note: venous communication (via the ophthalmic veins) between the facial vein and the cavernous sinus



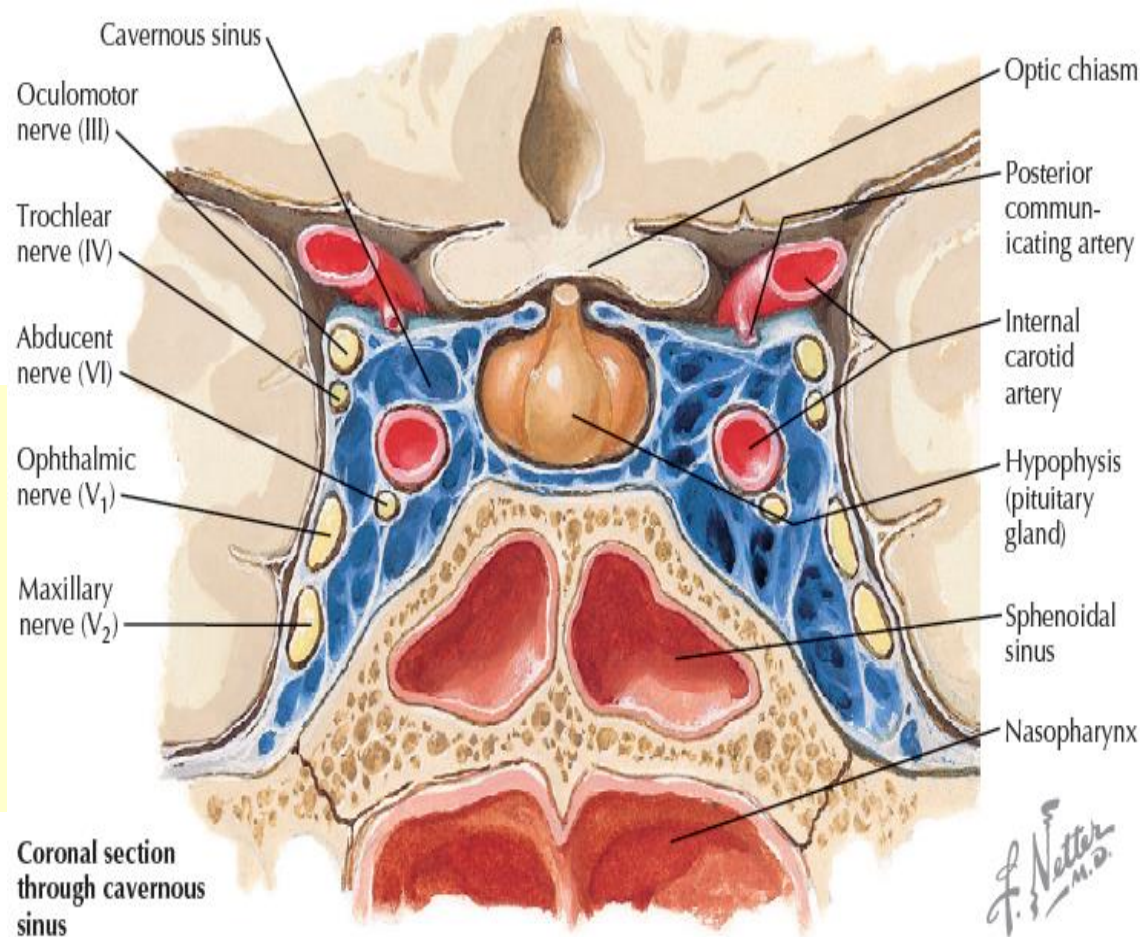
Cavernous sinus syndrome

Cavernous sinus syndrome

Can result from sepsis from the orbit, central portion of the face or paranasal sinuses

Clinical manifestations:

- Ophthalmoplegia with diminished pupillary light reflexes
- Venous congestion leading to periorbital edema
- Exophthalmos
- Pain or numbness of the face



Subsequent infection or inflammation in the cavernous sinus can result in damage to any of the cranial nerves that pass through it

Ophthalmoplegia is the paralysis or weakness of the eye muscles

Note the periorbital edema

Exophthalmos is a bulging of the eye anteriorly out of the orbit

