

Musculoskeletal system

Malek Abu Rahma

Final

Pathology

Severe knee joint space narrowing, subchondral bone cyst formation and subchondral bone Sclerosis are characteristic features of advanced cases of which one of the following?

- A) Ankylosing spondylitis
- B) Lyme disease
- C) Osteoporosis
- D) Degenerative joint disease (Osteoarthritis)
- E) Rheumatoid arthritis

Answer: D

A 7-year-old girl comes to the emergency department after falling on her wrist at the Playground at school. She has a history of fractures, and expresses pain of her left Wrist. Physical examination shows visible scoliosis and large light brown segmental Patches of hyperpigmentation with jagged borders across her left upper chest that Does not cross the midline. Which of the following is the most likely diagnosis?

- A. Tuberous sclerosis
- B. McCune-Albright syndrome
- C. Neurofibromatosis Type 2
- D. Addison disease
- E. Neurofibromatosis Type 1

Answer: B

A man came to the clinic with left knee pain, the arthroscopic picture Showed finger like projection into the joint with brown pigment. Best Disorder describes his condition?

- A. Pigmented villonodular synovitis (PVNS)
- B. Rheumatoid arthritis
- C. Degenerative joint disease
- D. Lyme disease

Answer: A

A 60-year-old man came to the emergency and complained of pain in his Joints. He denied that he had been exposed to such situations before, And when he was examined, it was found that the presence of positive Birefringence, Imagine yourself in the place of the emergency doctor. What is the best diagnosis you can give?

- A. Acute gout arthritis
- B. Acute pseudogout
- C. Rheumatoid arthritis
- D. Osteoarthritis

Answer: B

A 8-year-old boy is brought to the emergency room after a severe fall from a tree During a family vacation. His mother reports a history of recurrent fractures. Physical Examination shows visible scoliosis and large areas of light brown Hyperpigmentation with jagged borders on the right side of his back. Armpit hair And facial hair is also noted. His voice is noticeably deeper than most young boys his Age. Which of the following gene mutations is most likely the cause of his condition?

- A. FBN1
- B. GNAS1
- C. MEN-1
- D. NF
- E. RET

Answer: B

In contrast to lipomas, liposarcomas are?

- A. Larger masses, commonly in the thigh and retroperitoneum
- B. Treated mainly by chemotherapy alone.
- C. The most common soft tissue tumors
- D. Usually smaller in size
- E. Devoid of any specific genetic or molecular abnormalities

Answer: A

A 59-year-old man comes to the clinic because of right-sided groin pain. He notes that the pain prevented him from playing golf over the past several months. He expresses He is able to stand upright, but flexion of his right lower extremity is uncomfortable. He adds it has become increasingly difficult for him to put on his socks and shoes. The pain is generally worse in the mornings for 30 minutes and after periods of Activity. He denies any trauma. His temperature is 37.1°C (98.8°F), pulse is 90/min, Respirations are 16/min, and blood pressure is 136/72 mm Hg. Physical examination Shows no motor deficits and no gross abnormalities on visualization. Some pain with Manipulation of the right hip in flexion, internal rotation, and Abduction is noted. Which of the following is the most likely diagnosis?

- A. Deep vein thrombosis
- B. B.Femoral hernia
- C. C.Hip osteoarthritis
- D. D.Inguinal hernia
- E. E.Lumbar spinal stenosis

Answer: C

Rhomboid-geometric crystals were seen on joint aspirate from a 60-year-Old male patient who came with right ankle joint pain and swelling. The Crystals exhibit weakly positive birefringence under polarizing Microscope. What is the diagnosis?

- A. Pseudogout
- B. Sero-negative arthropathy of ankle joint
- C. Acute gouty arthritis
- D. Acute exacerbation of osteoarthritis
- E. Chronic gouty arthritis

Answer: A

A 52-year-old Caucasian man comes to the office because of a 3-week history of coughing and shortness of breath. The patient is originally from Maine and works as a mountaintop coal miner in the Appalachian Mountains. His medical history is relevant for occasional smoking and type II diabetes mellitus. Upon further interrogation, the patient reports morning stiffness on both hands, that fades away with hand warmers or physical activity. Physical exam shows slightly deformed and swollen proximal interphalangeal joints on both hands.

Auscultatory findings reveal late inspiratory crackles. His temperature is 36.7°C (98.2°F), pulse is 81/min, respirations are 16/min, blood pressure is 120/71 mmHg, oximetry on room air shows an oxygen saturation of 95%. Which of the following findings is most likely to be found in this patient?

- A. ulnar deviation
- B. Pleural effusion
- C. Pulmonary cavitation
- D. Emphysema
- E. Pulmonary abscess

Answer: A

A 65-year-old woman presents with multiple hand joint pain and Swelling. She complains of morning joint stiffness that improves slowly After initial movements. Bilateral ulnar deviation was noted on Examination. Which one of the following tests will confirm your top Differential diagnosis?

- A. Arthroscopic examination
- B. Rheumatoid factor
- C. High resolution X-ray of the hands and the feet
- D. Joint fine needle aspiration fluid examination
- E. No need for further testing; the patient has ankylosing spondylitis.

Answer: B

Fibromatoses diseases are best characterized by:

- A. Easy surgical excision with low recurrence rate
- B. Fibroblast growth factor receptor 3 mutations
- C. Locally destructive and infiltrative lesions
- D. Highly pleomorphic cells under the microscope
- E. Almost all are superficial subcutaneous lesions.

Answer: C

A 45-year-old woman comes to the office because of pain, stiffness, and swelling of The small joints of the hands and feet for 3 months. She also has increasing fatigue That has caused her to miss work at least 1 day per week. She has no other medical Problems. Physical examination shows the vital signs are within the normal range. A Photograph of one of her hands is shown. Complete blood count, serum chemistries, And urinalysis are all normal. Erythrocyte sedimentation rate is elevated at 44 mm/h And there is a nonsuppurative & proliferative inflammation Which of the following is the most likely diagnosis?

- A. Osteoarthritis
- B. Psoriatic arthritis
- C. Rheumatoid arthritis
- D. Systemic lupus erythematosus
- E. Gout

Answer: C

Which one of the following statements best characterizes degenerative joint disease of bone?

- A. Insidious and increase with age.
- B. Avascular necrosis is a common complication of severe cases.
- C. Pannus formation is characteristic.
- D. Primary disease of the synovium
- E. Secondary etiology is more common than idiopathic/primary.

Answer: A

A 7-year-old girl comes to the office because of spiking fevers that, as her mother Describes, would "come and go". Her mother also shows a "salmon-pink" rash that is Most prominent during her daughter's fevers. A complete blood count shows Significantly increased numbers of white blood cells. However, an infection was later Ruled out, and she is diagnosed with juvenile idiopathic arthritis. A diagnosis of Juvenile idiopathic arthritis includes all of the following criteria except:

- A. Arthritis in at least one joint
- B. Arthritis lasting for at least 6 weeks
- C. Exclusion of other causes of arthritis (unknown cause)
- D. Onset before age 16
- E. Usually Positive rheumatoid factor

Answer: E

A 50-year-old woman presents with bilateral hands joint pain with morning stiffness. The pain decreases after a couple of hours of daily activities. The small joints of the hand are swollen, tender and warm. Ulnar deviation and swan-neck deformity are noted on examination. Which one of the following statements best describes this condition?

- A. An associated sacroiliitis is usually present in 95% of the cases.
- B. Most cases are mild and are relieved by NSAIDs.
- C. Diagnosis needs CT scan imaging confirmation.
- D. Chronic non-suppurative autoimmune synovitis
- E. Reactive degenerative arthritis

Answer: D

A 19-year-old man comes to the emergency room because of difficulty breathing for 6 Hours. He reports that earlier that day, he was doing laundry and suddenly became Short of breath. He also reports back pain for a year that is worst after waking up in The morning. He reports that his morning stiffness typically lasts for approximately An hour. Over the past few months, he has noticed pain in his hips intermittently but Did not have insurance to see a doctor so he ignored it. Chest and spine X-rays are Obtained a damage of sacroiliac joint (Ankylosing spondylitis) . Which of the Following is associated with the most likely diagnosis?

- A. HLA-B27 positivity
- B. HLA-DR3 positivity
- C. Positive ANA
- D. Positive cyclic citrullinated peptide
- E. Positive rheumatoid factor

Answer: A

You are evaluating a 65-year-old female patient who came with right hip Joint pain. The Rheumatoid factor is negative. No other joints are Affected, and the patient recalled recent eye disease requiring frequent Ophthalmological evaluation. No skin manifestation or urinary Abnormalities noted. Bone MRI revealed right sacroiliac joint fusion. Serum HLA typing was positive for HLA B-27. What is your best Diagnosis?

- A. Sero-negative rheumatoid arthritis
- B. Ankylosing spondylitis
- C. Psoriatic arthritis
- D. Mono-ostotic osteoarthritis
- E. Reiter syndrome

Answer: B

A 55 year-old man comes to the emergency department because of a three-day history of pain, erythema, and swelling in the first metatarsophalangeal joint of his right foot. He is unable to sleep at night because he has severe pain whenever his bed sheet touches the joint. He admits to smoking one pack per day and drinking three to four beers nightly. He denies any previous episodes of pain in this joint and denies trauma to the area. He denies pain in any other joint. His only medication is hydrochlorothiazide for hypertension, and the dose of this medication was recently increased by his primary care provider. Physical examination shows a tender, warm, erythematous right toe. Synovial fluid is removed from the joint, and crystals are seen on microscopy. Which of the following substances is most likely to be seen on analysis?

- A. Calcium oxalate
- B. Calcium pyrophosphate dihydrate
- C. Cholesterol
- D. Monosodium urate
- E. Uric acid

Answer: D

You are an intern in the emergency room on Thursday night. A 12-year- Old male patient comes with sudden pain in his right knee and was Limping when you saw him. His right knee is swollen, red and feels hot on Touch. He has fever and his white blood count is 19,000/ mL with Increased neutrophils. What would be your best action?

- A. Treat as acute gouty arthritis, aspirate to check for crystals.
- B. Consider juvenile idiopathic arthritis, and order rheumatoid factor test.
- C. Consider acute septic arthritis; plan admission and consult pediatrics And orthopedics on call.
- D. Considering lower femur fracture, he only needs casting and pain Medications.
- E. Treat as a case of lower femur greenstick fracture

Answer: C

A 55 year-old man comes to the emergency department because of a three-day history Of pain, erythema, and swelling in the first metatarsophalangeal joint of his right Foot. He is unable to sleep at night because he has severe pain whenever his bed Sheet touches the joint. He admits to smoking one pack per day and drinking three to Four beers nightly. Last night he reports having a few extra beers. He denies any Previous episodes of pain in this joint and denies trauma to the area. He denies pain In any other joint. His only medication is hydrochlorothiazide for hypertension. His Temperature is 37.1°C (98.8°F), pulse is 90/min, respirations are 16/min, and blood Pressure is 136/72 mm Hg. Which of the following is most likely to be seen on joint Aspiration?

- A. Elevated PMNs only
- B. Gram positive cocci in clusters
- C. Linear and rhomboidally-shaped crystals
- D. Negatively birefringent crystals
- E. Positively birefringent crystals

Answer: D

A 65-year-old female patient came with chronic progressive bilateral Knee and ankle joint pain. While evaluating her knee X rays, you noticed Narrowing of joint spaces, eburnation of articular cartilage, subchondral Cystic formation and occasional osteophytes in the joint cavity. What is The most likely diagnosis?

- A. Reiter syndrome
- B. Seropositive rheumatoid arthritis
- C. Ankylosing spondylitis with fusion of joints
- D. Seronegative sacroiliitis and ulnar deviation
- E. Advanced degree of osteoarthritis/ degenerative joint disease.

Answer: E

A 49-year-old man comes to the clinic because of recurrent episodes of acute pain and Swelling of his left big toe. He is a lawyer and notes that these episodes usually occur After entertaining clients at elaborate dinners with alcohol. His temperature is 37.3°C (99.2°F), pulse is 90/min, respirations are 20/min, and blood pressure is 140/80 mm Hg. Physical examination shows his left big toe is erythematous, edematous, and Exceedingly tender to palpation. Analysis of synovial fluid from the joint reveals Needle-shaped crystals that appear yellow when viewed with parallel light. Which of The following is the most likely etiology of his condition?

- A. Rheumatic disease
- B. Calcium pyrophosphate dehydrate crystal deposition
- C. Mechanical injury
- D. Monosodium urate monohydrate crystal deposition
- E. Neisseria gonorrhoeae infection

Answer: D

You received a large soft tissue mass from the retroperitoneum for a 71-year-old male patient. The mass measures 20x18x15 cm and has ill-defined borders. Sectioning through the mass showed hemorrhage and necrosis. Which one of the following features would be most likely?

- A. Bland smooth muscle proliferation with low mitotic count
- B. Anaplastic cells with increased mitosis
- C. Benign neoplasm but with frequent local recurrence
- D. Low grade malignancy with good prognosis
- E. The presence of central cyst formation

Answer: B

A 40-year-old male comes to the emergency department because of foot pain. He states that since he awoke this morning his right big toe has been exquisitely painful and swollen. He denies any trauma to the area, fevers, or chills. He has a past medical history of diabetes mellitus type 2. Physical examination shows erythema and swelling of the right metatarsophalangeal joint. After initial treatment, he is given a medication to prevent this problem in the future. Which of the following is the most likely site of action of this medication?

- A. Binding and stabilization of tubulin
- B. Inhibition of COX1
- C. Inhibition of COX2
- D. Inhibition of ribonucleotide reductase
- E. Inhibition of xanthine oxidase

Answer: E

Morning stiffness that worsens with walking, diminished joint space and presence of osteophytes describes:

- A. Osteosarcoma
- B. Rheumatoid arthritis
- C. Paget disease
- D. Degeneration of articular cartilage

Answer: D

You are evaluating a possible smooth muscle tumor from the uterus for a 55-year-old female patient. Which one of the following features would raise the possibility of a malignant diagnosis (leiomyosarcoma) rather than benign leiomyoma (fibroid)?

- A. Increased mitosis and necrosis
- B. Red and hyaline degeneration
- C. Large size (> than 10 cm)
- D. Lobulated white cut surface
- E. The presence of central cyst formation

Answer: A

A 52-year-old man comes to the emergency department because of joint swelling, Pain, and trouble walking. Physical examination shows his right knee is swollen and Tender to palpation. An aspiration of the joint shows calcium pyrophosphate crystal Accumulation. Which of the following findings will most likely be found upon Microscopic examination of the synovial fluid?

- A. Elevated eosinophils
- B. Envelope-shaped crystals
- C. Less than 1,000/uL white blood cells
- D. Negatively birefringent needle shaped crystals
- E. Positively birefringent rhomboid crystals

Answer: E

Fibromatosis causes death by:

- A. Destruction of distant sites through metastasis
- B. Infiltration and local destruction
- C. Malignant proliferation of fibroblasts
- D. Benign proliferation with no recurrence

Answer: B

Severe form of osteoarthritis (Degenerative Joint Disease) is characterized by?

- A. Seronegative sacroiliitis and ulnar deviation
- B. Ankylosing spondylitis with fusion of joints
- C. Frequent vertebral compression fractures
- D. Greenstick fractures of long bones and pannus formations
- E. Osteophytes, narrowing of joint space, eburnation of the articular cartilage and subchondral cyst formation.

Answer: E

Pseudogout of the joint characterized by?

- A. Only acute attacks of joint pain and swelling.
- B. Deposition of negative birefringent needle shaped crystals
- C. Ulnar deviation and swan neck deformity in most cases
- D. Leukocytosis and febrile illness in affected patients
- E. Geometric and rhomboid crystals in joint space

Answer: E

Which of the following statements best describes synovial sarcoma?

- A. Highly anaplastic sarcoma with frequent lung metastasis
- B. Only found around the synovial joints
- C. Optimum treatment is by appropriate chemotherapy.
- D. Translocation (X;18) (p11; q11) is a characteristic finding.
- E. Biphasic benign tumor

Answer: D

You are evaluating a possible smooth muscle tumor from the uterus for a 55-year-old female patient. Which one of the following features would raise the possibility of a malignant diagnosis (leiomyosarcoma) rather than benign leiomyoma (fibroid)?

- A. Increased mitosis and necrosis
- B. Red and hyaline degeneration
- C. Large size (> than 10 cm)
- D. Lobulated white cut surface
- E. The presence of central cyst formation

Answer: A

A 45-year-old man came to your clinic with severe big toe pain and swelling. No history of trauma was mentioned. Aspiration of the big toe interphalangeal joint revealed needle shaped crystals with negative birefringence. The most likely diagnosis is:

- A. Osteoarthritis
- B. Acute Gouty arthritis
- C. Sero-negative Reiter disease
- D. Rheumatoid arthritis
- E. Pseudogout arthritis

Answer: B

Needle shaped negative birefringent is diagnostic of:

- A. Suppurative arthritis
- B. Rheumatoid arthritis
- C. Pseudogout
- D. Gouty arthritis

Answer: D

Which of the following is wrong regarding rheumatoid arthritis?

- A. TNF is the major mediator in pathogenesis.
- B. Distal interphalangeal joints are most affected.
- C. It is a chronic inflammatory auto-immune disease.
- D. Up to 80% of patients are seropositive for antibodies that attack self-antibodies

Answer: B

A 76-year-old male patient came with severe acute hip pain. Pelvic X-ray revealed a pathologic fracture at the neck of femur with multiple osteoblastic lesions of all pelvic bones and vertebrae. What would be the most cost-effective test to confirm the diagnosis?

- A. Open reduction and tissue biopsy**
- B. Grade V degenerative joint disease changes**
- C. Rheumatoid arthritis**
- D. CT scan of abdomen and pelvis**
- E. Serum prostate specific antibody (PSA) level**

Answer: E

which of the following is not true about gouty arthritis:

- A. Tophi are found only in joints.**
- B. Tophi in the articular cartilage**

Answer: A

Giant cell tumor has:

Answer: osteoclast-like cells

Which of the following is true regarding rheumatoid arthritis?

Answer: true non suppurative autoimmune synovitis

Brown projections, diagnosis:

Answer: Pigmented VilloNodular Synovitis PNVS

Old man comes to the ER complaining of joint pain, aspiration of the joint showed Positive birefringent, what is the possible diagnosis?

Answer: acute pseudogout

Which of the following is the best description for giant cell tumor?

Answer: Osteoclast-like giant cells

Osteoarthritis compared to rheumatoid arthritis is:

Answer: true non-suppurative chronic arthritis

True regarding fibrous tumors:

Answer: It is important not to diagnose nodular fasciitis as malignant

Anatomy

Which of the followings is NOT considered a content of infratemporal fossa?

- A) Otic ganglion
- B) Chorda tympani
- C) Greater petrosal nerve
- D) Pterygoid venous plexus
- E) E.Pterygoid muscles

Answer: C

Regarding ear anatomy which of the following is WRONG?

- A) The organ of Corti is present in scala media
- B) Reissners membrane separates scala media and scala vestibuli
- C) Membrane Labyrinth contains endolymph
- D) External acoustic meatus extends from concha to tympanic Membrane
- E) Upon an Examination of normal tympanic membrane using an Otoscope, the cone of light is directed anterosuperior

Answer: E

Which of the following retinal layers contains the nuclei of the bipolar cells, amacrine cells, Horizontal cells, and Muller cells?

- A) Rod and cone layer
- B) Outer limiting layer.
- C) Outer nuclear layer
- D) Inner nuclear layer
- E) Outer plexiform layer

Answer: D

All of the following regarding macula lutea is correct, except?

- A) Has diffuse margine
- B) is avascular
- C) Has the highest concentration of cone photoreceptor
- D) Is located nasal and inferior to optic disc

Answer: D

Examination of a patient indicates that he has a medially directed strabismus answered (squint). This sign strongly suggests a diagnosis of:

- A) None of the mentioned
- B) Third nerve palsy
- C) Fourth nerve palsy
- D) Sixth nerve palsy
- E) Trigeminal neuralgia

Answer: D

Stap wound in posterior triangle of neck can cause :

- A) Drop of shoulder
- B) loss of taste sensation
- C) tilting head to the same side
- D) ptosis

Answer: A

The intercostal space: Choose the INCORRECT statement:

- A) The collateral branch of the intercostal nerve is purely sensory
- B) The internal intercostal muscles are replaced posteriorly by a membrane
- C) The anterior intercostal veins in the upper 6 spaces join the internal thoracic vein
- D) The posterior intercostal arteries in the lower thorax originate from the aorta
- E) The external intercostal muscles are replaced anteriorly by a membrane

Answer: A

All the followings are considered branches of the second part of maxillary artery EXCEPT:

- A) Deep temporal arteries
- B) Masseteric artery
- C) Buccal artery
- D) Pterygoid branches
- E) Middle meningeal artery

Answer: E

Choose the CORRECT statement regarding optic disc:

- A) It is more nasal compared to macula lutea
- B) It has the highest concentration of rods
- C) It is relatively avascular
- D) It has a diffuse margin
- E) It contains fovea centralis

Answer: A

Regarding the two muscle of the middle ear , choose the wrong statement :

- A) Both muscles are derived from the first and second pharyngeal arches
- B) tensor tympani muscle is related to the anterior wall
- C) stapedius muscle is related to the posterior wall
- D) tensor tympani muscle Dampens down vibration of the secondary tympanic membrane .
- E) Stapedius muscle dampens down vibration of stapes

Answer: D

A patient has a fracture in the middle cranial fossa. You suspect damage to the nerve passing Through foramen ovale. You would test the motor function of this nerve by:

- A) Touching the face around the jawline with a cotton swab and ask the patient whether he felt it
- B) Asking the patient to rotate his head to one side against resistance
- C) Asking the patient to clench his teeth together and feel the bulk of the muscles supplied by Mandibular nerve
- D) Asking the patient to close his eyes tightly and open them by applying gentle pressure
- E) Asking the patient to speak loudly

Answer: C

Parasympathetic innervation to the head, choose the CORRECT statement:

- A) Ciliary ganglion receives its preganglionic parasympathetic fibers from nasociliary nerve
- B) Preganglionic parasympathetic fibers in facial nerve end in two different ganglia
- C) Submandibular ganglion receives preganglionic parasympathetic fibers from Glossopharyngeal nerve
- D) Preganglionic parasympathetic fibers of lesser petrosal nerve synapse in pterygopalatine Ganglion
- E) Ciliary ganglion sends postganglionic parasympathetic fibers to the radial muscle of the iris

Answer: B

Which of the following is content of infratemporal fossae ?

- A) greater wing of sphenoid
- B) lesser wing of sphenoid
- C) palatine
- D) occipital bone

Answer: A

Contents of the neck triangles, choose the WRONG match:

- A) Internal jugular vein: carotid triangle
- B) Ansa cervicalis: muscular triangle
- C) Spinal accessory: posterior triangle
- D) Subclavian vessels: supraclavicular triangle
- E) Facial vessels: submandibular triangle

Answer: B

A lesion causing compression of the facial nerve at the internal acoustic meatus will cause Ipsilateral:

- A) Paralysis of the facial muscles
- B) Paralysis of the facial muscles, a decreased salivation, loss of taste and lacrimation
- C) Paralysis of the facial muscles, increased salivation, loss of taste and lacrimation
- D) Paralysis of the facial muscles and loss of taste
- E) Paralysis of the facial muscles, loss of taste and lacrimation

Answer: B

Which of the following is wrong regarding lymph drainage of The neck?

- A) Deep cervical lymph nodes drain only from the neck
- B) Superficial cervical nodes are superficial to sternocleidomastoid Muscle
- C) The intermediate tendon of omohyoid divides deep cervical nodes into upper and lower groups
- D) The jugulo-omohyoid node receives drainage from the tongue

Answer: A

All the following muscles are supplied by ansa cervicalis EXCEPT:

- A) Sternohyoid
- B) Sternothyroid
- C) Superior belly of omohyoid
- D) Inferior belly of omohyoid
- E) Thyrohyoid

Answer: E

The carotid sheath and its contents may be safely retracted as a unit during surgical procedures of the neck. The contents of the carotid sheath include all of the following structures EXCEPT the:

- A) External carotid artery
- B) Internal jugular vein
- C) Carotid plexus
- D) Deep cervical lymph nodes
- E) Tenth cranial nerve

Answer: A

Which of the following muscles receives its motor supply by 2 cranial nerves?

- A) Trapezius
- B) Thyrohyoid
- C) Omohyoid
- D) Digastric
- E) Buccinator

Answer: D

Which of the following is false about triangles of the neck?

- A) The inferior belly of omohyoid muscle divides the posterior Triangle into two triangles
- B) Hypoglossal nerve passes through posterior triangle
- C) The anterior triangle is bordered superiorly by the mandible
- D) The trachea and esophagus are contents of the muscular triangle

Answer: B

The correct path of vestibulocochlear nerve is:

- A) Hypoglossal canal > neck
- B) Internal acoustic meatus > Inner Ear
- C) Foramen rotunda > Pterygopalatine fossa
- D) Internal acoustic meatus > stylomastoid foramen

Answer: B

A patient suffers damage to the orbit in a road traffic accident resulting in damage to the third cranial nerve. All the following signs will probably be present in the involved eye EXCEPT which?

- A) Rounding of the crystalline lens is affected due to accommodation loss
- B) The eyelid is manually elevated due to ptosis
- C) The pupil is dilated
- D) The eyeball is deviated downward and out
- E) Decreased lacrimation

Answer: E

Sternocleidomastoid, choose the WRONG statement:

- A) It is crossed superficially by the external jugular vein
- B) Contraction of one muscle rotates the head to the opposite side
- C) Has two heads of origin
- D) It is paralyzed when spinal accessory is severed in the posterior triangle
- E) It is enclosed by the investing fascia

Answer: D

Which of the following muscles is paralyzed when accessory Nerve is damaged in posterior triangle?

- A) Scalene anterior
- B) Trapezius
- C) Sternomastoid
- D) Posterior belly of digastric

Answer: B

Which of the following is wrong regarding the middle ear?

- A) The muscle on the posterior wall is innervated by a branch of trigeminal nerve
- B) It is separated from inner ear by the medial wall
- C) Its floor is related to the internal jugular vein
- D) None of the above is wrong

Answer: A

Ear anatomy, choose the WRONG statement

- A) Both muscles of the middle ear dampen down vibrations of tympanic membrane
- B) The pharyngotympanic tube is at the anterior wall of the middle ear
- C) Internal jugular vein is closely related to the floor of the middle ear
- D) The sensory innervation of the lower half of the auricle is derived from great Auricular nerve
- E) The tympanic membrane is at the lateral wall of the middle ear and is concave Laterally

Answer: A

How to test injury of the motor branch of mandibular nerve?

- A) Make them open the jaw against resistance
- B) Ask them to open their eyes
- C) Ask them to show their teeth
- D) Ask them to close their eyes

Answer: A

Which of the following is correct?

- A) Posterior digastric is found between the submandibular triangle and the carotid triangle
- B) The posterior belly of digastric bounds the submental triangle
- C) Ansa cervicalis is found outside of the carotid triangle
- D) Facial artery and vein pass through the submental triangle

Answer: A

Which of the following sentences is wrong regarding the middle ear?

- A) The roof is formed by the petrous part of the temporal bone
- B) Polmontory forms the anterior wall
- C) The vertical part of the facial nerve passes through the posterior wall
- D) It contains two muscles, two nerves and three ossicles

Answer: B

All of the following are true about lymph nodes except:

- A) Superficial cervical nodes are found along the external jugular vein
- B) Lateral group of deep cervical nodes are found along internal jugular vein
- C) Jugulo-omohyoid node receives lymphatic drainage from the tongue
- D) Pretracheal lymph nodes are found in superficial fascia

Answer: D

false about infratemporal fossa

- A) Contains otic ganglion
- B) The maxillary artery and nerve pass through it
- C) The mandibular nerve passes through it
- D) The lesser petrosal nerve is one of its contents

Answer: B

injury to oculomotor

- A) Pupil constriction
- B) Drooping of the lower eyelid
- C) Inability to abduct the eye
- D) None of the above

Answer: D

Which of the following is true?

- A) Stapedius is supplied by the mandibular nerve
- B) Tensor tympani is supplied by the facial nerve
- C) Stapedius muscle originates from the posterior wall & inserted into the Medial wall
- D) Tensor tympani dampens vibrations of stapes and tympanic membrane

Answer: C

Which of the following is mismatched?

- A) Glossopharyngeal – Otic ganglion
- B) Mandibular nerve – foramen ovale
- C) Stapedius – temporal bone
- D) Macula lutea – sharpest vision

Answer: C

Removing a bone flap from the skull to operate on the brain is called:

- A) Craniotomy
- B) Cortectomy
- C) Decompression
- D) Ventriculostomy
- E) Skullectomy

Answer: A

One of the following is not a content of the infratemporal fossa?

Answer: masseter muscle

True about the muscles of the neck:

Answer: Branches of the mandibular nerve supply two suprahyoid muscles

Wrong about the cornea?

Answer: descemet's membrane is the membrane under the stratified epithelium Layer

All are correct about muscles of mastication except:

Answer: fibers of medial pterygoid muscle are oriented almost horizontally

Which of the following depresses mandible or elevates hyoid bone?

Answer: Posterior belly of digastric

About ear anatomy, which is wrong?

Answer: upon the examination of normal tympanic membrane using an Otoscope, the cone of light is directed anterosuperior

Regarding macula lutea, all are correct except?

Answer: it is located nasal and inferior to optic disc

A stab wound in the posterior triangle on the neck can lead to:

Answer: drop of shoulder

Choose the wrong statement about the 2 muscles of the middle ear:

Answer: tensor tympani muscle dampens down vibrations of the secondary Tympanic membrane

The roof of the infratemporal fossa is formed by:

Answer: the greater wing of sphenoid bone

About the neck, choose the incorrect:

Answer: occipital and carotid triangles are bound posteriorly by trapezius Muscle

Wrong about chorda tympani:

Answer: Carries postganglionic parasympathetic fibers

Which retinal layer contains cell bodies of rods and cones?

Answer: Outer nuclear

Wrong about the ciliary muscle?

Answer: Contraction of the ciliary muscle increases the tension in the Suspensory ligament

Embryology

Bone of the middle ear formed by :

- A) 1st pharyngal arch
- B) 1st and 2nd pharyngal arches
- C) 1st,2nd,3rd,4th,pharyngal arches
- D) 2nd,3rd pharyngal arches

Answer: B

Which of the followings is a derivative of the first pharyngeal cleft?

- A) Linner mucous layer of tympanic membrane
- B) Mucous layer of pharyngotympanic tube
- C) Sphenomandibular ligament
- D) Outer cutaneous layer of tympanic membrane
- E) Palatine tonsil

Answer: D

Which of the following arches form hyoid bone?

- A) 1st arch
- B) 2nd arch
- C) 3rd arch
- D) B+c

Answer: D

The tympanic cavity is formed by:

- A) 1st arch
- B) 1st and 2nd arches
- C) 1st pouch
- D) 1st cleft

Answer: C

Glossopharyngeal nerve supplies muscles of which arch?

- A) 1st arch
- B) 2nd arch
- C) 3rd arch
- D) 4th and 6th arches

Answer: C

Muscles of facial expression are derivatives of which of the following pharyngeal arches?

- A) 2nd arch
- B) 3rd arch
- C) 4th arch
- D) 1st arch
- E) 6th arch

Answer: A

Failure of fusion between the maxillary process and the intermaxillary segment at one side Results in which one of the followings?

- A) Median cleft lip
- B) Unilateral macrostomia
- C) Unilateral oblique facial cleft
- D) Bilateral primary cleft palate combined with bilateral cleft lip
- E) Unilateral primary cleft palate combined with unilateral cleft lip

Answer: E

Regarding the two muscle of the middle ear , choose the wrong statement :

- A) Both muscles are derived from the first and second pharyngeal arches
- B) tensor tympani muscle is related to the anterior wall
- C) stapedius muscle is related to the posterior wall
- D) tensor tympani muscle Dampens down vibration of the secondary Tympanic membrane .
- E) Stapedius muscle dampens down vibration of stapes

Answer: D

Failure of fusion between maxillary and fronto-nasal processes causes:

- A) Median cleft lip
- B) Oblique facial cleft
- C) Unilateral cleft lip
- D) Bilateral cleft lip

Answer: B

The hyoid bone is derived from:

- A) The first pharyngeal arch
- B) The second pharyngeal arch
- C) The second and third pharyngeal arches
- D) The third pharyngeal arch

Answer: C

Oblique facial cleft results from the failure in fusion of:

- A) Maxillary and lateral nasal prominences
- B) Medial nasal prominences
- C) Maxillary prominences
- D) Maxillary and medial nasal prominences

Answer: A

During a routine auditory test, a child is found have a severe conduction deficit in one ear. High resolution CT scan of the tympanic cavity shows a complete agenesis of the stapes. This condition could result from failur of formation of the stapes from which of the following structures?

- A) First branchial arch
- B) First branchial pouch
- C) Second branchial arch
- D) Third branchial arch
- E) Frontonasal process

Answer: C

From what pharyngeal arches is the bone of the middle ear formed?

Answer: 1st and 2nd pharyngeal arches

Which of the following conditions results from failure of fusion between Maxillary process and intermaxillary segment on both sides?

Answer: Bilateral cleft lip

Not formed by the first arch?

Answer: stylohyoid

Microbiology

A 50-year-old woman receiving chemotherapy via a subclavian catheter For acute leukemia. She presented with fever and stiffness in the neck with Clinical suspicion of meningitis. CF culture grew budding yeasts that Formed germ tubes. The organism most likely causing this infection is:

- A) *Cryptococcus neoformans*
- B) *Candida albicans*
- C) *Aspergillus Fumigatus*
- D) *Histoplasma capsulatum*
- E) *Candida tropicalis*

Answer: B

Which of the following is true regarding *Tinea versicolor*?

- A) It is an example of cutaneous mycoses
- B) It is caused by candida species
- C) Its only clinical manifestation is hyperpigmentation
- D) It is diagnosed by a device called Wood lamp

Answer: D

The most prevalent (common) infection among all dermatophytoses is:

- A) *Tinea pedis*
- B) *Tinea unguium*
- C) *Tinea corporis*
- D) *Tinea capitis*
- E) *Tinea cruris*

Answer: A

Which of the following is Not considered an opportunistic fungal infection:

- A) Candidiasis
- B) Sporotrichosis
- C) Aspergillosis
- D) Zygomycosis
- E) All answers considered opportunistic fungal infections

Answer: B

Which of the following is the most common form of infection in patients With mucormycosis:

- A) Cutaneous
- B) Rhinocerebral
- C) Pulmonary
- D) Gastrointestinal
- E) Hematogenous dissemination

Answer: B

Which of the following is correct: (OM=Osteomyelitis)

- A) The presence of a prosthetic joint will less likely aid hematogenous Spreading organisms to cause OM
- B) MRSA and MSSA are shown to be equally aggressive (virulent)
- C) Countries with better healthcare and access to orthopedics, have less OM than countries with limited healthcare
- D) Direct bone contamination yields hematogenous seeding of the bone Causing OM
- E) A patient with vertebral OM from Africa is likely to reveal mycobacterial OM

Answer: E

Dermatophytes are fungi that:

- A) Infect the superficial keratinized areas of the body
- B) Cause inapparent systemic infections
- C) Invariably invade the subcutaneous tissues
- D) Produce morphologically identical spores by all genera
- E) Best grow at 37°C

Answer: A

Which of the following is true regarding Tinea versicolor:

- A) It is an example of cutaneous mycoses
- B) It is caused by candida species
- C) Its only clinical manifestation is hyperpigmentation
- D) It is diagnosed by a device called Wood lamp

Answer: D

Pityriasis versicolor is caused by:

- A) Candida albicans
- B) Dermatophytes
- C) Malassezia furfur
- D) Madurella mycetomatis
- E) None of the above

Answer: C

Which of the following is CORRECT:

- A) Surgeries that involve GI tract or other lumens produce monomicrobial Surgical site infections
- B) More infectious dose is required to cause infection on prosthesis
- C) Non infected surgical wounds are not aerated and remain sutured
- D) If a large amount of infected material and dead tissue is present in the Wound, systemic therapy with antimicrobials and primary intention healing Is indicated
- E) Surgical site infections will have clinical manifestations within the first Few hours post-surgery

Answer: C

• Which of the following is correct: (OM=Osteomyelitis)

- A) Pseudomonas is becoming increasingly more sensitive to Antimicrobials in OM setting
- B) Viruses almost never infect bone
- C). S. Pyogenes is most associated with implants or foreign material
- D). K. Pneumoniae may be resistant to antimicrobials before or after Therapy, but not during
- E) The most common and most aggressive pathogen is S. Aureus

Answer: E

Which of the following is correct: (OM=Osteomyelitis)

- A) There is no way for us to detect antimicrobial resistance using PCR
- B) X-ray features can be seen within a few days of OM
- C) Normal White cell count Excludes the diagnosis of OM
- D) High ESR or CRP confirms the diagnosis of OM in presence of clinical Suspicion
- E) Blood cultures can be negative in the setting of OM

Answer: E

Hypopigmented macules on the patient's chest and back / mild itchiness. On KOH mount, we will most likely see:

Answer: round cells with short curved hyphae

True about pressure ulcer with deep necrosis:

Answer: blood infection is more likely

An 8-month old boy burned by hot water had partial thickness burns on 10% of his total surface area. He was admitted to hospital and received fluid therapy and wound care treatment. During hospitalization, he developed a high fever and exfoliation of the skin, except for the burns. He then received antibiotic infusion treatment daily. 6 days after initiating the treatment, he had epithelization of the trap surface, except for his burns. Skin exfoliation affected 36% of the total body surface area. What is the possible diagnosis:

Answer: pseudomonas

Regarding hematogenous osteomyelitis, which of the following is correct:

Answer: hematogenous osteomyelitis is the most common form in Children

Pharmacology

Allopurinol decreases the plasma concentration of:

- A) Hypoxanthine
- B) Xanthine
- C) Uric acid
- D) Purine bases
- E) All of the above

Answer: C

Which of the following drugs could be used to decrease rate of production of uric acid:

- A) Naproxen
- B) Aspirin
- C) Colchicine
- D) febuksostat
- E) Ibuprofen

Answer: D

All the following drugs will be useful in the treatment of an acute Attack of gout; EXCEPT:

- A) Indomethacin
- B) Prednisone.
- C) Colchicine.
- D) Allopurinol.
- E) Diclofenac sodium

Answer: D

Which of the following is true regarding depolarizing and non-Depolarizing neuromuscular blockers?

- A) They have the same chemical structure.
- B) They have different modes of elimination.
- C) They have the same duration of action.
- D) They generally work on different targets.

Answer: B

Which of the following agents binds to tubulin leading to depolymerization and disrupting neutrophils mobility:

- A) Colchicine
- B) Febuxostat
- C) Sarilumab
- D) Abatacept
- E) Probenecid

Answer: A

Which of the following drugs is not used for acute gouty arthritis?

- A) Probenecid
- B) Steroids
- C) Ibuprofen
- D) Colchicine

Answer: A

Depolarizing agents include all of the following properties EXCEPT:

- A) Interact with nicotinic receptor to compete with acetylcholine without receptor activation
- B) React with the nicotinic receptor to open the channel and cause depolarisation of the end plate
- C) Cause desensitization, noncompetitive block manifested by flaccid paralysis
- D) Cholinesterase inhibitors do not have the ability to reverse the blockade
- E) None are correct

Answer: A

Which of the following drugs acts as agonist at Nm receptors?

- A) Tizanidine
- B) Succinylcholine
- C) Cisatracurium
- D) Mivacurium
- E) Tubocurarine

Answer: B

Which of the following neuromuscular blockers causes transient muscle fasciculations:

- A) Mivacurium
- B) Pancuronium
- C) Succinylcholine
- D) Tubocurarine

Answer: C

All the following are concerned as drugs of acute gout arthritis,except?

- A) Allopurinol
- B) Probenecid
- C) Colchicine
- D) Diclofenac

Answer: A

Non-depolarisation neuromuscular blocking agents:

- A) Block acetylcholine reuptake
- B) Prevent access of the transmitter to its receptor and depolarization
- C) Block transmission by an excess of a depolarizing agonist
- D) All of the above

Answer: B

Neuromuscular blockers don't cause effects on CNS because of:

- A) They do not cross BBB.
- B) Acetylcholine receptors attach to them and do not let them go.
- C) They are more selective for muscular ones.
- D) Nicotinic receptors are not found in the brain.

Answer: A

Colchicine is best described as it:

- A) Causes cellular proliferation.
- B) Enhances uric acid excretion.
- C) Is an effective analgesic in osteoarthritis.
- D) Is used for treatment and prevention of acute gouty arthritis.
- E) All of the above

Answer: D

Characteristics of probenecid include all of the following, EXCEPT:

- A) It promotes the renal tubular secretion of penicillin
- B) It is useful in the treatment of gout
- C) At appropriate doses, it promotes the excretion of uric acid
- D) The metabolic products of probenecid are uricosuric

Answer: A

Which of the following muscle relaxants has the maximum Duration of action:

- A) Doxacurium
- B) Atracurium
- C) Vecuronium
- D) They all have the same duration of action.
- E) Rocuronium

Answer: A

To lower uric acid levels in blood and urine you should use:

- A) Colchicine
- B) Indomethacin
- C) Allopurinol
- D) Corticosteroids

Answer: C

A 38-year-old patient who was admitted to the emergency room with extensive soft-tissue burns. He was semiconscious and was Artificially ventilated. His uncoordinated respiratory movements were Interfering with the mechanical ventilation. Which of the following Drugs was most likely administered to decrease the patient's Spontaneous breathing?

- A) Botulinum toxin
- B) Dantrolene
- C) Vecuronium
- D) Neostigmine
- E) Succinylcholine

Answer: C

Which of the following drugs used in the treatment of gout has as its primary effect the reduction of uric acid synthesis

- A) Allopurinol
- B) Naproxen
- C) Colchicine
- D) Indomethacin

Answer: A

A 56-year-old male came to the emergency room complaining of bone Pain ,the physicians decided for surgery, before the operation, they Made the dibucaine number test and they found that the patient has Choline esterase deficiency ,which one of the following neuromuscular Blockers is contraindicated for this patient : (this question is very Similar to the question written in the exam but the difference is in Paraphrasing)

- A) Succinylcholine
- B) Cisatracurium
- C) Mivacurium
- D) Vecuronium
- E) Tubocurarine

Answer: C

A 61-year-old woman. Anesthesia was induced by thiopental and Maintained by sevoflurane and tubocurarine. After surgery the Anesthesiologist administered a drug to overcome the residual muscle Relaxant effect of tubocurarine. Which of the following drugs was most likely given

- A) Neostigmine
- B) Succinylcholine
- C) Cisatracurium
- D) Tizanidine
- E) Dantrolene

Answer: A

Strong nonsteroidal anti-inflammatory drugs are more commonly Used than colchicine in acute gout because:

- A) They are more effective.
- B) They are better tolerated.
- C) They act more rapidly.
- D) They have additional uricosuric action.
- E) All of the above

Answer: B

What makes the acyclovir specific:

Answer: Its conversion to MP derivative by viral thymidine kinase

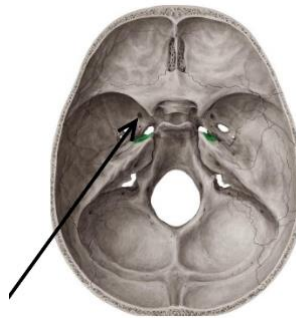
How does Probenecid decrease serum uric acid:

Answer: By inhibiting tubular reabsorption

PRACTICAL

Whats the name of these foramen?

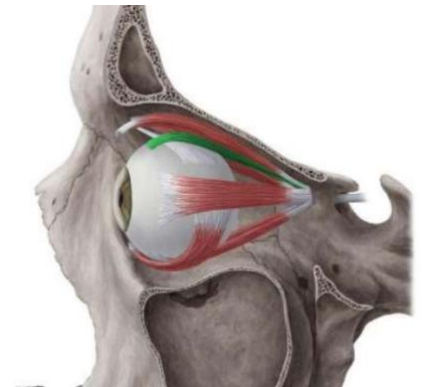- A) ovale
- B) rotundum
- C) lacerum
- D) Spinosum



Answer: B

If all extraocular muscles were paralyzed except for the green Highlighted muscle, the cornea would of be in this position:

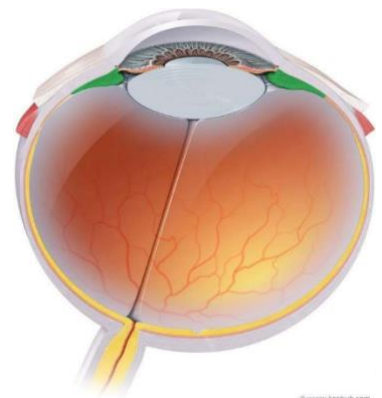
- A) Abducted and elevated
- B) Adducted and depressed
- C) None of the mentioned
- D) Abducted and depressed
- E) Adducted and elevated



Answer: E

Cell bodies of motor neurons supplying the green highlighted structure lie in which ganglion?

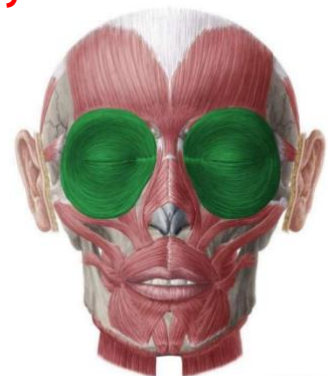- A) Trigeminal
- B) Ciliary
- C) Pterygopalatine
- D) Genuiculate
- E) Otic



Answer: B

Paralysis of the green highlighted muscle would most probably result in:

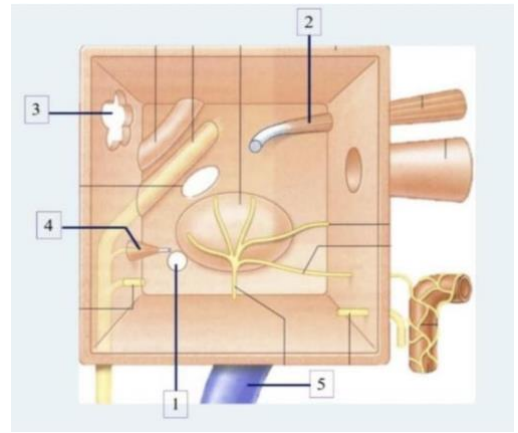
- A) Inability to rotate the eyeballs laterally
- B) Double vision
- C) Inability to elevate the upper eyelids
- D) Inability to close the eyes
- E) Inability to elevate the eyebrows



Answer: D

Choose the WRONG match:

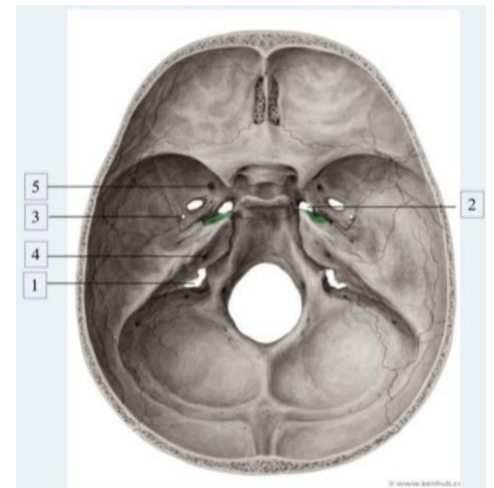
- A) A muscle supplied by mandibular nerve: 2
- B) Round window in the medial wall: 1
- C) External jugular vein: 5
- D) Aditus to mastoid: 3
- E) A muscle supplied by facial nerve: 4



Answer: C

Choose the WRONG match:

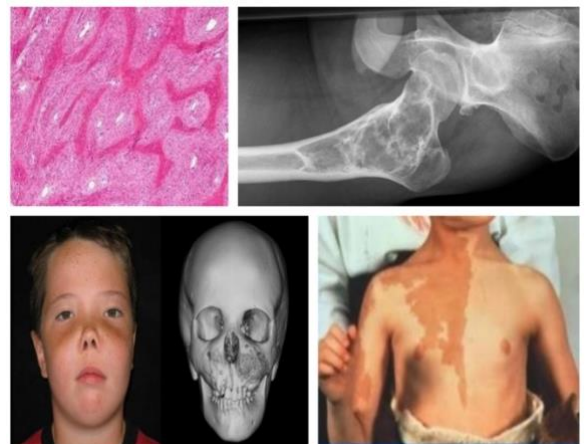- A) Filled by cartilage and fibrous tissue: 2
- B) Vagus, accessory and glossopharyngeal nerves: 1
- C) Middle meningeal artery: 3
- D) Mandibular nerve: 5
- E) Facial and vestibulocochlear nerves: 4



Answer: D

The images below belong to a 1-year-old boy who came with precocious puberty and multiple Endocrine glands abnormalities. What is the most likely Diagnosis?

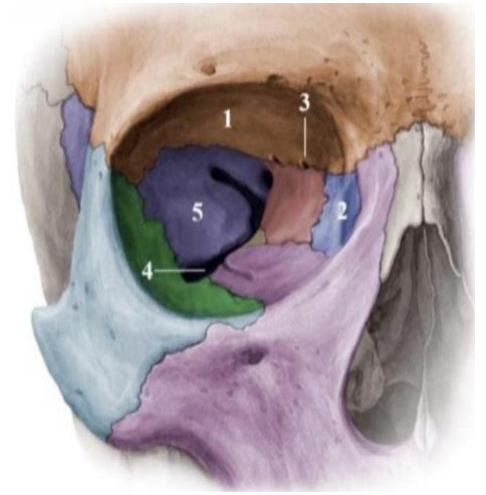
- A) Leontiasis ossea / platybasia
- B) McCune-Albright syndrome
- C) Multiple hereditary chondromatosis
- D) Familial Paget disease of bone
- E) Mazabraud syndrome



Answer: B

Choose the WRONG match:

- A) 4 is located between the floor and the lateral wall
- B) 1 is the orbital plate of frontal bone
- C) 2 is the lacrimal bone
- D) 5 is the orbital plate of zygomatic bone
- E) 3 transmits anterior ethmoidal nerve and vessels



&Answer: D

Identify the green highlighted layer:

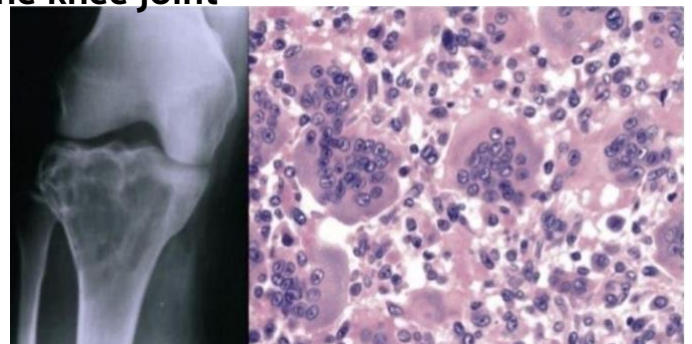
- A) Outer nuclear layer
- B) Inner nuclear
- C) Outer plexiform
- D) Photoreceptor layer
- E) Retinal pigment epithelium



Answer: D

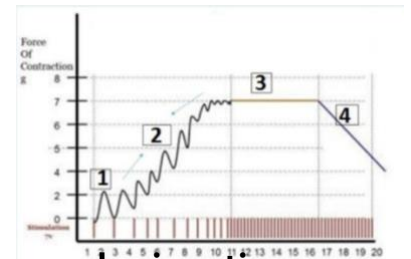
You are evaluating a 45-year-old woman with upper leg pain. The X- ray and the open biopsy material are shown below. This disease is characterized by?

- A) Association of Paget disease of bone
- B) Tumor cells lack RNANKL protein
- C) Cure is achieved by disarticulation from the knee joint
- D) Locally aggressive neoplasm of adults
- E) High frequency of metastasis.



Answer: D

4) The figure below, represents recordings of Twitches by stimuli that caused contraction of All muscle fibers in the preparation. Which of The following statements is TRUE with regard To the recording?

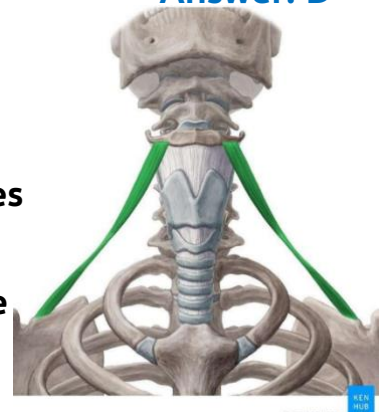


- A) 4 represents complete tetanization
- B) 3 represents incomplete tetanization
- C) 2 represents motor unit summation
- D) 4 happens due to decreased transmission at neuromuscular junction
- E) In 3 lower Ca^{++} concentration is found in the sarcoplasm than in 1

Answer: D

Choose the WRONG statement regarding this muscle:

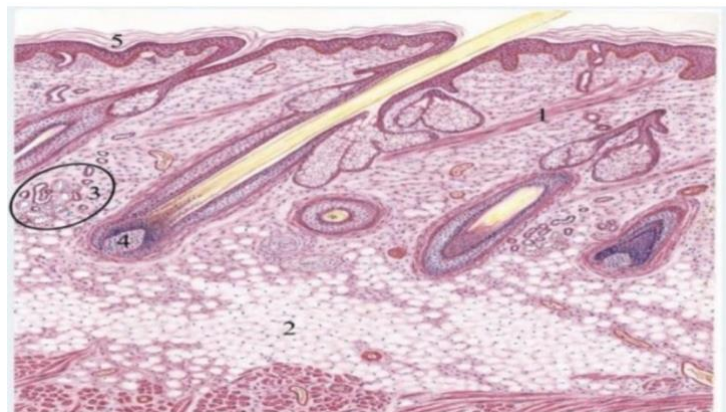
- A) Its supplied by ansa cervicalis
- B) Its superior belly separates muscular and carotid triangles
- C) None of the mentioned
- D) Its inferior belly is located in the posterior triangle of the neck
- E) It is one of infrahyoid muscles and has two bellies



Answer: C

Choose the WRONG match:

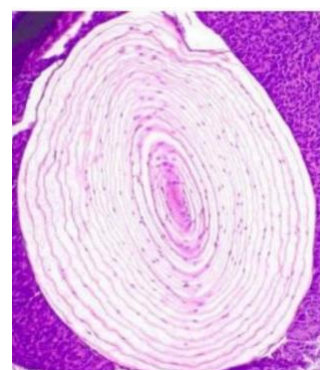
- A) Keratin: 5
- B) Dermal papilla: 4
- C) Arrector pili: 1
- D) Sebaceous gland: 3
- E) Hypodermis: 2



Answer: D

The following section represents:

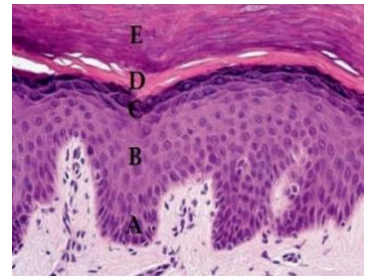
- A) Meissner corpuscle
- B) Pacinian Corpuscle
- C) Ruffini Corpuscle
- D) Merkel disc



Answer: B

Which of the following is false regarding this histology section:

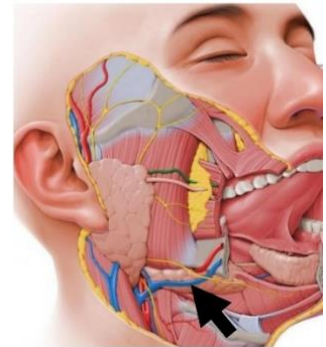
- A) It is taken from the palms and soles of the feet
- B) No hair or sebaceous glands
- C) This section is taken from the eyelid
- D) Thick skin with prominent stratum corneum



Answer: C

The arrow represents:

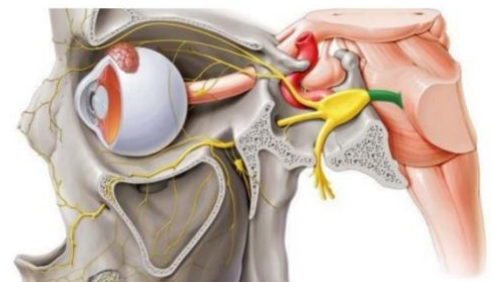
- A) Facial vein
- B) Facial artery
- C) Internal jugular vein
- D) External jugular vein



Answer: A

Branches of the following nerve pass through all of the following except:

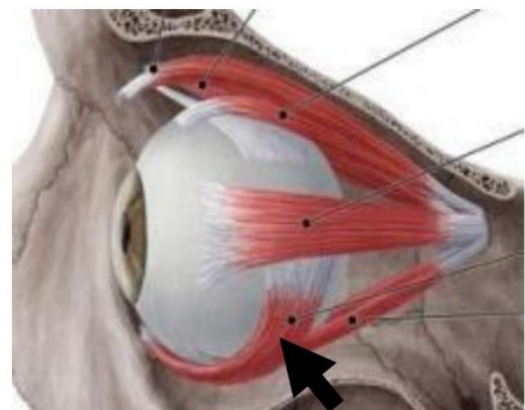
- A) Foramen lacerum
- B) Superior orbital fissure
- C) Foramen ovale
- D) Foramen rotundum



Answer: A

The action of the following muscle is:

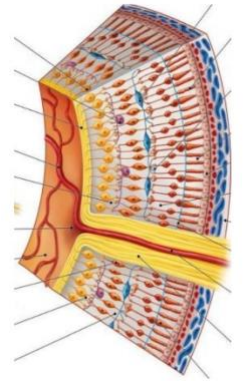
- A) Adduction and depression
- B) Medial rotation
- C) Lateral rotation
- D) Abduction and elevation



Answer: D

Which of the following regarding the following structure is incorrect?

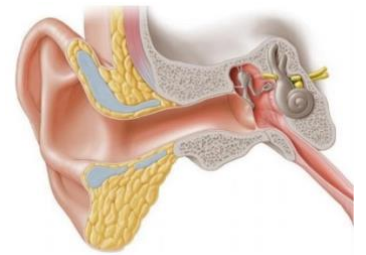
- A) The neural retina is composed of 9 layers
- B) Central retinal artery ends have anastomosis
- C) Muller cells are found in the inner nuclear layer
- D) Photoreceptors are located in the rod and cone layer



Answer: B

Which of the following is wrong?

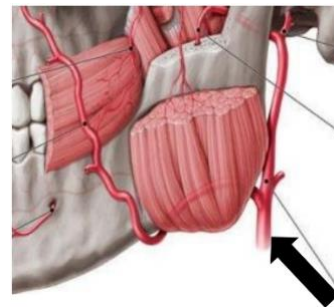
- A) The stapedius muscle is innervated by the facial nerve
- B) Tensor tympani is innervated by the anterior division of mandibular never
- C) The 8th cranial nerve is responsible for hearing and equilibrium
- D) Two muscles are responsible for dampening vibrations



Answer: B

Which of the following is wrong regarding the following artery?

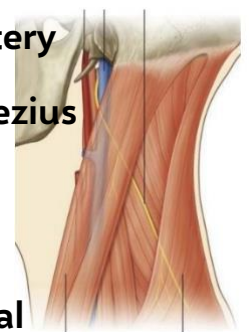
- A) Divides into superficial temporal and maxillary arteries behind the neck of mandible
- B) Not found inside the carotid sheath
- C) Its posterior branch pass deep to pterion
- D) One of the contents of the carotid triangle



Answer: C

Which of the following is wrong?

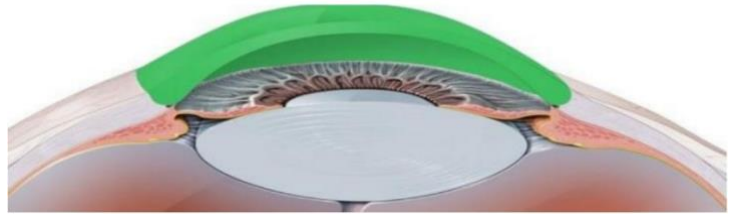
- A) The internal jugular vein does not pass with the internal carotid artery
- B) The accessory nerve passes between sternocleidomastoid and trapezius muscle
- C) The external carotid artery is not shown
- D) The internal carotid artery enters the skull through the carotid canal



Answer: A

Cell bodies of sensory neurons for the following structures are from

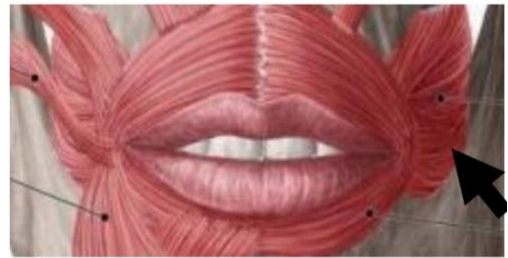- A) Facial nerve
- B) Optic nerve
- C) Oculomotor nerve
- D) Trigeminal nerve



Answer: D

Paralysis to the following muscle causes:

- A) Saliva dropping
- B) Inability to open the mouth
- C) Inability to clench teeth
- D) Inability to move the jaw



Answer: A

The following picture represents:

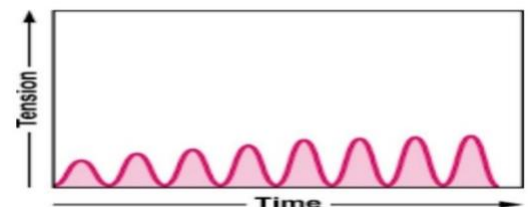
- A) Benign most common soft tissue tumor
- B) Malignant soft tissue tumor
- C) Nodular fasciitis
- D) Fibromatoses



Answer: A

The following graph represents:

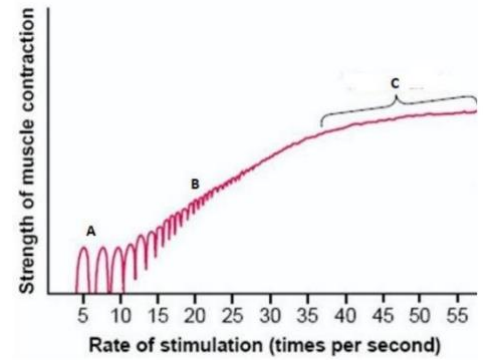
- A) Complete tetanization
- B) Fatigue state
- C) Treppe graph
- D) Wave summation



Answer: C

Which of the following regarding the following graph is false?

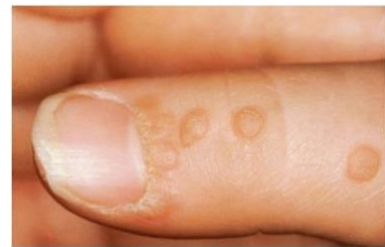- A) C represents tetanization
- B) Fatigue follows C
- C) B has lower stimulation frequency than A
- D) C has higher stimulation frequency than A



Answer: C

The following picture represents:

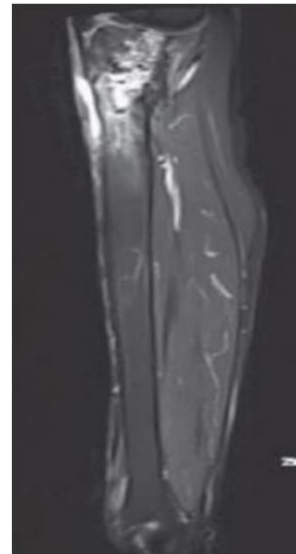- A) Impetigo
- B) Whitlow
- C) Paronychia
- D) Verruca vulgaris



Answer: D

The following X-ray represents:

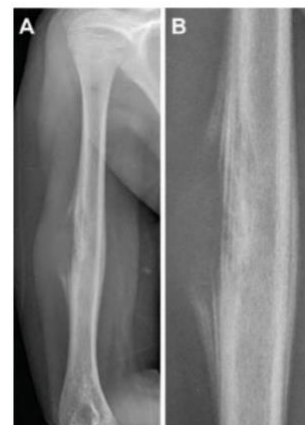- A) Osteomyelitis
- B) Septic arthritis
- C) Myositis
- D) Pyomyositis



Answer: A

The following syndrome is caused by a mutation in which of the following genes?

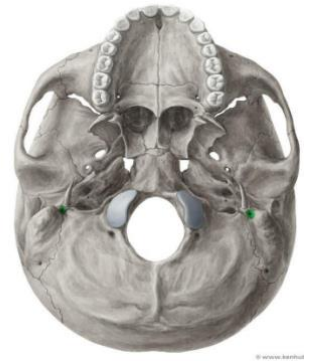
- A) APC gene
- B) t(11;22)
- C) t(17;22)
- D) CTNNB1



Answer: B

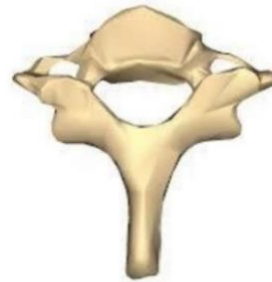What is the cranial nerve crossing the pointed foramen?

Answer: 7th cranial nerve



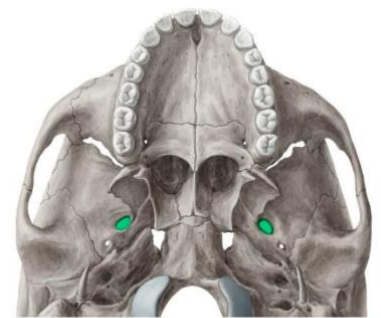
What is the name of this vertebrae?

Answer: 7th cervical vertebrae



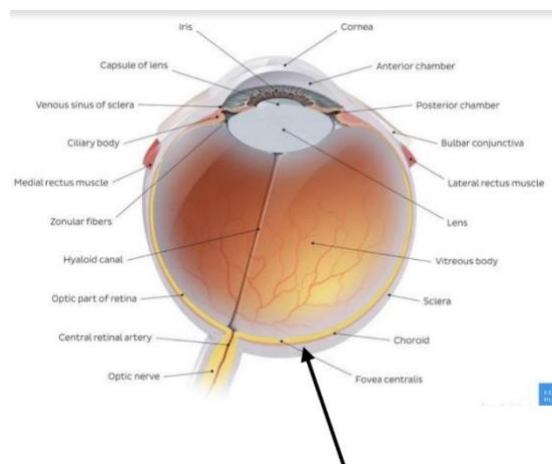
The foramen showed in the picture below is called:

Answer: ovale



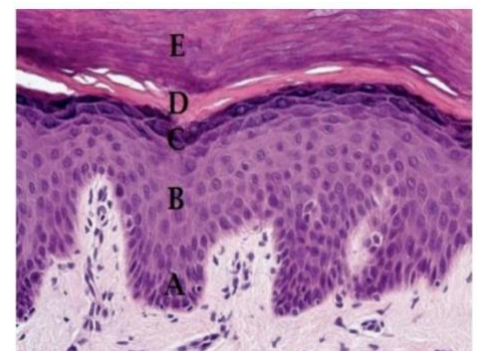
Regarding the pointed structure, choose the false statement:

Answer: the sclera is made of Dense connective tissue And is transparent



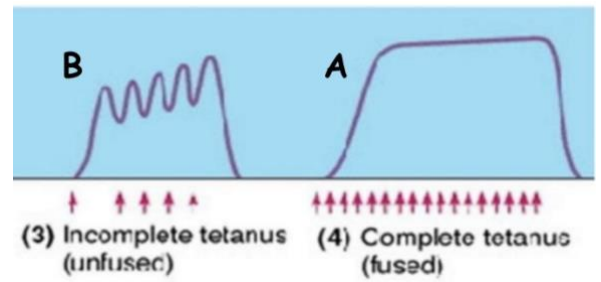
Name B,D respectively:

Answer: stratum spinosum, stratum lucidum.



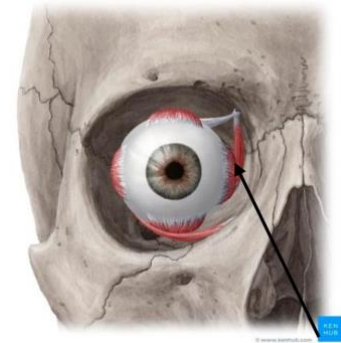
Which is not true:

Answer: the concentration of calcium ions in the sarcoplasm of B is lower than that of A



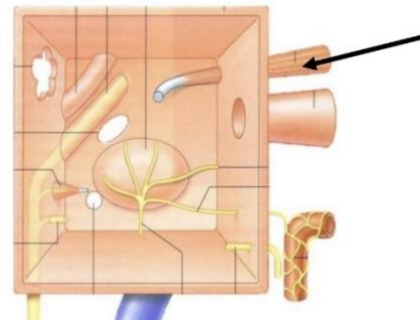
What is the function of the pointed muscle?

Answer: adduction



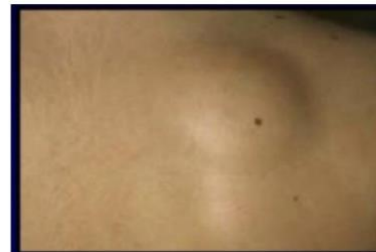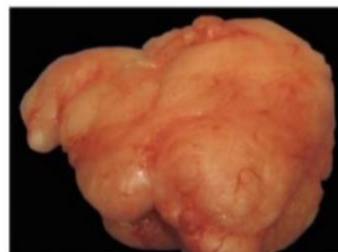The pointed structure is

Answer: Tensor Tympani muscle



A patient showed up with a similar appearance as in the picture, which of the following is true?

Answer: the forming cells are typical adipocytes



The End

أتمنى لكم التوفيق دفعتي العزيزة 😊

لا تنسوني من صالح دعائكم 🙏

Malek Abu Rahma