



Skull-1

Norma Frontalis, Lateralis,
Occipitalis and Verticalis

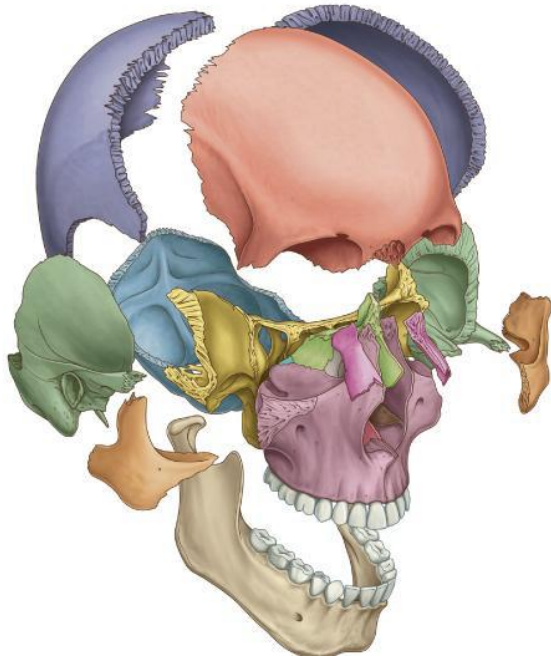
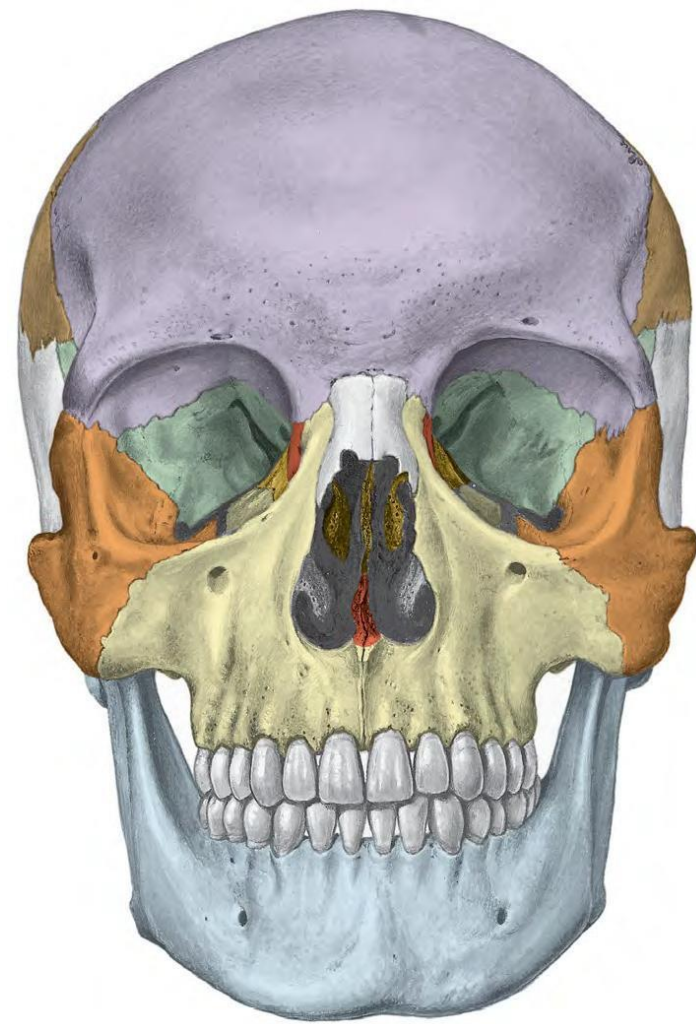
Dr. Heba Kalbouneh

DDS, MSc, DMD/PhD

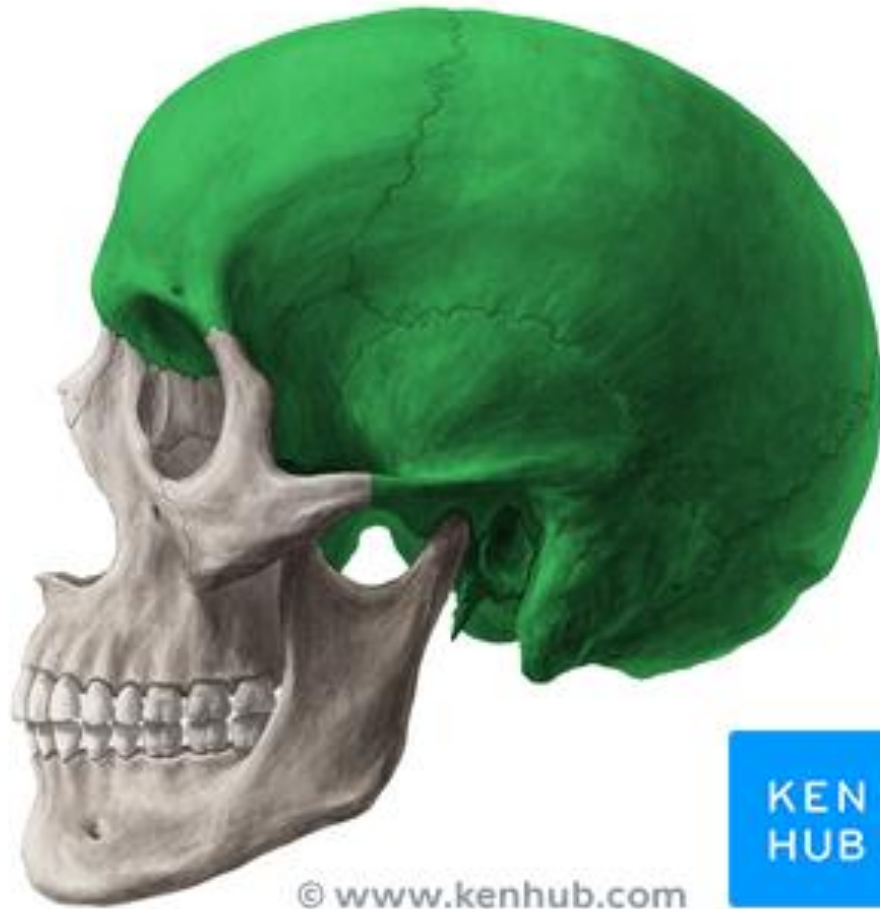Professor of Anatomy, Histology and Embryology

The Skull

- The skull is composed of several separate bones (22 bones) united **at immobile joints called sutures.**
 - The connective tissue between the bones is called a sutural ligament
- Only one moveable bone, the mandible which is united to the skull by the mobile Temporomandibular Joint



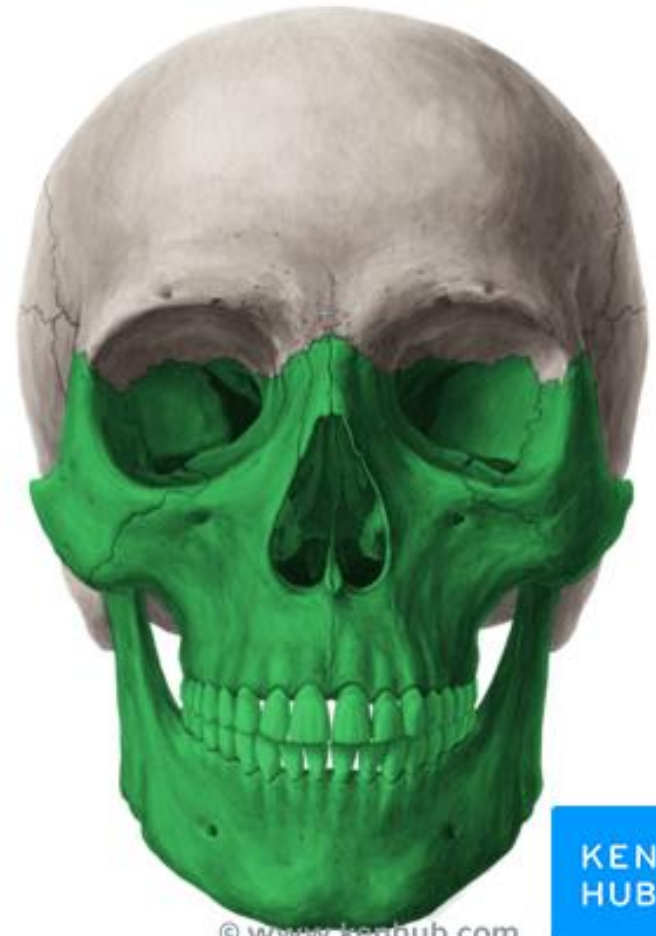Cranial bones



© www.kenhub.com

KEN
HUB

Facial bones



© www.kenhub.com

KEN
HUB

- The bones of the skull can be divided into
- 1- Cranial bones (Neurocranium)
 - 2- Facial bones (Viscerocranium)

The cranial bones

consists:

Frontal bone: 1

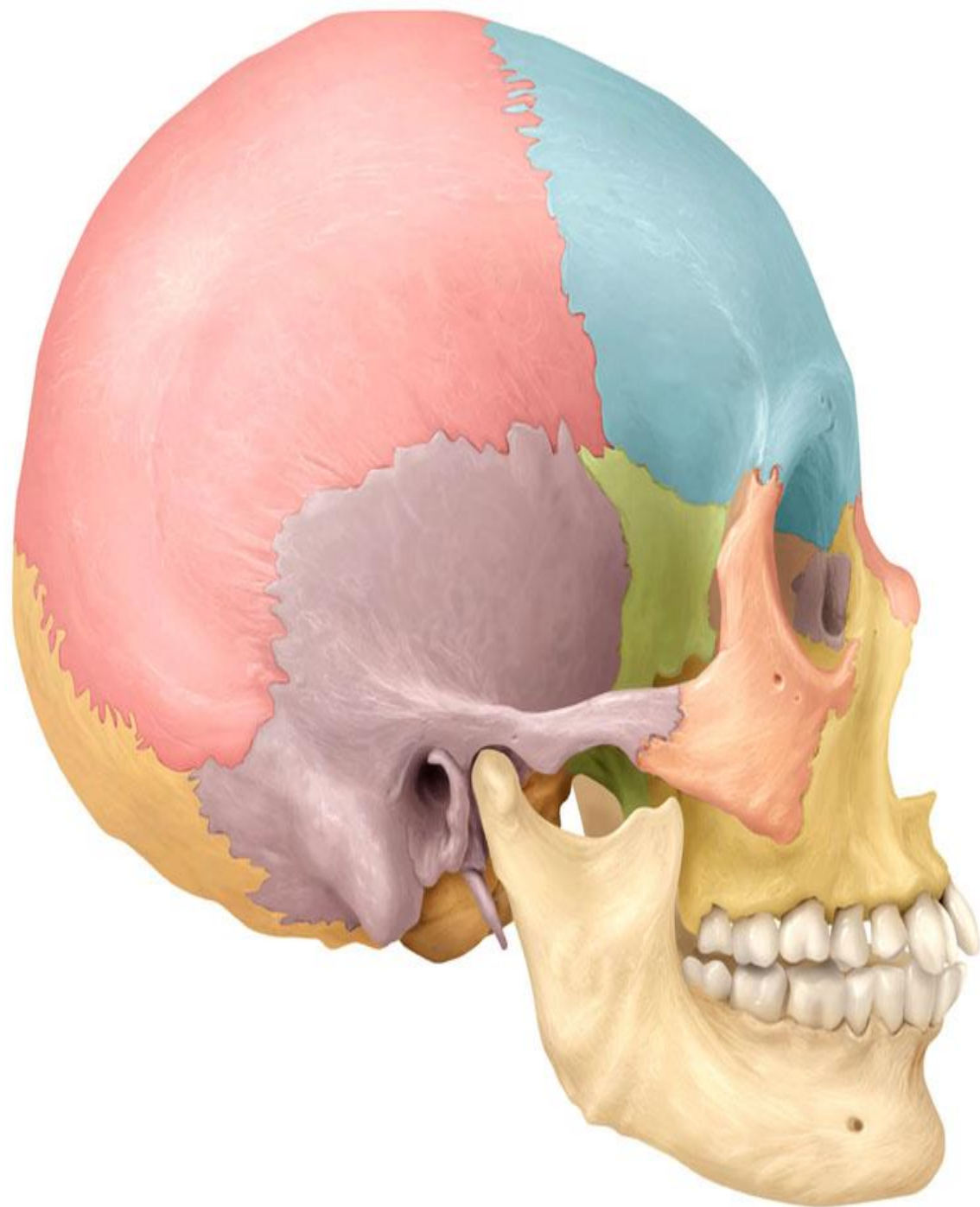
Parietal bones: 2

Occipital bone: 1

Temporal bones: 2

Sphenoid bone: 1

Ethmoid bone: 1



Two bones are paired

The **facial bones** consist of :

Zygomatic bones: 2

Maxillae: 2

Nasal bones: 2

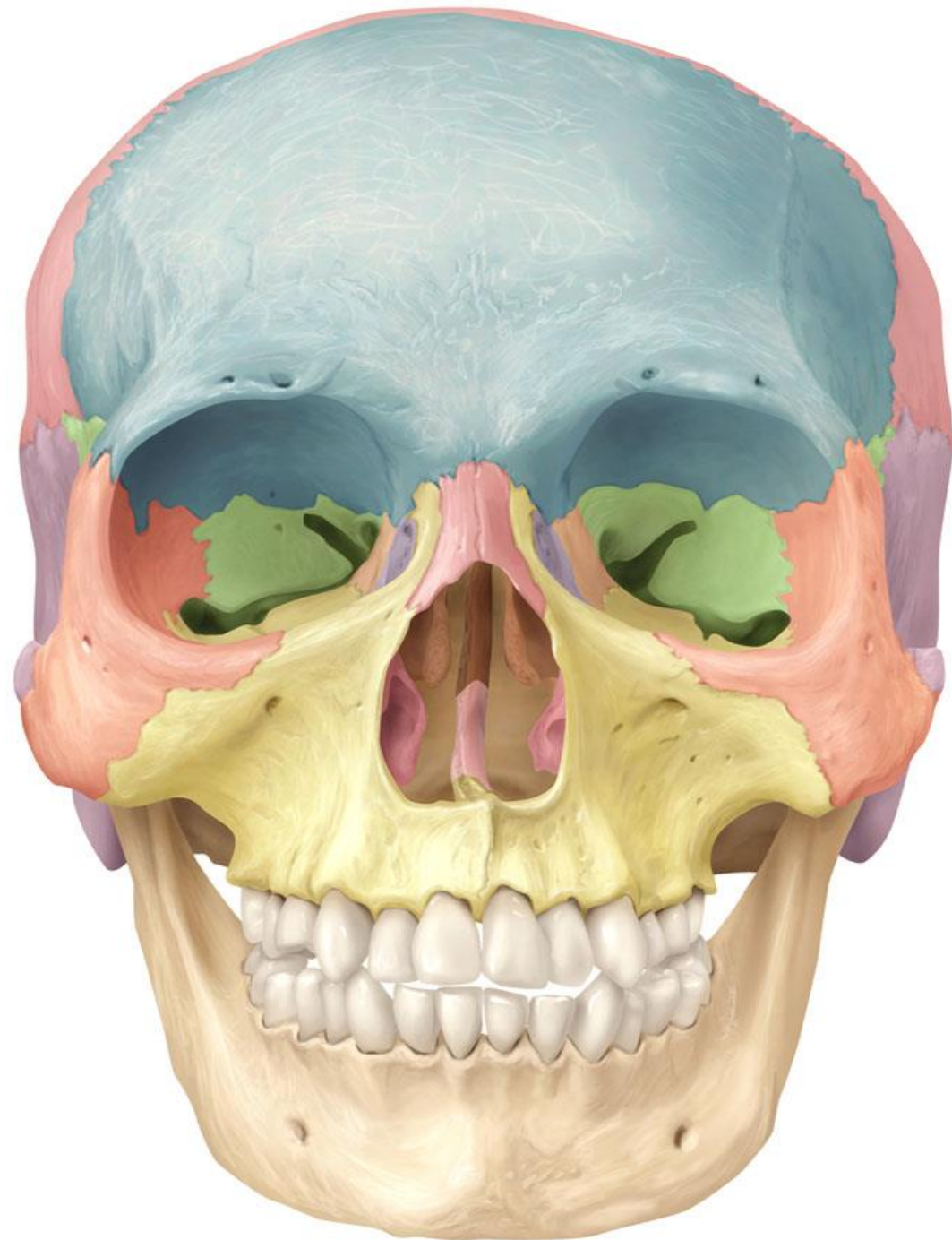
Lacrimal bones: 2

Vomer: 1

Palatine bones: 2

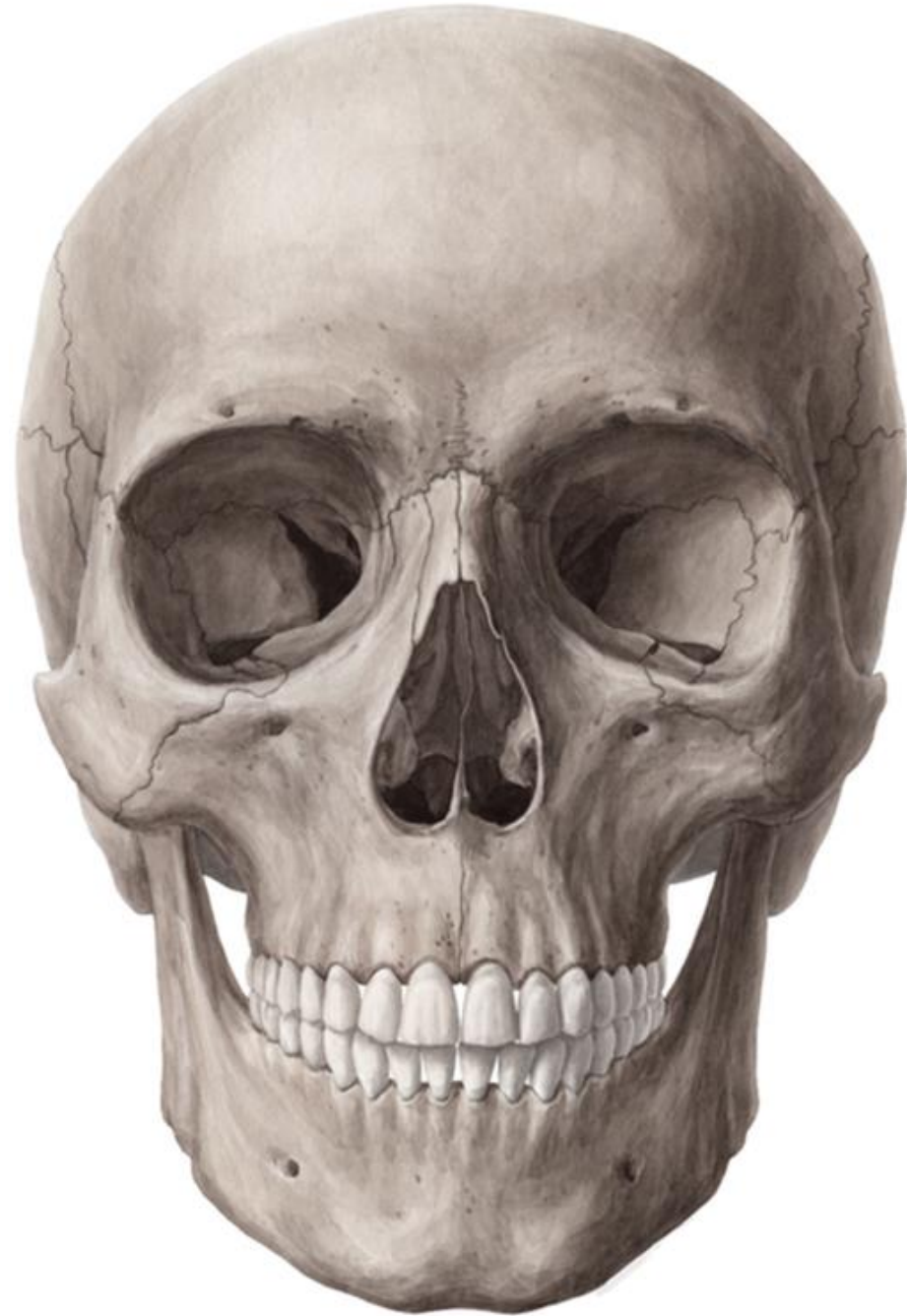Inferior conchae: 2

Mandible: 1



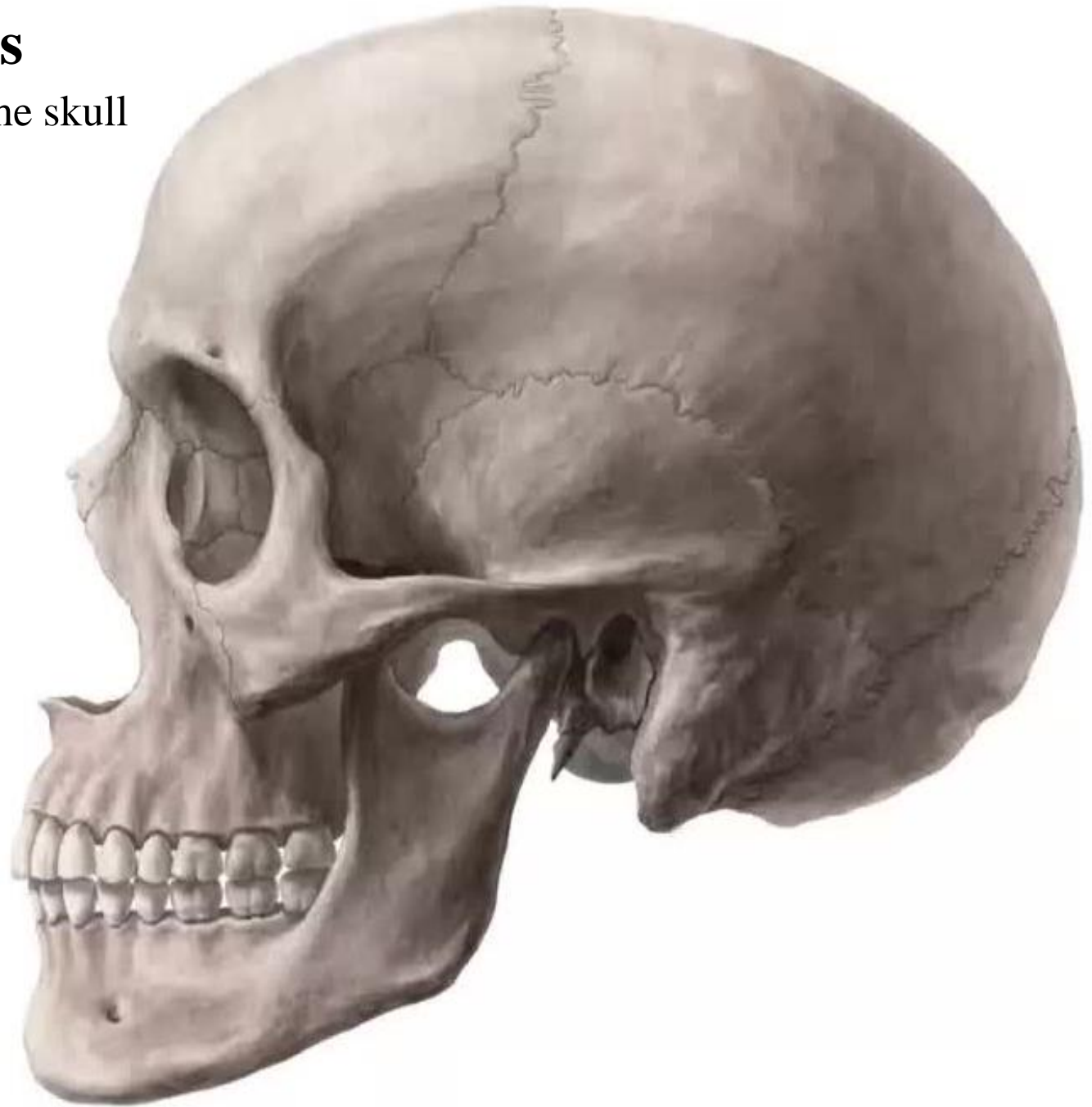
Norma frontalis

It is the anterior view of the skull



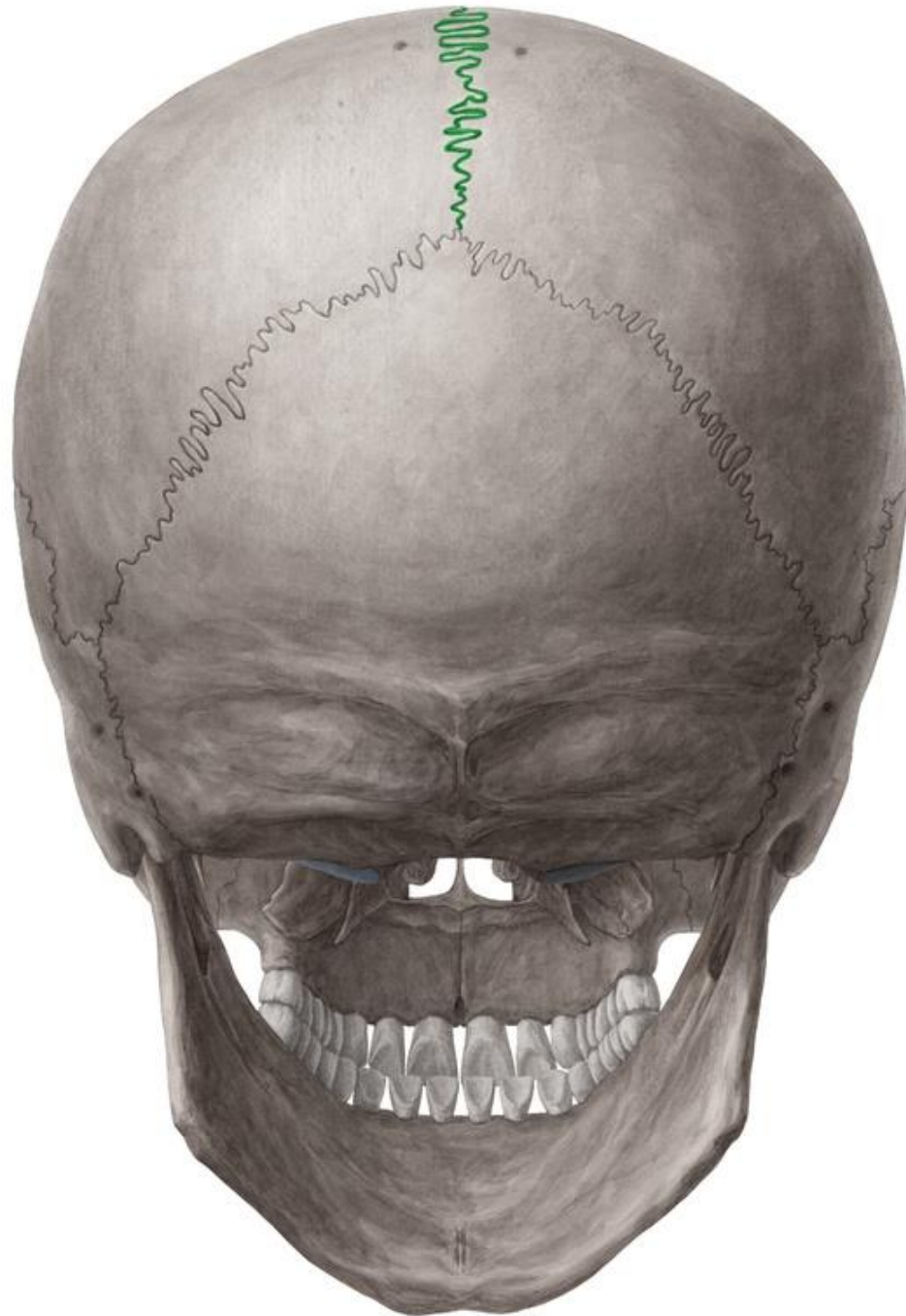
Norma lateralis

It is the lateral view of the skull



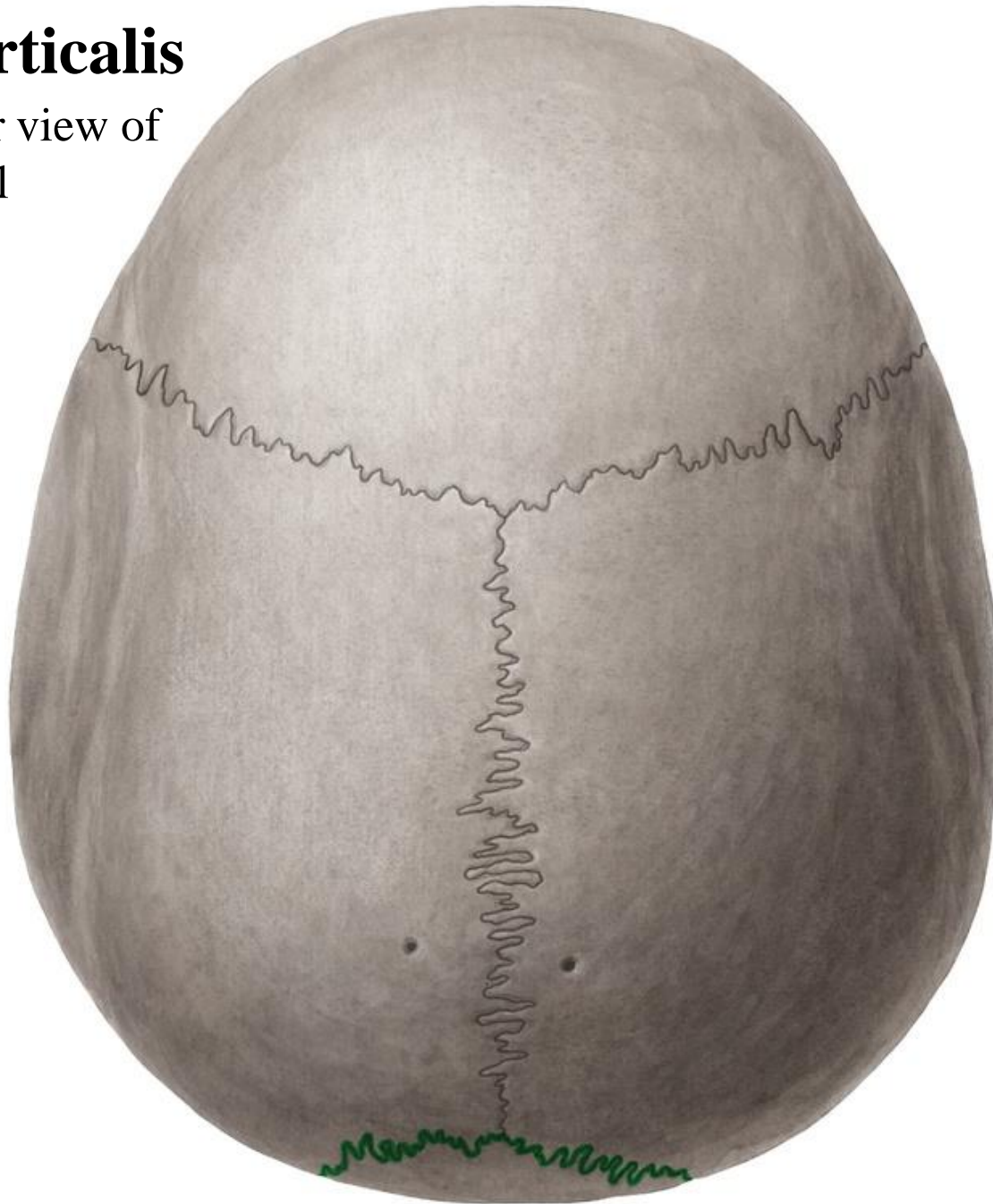
Norma occipitalis

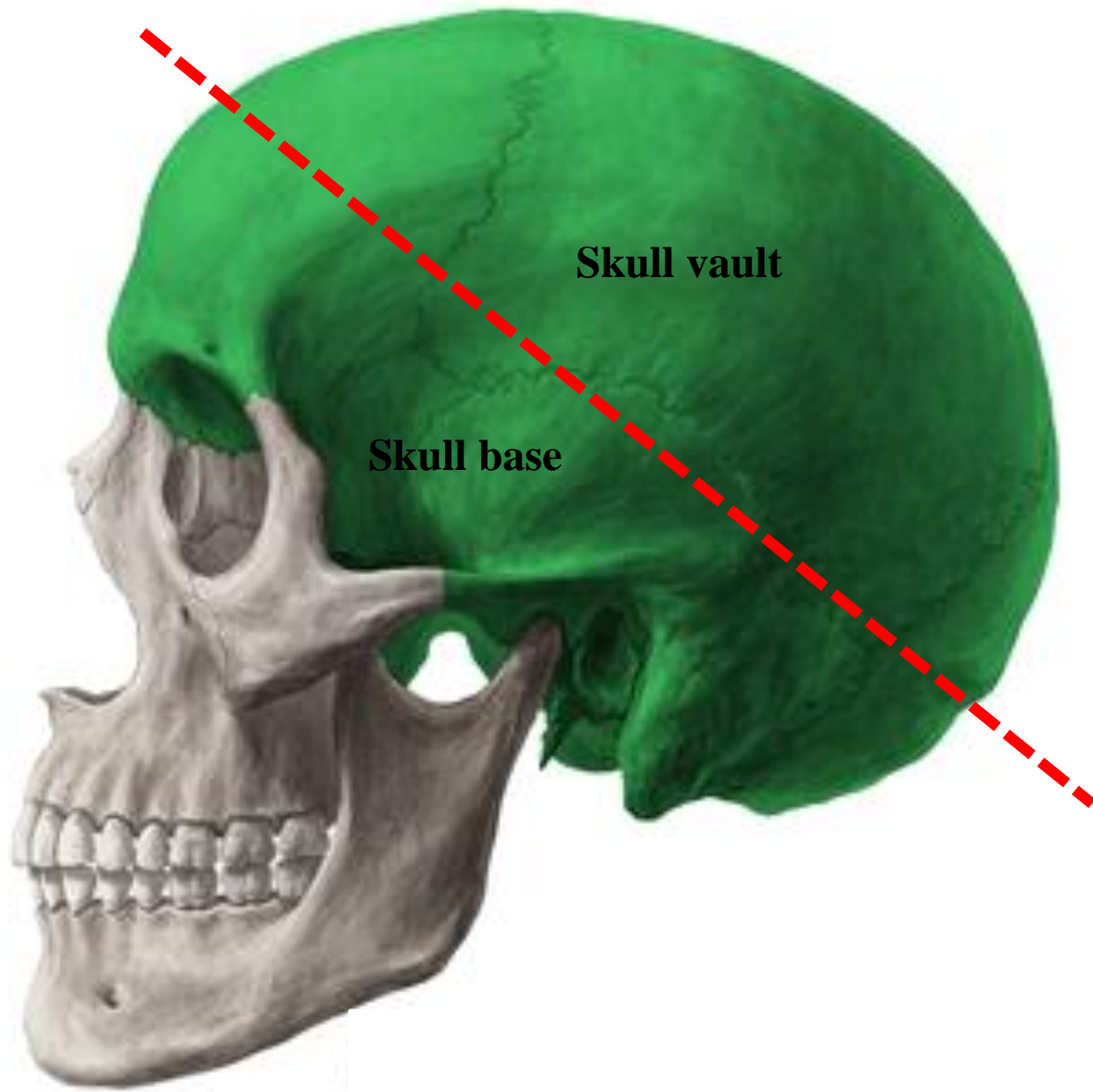
It is the posterior view of the skull



Norma verticalis

It is the superior view of the skull



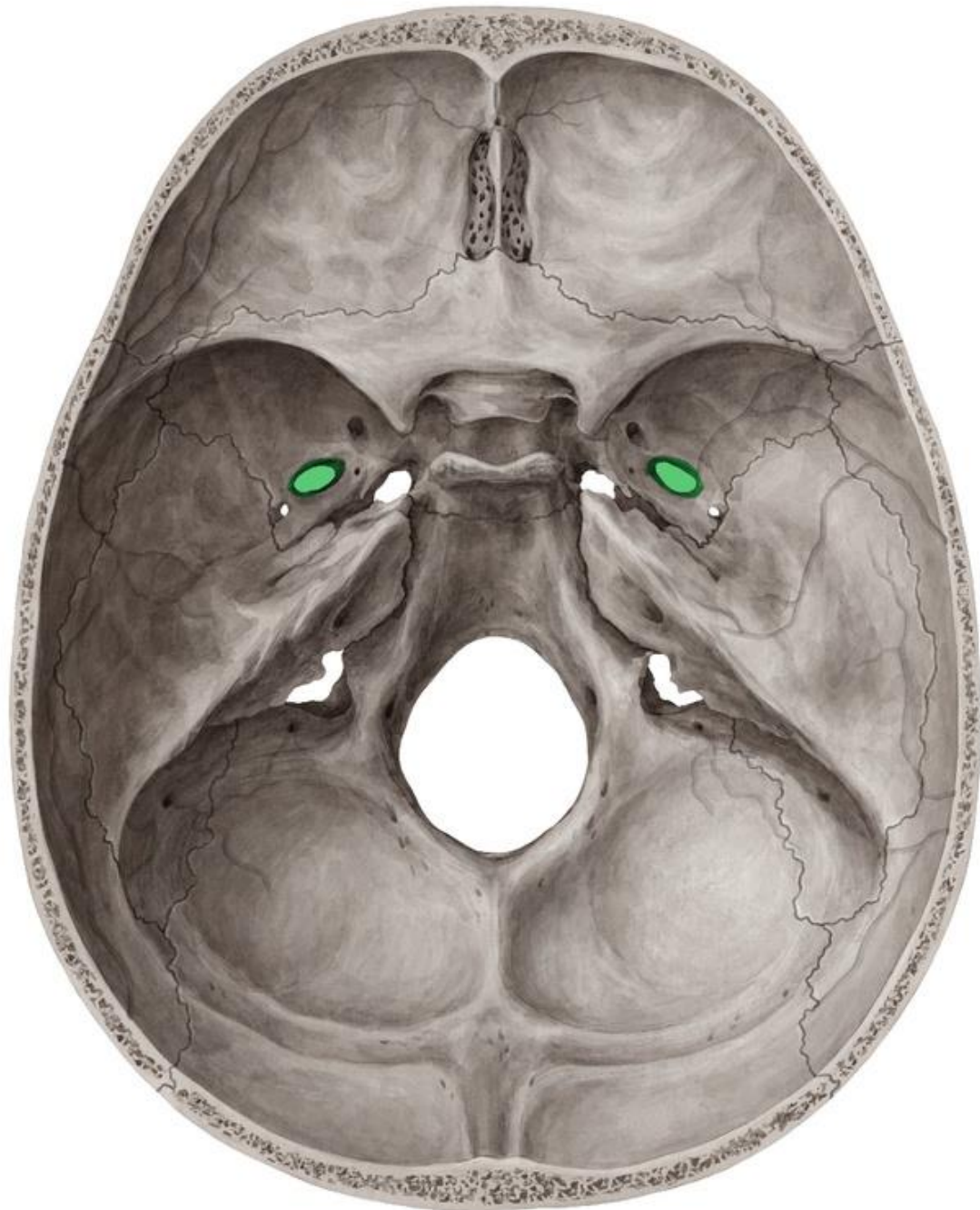


Skull vault

Skull base

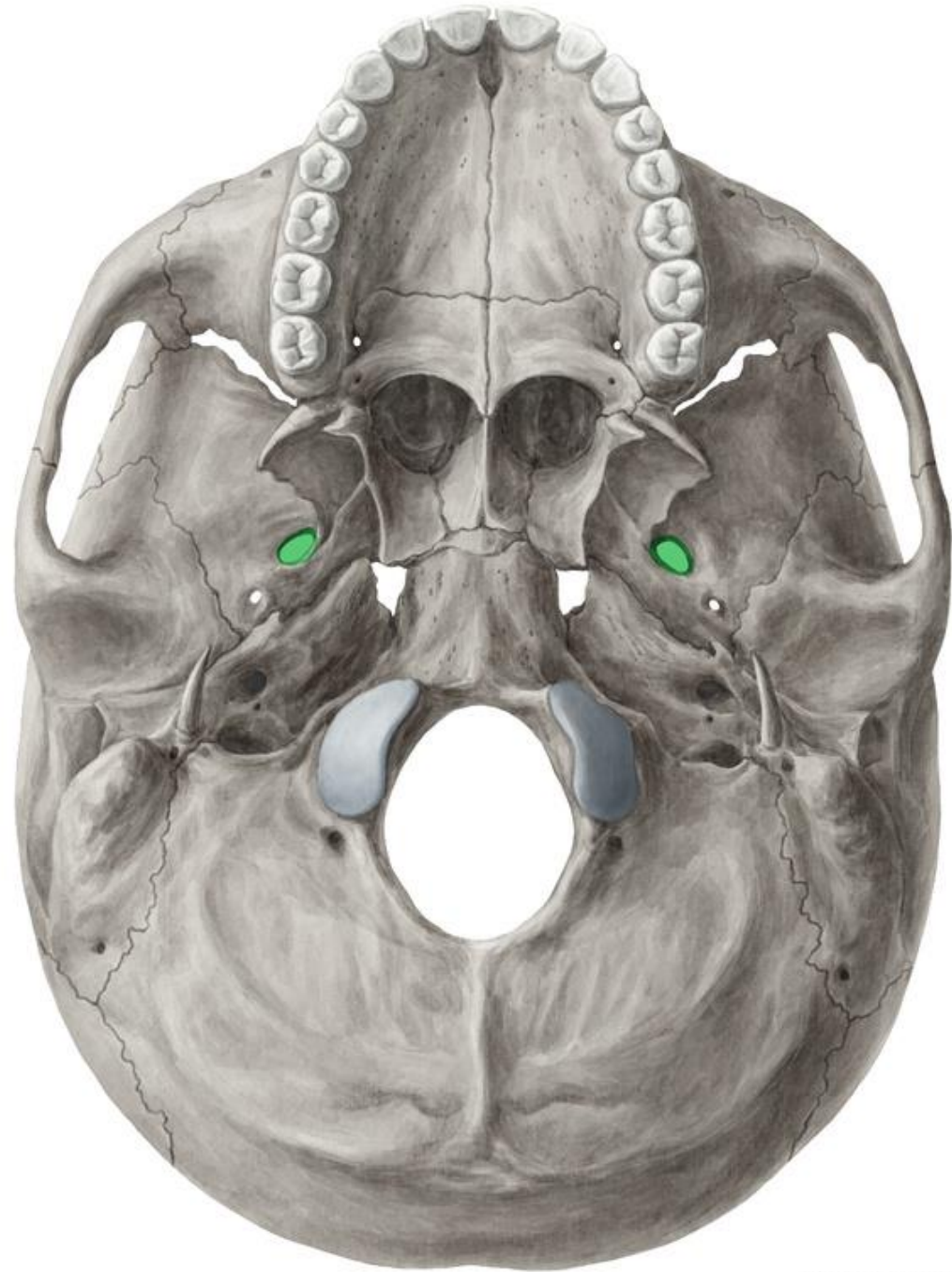
Norma basalis interna

Base of the skull- Superior view



Norma basalis externa

Base of the skull- Inferior view

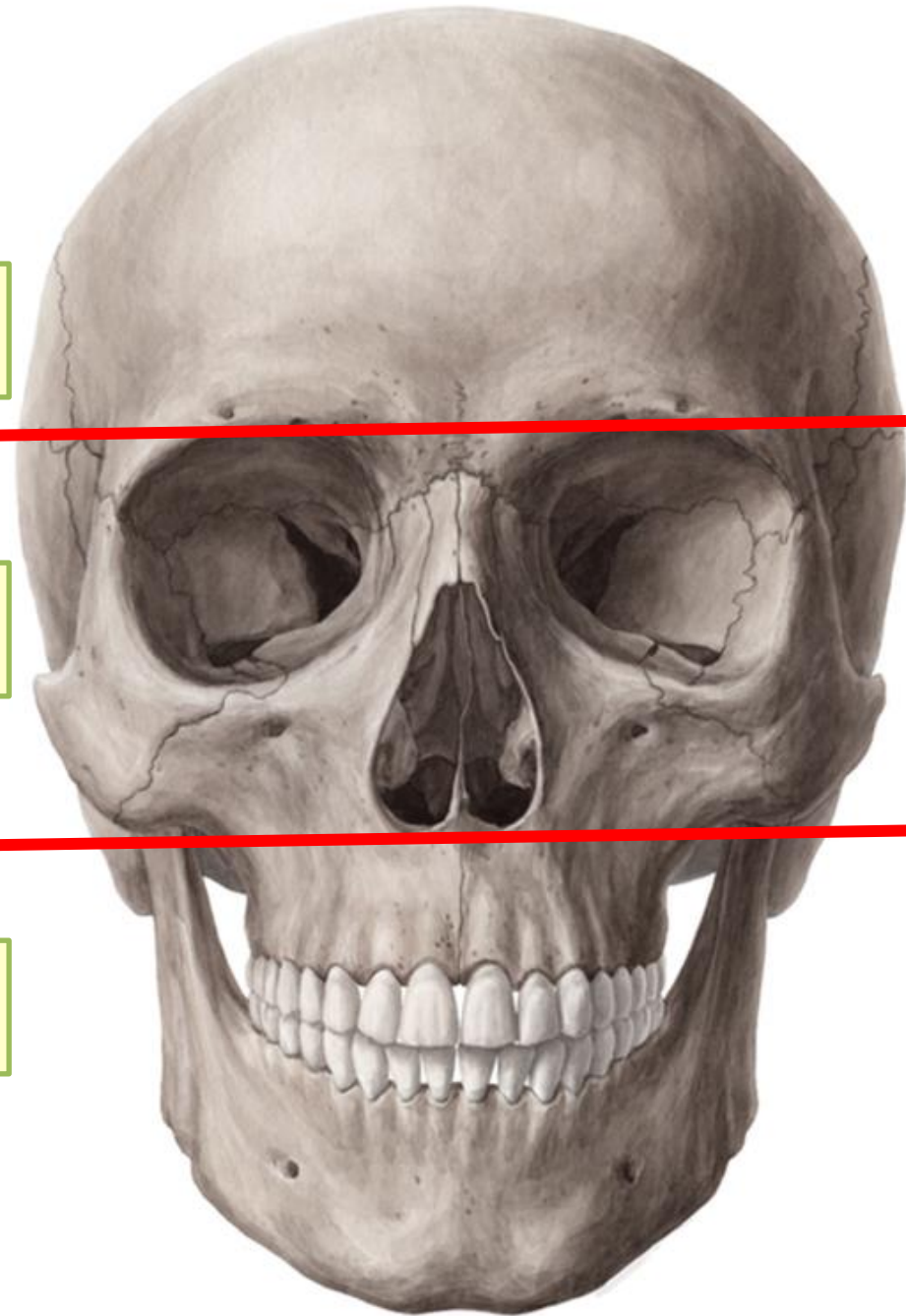


Norma Frontalis

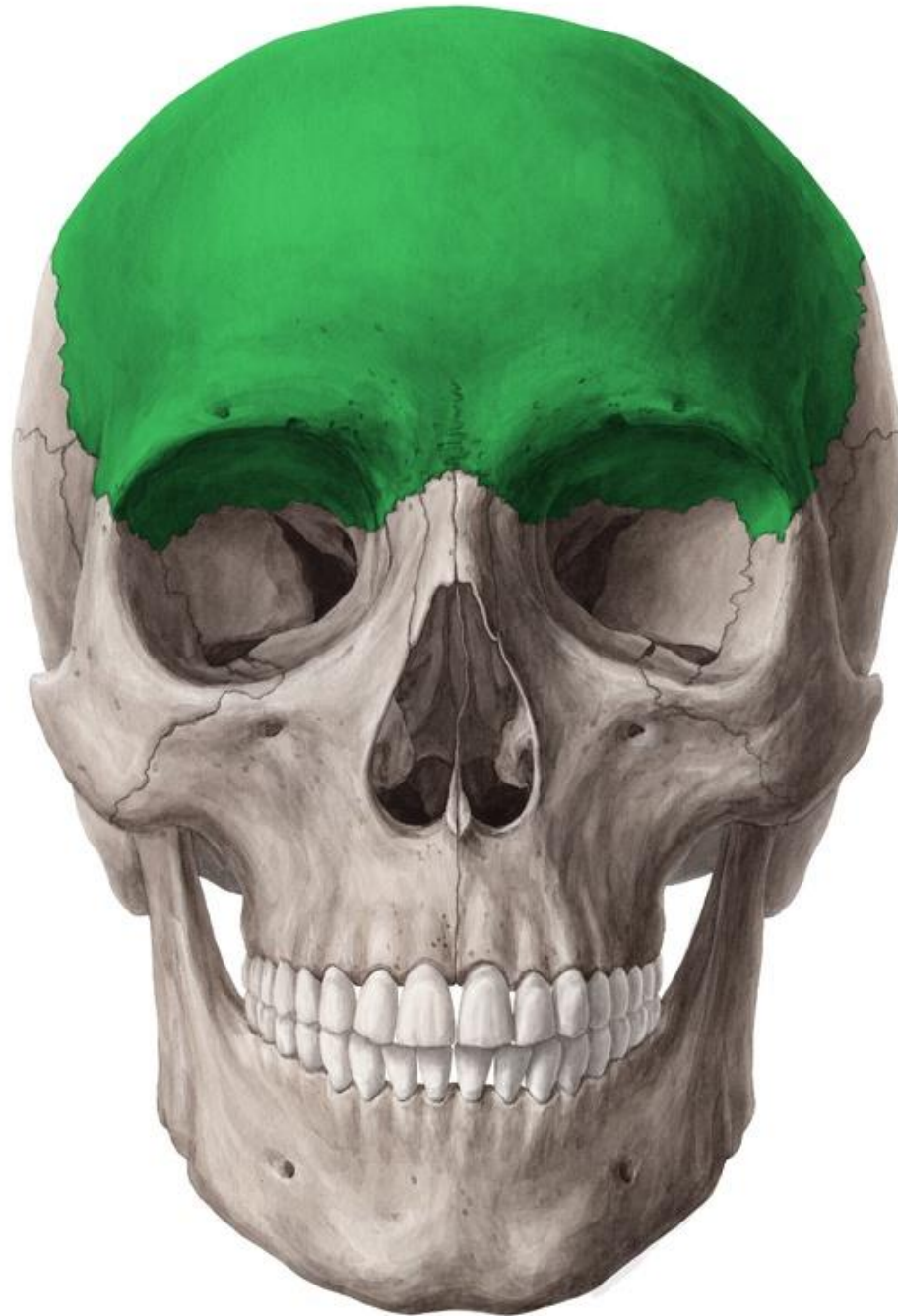Upper part: Forehead; made of the frontal bone

Middle part: contains 3 cavities; 2 orbital & 1 nasal

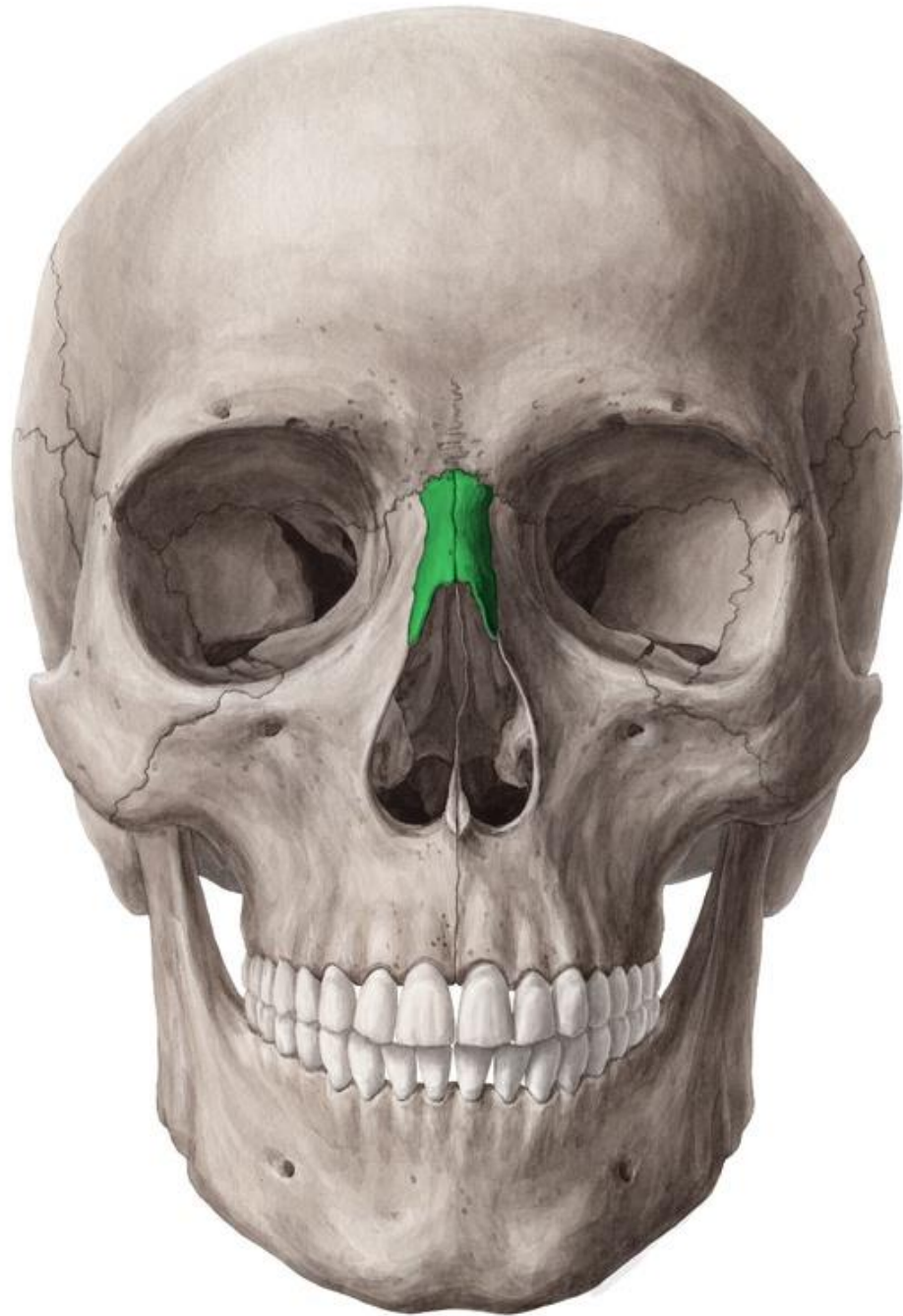Lower part: formed by the upper & lower jaws



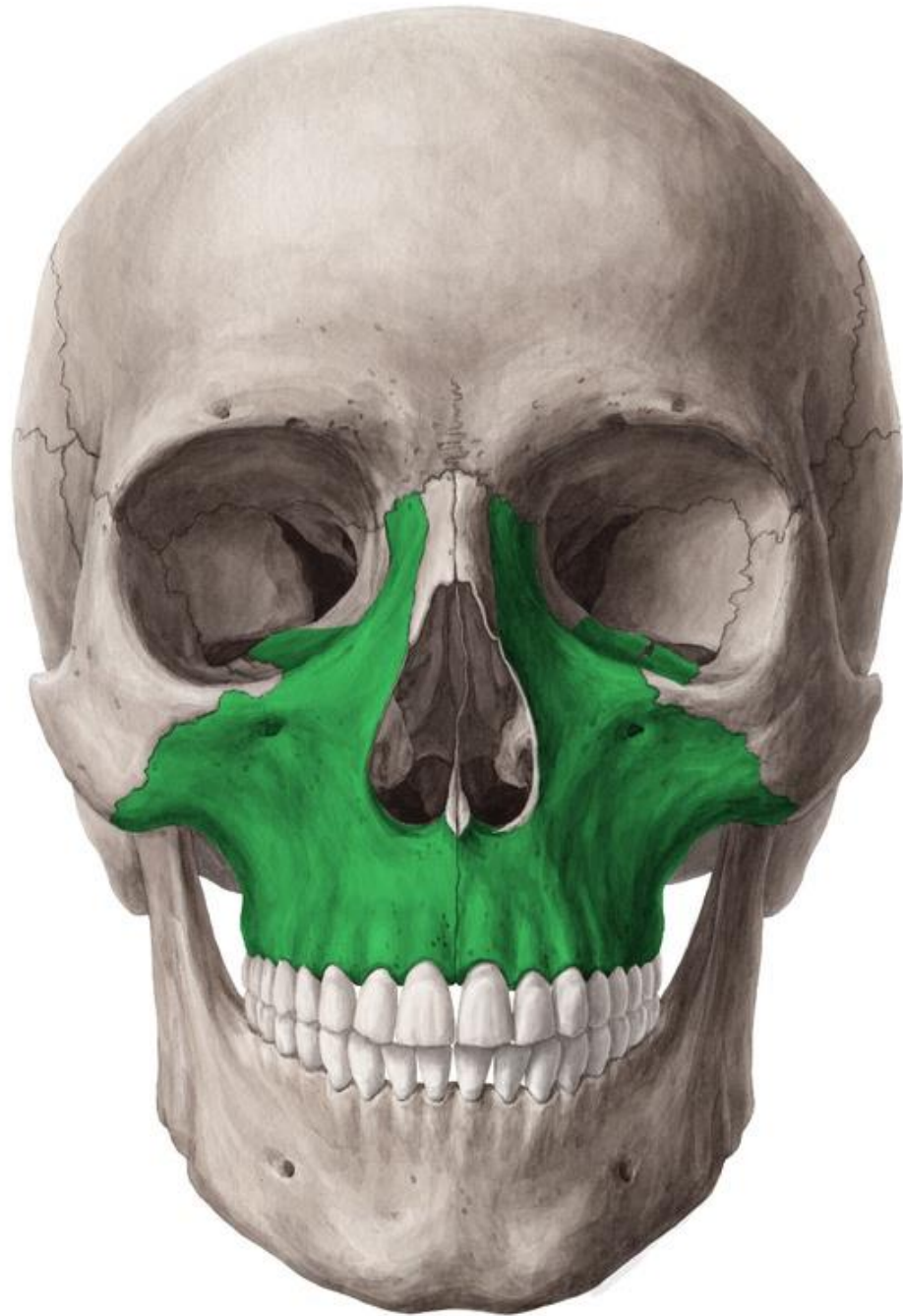Frontal bone



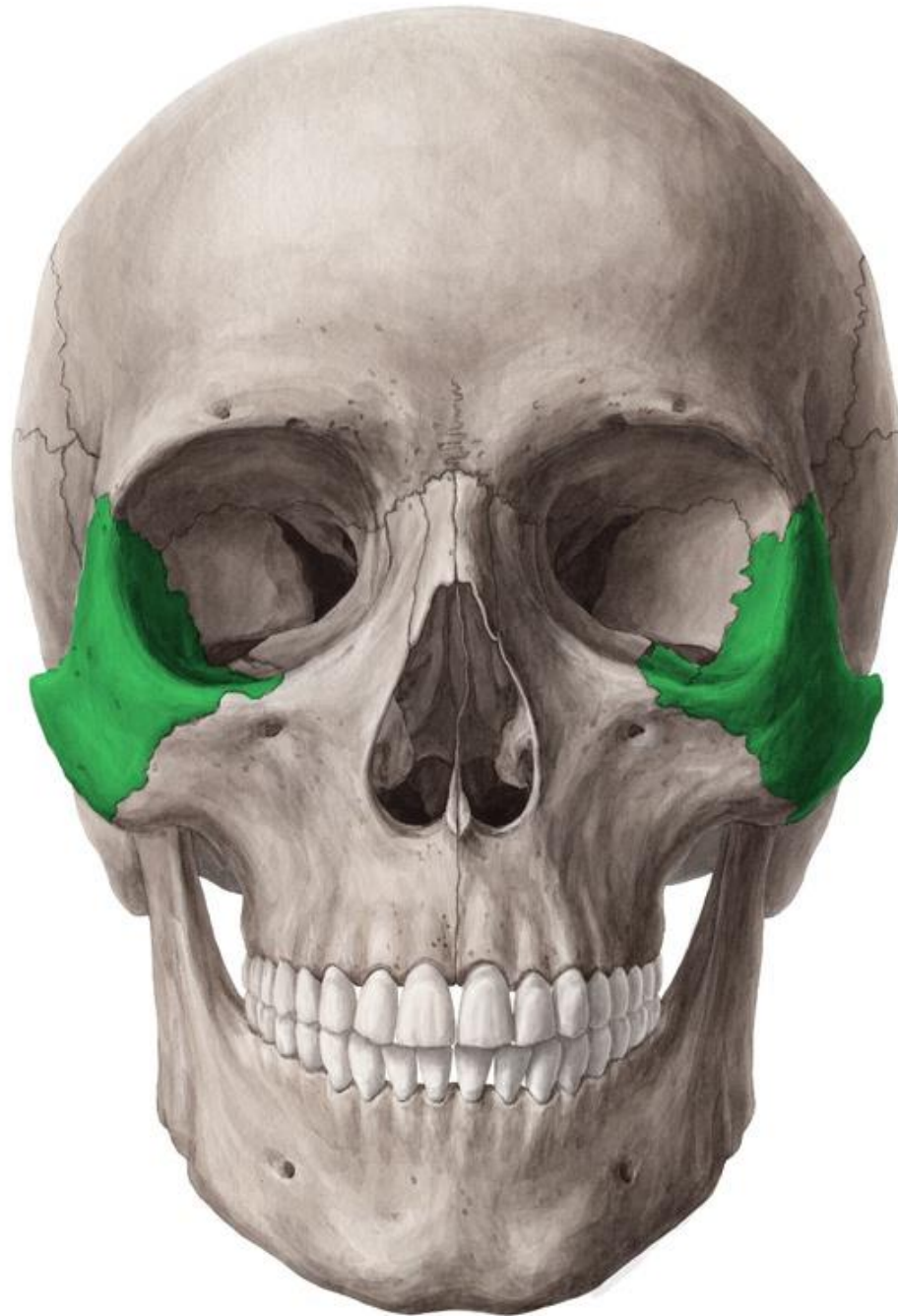Nasal bone



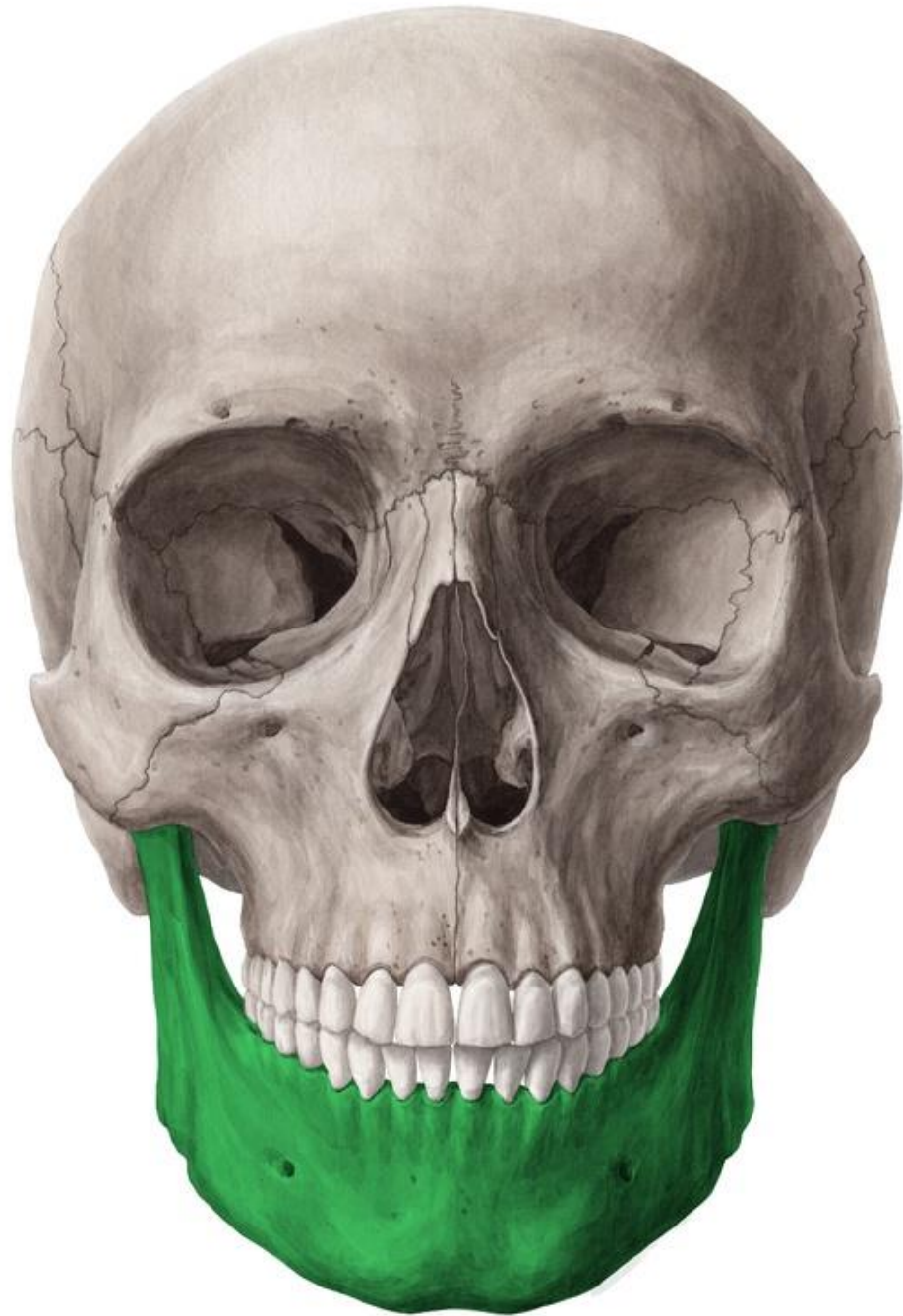Maxilla



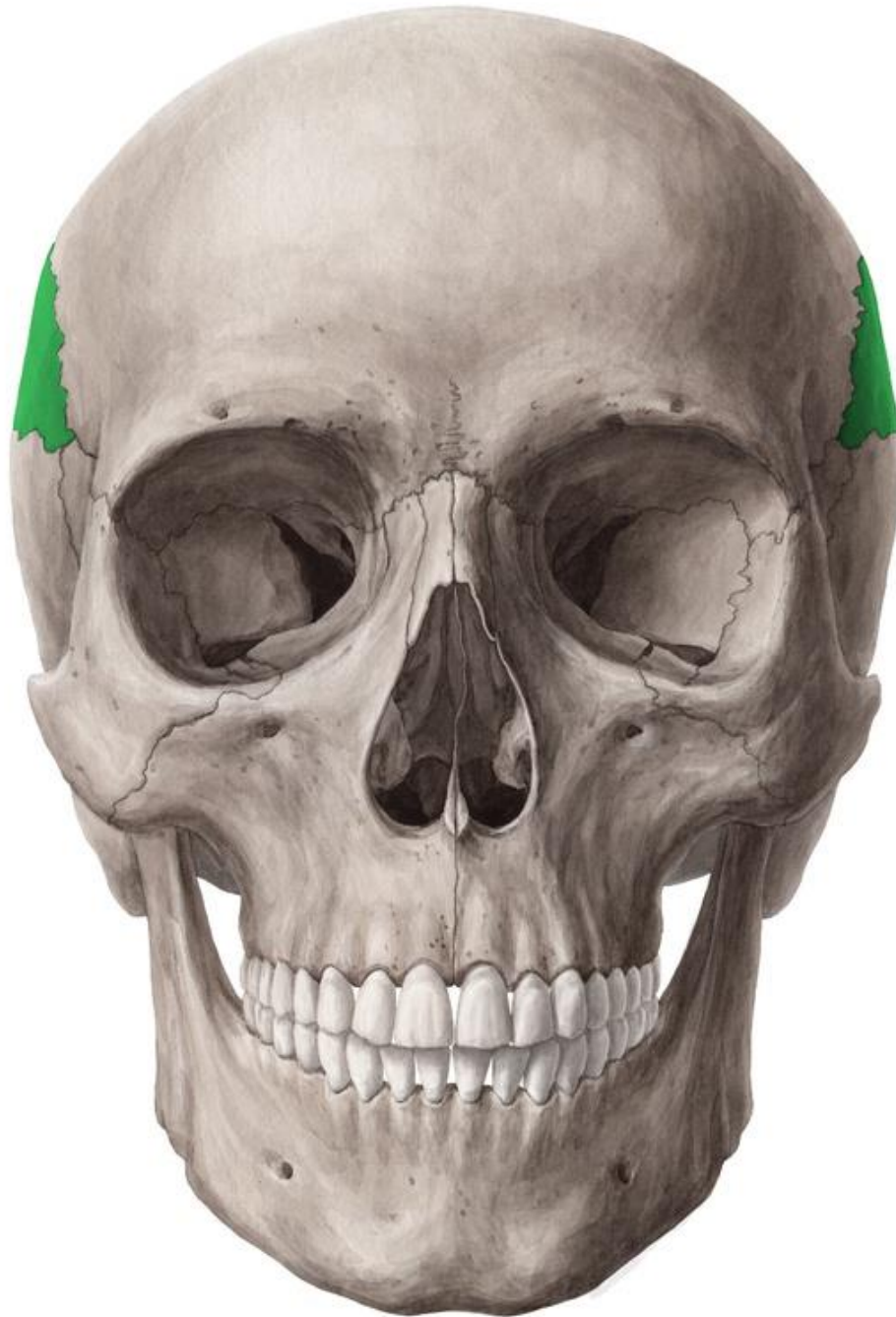Zygomatic bone (cheek bone)



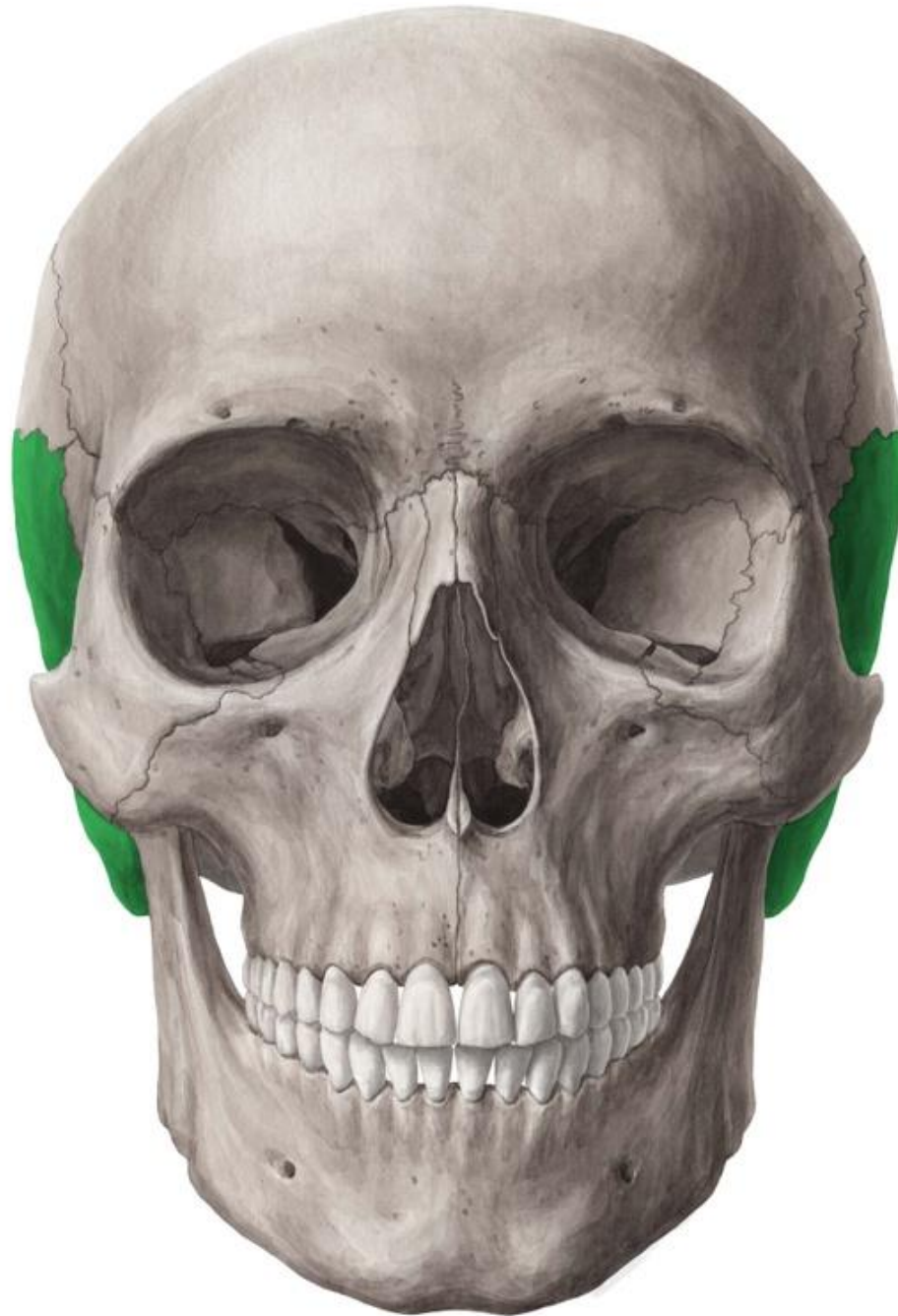
Mandible



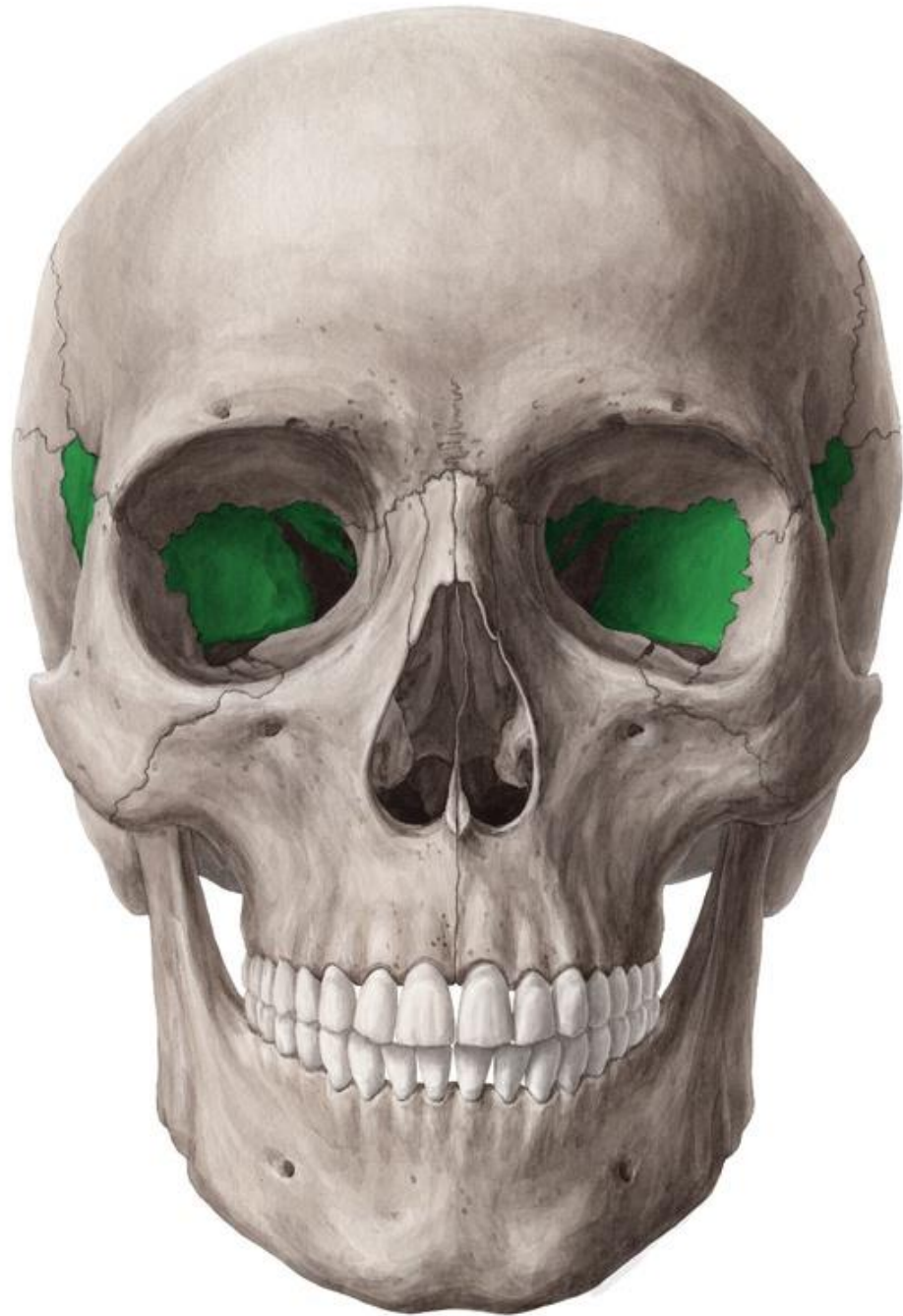Parietal bone



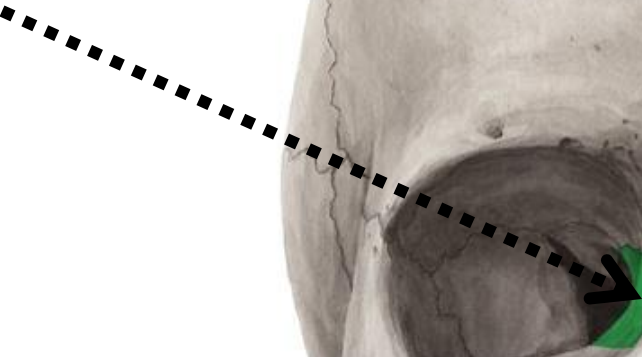
Temporal bone



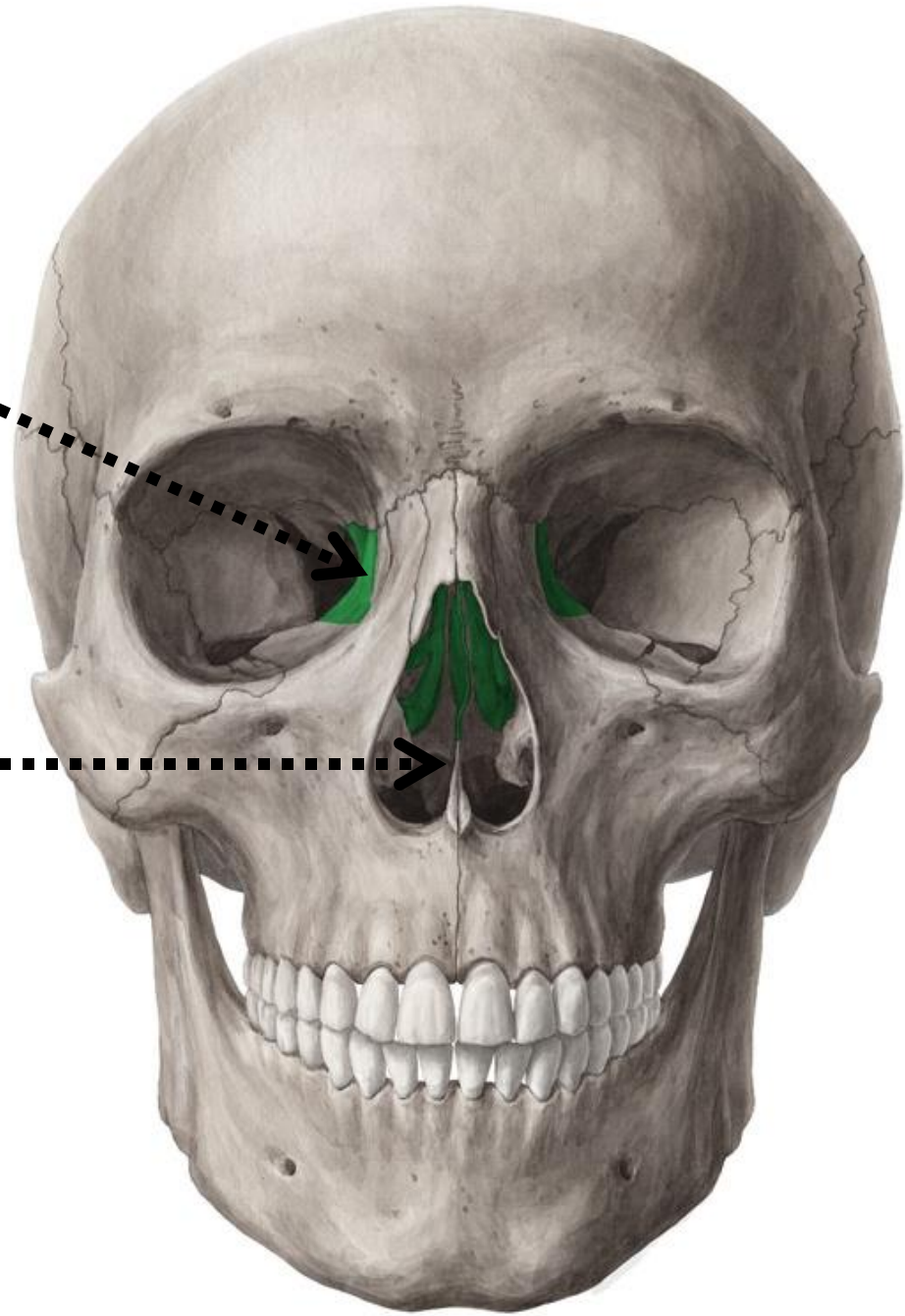
Sphenoid



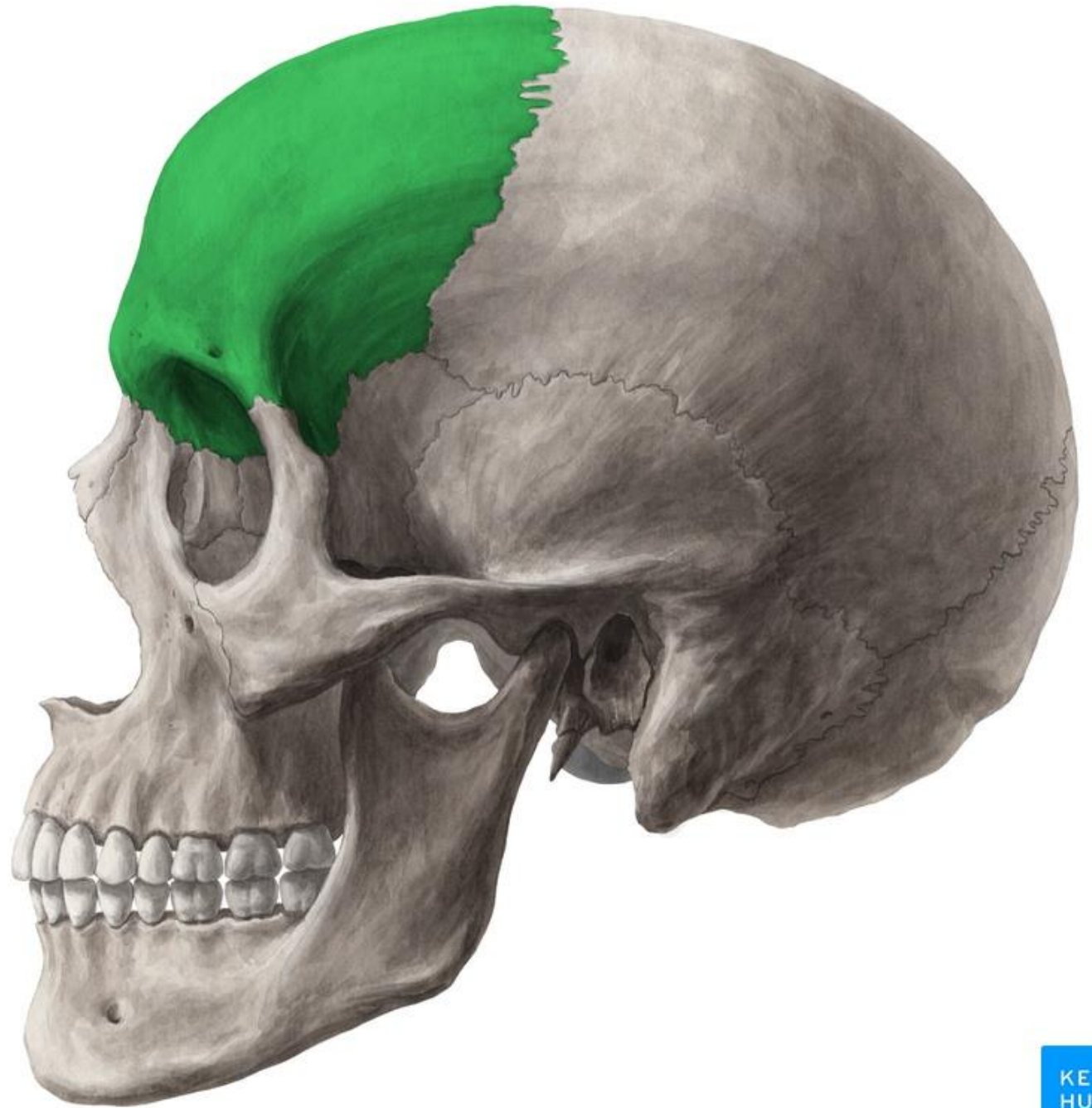Ethmoid



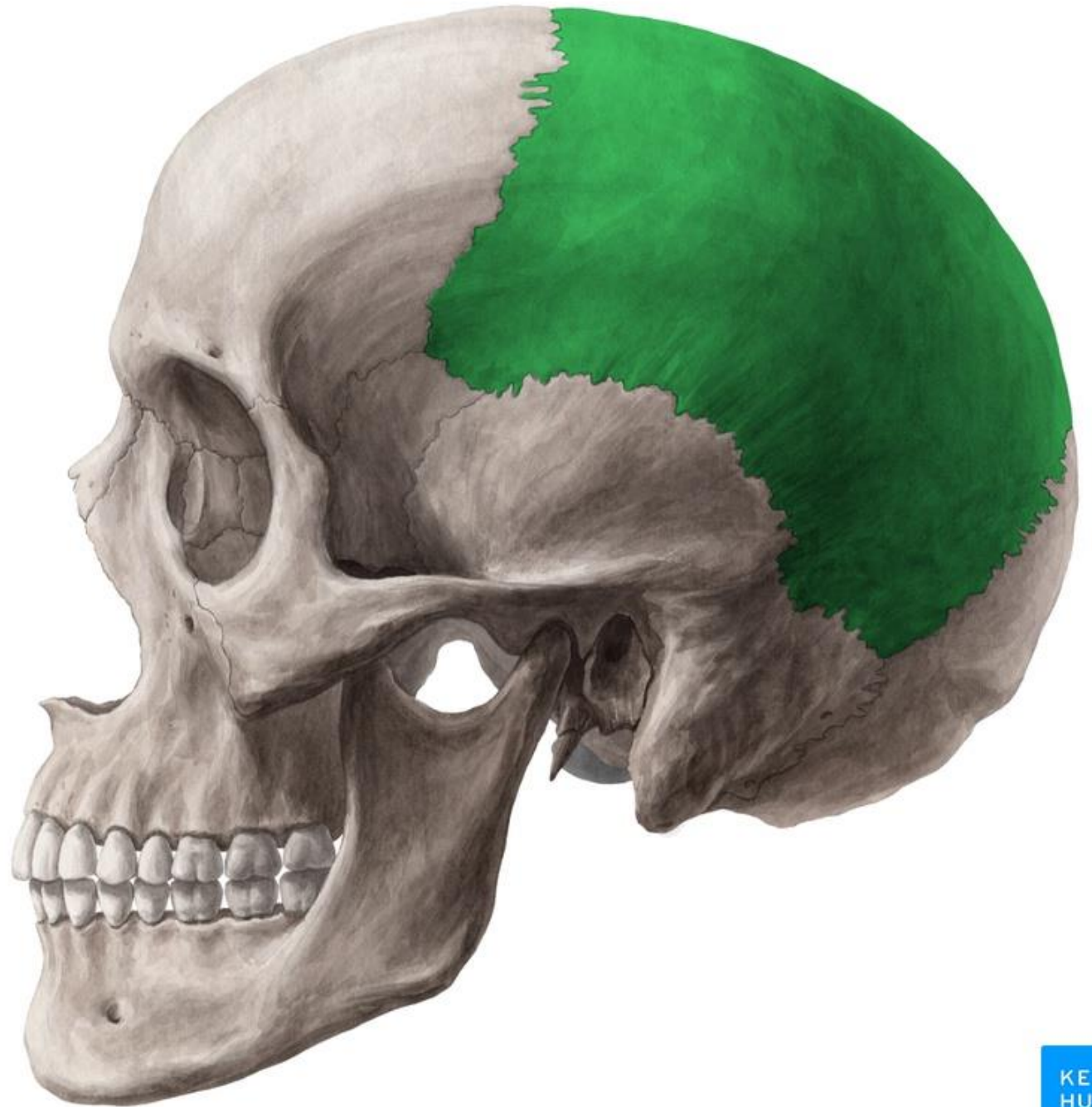Vomer bone



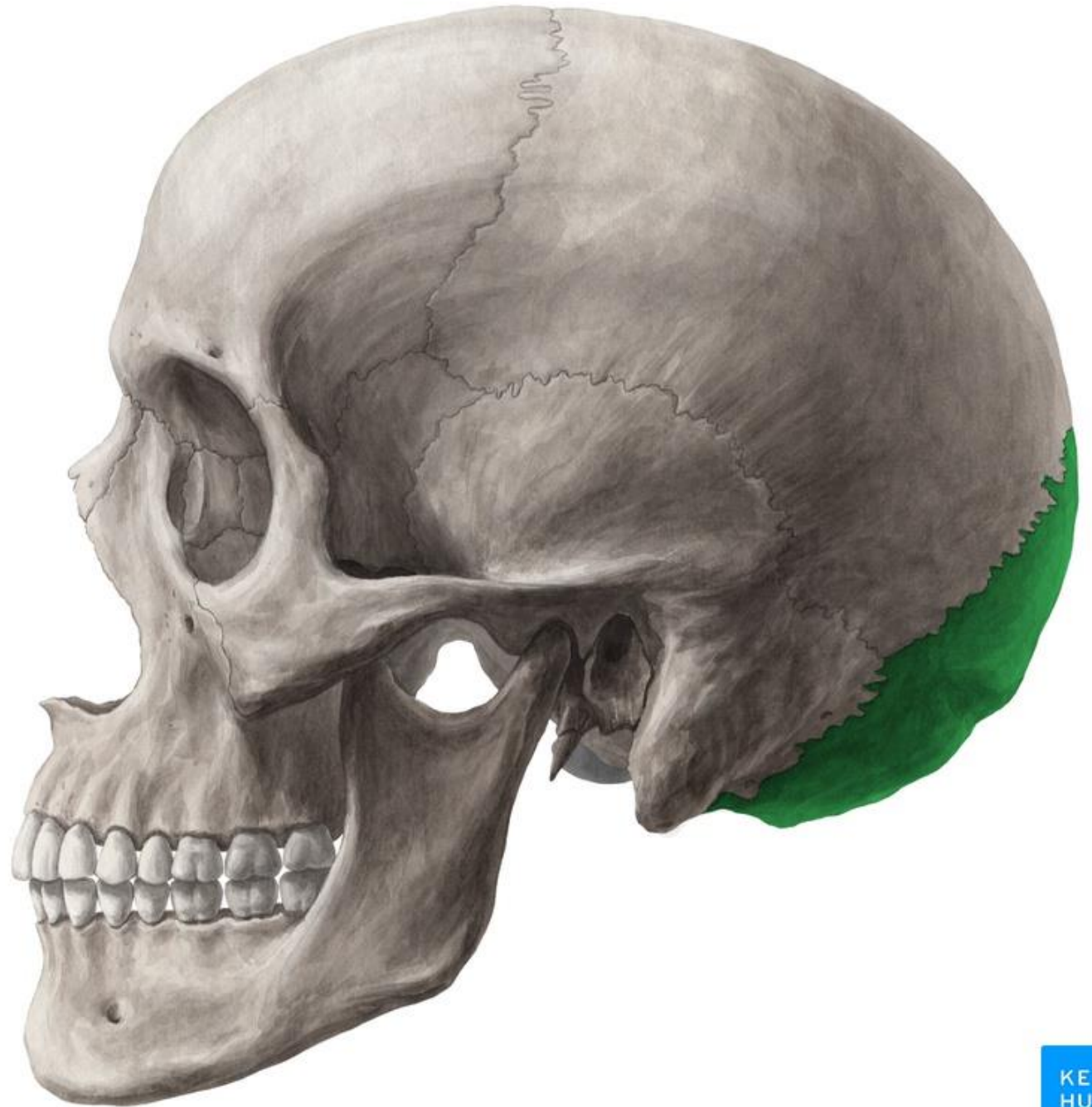Frontal bone



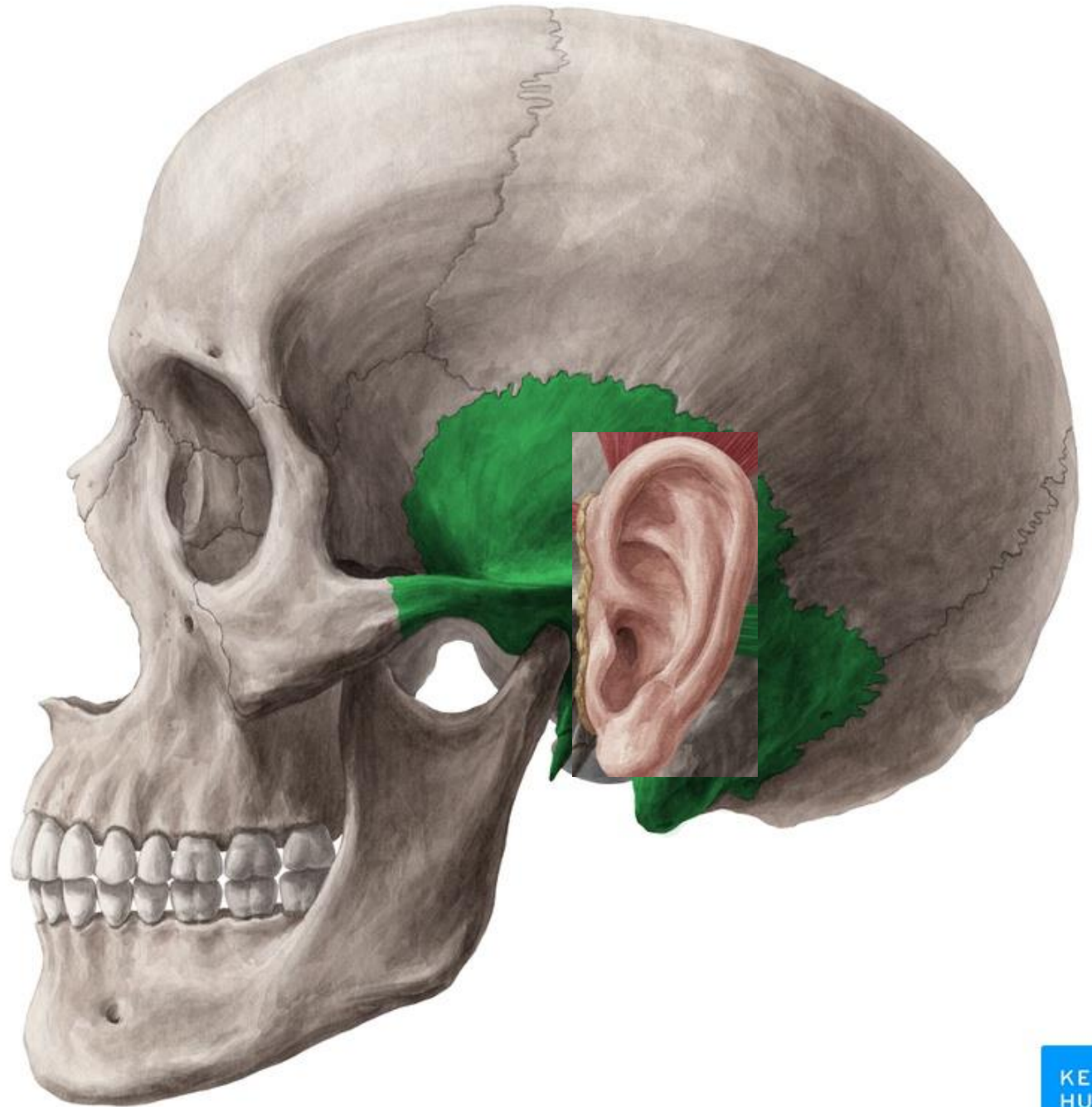
Parietal bone



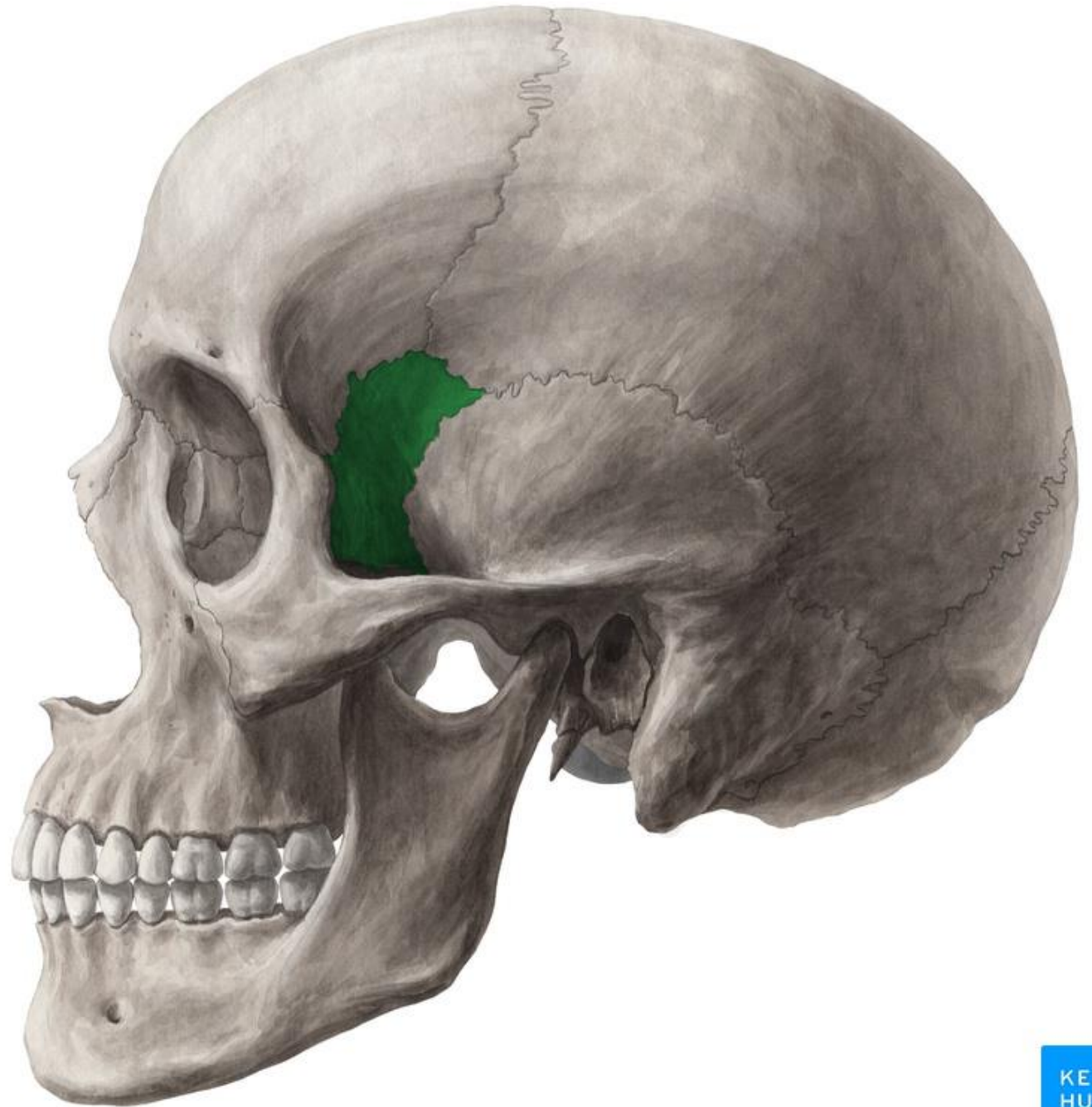
Occipital bone



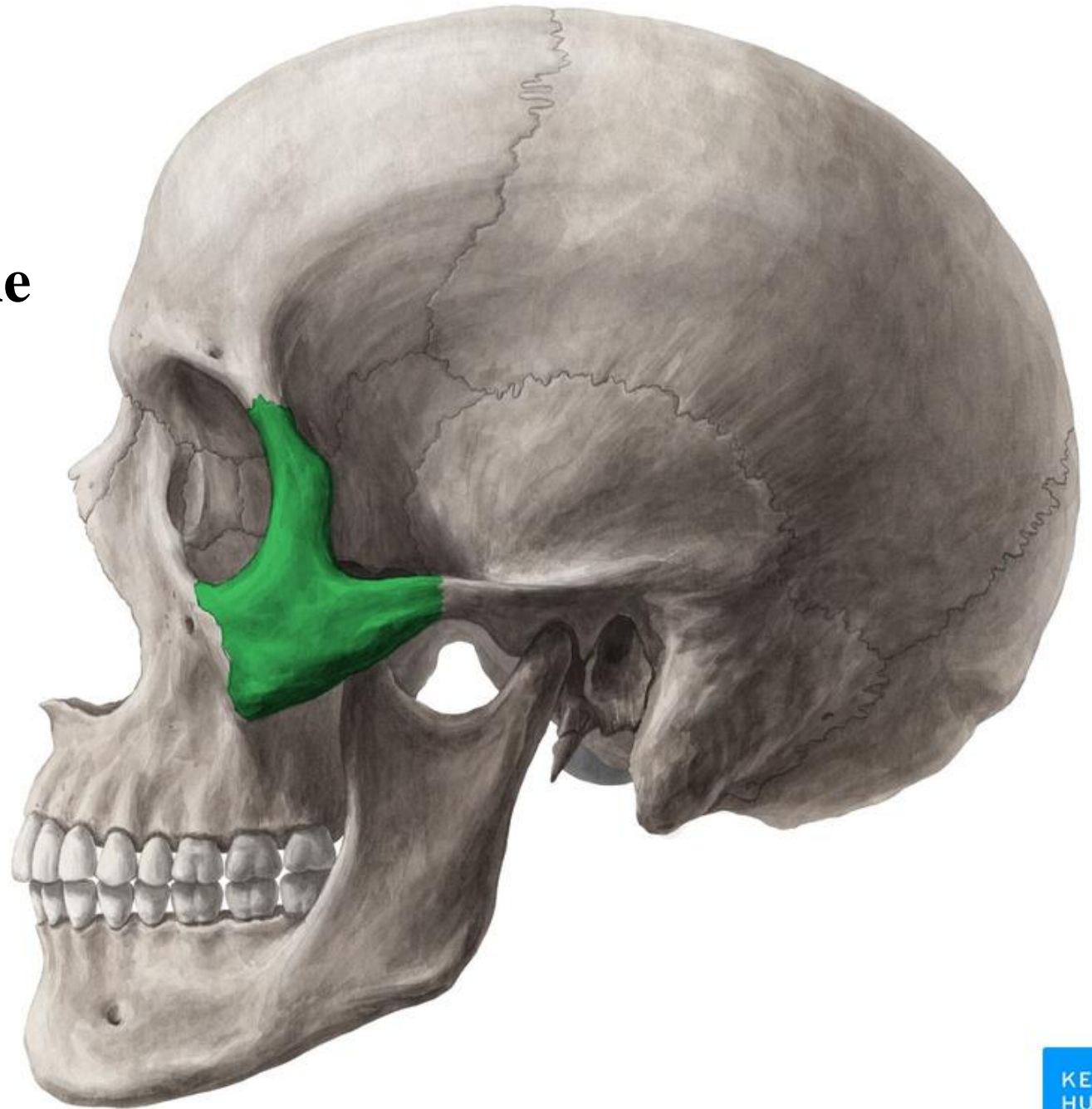
Temporal bone



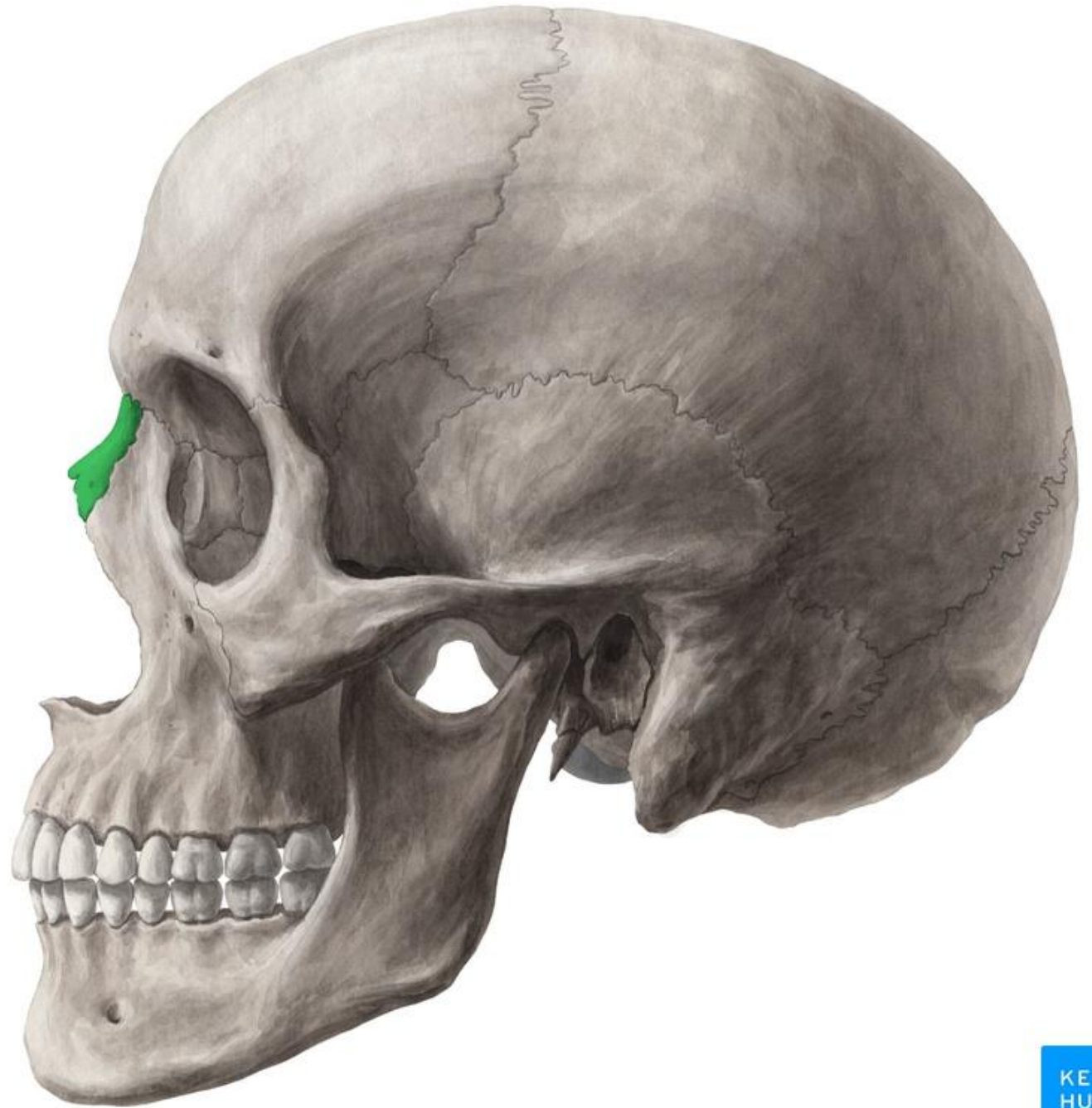
Sphenoid (Greater wing)



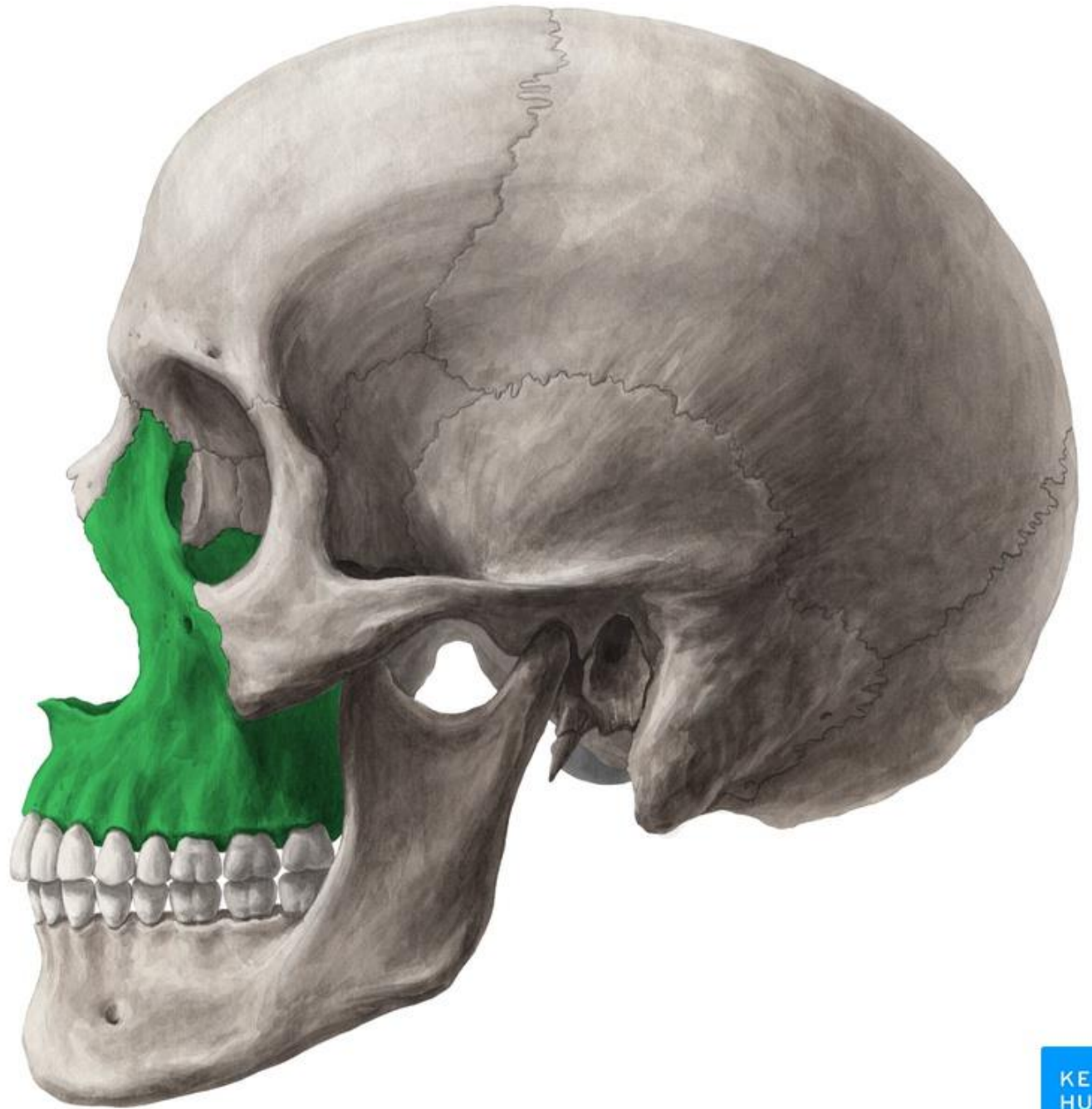
Zygomatic bone



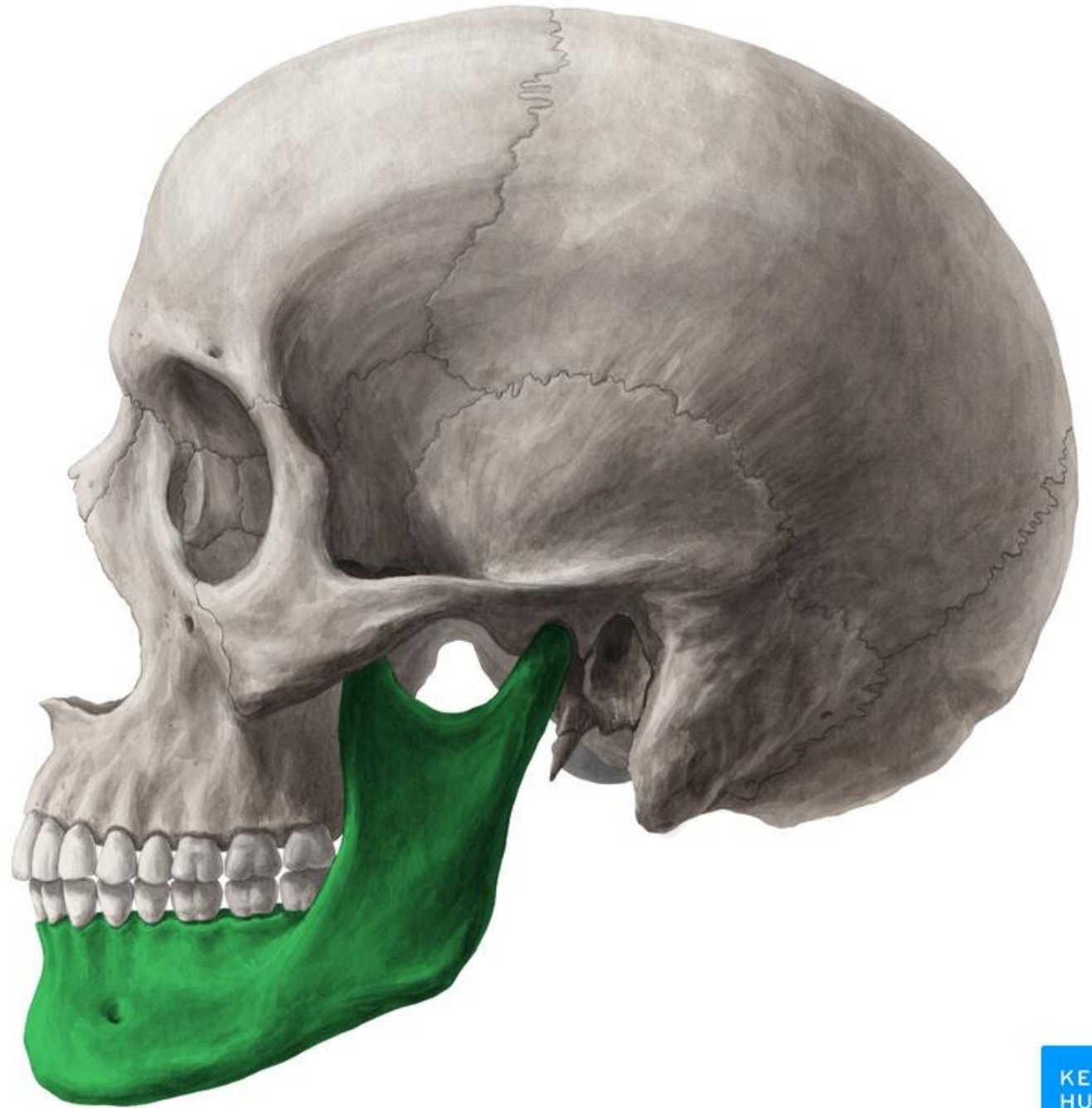Nasal bone



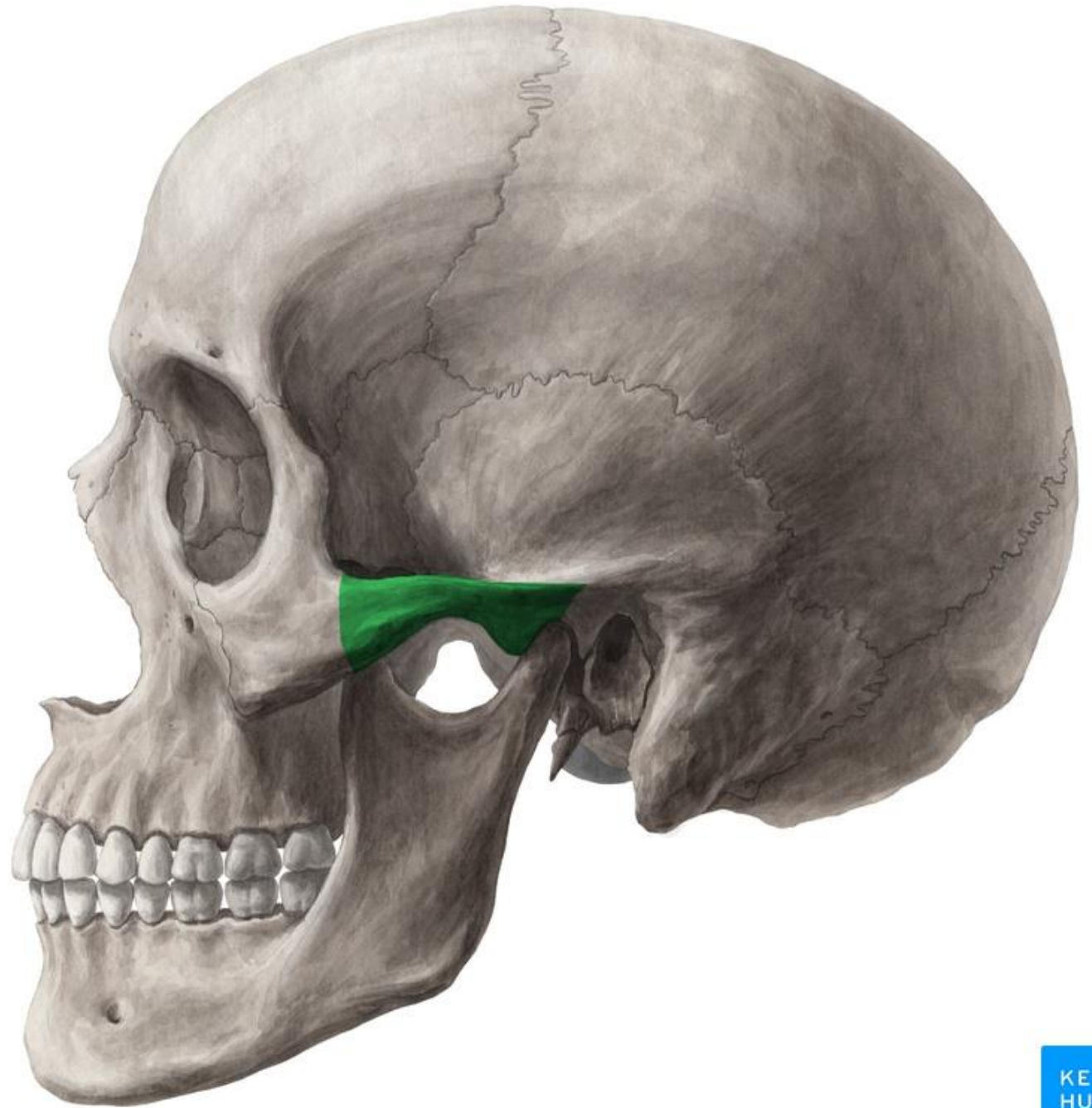
Maxilla



Mandible



Zygomatic arch



Norma Verticalis

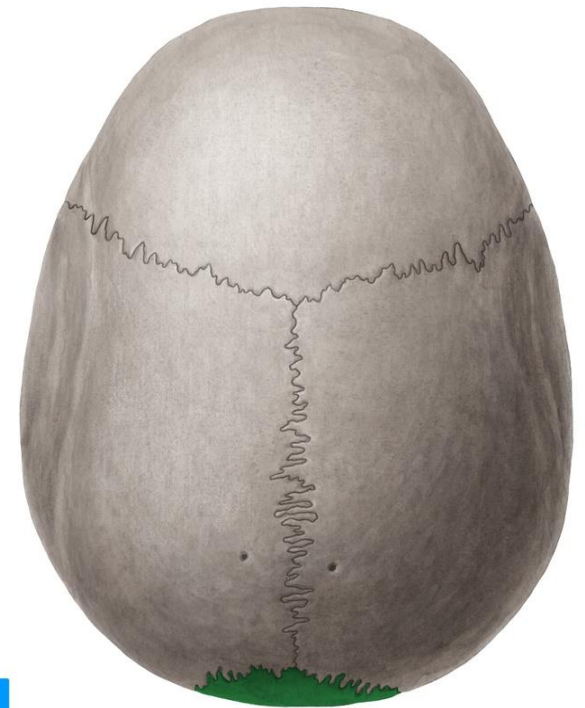
It is the superior view of the cranium



© www.kenhub.com



© www.kenhub.com

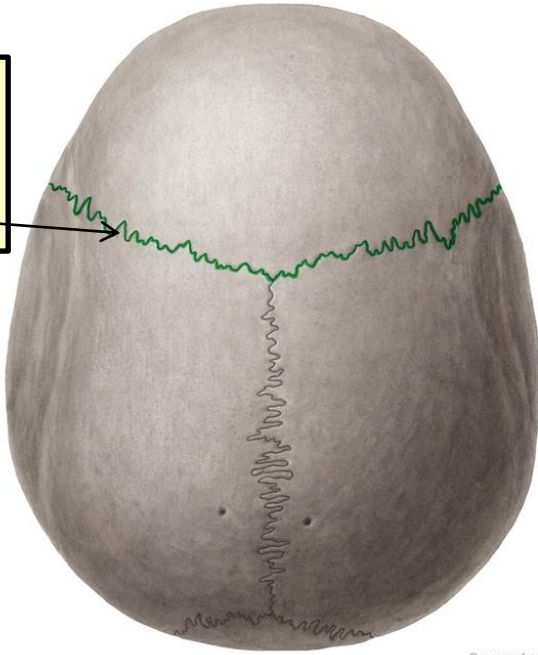


© www.kenhub.com

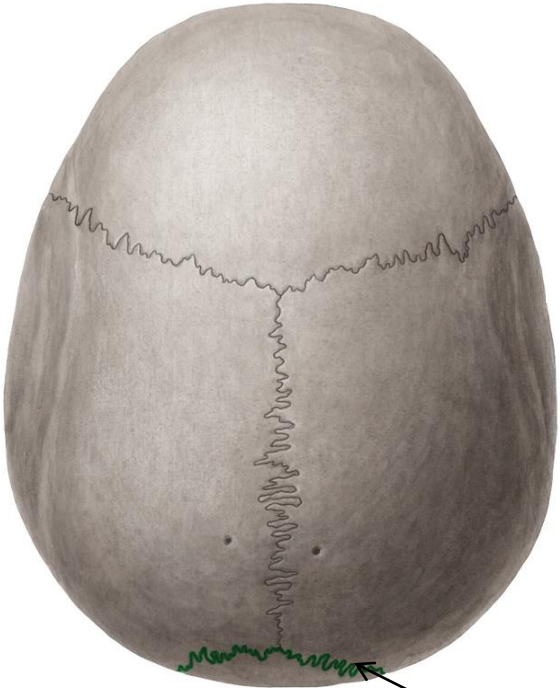
KEN
HUB

KEN
HUB

The frontal bone articulates with the two parietal bones at the **coronal suture**



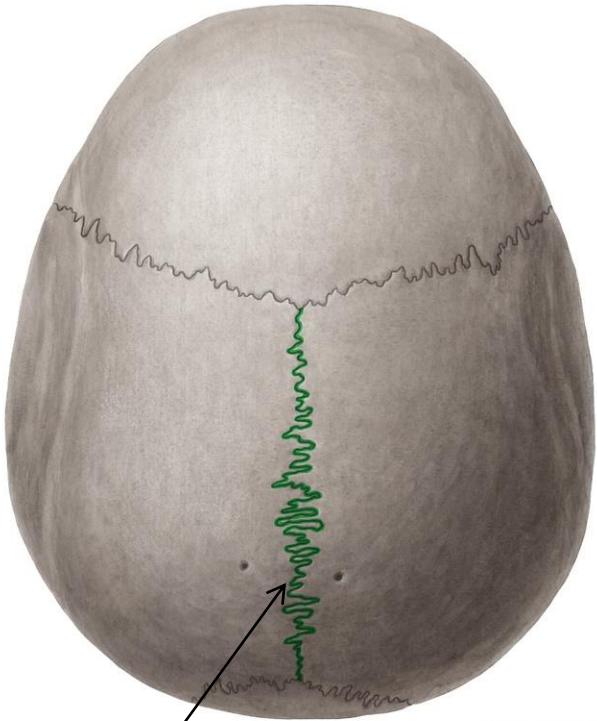
© www.kenhub.cc



© www.kenhub.com



The parietal bones articulate with the occipital bone at the **lambdoid suture**




© www.kenhub.com

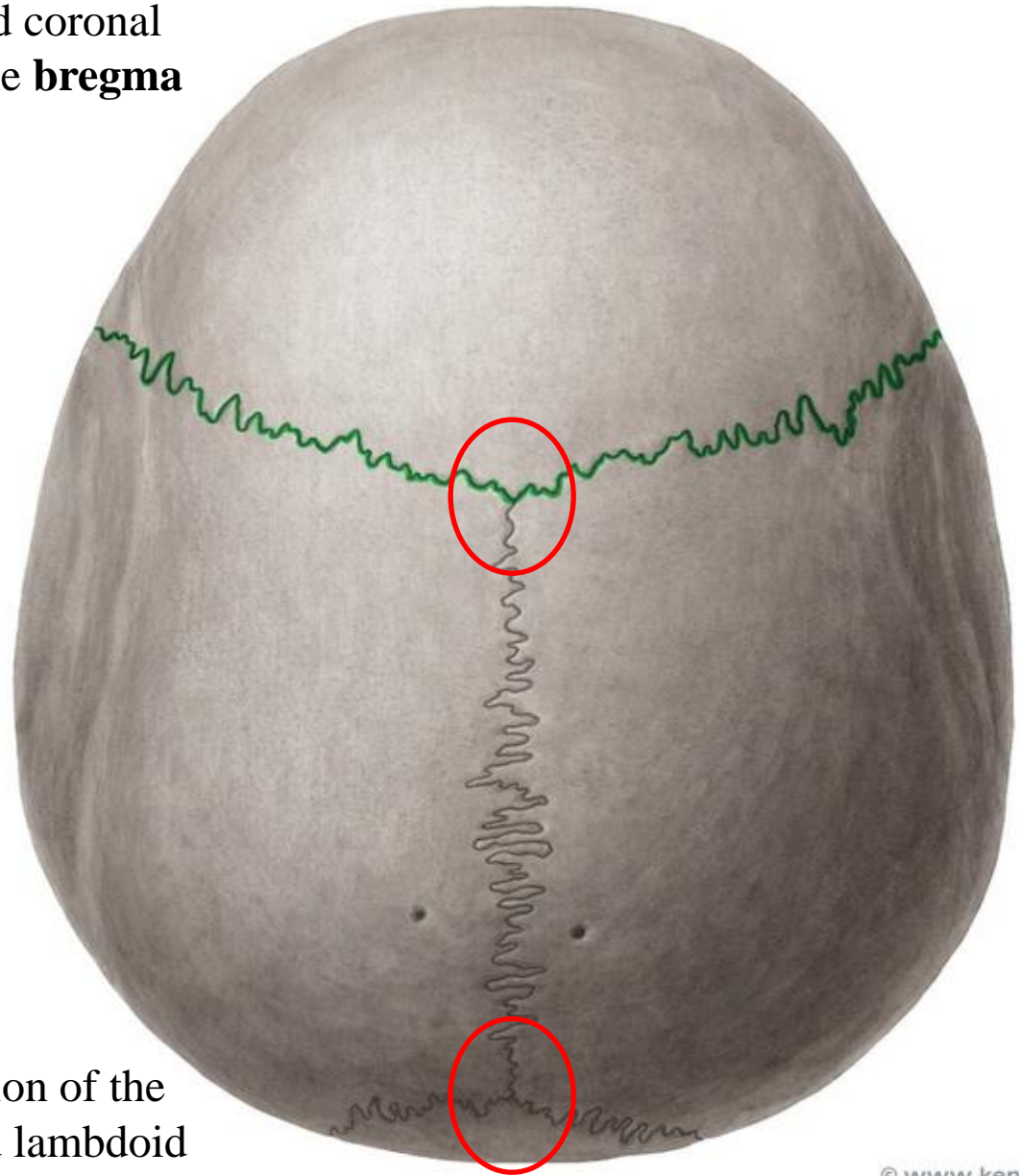
The two parietal bones articulate in the midline at the **sagittal suture**

The junction of the sagittal and coronal sutures is the **bregma**

Anterior fontanel

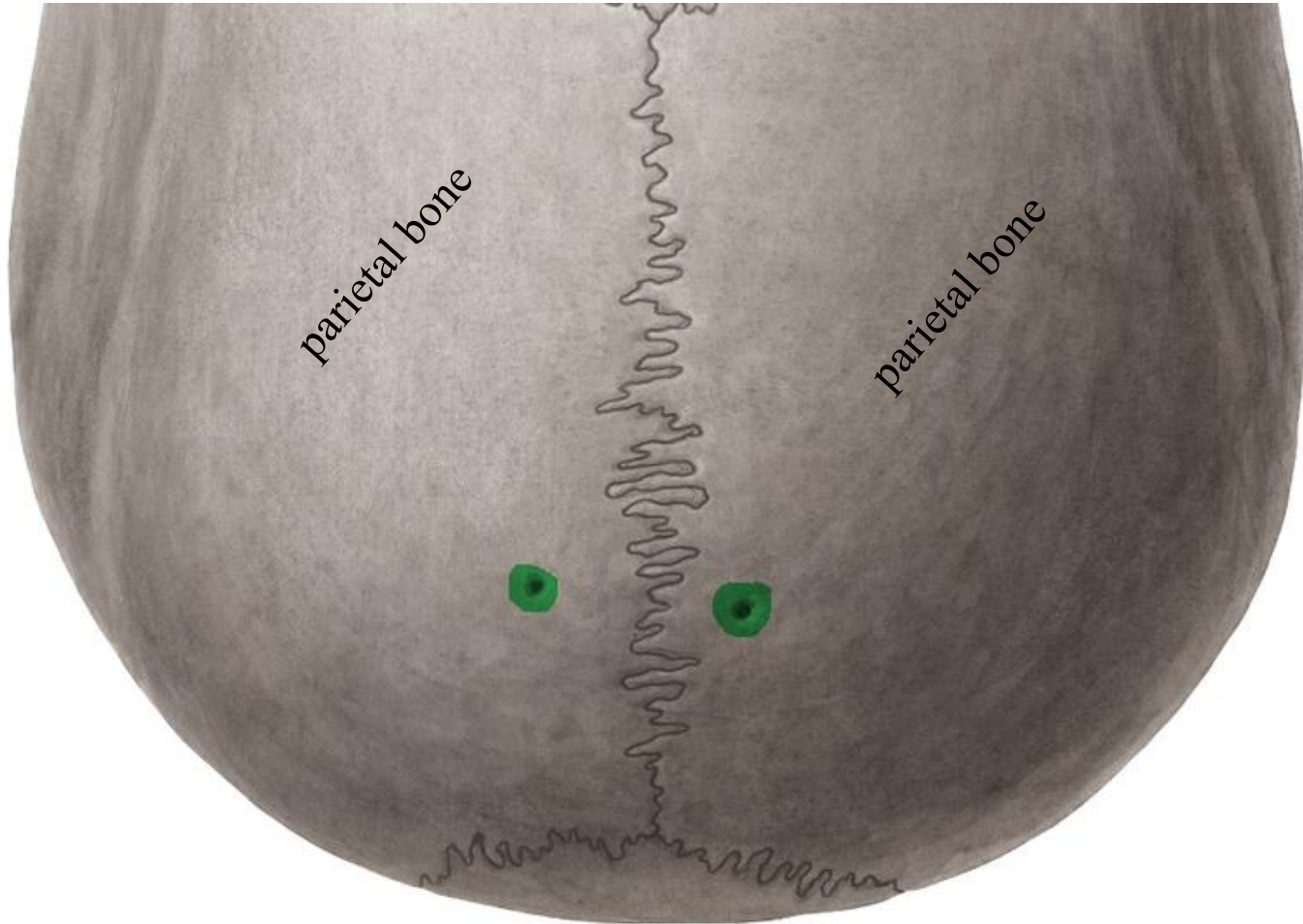


Posterior fontanel

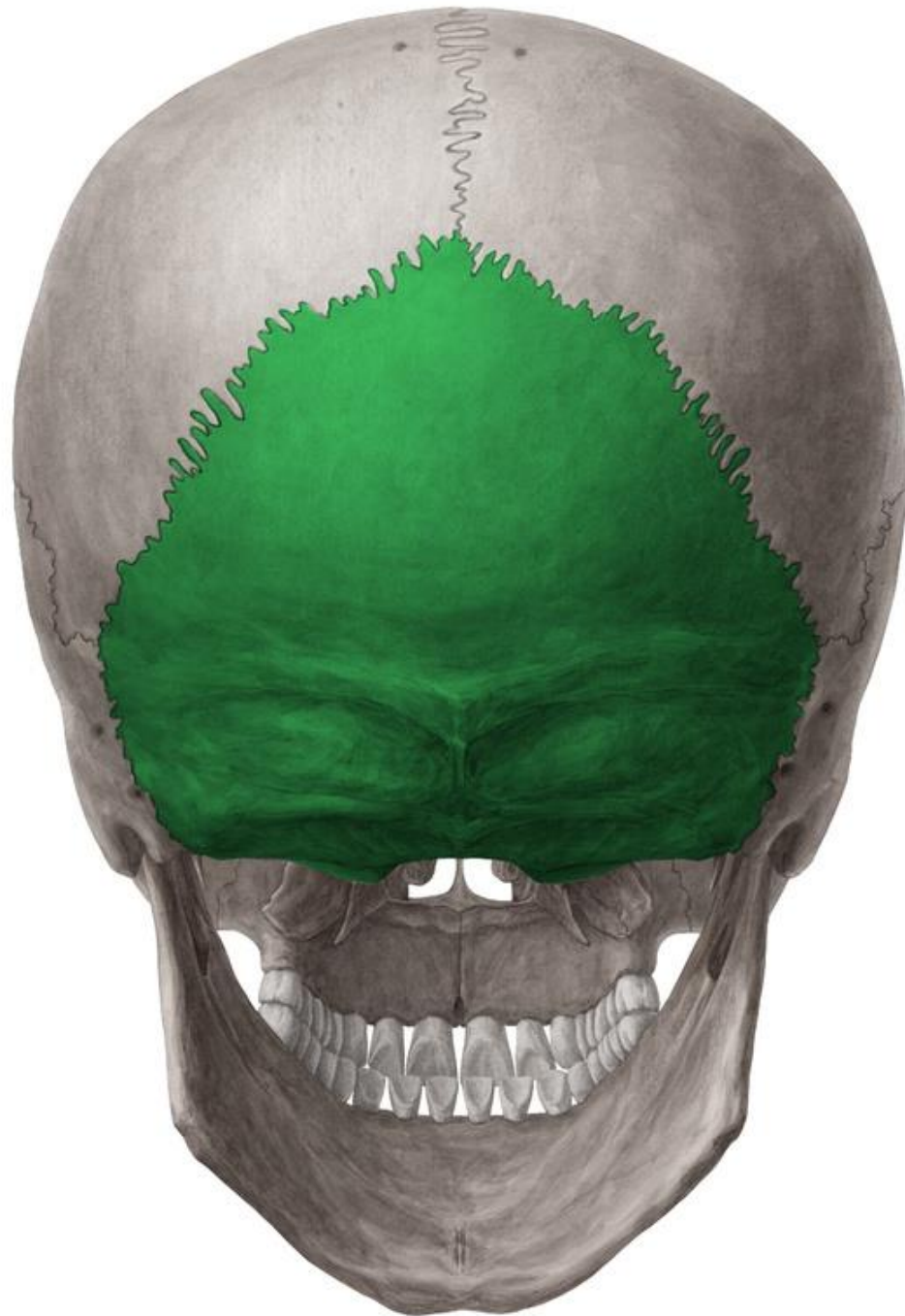


The junction of the sagittal and lambdoid sutures is the **Lambda**

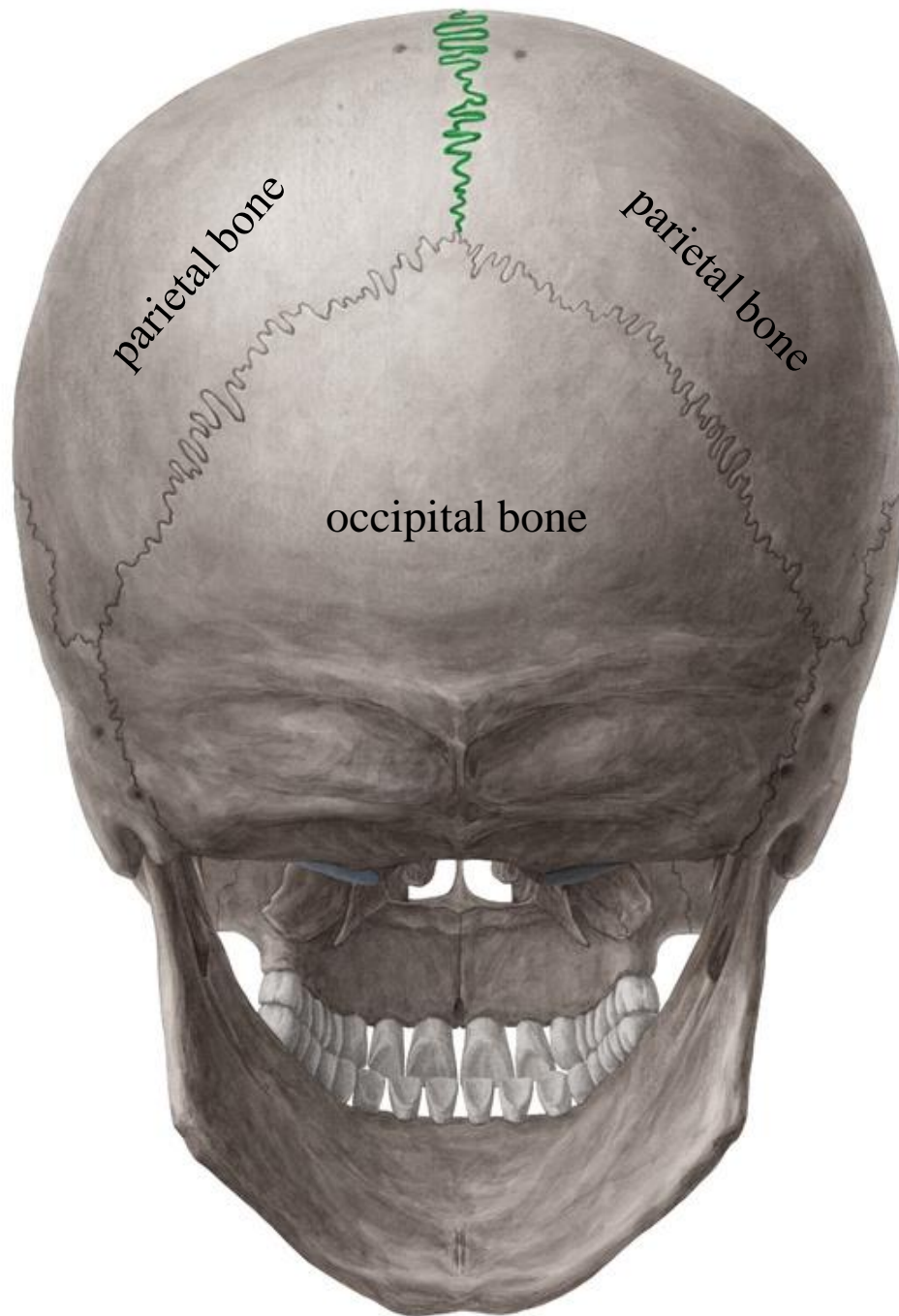
Parietal foramina



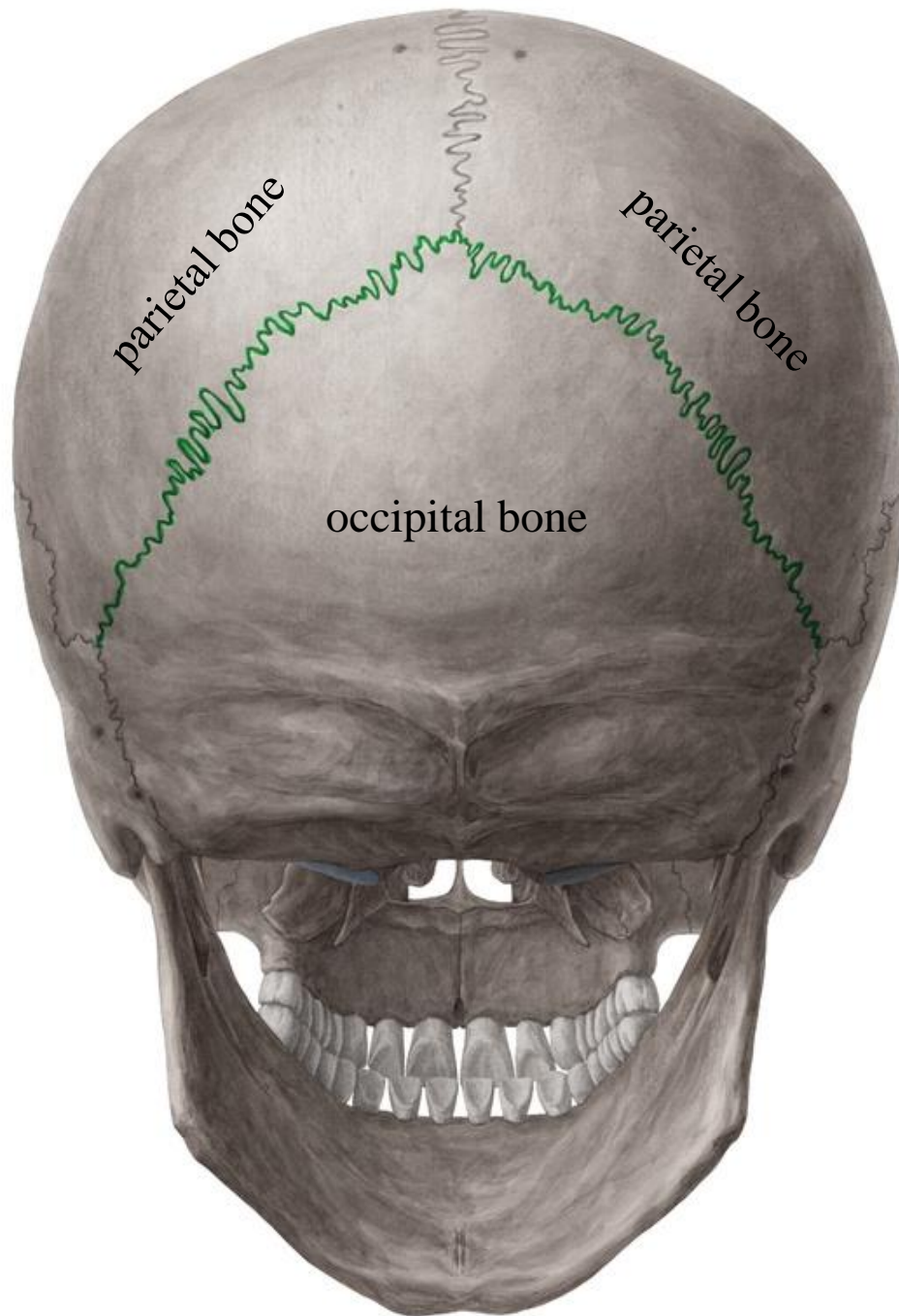
Occipital bone

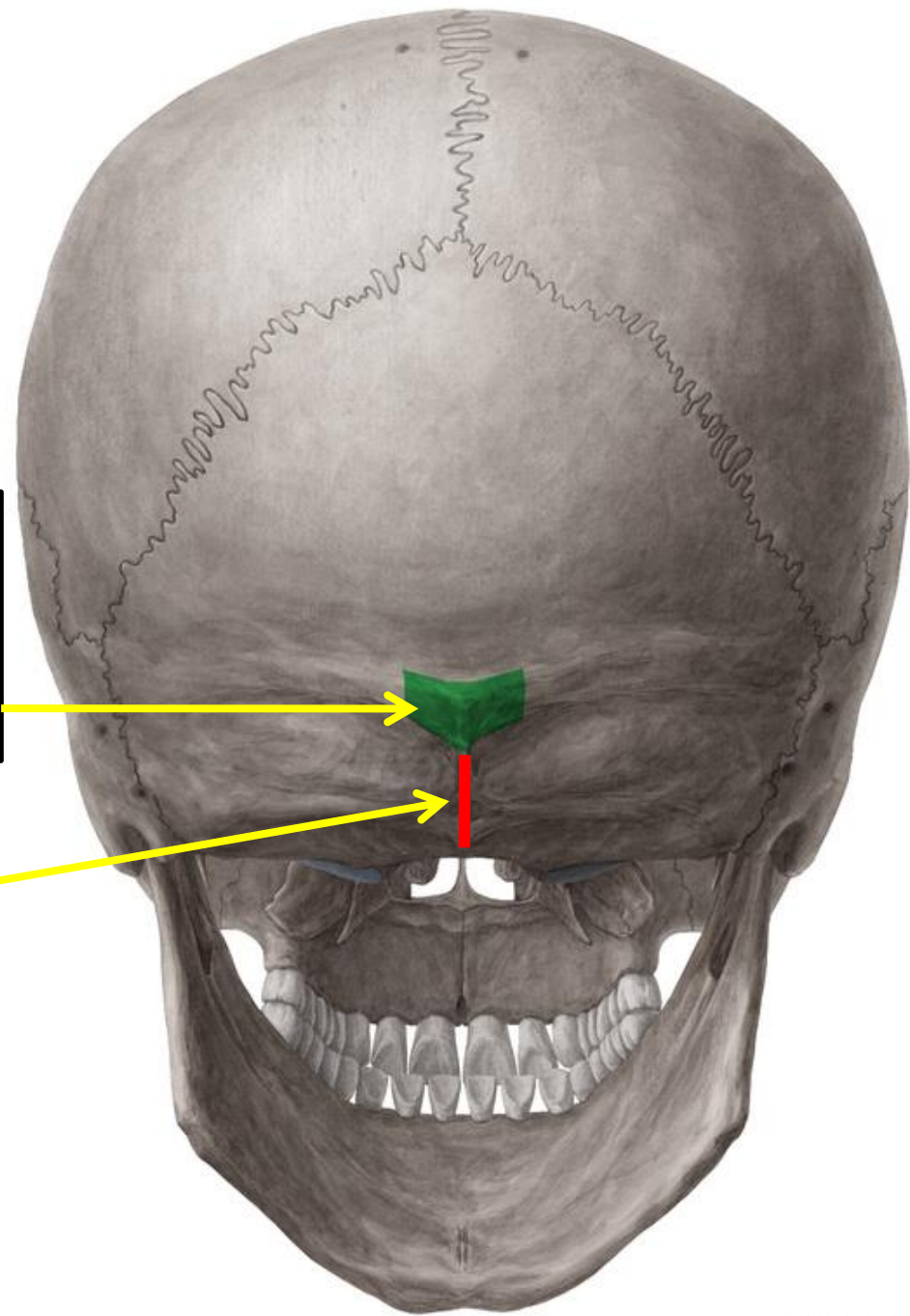


The two parietal bones
articulate in the midline at the
sagittal suture



The parietal bones articulate with the occipital bone at the **lambdoid suture**

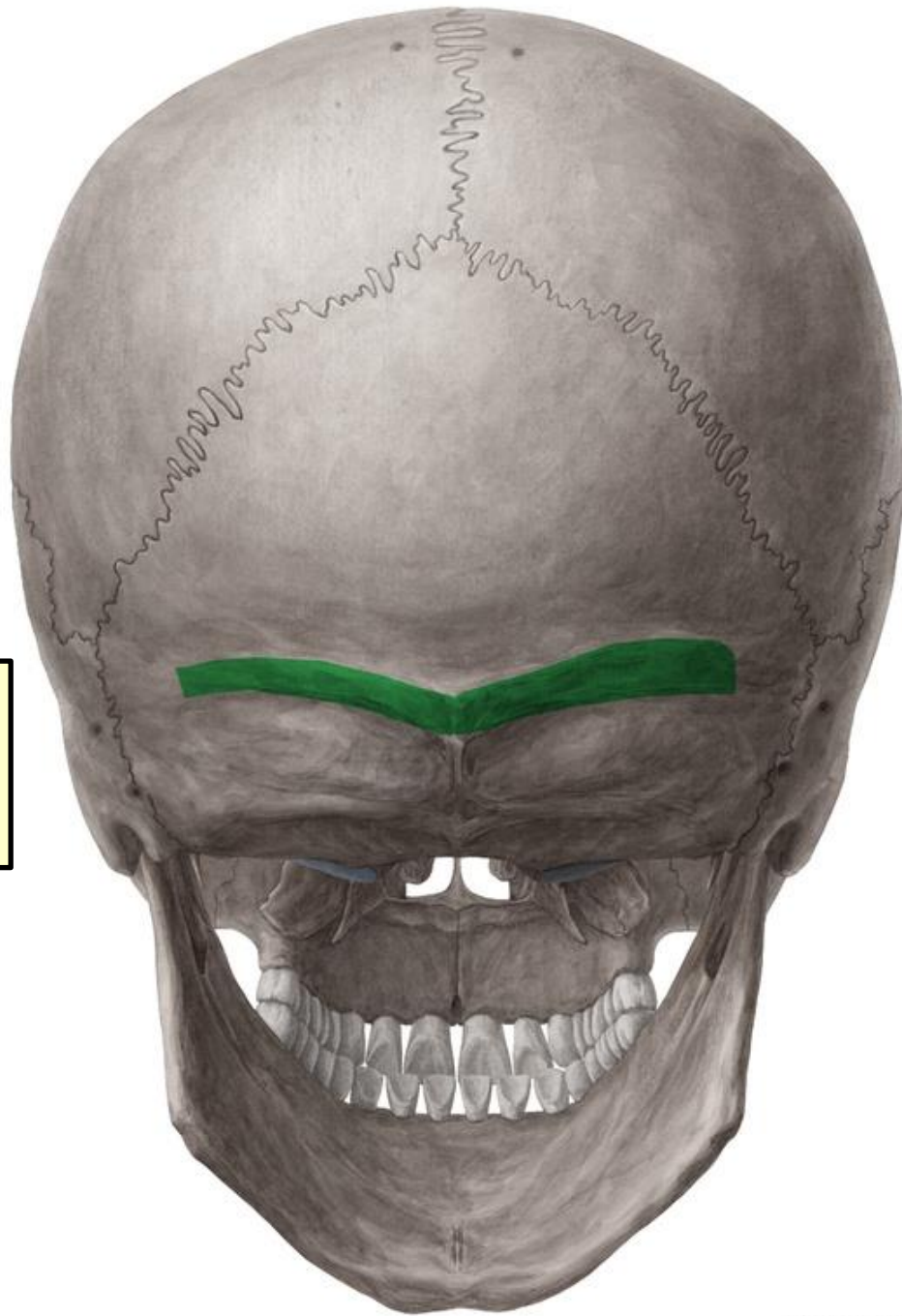




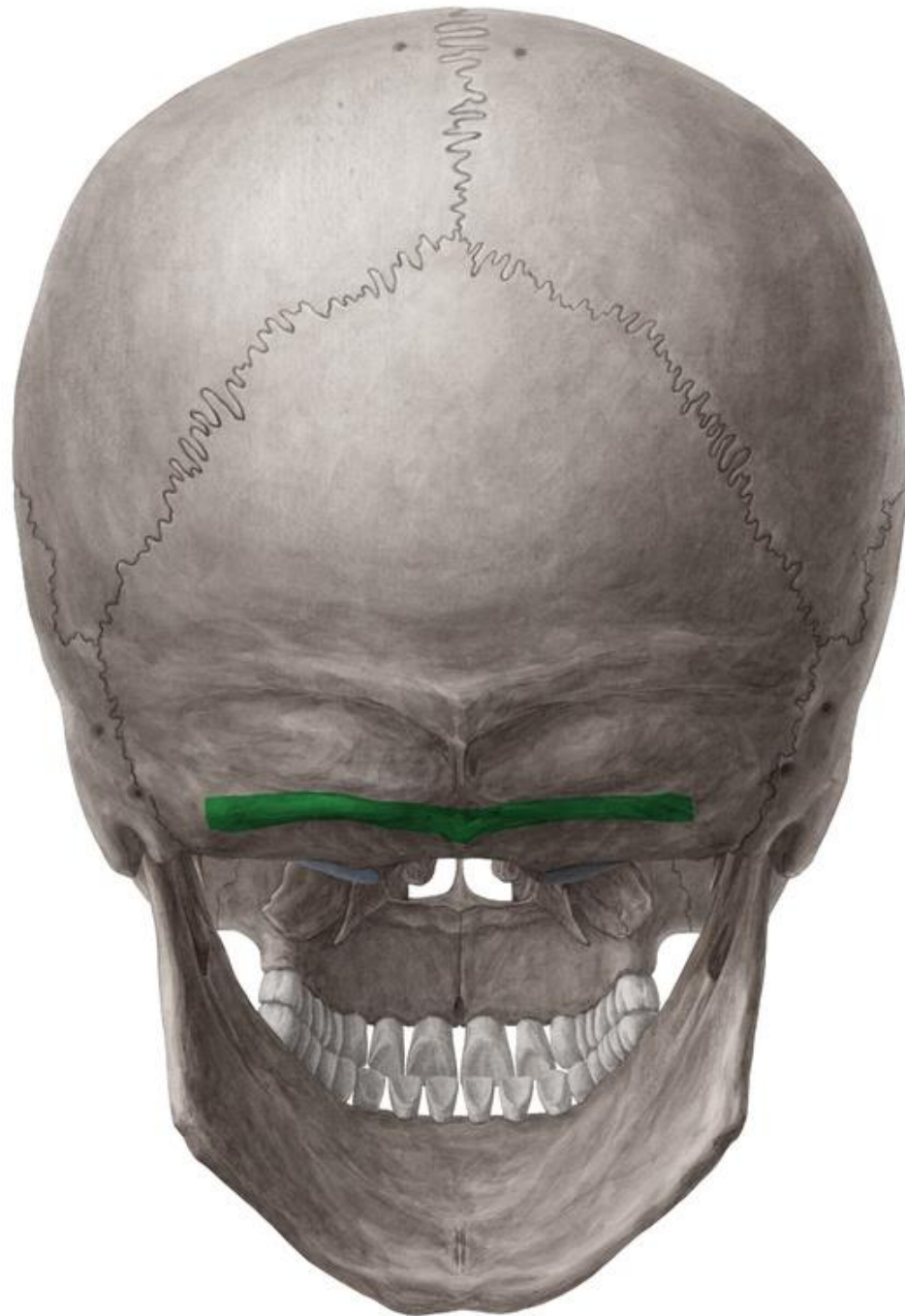
In the midline of the occipital bone is a roughened elevation called **External occipital protuberance**

External occipital crest

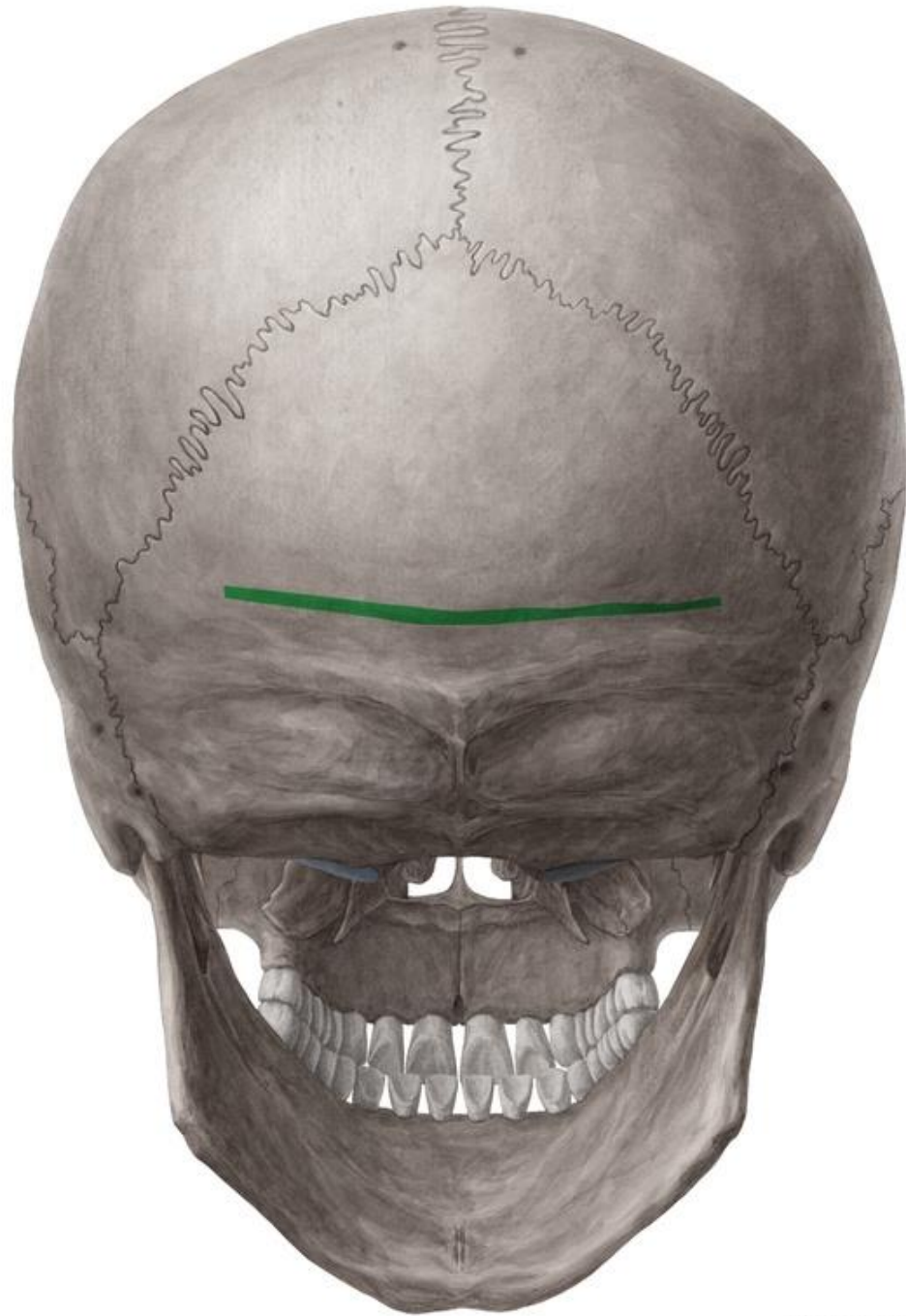
On either side of the protuberance the **superior nuchal lines** extend laterally



Inferior nuchal line

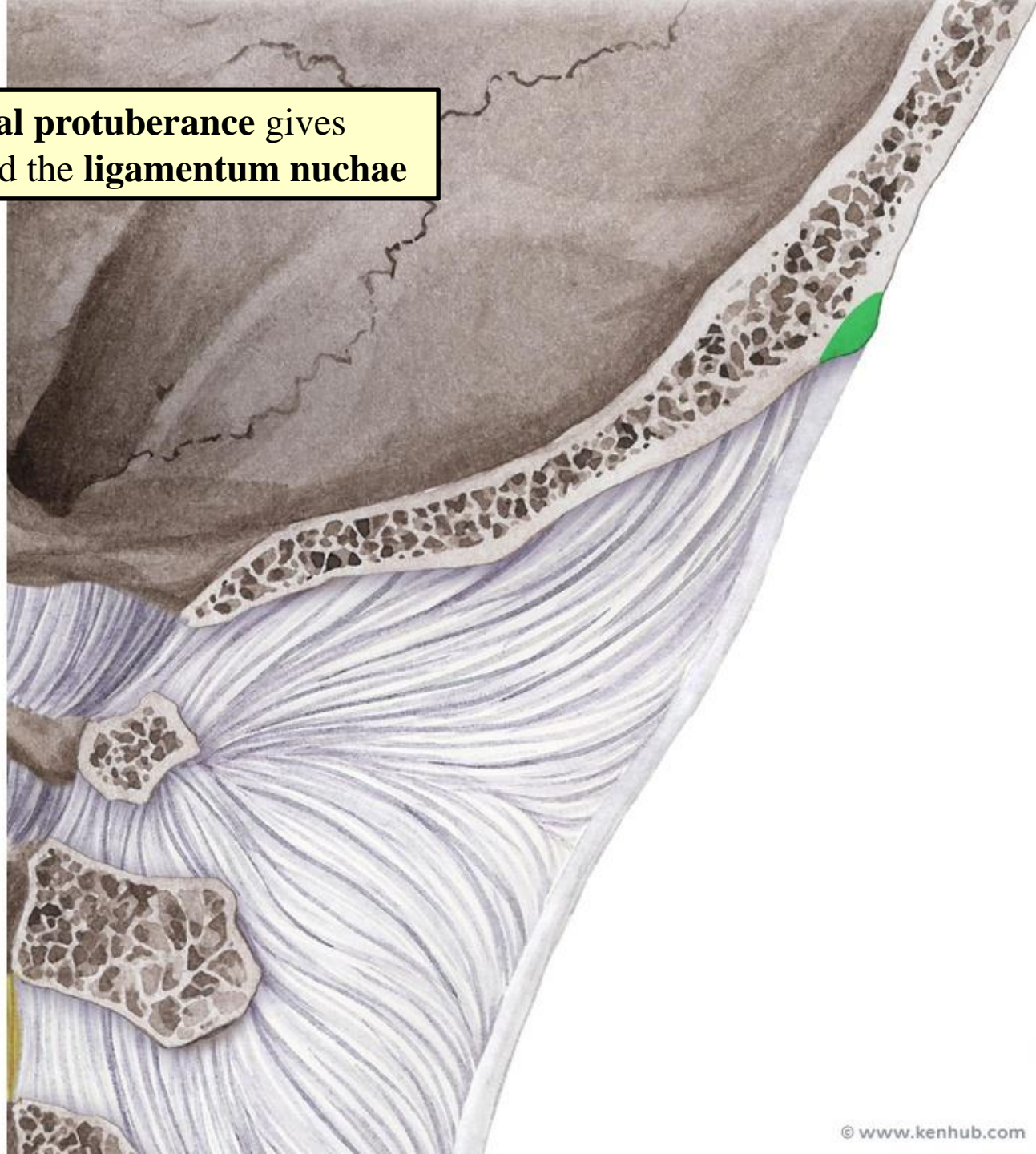


Highest nuchal line



The **external occipital protuberance** gives attachment to muscles and the **ligamentum nuchae**

Ligamentum nuchae extends from the external occipital protuberance to the spinous process of the seventh cervical vertebra



Frontal bone

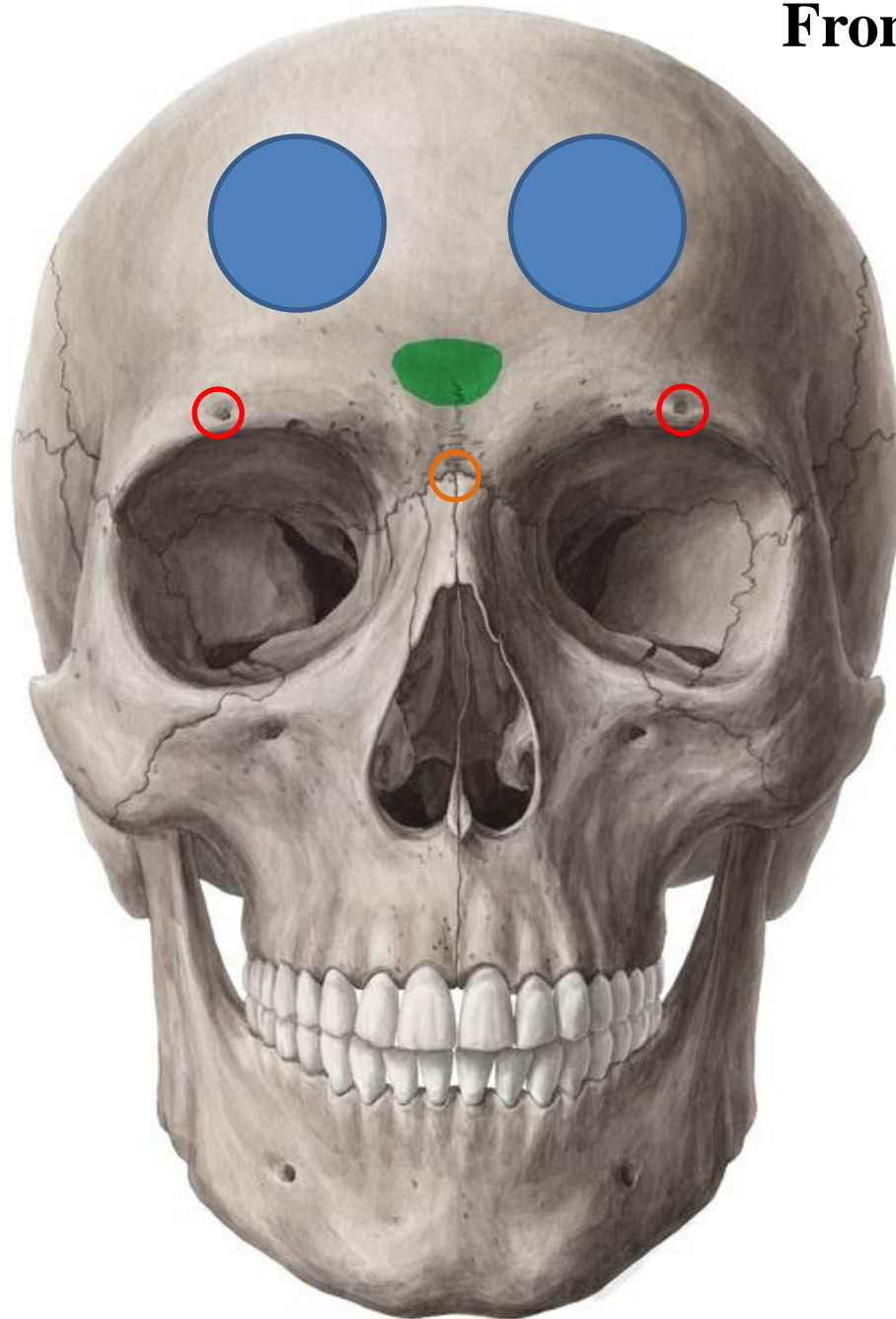
Frontal eminence: the most prominent areas on either side of the forehead

Superciliary arches (brow ridges): Elevated ridges above the sup. orbital margins

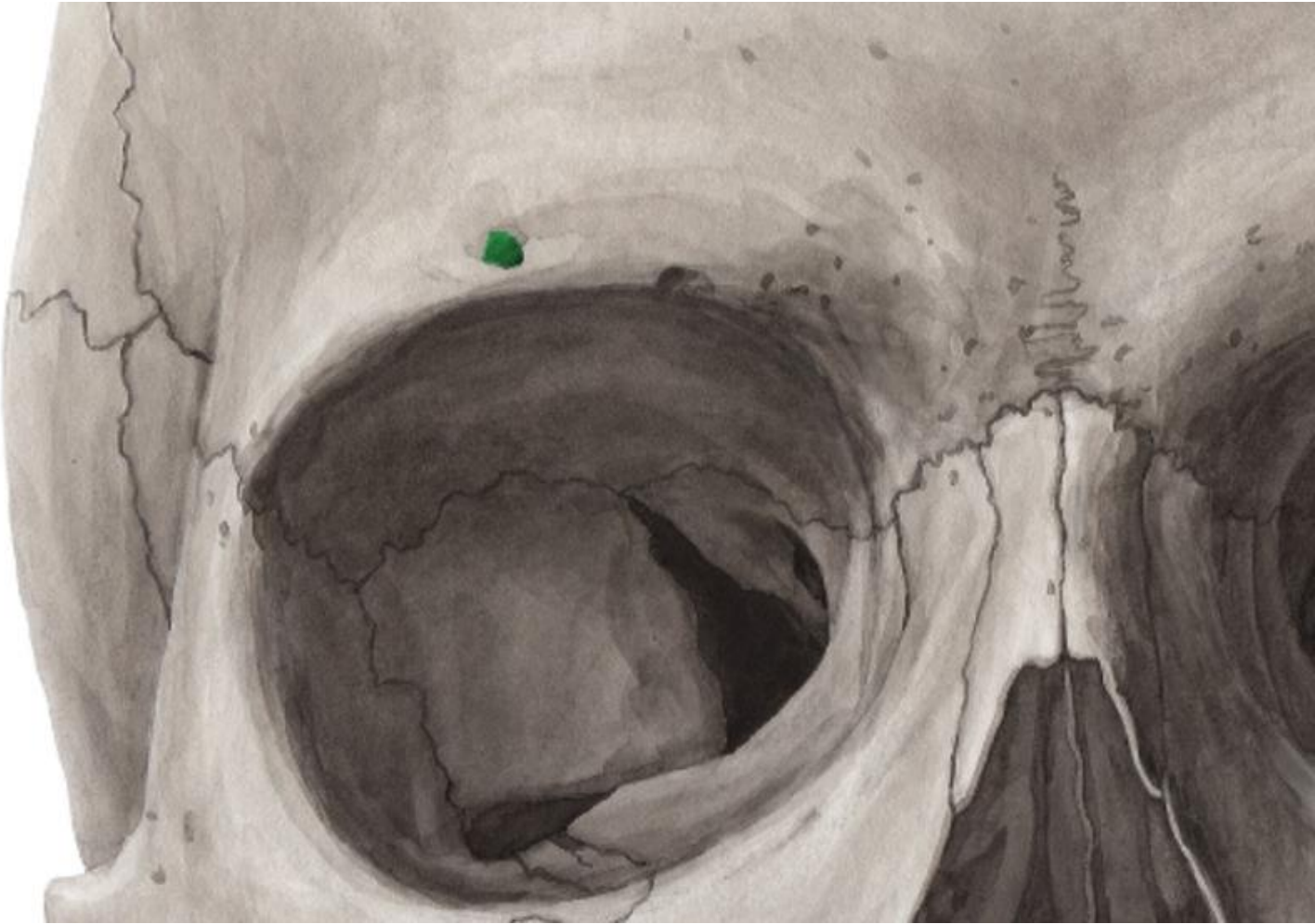
Supraorbital notch, or foramen: transmits the supraorbital nerve & vessels

Glabella: a slightly elevated area above the root of the nose between the 2 superciliary arches

Nasion: a point where the frontonasal & internasal sutures meet



Supraorbital foramen: transmits supraorbital nerve and vessels



Maxilla

The Maxilla has:

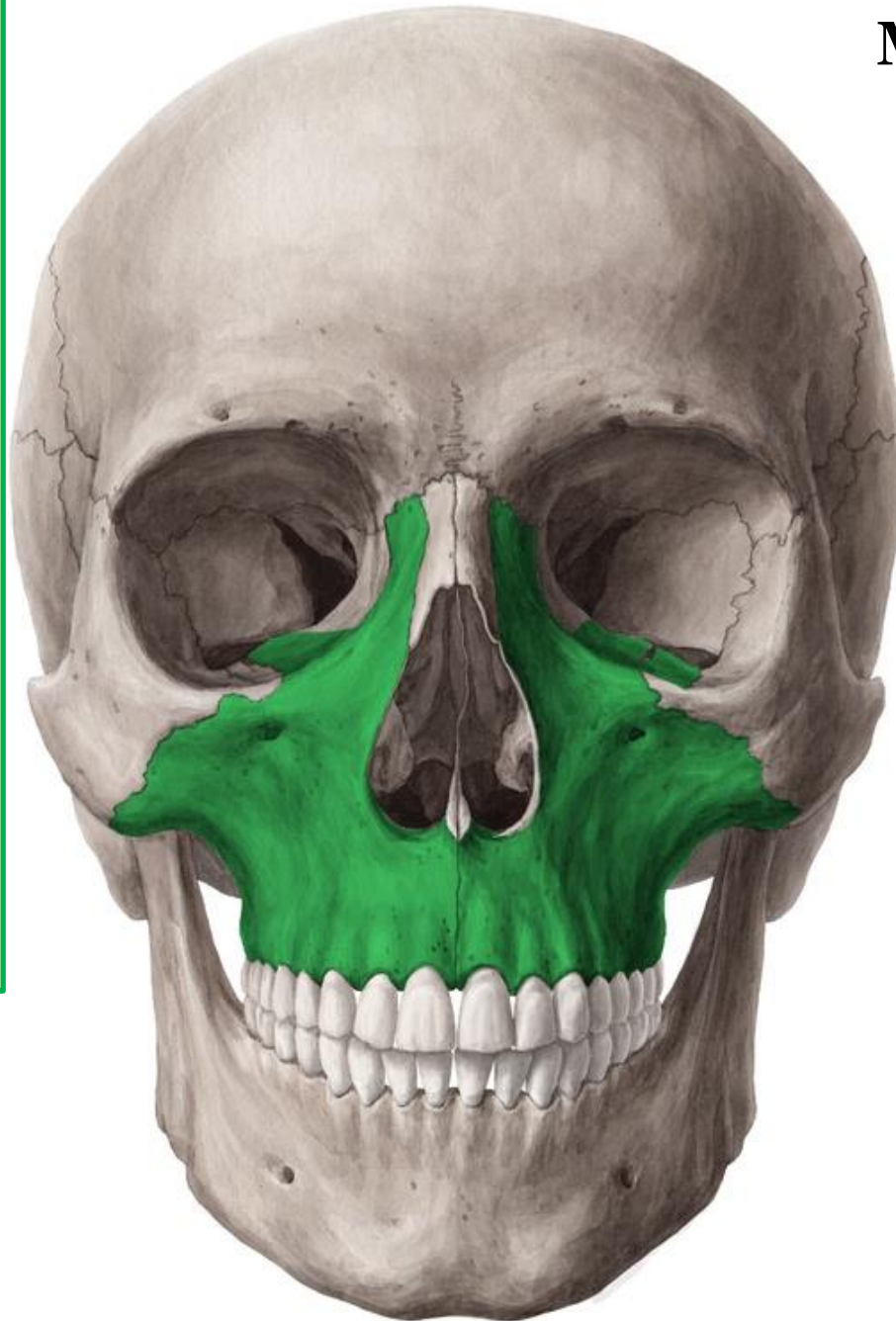
Frontal process: articulates with frontal bone

Zygomatic process: articulates with zygomatic bone

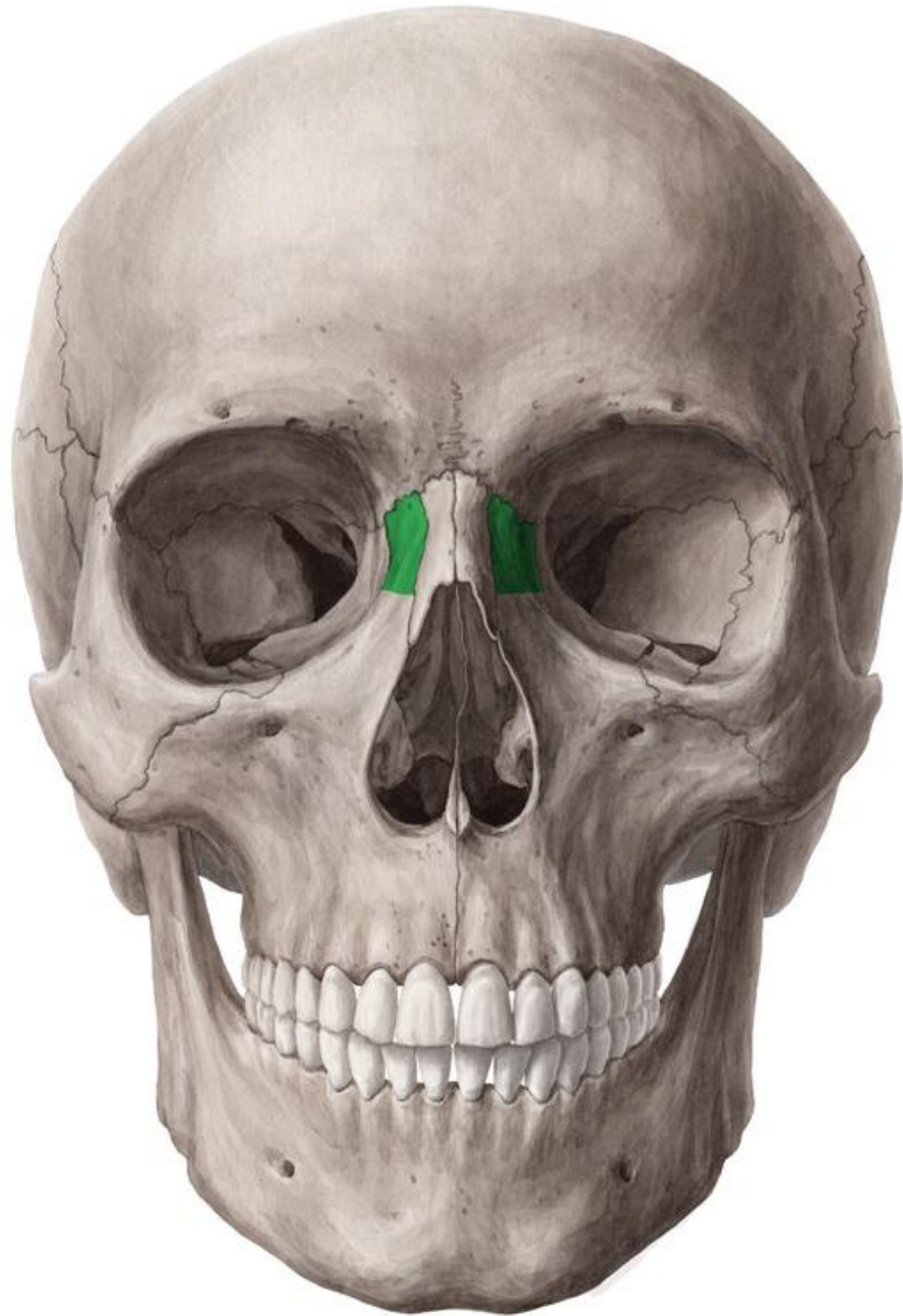
Alveolar process: the bony ridge that contains the tooth sockets for holding upper teeth

Orbital plate: forms of the floor of the orbit

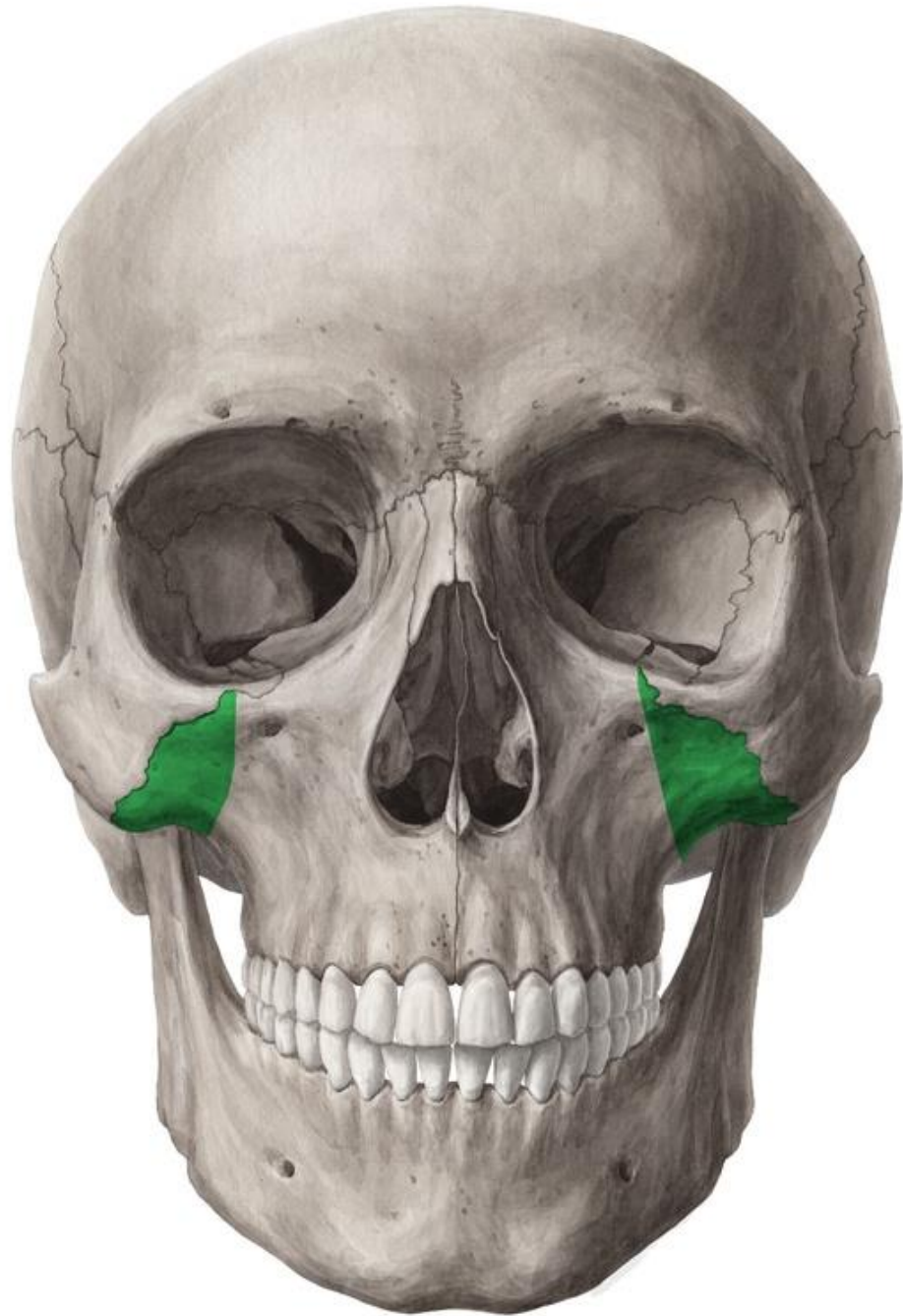Palatine process: forms the anterior part of hard palate



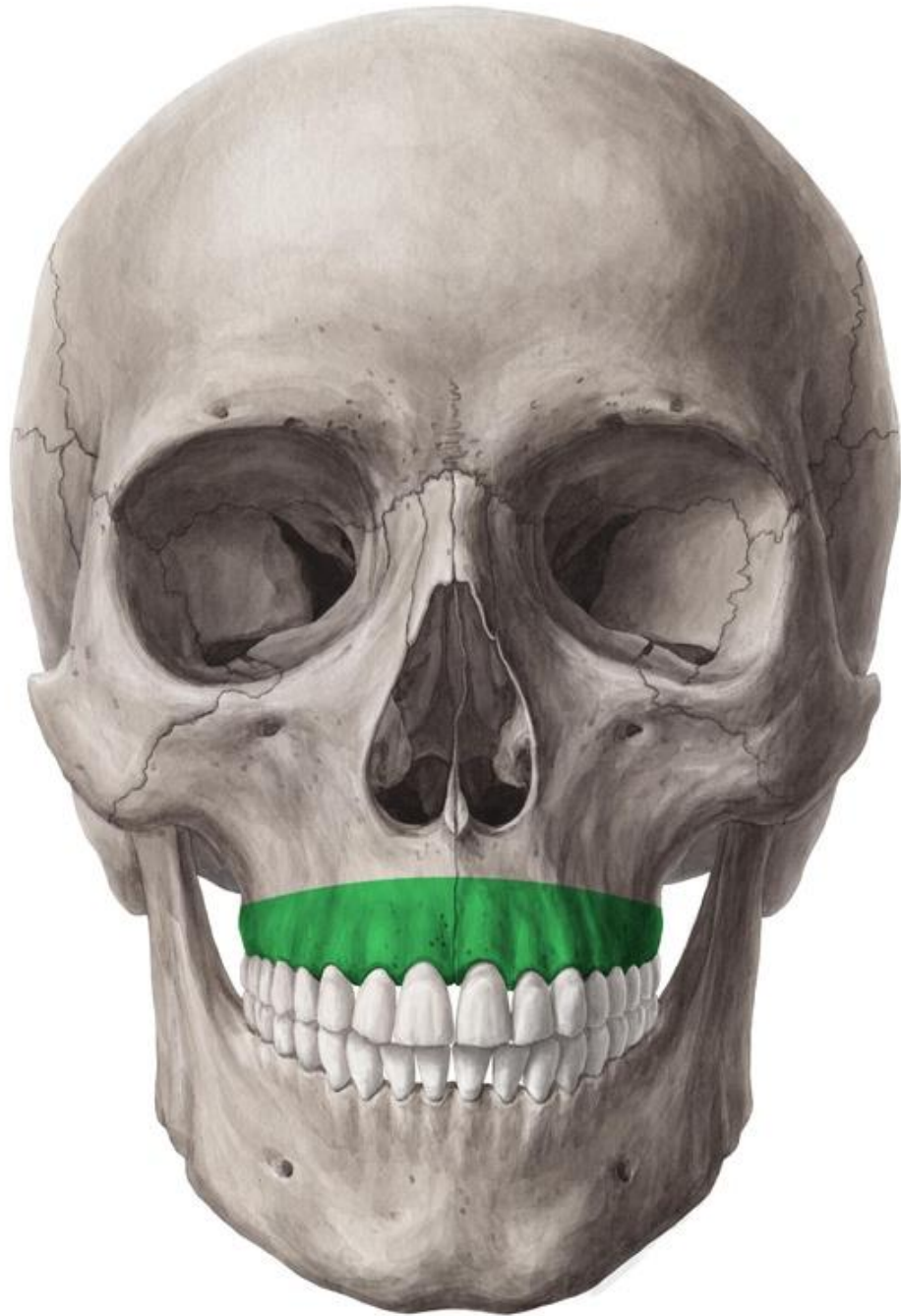Frontal process of maxilla



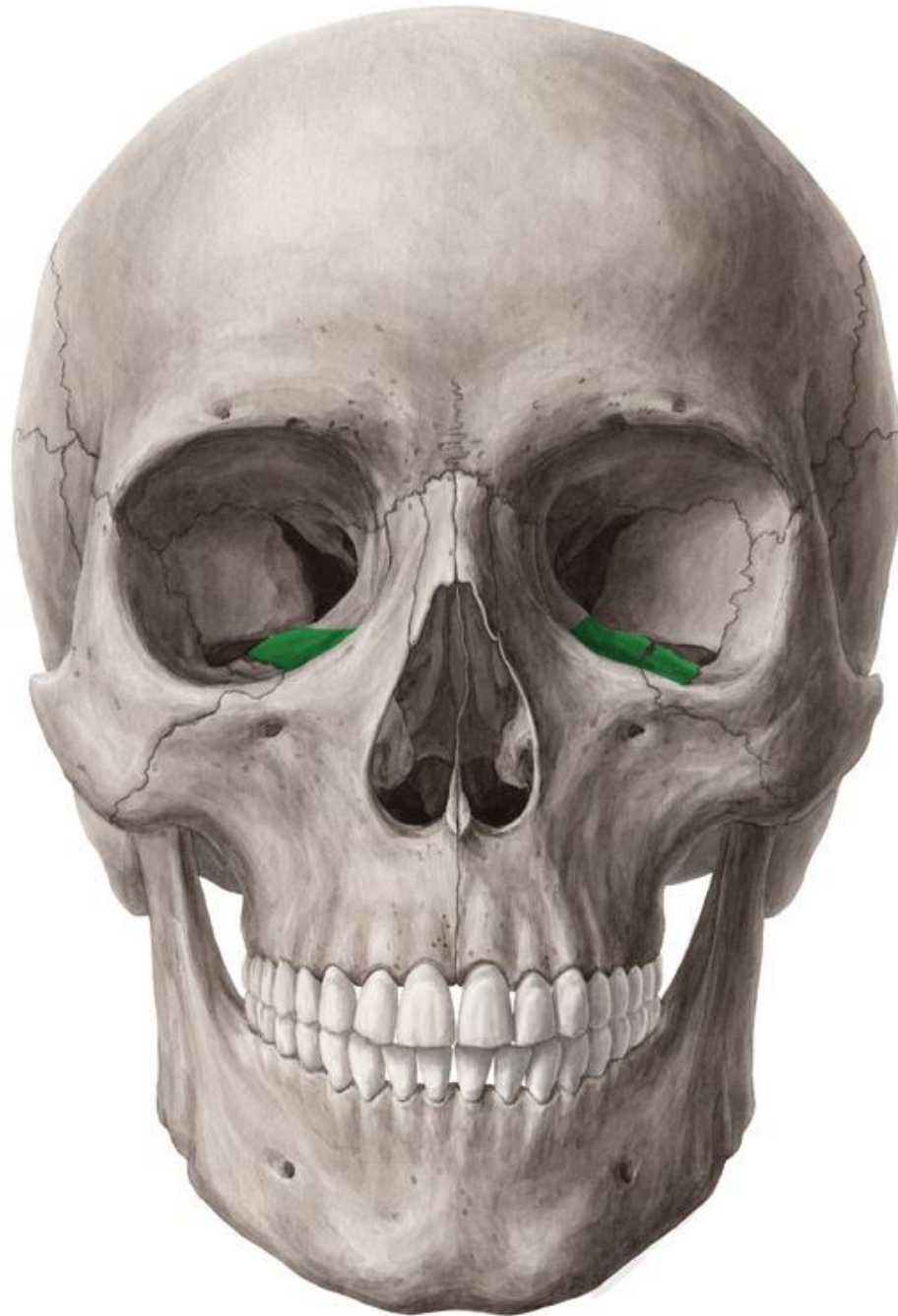Zygomatic process of maxilla



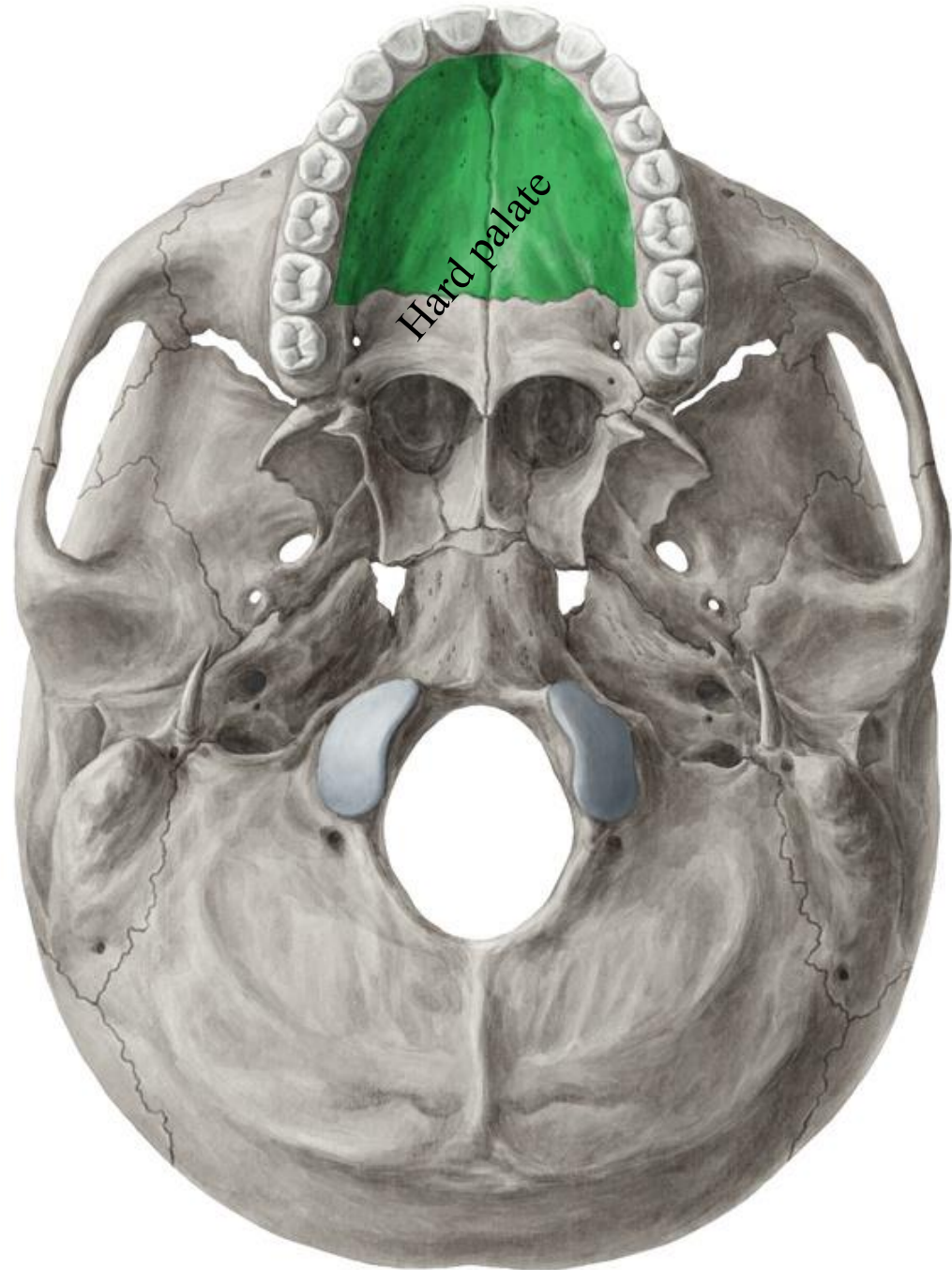Alveolar process of maxilla



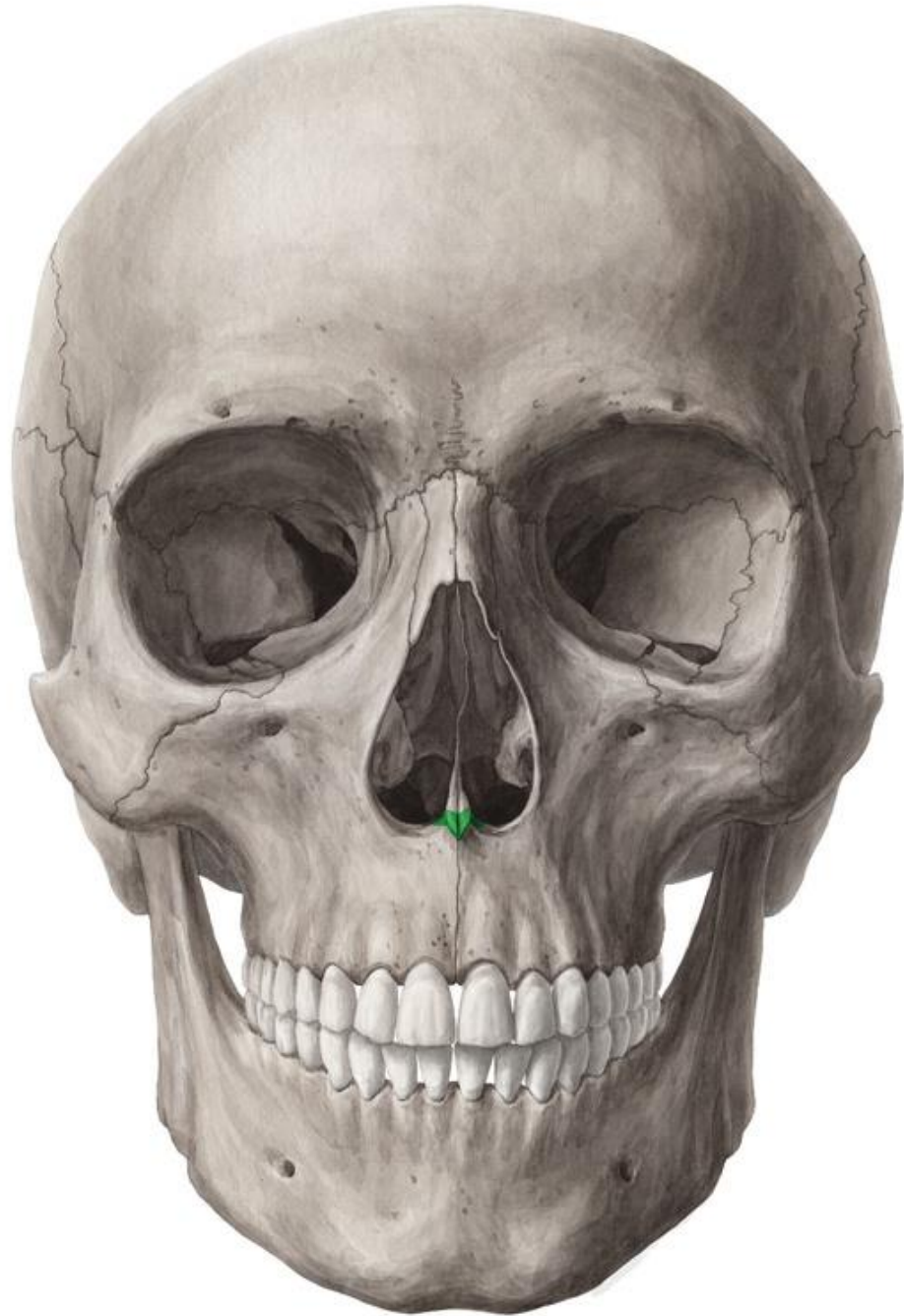Orbital plate of maxilla



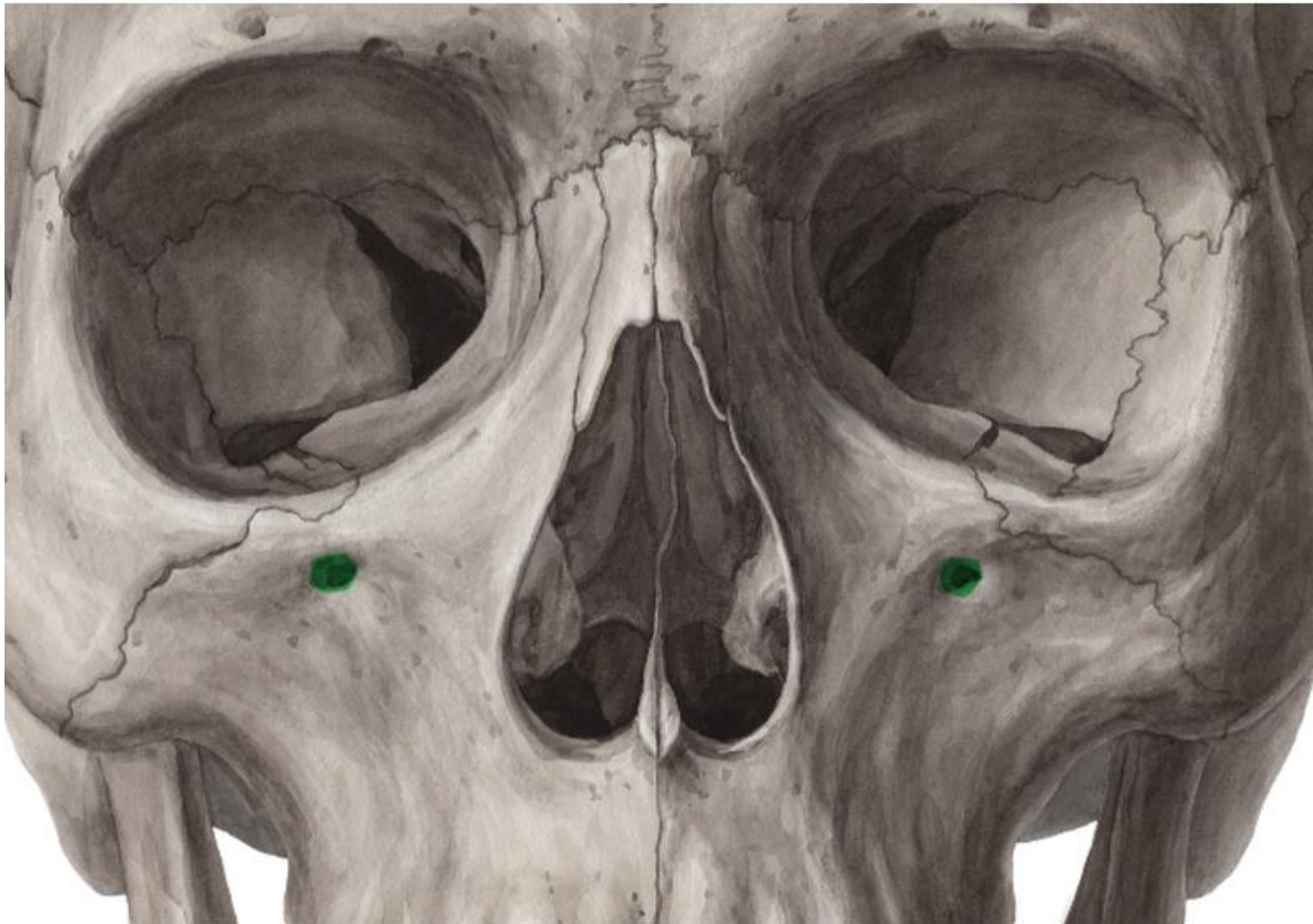
Palatine process of maxilla



Anterior nasal spine



Infraorbital foramen: transmits the infraorbital nerve & vessels



Zygomatic bone

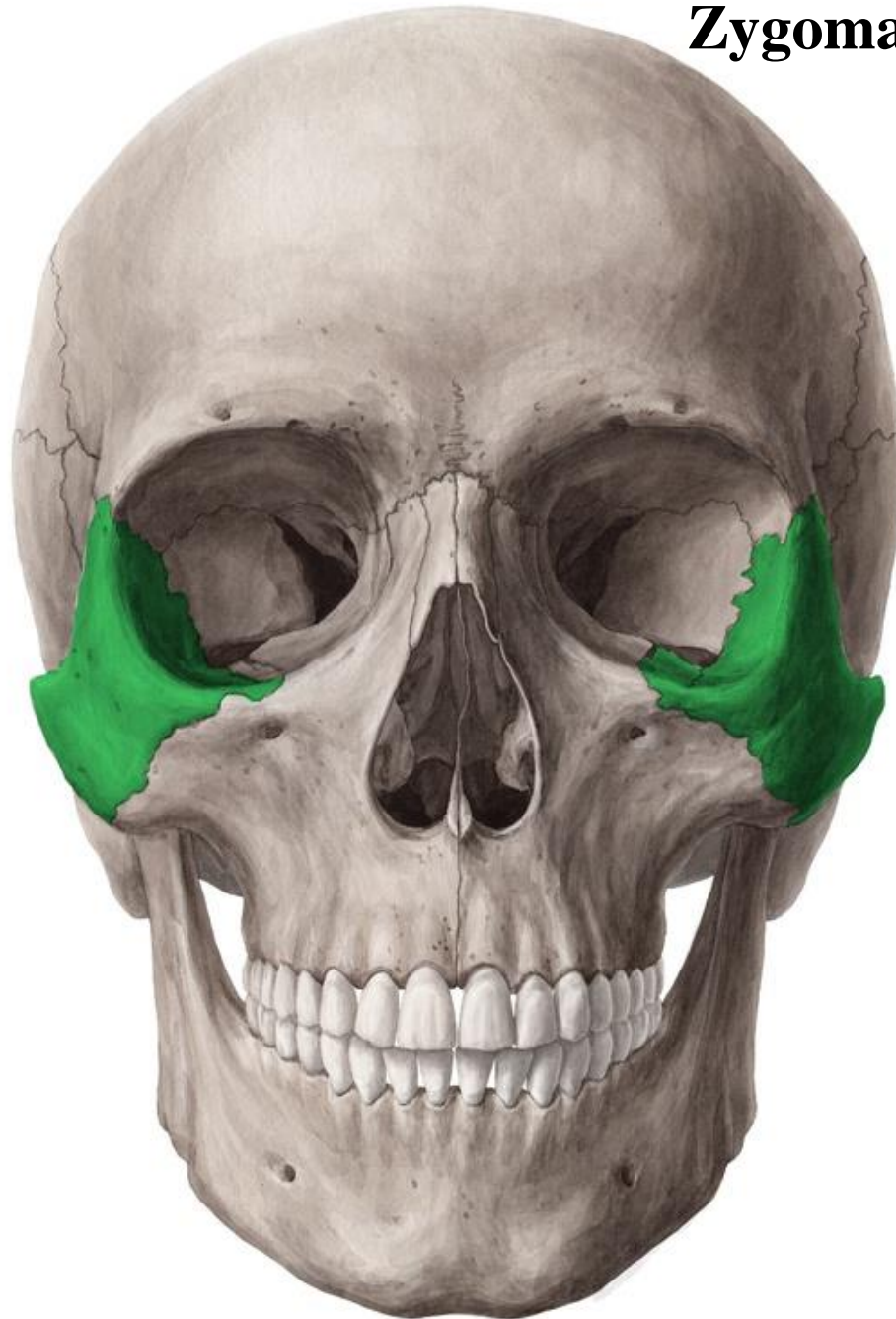The zygomatic bone has:

Frontal process: articulates with frontal bone

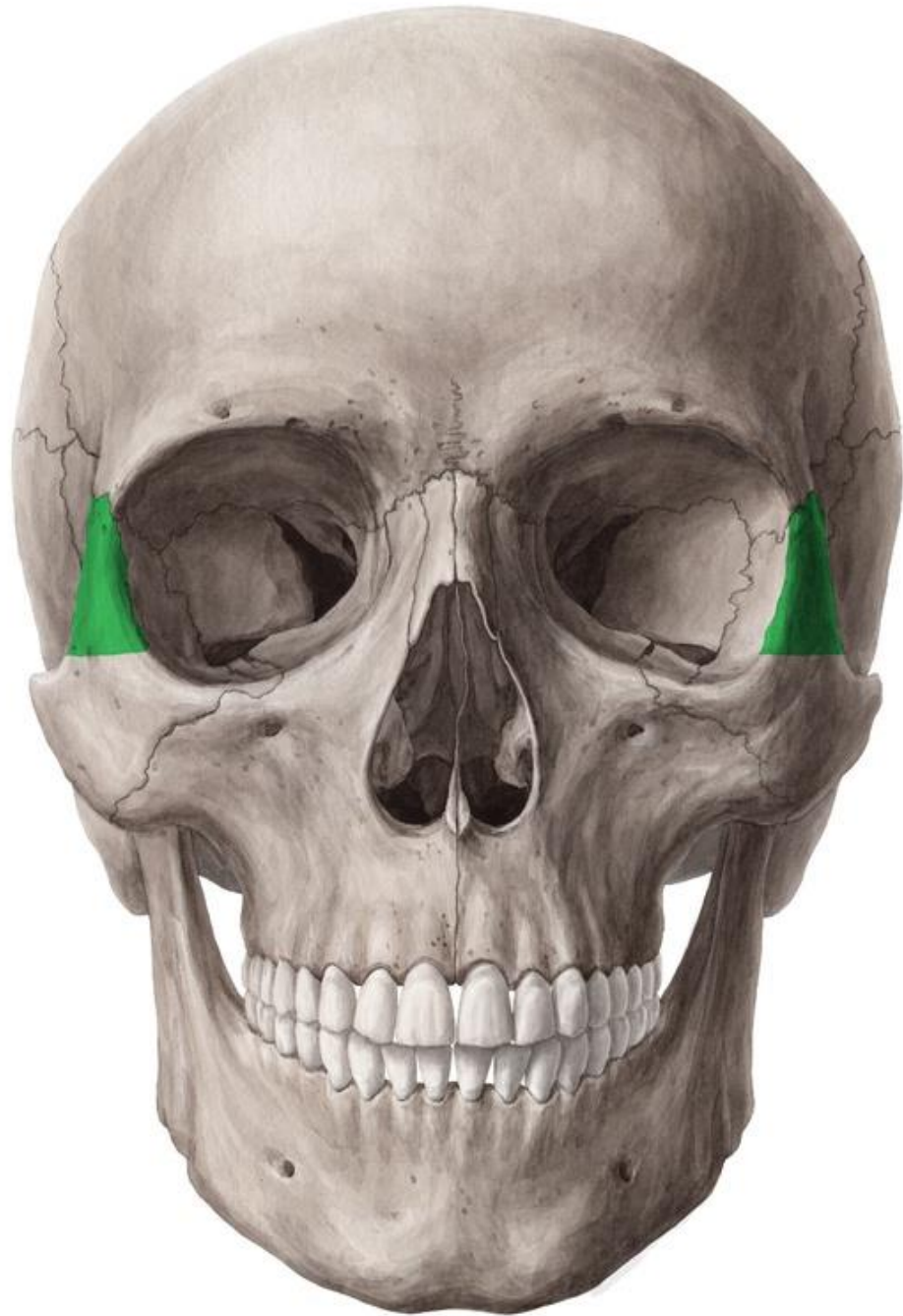Temporal process: articulates with zygomatic process of the temporal bone to form the zygomatic arch

Maxillary process: articulates with the maxillary bone

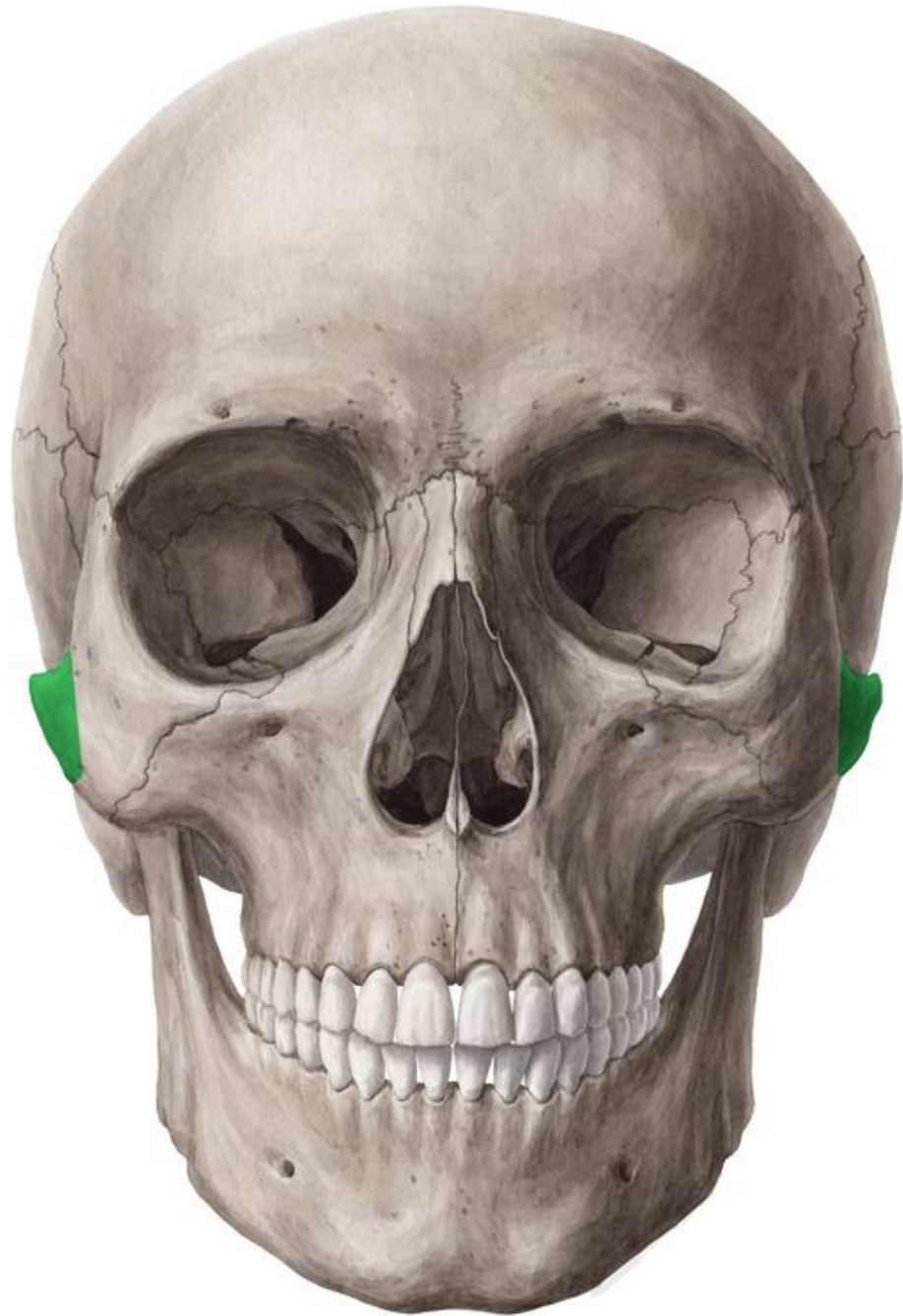
Orbital plate: forms part of the lateral wall of the orbit



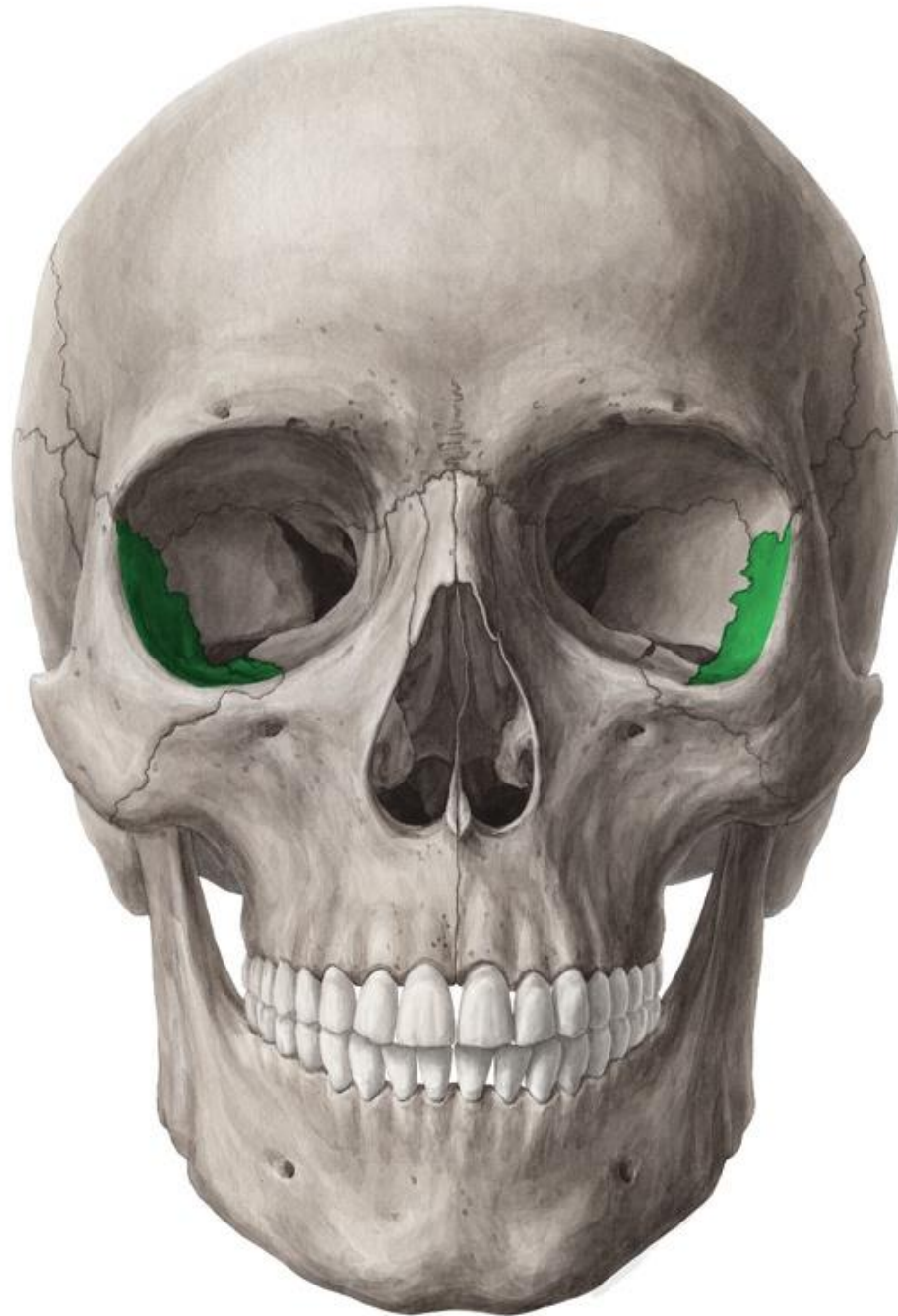Frontal process of zygomatic bone



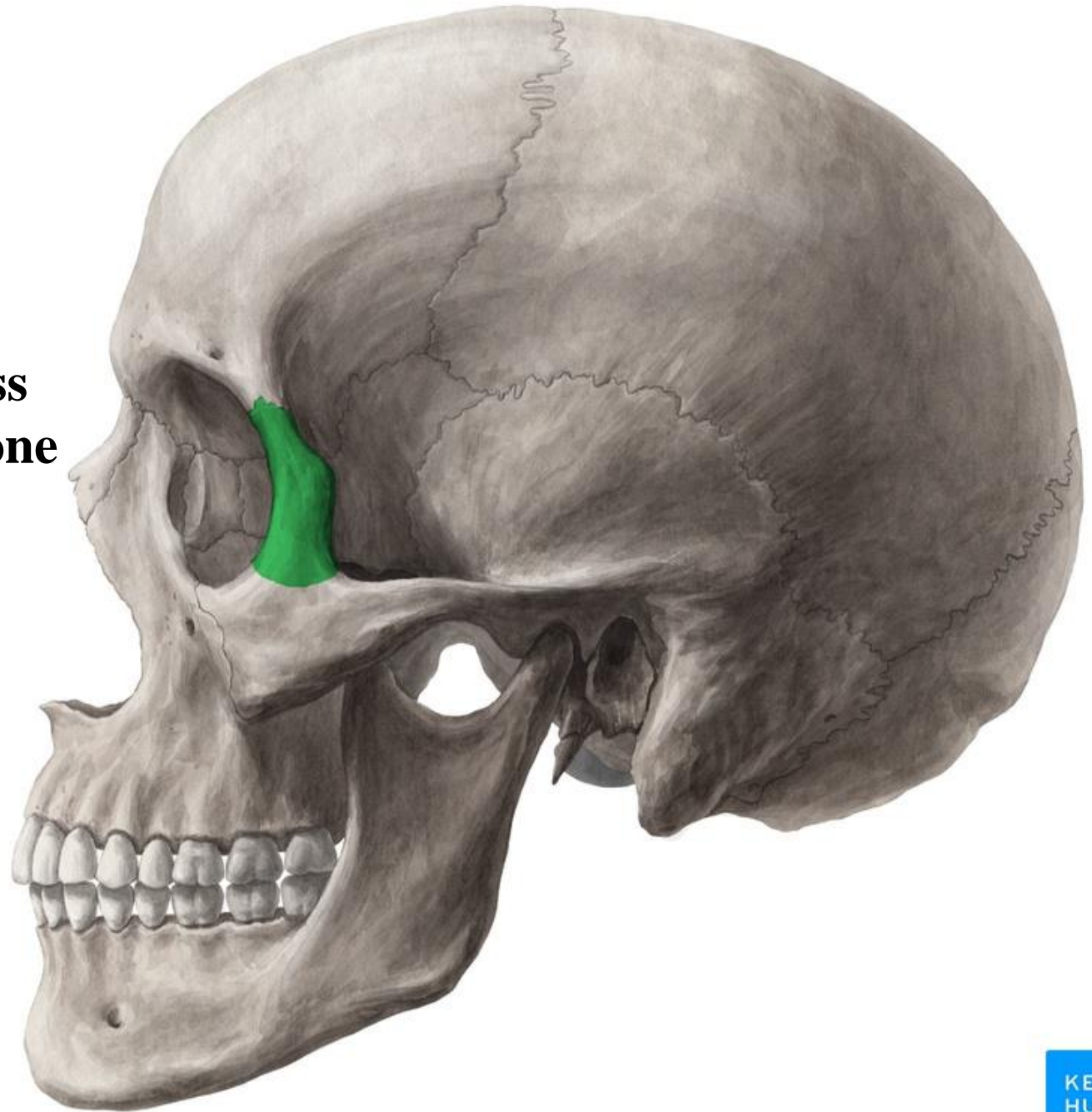
Temporal process of zygomatic bone



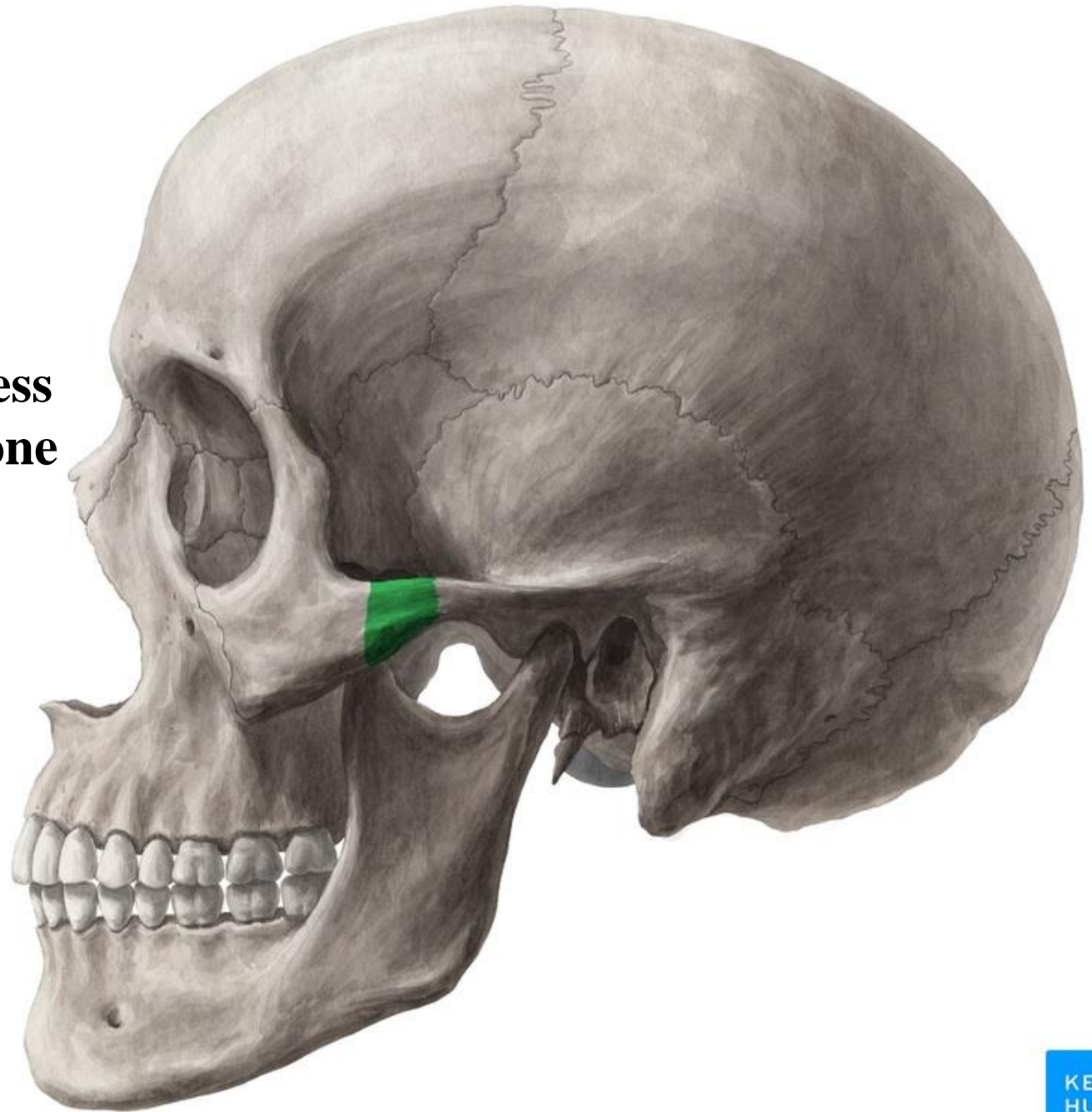
Orbital plate of zygomatic bone



**Frontal process
of zygomatic bone**



Temporal process of zygomatic bone

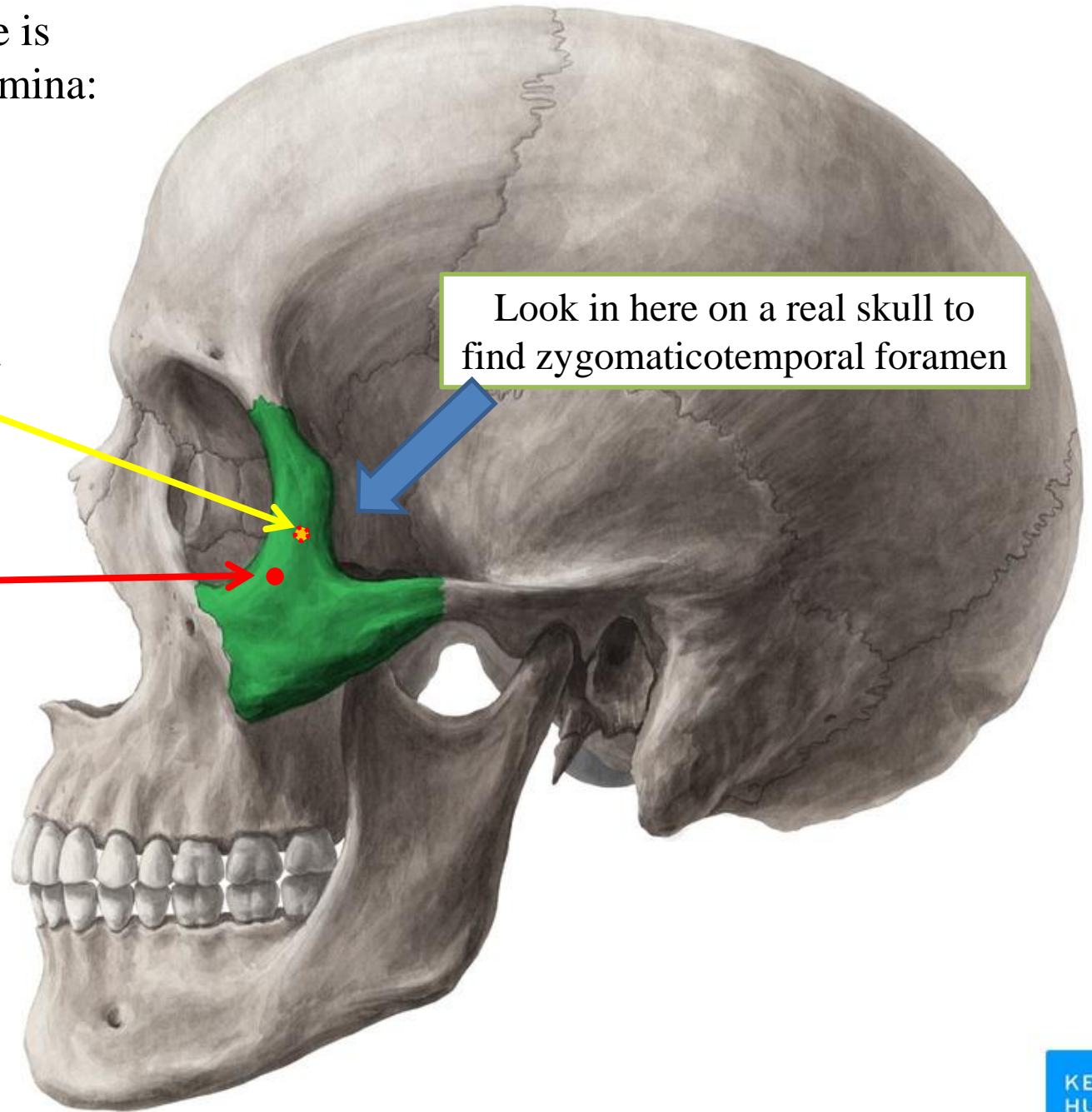


The zygomatic bone is perforated by two foramina:

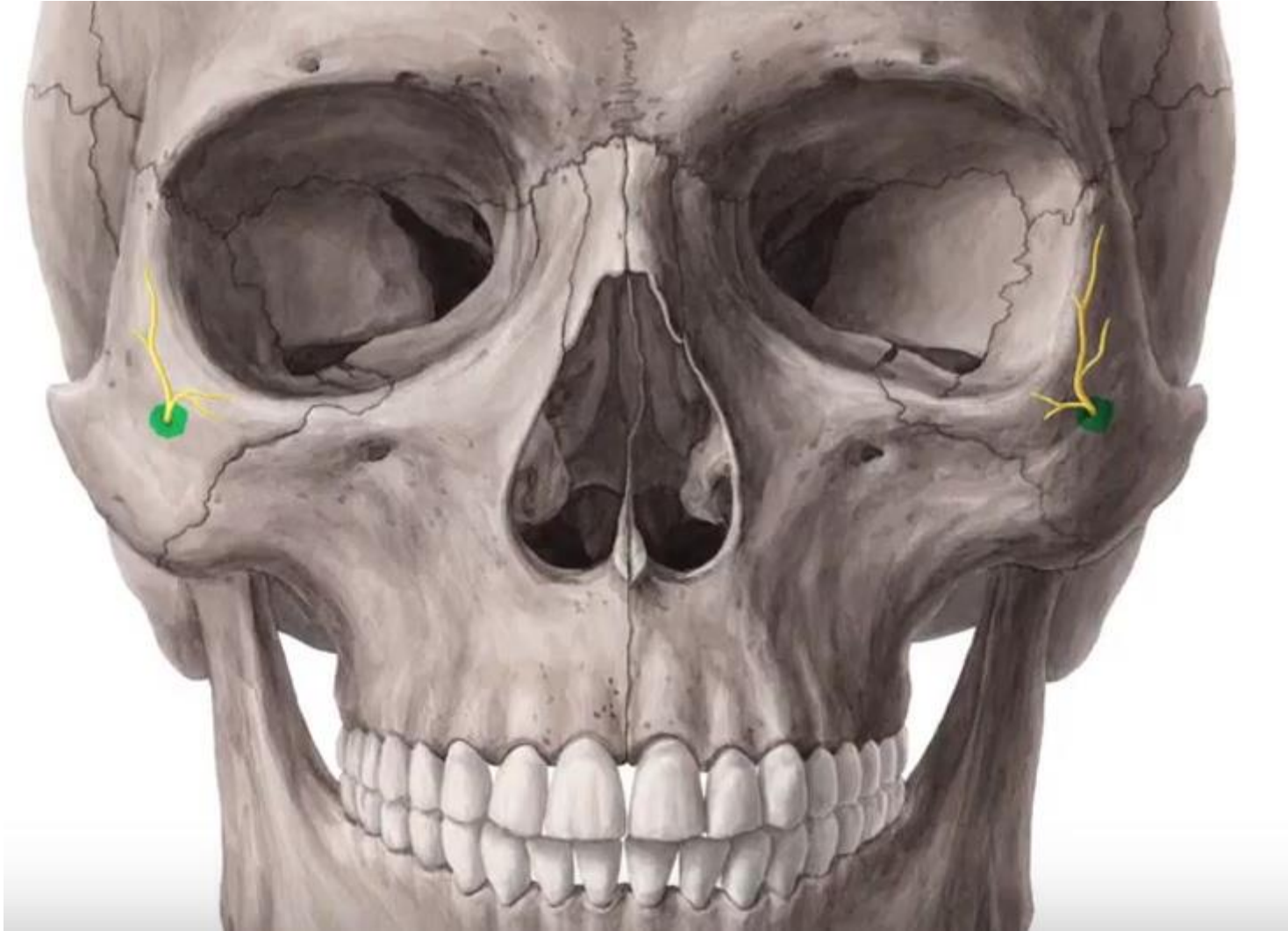Zygomatocotemporal
foramen

Zygomatofacial
foramen

Look in here on a real skull to
find zygomatocotemporal foramen



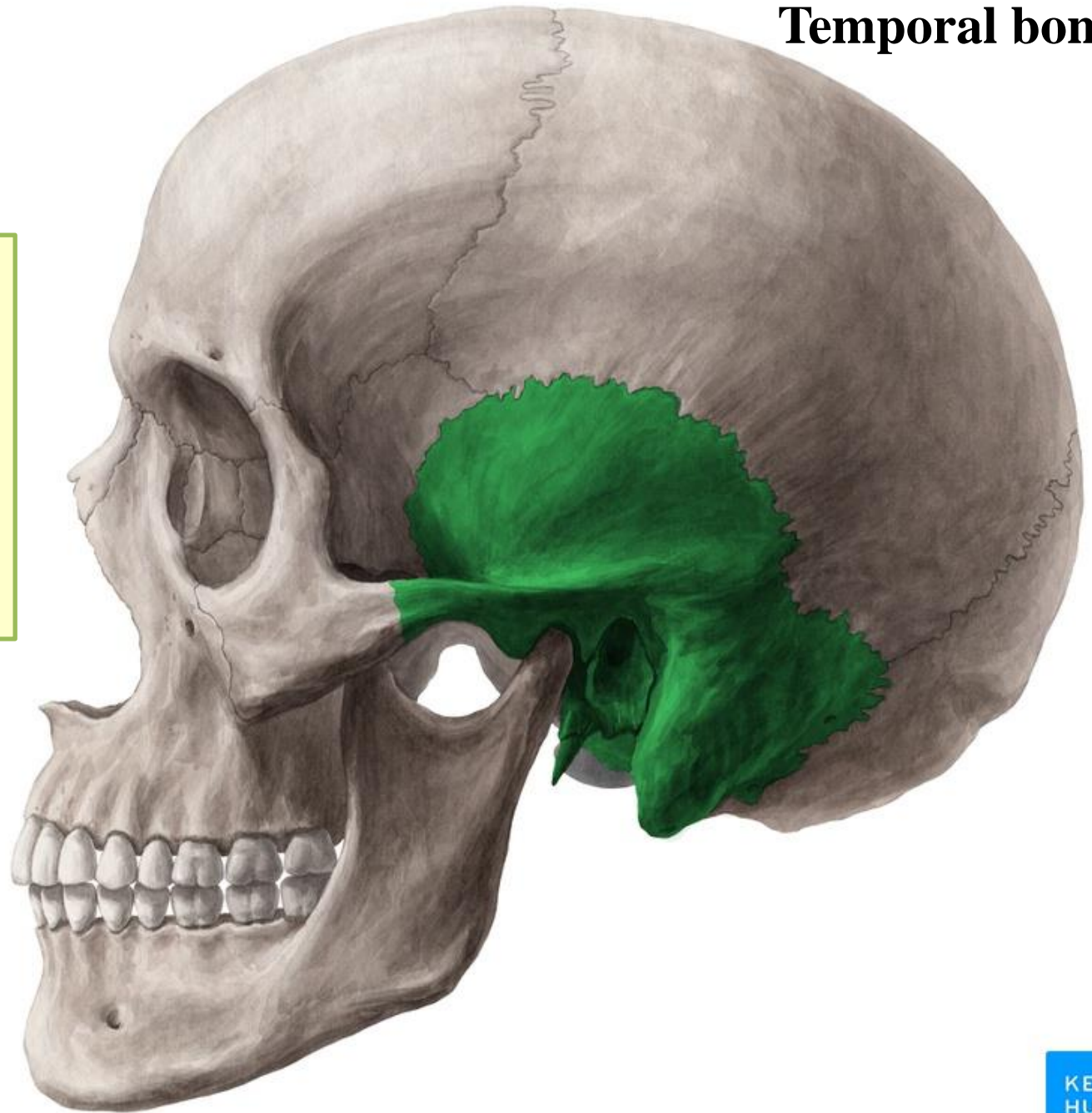
Zygomatofacial foramen transmits Zygomatofacial nerve and vessels



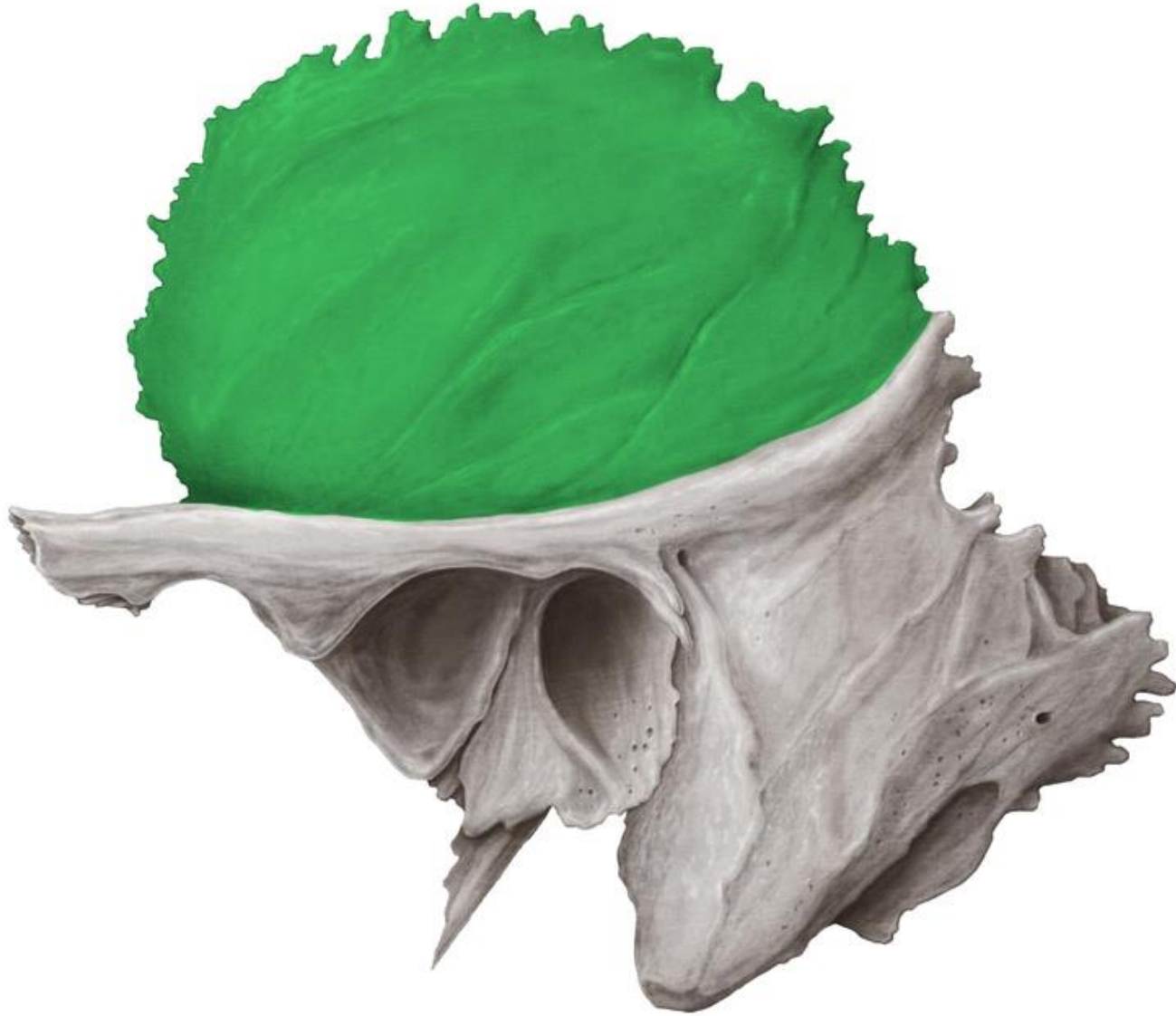Temporal bone

Parts of temporal bone:

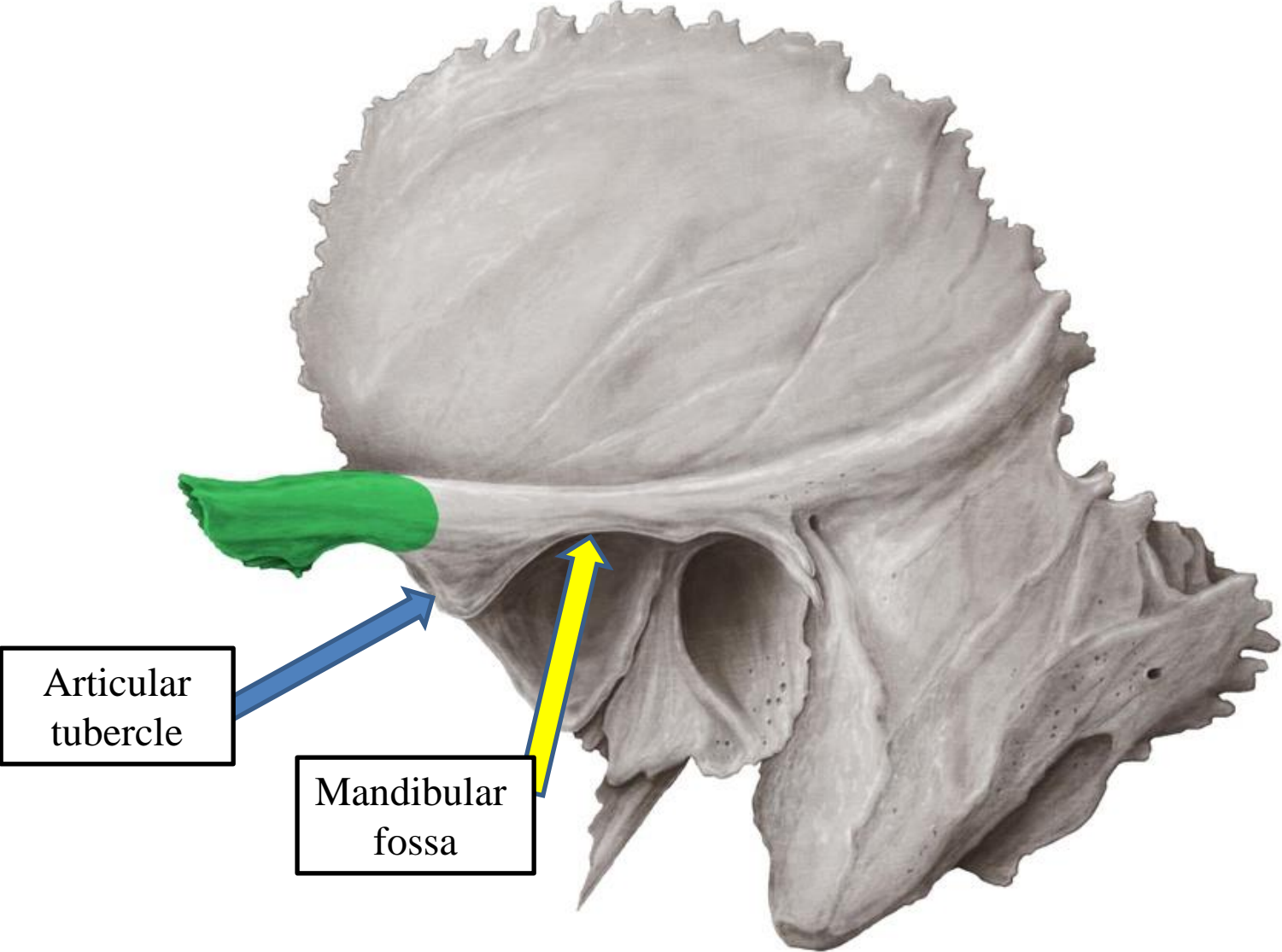
- Squamous part
- Tympanic part
- Mastoid process
- Styloid process
- Zygomatic process
- Petrous part



Squamous part of temporal bone



Zygomatic process of temporal bone

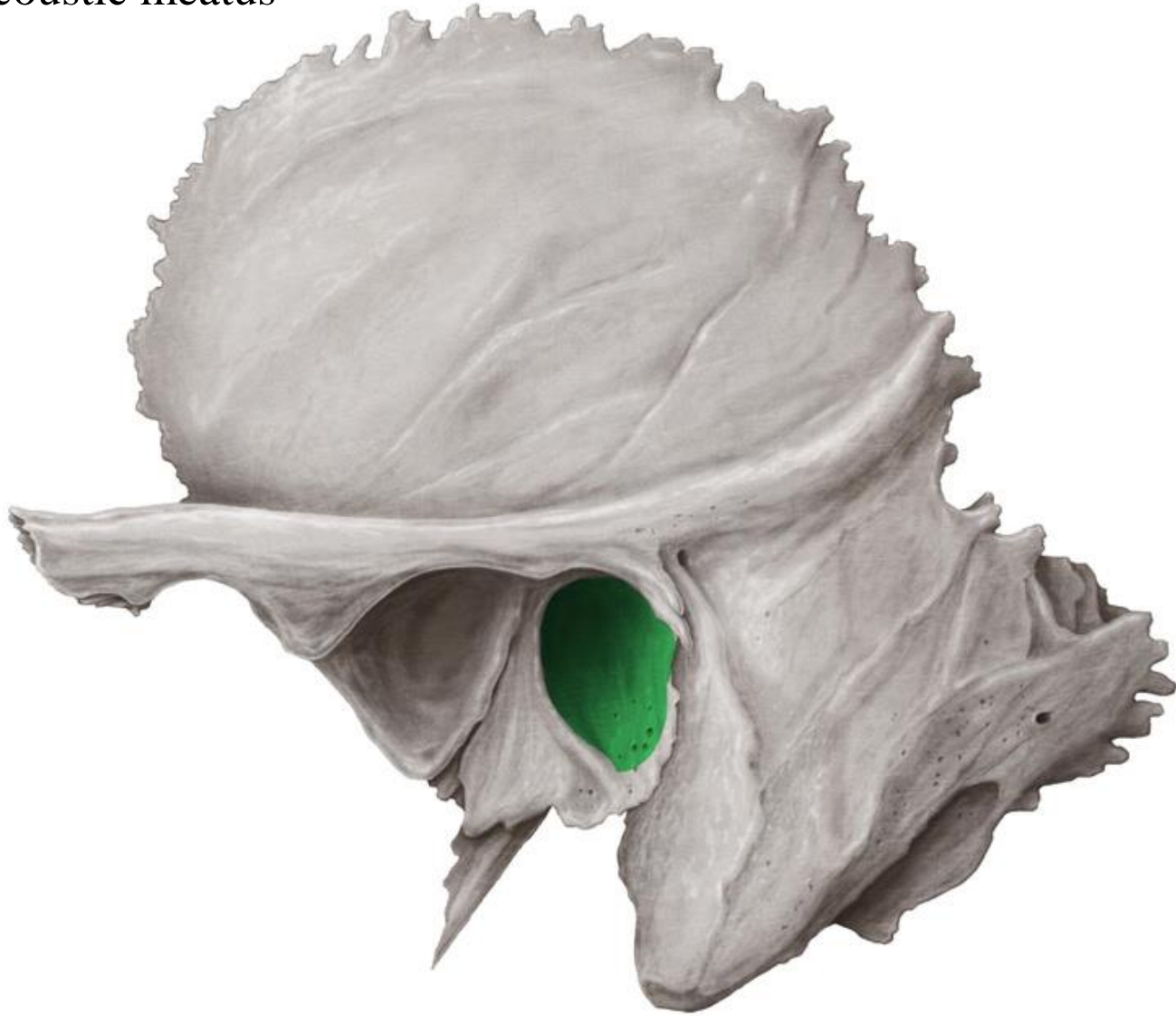

Articular tubercle

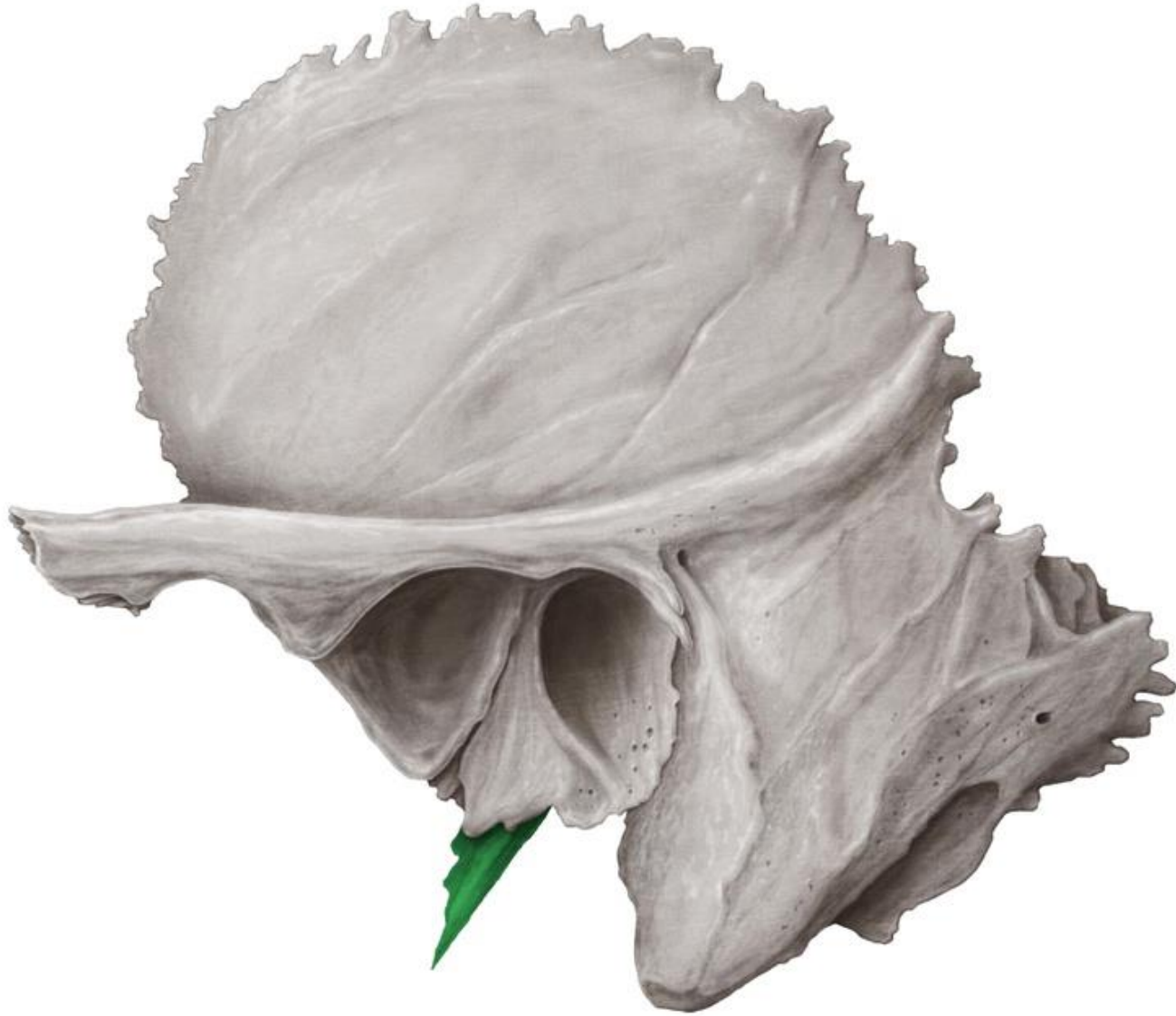Mandibular fossa

Tympanic part of temporal bone

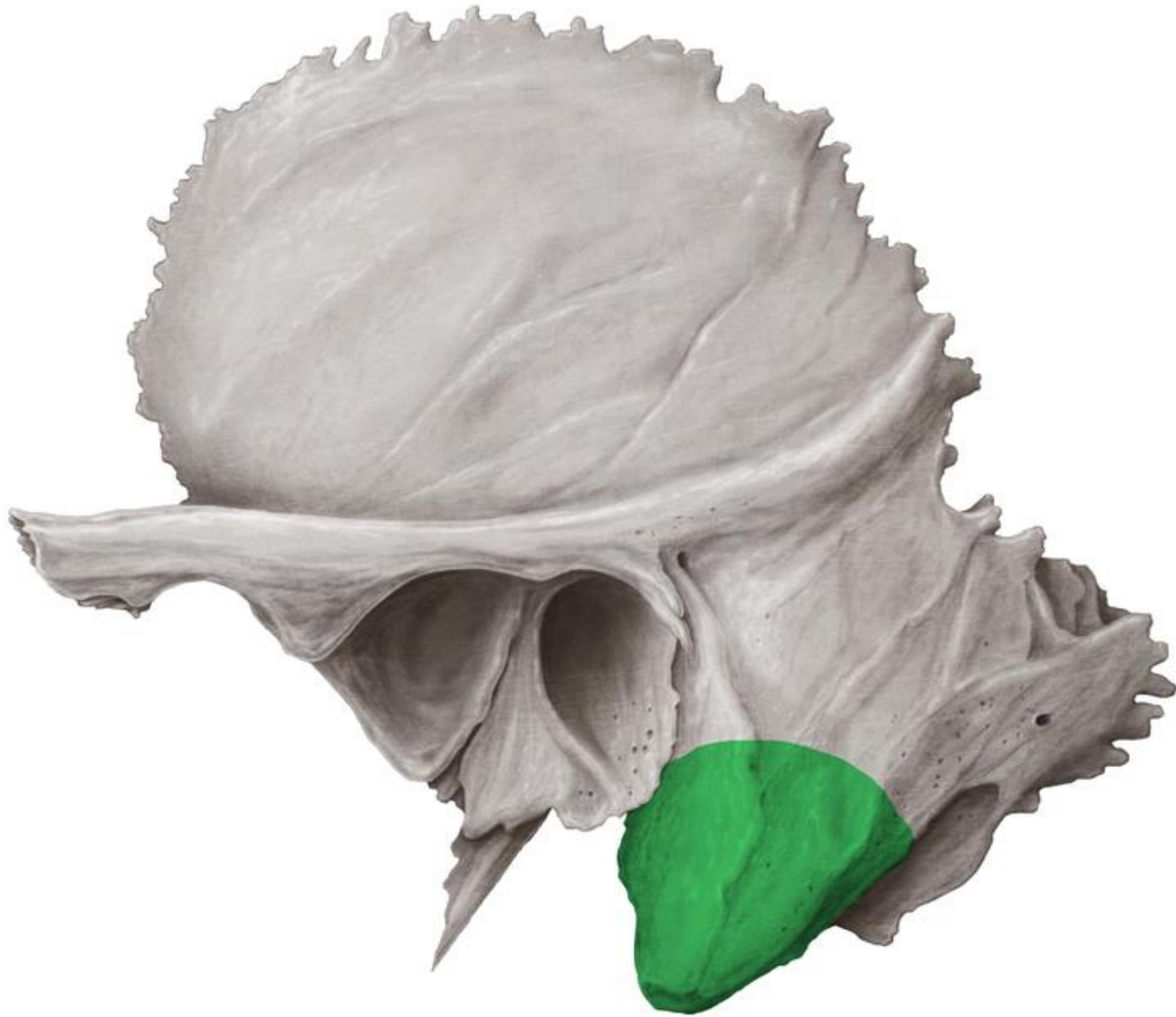External acoustic meatus



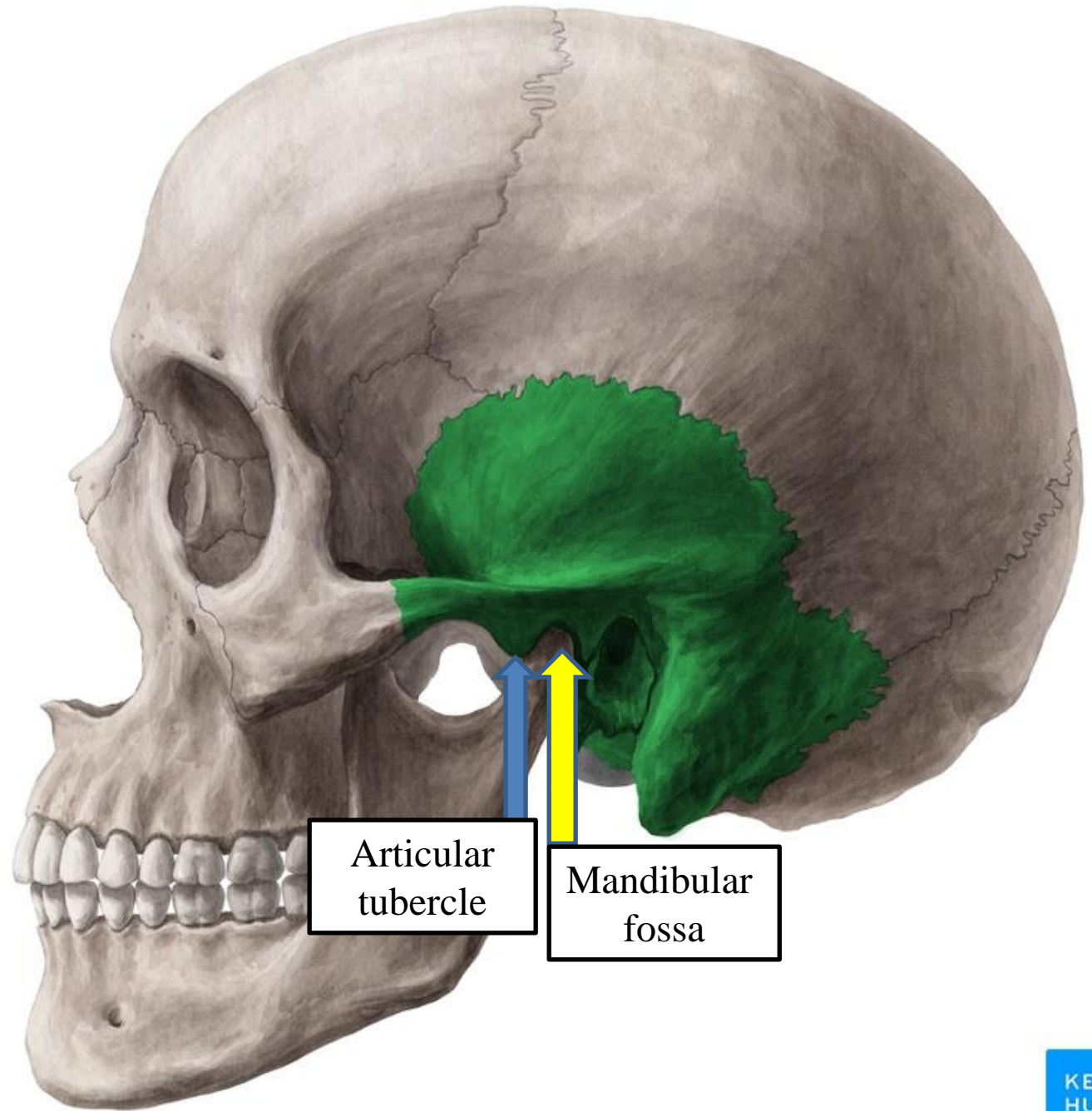
Styloid process of temporal bone



Mastoid process of temporal bone



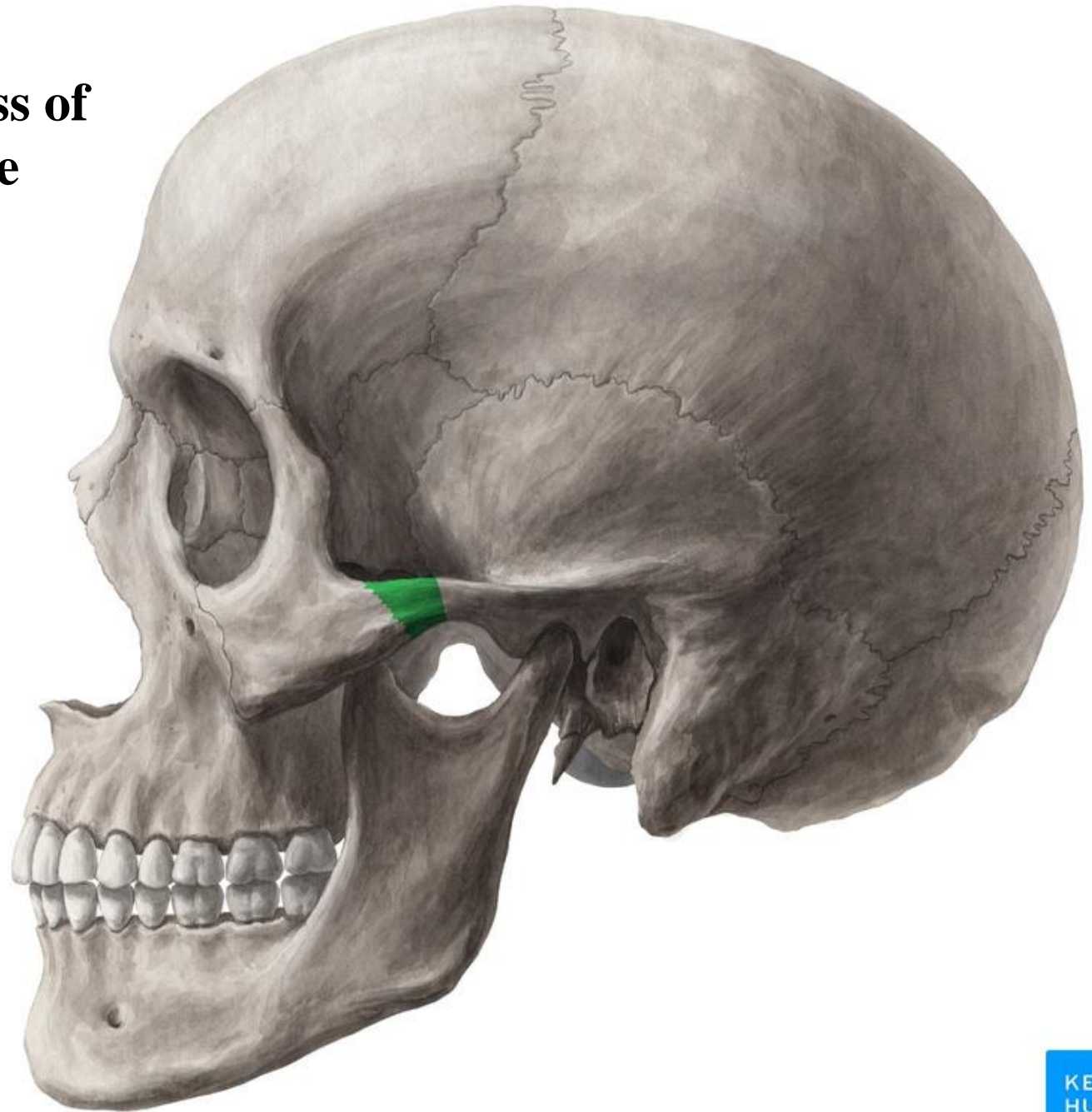
Temporal bone



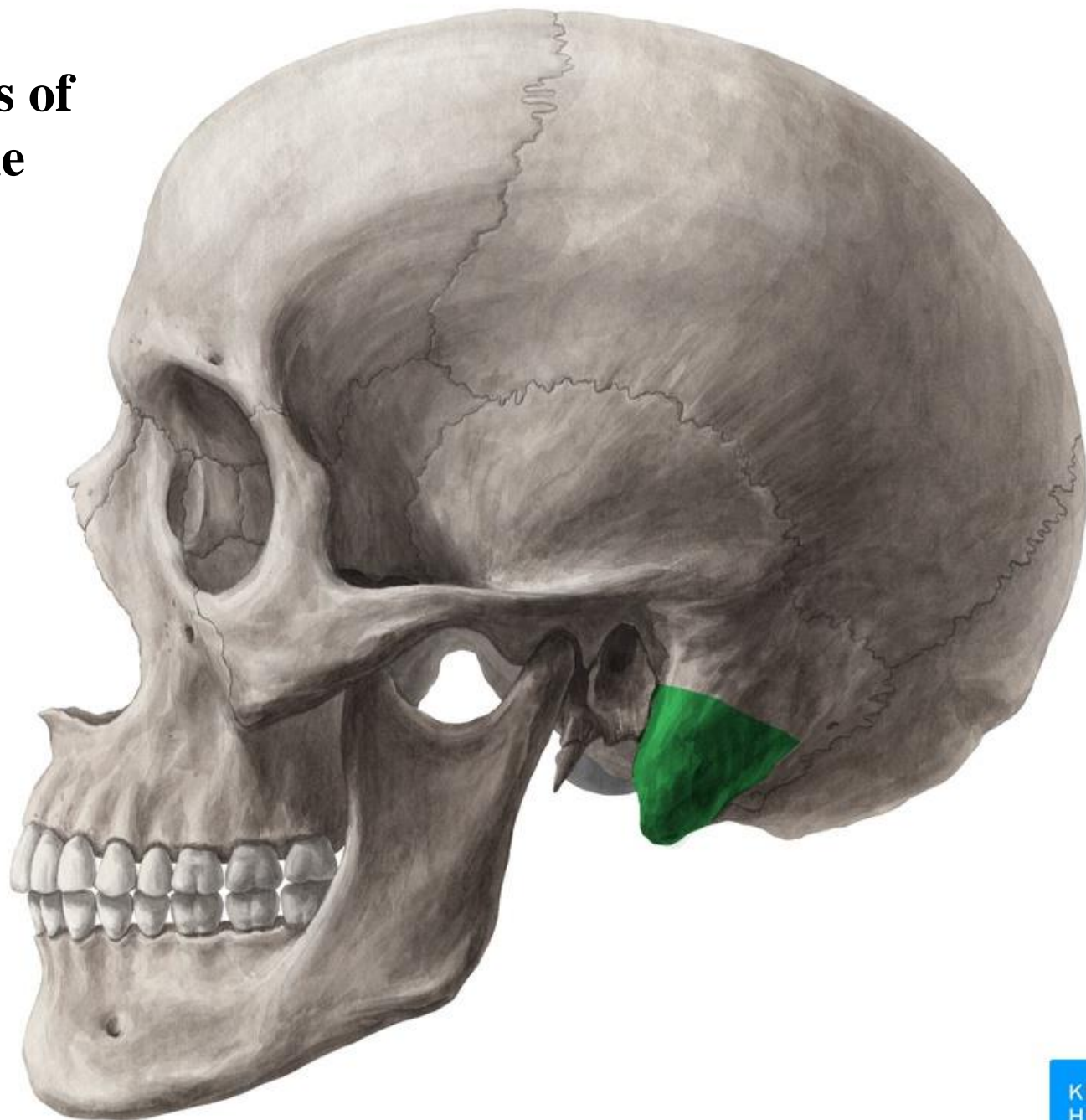
Articular
tubercle

Mandibular
fossa

Zygomatic process of temporal bone

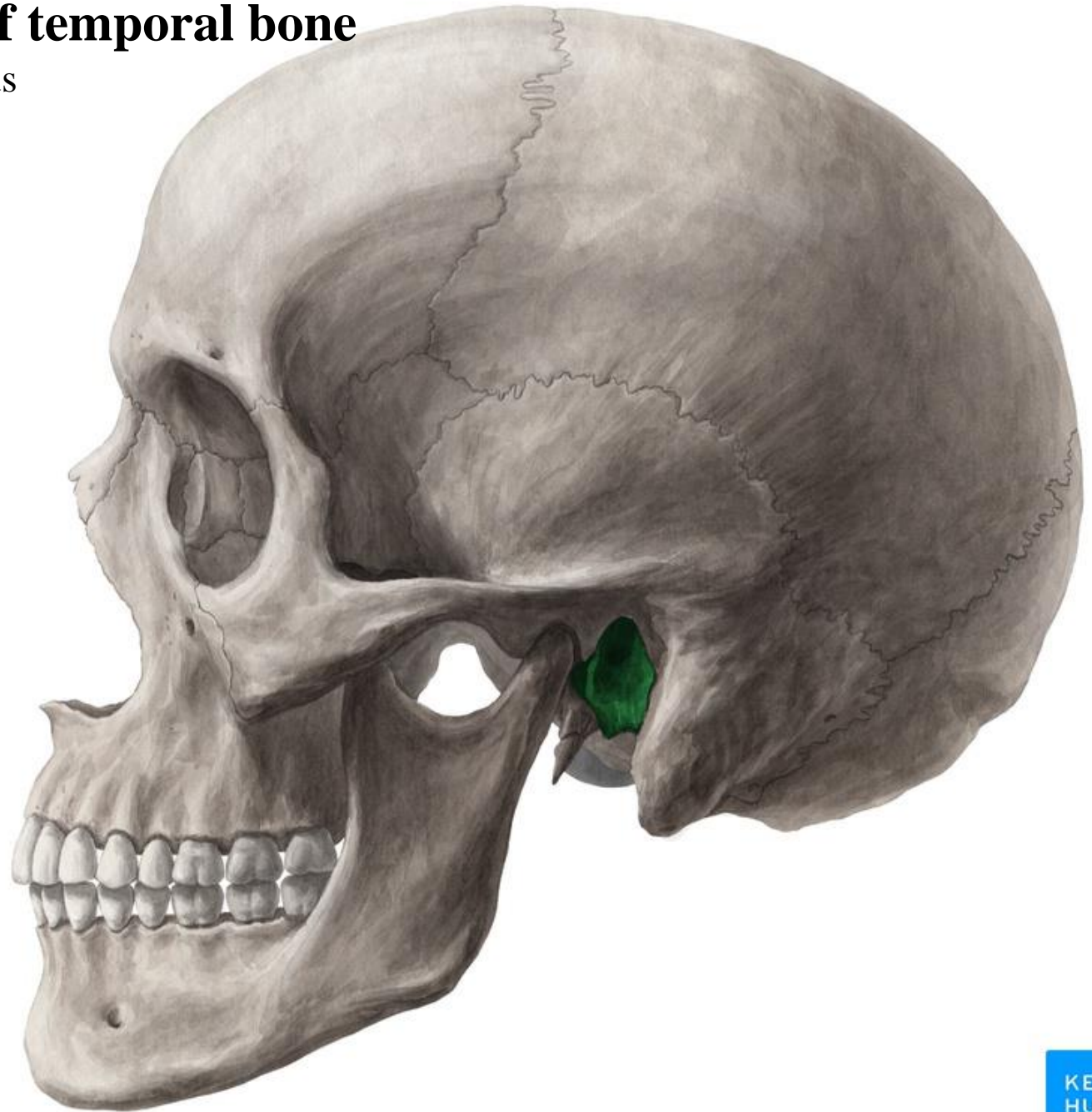


Mastoid process of temporal bone

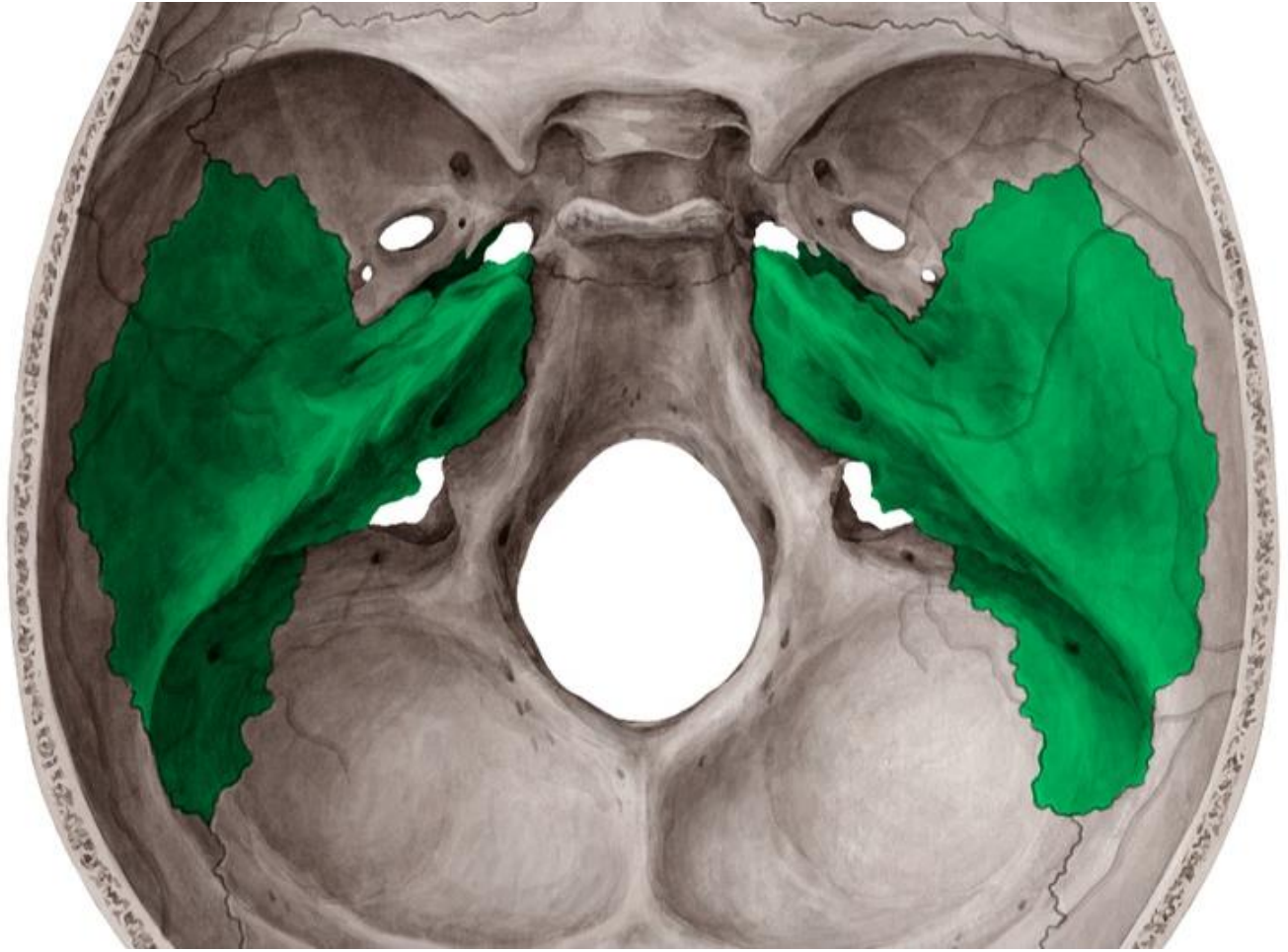

Tympanic part of temporal bone

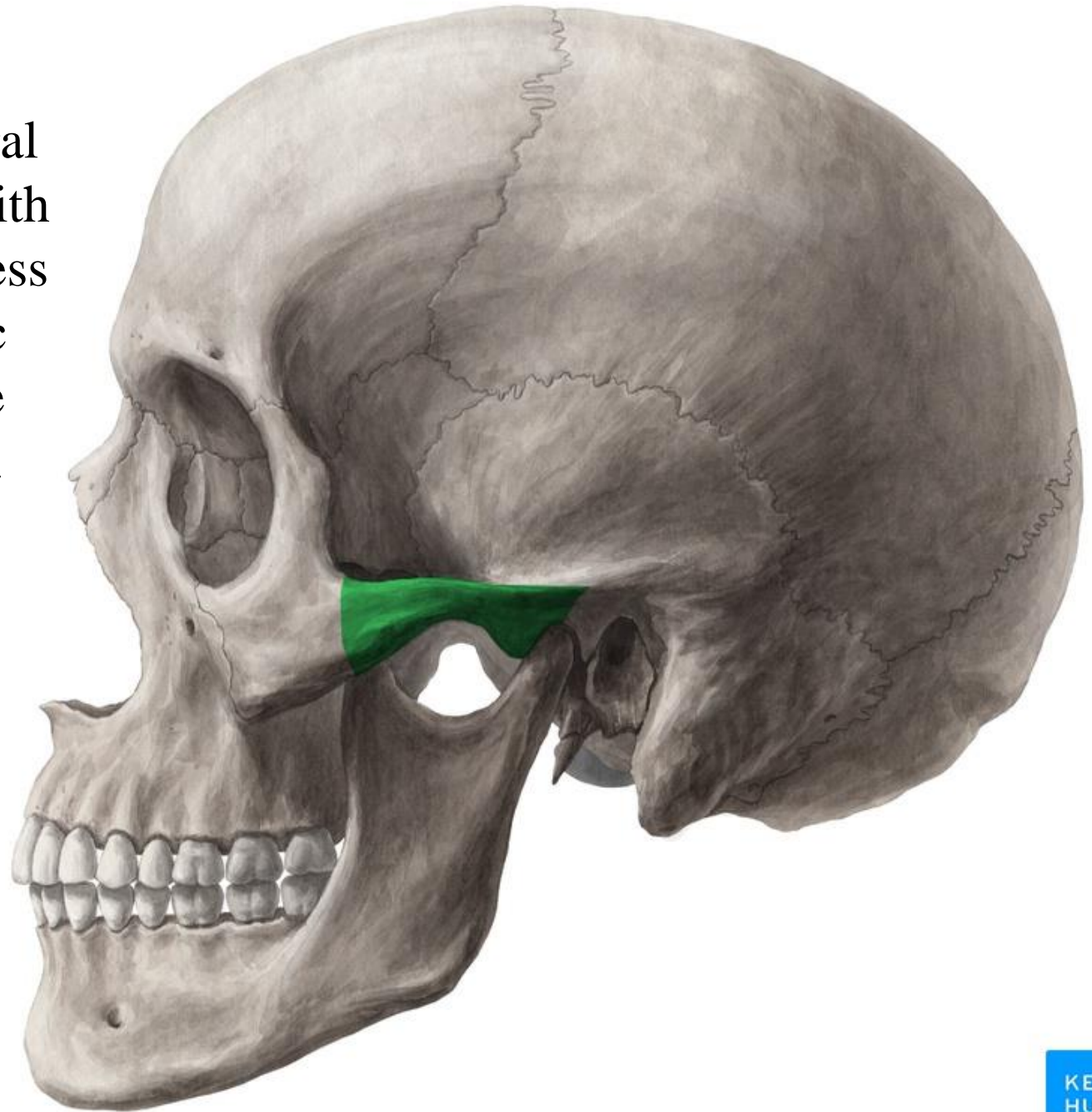
External acoustic meatus



Squamous and petrous parts of the temporal bone

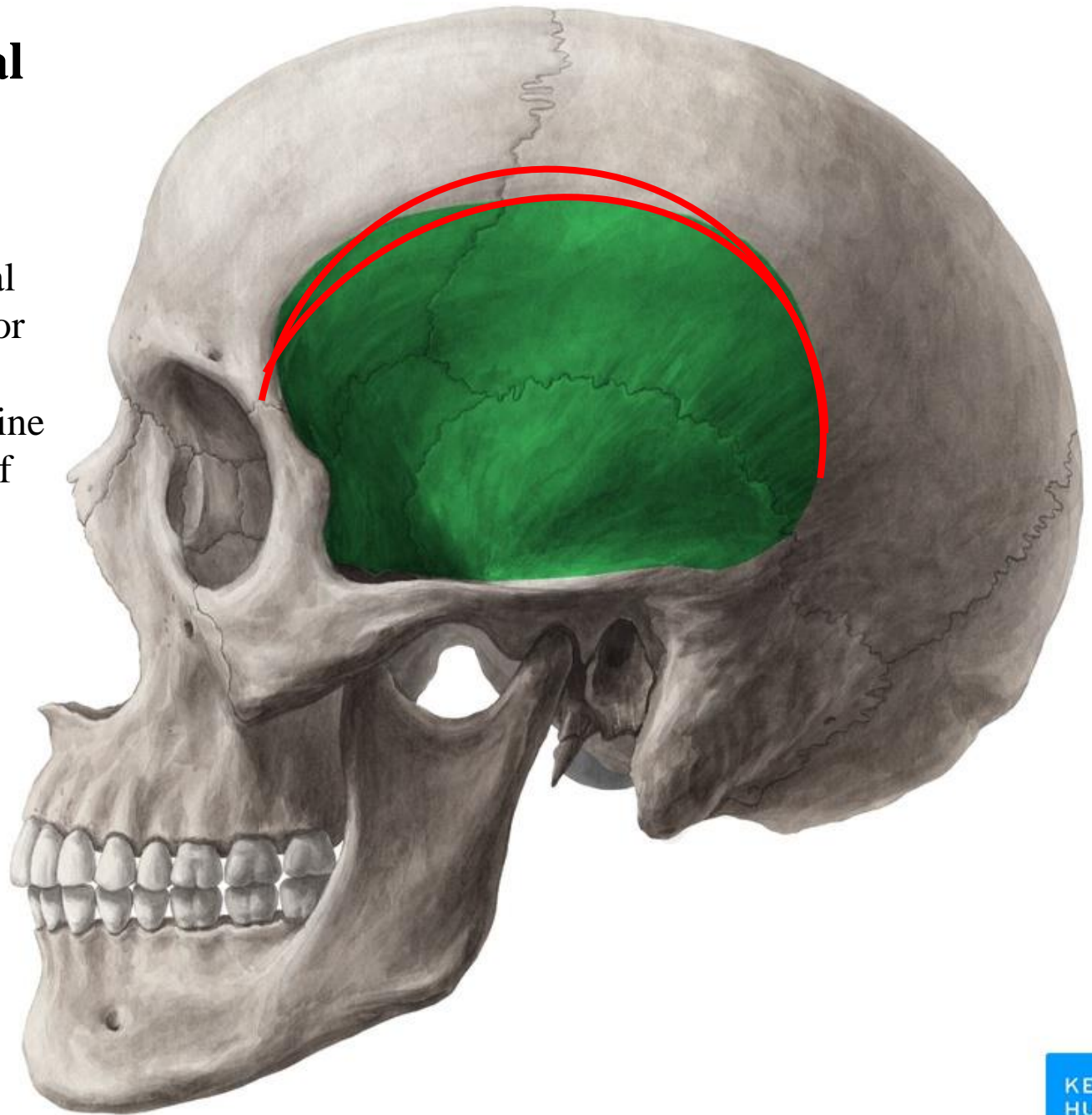
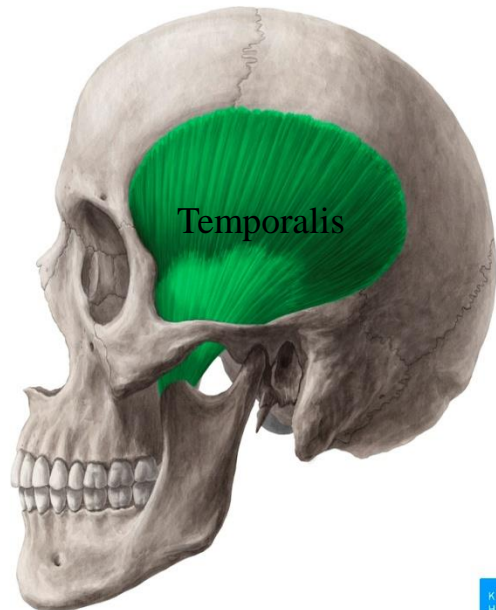


The zygomatic process of temporal bone articulates with the temporal process of the zygomatic bone to form the **zygomatic arch**



Superior and inferior temporal lines:

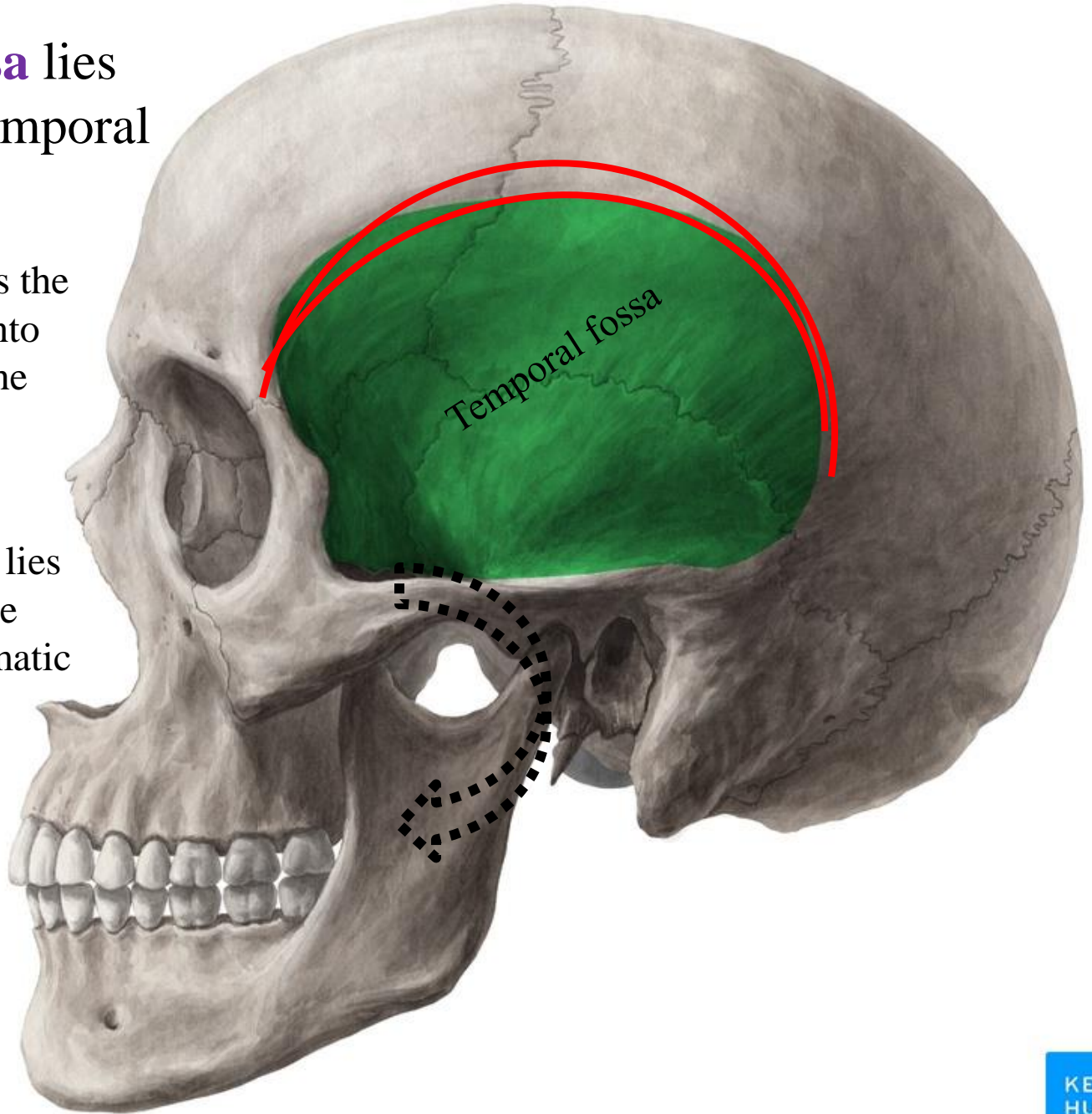
- The superior temporal line gives attachment for the temporal fascia
- The inferior temporal line is for the attachment of temporalis muscle



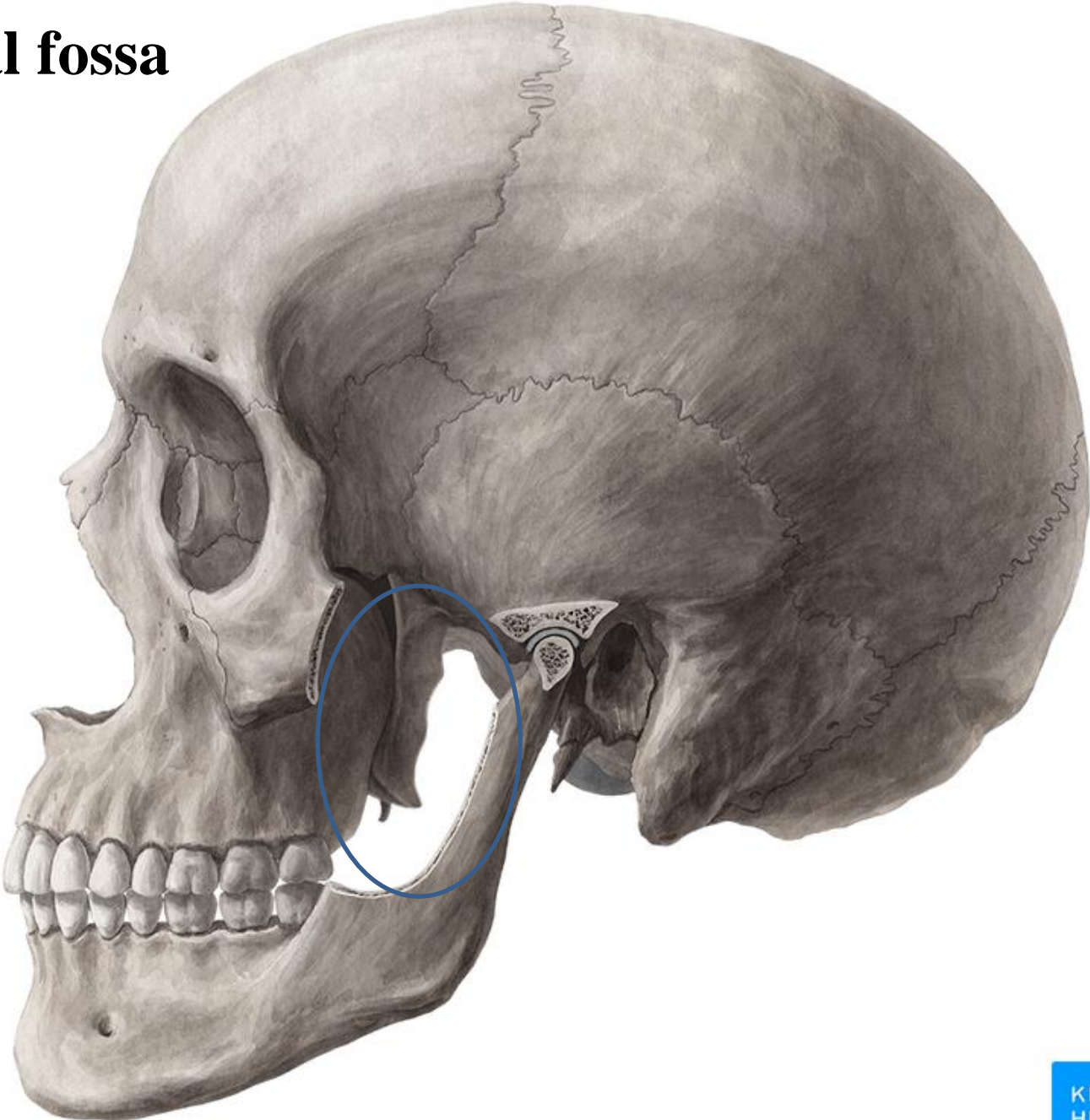
The **temporal fossa** lies below the inferior temporal line

The zygomatic arch divides the lateral side of the Skull into The temporal fossa & The infratemporal fossa

The **infratemporal fossa** lies deep to the ramus of the mandible below the zygomatic arch

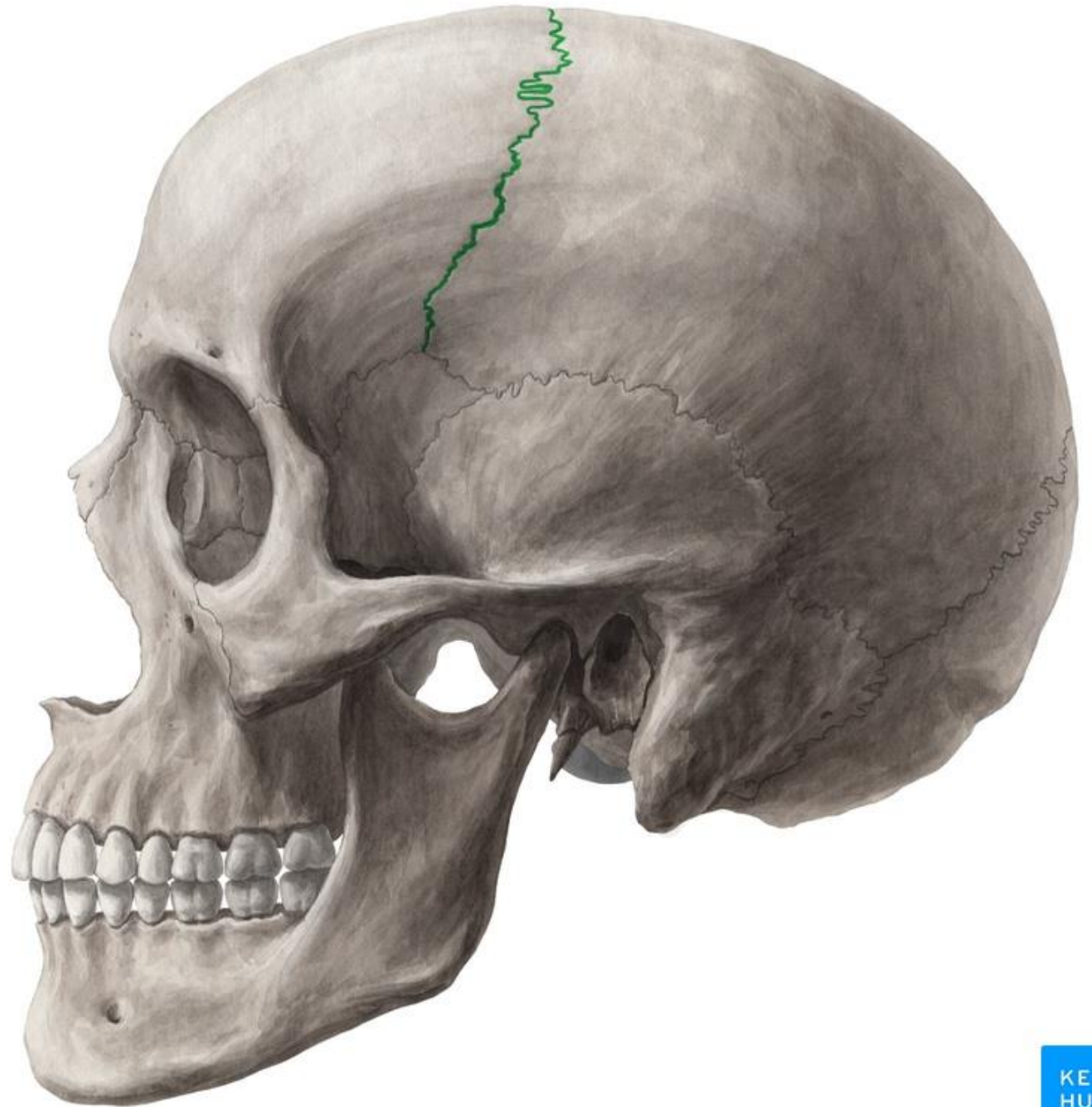


Infra-temporal fossa

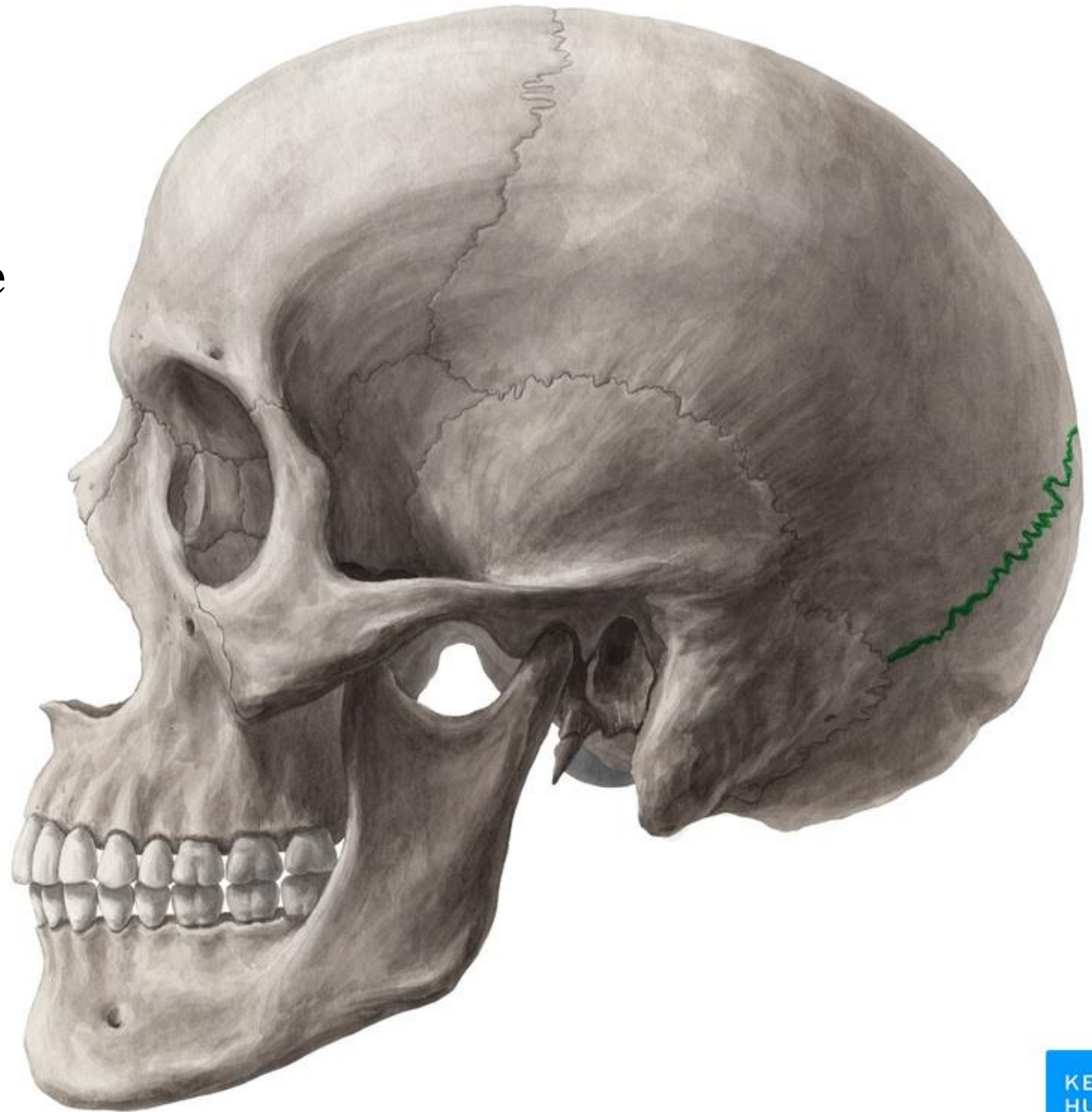


Identify

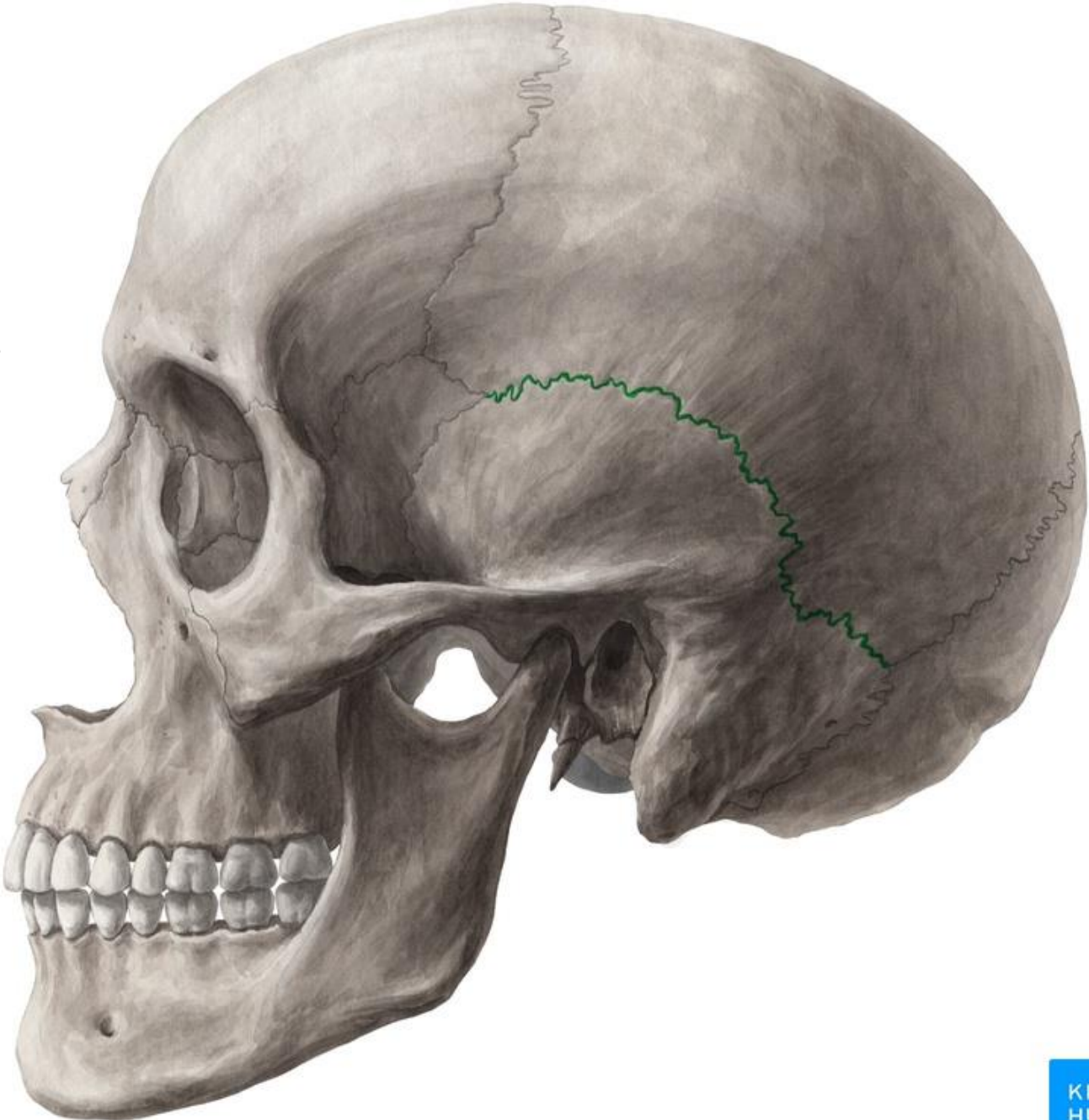
Coronal suture



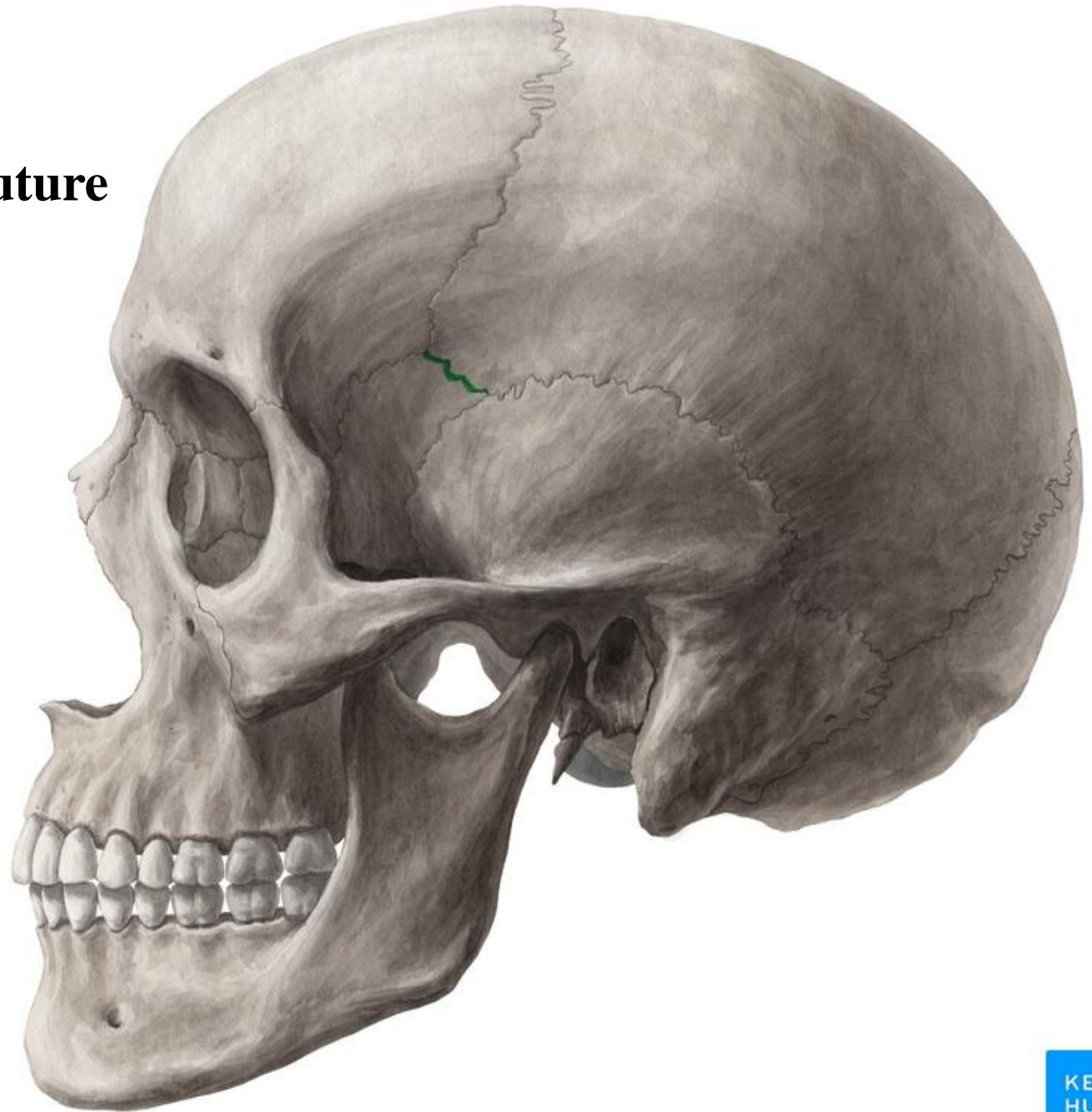
Lambdoid suture



**Parieto-temporal
suture (squamous
suture)**



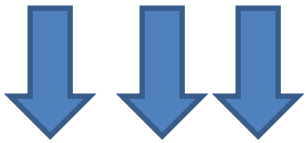
Sphenoparietal suture



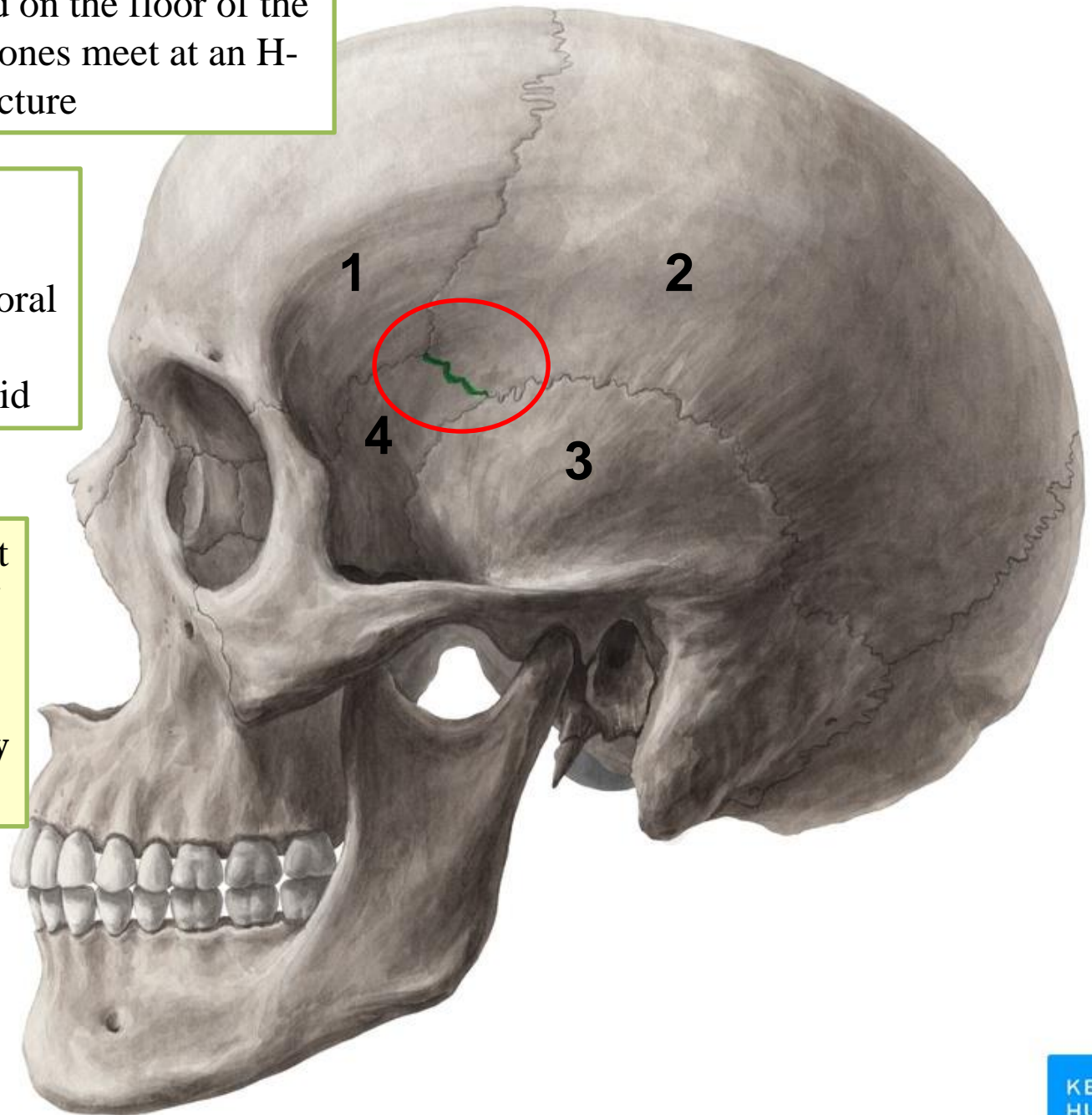
Pterion: is an area located on the floor of the temporal fossa where 4 bones meet at an H-shaped structure

- 1- Frontal
- 2- Parietal
- 3-Squamous part of temporal bone
- 4-Greater wing of sphenoid

The pterion is the thinnest part of the lateral wall of the skull. It overlies the anterior division of the **middle meningeal artery** and vein



Epidural bleeding



The **Superior orbital fissure** is a fissure between the greater and lesser wings of the sphenoid bone . It leads forward into the orbit

The **Inferior orbital fissure** is a fissure between the greater wing of the sphenoid bone and the maxilla. It leads forward into the orbit

