

Abdominal wall



Borders of the Abdomen

- Abdomen is the region of the trunk that lies between the diaphragm above and the inlet of the pelvis below
- Borders

Superior:

Costal cartilages 7-12.

Xiphoid process:

• Inferior:

Pubic bone and iliac crest:

Level of L4.

• Umbilicus:

Level of IV disc L3-L4

Abdominal Quadrants

Formed by two intersecting lines:

Vertical & Horizontal
Intersect at umbilicus.

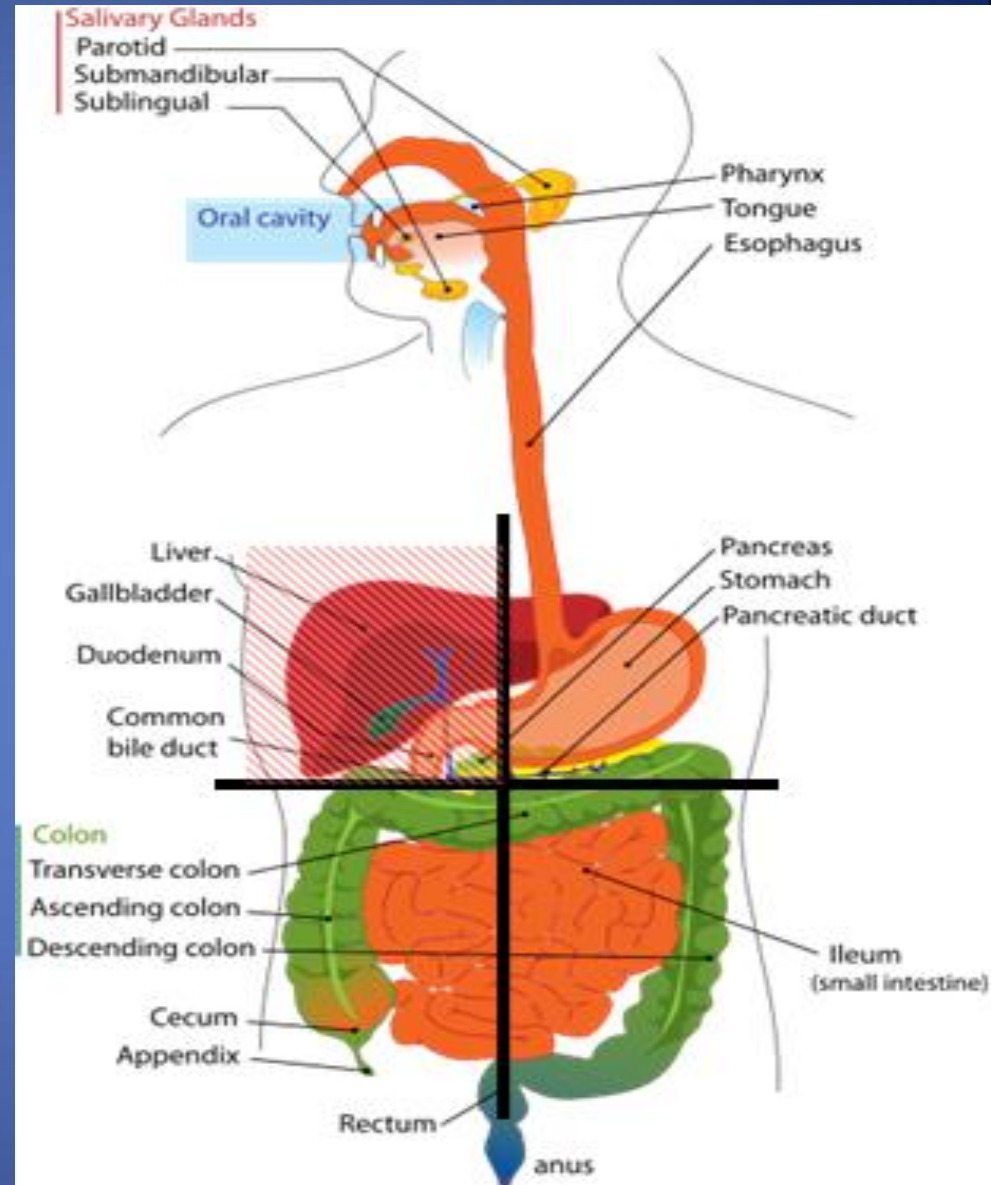
Quadrants:

Upper left.

Upper right.

Lower left.

Lower right



Abdominal Regions

Divided into 9 regions by two pairs of planes:

1- Vertical Planes:

- Left and right lateral planes
- Midclavicular planes
- passes through the midpoint between the ant.sup.ilic spine and symphysis pupis

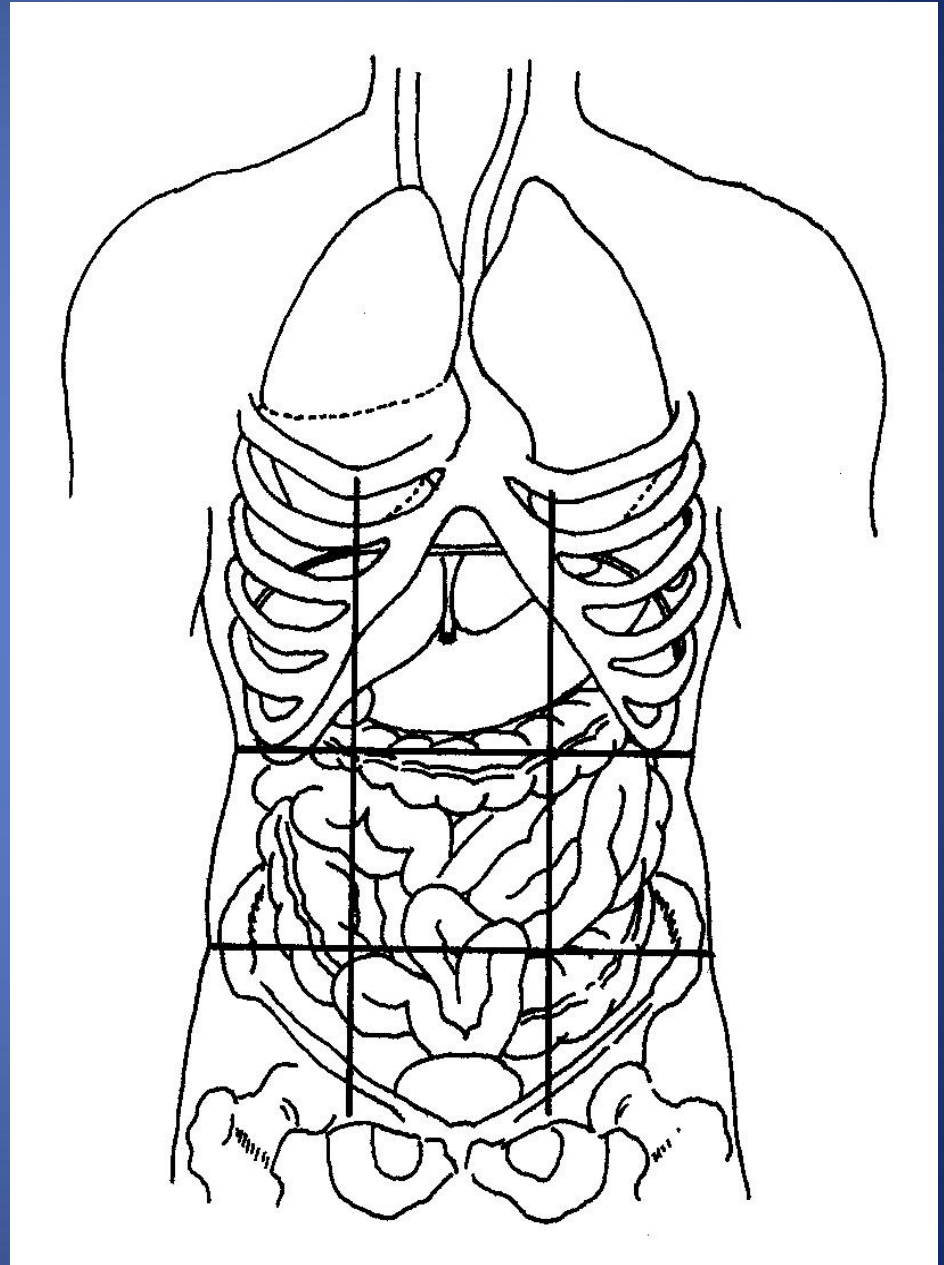
2- Horizontal Planes:

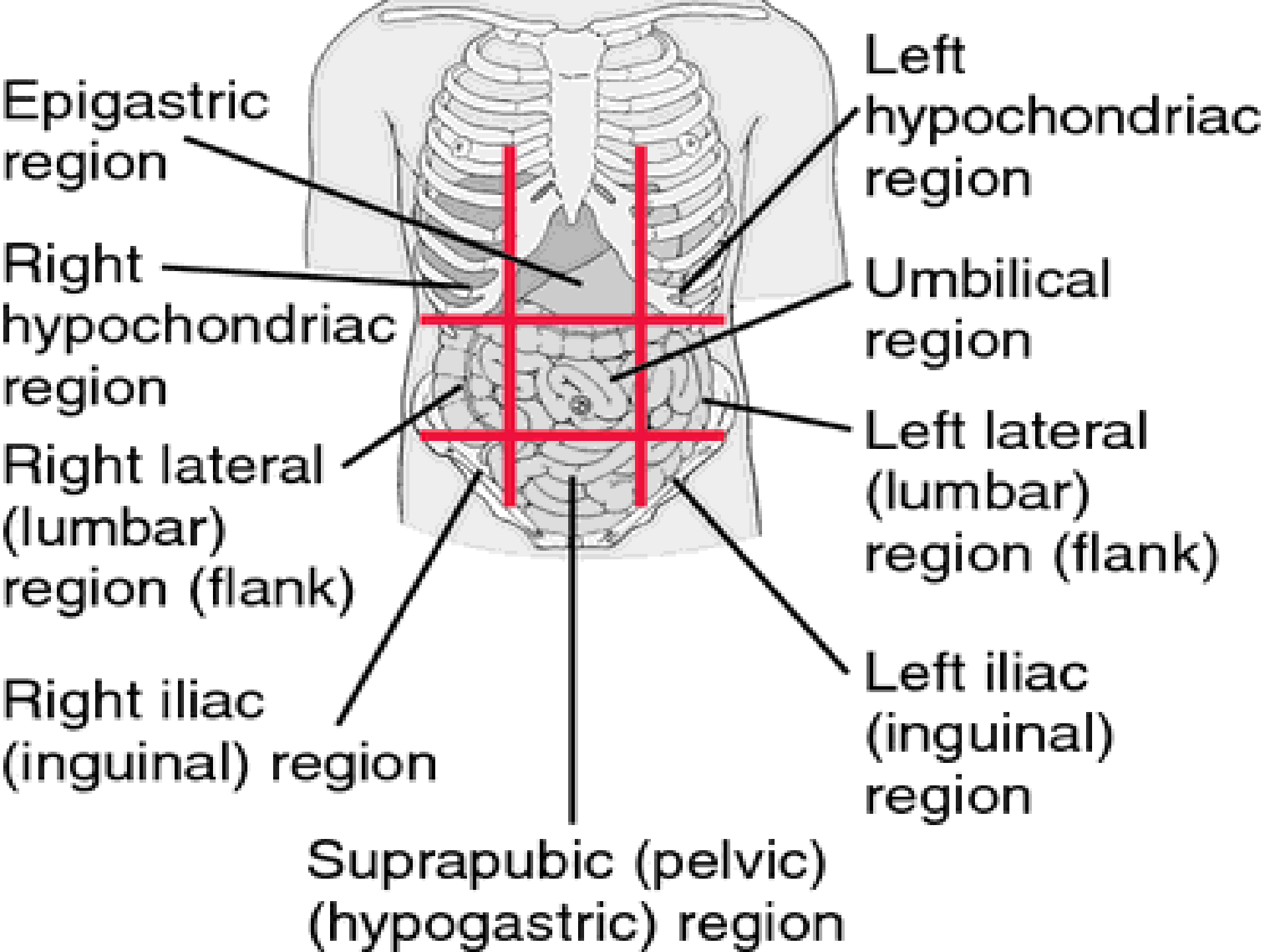
-Subcostal plane

- at level of L3 vertebra
- Joins the lower end of costal cartilage on each side

-Intertubercular plane:

- At the level of L5 vertebra
- Through tubercles of iliac crests.





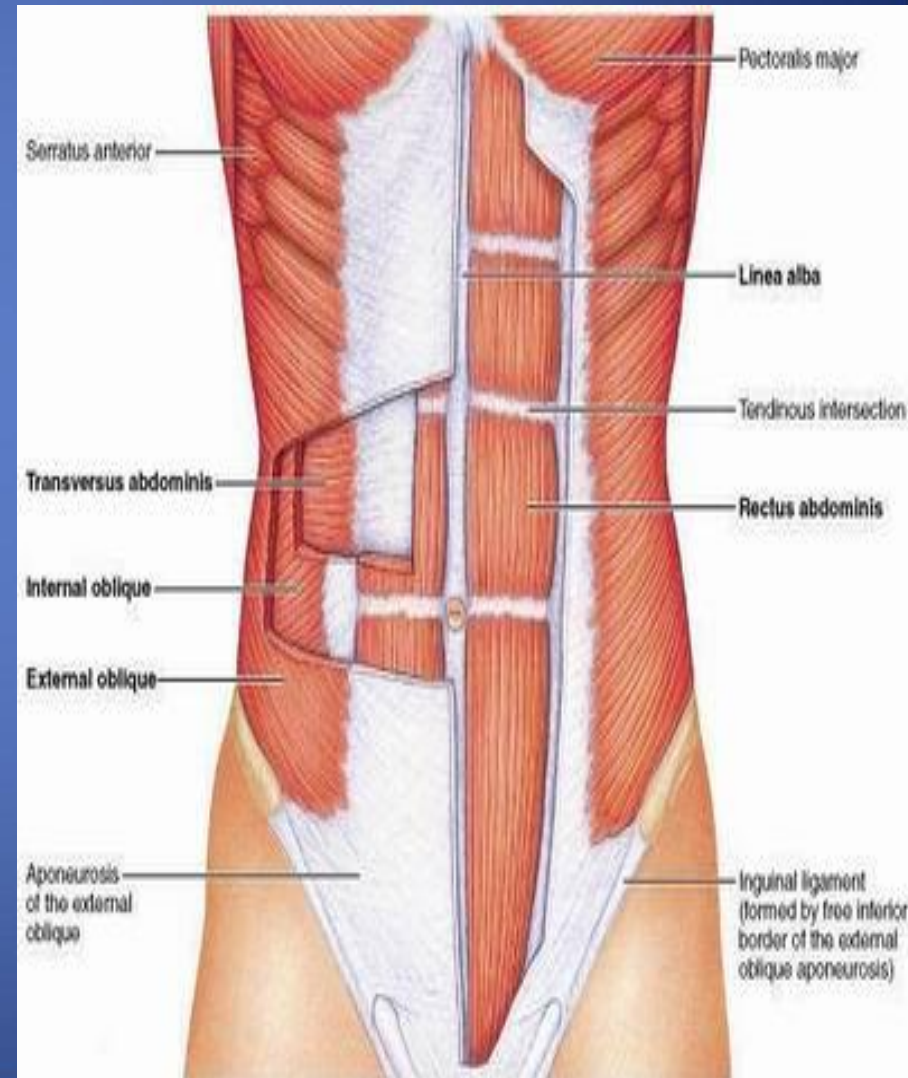
Abdominal wall divided into:-

 **Anterior abdominal wall**

 **Posterior abdominal wall**

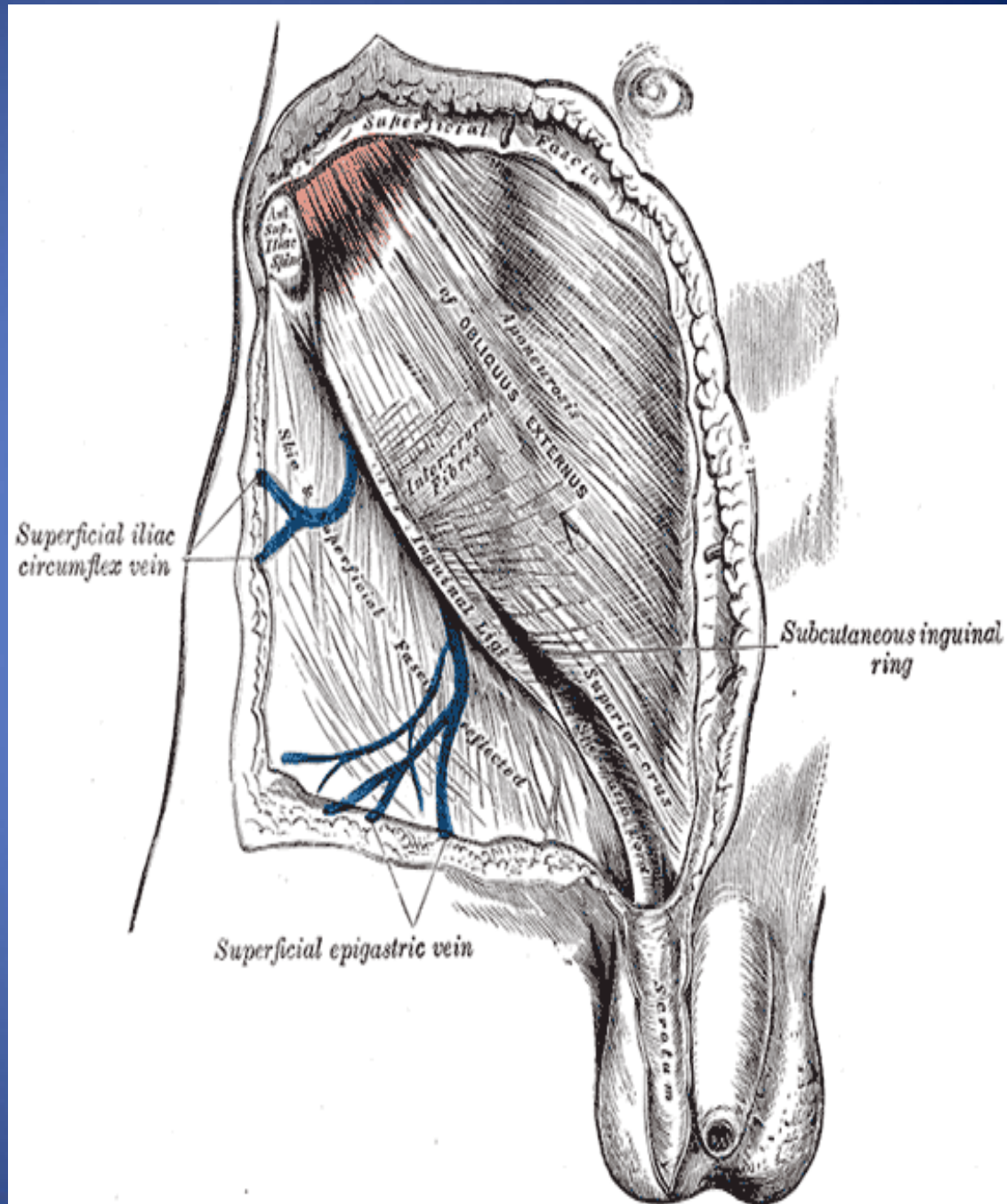
What are the Layers of Anterior Abdominal Wall

- ✓ **Skin**
- ✓ **Superficial Fascia**
 - Above the umbilicus one layer
 - Below the umbilicus two layers
 - Camper's fascia - fatty superficial layer.
 - Scarp's fascia - deep membranous layer.
- ✓ **Deep fascia :**
 - Thin layer of C.T covering the muscle may absent
- ✓ **Muscular layer**
 - External oblique muscle
 - Internal oblique muscle
 - Transverse abdominal muscle
 - Rectus abdominis
- ✓ **Transversalis fascia**
- ✓ **Extraperitoneal fascia**
- ✓ **Parietal Peritoneum**



Superficial Fascia

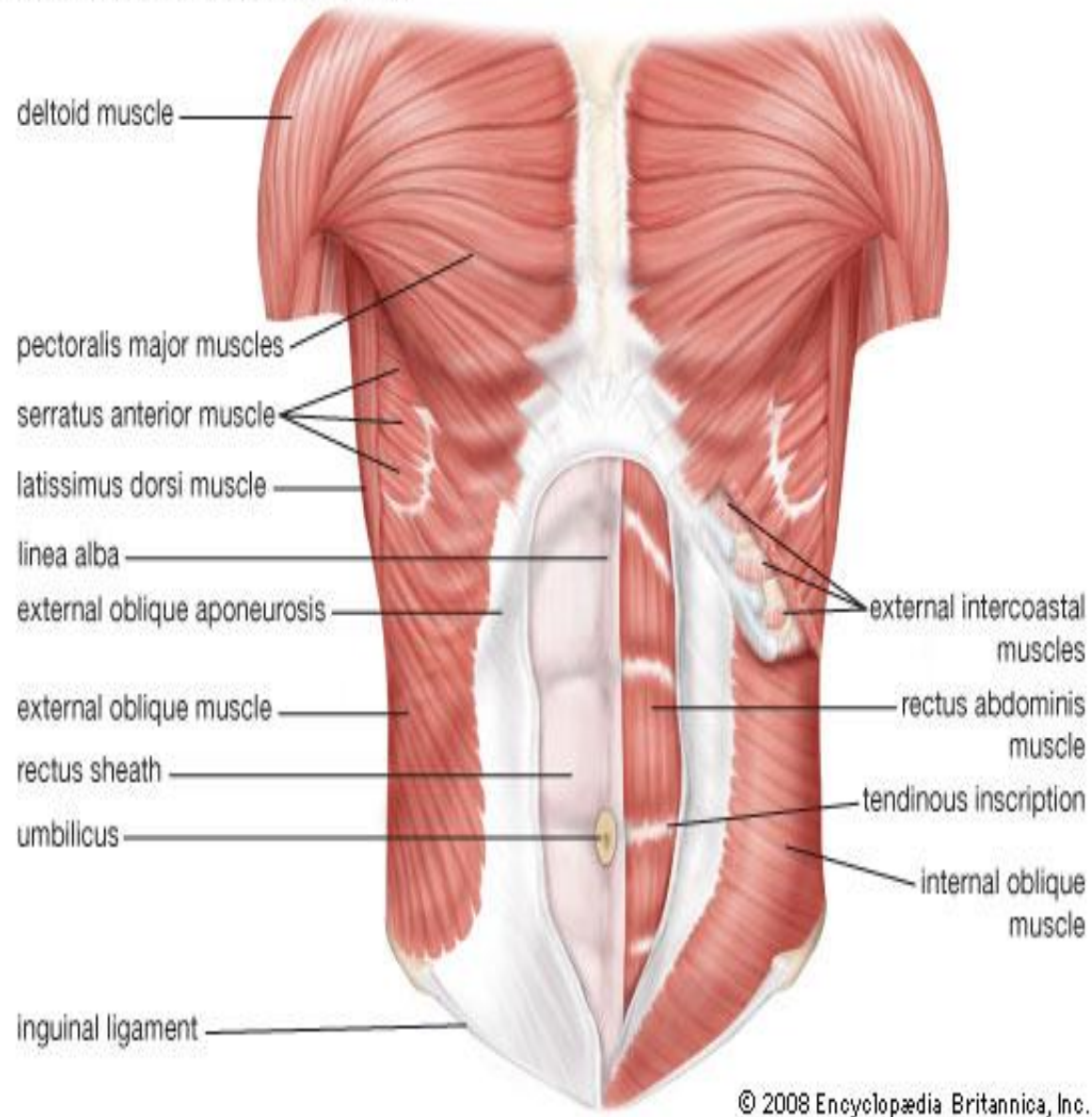
- Camper's fascia – fatty layer= dartos muscle in male
- Scarpa's fascia – membranous layer.
- Attachment of Scarpa's fascia= membranous fascia
 - INF: Fascia lata
 - Sides: Pubic arch
 - Post: Perineal body
- Membranous layer in scrotum referred to as Colles' fascia
- Rupture of penile urethra lead to extravasations of urine into (scrotum, perineum, penis & abdomen)



✓ Muscles

- Rectus abdominis
- External oblique muscle
- Internal oblique muscle
- Transverse abdominal muscle

Muscles of the abdominal wall



External oblique muscle

-Broad

-Thin

✓ Direction:

Downward forward medially

✓ Origin

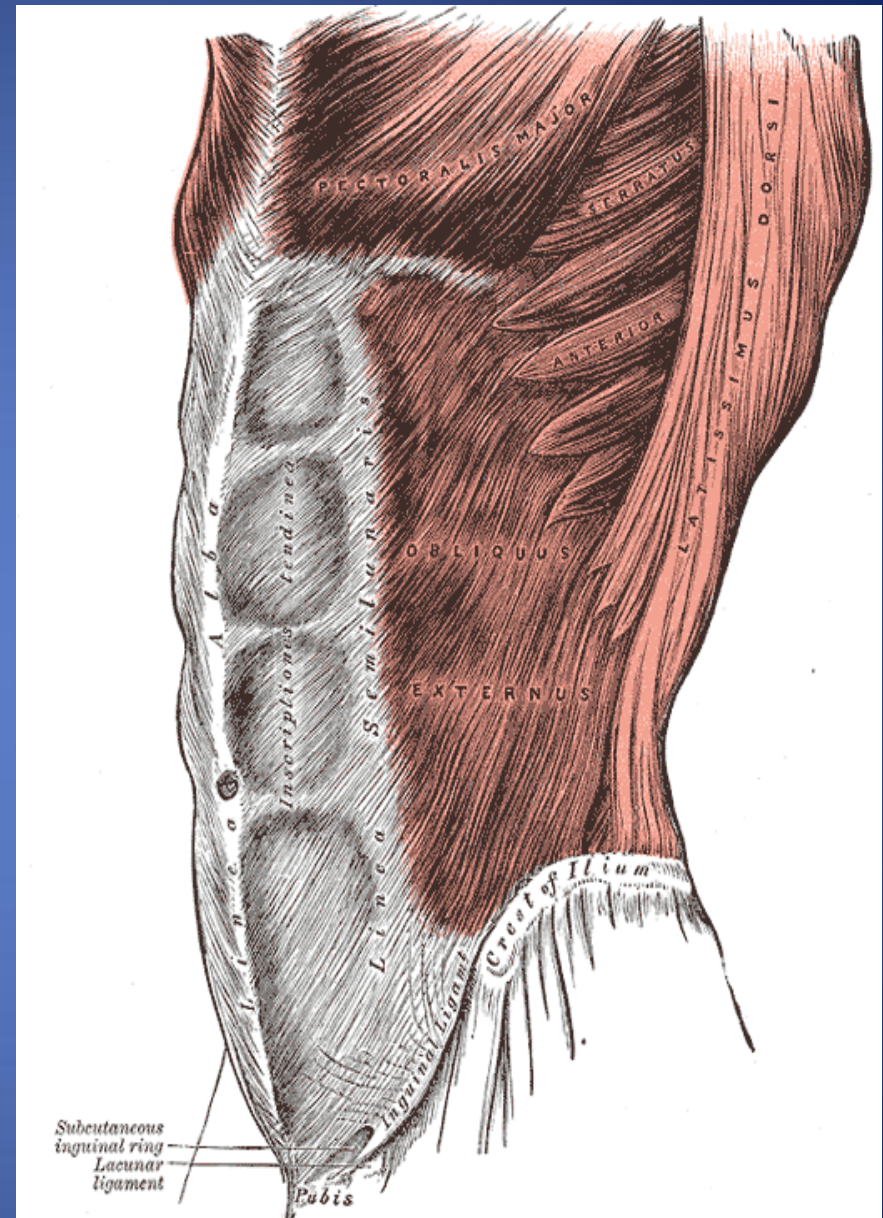
outer surface of lower 8 ribs.

✓ Insertion

Xiphoid process, Linea alba,
pubic crest, pubic tubercle,
iliac crest(ant. Half).

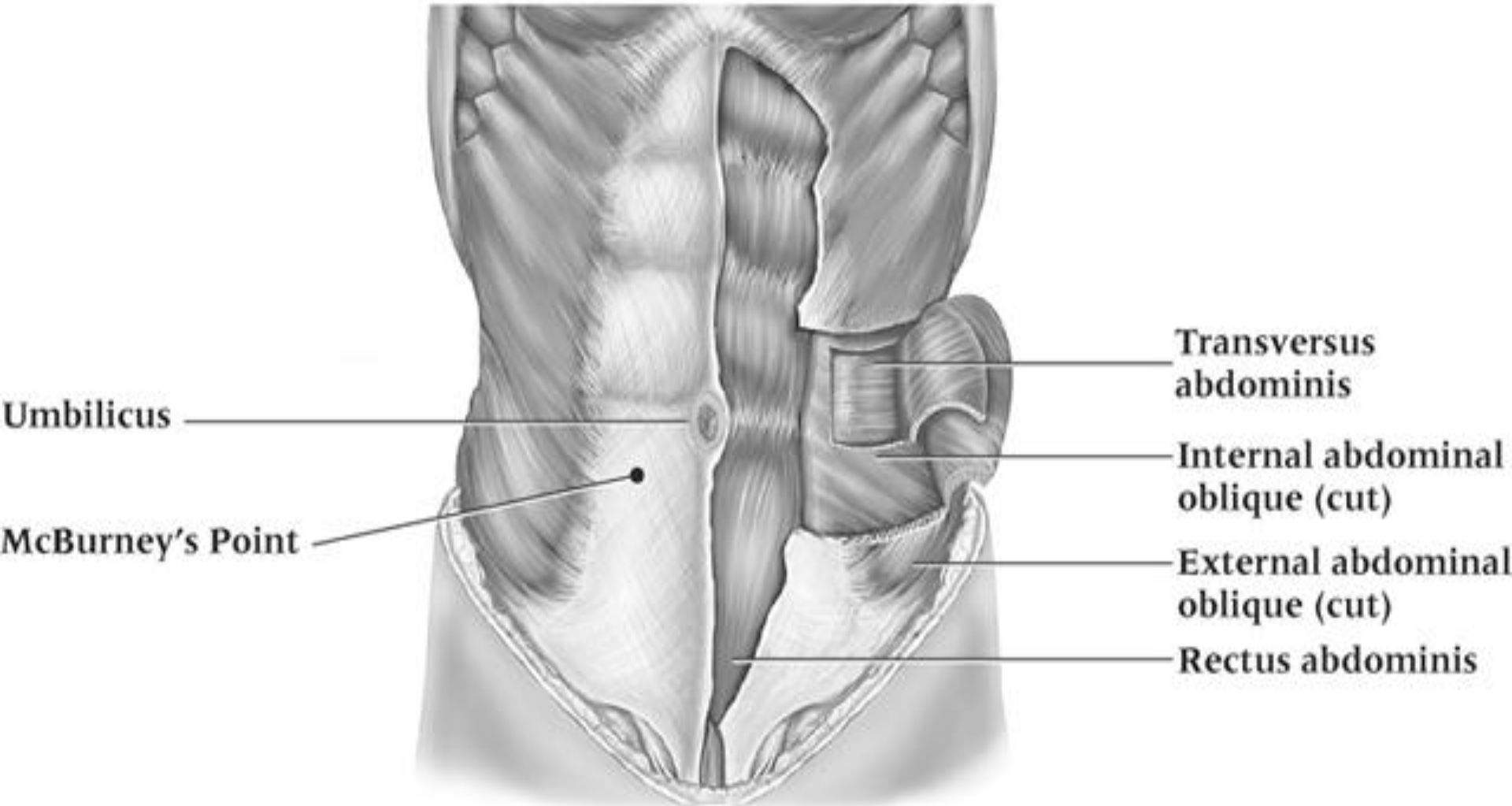
✓ Nerve Supply

- 1- Lower 6th thoracic nerves
- 2- L1(iliohypogastric n., ilioinguinal n.)



Muscles of the anterior abdominal wall

Anterior view



✓ Aponeurosis of external oblique muscle

Superficial inguinal ring.

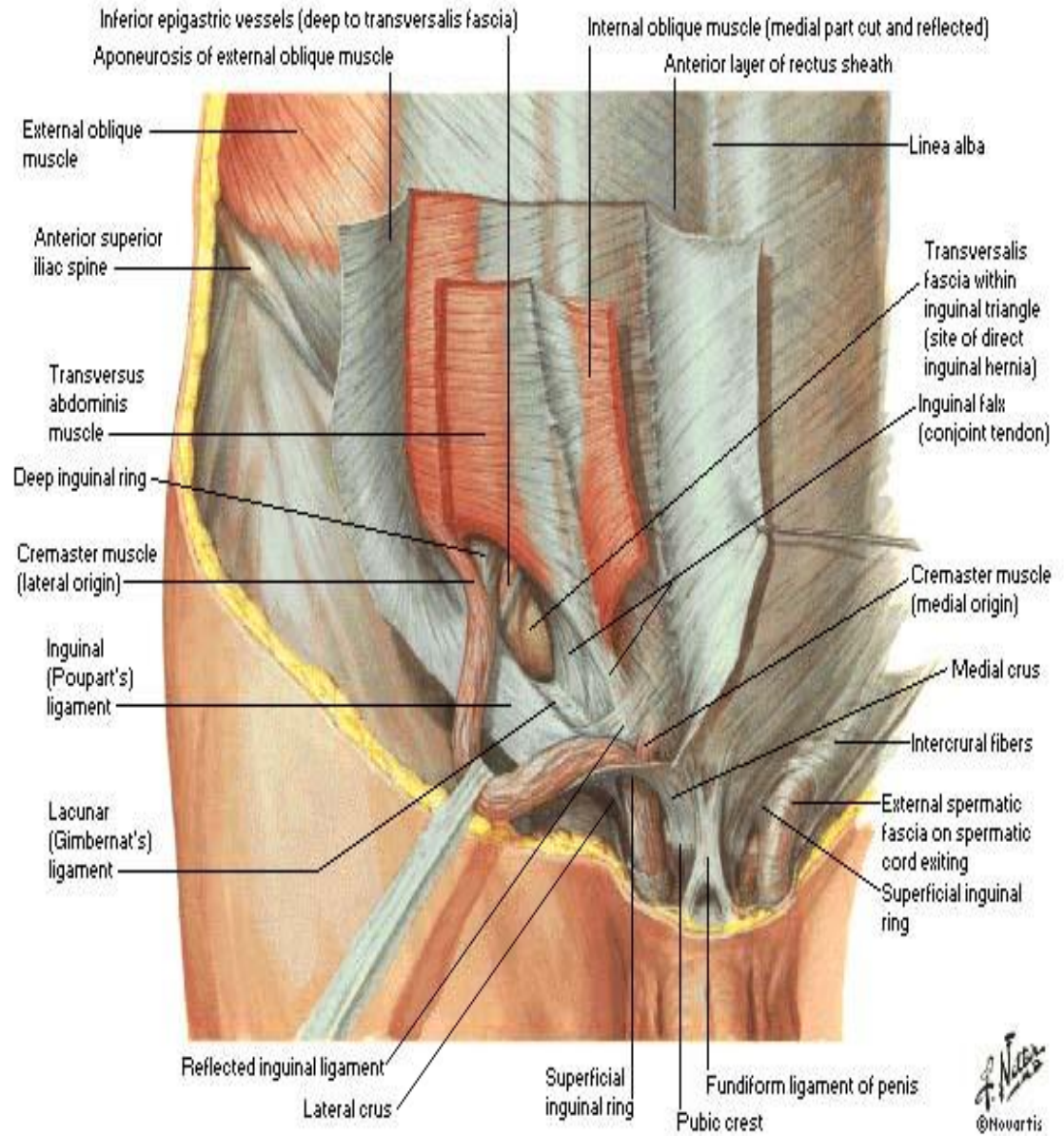
Inguinal ligament

Lacunar ligament

Pectineal ligament

Boundaries of inguinal canal

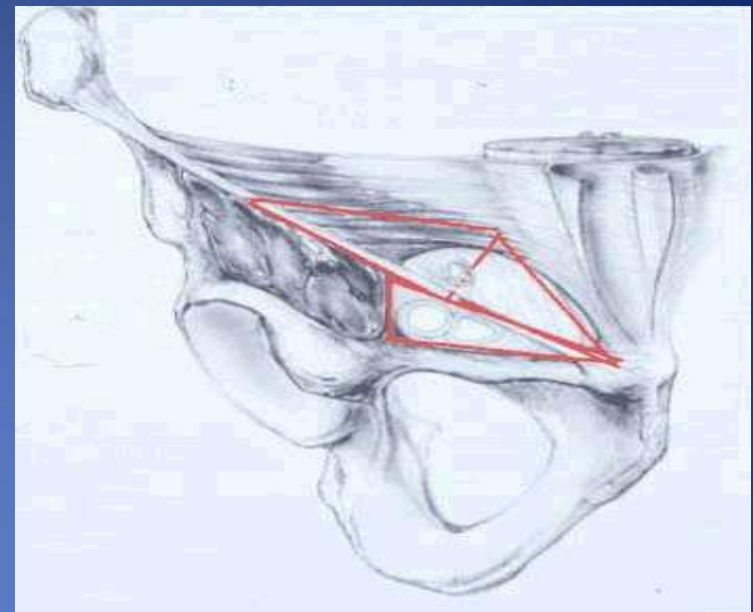
Formation of rectus sheath (



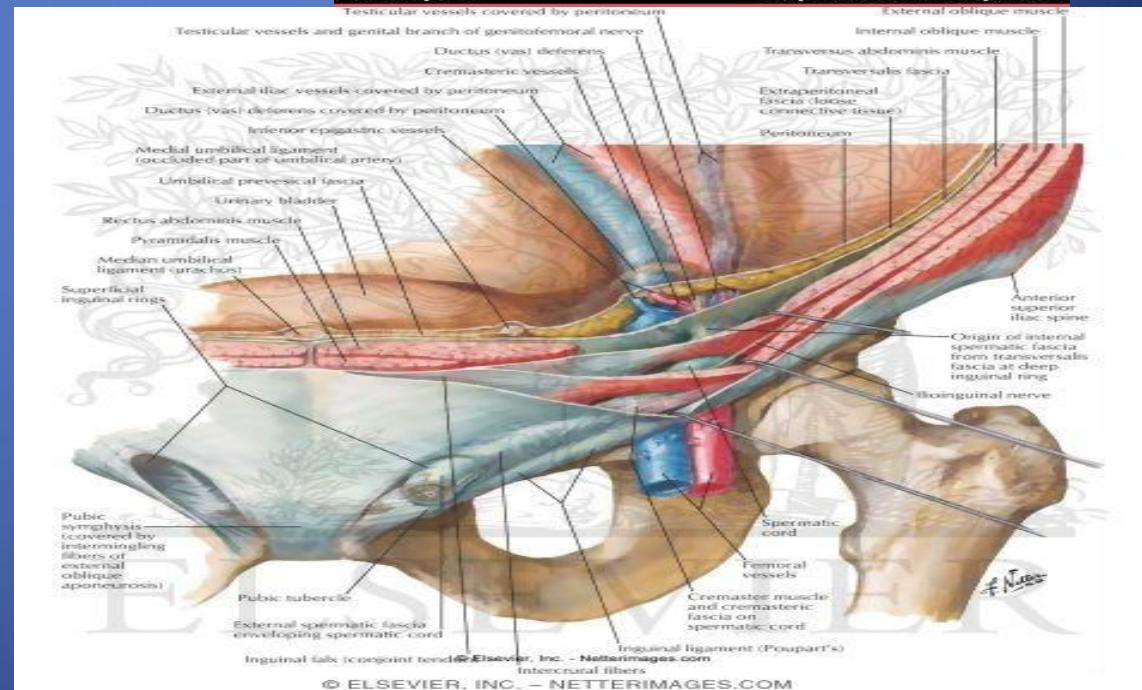
Inguinal ligament

1- folded back ward the lower border of aponeurosis of external muscle on it self

2- between ant.sup.ilic spine and the pupic tubercle



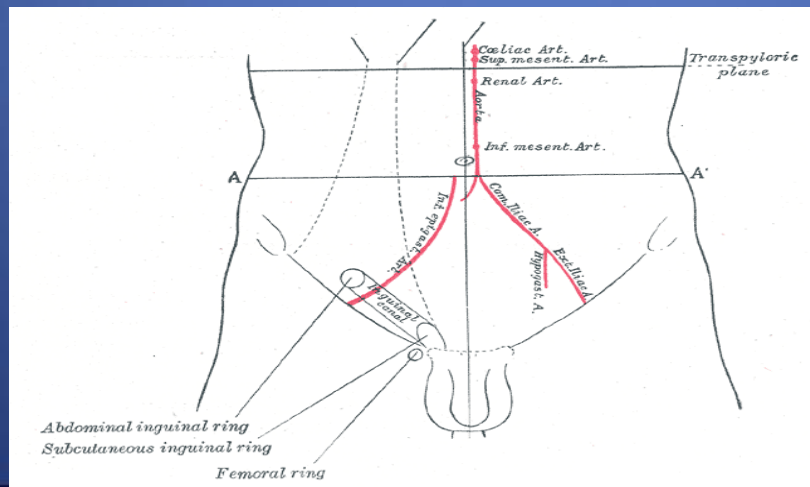
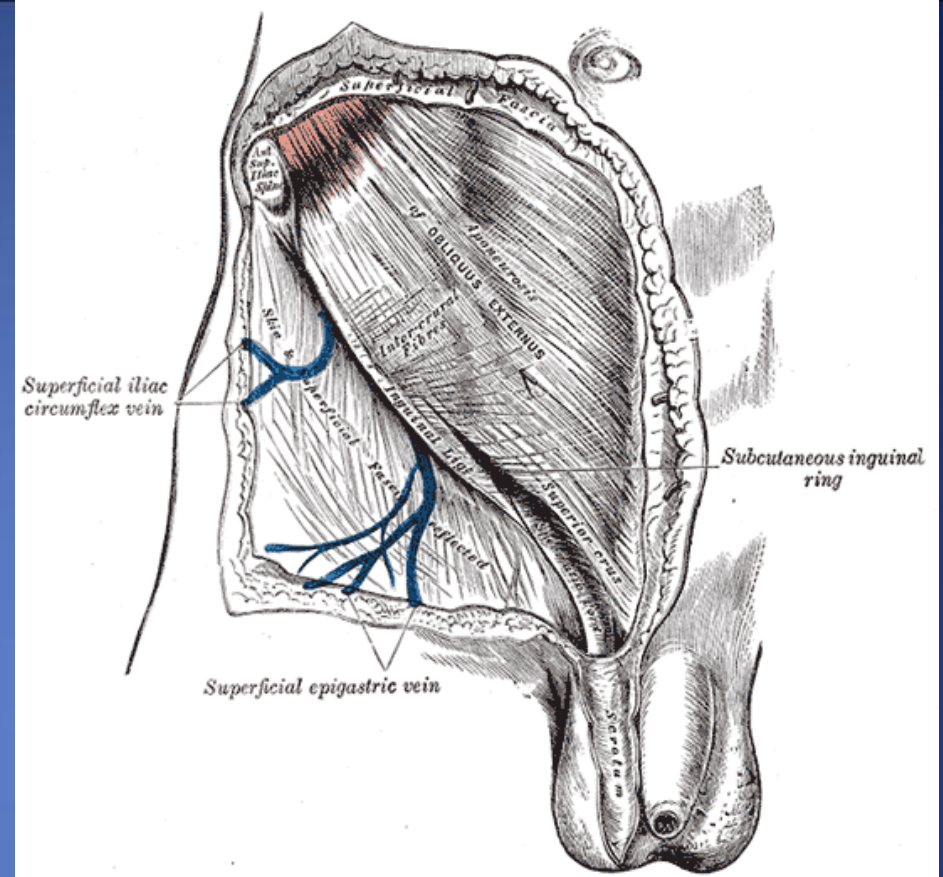
Medscape © <http://www.medscape.com>

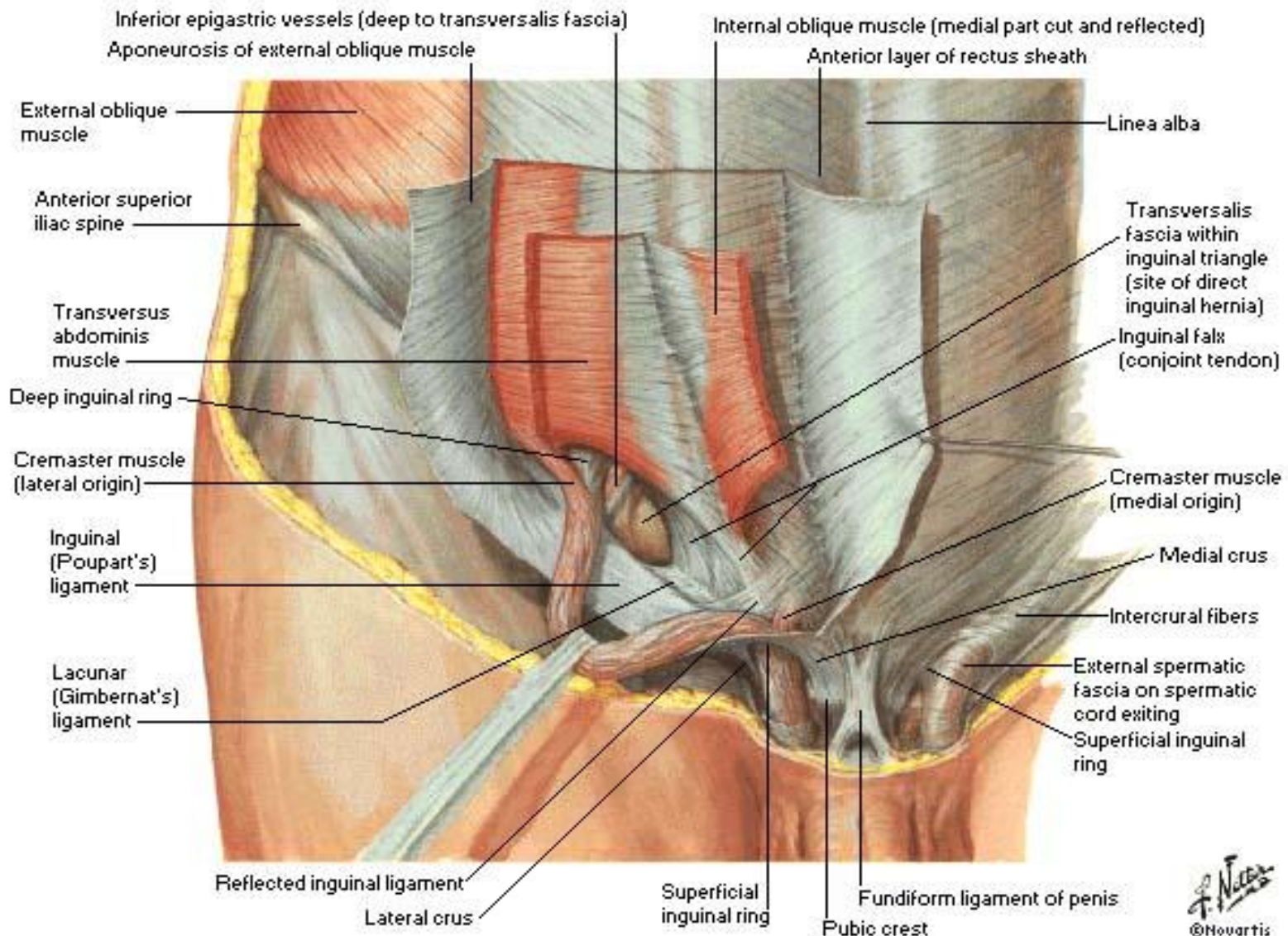


© ELSEVIER, INC. - NETTERIMAGES.COM

Superficial inguinal ring.

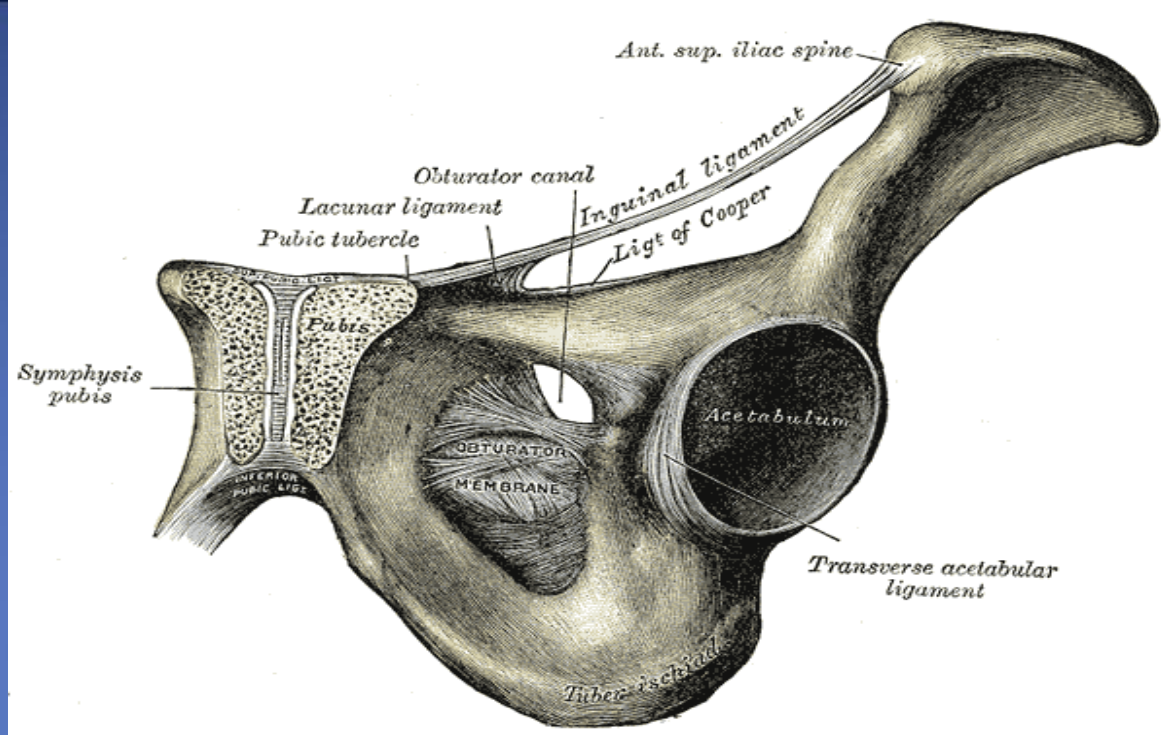
- 1- triangular shape
- 2- Defect in external oblique aponeurosis
- 3- lies immediately above and medial to the pubic tubercle
- 4- Opening for passing the spermatic cord or ligament of uterus





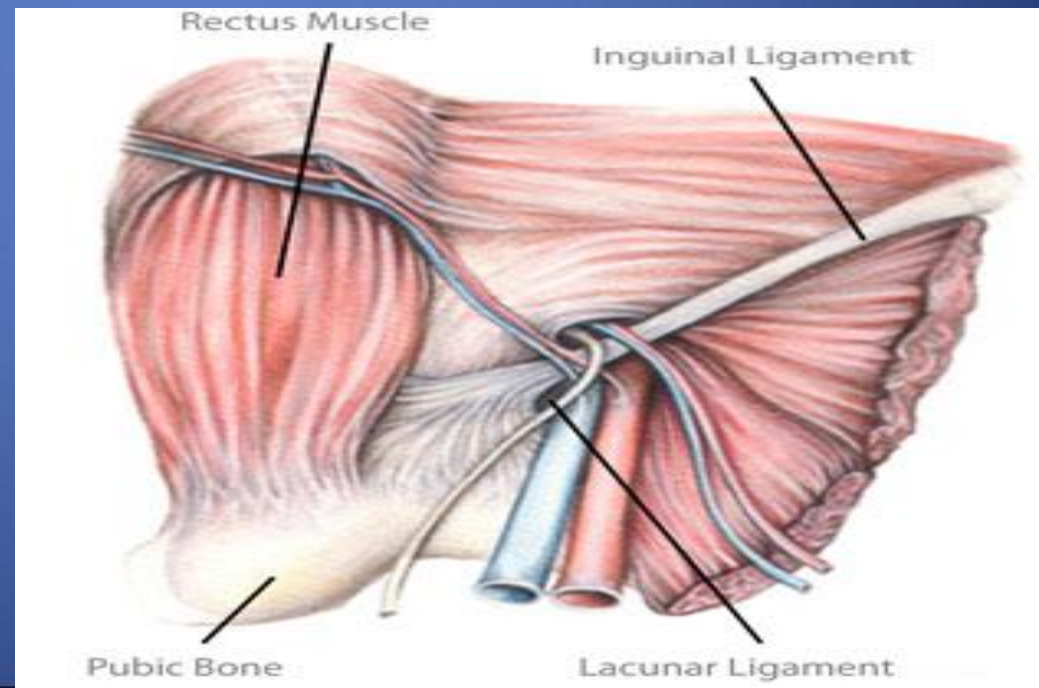
Lacunar ligament

- 1- extension of aponeurosis of external muscle backward and upward to the pectineal line
- 2- on the superior ramus of the pubis
- 3- its sharp, free crecentric edge forms the medial margin of the femoral ring



Pectineal ligament

- 1- Continuation of the lacunar ligament at pectineal line
- 2- Continuation with a thickening of the periosteum



Internal Oblique

✓ Direction:

upward forward medially

✓ Origin

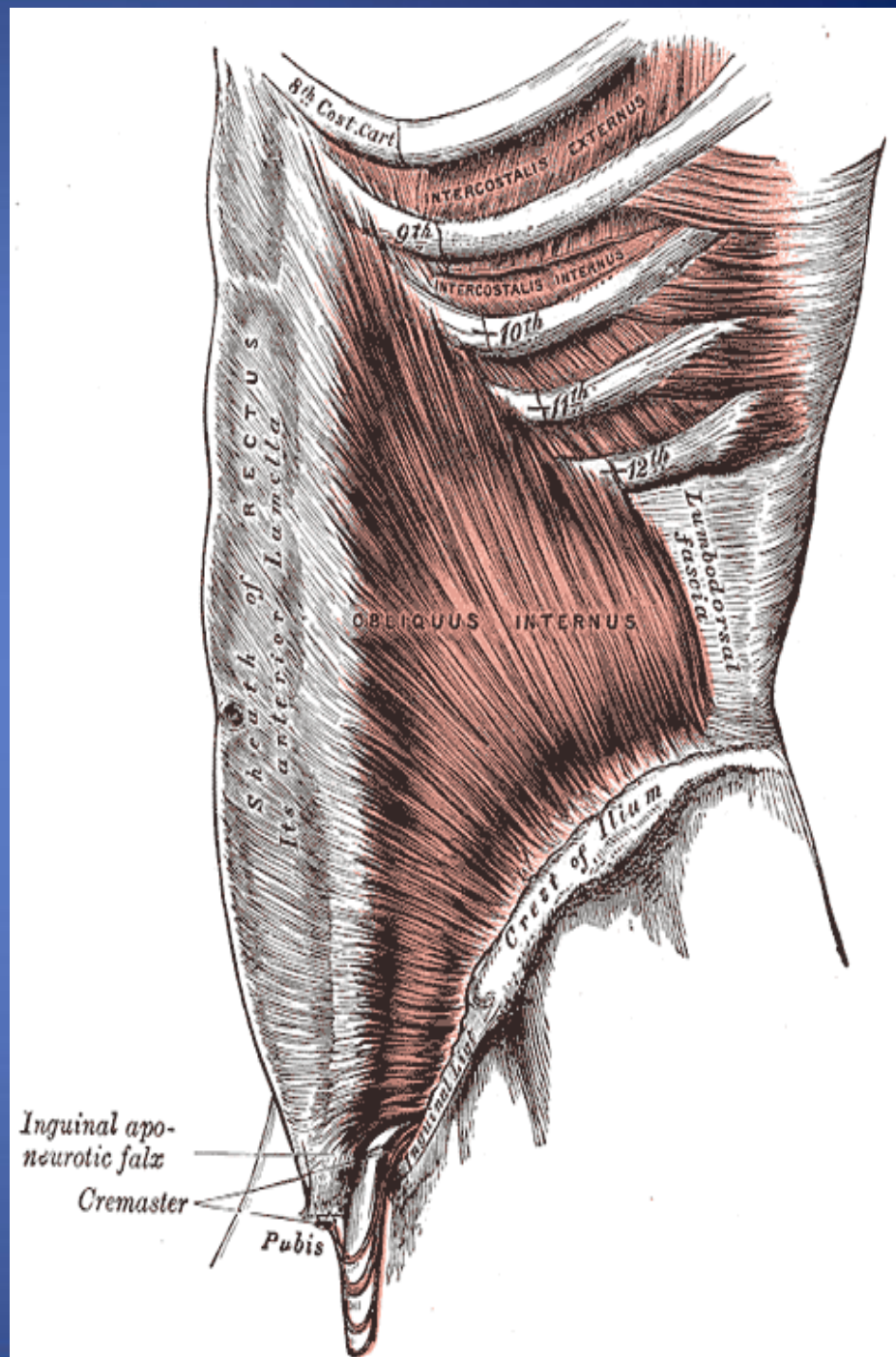
Lumbar Fascia, Ant 2/3 iliac crest,
lateral two thirds of inguinal
ligament.

✓ Insertion

- Lower three ribs & costal
cartilage, Xiphoid process,
Linea alba, symphysis pubis.

✓ Nerve Supply

Lower 6th thoracic nerves,
iliohypogastric n & ilioinguinal
n → L1.



Internal oblique muscle.....cont

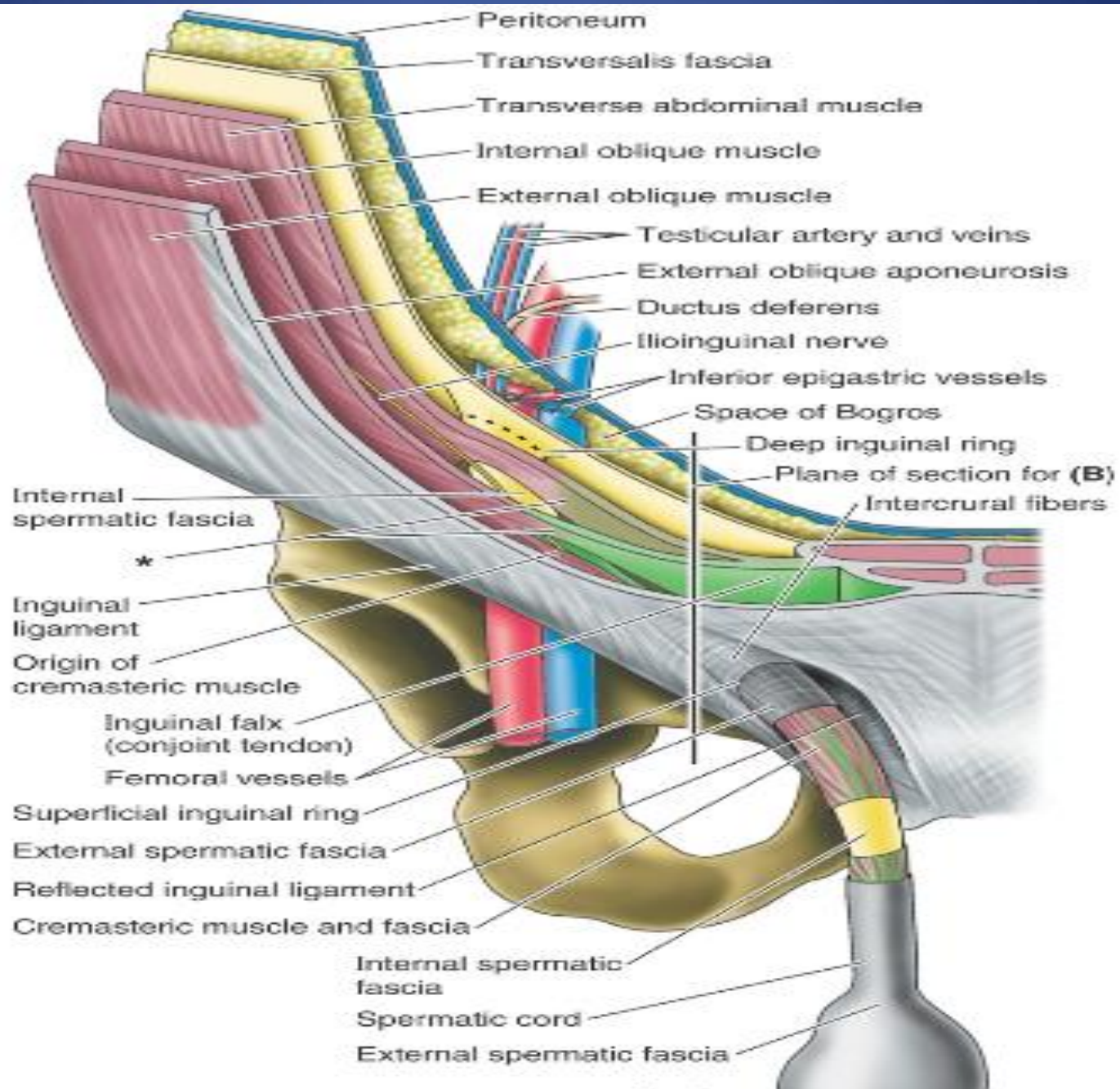
Conjoint tendon

- The lowest tendinous fibers of internal oblique which joint with transversus abdominis
- Attach medially to linea alba
- Support the inguinal canal
- Has lateral free border

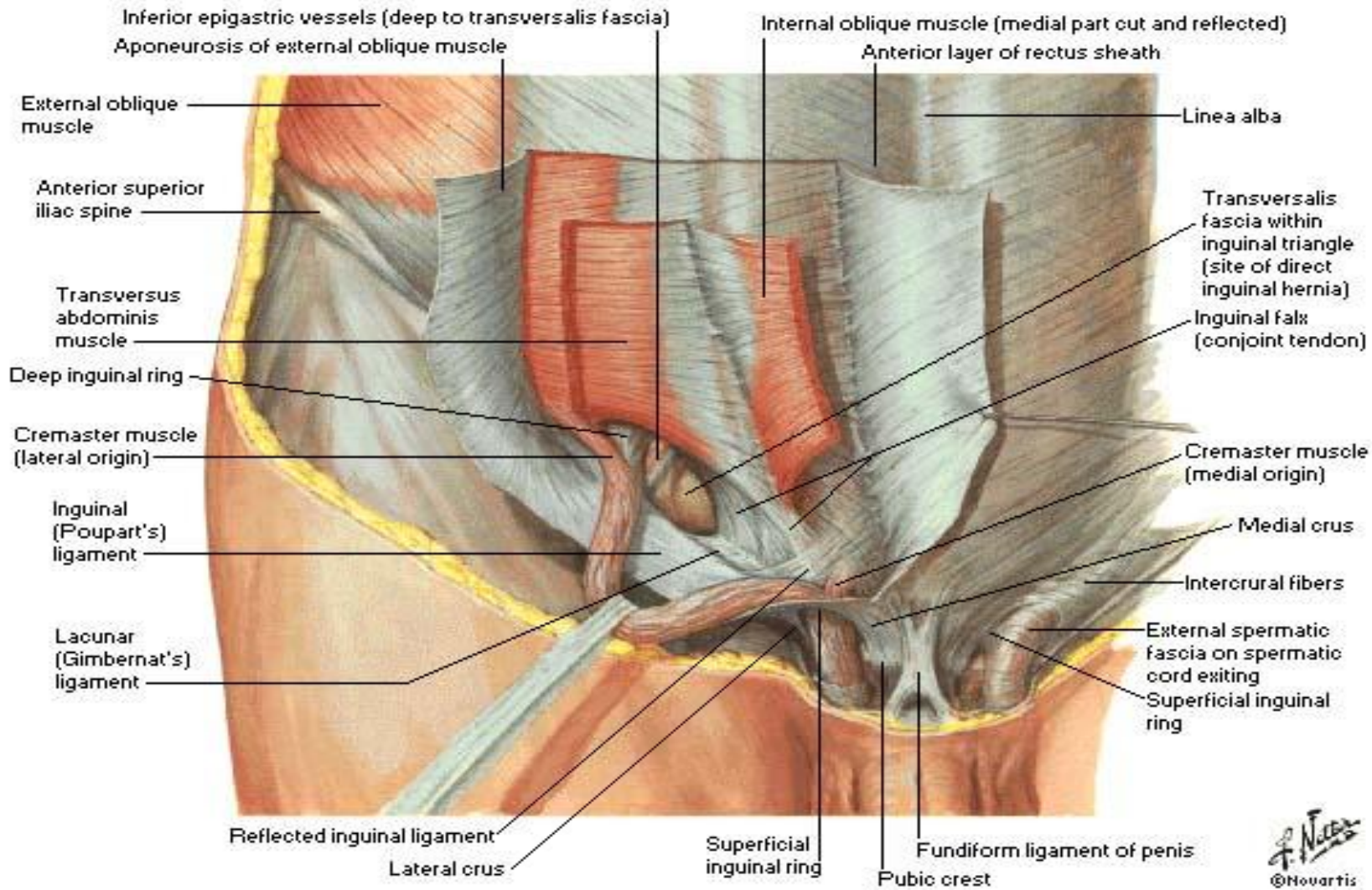
Cremastric fascia

Internal oblique has free lower border arches over the **spermatic cord** or **ligament of uterus**

- Cremastric muscle
- Fascia
- Int. abd.muscle assist in the formation of the **Roof of the inguinal canal**



Conjoint tendon & Cremastic fascia



❖ Transversus Abdominis

Direction

- Its fibers run horizontally forward under the internal oblique

✓ Origin

- Inner surface of lower six costal cartilage, lumbar fascia, anterior two thirds of iliac crest, lateral third of inguinal ligament.

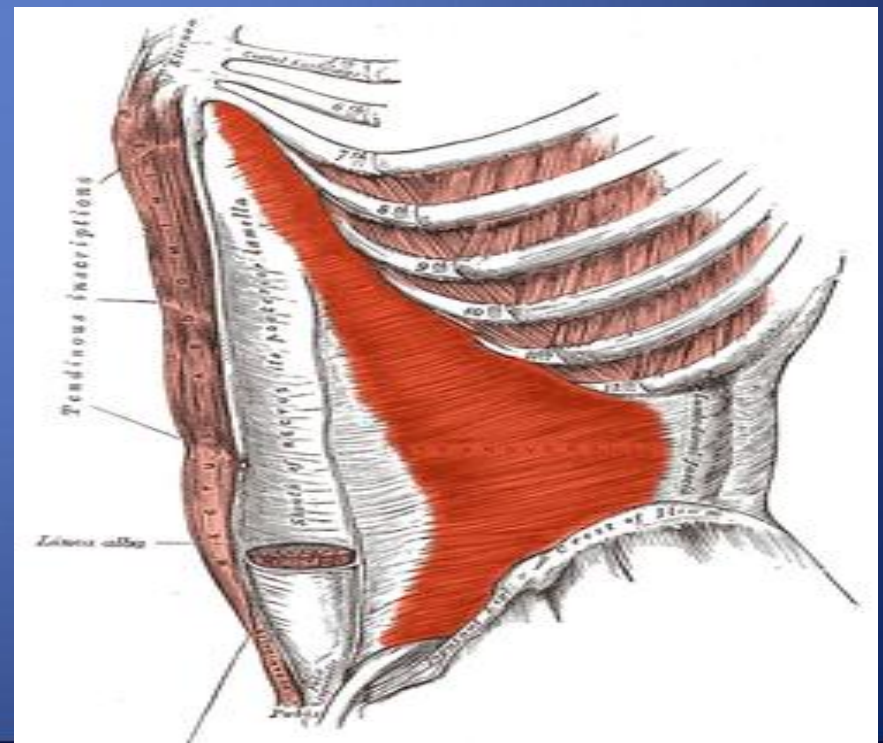
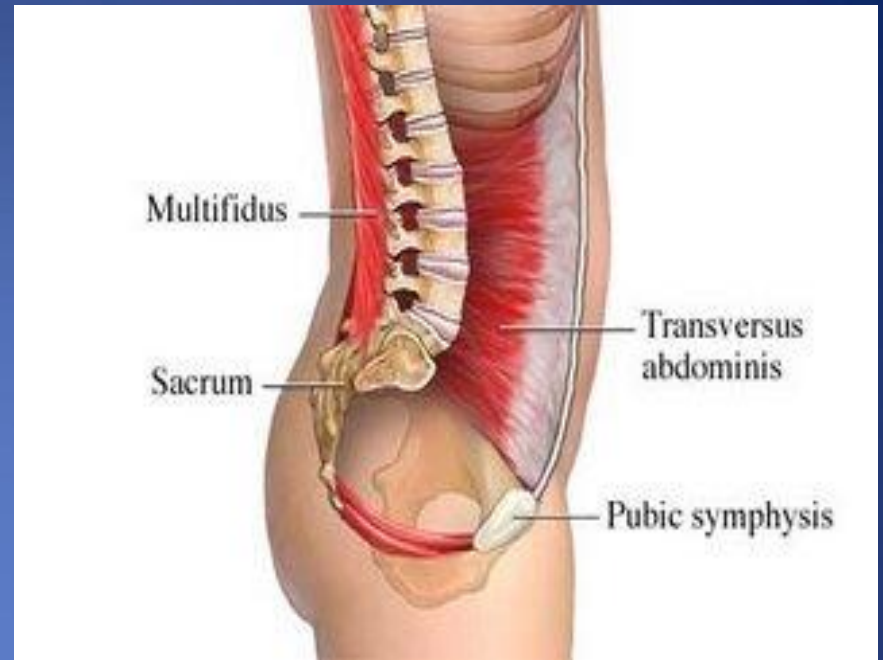
✓ Insertion

Xiphoid process, Linea alba, symphysis pubis.

- ✓ The lower part fuses with internal oblique to form conjoint tendon which attach to pubic crest and pectineal line

✓ Nerve Supply

Lower six thoracic nerves, L1 (iliohypogastric n. & ilioinguinal n.)



Transversus Abdominis.....cont

Assist in the formation of

- Conjoint tendon
- Rectus sheath

RECTUS ABDOMINIS

- Long strap muscle
- Extends along the whole length of the anterior abdominal wall
- In the rectus sheath

✓ Origin

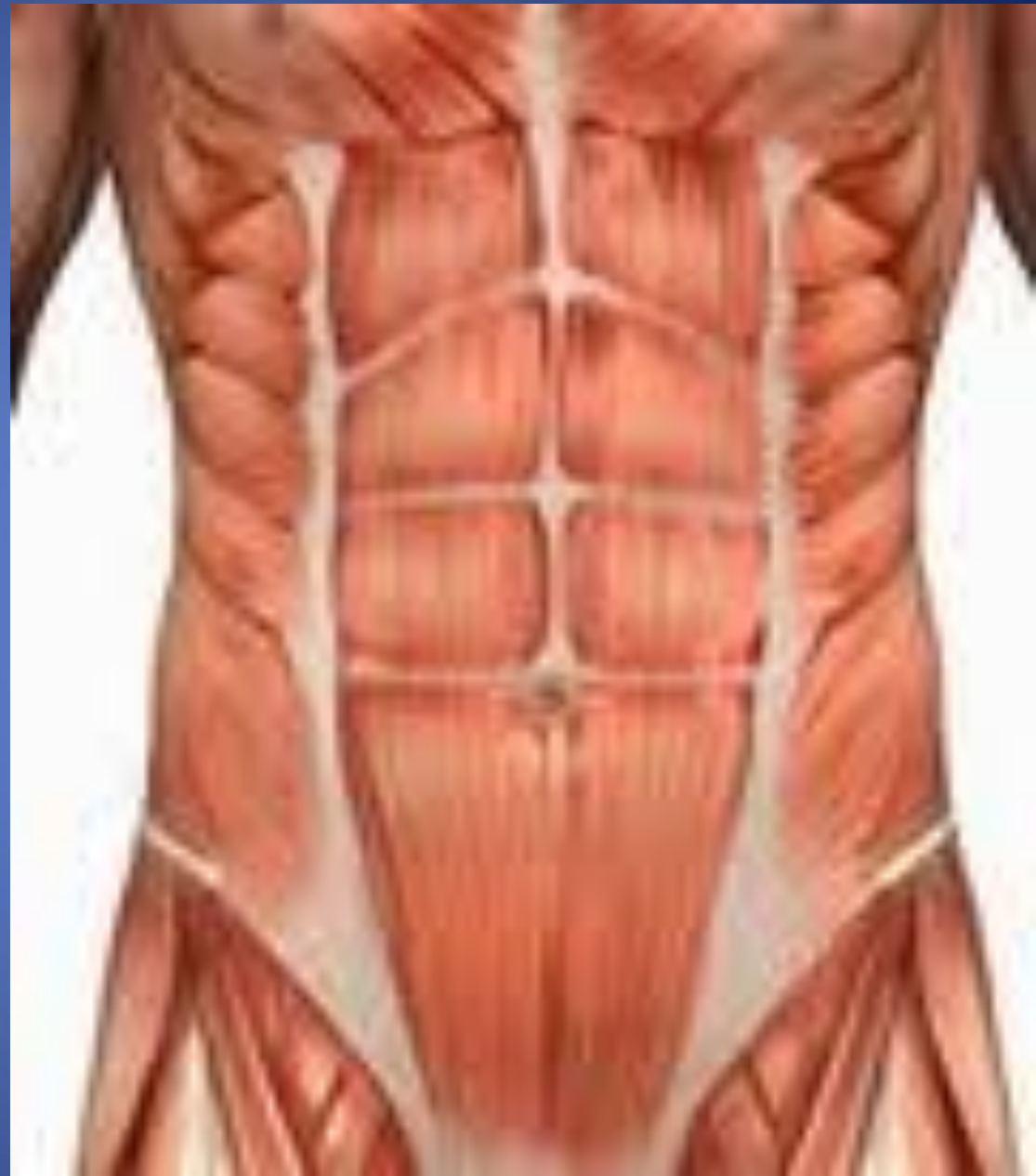Symphysis pubis, pubic crest

✓ Insertion

5th, 6th and 7th costal cartilage & xiphoid process.

✓ Nerve Supply

Lower 6th thoracic nerves



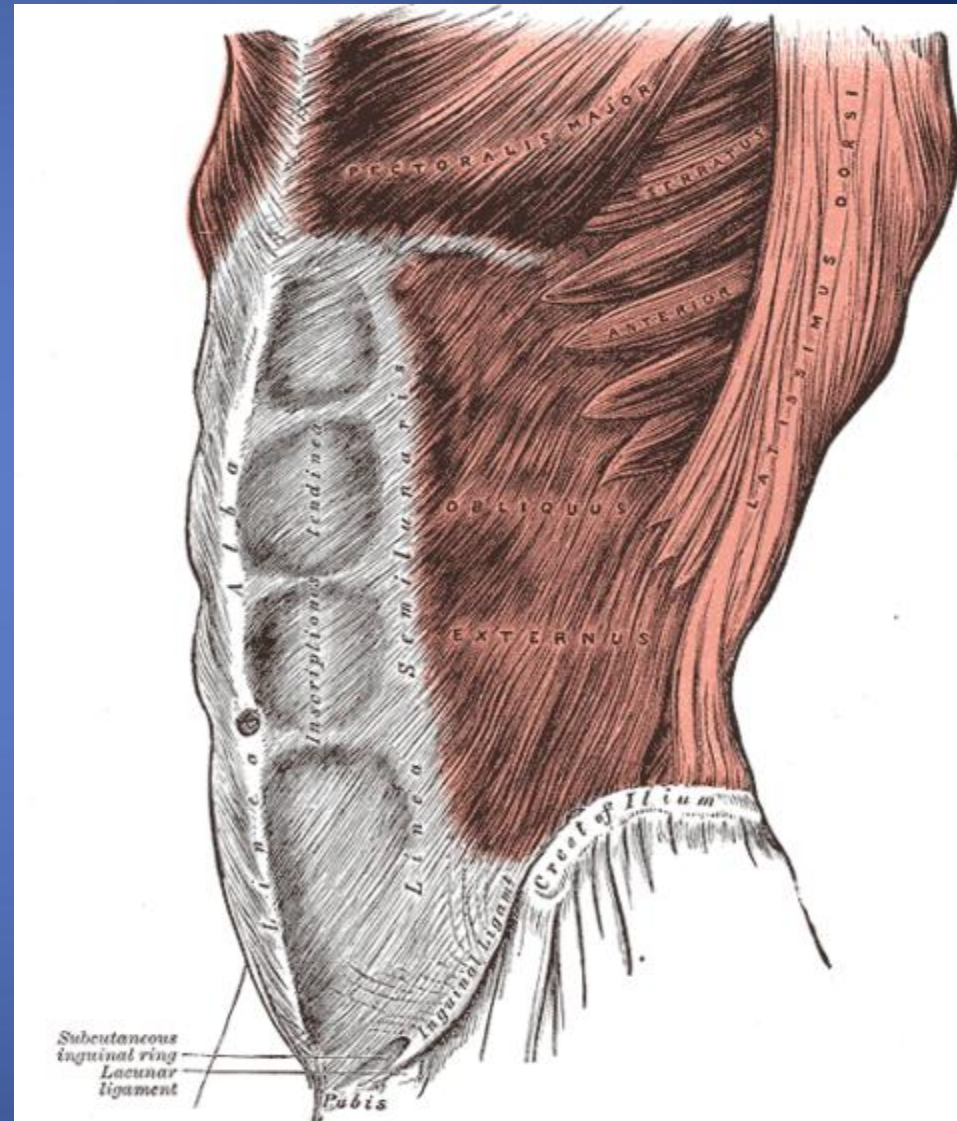
Rectus abdominis muscle.....cont

- *Linea semilunaris*
- *Tendinous intersection:*

Lines & Land marks of the Anterior Abdominal Wall

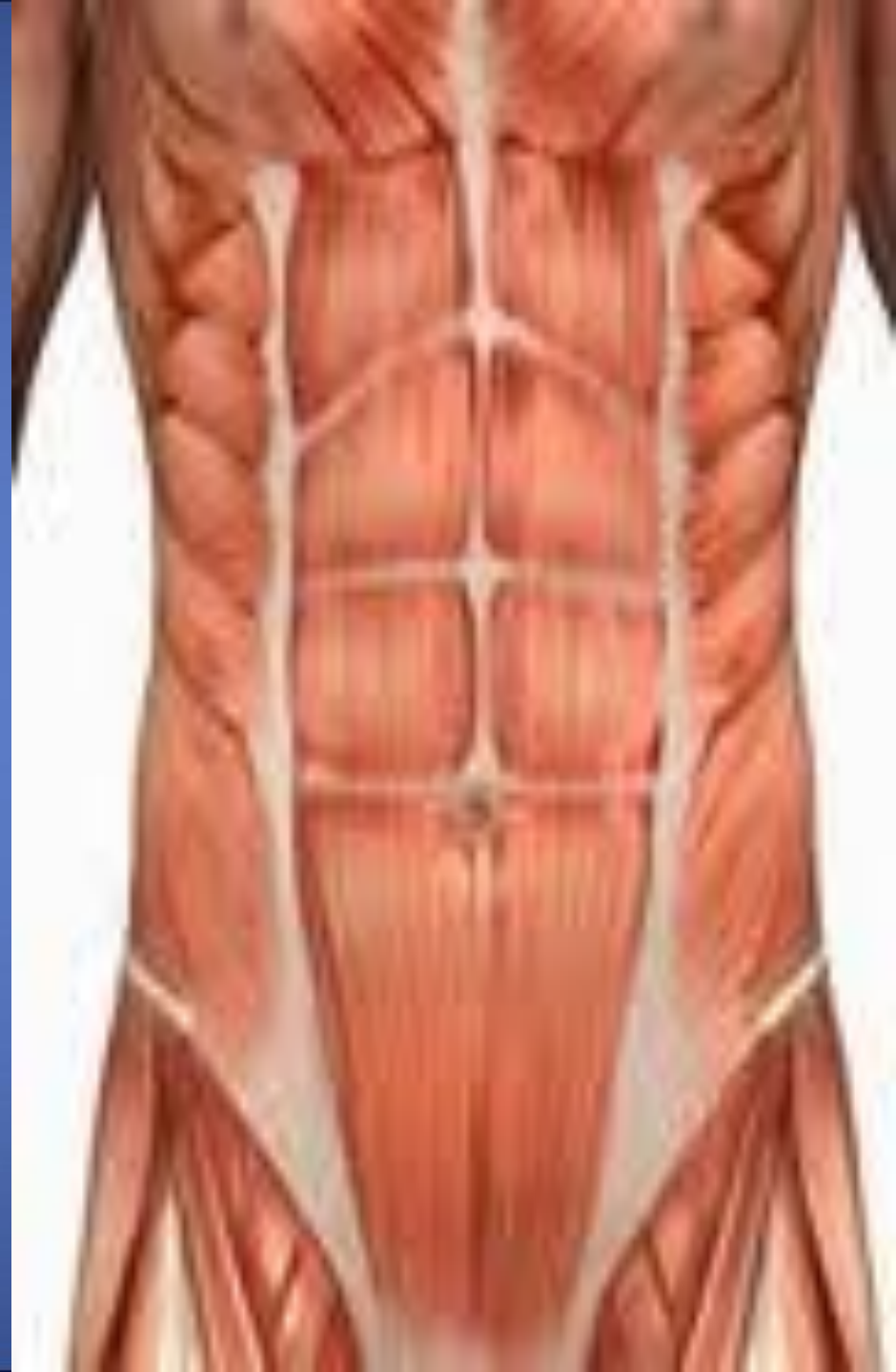Linea alba:

- Located along the midline.
 - Between the xiphoid process & symphysis pubis
 - Formed by the fusion of aponeuroses of three abdominal wall (Ex.In, Tran. Abd.muscle)
-
- **Linea semilunaris**
 - Lateral margins of rectus abd. muscle
 - Can be palpated
 - Extend from 9th c.c to pubic tubercle



Tendinous intersection: = Linea
transverses

- 3 transverse fibrous bands
- divide the rectus abdominis muscle into distinct segments
 - 1- one at level of xiphoid process
 - 2- one at level of umbilicus and
 - 3- one half way between these two
- They can be palpated as a transverse depressions



Pyramidalis muscle

Origin

Ant. Surface of the pubis

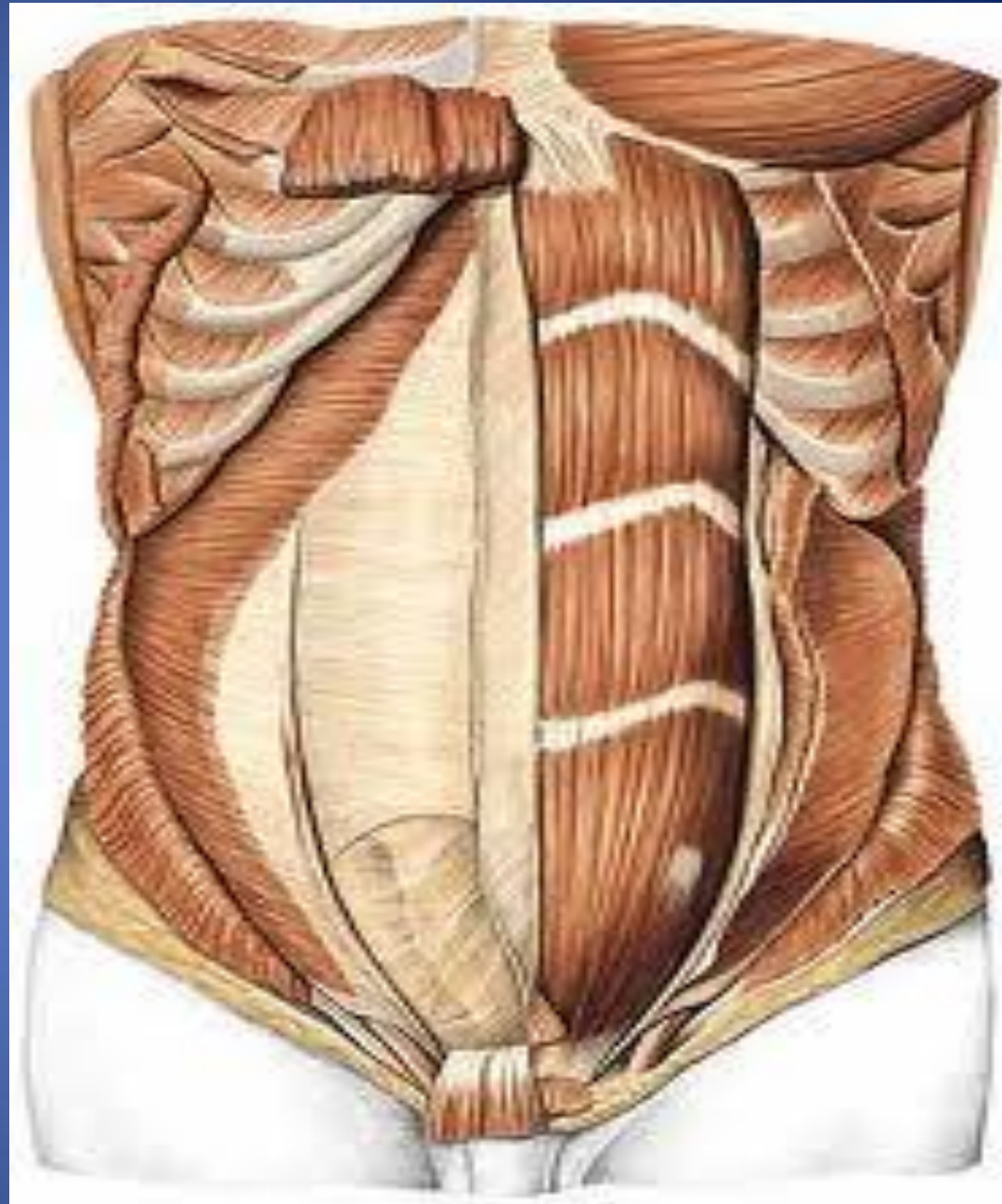
Insertion:

Linea alba

-It lies in front of the lower part of the rectus abdominis muscle

-Nerve supply

12th subcostal nerve



Rectus sheath

Rectus sheath.....cont

- The rectus sheath is a long fibrous sheath
- Formed mainly by the aponeuroses of the three lateral abdominal muscles.
- **Contents**
 - Rectus abdominis muscle
 - Pyramidalis muscle (if present)
 - The anterior rami of the lower six thoracic nerves
 - The superior and inferior epigastric vessels
 - Lymphatic vessels.

Rectus sheath.....cont

- Description the rectus sheath is considered at three levels.
 - 1- Above the costal margin*
 - 2- Between the costal margin and the level of the anterior superior iliac spine*
 - 3- Between the level of the anterosuperior iliac spine and the pubis the anterior wall*

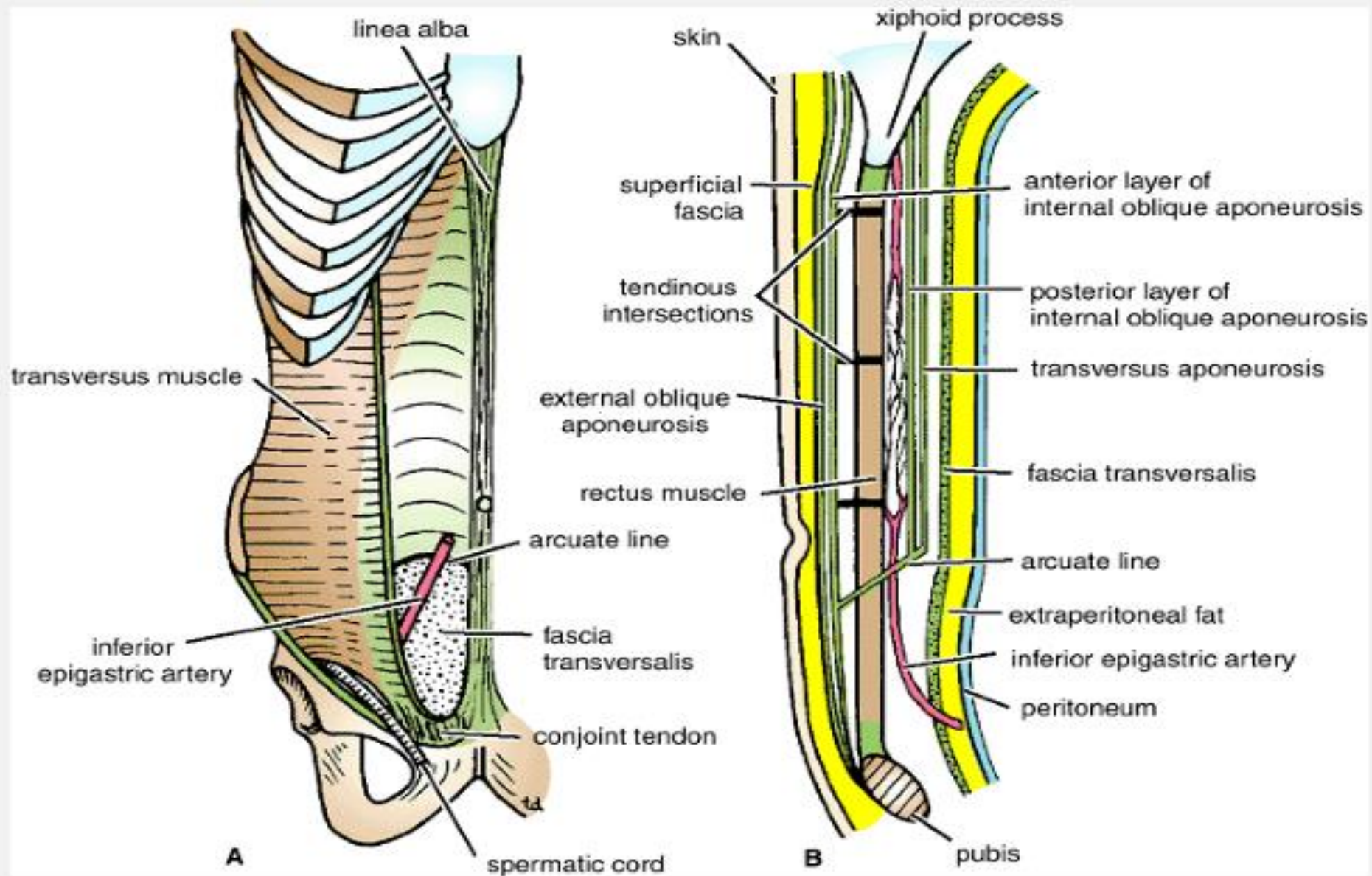
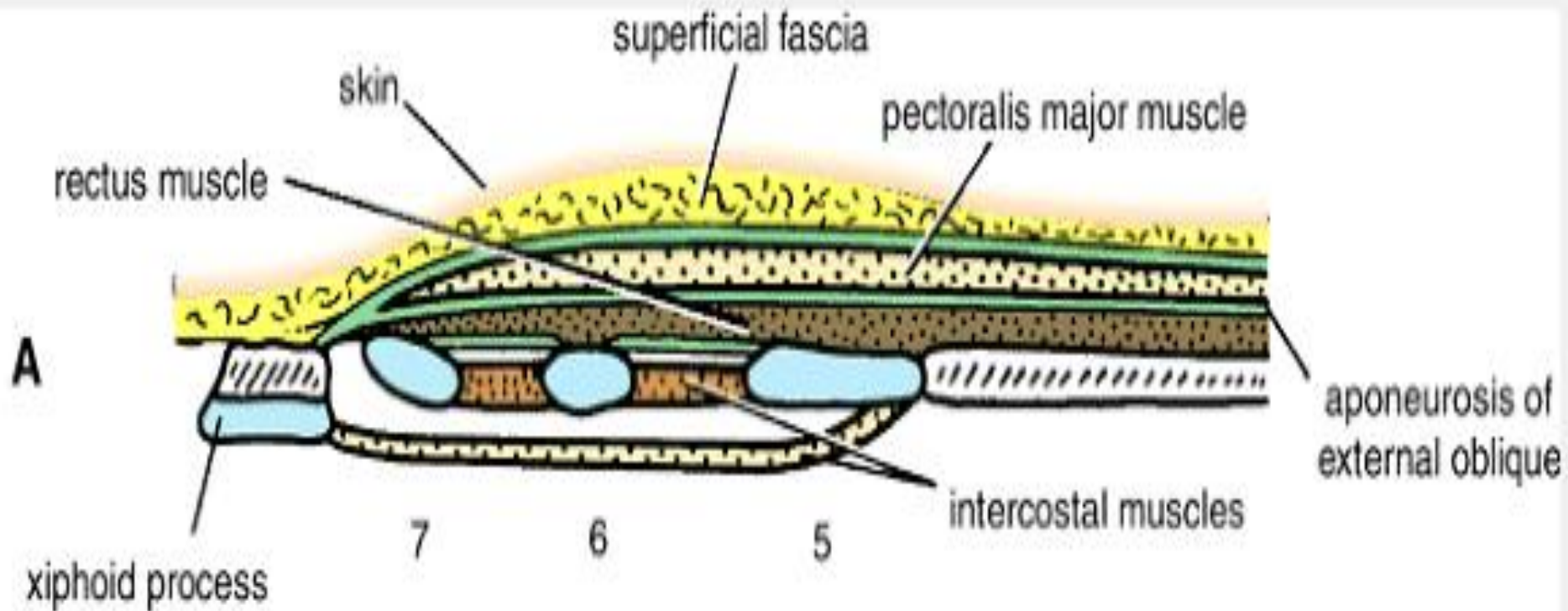


Figure 4-10 Rectus sheath in anterior view (A) and in sagittal section (B). Note the arrangement of the aponeuroses forming the rectus sheath.

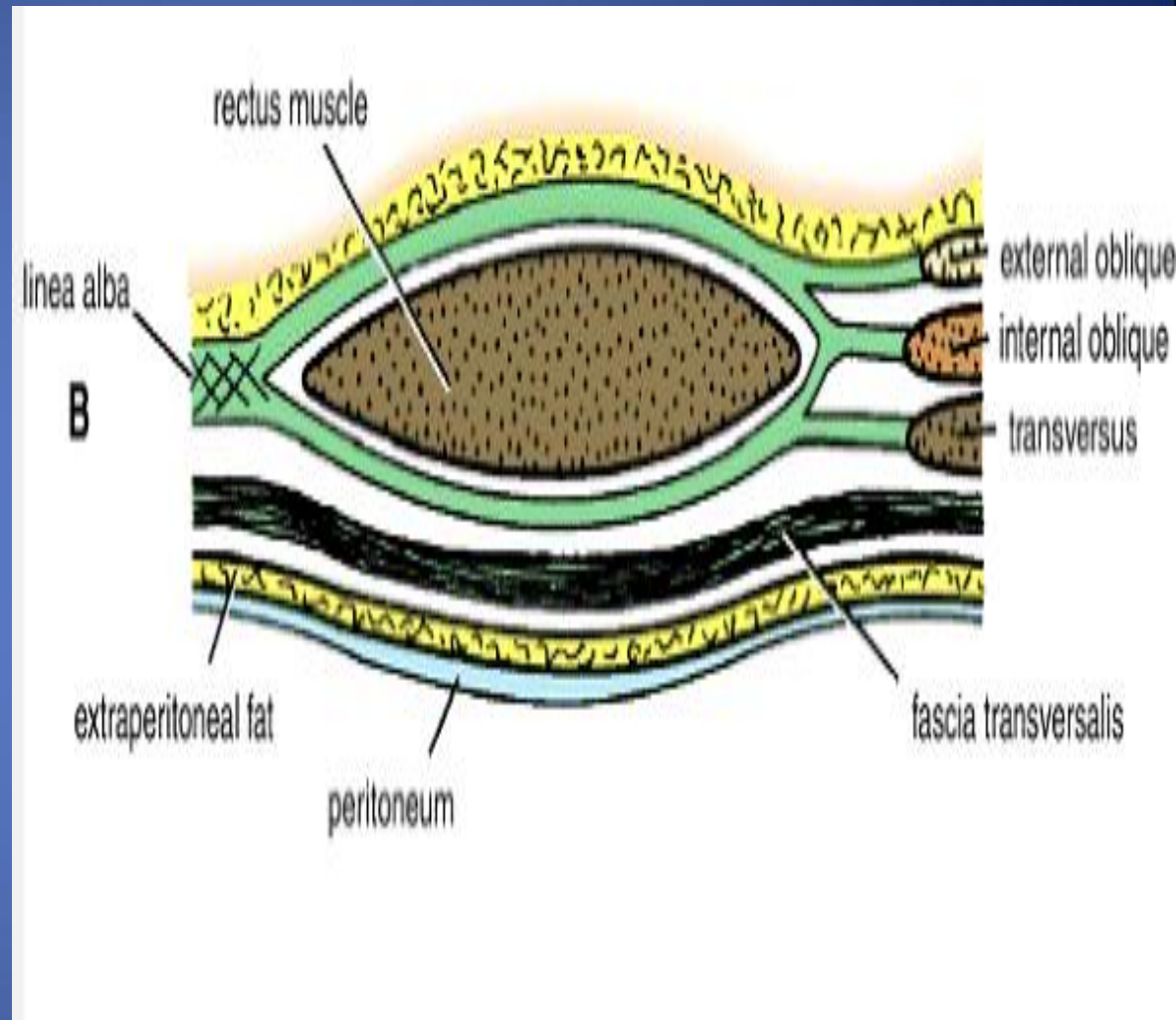


ABOVE THE COSTAL MARGIN,

- ANTERIOR WALL # APONEUROSIS OF THE EXTERNAL OBLIQUE.
- POSTERIOR WALL # THORACIC WALL THAT IS, THE FIFTH, SIXTH, AND SEVENTH COSTAL CARTILAGES AND THE INTERCOSTAL SPACES.

***Between the costal margin
and the level of the anterior
superior iliac spine***

- The aponeurosis of the internal oblique splits to enclose the rectus muscle
- the external oblique aponeurosis is directed in front of the muscle
- the transversus aponeurosis is directed behind the muscle.



Between the level of the anterosuperior iliac spine and the pubis

the anterior wall : the aponeurosis of all three muscles form.

The posterior wall is absent, and the rectus muscle lies in contact with the fascia transversalis.

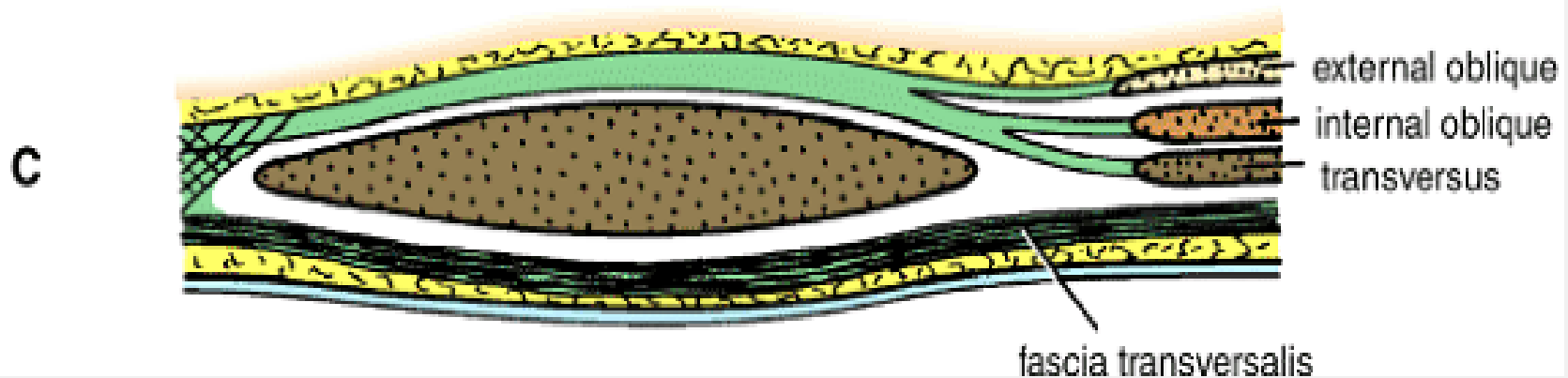


Figure 4-13 Transverse sections of the rectus sheath seen at three levels. **A.** Above the costal margin. **B.** Between the costal margin and the level of the anterior superior iliac spine. **C.** Below the level of the anterior superior iliac spine and above the pubis.

Rectus sheath.....cont

- The posterior wall of the rectus sheath is not attached to the rectus abdominis muscle. The anterior wall is firmly attached to it by the muscle's tendinous intersections
- **Linea semicircularis** (arcuate line)
- Is a crescent-shaped line marking the inferior limit of the posterior layer of the rectus sheath just below the level of the iliac crest.

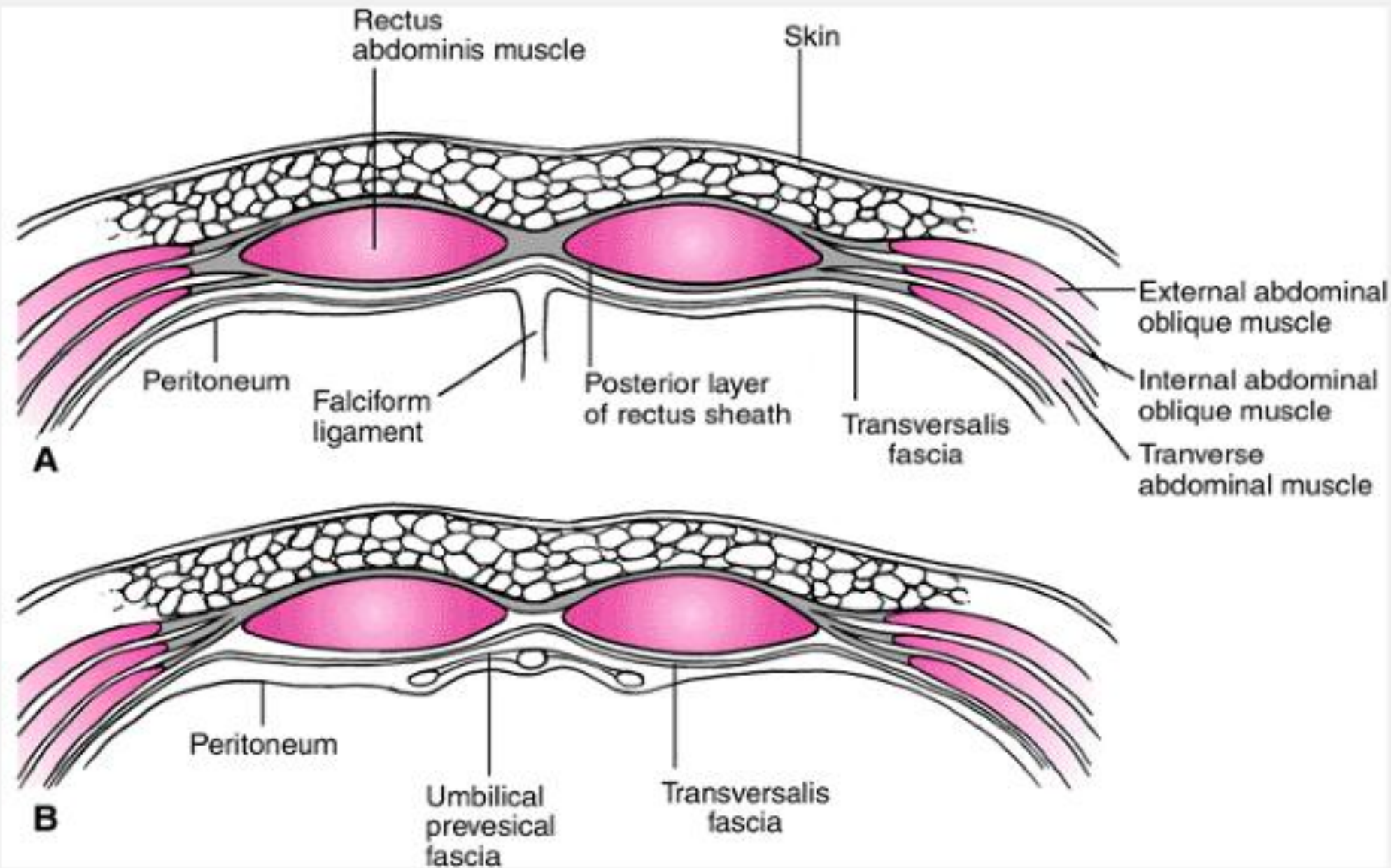


Figure 5-2 Arrangement of the rectus sheath above the umbilicus (upper) and below the arcuate line (lower).

Others fascia in the ant. abd.ominal wall

❖ Transversalis fascia

- a thin layer of fascia that lines the Transversus Abdominis muscle
- continue to diaphragm , iliac muscle & pelvis fascia
- contribute to femoral sheath

❖ Extraperitoneal Fascia

- ✓ The thin layer of C.T and adipose tissue between the peritoneum and fascia transversalis.

❖ Parietal peritoneum

- ✓ It is a thin serous membrane
- ✓ Continuous below with the parietal peritoneum lining the pelvis.

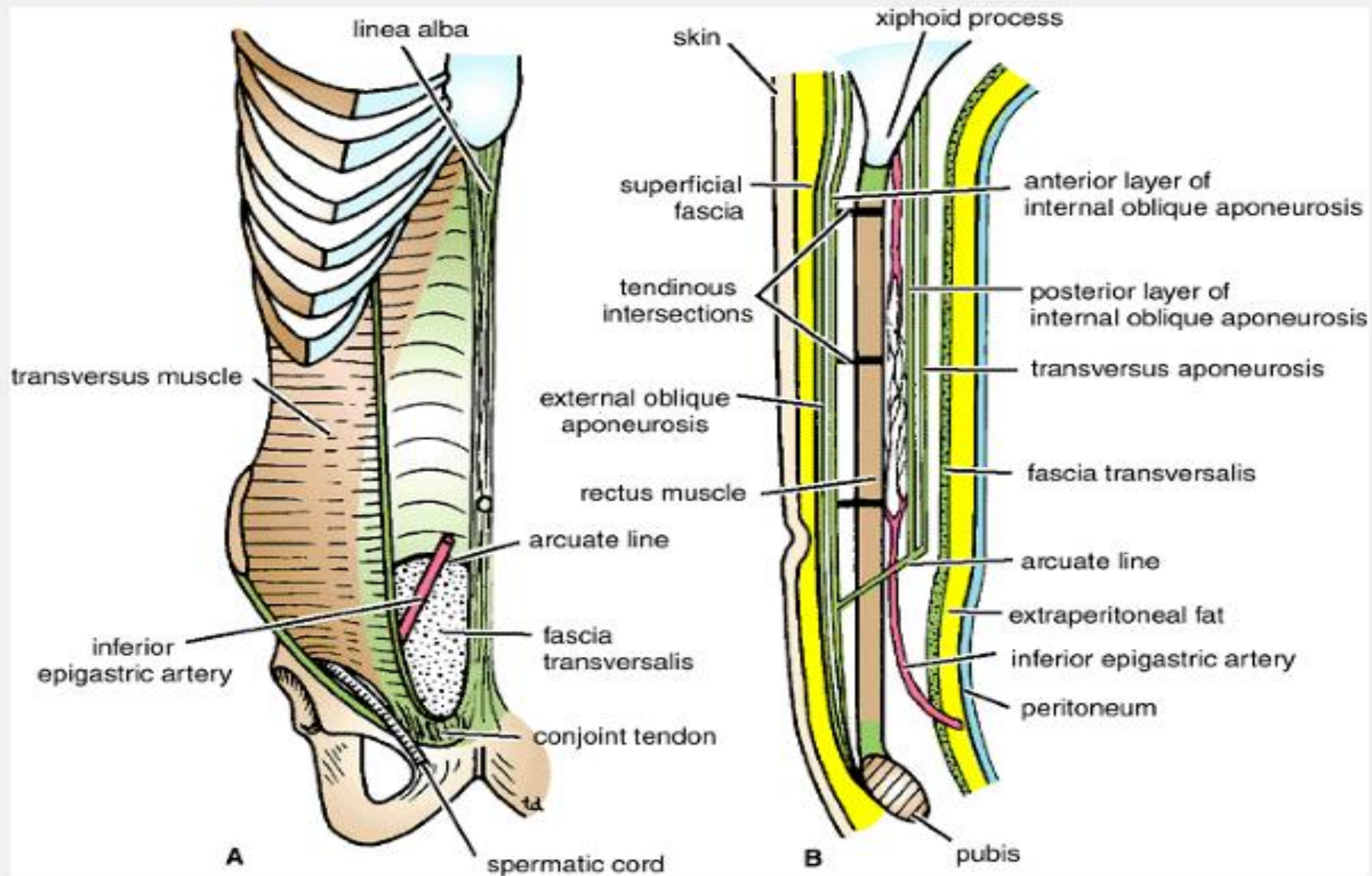
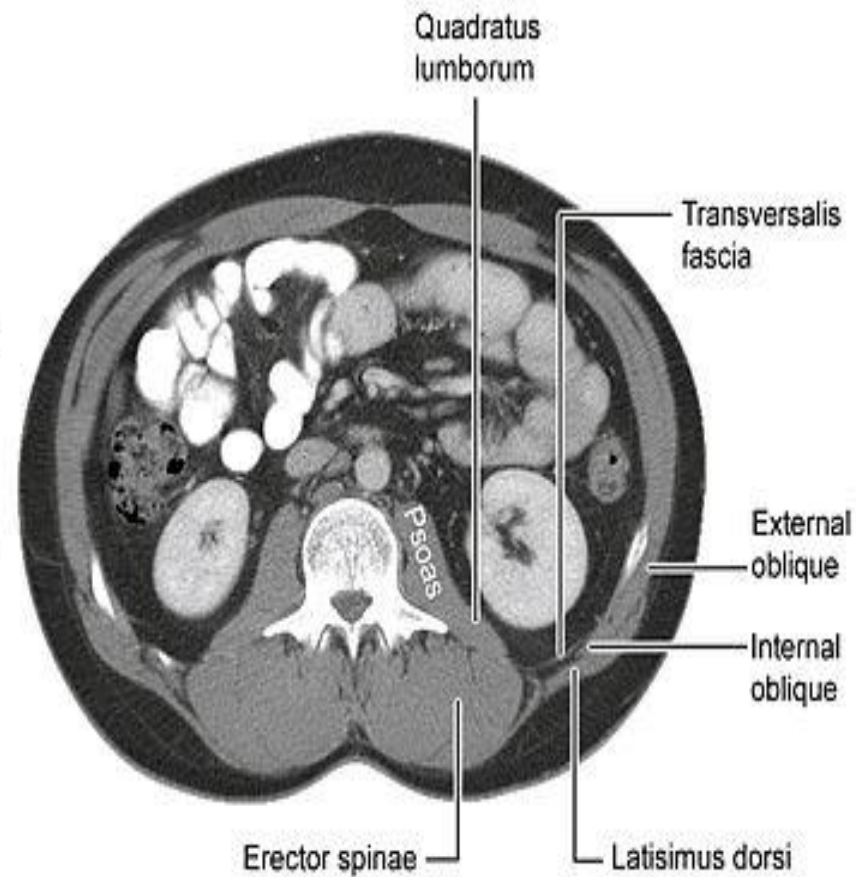
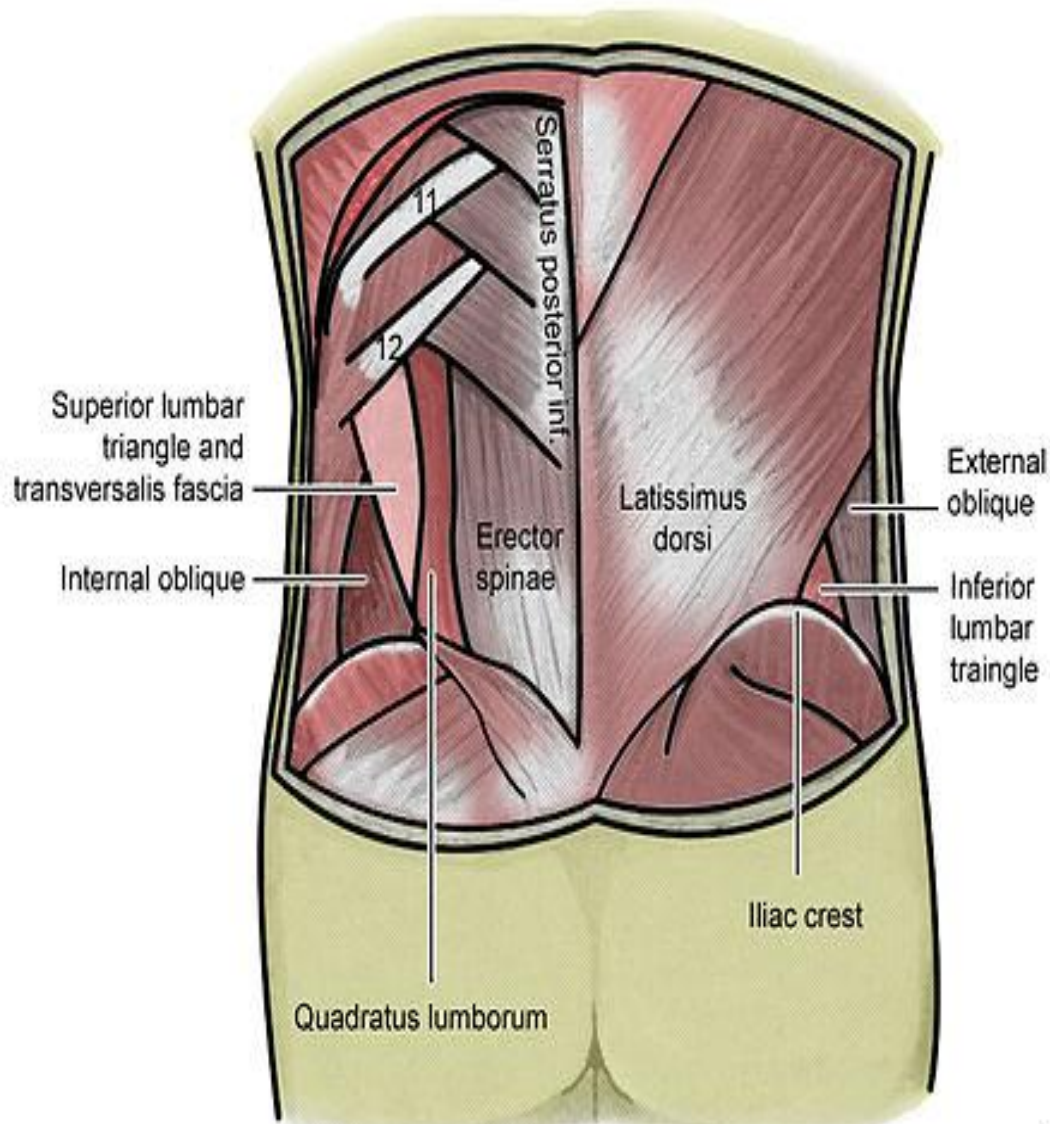


Figure 4-10 Rectus sheath in anterior view (A) and in sagittal section (B). Note the arrangement of the aponeuroses forming the rectus sheath.

Lumbar triangle



lumbar triangle

- 1- the inferior lumbar (Petit) triangle, which lies superficially
 - 2- the superior lumbar (Grynfeltt) triangle, which is deep and superior to the inferior triangle.
- Of the two, the superior triangle is the more consistently found in cadavers, and is more commonly the site of herniation
 - however, the inferior lumbar triangle is often simply called the lumbar triangle, perhaps owing to its more superficial location and ease in demonstration.

Lumber triangle(petitis)

- The inferior lumbar (Petit) triangle is formed
 - **Medially** by the latissimus dorsi muscle
 - **laterally** by the external abdominal oblique muscle
 - **Inferiorly** by the iliac crest
 - **The floor** internal abdominal oblique muscle.
- The fact that herniation occasionally occur here is of clinical importance.

Superior lumbar (Grynfeltt-Lesshaft) triangle

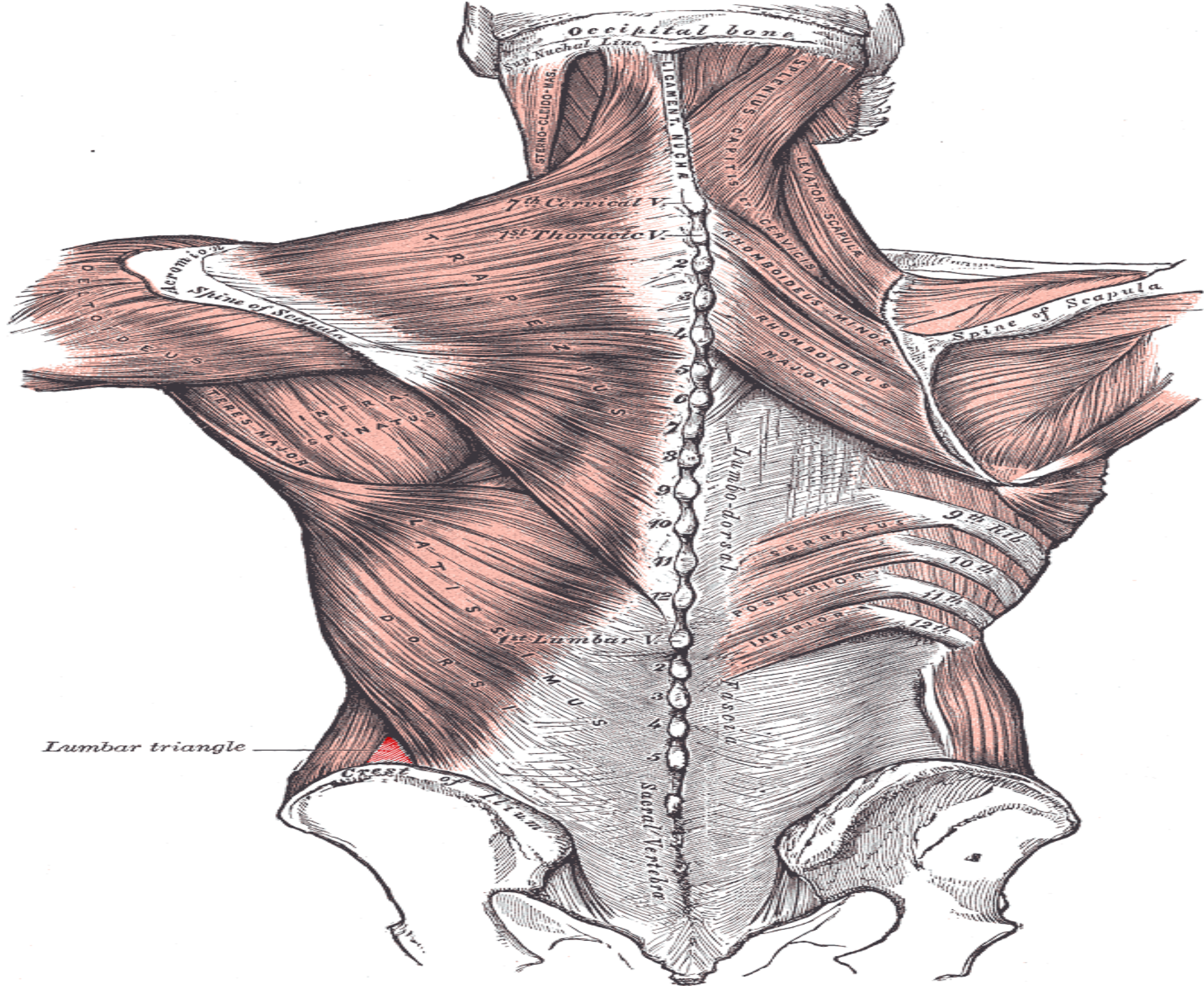
Medially: by the quadratus lumborum muscle

laterally :by the internal abdominal oblique muscle

Superiorly: by the 12th rib.

The floor : transversalis fascia

Roof: is the external abdominal oblique muscle



Action of the Ant. Abdominal muscle

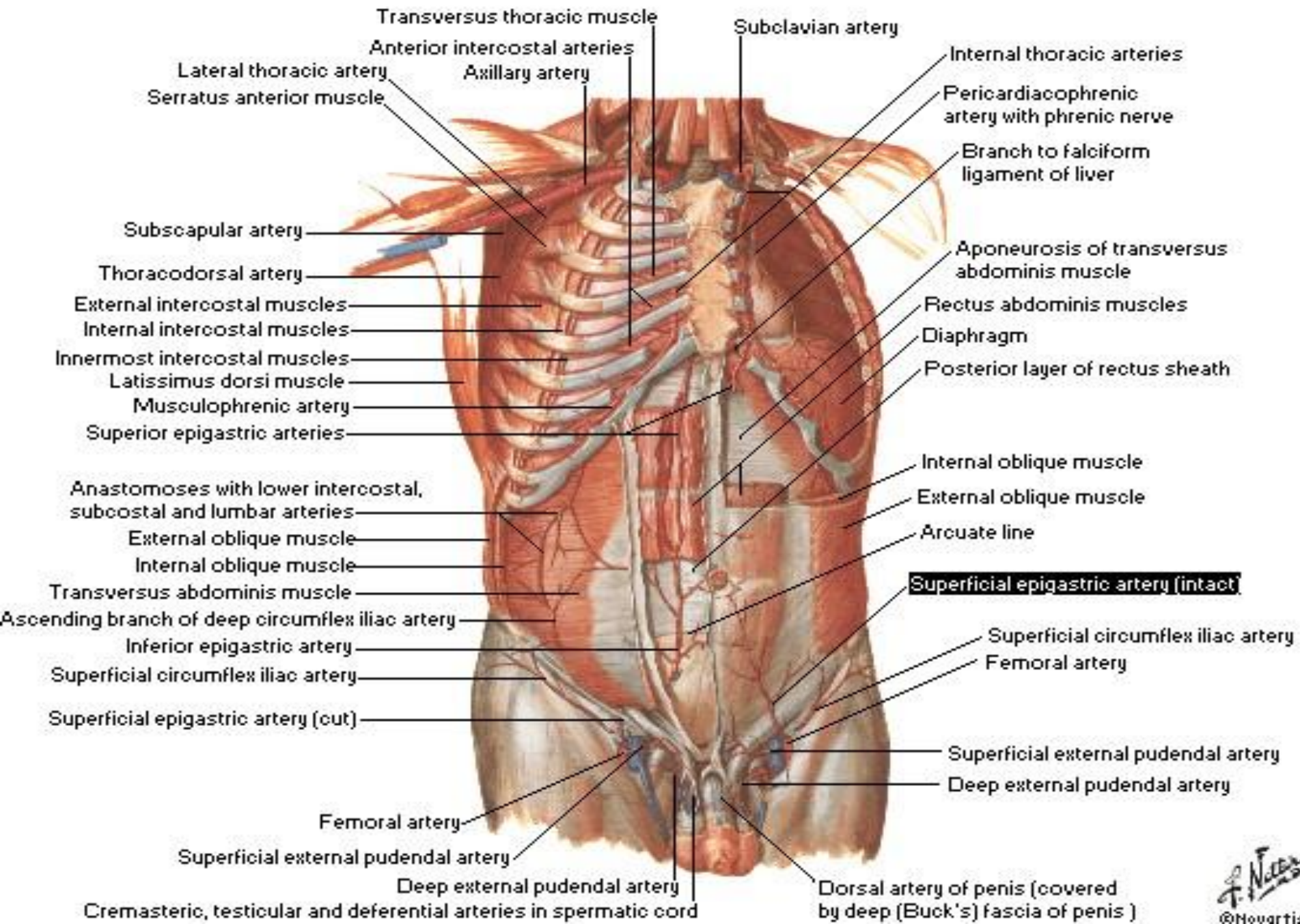
- Deep expiration
- Increase the intra abdominal pressure in
 - Vomiting
 - Cough
 - Defecation
 - Labour
- Protect viscera
- keep viscera in position
- Rectus abdominis → bends trunk forward

Blood supply of the ant. Abdominal wall

Arteries

- Sup. Epigastric artery
- Inf. Epigastric artery
- Intercostal arteries
- Lumbar arteries
- Deep circumflex artery

Arteries of Anterior Abdominal Wall



Blood supply.....cont

Veins

1- Above the umbilicus

- Lat. Thoracic. vein. → Axillary vein

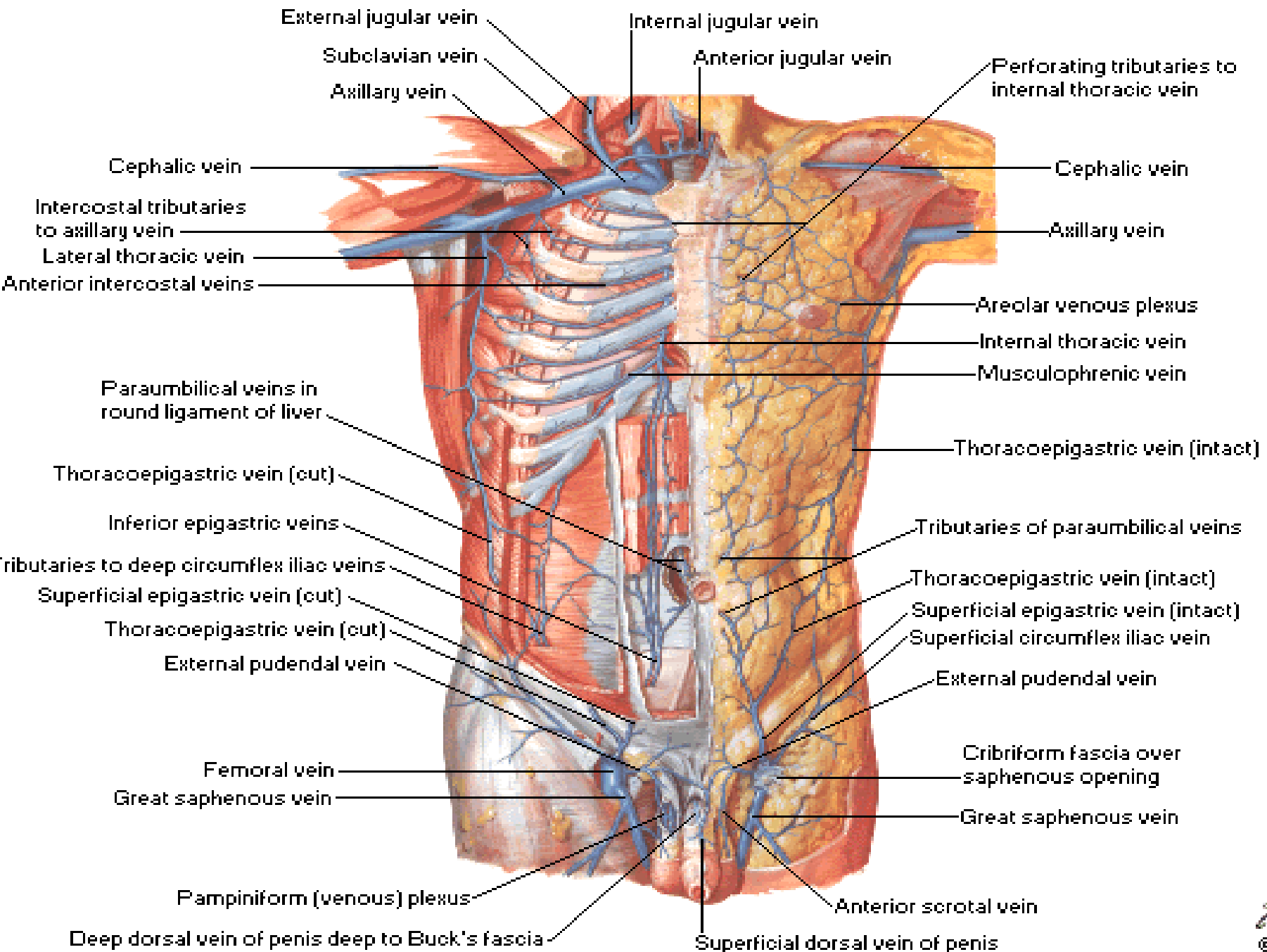
2- Below the umbilicus

- Inf. Epigastric → Femoral vein

3- Paraumbilical veins

- Ligamentum teres → portal vein(Porto- systemic anastomosis)

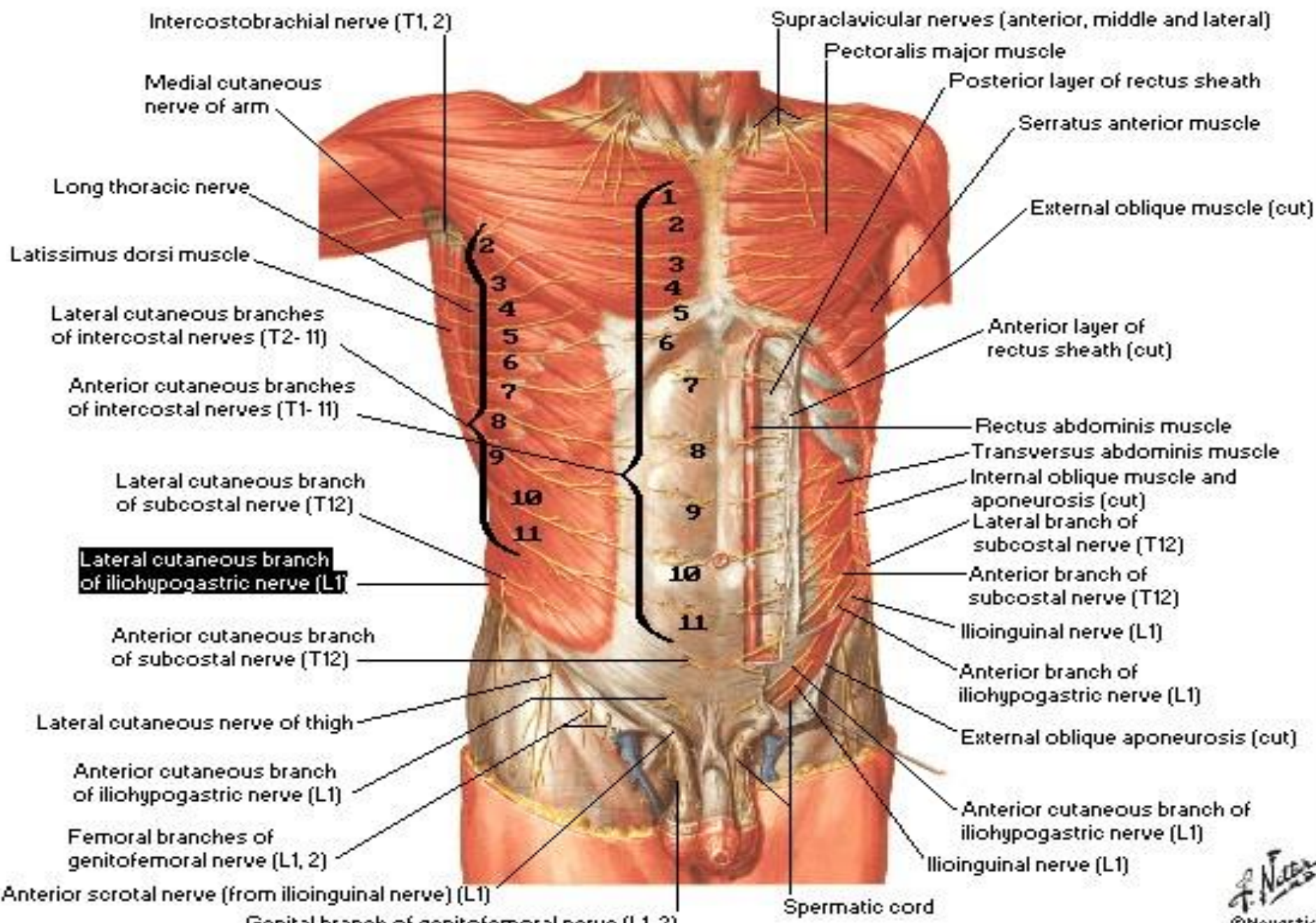
Veins of Anterior Abdominal Wall



Nerve supply of the ant. Abdominal wall

- **Thoracoabdominal nerve:** Lower 6th thoracic nerves & 12th subcostal nerve
- **Dermatomes** (Anterior, lateral cutaneous nerve terminal branches of Thoracoabdominal nerve)
 - T7 to skin superior to umbilicus below xiphoid process
 - T10 to skin surrounding umbilicus
 - L1 to skin inferior to umbilicus above sym.pubis
- **L1 nerve**
 - Iliohypogastric nerve
 - Ilioinguinal nerve

Nerves of Anterior Abdominal Wall



Lymphatic drainage of ant. Abdominal wall

- Above the umbilicus → Ant.axillary L.N
- Below the umbilicus → Sup. Inguinal L.N
- Above the iliac crest → Post.axillary.L.N
- Below the iliac crest → Sup.inguinal L.N

Clinical notes

Abdominal stab wounds

Surgical incision

Abdominal stab wounds

- Lateral to rectus sheath
- Ant. To rectus sheath
- In the midline= Linea alba
- Structures in the various layers through which an abdominal stab wound depend on the anatomical location

Surgical incision

- The length and direction of surgical incision through the ant. Abdominal wall to expose the underlying viscera are largely controlled by
 - 1- position & direction of nerves
 - 2- direction of muscle fibers
 - 3- arrangement of the apponeurosis forming the rectus sheath
- The incision should be made in the direction of the line of cleavage in the skin so that the hairline scar is produced

Incision through the rectus sheath

- Widely used
- The rectus abdominis muscle and its nerve supply are kept intact
- On closure the ant & post wall of the sheath are sutured separately and the rectus muscle back into position between the suture lines

Common types of incisions

- Paramedian incision
- Pararectus incision
- Midline incision
- Transrectus incision
- Transverse incision
- Muscle splitting
- Abdominothoracic incision