

*Dr FADi material*

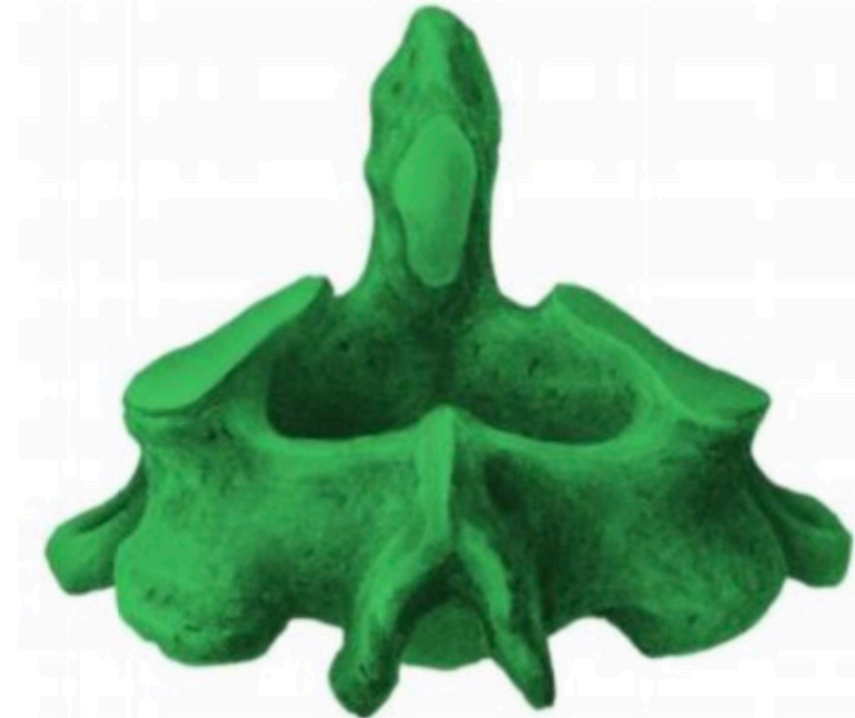
- *Which of the following muscles is NOT a muscle of the deep layer of the deep back muscles:*
- *a. Trapezius*
- *b. Semispinalis*
- *c. Multifidus*
- *d. Spinalis*
- *e. Erector spinae*
  
- *Answer: A*

- *All of the following are correct about the atlas bone except:*
- *a. No body*
- *b. Has transverse process*
- *c. Has spinous process*
- *d. Has anterior and posterior arches*
  
- *Answer: C*

- *Which of the following is wrong about lumbar vertebrae:*
- *a. They have bifid spinous processes*
- *b. They are larger than cervical vertebrae*
- *c. They have kidney-shaped body*
- *d. Their spinous processes are thick and short*
  
- *Answer: A*

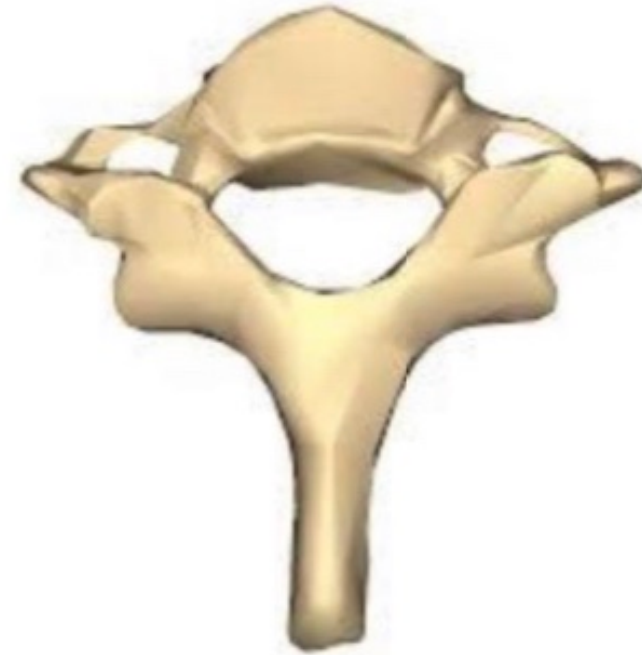- *Which of the following is true regarding deep muscles of the back:*
- *a. They help in respiration*
- *b. They are fatigue resistant*
- *c. They stabilize the shoulder girdle*
- *d. Latissimus dorsi is an example*
  
- *Answer: B*

- *Identify the vertebra:*
- *a. Atlas*
- *b. Axis*
- *c. Sacral*
- *d. Lumbar*
- *e. Seventh cervical*
  
- *Answer: B*



- *The most laterally projected rib is the:*
- *a. 10th rib*
- *b. 9th rib*
- *c. 7th rib*
- *d. 8th rib*
- *e. 4th rib*
  
- *Answer: d (maybe not required)*

- *What is the name of this vertebrae:*
- *Answer: 7th cervical vertebrae*





- *which of the following vertebrae that weight line does not pass through*
- *Answer : T11*

- *The costal process in the lumbar region participates in the formation of :*
- *a. Lamina*
- *b. Spinous process*
- *c. Superior articular process*
- *d. Transverse processes*
- *e. Pedicle*
  
- *Answer :D*

Best of luck <3