

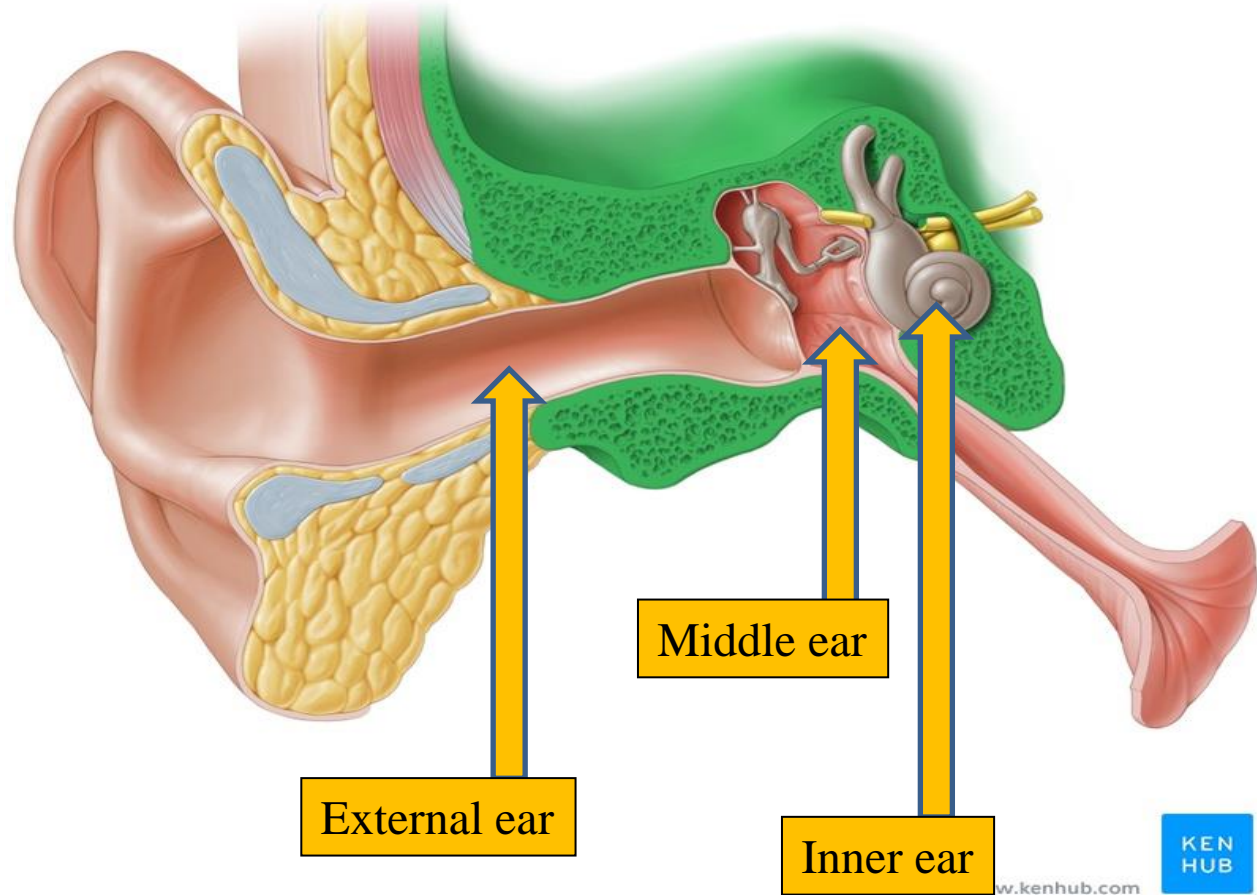


# The Ear

Dr. Heba Kalbouneh  
DDS, MSc, DMD/PhD  
Professor of Anatomy, Histology and Embryology

# The Ear


The ear consists of the external ear; the middle ear (tympanic cavity); and the internal ear (labyrinth), which contains the organs of hearing and balance.



Sound is captured by the external ear



Mechanical signals in the middle ear



The internal ear converts the mechanical signals into electrical signals to transfer information to the brain

The internal ear also contains receptors that detect motion and position

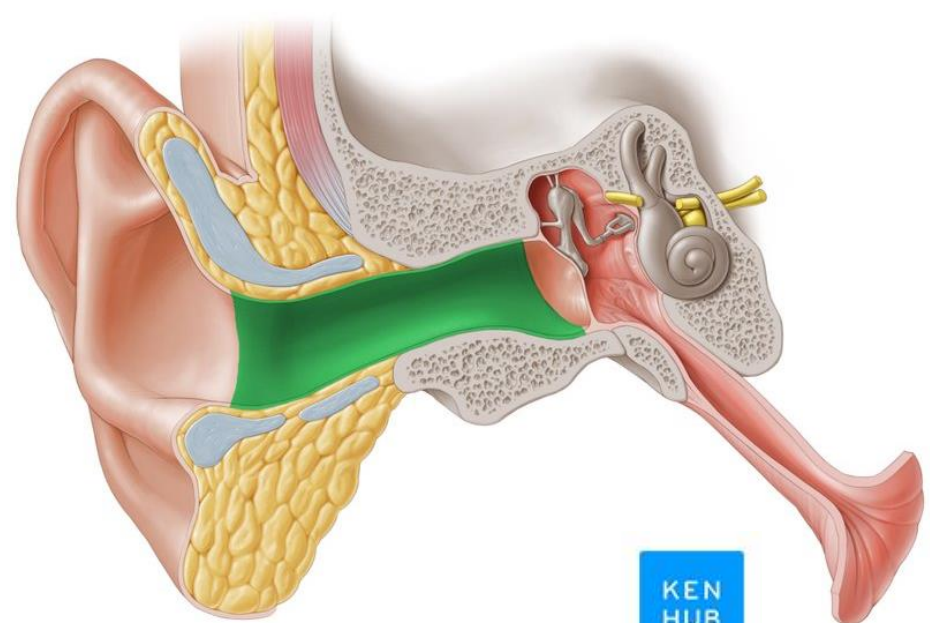
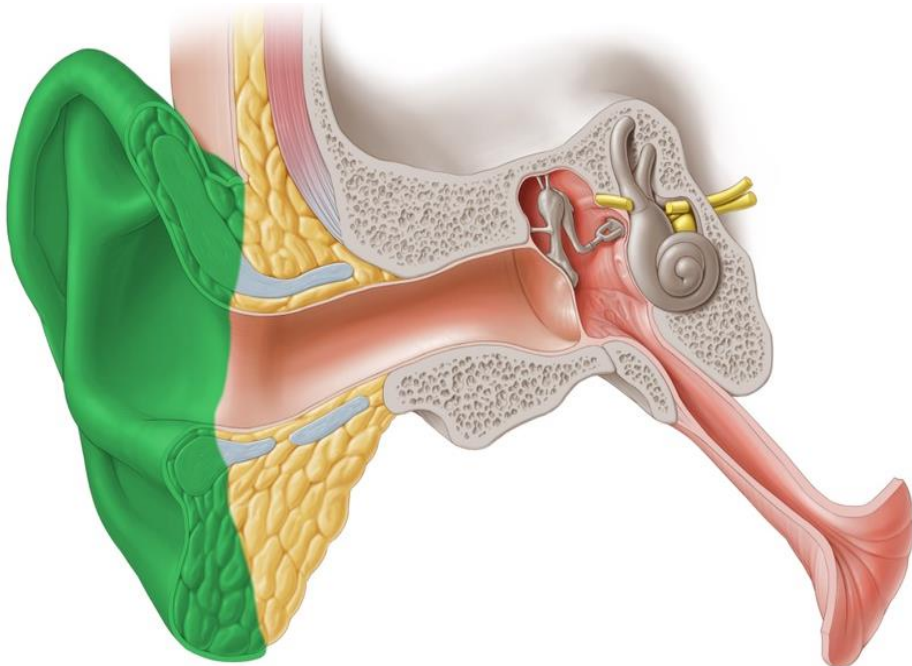
# External Ear

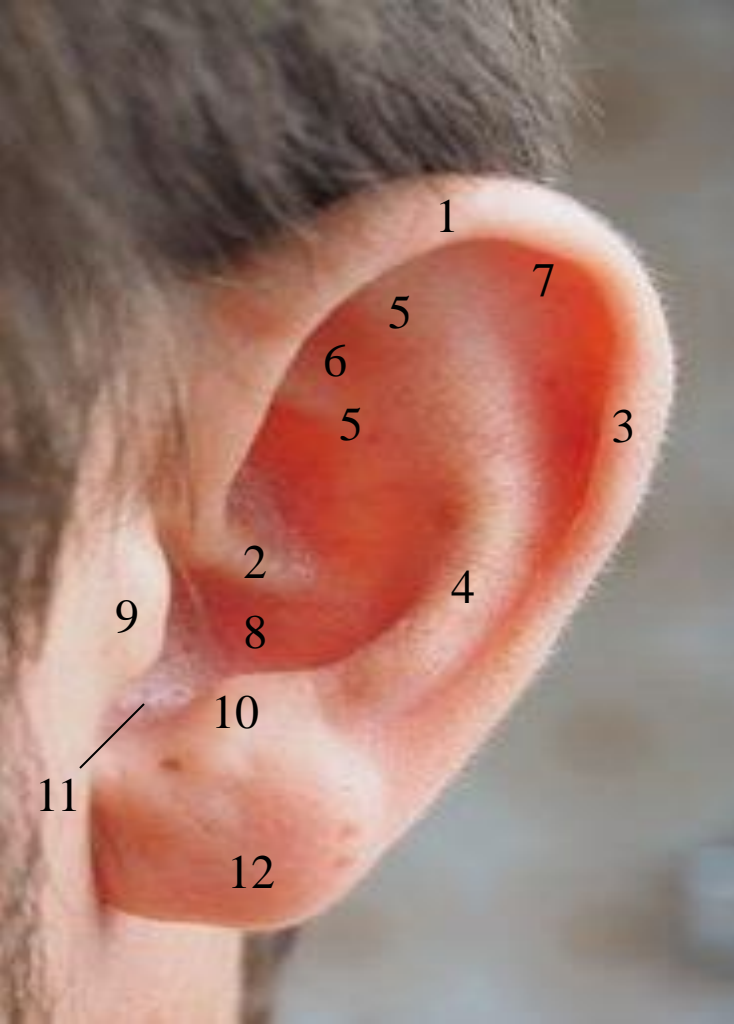## Auricle (pinna)

- ✓ The auricle has a characteristic shape
- ✓ It collects air vibrations
- ✓ It consists of a thin plate of elastic cartilage covered by skin

## External auditory meatus

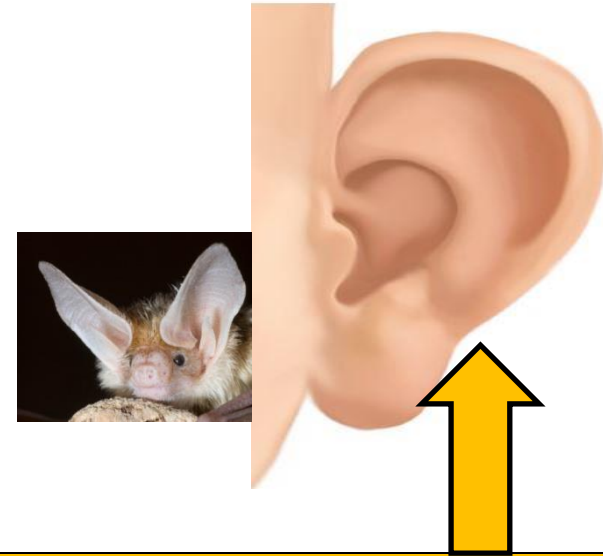- ✓ The external auditory meatus is a curved tube that leads from the auricle to the tympanic membrane
- ✓ It conducts sound waves from the auricle to the tympanic membrane





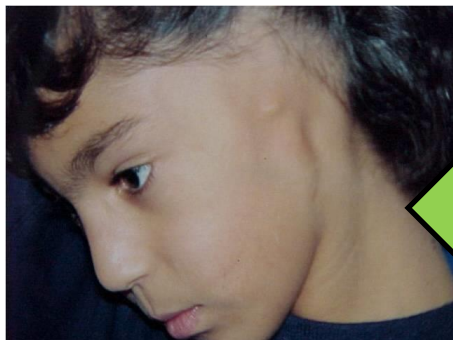1. **Helix.**
2. Crus of helix
3. Auricular tubercle.
4. **Antihelix.**
5. Crura of antihelix.
6. Triangular fossa.
7. Scaphoid fossa.
8. **Concha of auricle.**
9. **Tragus.**
10. **Antitragus.**
11. Intertragic notch.
12. **Lobule of auricle.**

The cartilage of the auricle is arranged in a pattern of elevations and depressions



Required

**Prominent ears (also known as 'bat' ears) are caused by the absence or inadequacy of an antihelical fold.**



Read only

**Anotia is complete absence of the external ear, and is most likely caused by a developmental disturbance between the seventh and eighth gestational week.**

# Nerve supply of the auricle

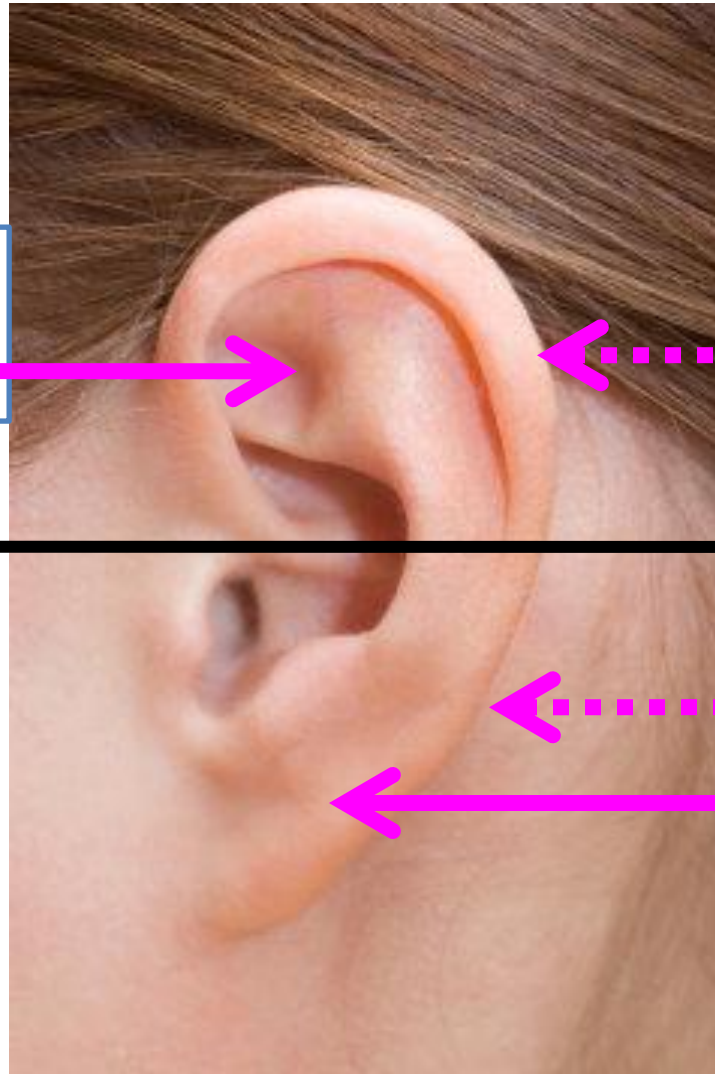
**Auriculotemporal nerve:**  
upper part of the outer  
surface

**Lesser occipital nerve:**  
the upper part of the  
inner surface

**Great auricular nerve:**  
the lower part of both  
inner and outer  
surfaces

Note that the Auricular branches of vagus and facial nerves supply deeper parts of the auricle

*!!!!The cough reflex via the vagus nerve*



# The external auditory meatus

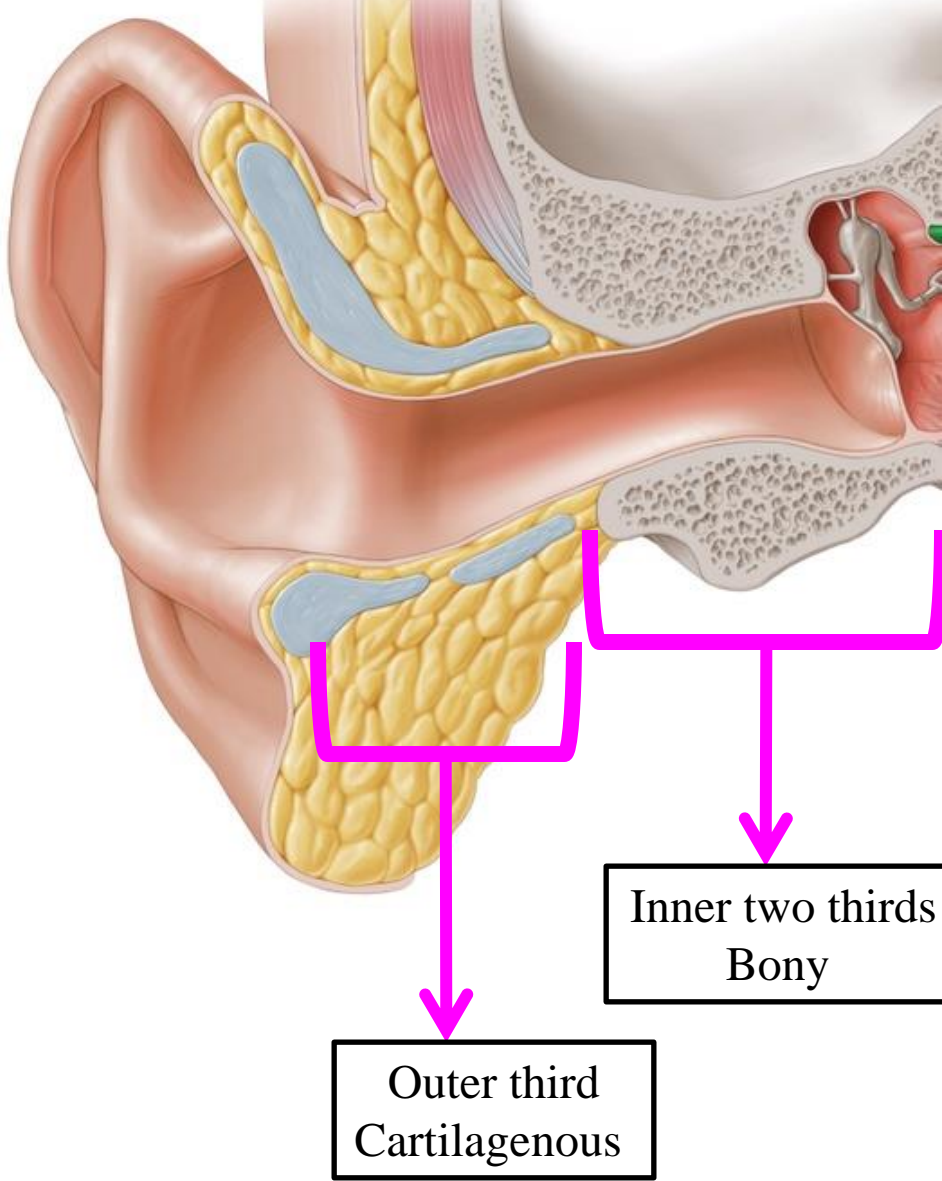
- ✓ The framework of the outer third of the meatus is elastic cartilage, and the inner two thirds is bone
- ✓ The meatus is lined by skin
- ✓ The outer third is provided with hairs and sebaceous and ceruminous glands

**Ceruminous glands** are modified sweat glands that secrete (along with the sebaceous glands) a yellowish brown wax (cerumen=earwax)

The hairs and the wax provide a sticky barrier that prevents the entrance of foreign bodies



Cerumen is produced in the outer third of the ear canal  
pH is acidic in normal healthy canals.  
Contains a bactericidal enzyme.

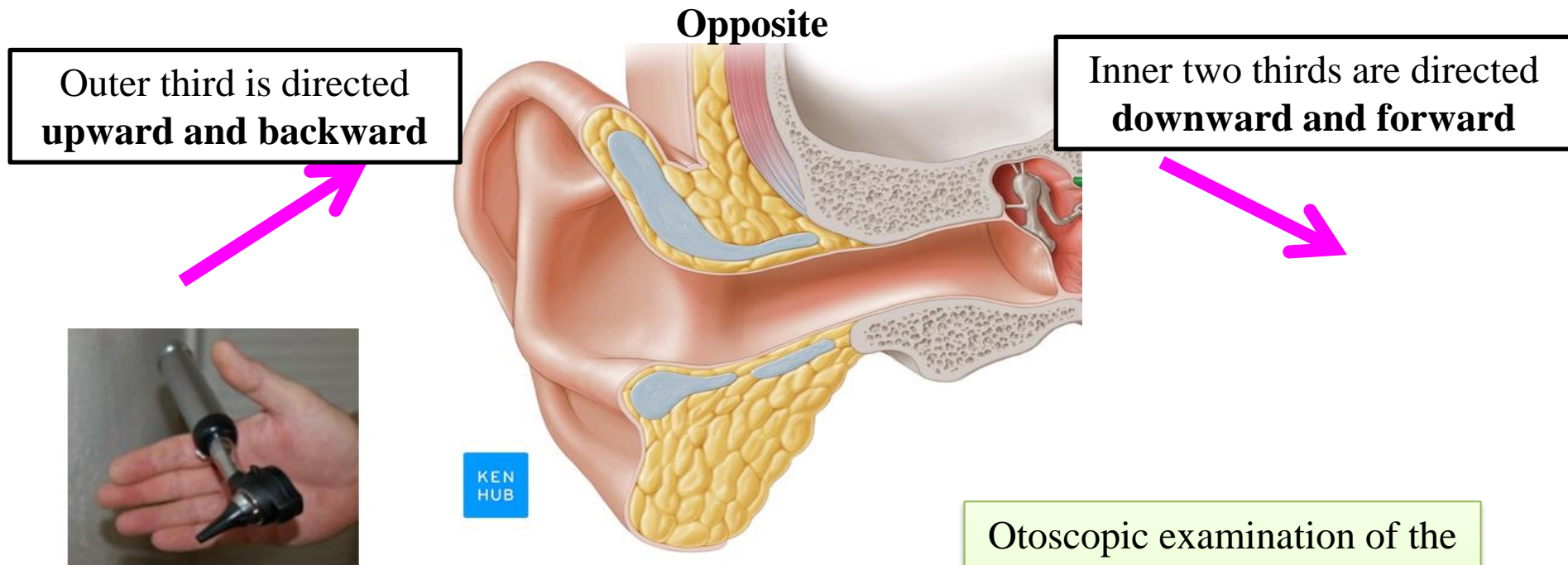


Inner two thirds  
Bony


Outer third  
Cartilaginous



# External acoustic meatus



Move the mobile part to make meatus straight

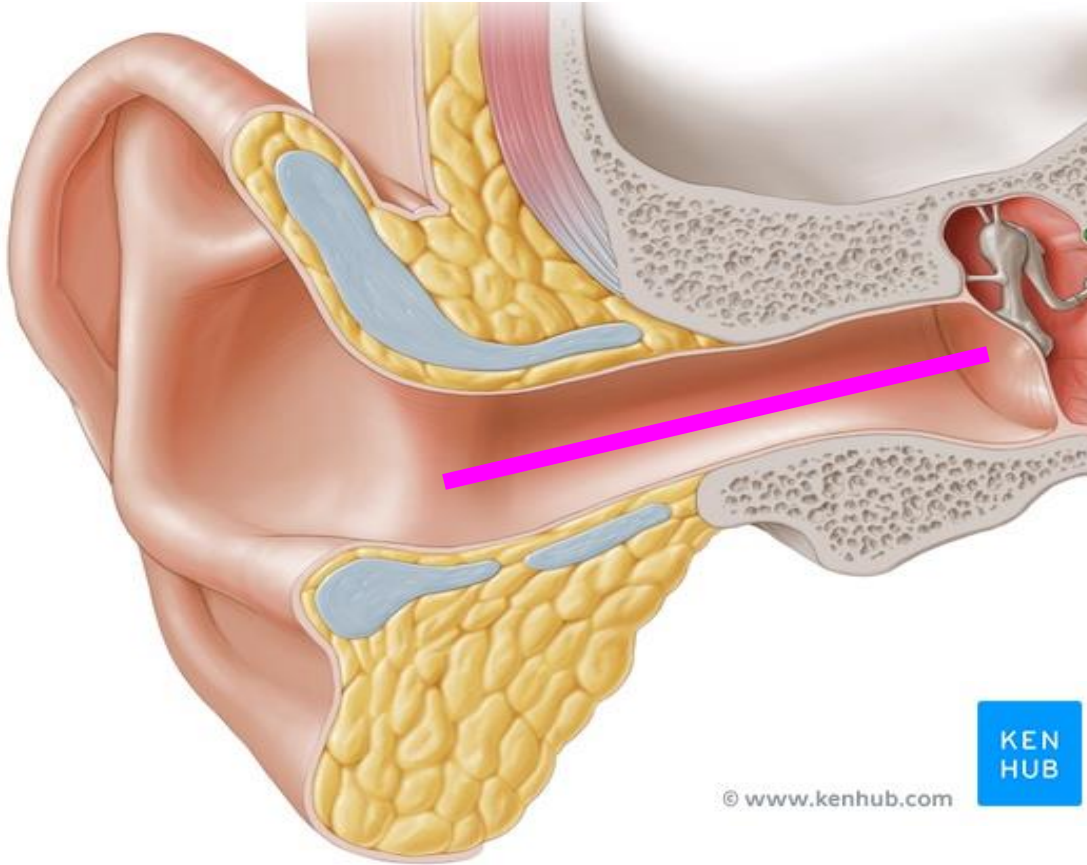


Otoscopic examination of the tympanic membrane is facilitated by first straightening the external auditory meatus by gently pulling the auricle **upward and backward** in the **adult**

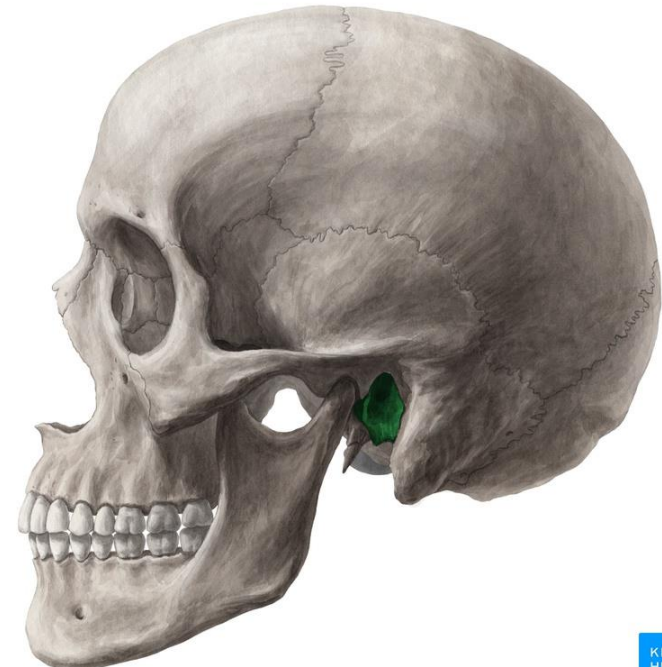This straightens the ear canal and improves visualization.



In the adult the external meatus is about 1 in. (2.5 cm) long and is narrowest about 0.2 in. (5 mm) from the tympanic membrane



**External acoustic meatus**





# The Tympanic membrane (ear drum)

Is a thin, fibrous membrane

Is formed of:

1-Outer layer:

Skin

2- Middle layer:

Fibrous tissue

3-Inner layer:

Mucous membrane

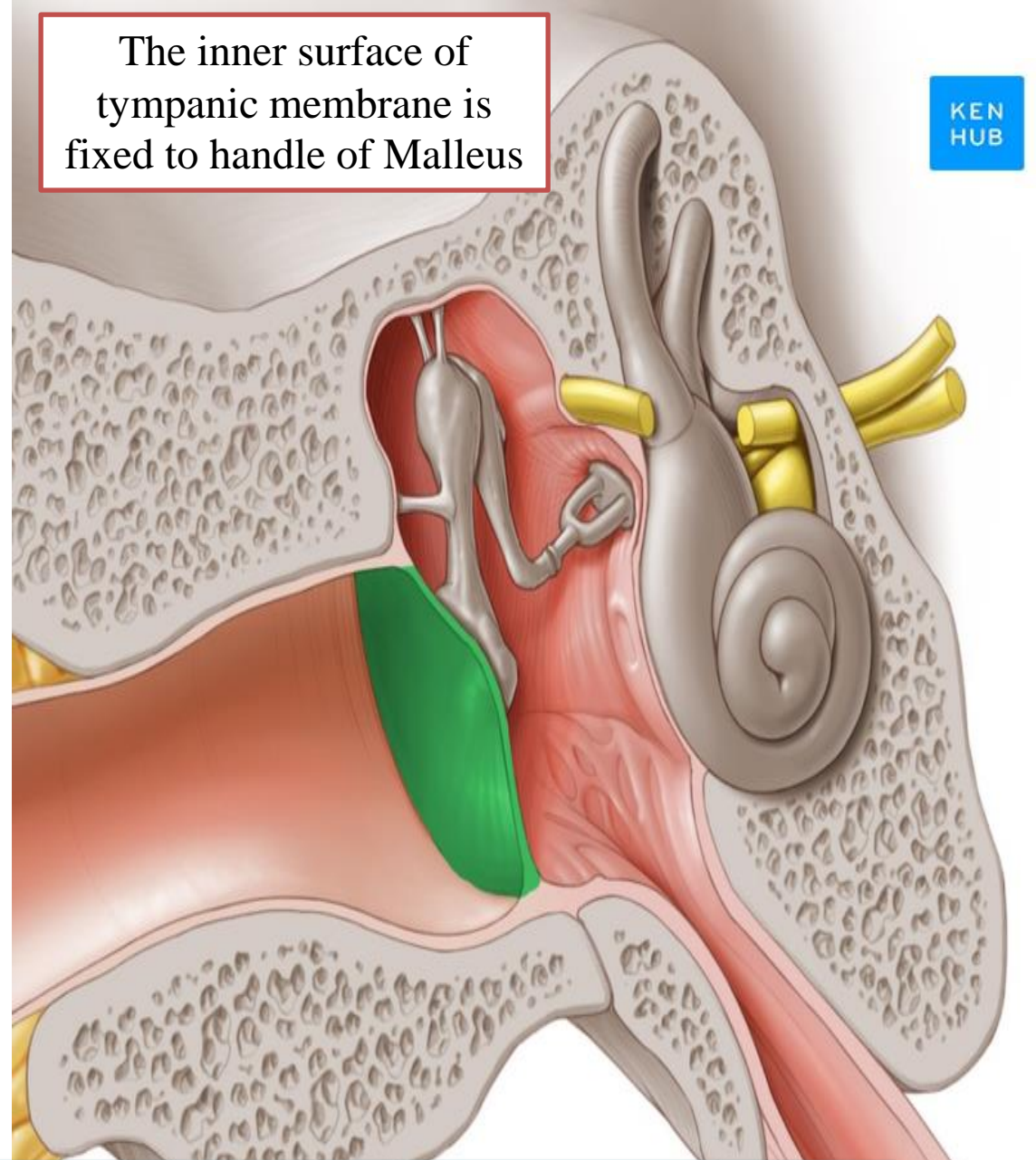
✓ It is concave laterally

✓ **Umbo** is a small depression produced by the tip of the handle of the malleus

The membrane is obliquely placed, facing downward, forward, and laterally

The inner surface of tympanic membrane is fixed to handle of Malleus

KEN  
HUB

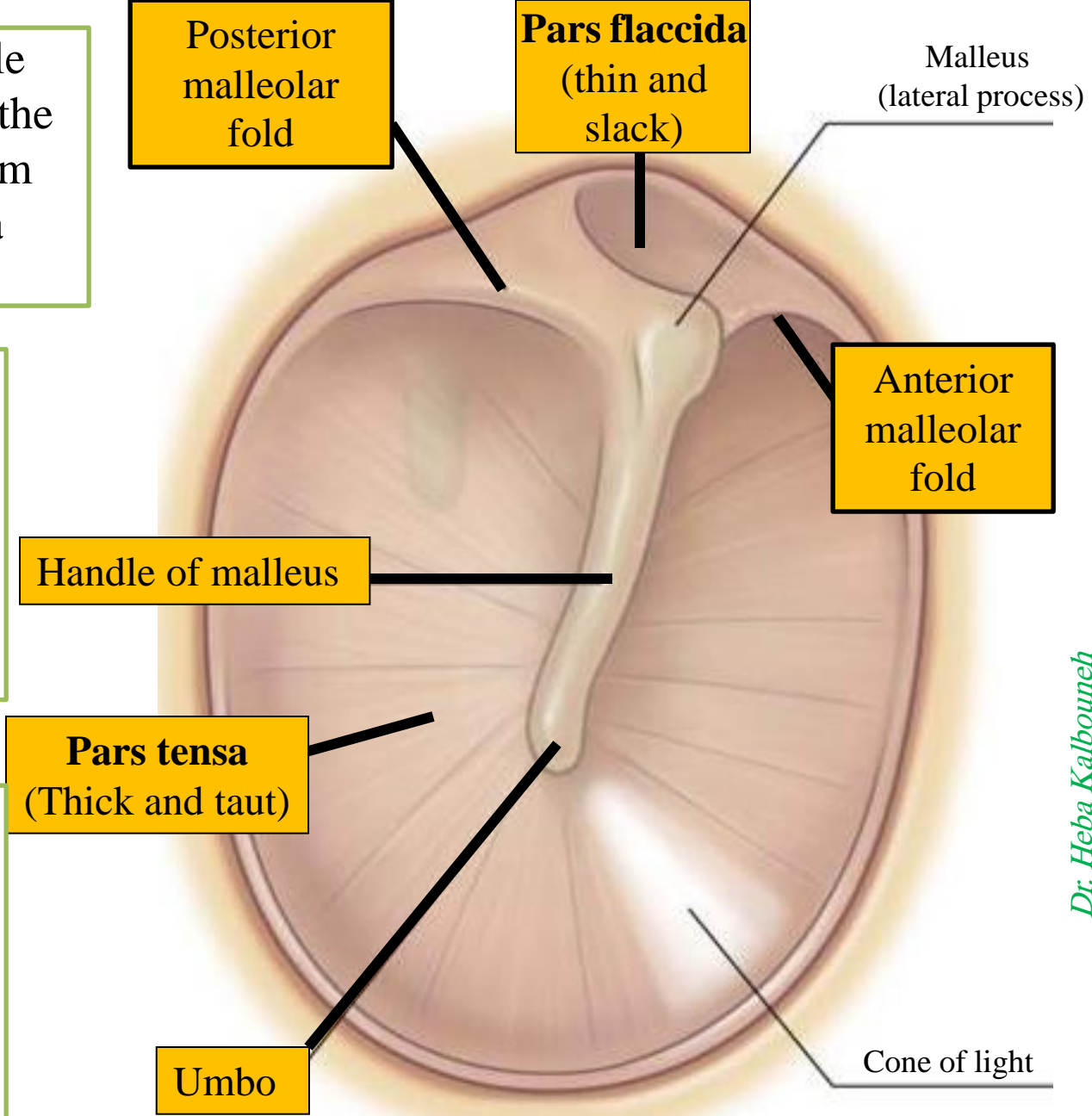


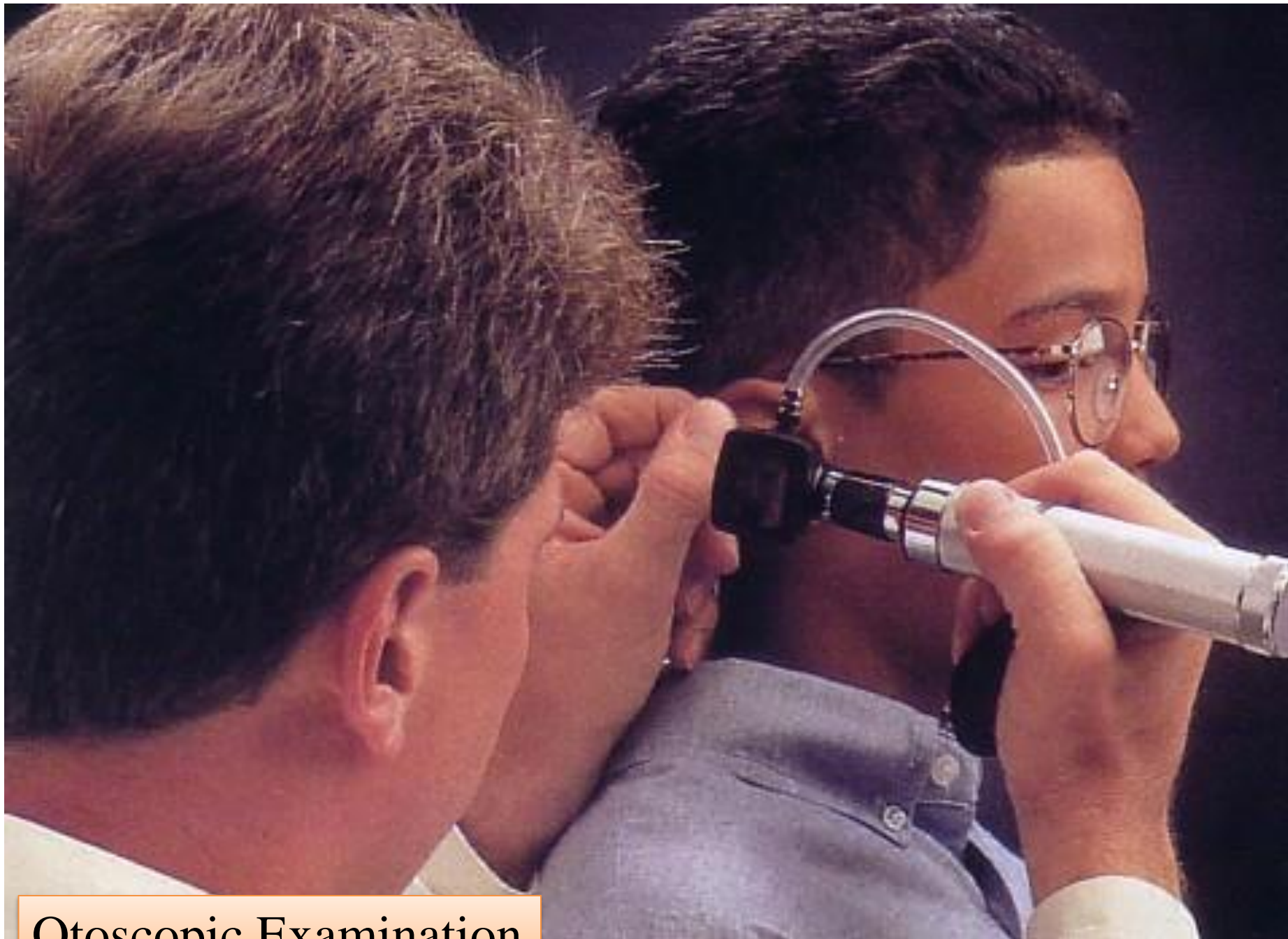
Remember that the middle fibrous layer is present in the major parts of the ear drum which called **pars tensa**

However, this layer is absent in the upper part of the ear drum which is called **pars flaccida** (Shrapnell's membrane) (Rivinus' ligament)

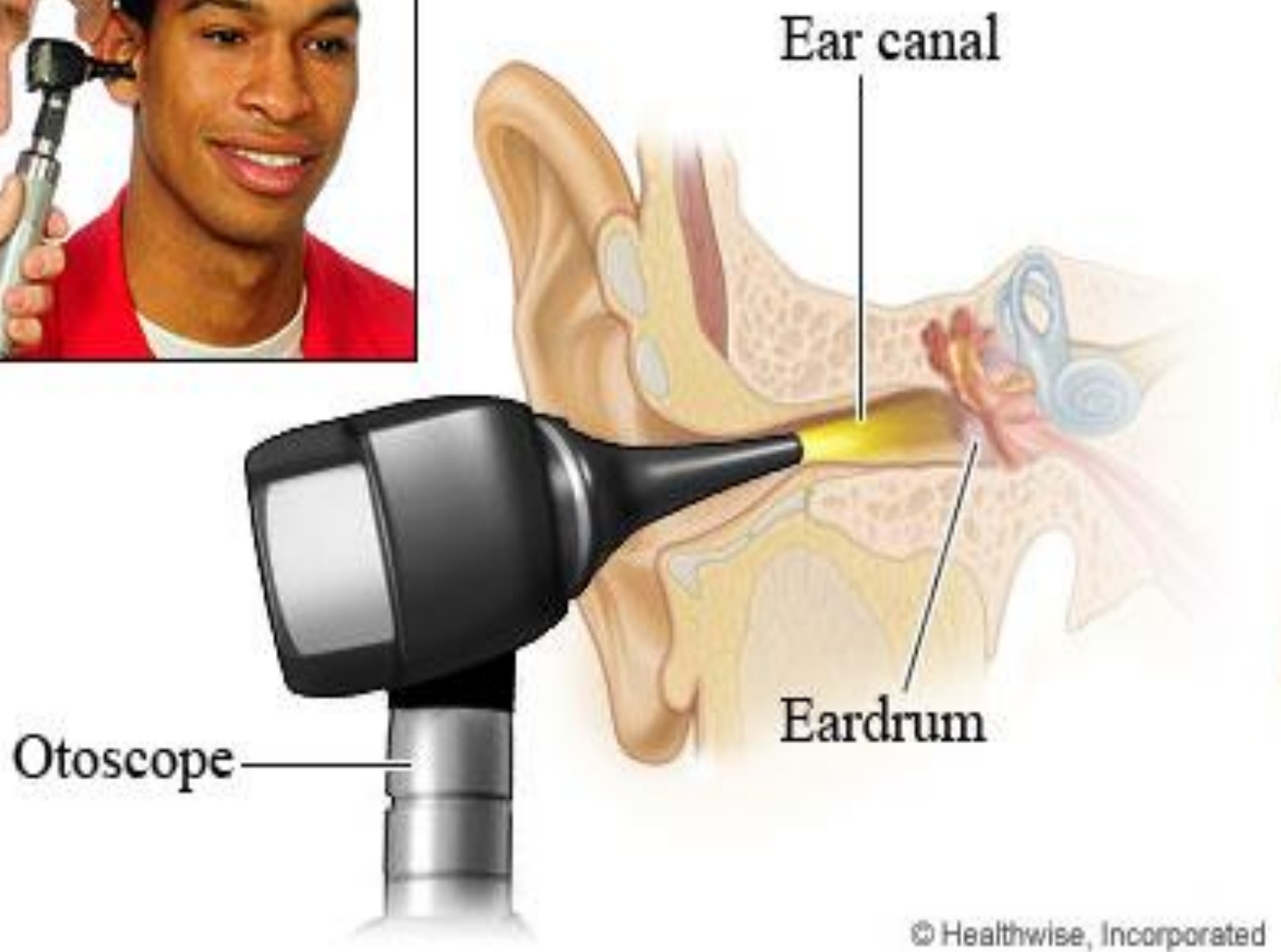The pars tensa and flaccida are separated from each other by two folds called the anterior and posterior malleolar folds

The tympanic membrane is extremely sensitive to pain





Otoscopic Examination



### Note

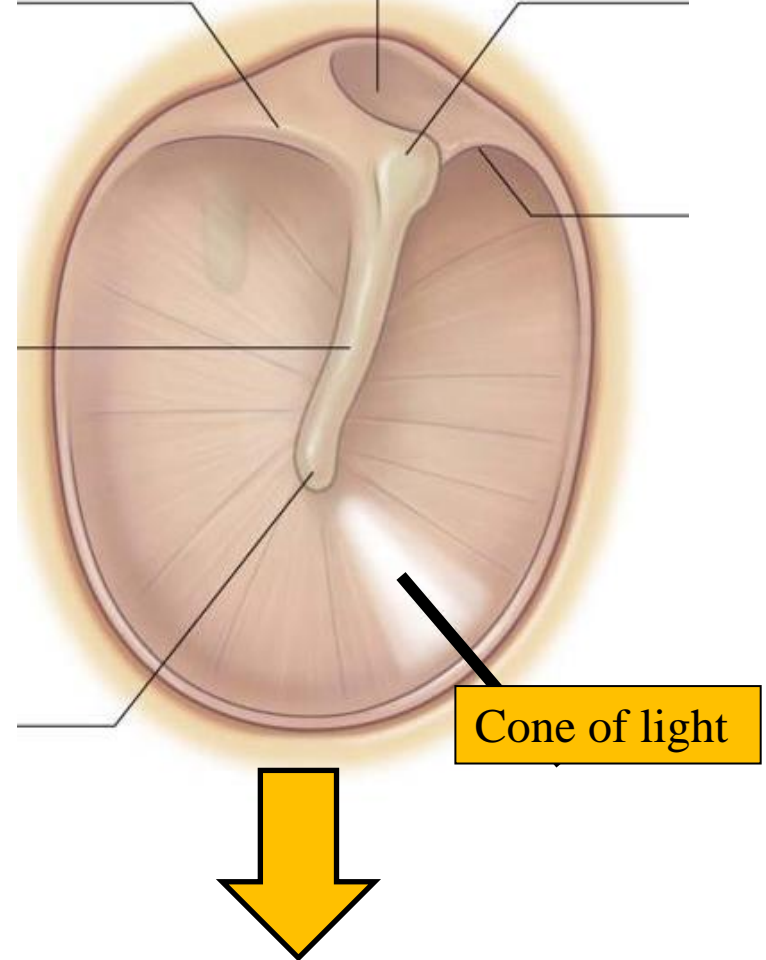
The translucency of the tympanic membrane allows the structures within the middle ear to be observed during otoscopy.

When the membrane is illuminated through an otoscope, the concavity produces a cone of light, which radiates anteriorly and inferiorly from the umbo

### Clinical application

The tympanic membrane is a relatively thin connective tissue structure, and is susceptible to **perforation** (usually by trauma or infection).

An infection of the middle ear (**otitis media**) causes pus and fluid to build up behind the tympanic membrane. This causes an increase in pressure within the middle ear, and eventually the eardrum can rupture.



- ✓ The tympanic membrane is pearly white or light gray, and you can see through it.
- ✓ You can see the tiny bones of the middle ear pushing on the tympanic membrane.

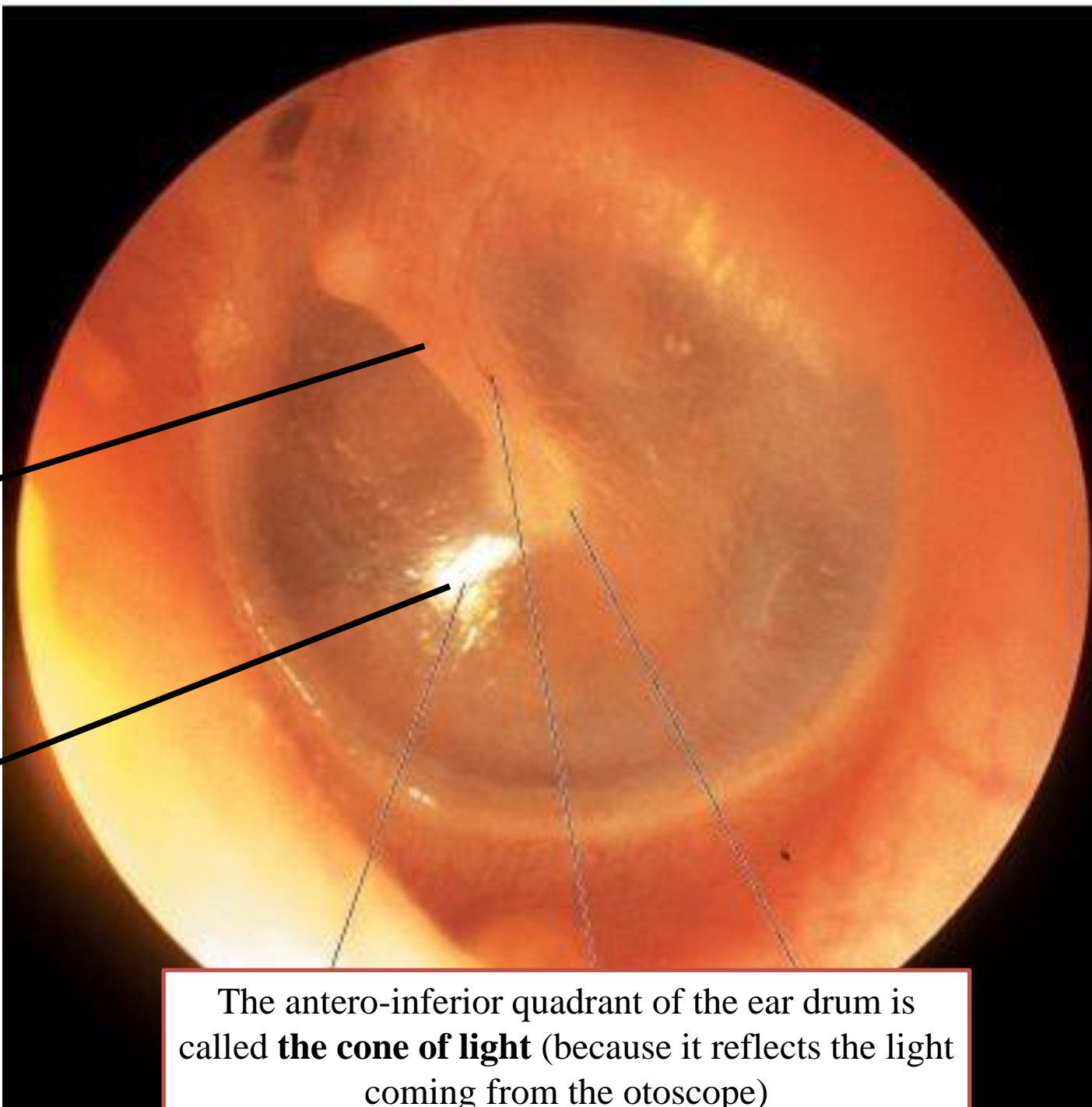
# Lateral surface of tympanic membrane

Handle of malleus

Cone of light

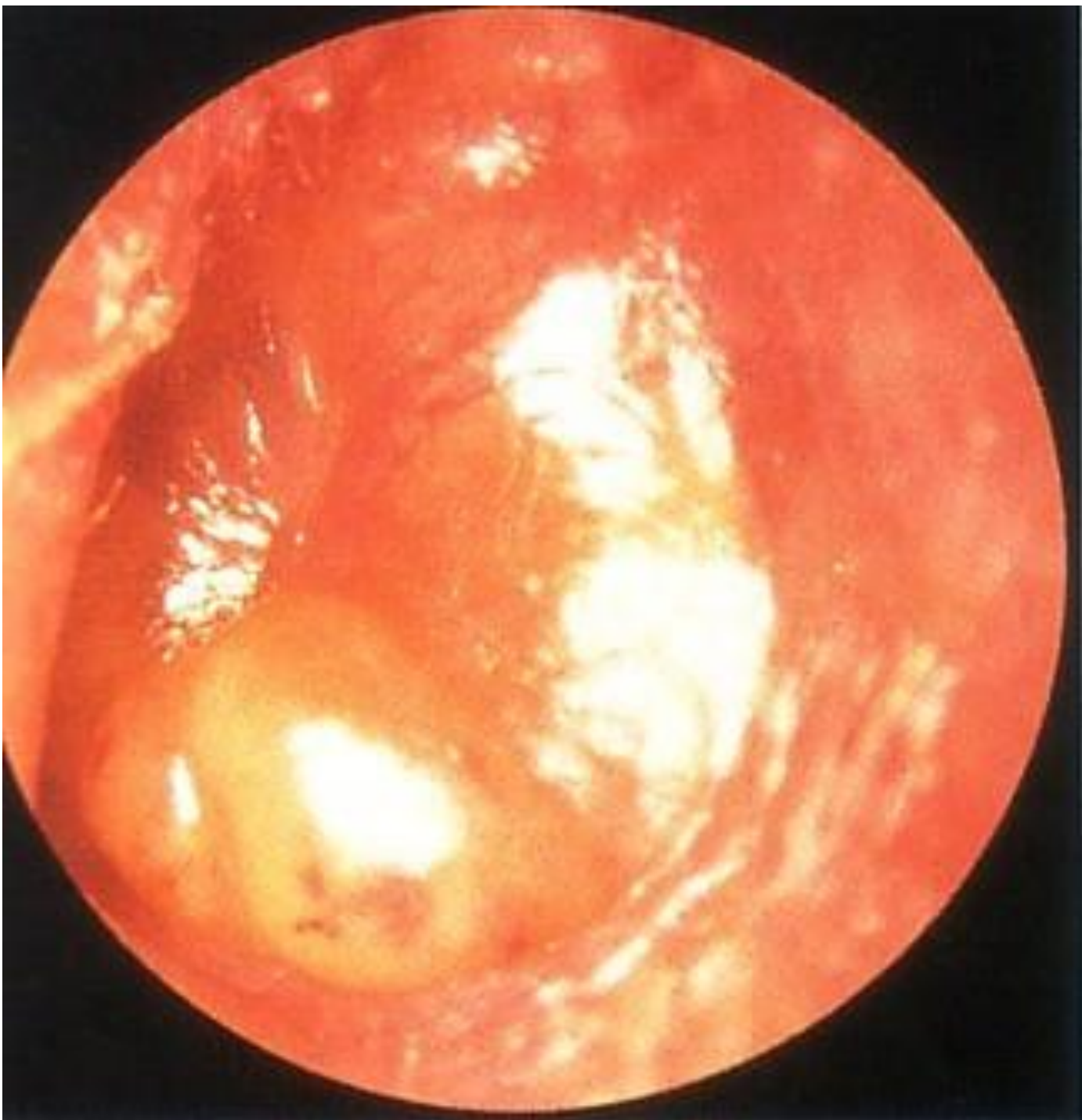Note the tympanic membrane is translucent, concave laterally

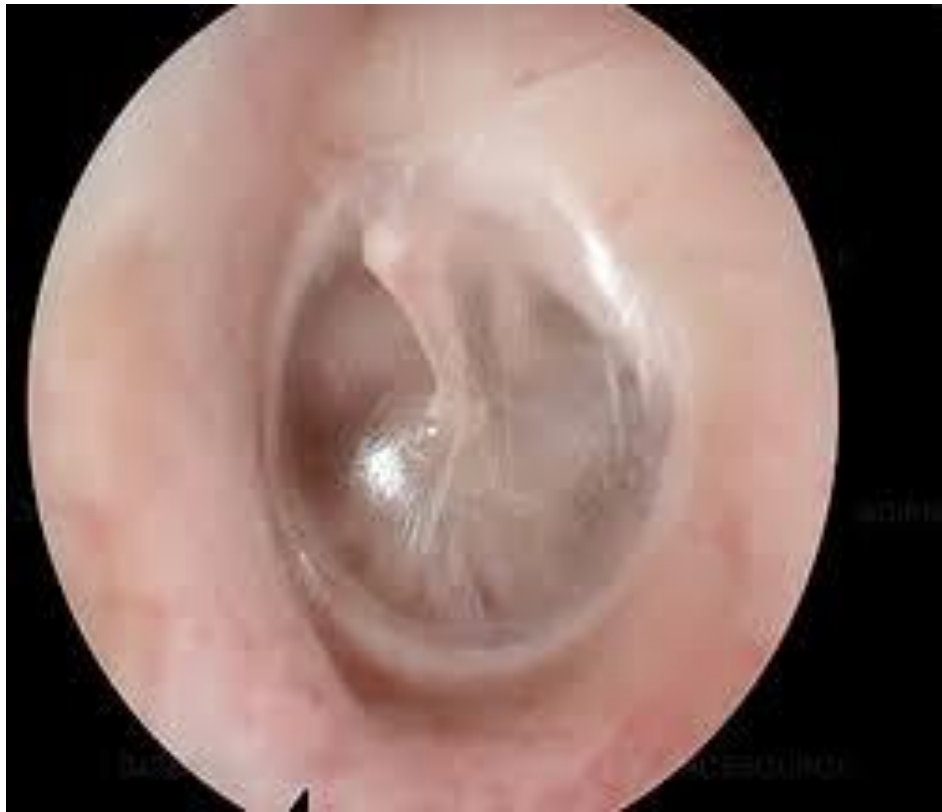The antero-inferior quadrant of the ear drum is called **the cone of light** (because it reflects the light coming from the otoscope)



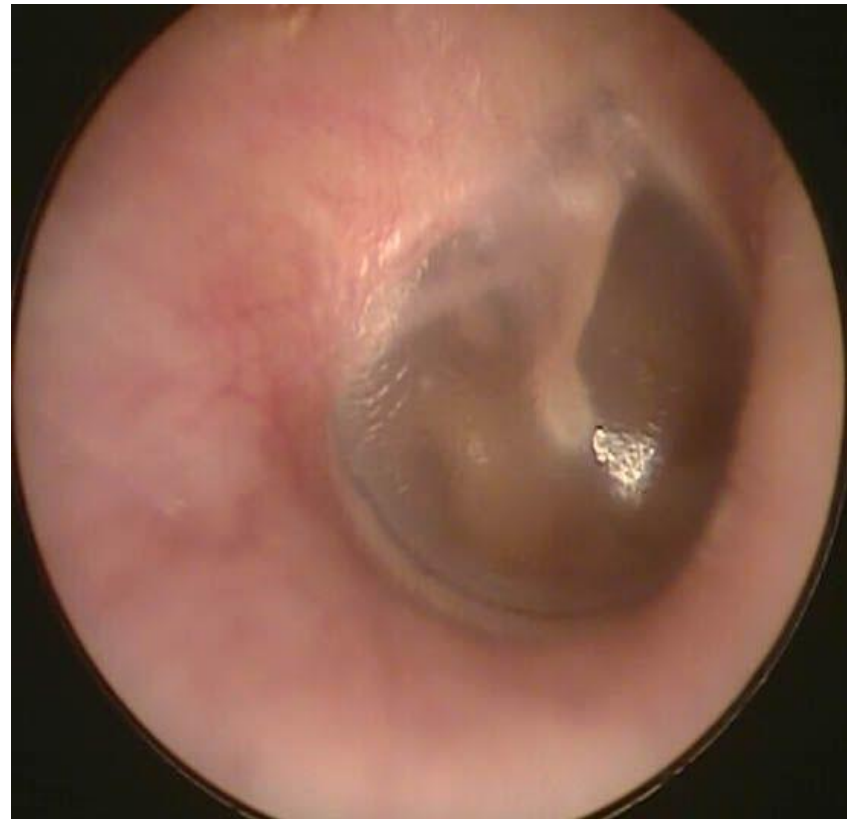
# Otitis media

The light reflex on the tympanic membrane is dull or absent. The tympanic membrane is red and bulging. You can often see amber liquid or bubbles behind the eardrum.





Left tympanic membrane



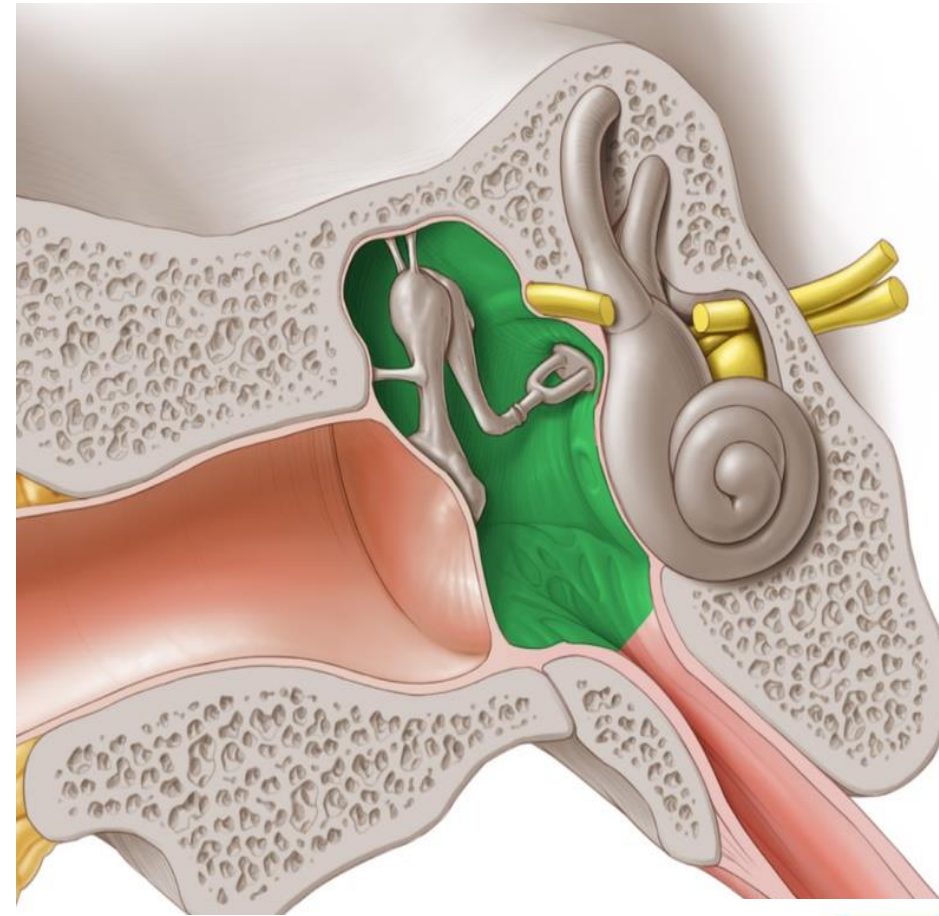
Right tympanic membrane

The cone of light is at the 5 o'clock position in the right ear and at the 7 o'clock position in the left ear.



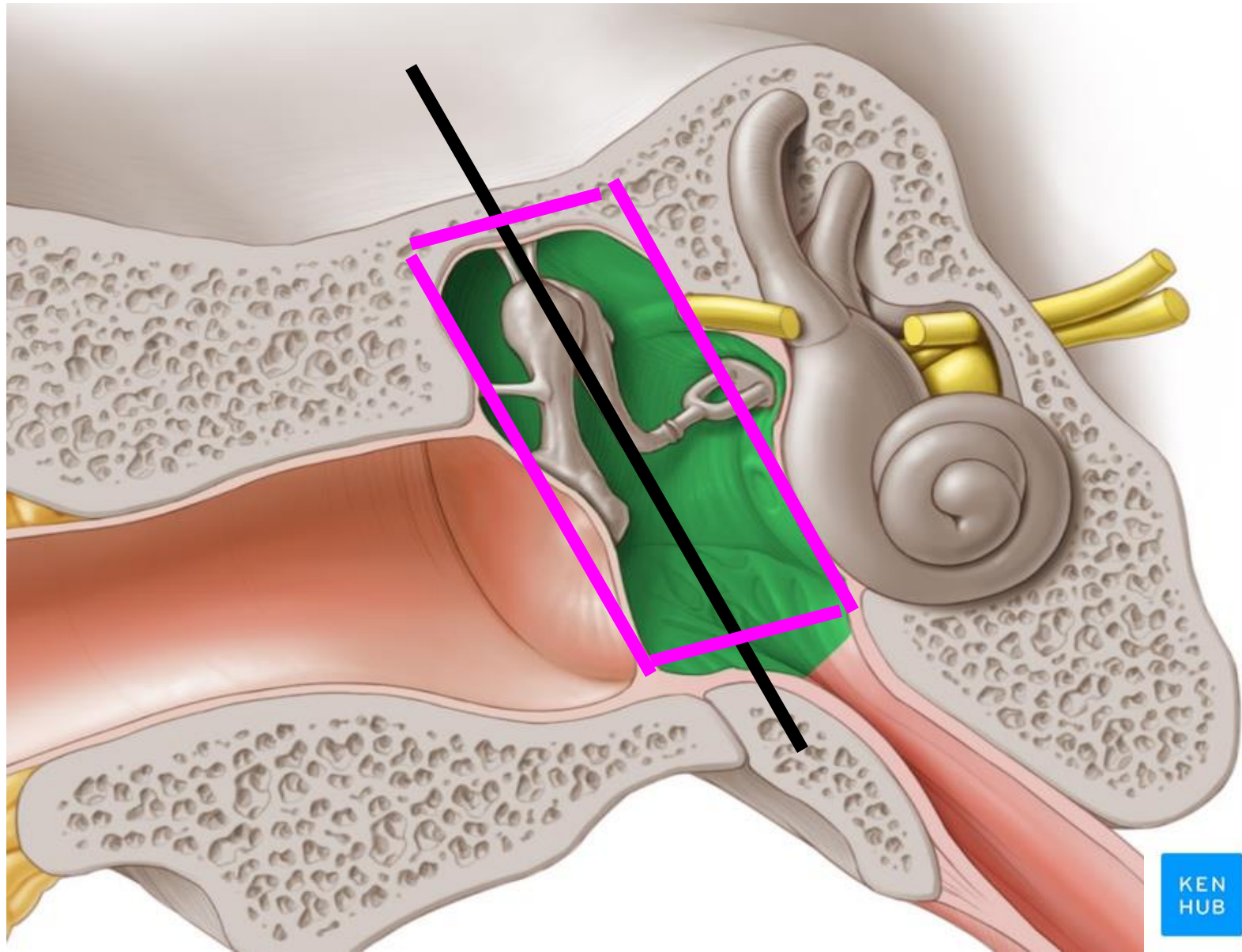
# Middle Ear (Tympanic Cavity)

- Is an air-containing cavity in the petrous part of the temporal bone
- Is lined with mucous membrane
- It contains the auditory ossicles, whose function is to transmit the vibrations of the tympanic membrane (eardrum) to the inner ear

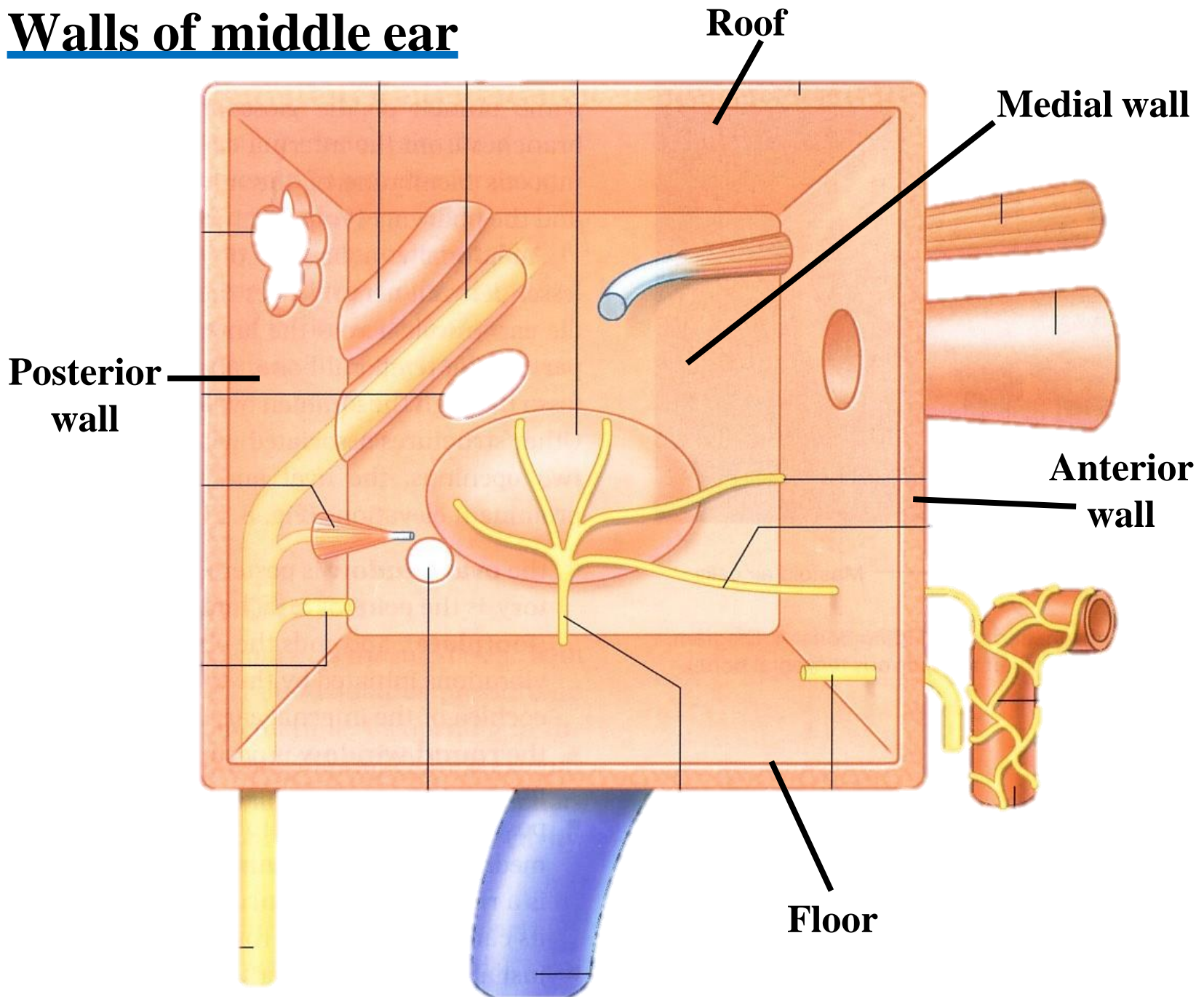


**The middle ear has**  
**ROOF**  
**FLOOR**  
**ANTERIOR WALL**  
**POSTERIOR WALL**  
**LATERAL WALL**  
**MEDIAL WALL**

Tympanic cavity (middle ear) is a narrow, oblique, slitlike cavity whose long axis lies approximately parallel to the plane of the tympanic membrane



# Walls of middle ear



# Roof

## TEGMENTAL WALL

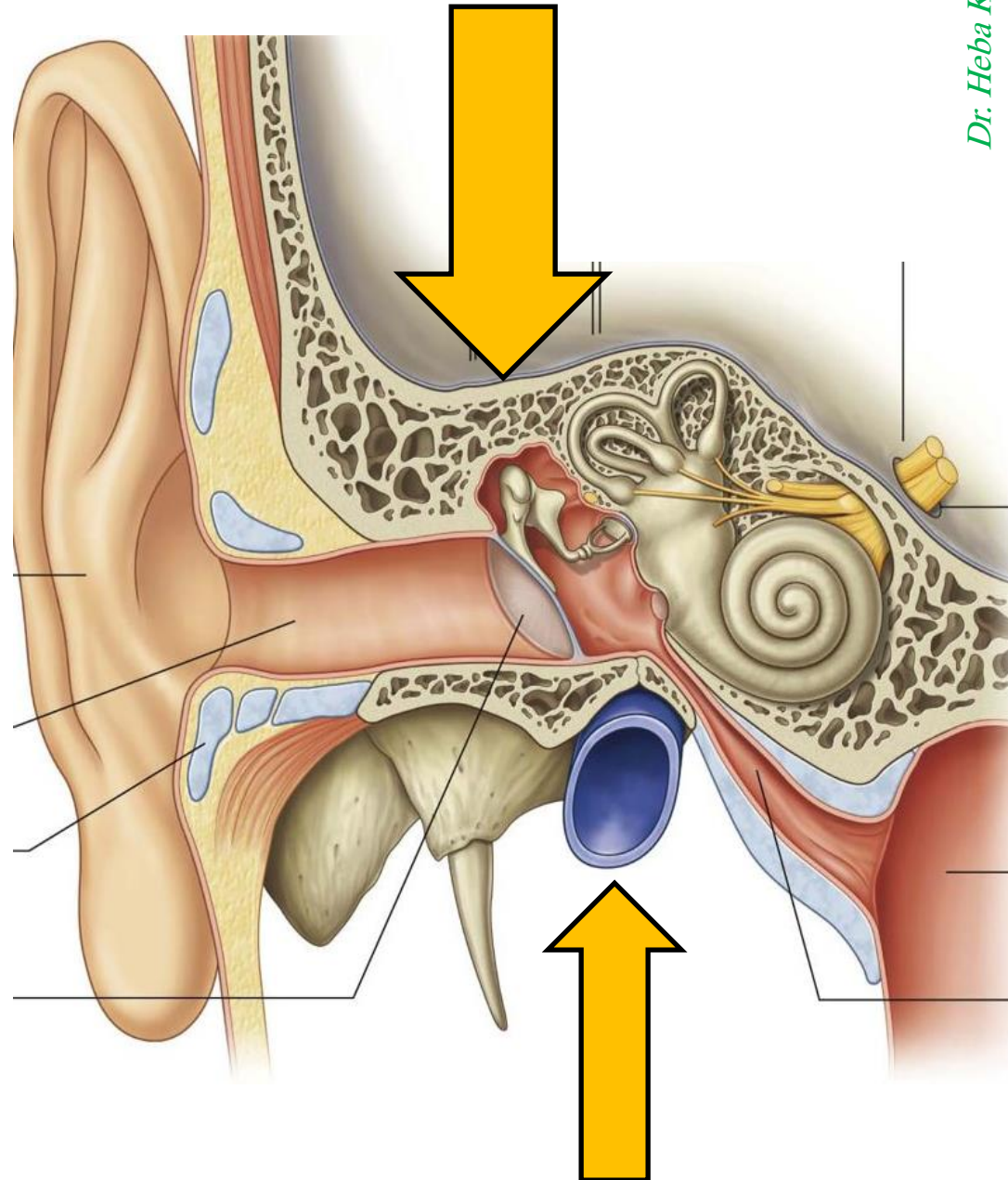
Is formed by **tegmen tympani** (part of the petrous temporal bone)

It separates the tympanic cavity from the **meninges and the temporal lobe** of the brain in the middle cranial fossa.

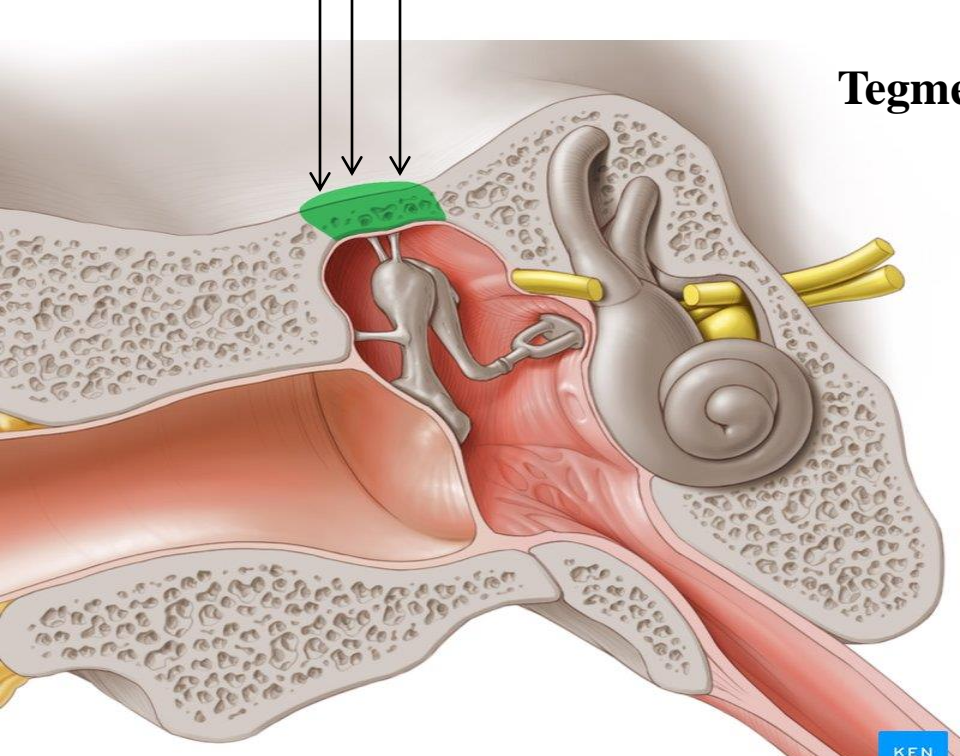
# Floor

## JUGULAR WALL

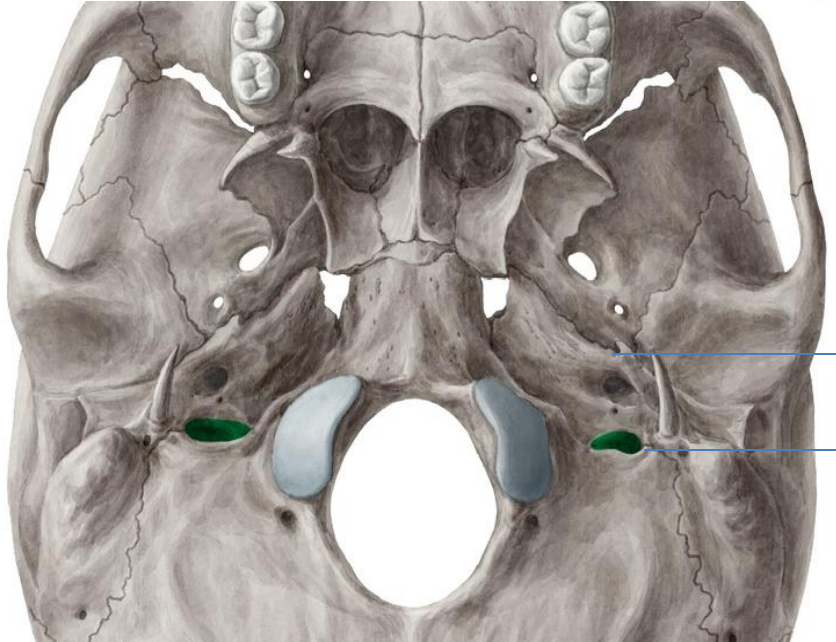
It separates the tympanic cavity from the **internal jugular vein**



# Tegmen tympani



© www.kenhub.com  
KEN HUB



Petrous bone

Jugular foramen

KEN HUB

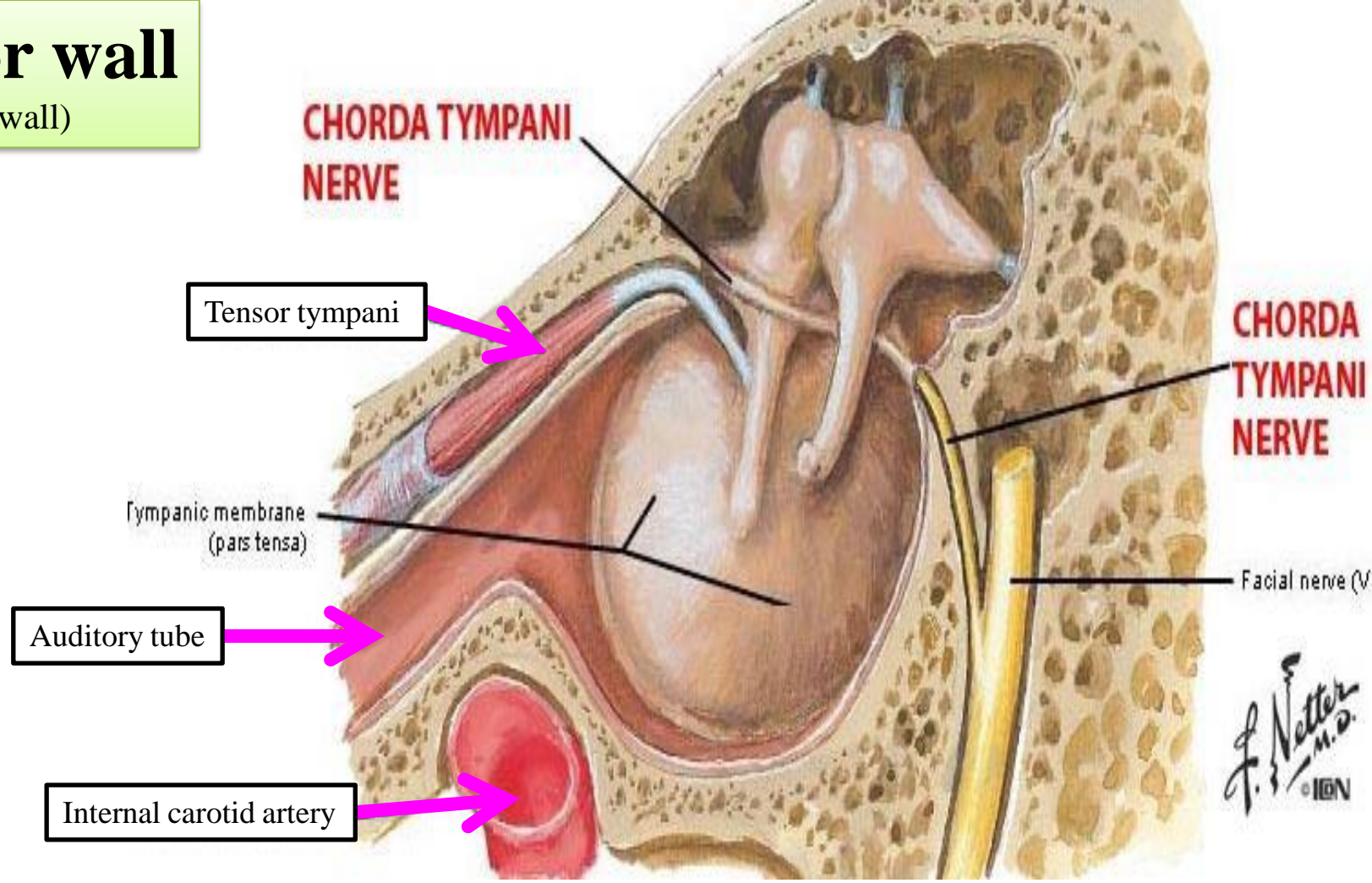
Dr. Heba Kalbouneh

# Anterior wall

(carotid wall)

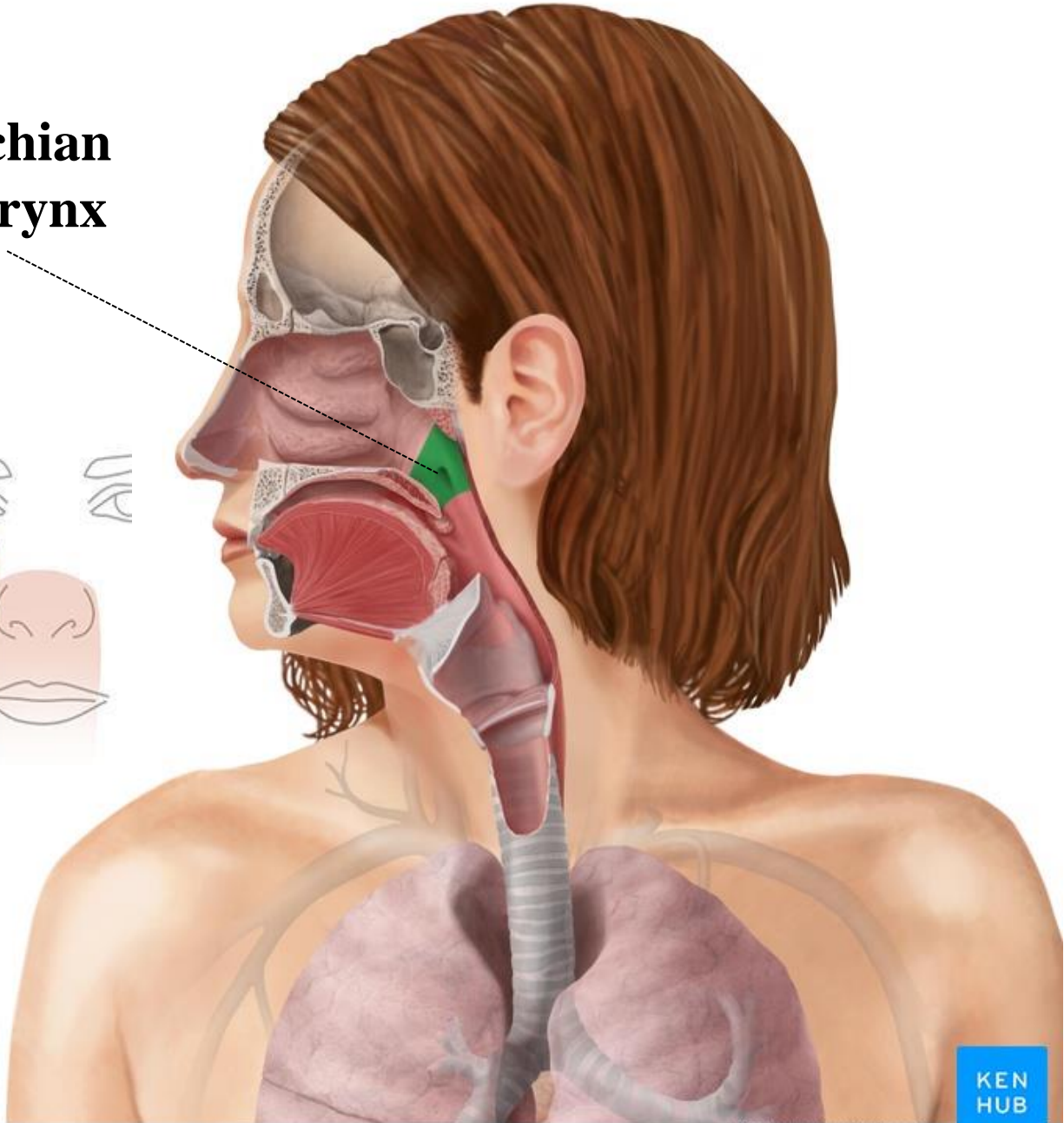
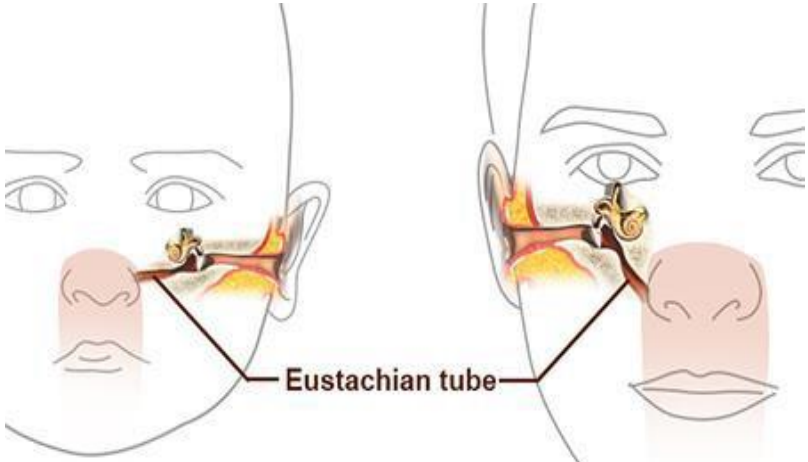
Dr. Heba Kalbouneh

Anterior



- Is formed below by a thin plate of bone that separates the tympanic cavity from the **internal carotid artery**
- At the upper part of the anterior wall are the openings into two canals  
The lower and larger leads into **the auditory tube**  
The upper and smaller is the entrance into **the canal for the tensor tympani muscle**

# Opening of Eustachian tube into nasopharynx



# EUSTACHIAN TUBE:

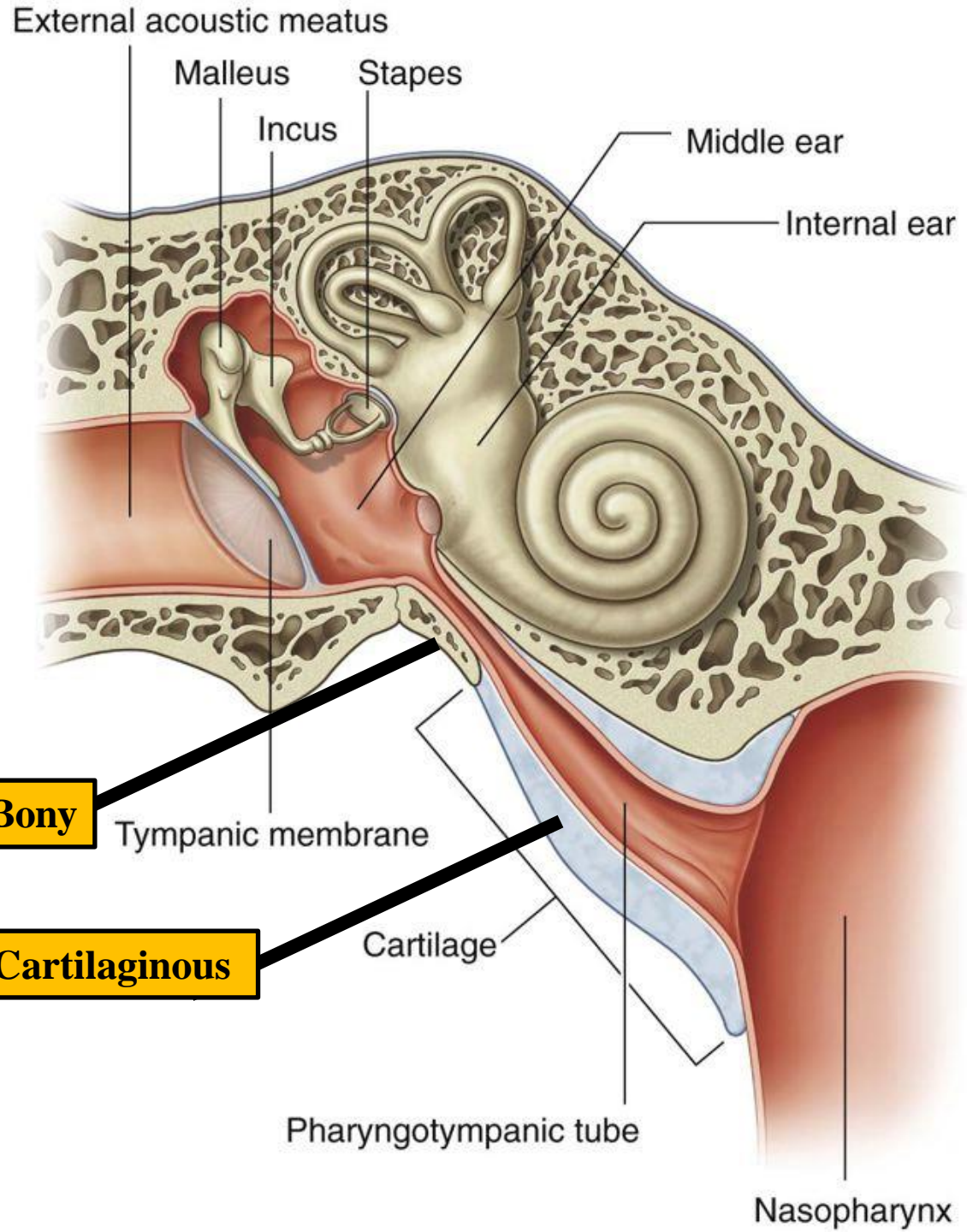
It connects the anterior wall of the **tympanic cavity** to the **nasopharynx**

It serves to equalize air pressures in the tympanic cavity and the nasopharynx

Its posterior inner third is **bony**  
Its anterior two thirds are **cartilaginous**

*Normally, the Eustachian tube is collapsed, but it opens with swallowing*

Pharyngo-tympanic tube  
Auditory tube  
Eustachian tube



**Bony**

**Cartilaginous**



# Medial wall

Labyrinth wall

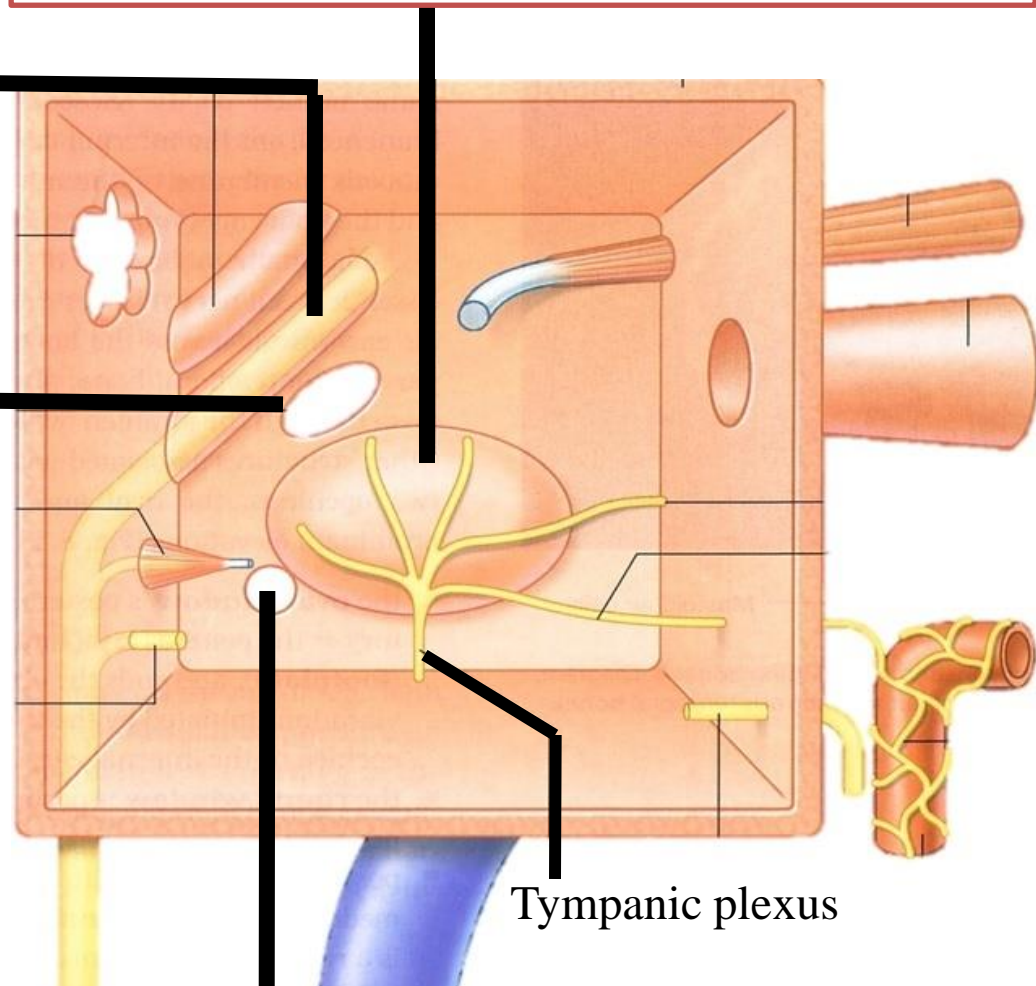
The horizontal part of the facial nerve arching above the promontory

**Oval window:**  
Above and behind the promontory, oval shaped and closed by the base of the stapes (**Fenestra vestibuli**)

The medial wall is formed by the lateral wall of the inner ear.

Fenestra means window

**Promontory** is a rounded projection (results from the underlying first turn of the cochlea)



Tympanic plexus

**Round window:**  
Below the posterior end of the promontory, round and closed by the secondary tympanic membrane (**Fenestra cochleae**)

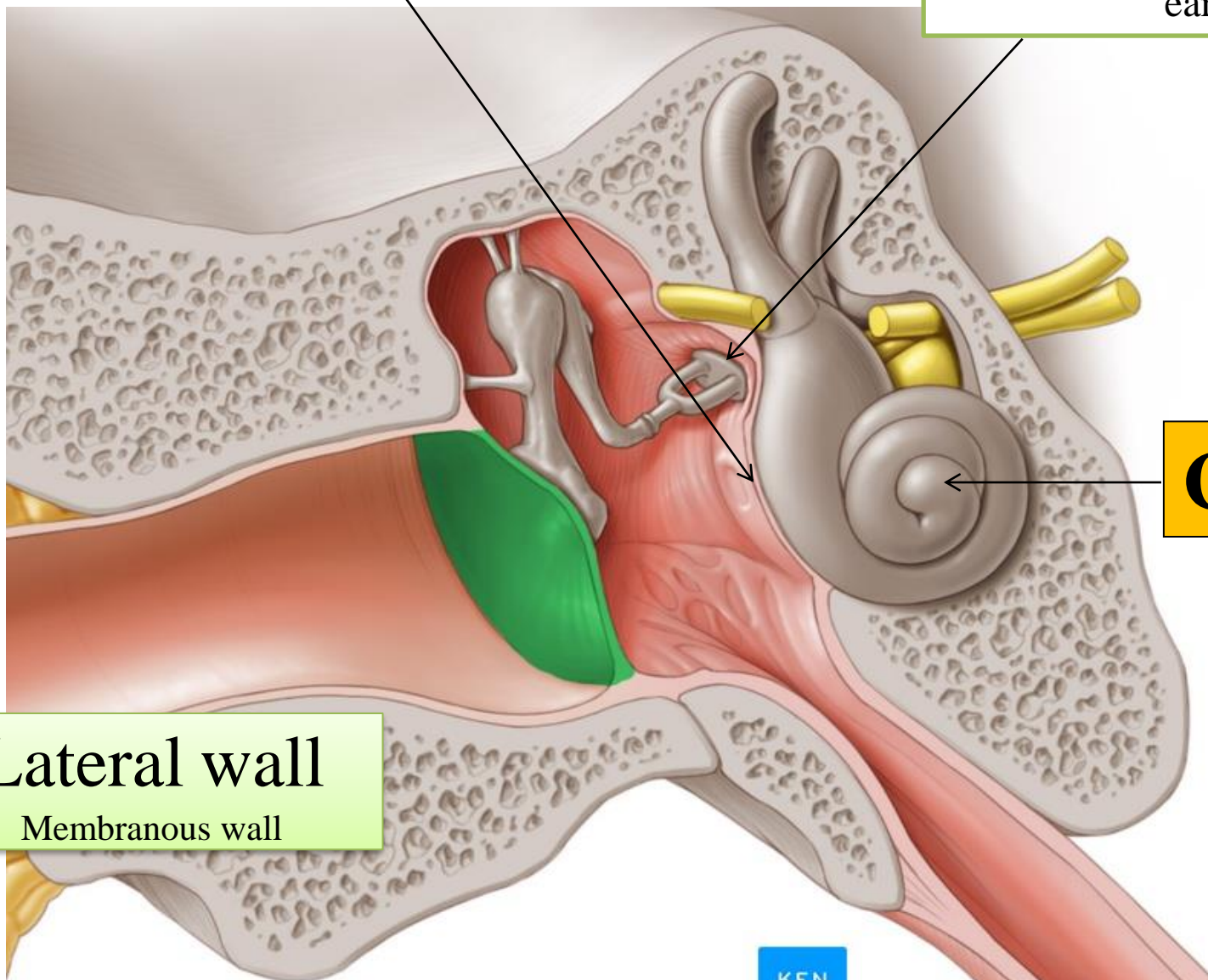
**Promontory**

**The base of stapes closes the oval window of the internal ear**

**Cochlea**

**Lateral wall**

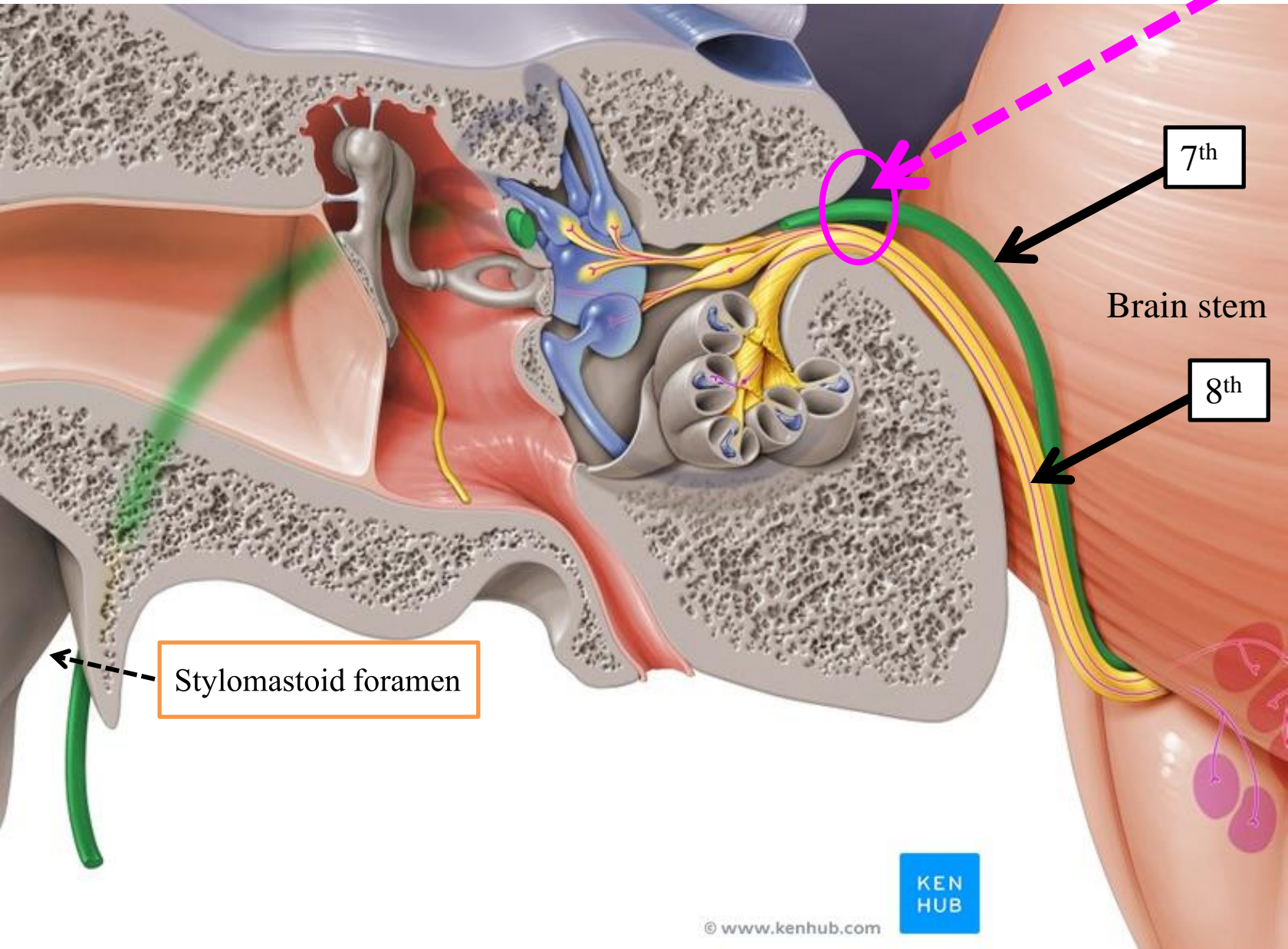
Membranous wall



*Dr. Heba Kalbouneh*



Internal acoustic meatus



7th

Brain stem

8th

Stylomastoid foramen



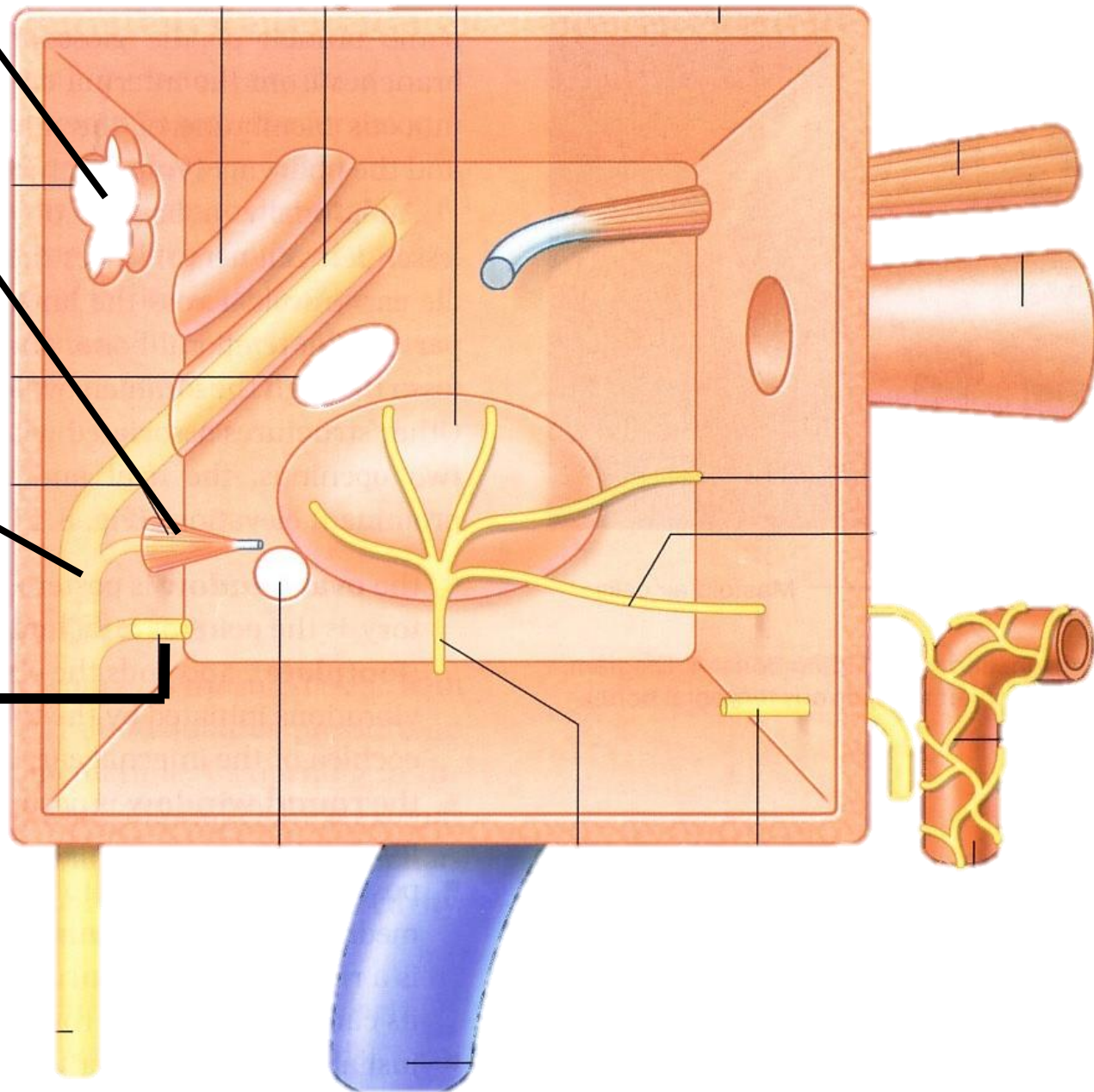
# Posterior wall

Aditus

Pyramid

Vertical part of  
Facial canal

Chorda tympani



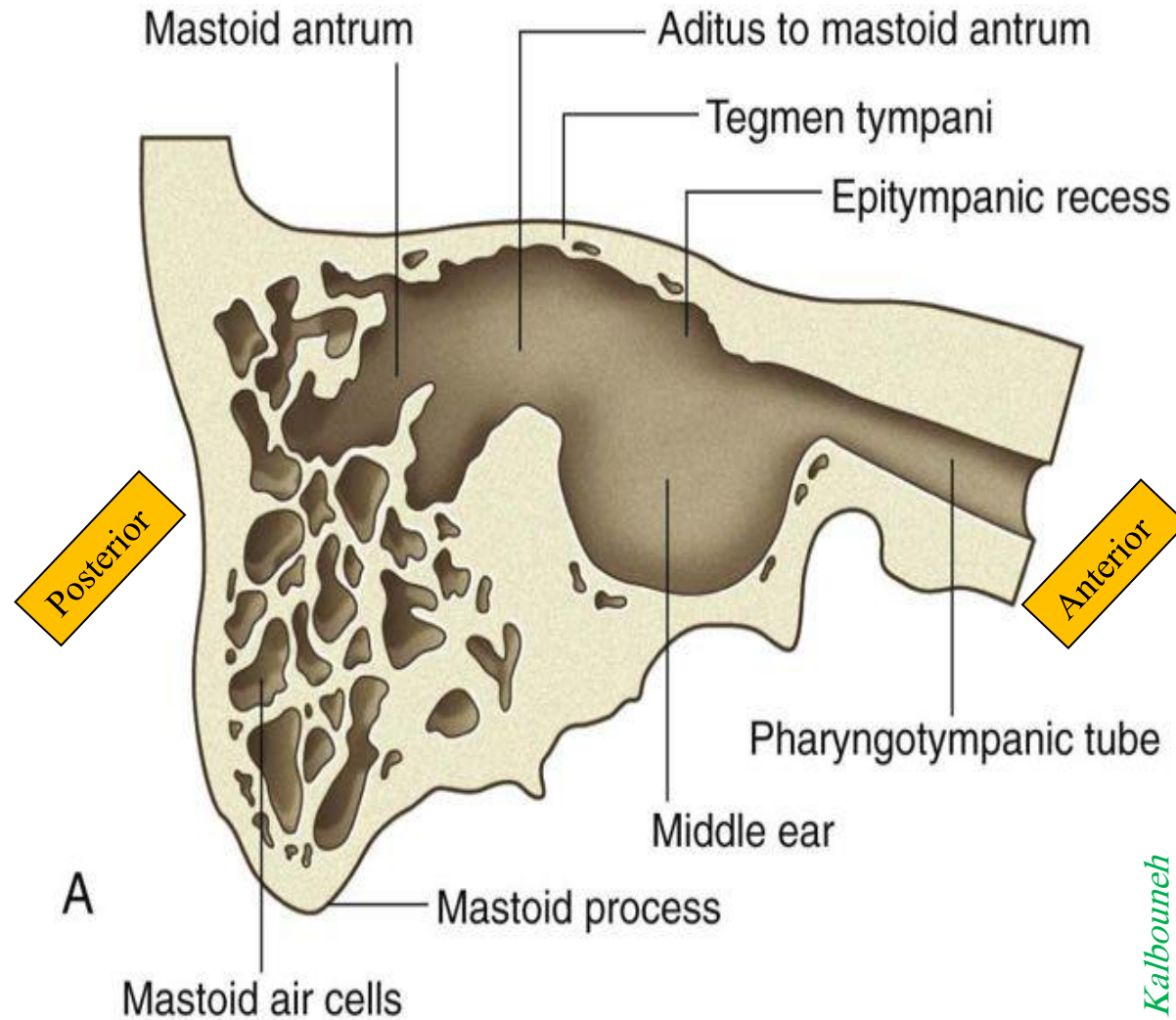
# Posterior wall

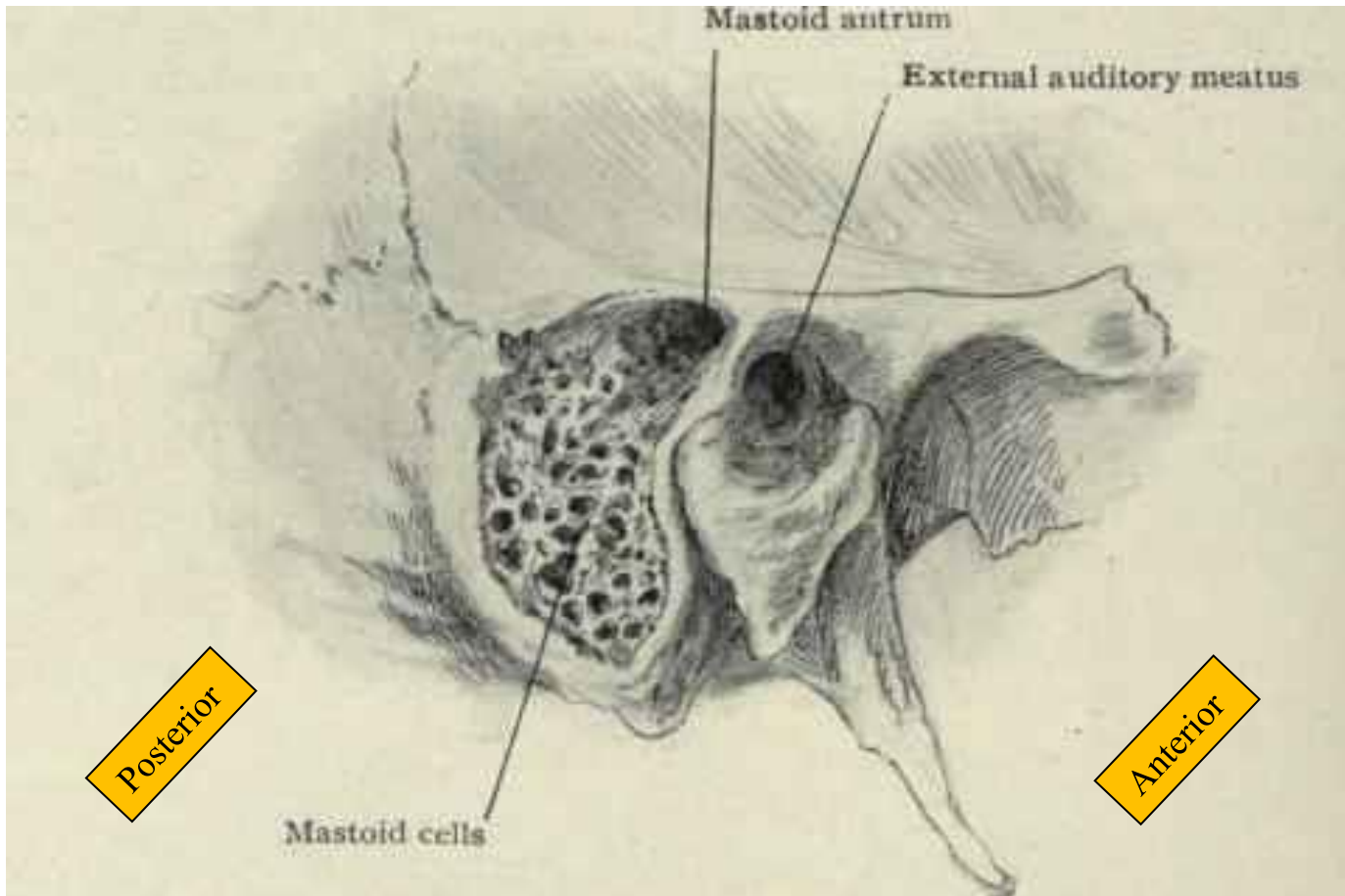
Mastoid wall

1- Has in its upper part a large, irregular opening, the **aditus** to the mastoid

2-Below, a small conical projection, the **pyramid**, from its apex emerges the tendon of the stapedius muscle

3- The **vertical part of the facial nerve**



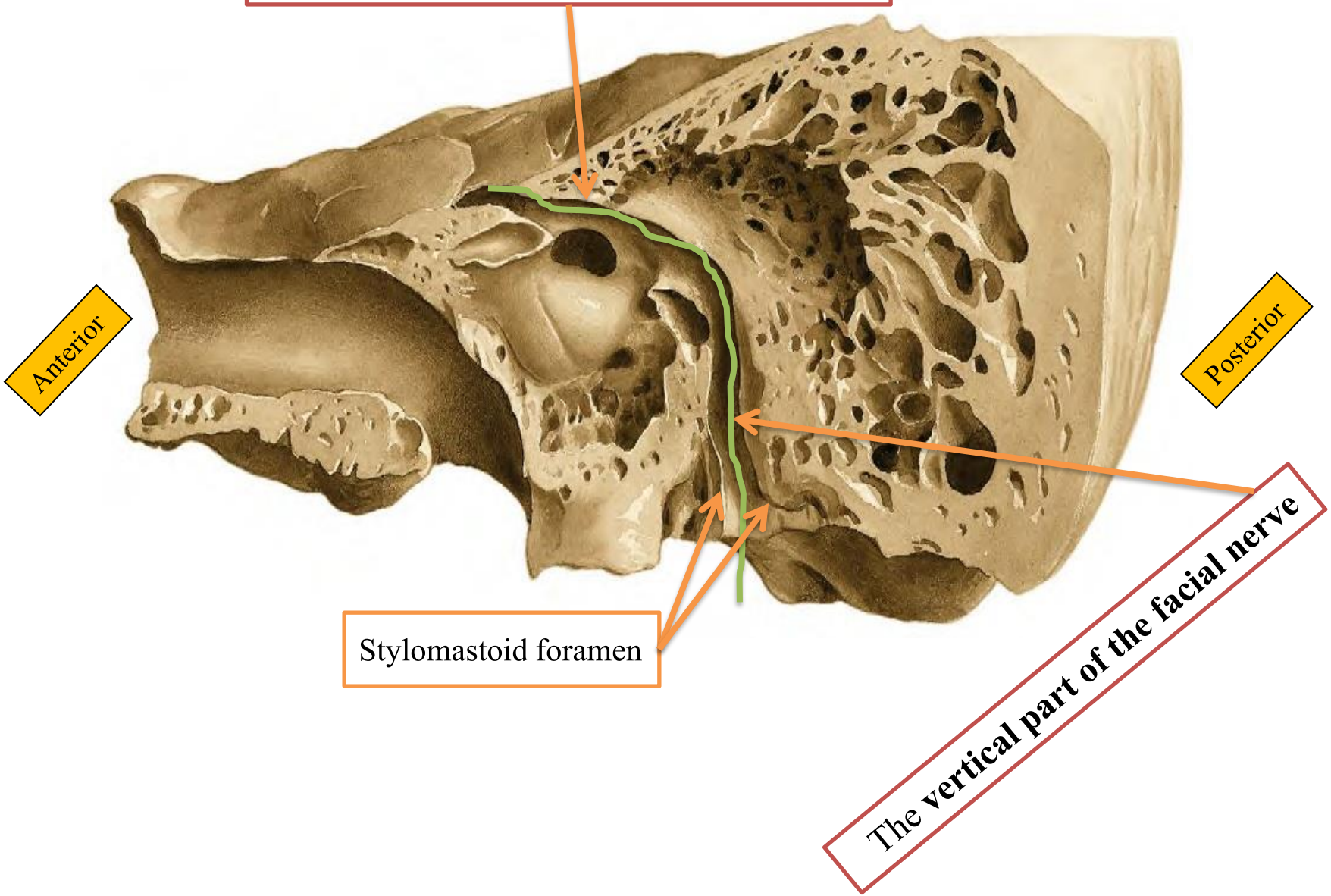


## **Mastoid Antrum**

The mastoid antrum lies behind the middle ear in the petrous part of the temporal bone

It communicates with the middle ear by the aditus

The horizontal part of the facial nerve



Anterior

Posterior

Stylomastoid foramen

The vertical part of the facial nerve

# Infections and Otitis Media

The meninges and the temporal lobe of the brain lie superiorly  
*(Meningitis and cerebral abscess in the temporal lobe)*

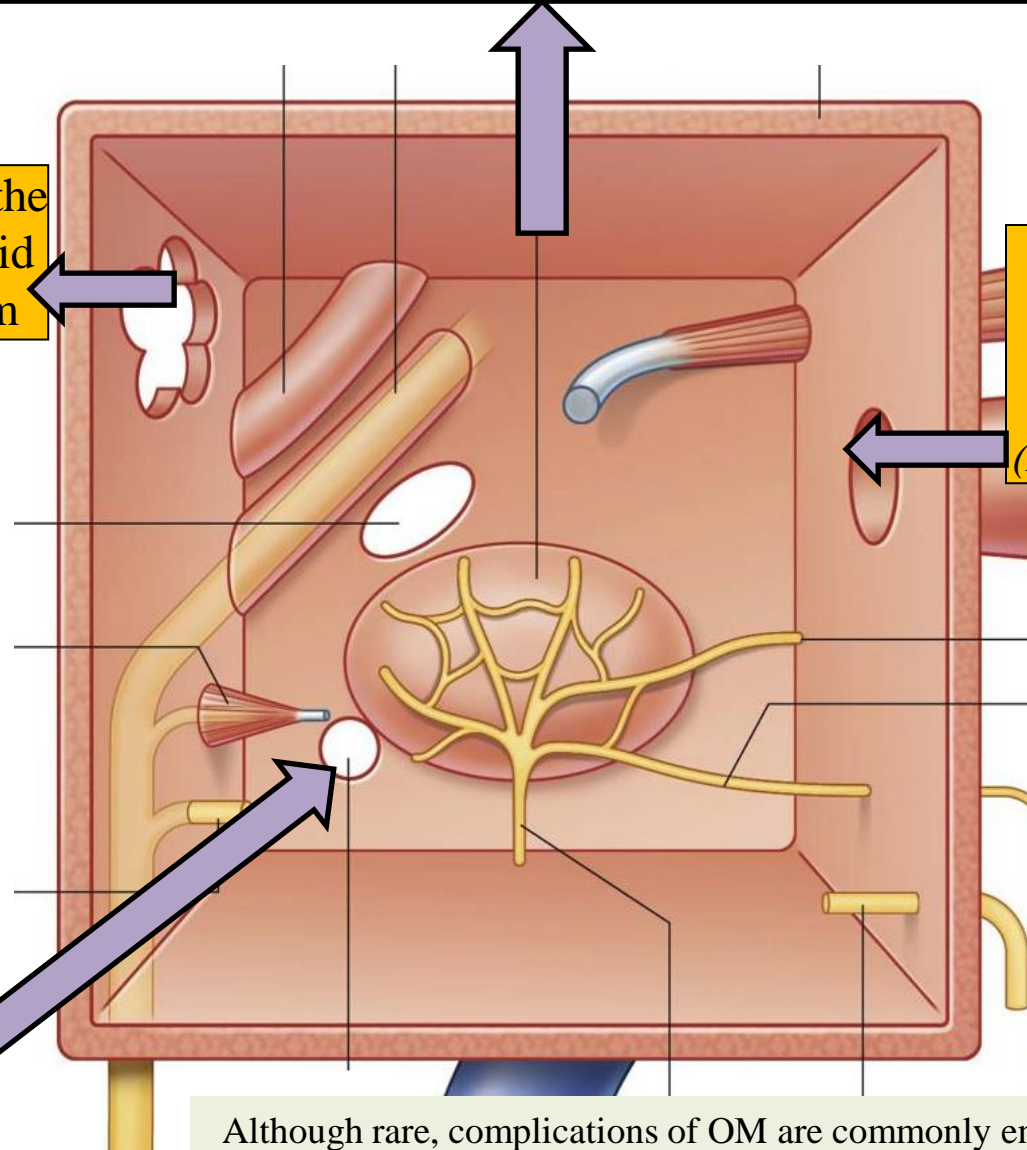
*(Acute mastoiditis)*

Into the mastoid antrum

Through the auditory tube from nasopharynx.  
*(nasopharyngitis)*

The posterior wall of the mastoid antrum is related to the **sigmoid venous sinus**. If the infection spreads in this direction, a *thrombosis in the sigmoid sinus* may take place

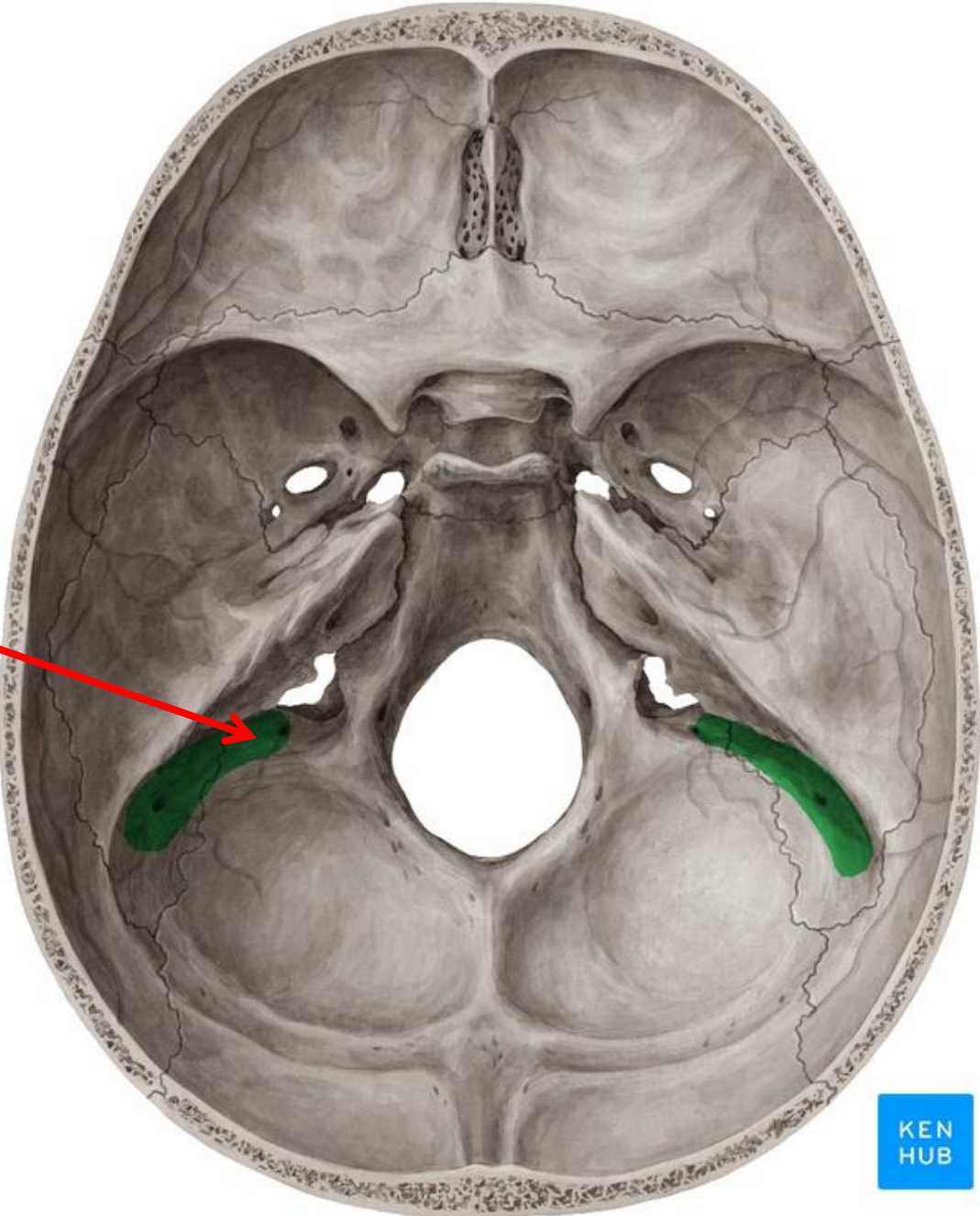
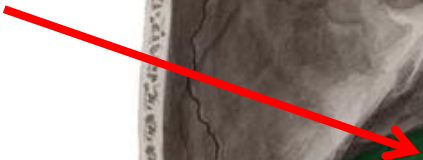Medial wall: A spread of the infection in this direction can cause a *facial nerve palsy and labyrinthitis with vertigo*



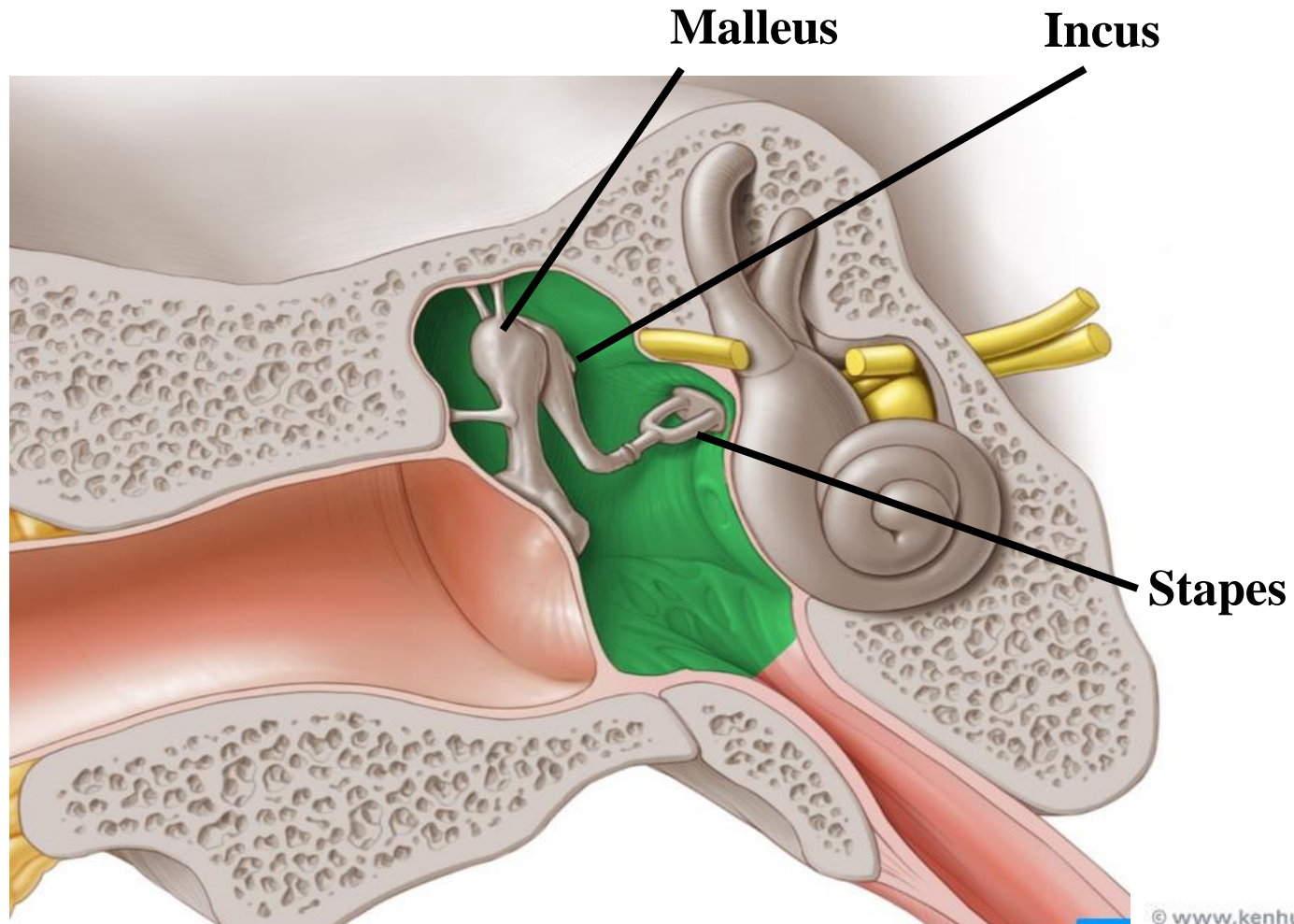
Although rare, complications of OM are commonly encountered given its high prevalence. Complications of OM are classified as extracranial or intracranial. Brain abscess are commonly considered the second most common intracranial complication of OM after meningitis



Groove for the **sigmoid sinus**



# CONTENTS OF THE MIDDLE EAR



Dr. Heba Kalbouneh

KEN  
HUB

© www.kenhub.com

A-3 Auditory Ossicles

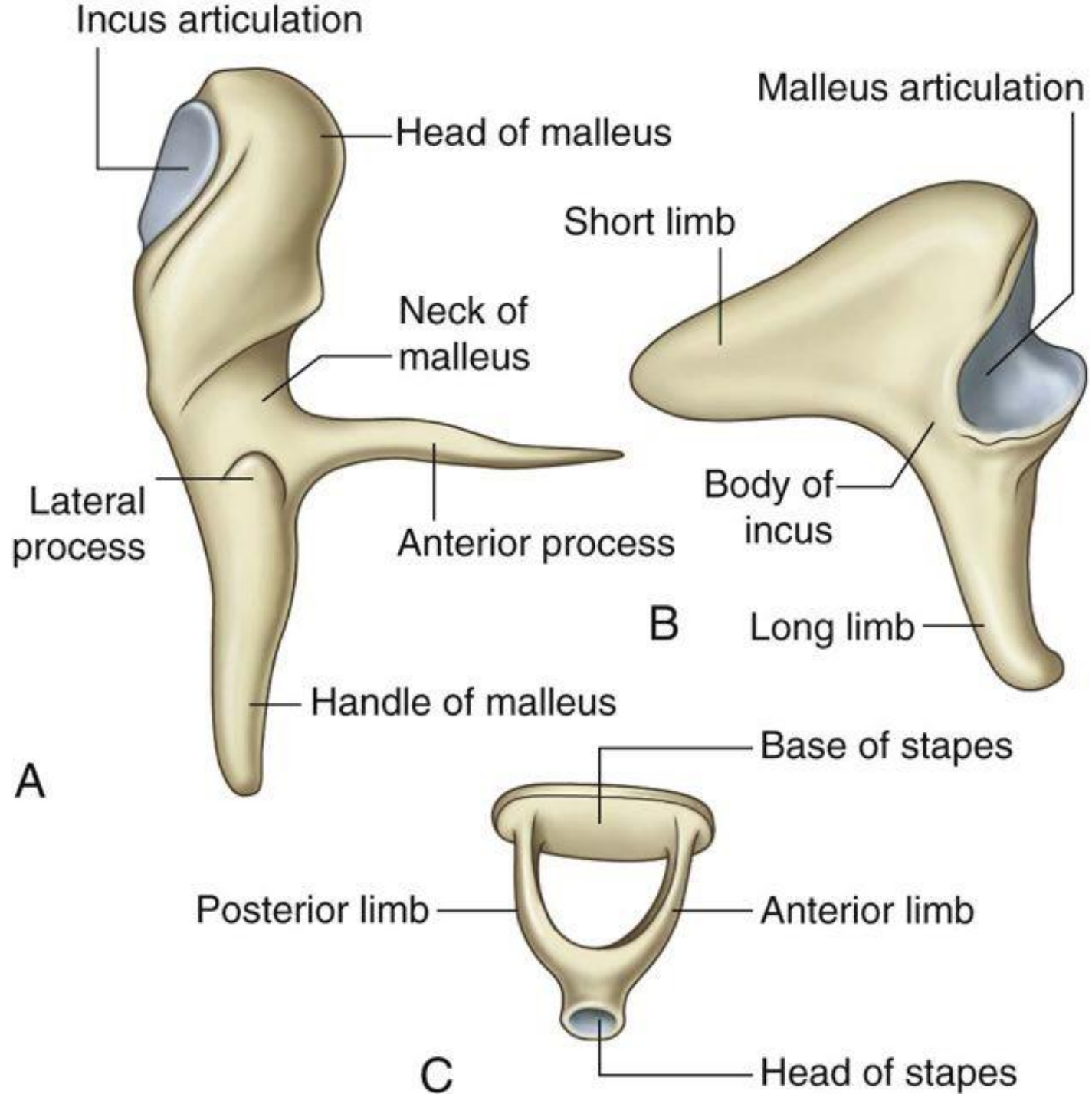
B-2 muscles

C-2 nerves (tympanic plexus and chorda tympani)

D-air

- It contains the auditory ossicles, whose function is to transmit the vibrations of the tympanic membrane (eardrum) to the perilymph of the internal ear

# Ossicles



1-The malleus is the largest ossicle and possesses head, a neck, a long process or handle, an anterior process, and a lateral process.

its head is rounded and articulates posteriorly with the **incus**

**The incus possesses:**

a large body and two processes:

The body articulates with the head of the malleus.

The long process articulates with the head of the stapes

Read only

**The stapes** has a head, a neck, two limbs, and a base

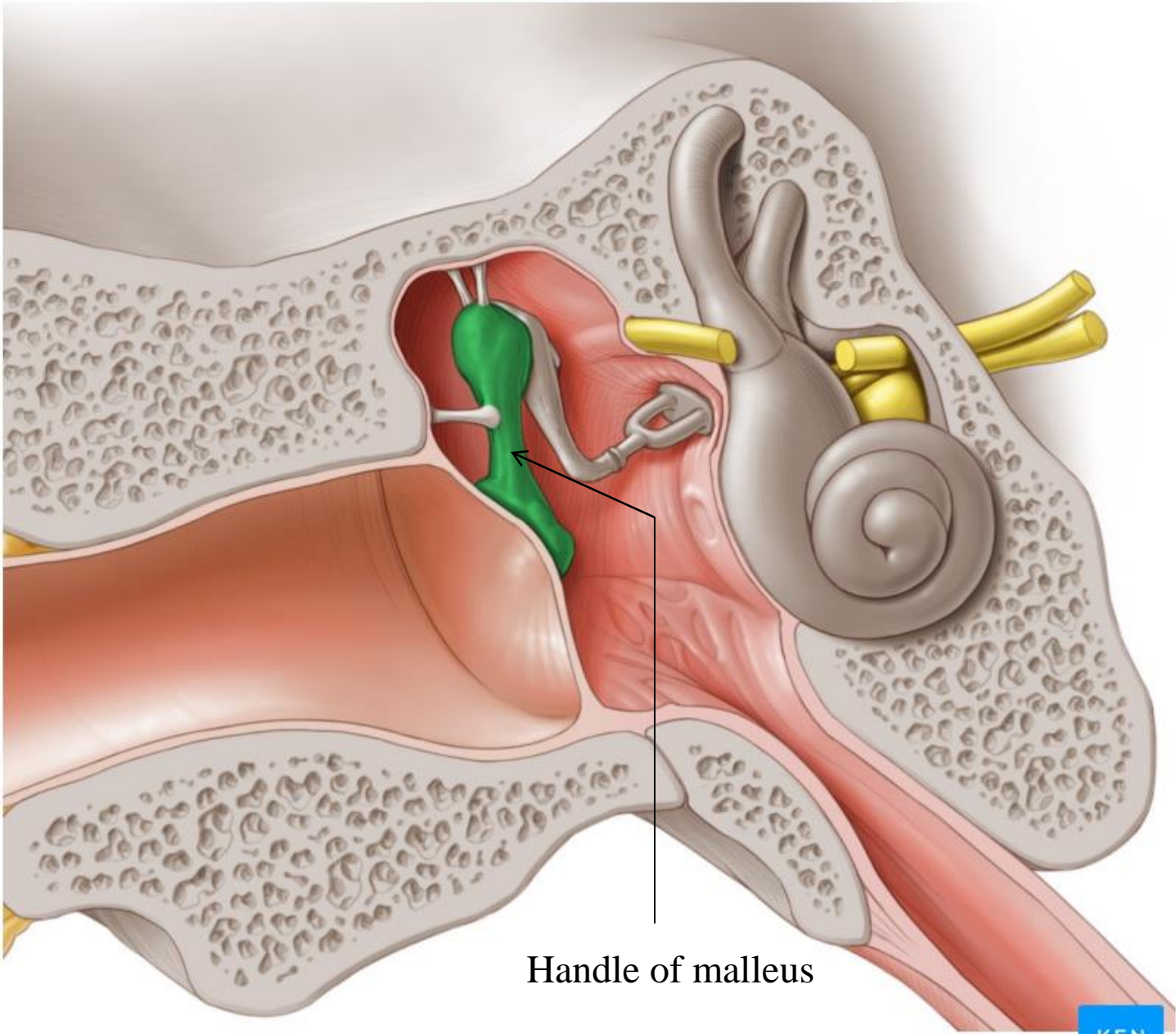
**The head** articulates with the long process of **the incus**.

The neck is narrow and receives the

insertion of the **stapedius** muscle. The two limbs diverge from the neck and are attached to **the oval base** which closes **the oval window** of the internal ear

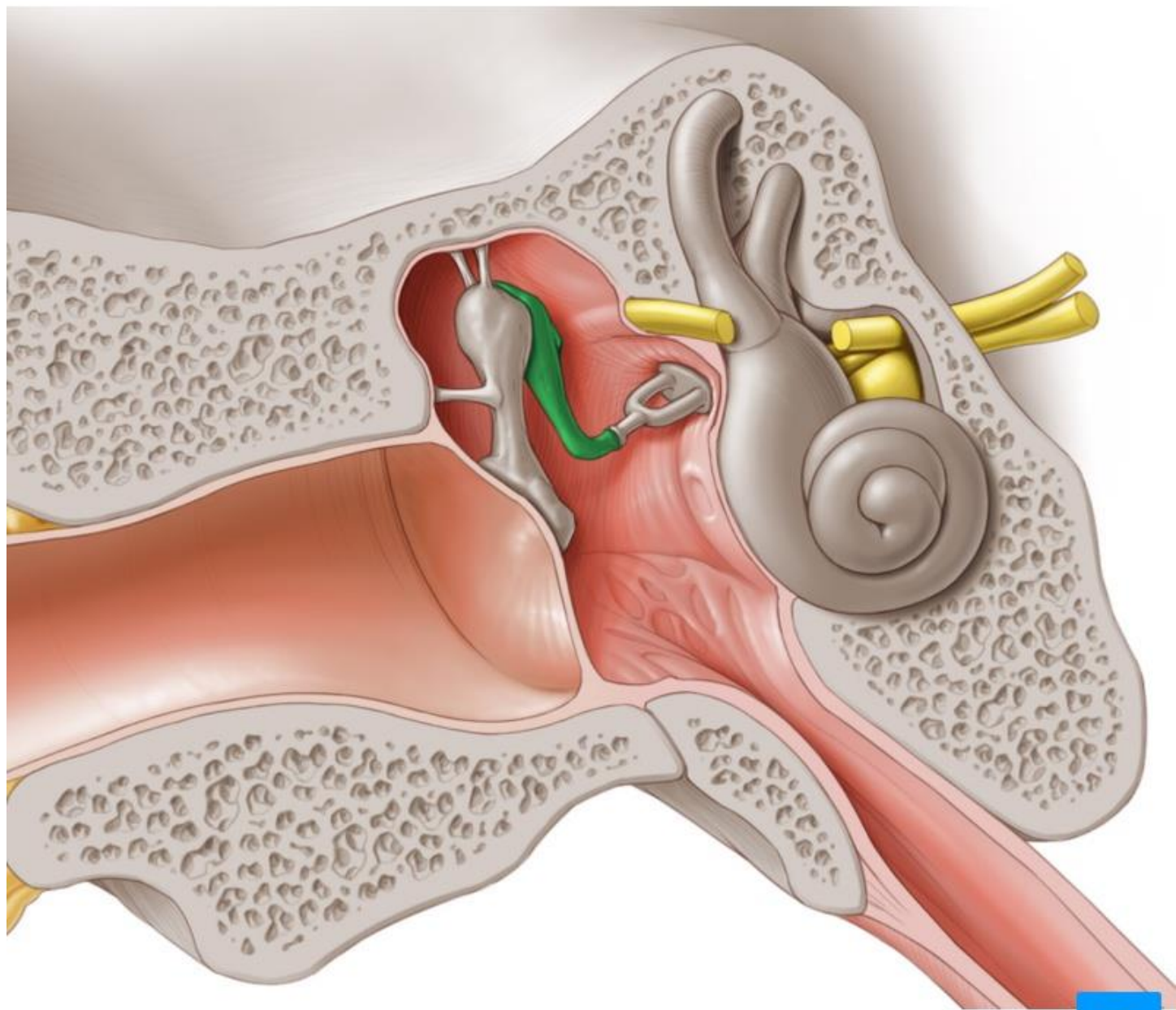
# Malleus

The handle is firmly attached to the medial surface of the tympanic membrane



Handle of malleus


# Incus



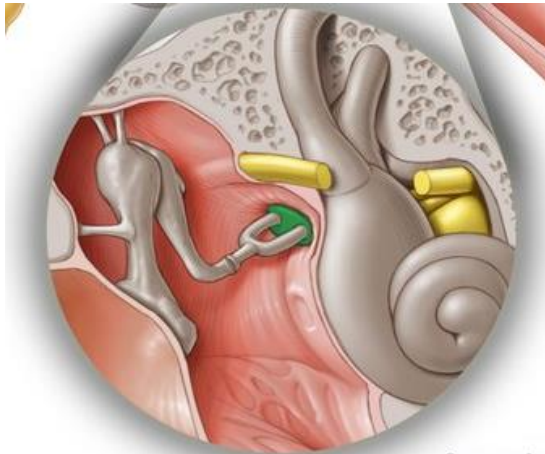
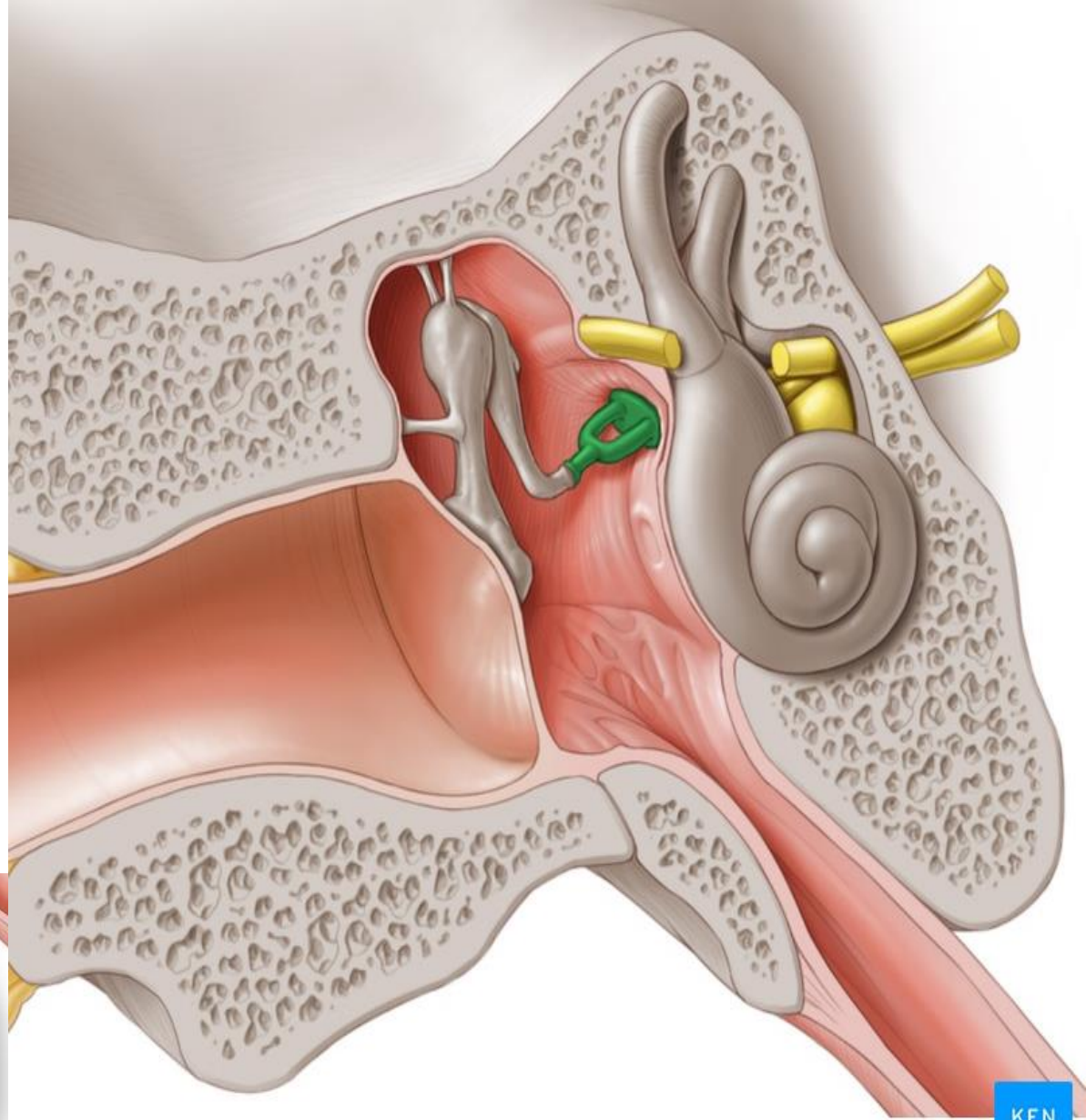
# Stapes

The base of stapes closes the oval window of the internal ear

The **Annular stapedial ligament** is a ring of fibrous tissue that connects the base of the stapes to the oval window of the inner ear

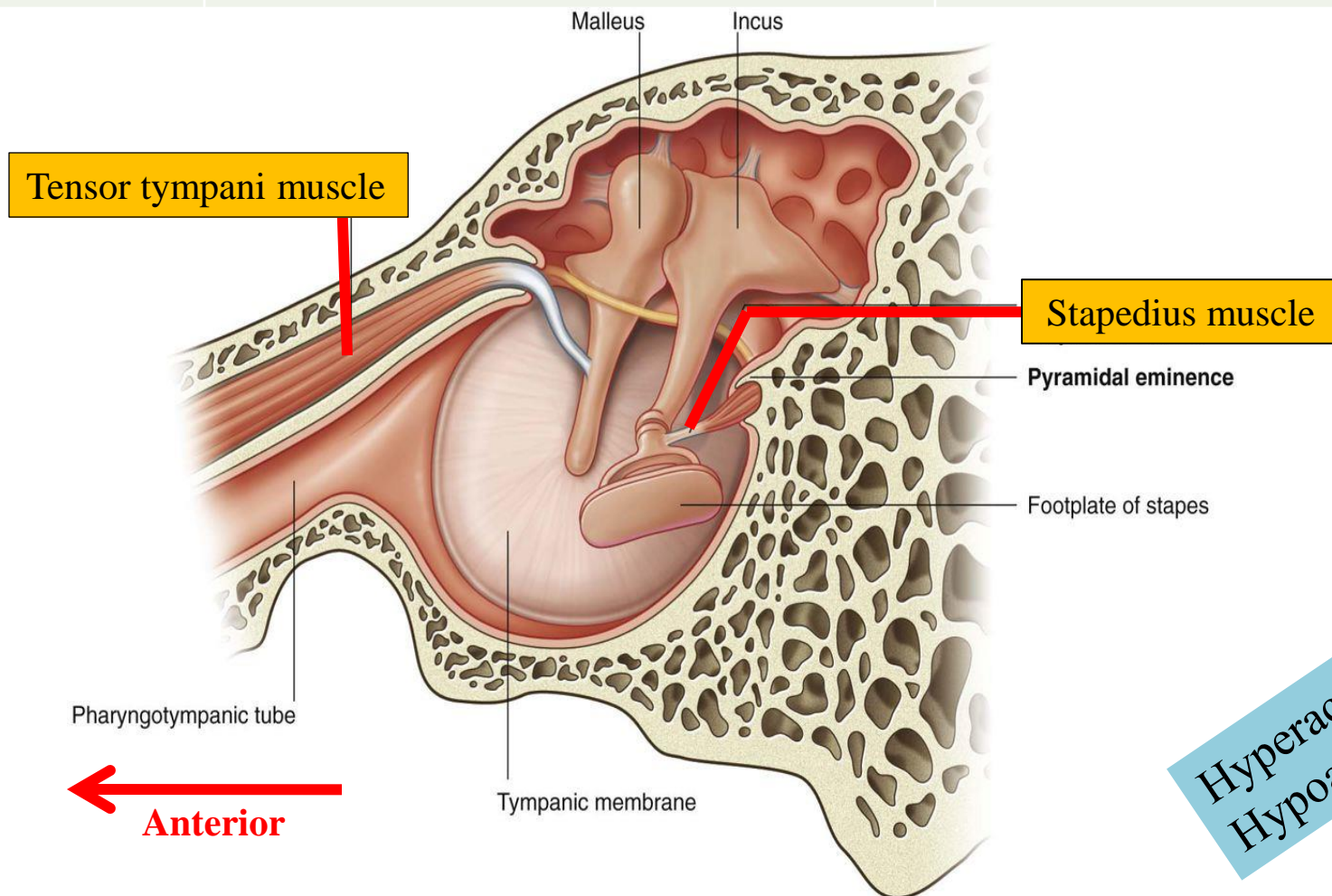


Calcification and hardening of the annular ligament of the stapes (Otosclerosis) is a common cause of adult deafness

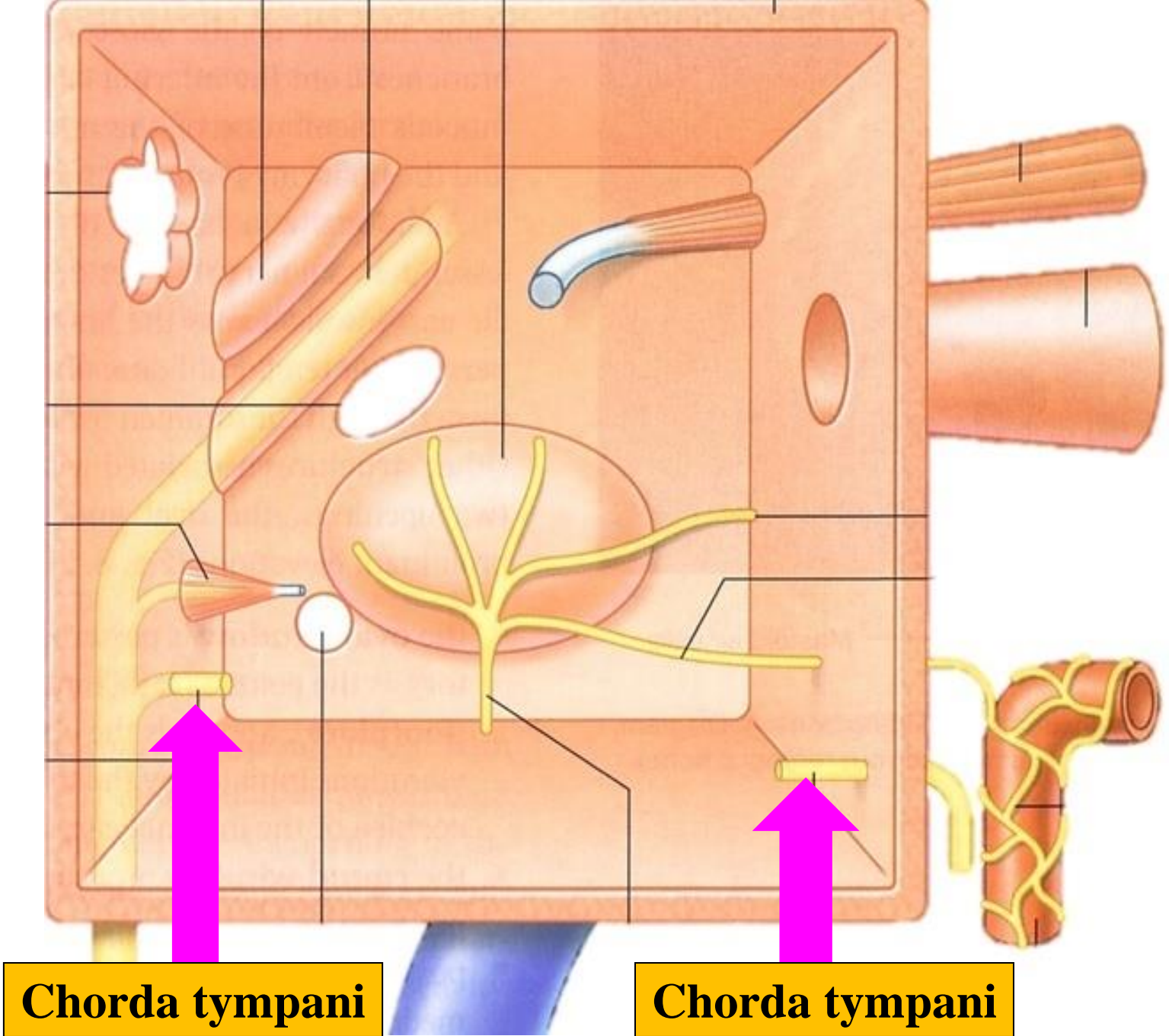


# Muscles of middle ear

Muscle	Nerve supply	Action
Tensor tympani	Mandibular division of trigeminal nerve	Dampens down vibrations of tympanic membrane
Stapedius	Facial nerve	Dampens down vibrations of stapes







**Chorda tympani**

**Chorda tympani**

**CHORDA TYMPANI  
NERVE**

Tensor tympani muscle

**Anterior**

**CHORDA  
TYMPANI  
NERVE**

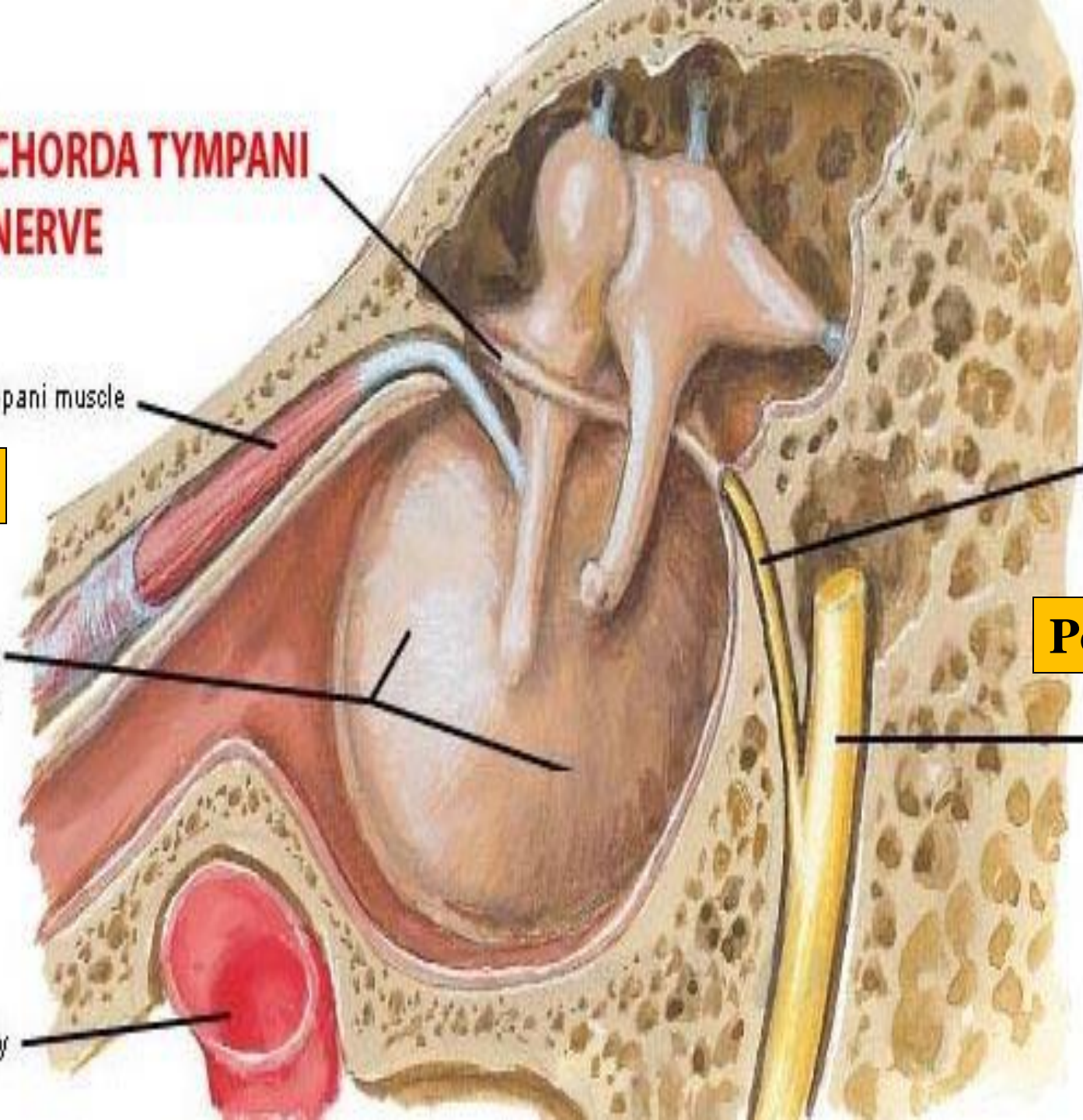
**Posterior**

Tympanic membrane  
(pars tensa)

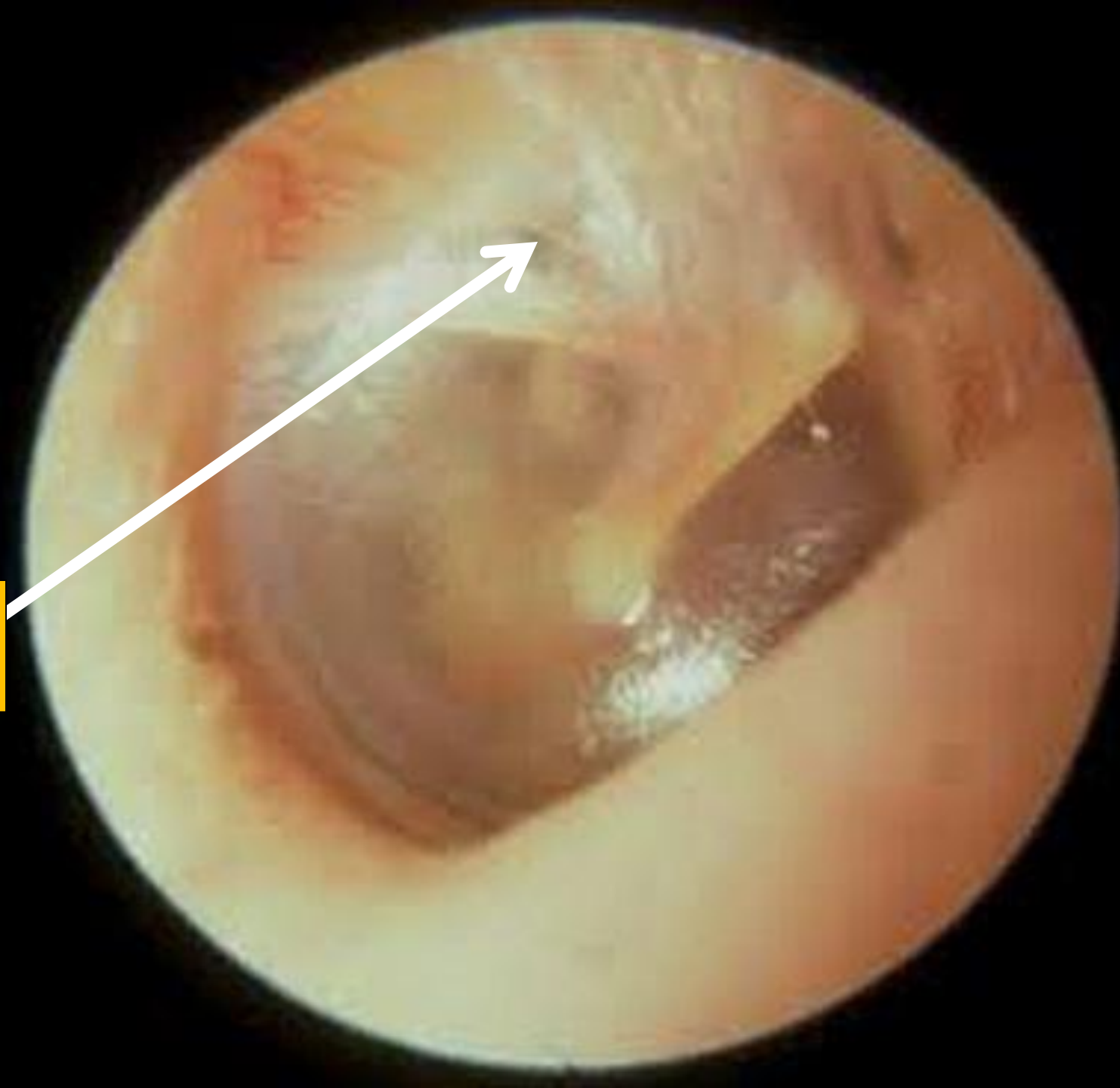Facial nerve (V)

Internal carotid artery

*F. Netter  
M.D.  
© 1976*



**Chorda  
tympani**



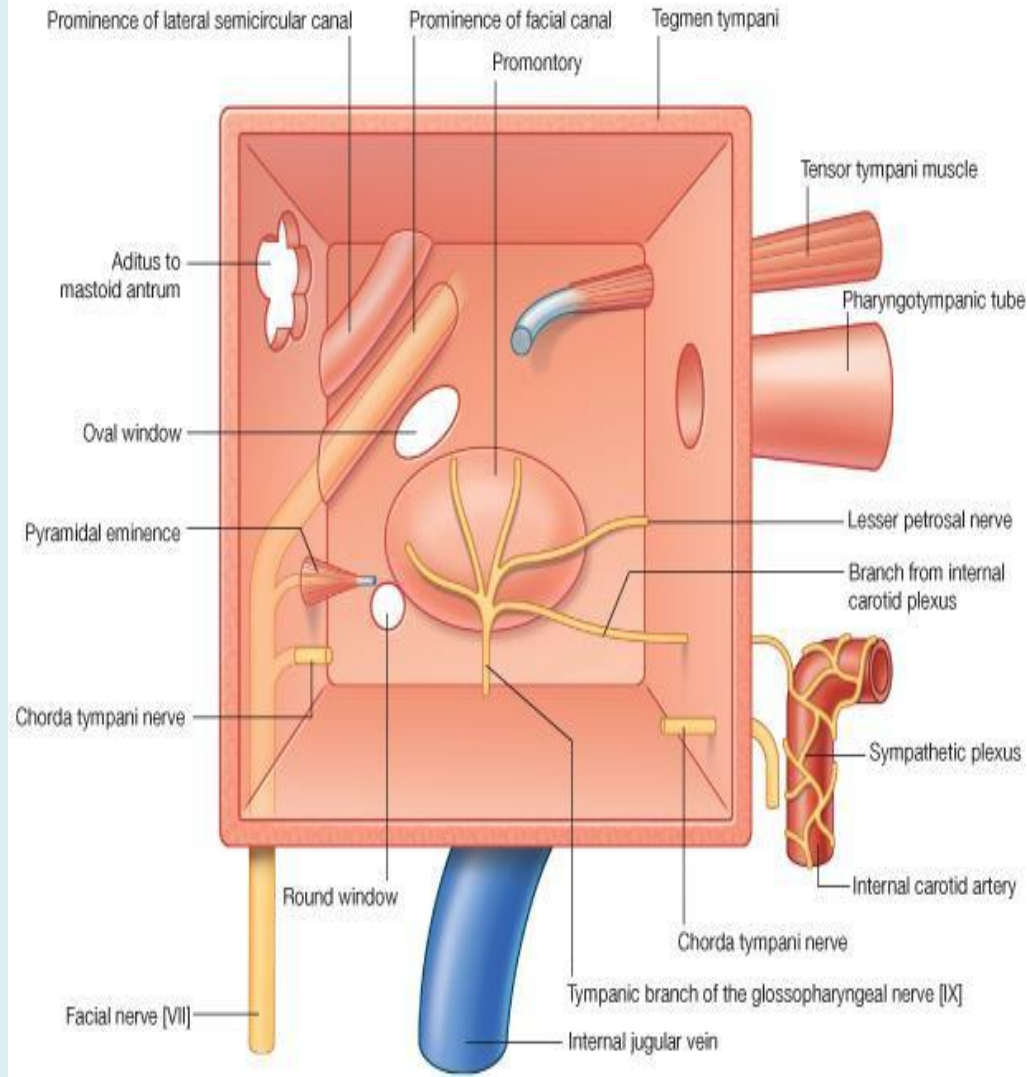
# The chorda tympani

- ✓ It arises from the facial nerve just above the stylomastoid foramen
  - ✓ It enters the middle ear close to the posterior border of the tympanic membrane.
  - ✓ It then runs forward over the tympanic membrane and crosses the root of the handle of the malleus
- ✓ It leaves the middle ear through the petrotympanic fissure and enters the infratemporal fossa, where it joins the lingual nerve



The chorda tympani contains:

1. Taste fibers from the mucous membrane covering the anterior two thirds of the tongue and the floor of the mouth.
2. Carries preganglionic parasympathetic fibers to the submandibular and sublingual glands via the **submandibular ganglion**



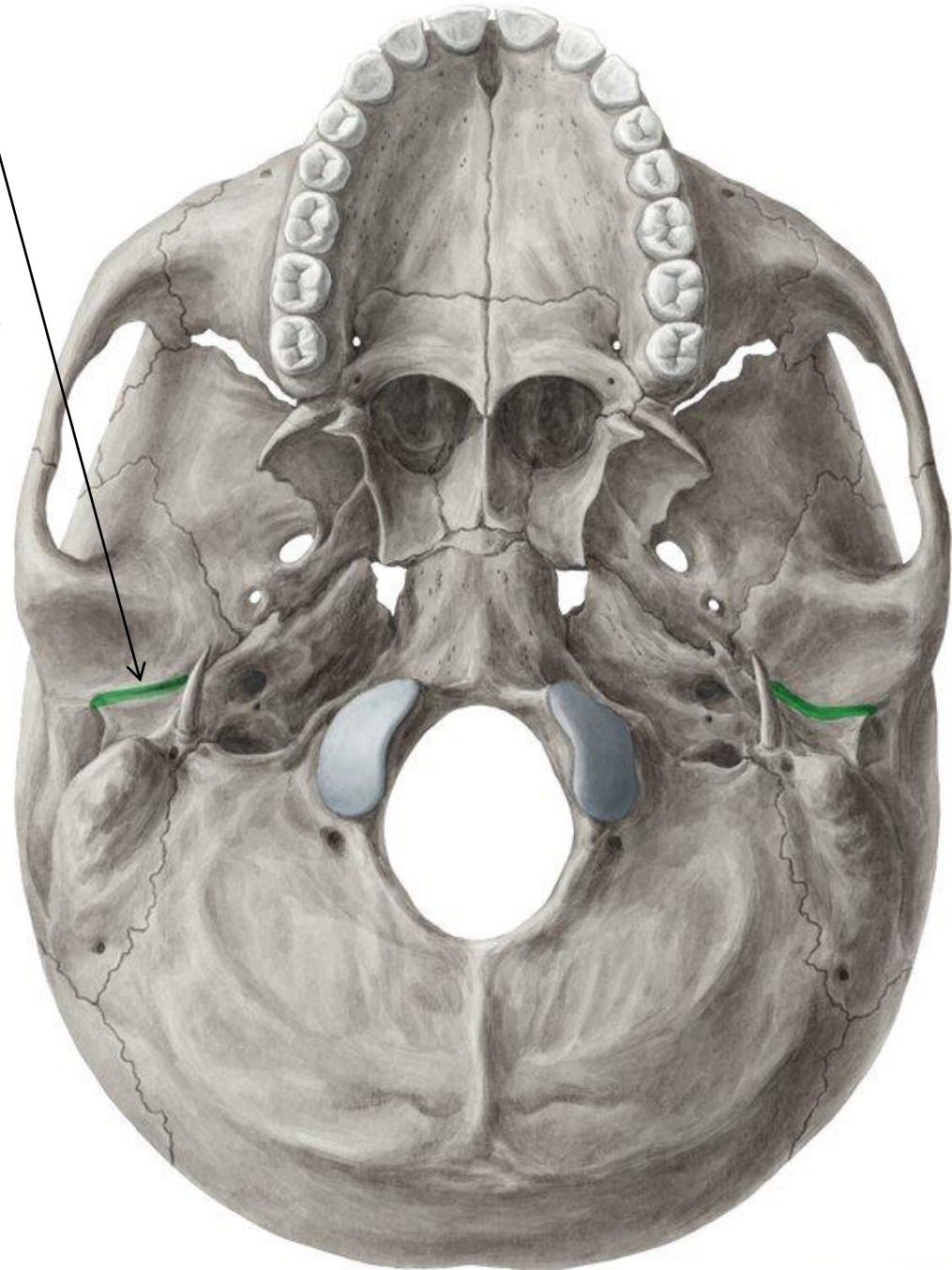
The **petrotympanic fissure** is a fissure in the temporal bone



The chorda tympani runs through the fissure to join with the lingual nerve in the infratemporal fossa

The **chorda tympani** is a branch of the facial nerve

The **chorda tympani** passes medial to the tympanic membrane and the handle of the malleus, and again enters the temporal bone. It exits the skull through the petrotympanic fissure and descends in the infratemporal fossa.



# Tympanic Nerve

➤ The tympanic nerve arises from the glossopharyngeal nerve, just below the jugular foramen


➤ It passes through the floor of the middle ear and onto the promontory

➤ Here it splits into branches, which form the **tympanic plexus**.

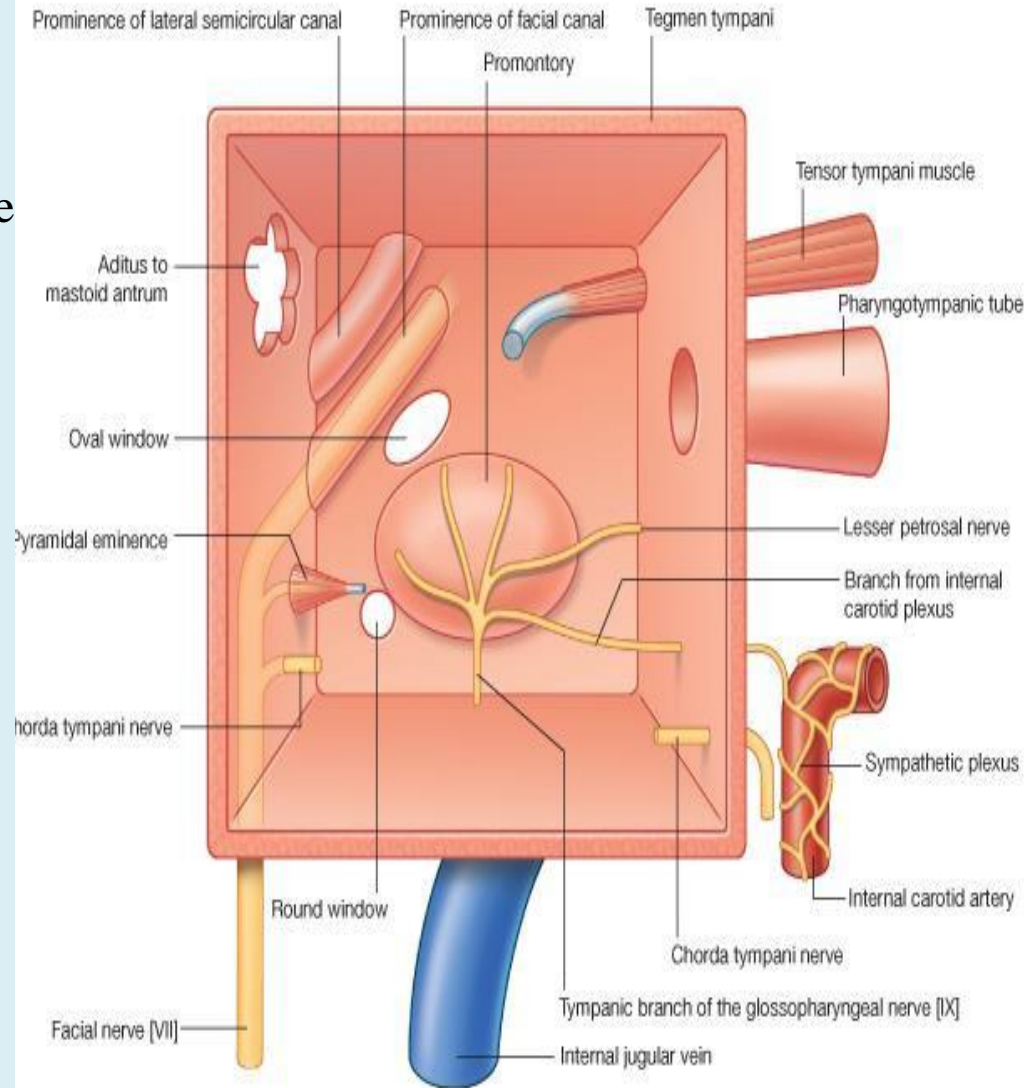
➤ The tympanic plexus supplies the lining of the middle ear and gives off:

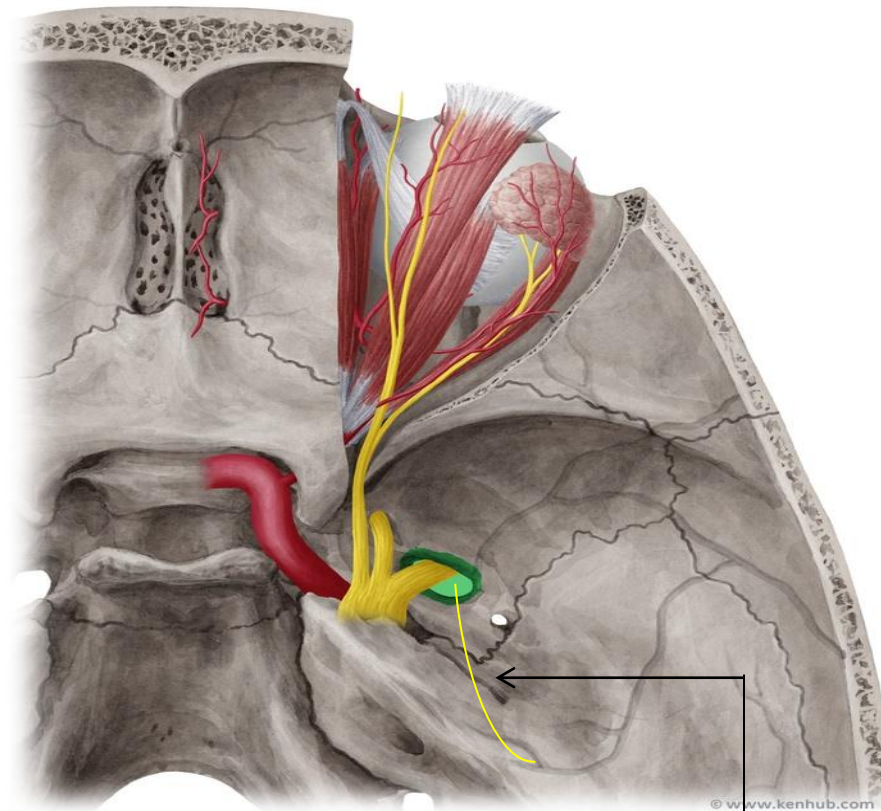
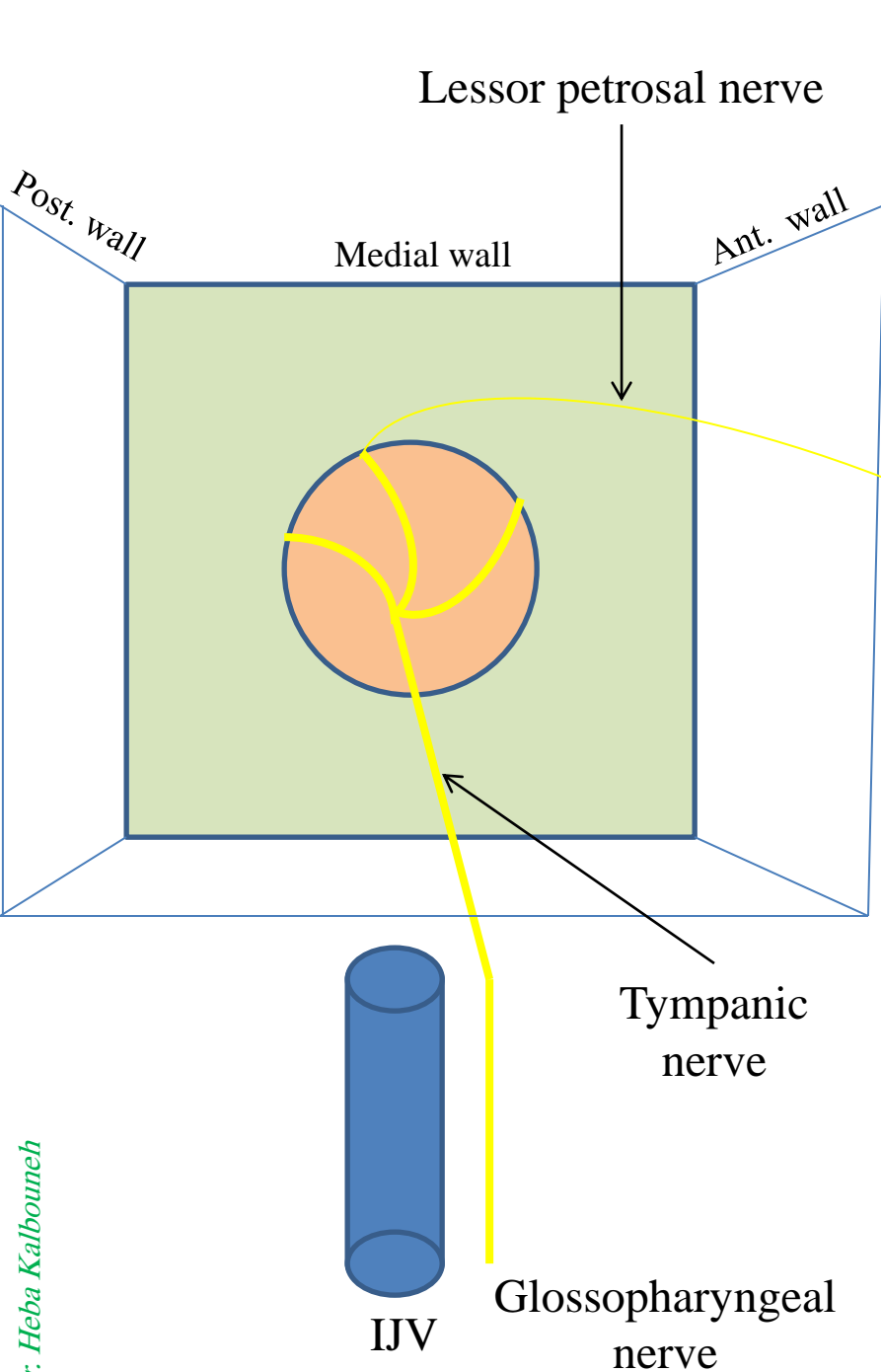
**Lesser petrosal nerve**

It leaves the skull through the foramen ovale



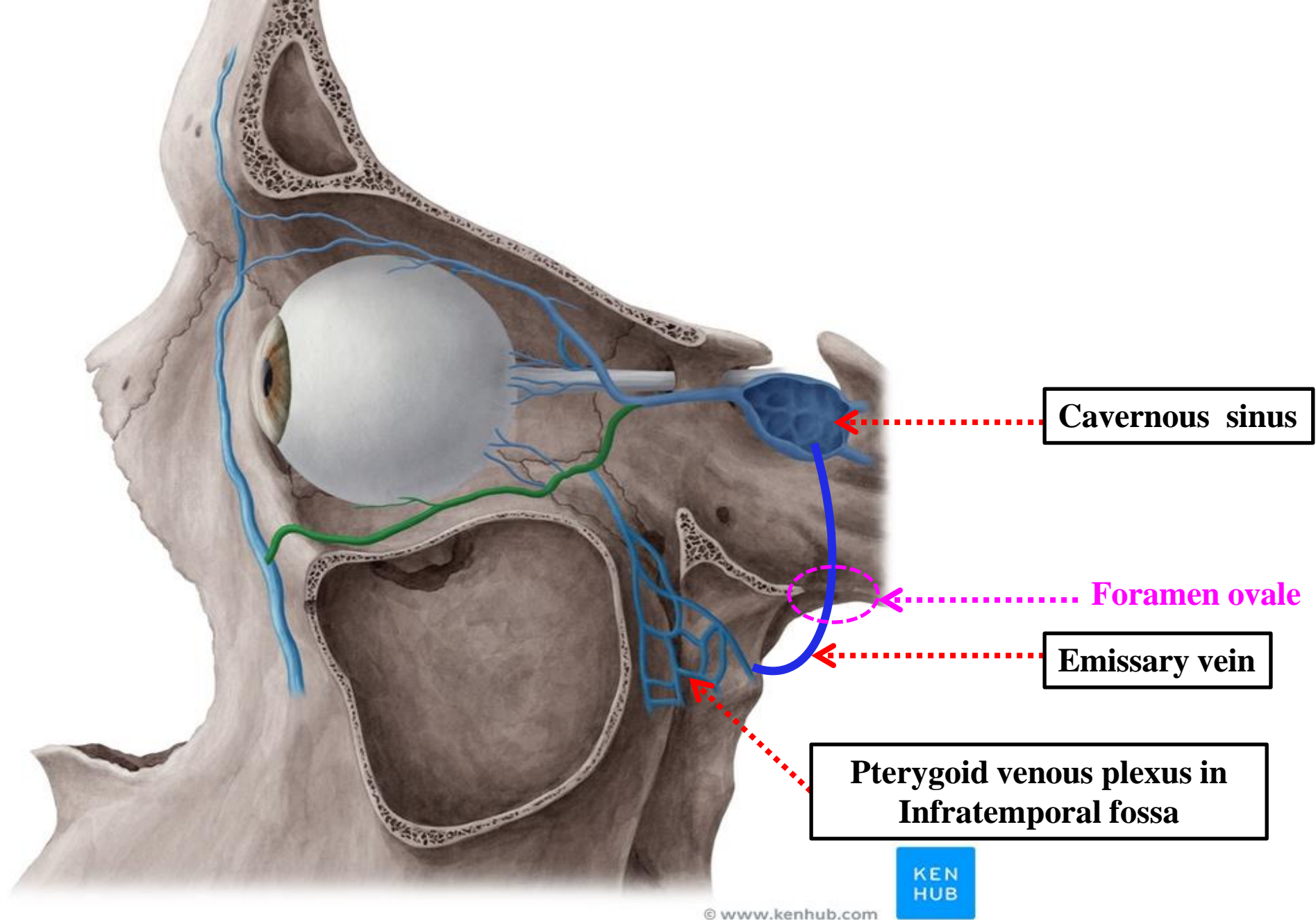
Carries preganglionic parasympathetic fibers to the parotid gland via the **otic ganglion**





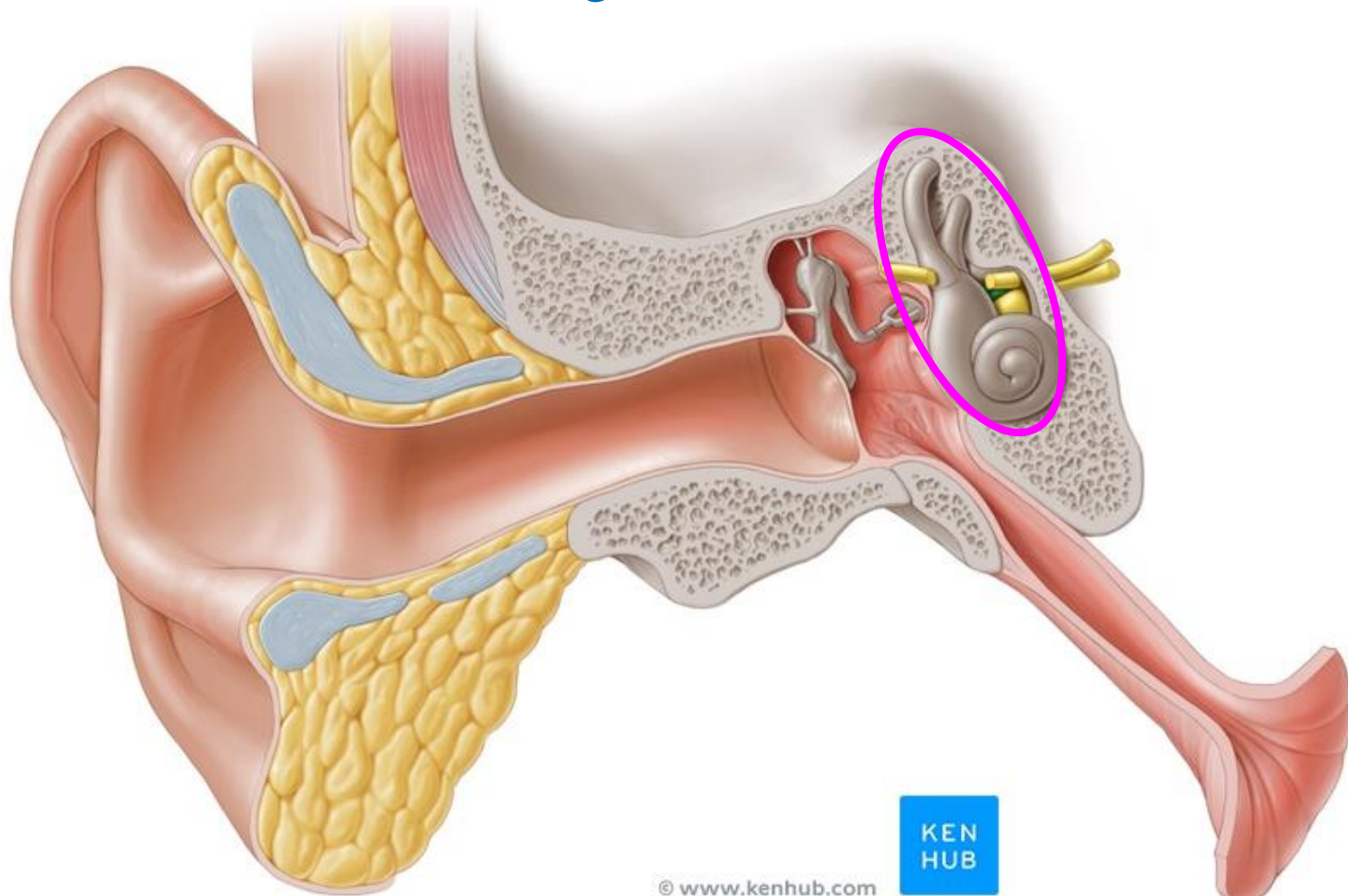
**Foramen ovale transmits:**  
**Mandibular nerve**  
**Accessory meningeal artery**  
**Lessor petrosal nerve**  
**Emissary vein**

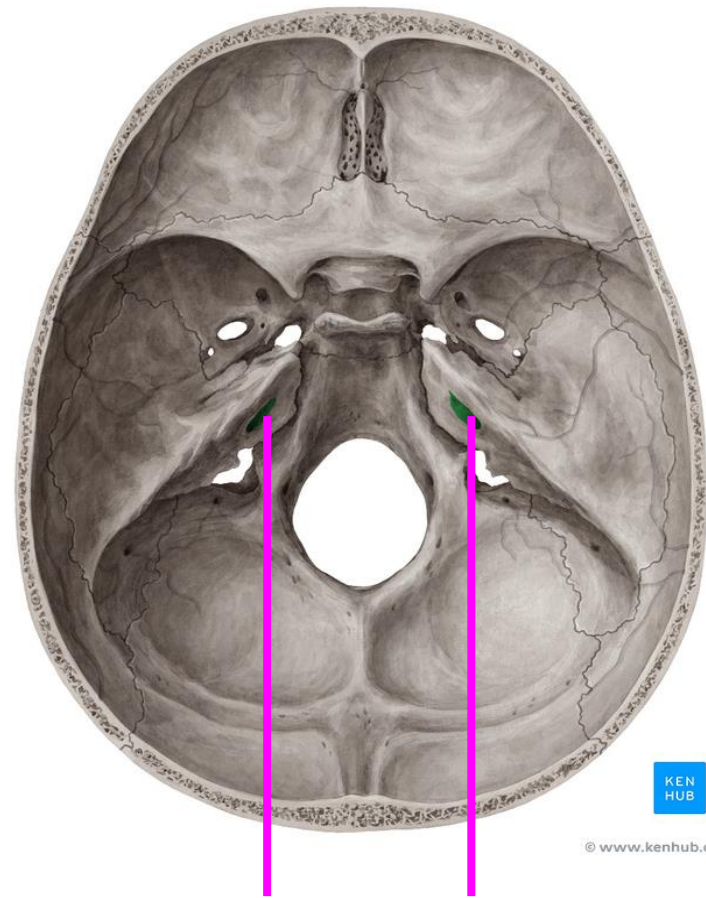
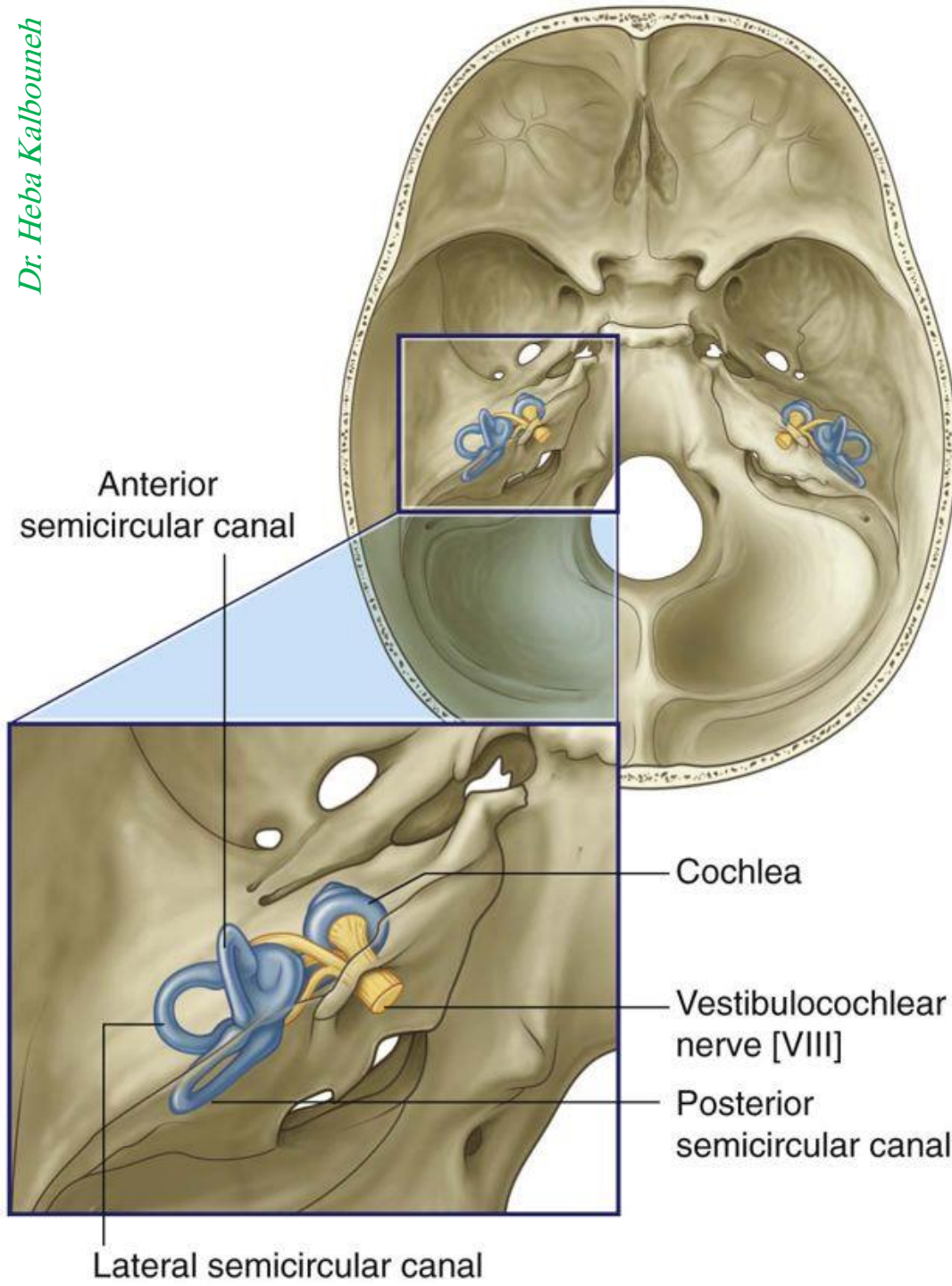
↓  
**MALE**





# Inner Ear (labyrinth)





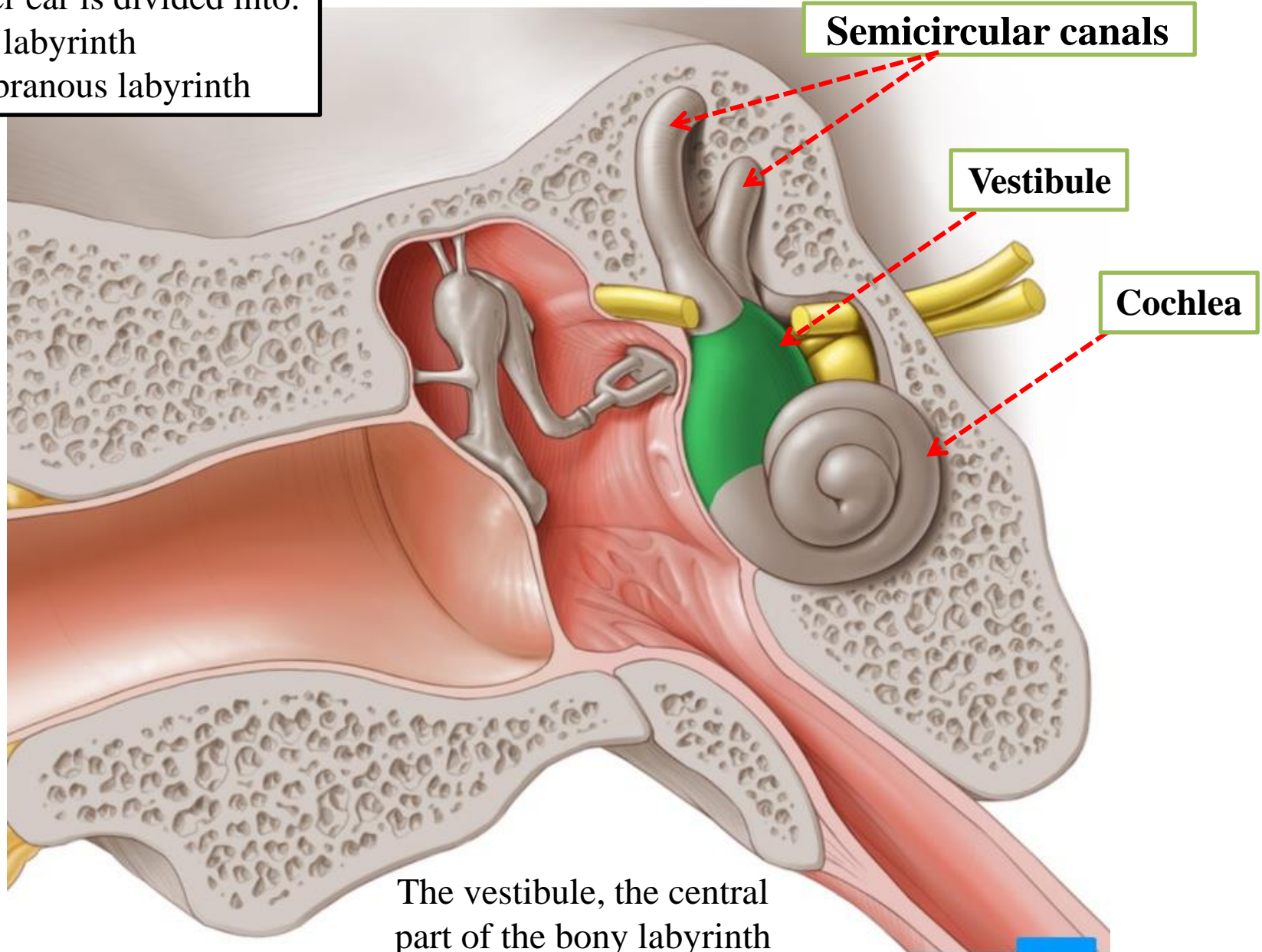
**Internal acoustic meatus**

Inner ear is situated in the petrous part of the temporal bone

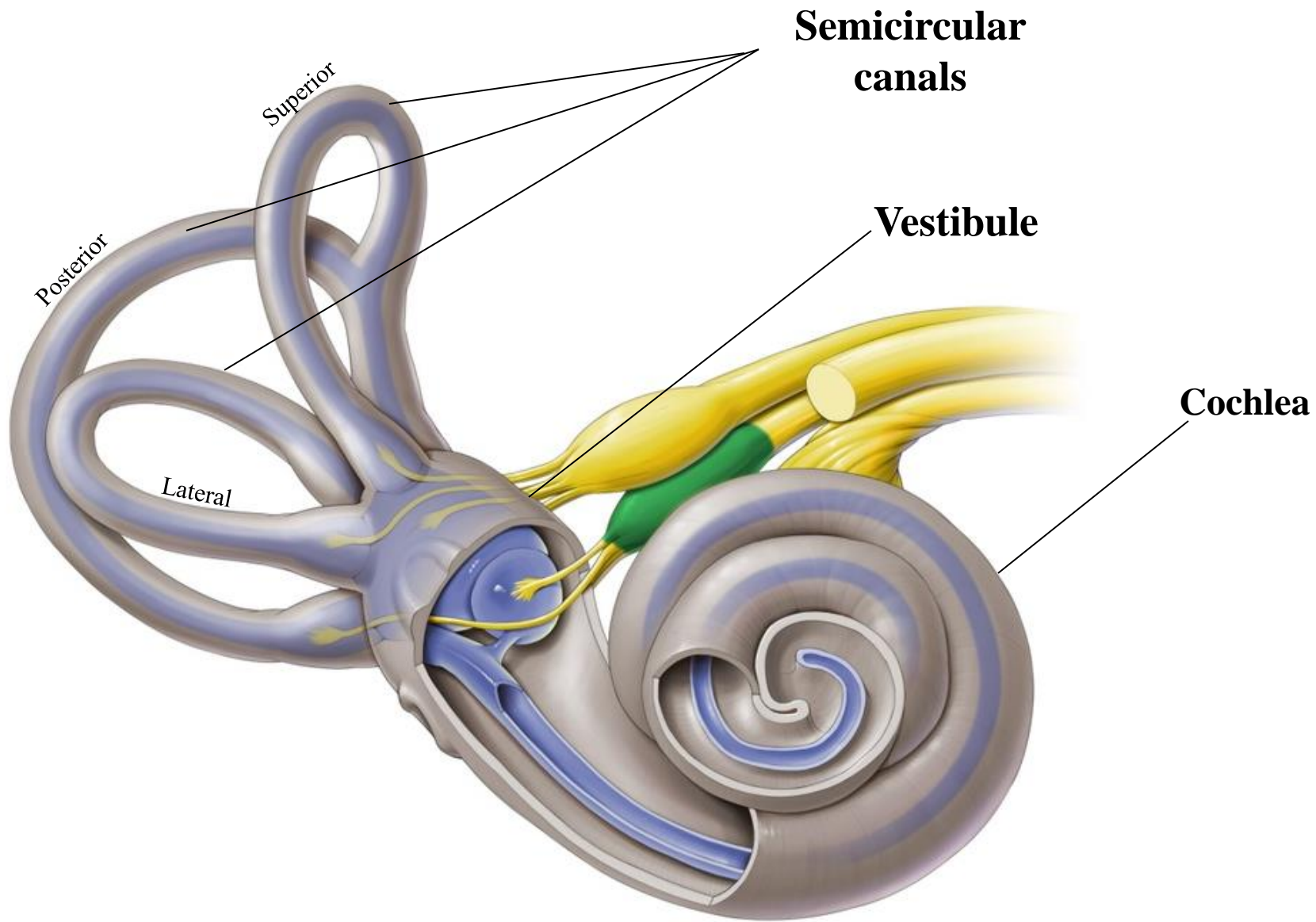
The inner ear is divided into:

1- Bony labyrinth

2- Membranous labyrinth

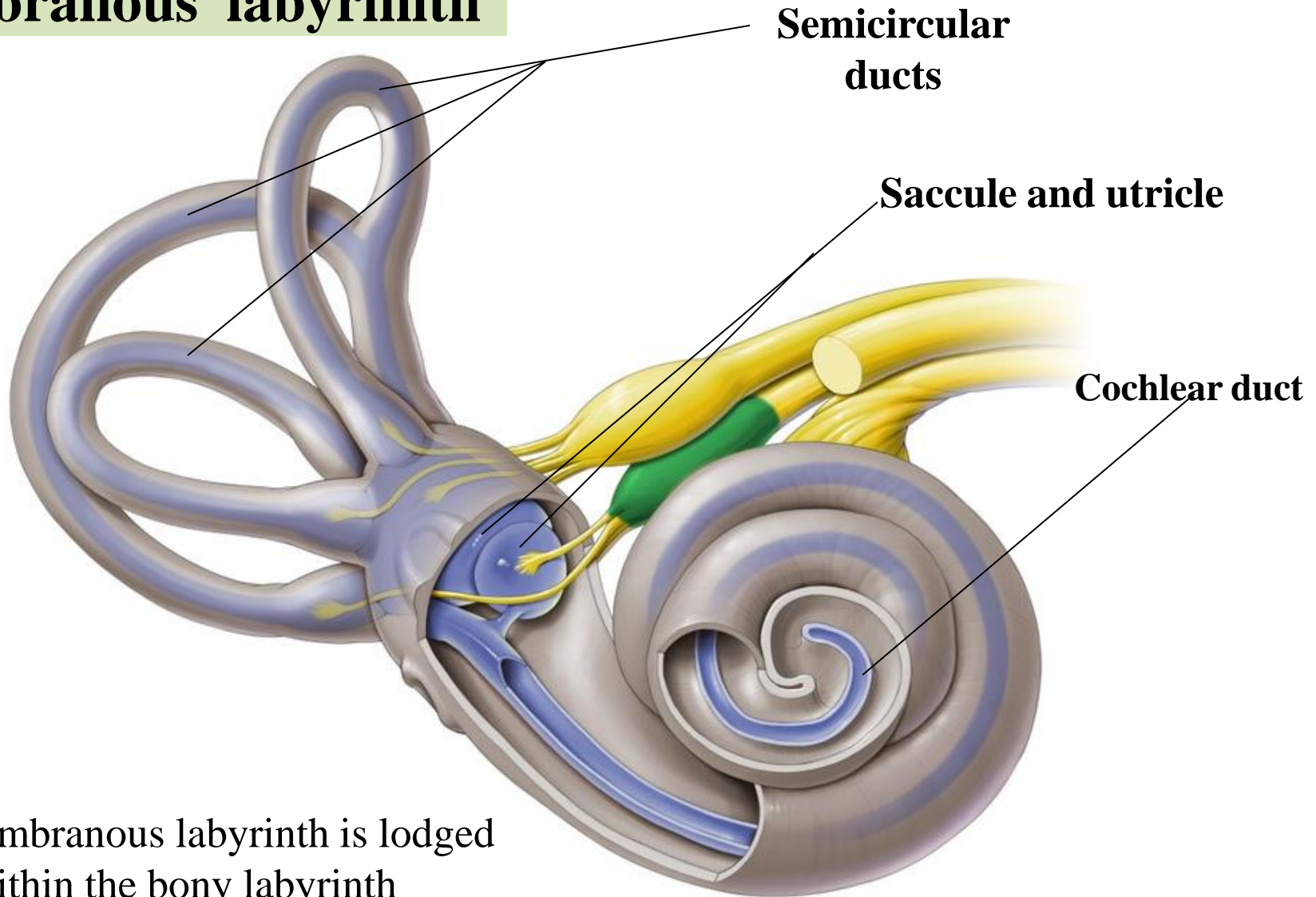


The vestibule, the central part of the bony labyrinth

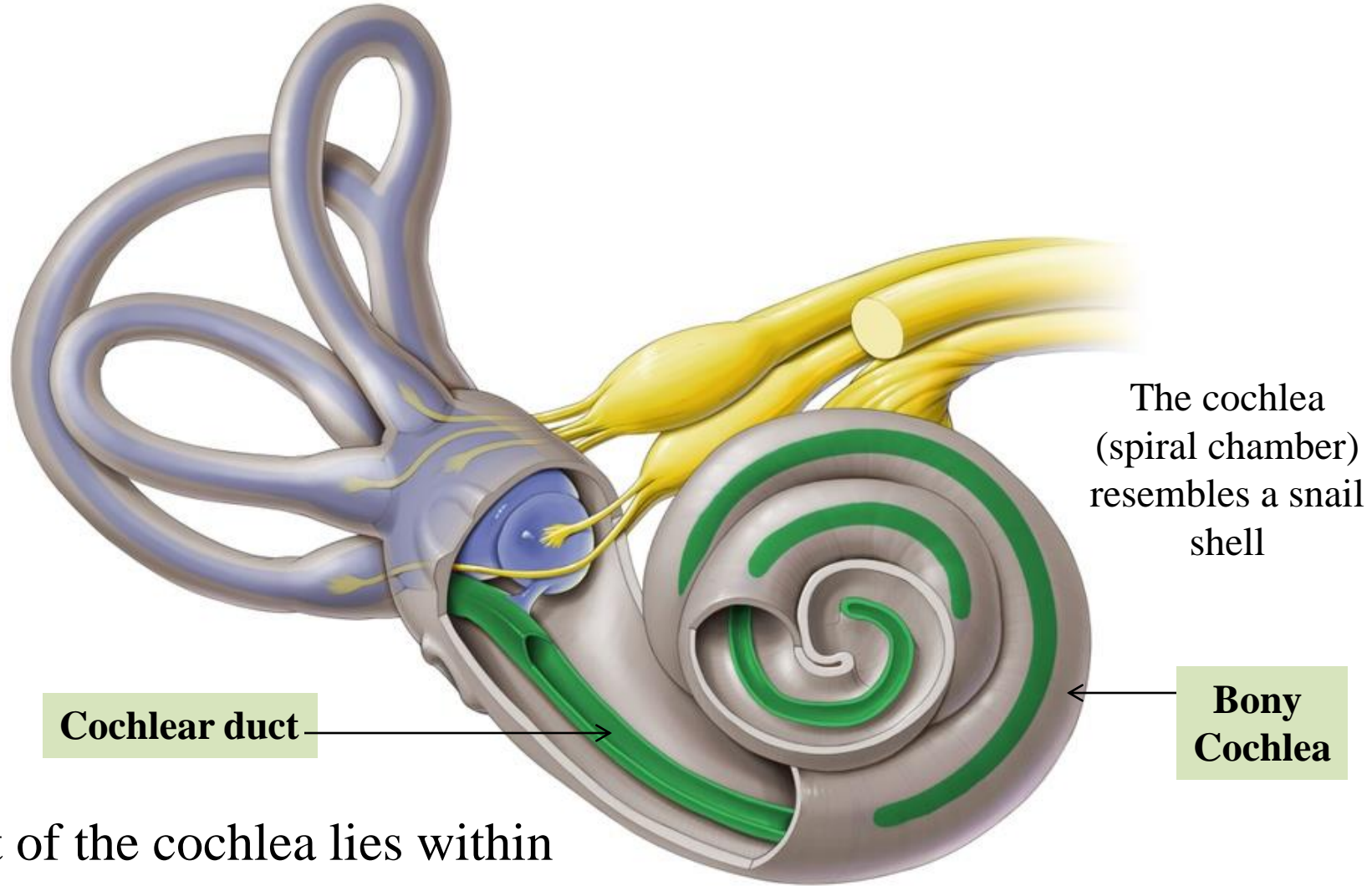


# Bony labyrinth

# Membranous labyrinth



The membranous labyrinth is lodged within the bony labyrinth  
It is filled with **endolymph** and surrounded by **perilymph**



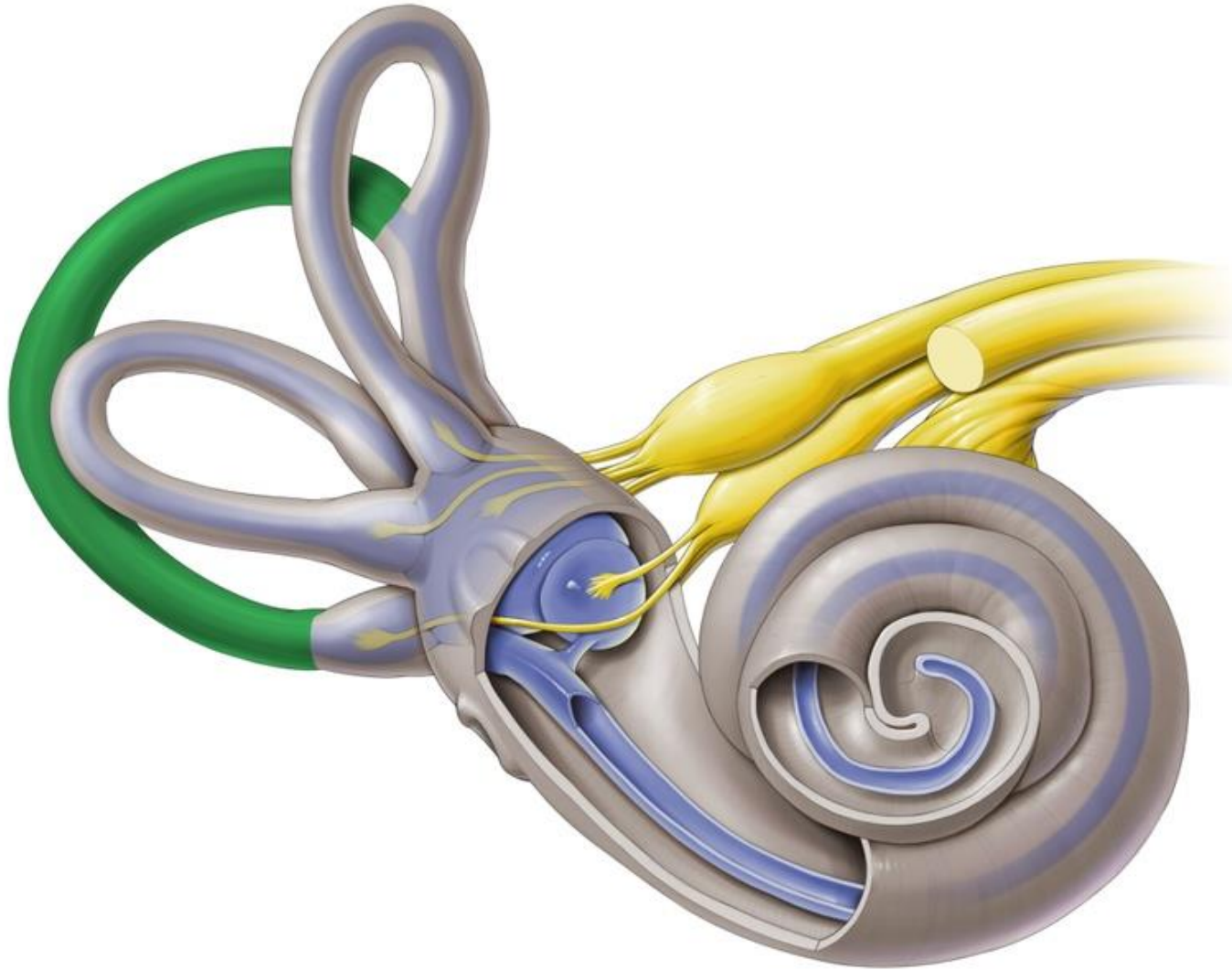
The cochlea (spiral chamber) resembles a snail shell

Cochlear duct

Bony Cochlea

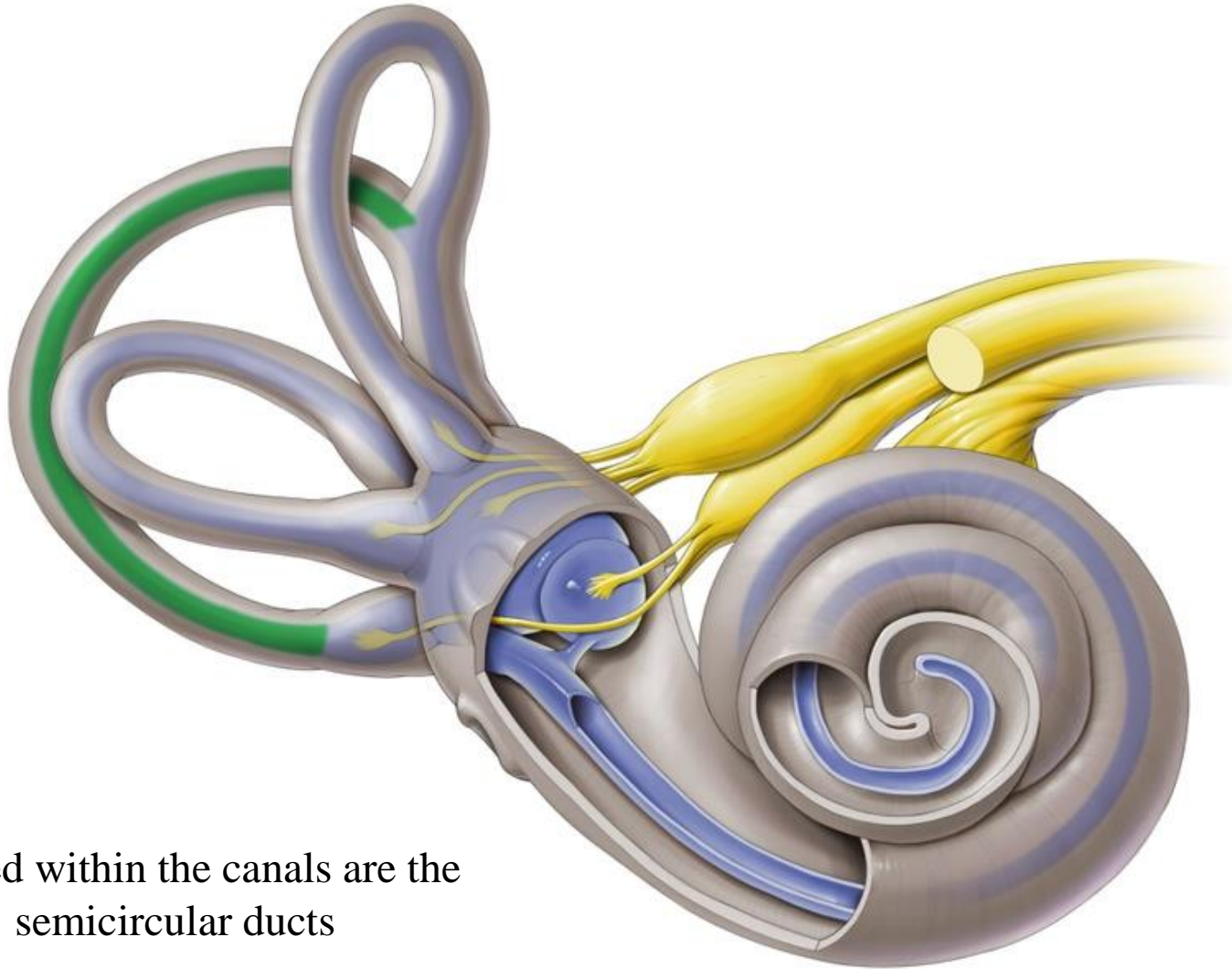
The duct of the cochlea lies within the bony cochlea

# Posterior semicircular canal



*Dr. Heba Kalbouneh*

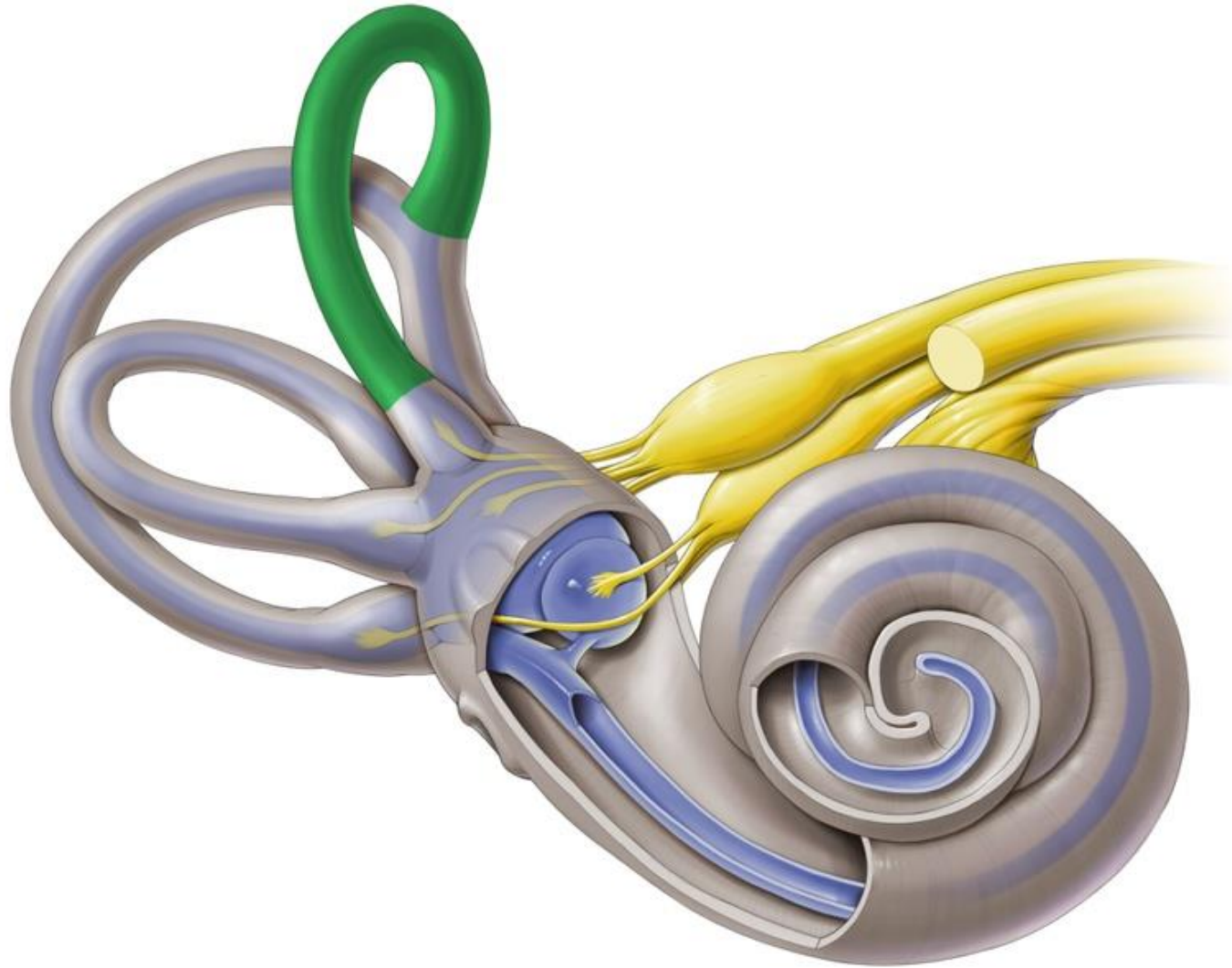
# Posterior semicircular duct



Lodged within the canals are the  
semicircular ducts

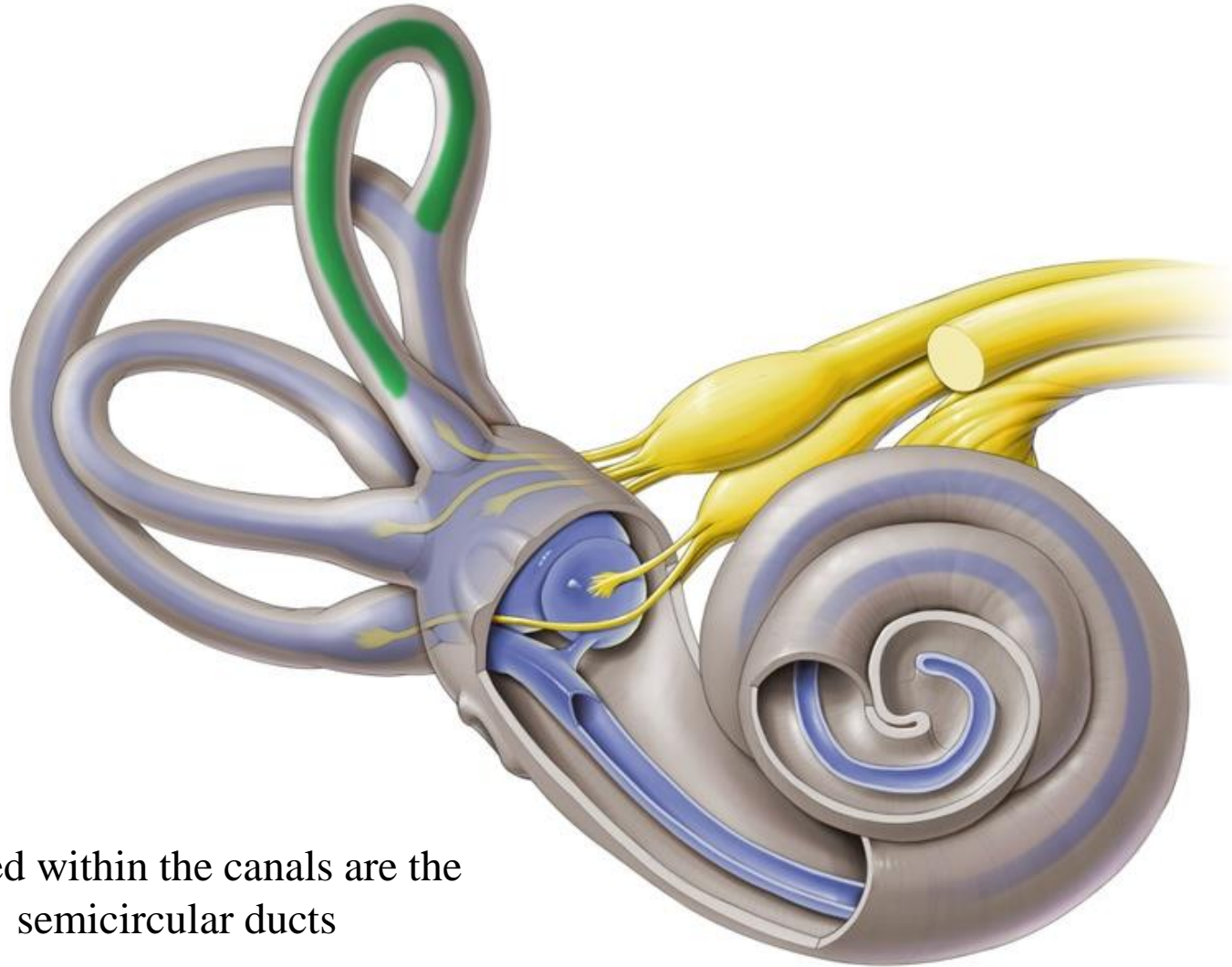


# Superior semicircular canal



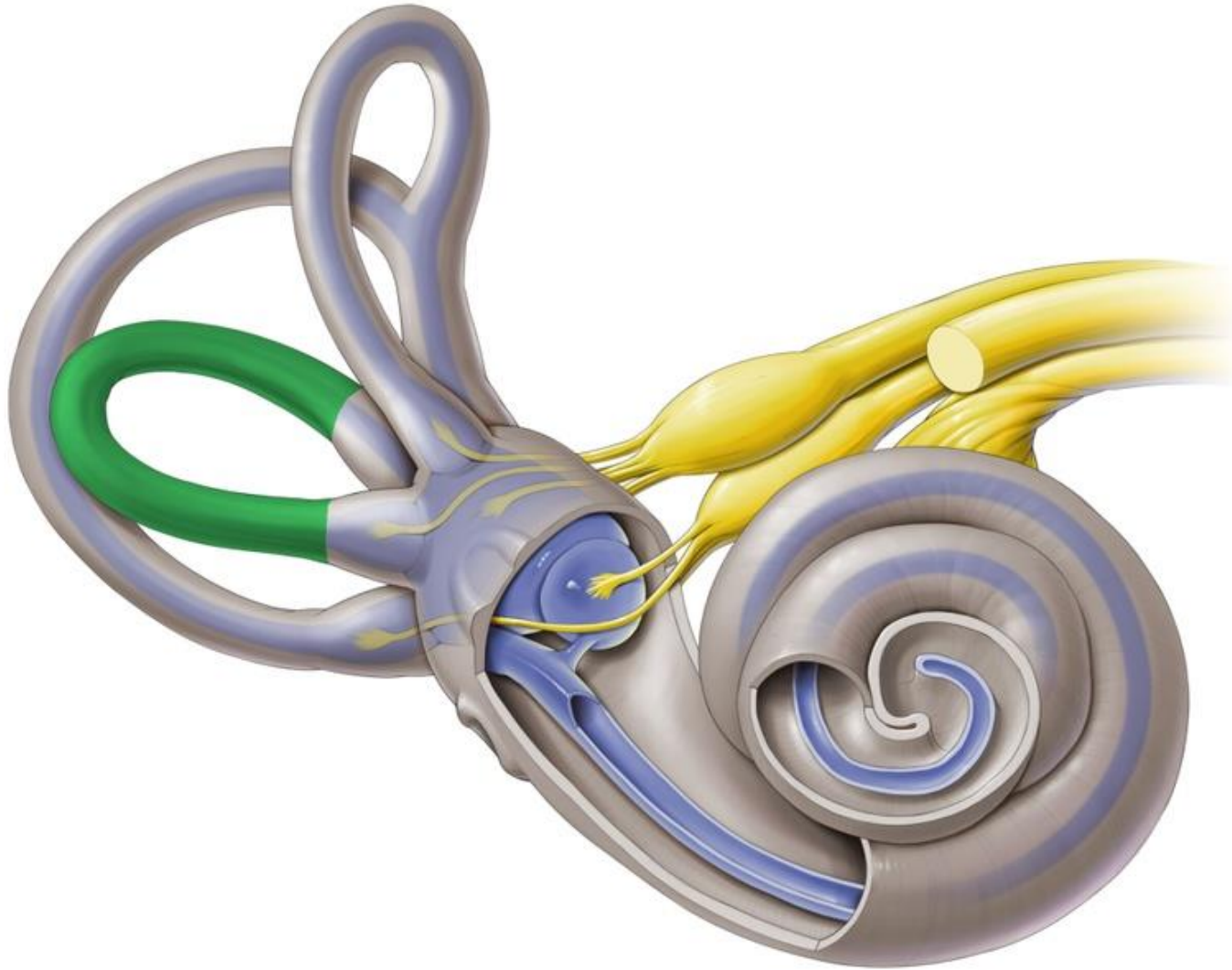
*Dr. Heba Kalbouneh*

# Superior semicircular duct



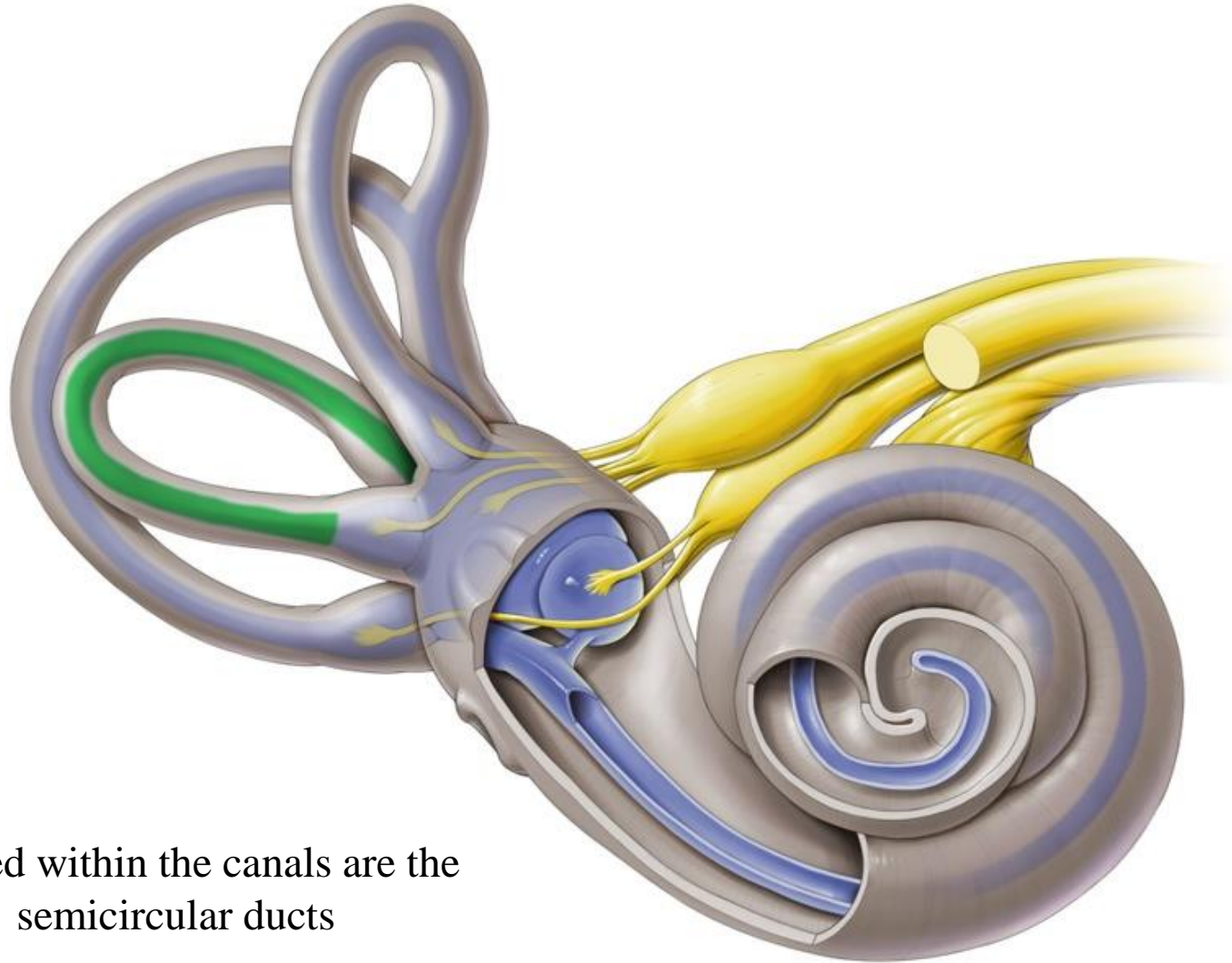
Lodged within the canals are the  
semicircular ducts

# Lateral semicircular canal



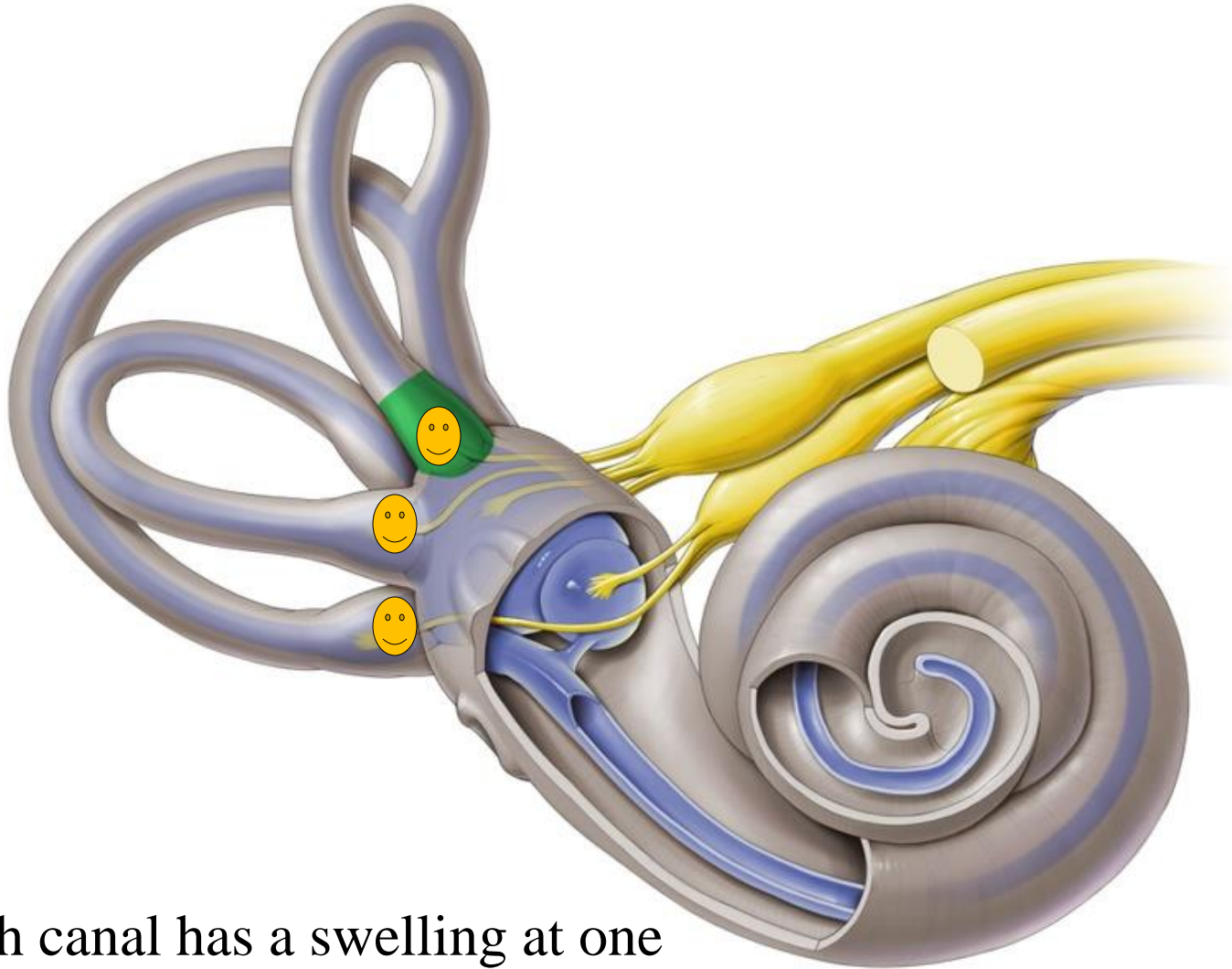
*Dr. Heba Kalbouneh*

# Lateral semicircular duct



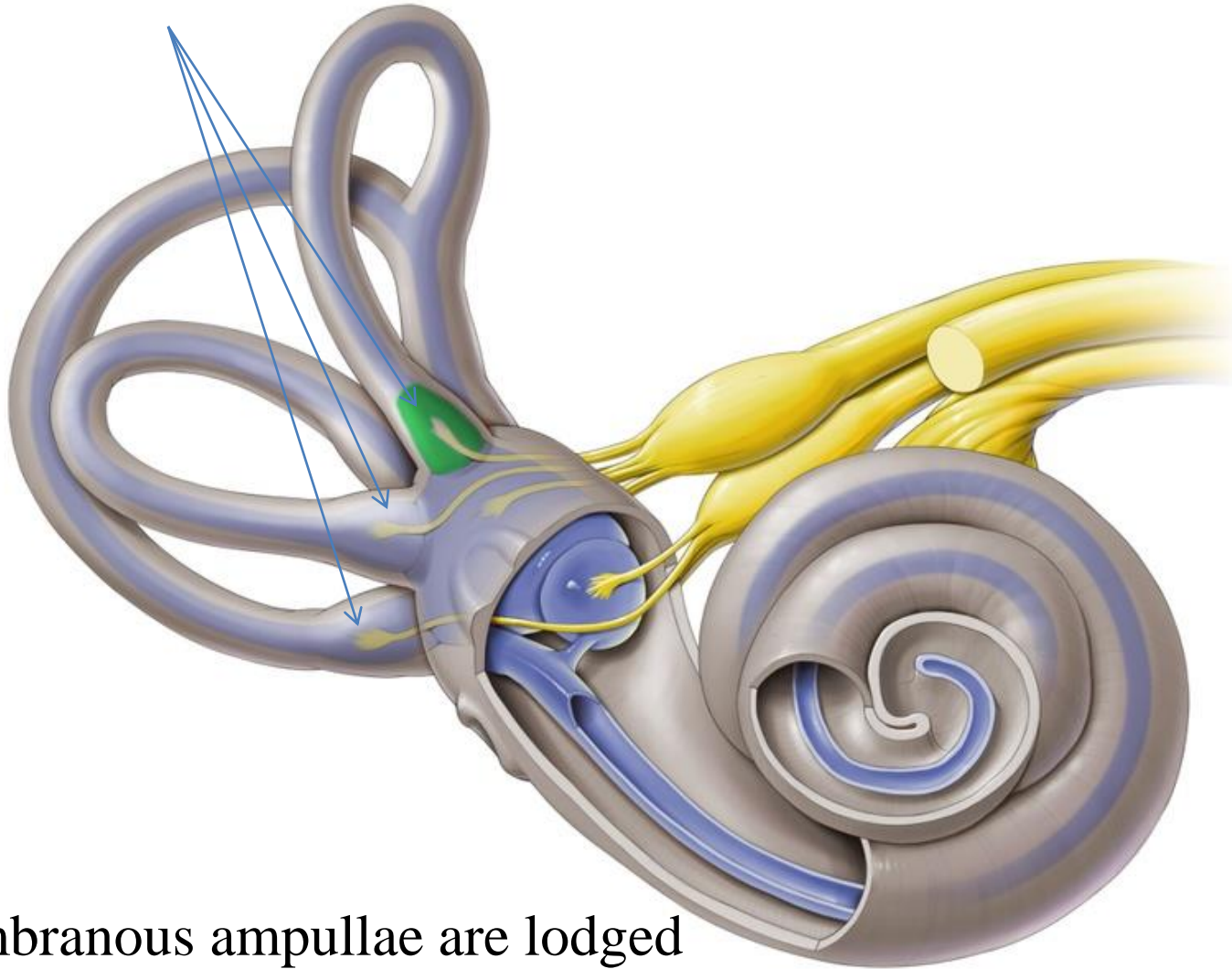
Lodged within the canals are the  
semicircular ducts

# Bony ampullae



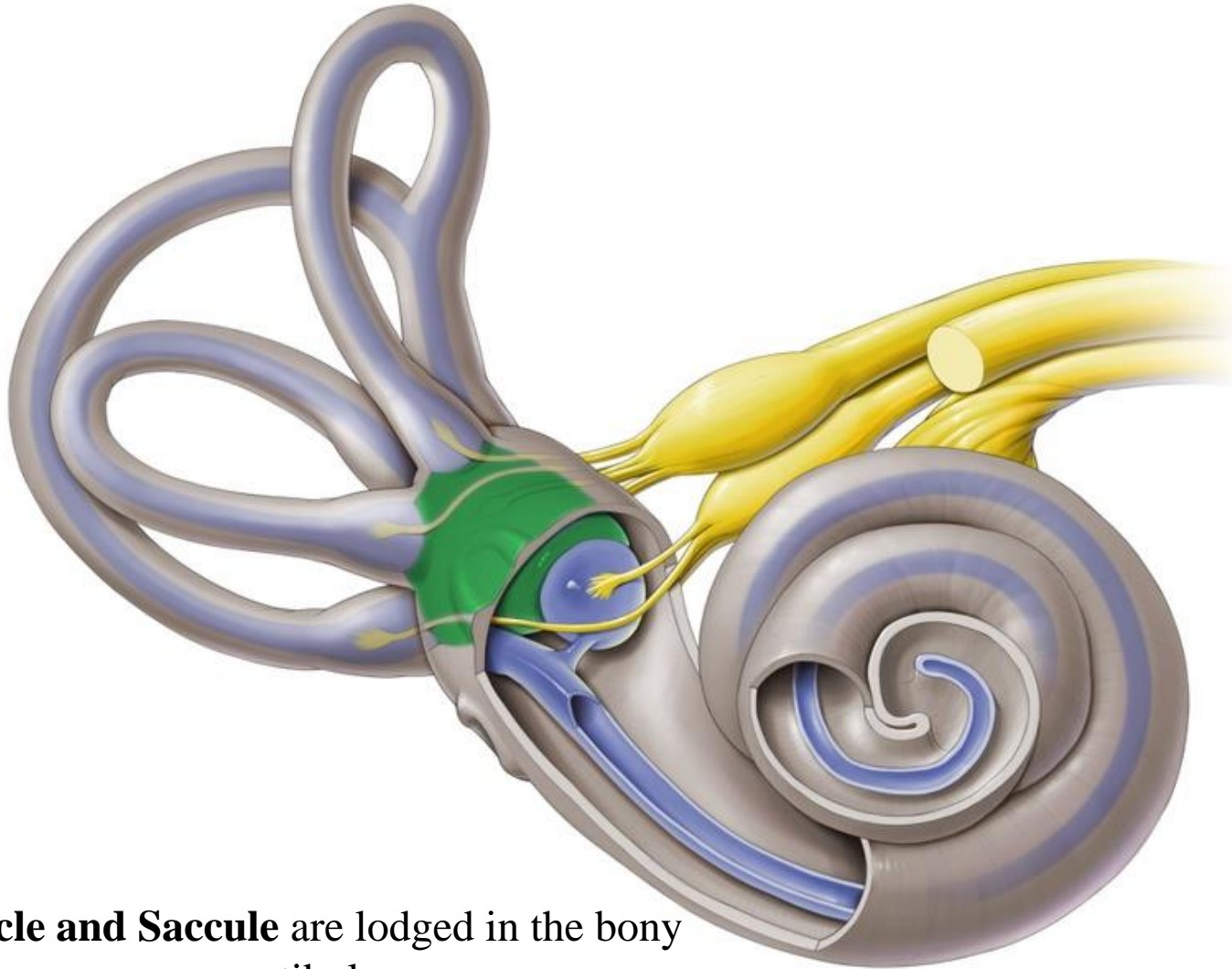
Each canal has a swelling at one end called the **ampulla** 😊

# Membranous ampullae



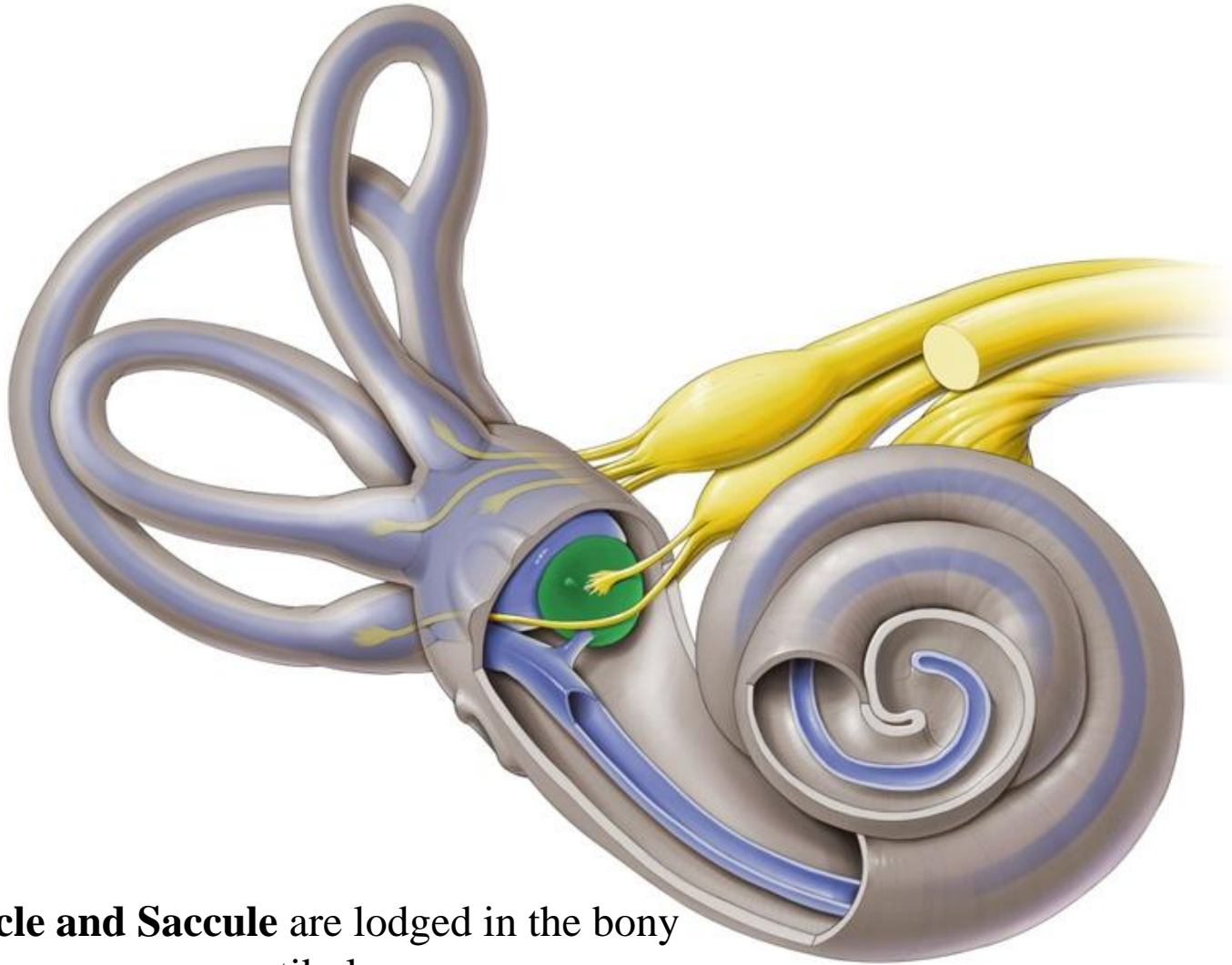
Membranous ampullae are lodged  
in the bony ampullae

# Utricle



**Utricle and Saccule** are lodged in the bony vestibule

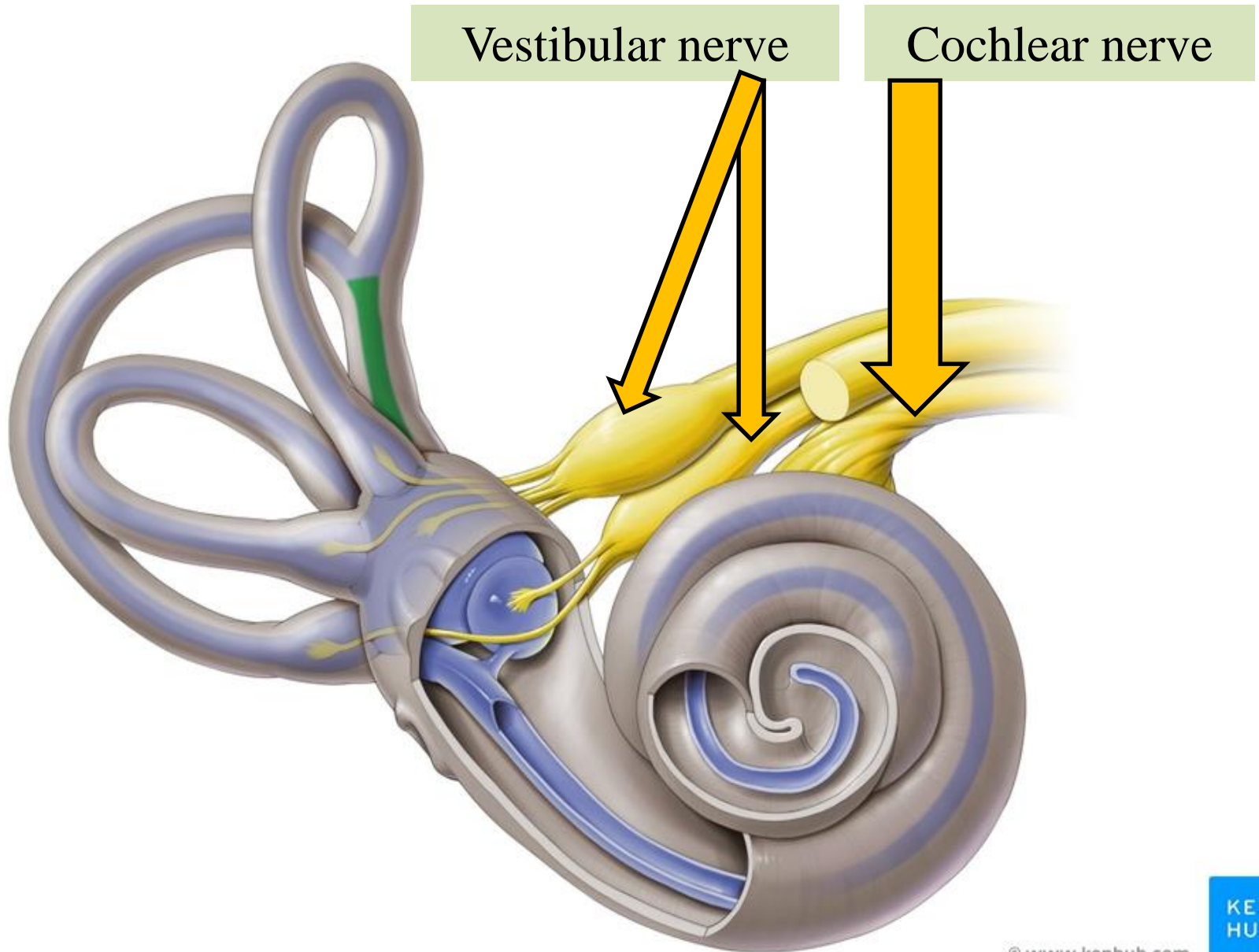
# Saccul



**Utricle and Saccule** are lodged in the bony vestibule




# Vestibulo-cochlear nerve

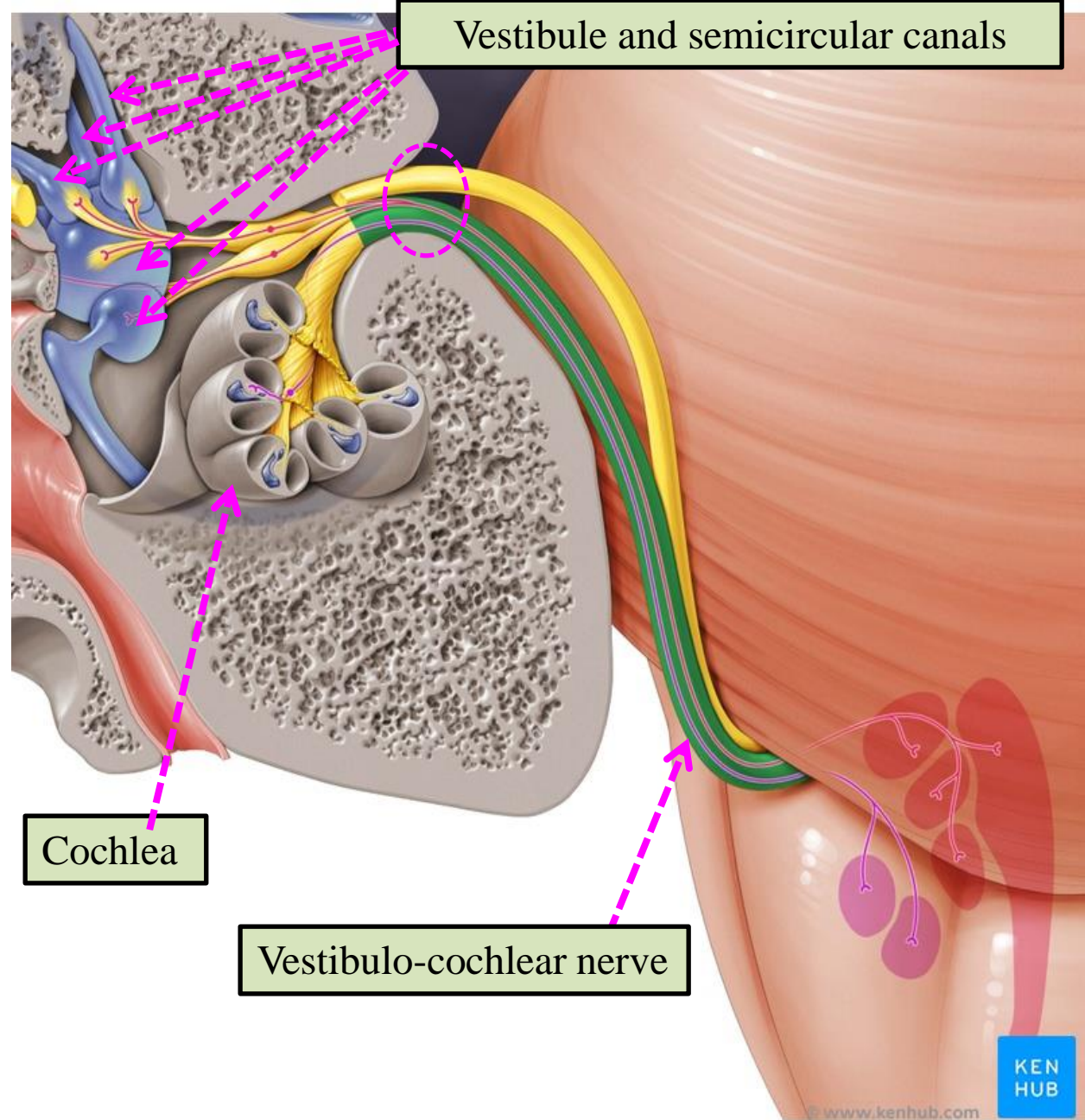


**The inner ear contains  
Sensory receptors for  
hearing and balance**

**Mechanoreceptors/ Hair cells  
(Columnar cells)**



- ✓ Two maculae of the utricle and saccule,
- ✓ Three cristae ampullares in the ampullae of each semicircular duct
- ✓ The organ of Corti in the cochlear duct.



**Cristae**

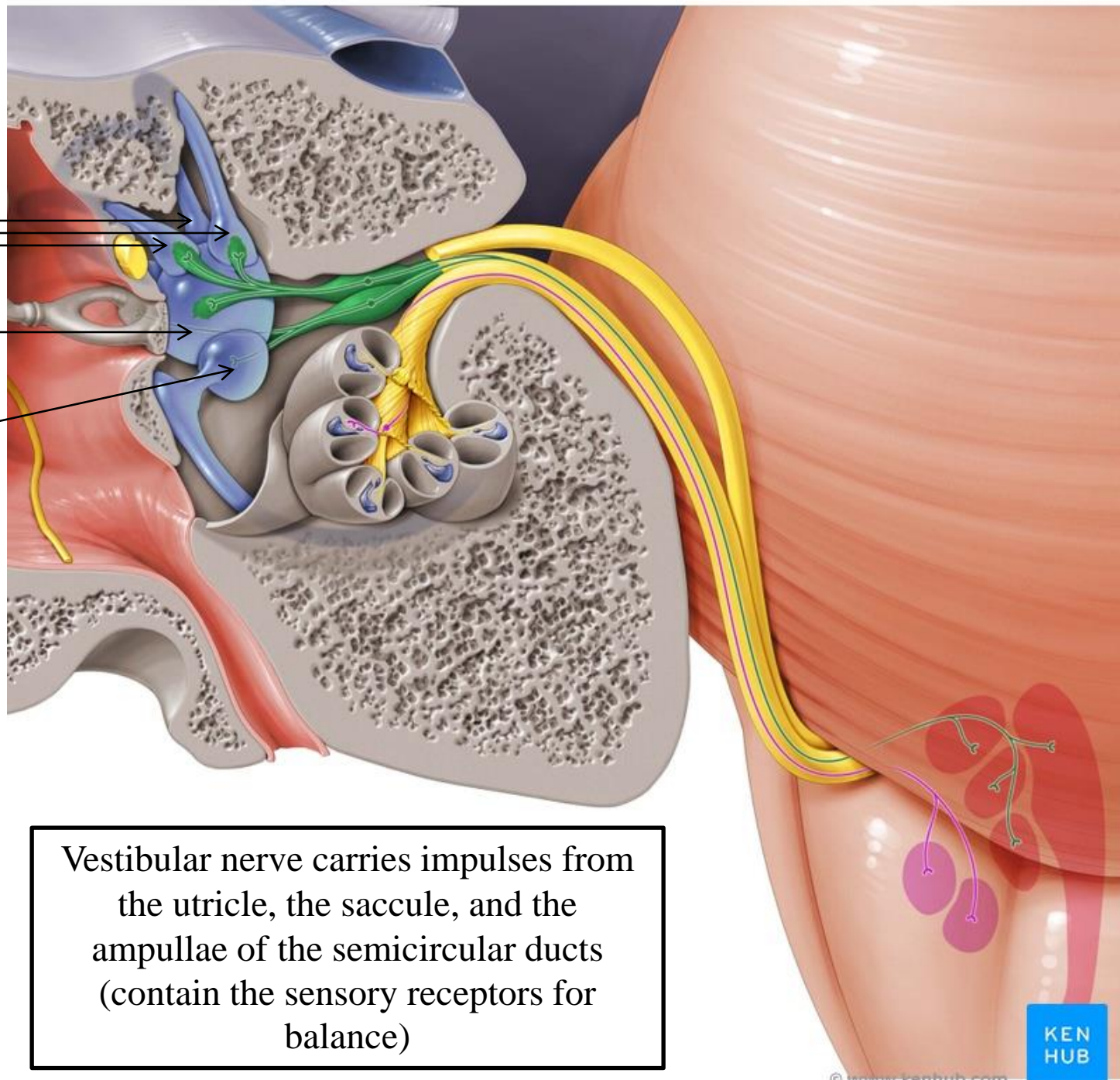
Ampullae of  
semicircular canals

Vestibule

Utricle

Sacculae

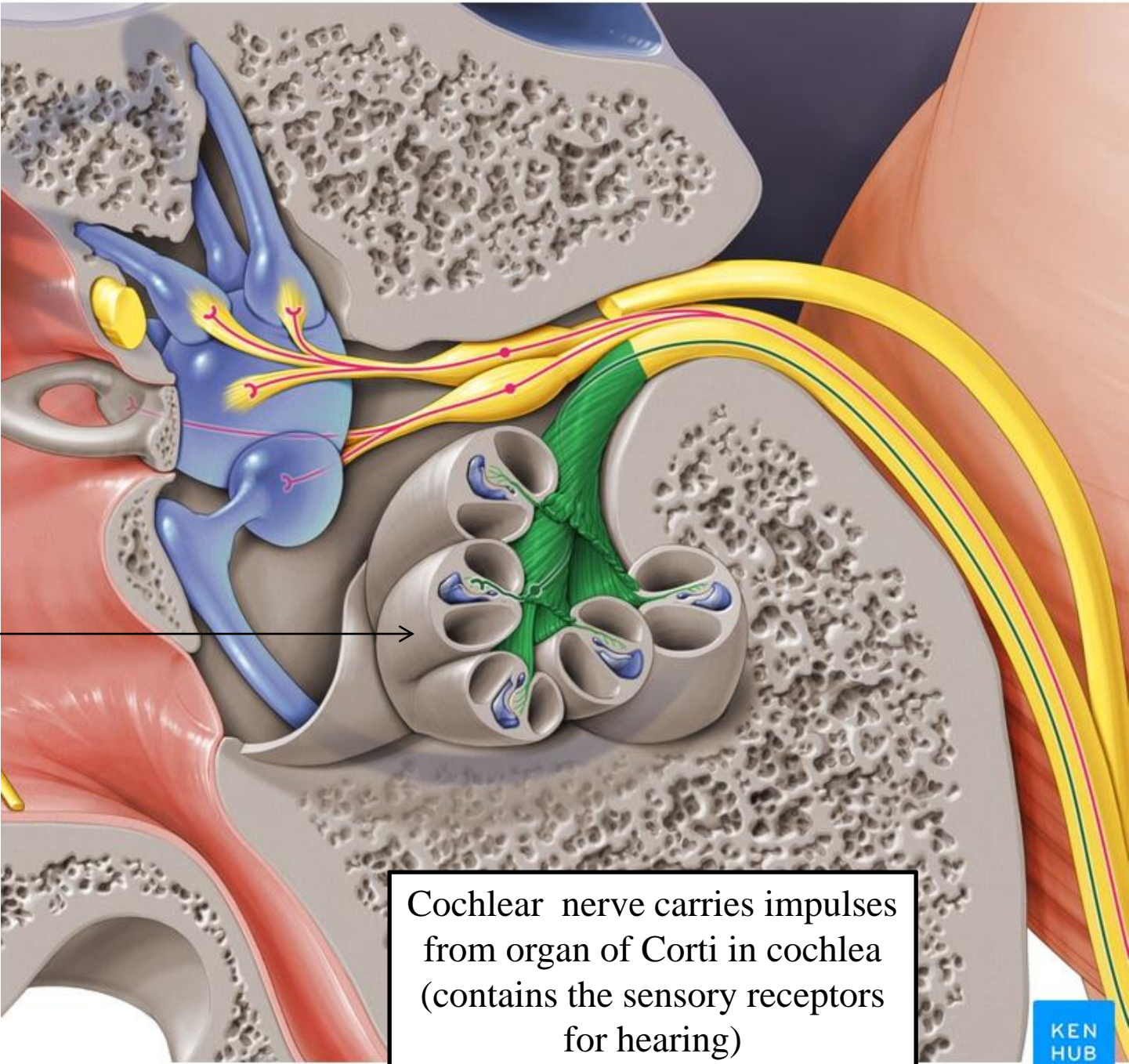
**Maculae**



Vestibular nerve carries impulses from the utricle, the saccule, and the ampullae of the semicircular ducts (contain the sensory receptors for balance)

**Organ of Corti**

Cochlea

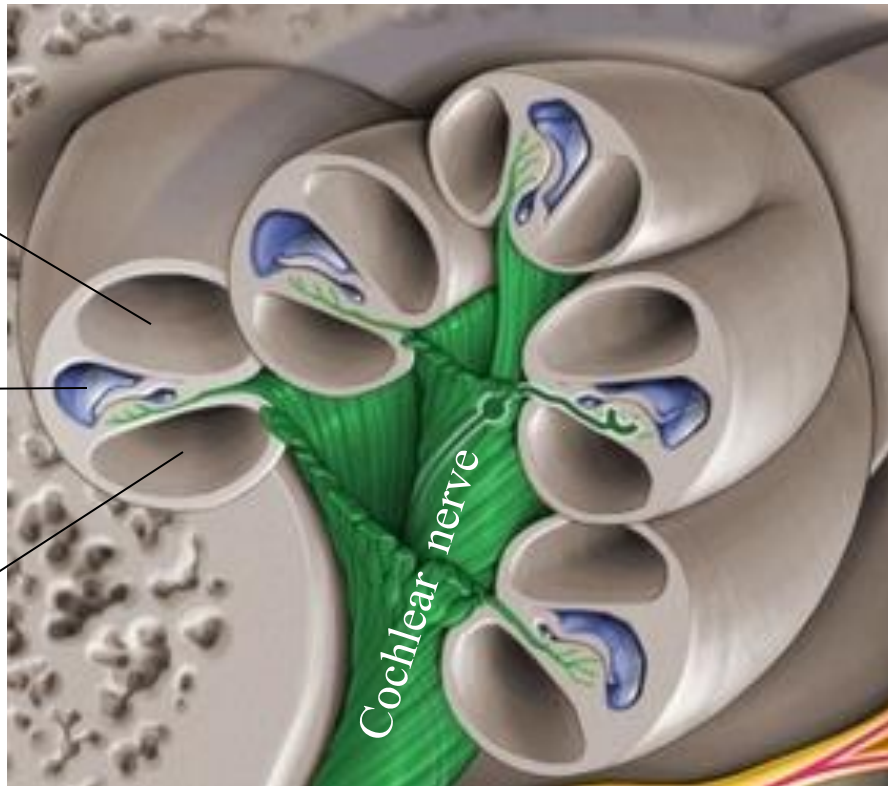


Cochlear nerve carries impulses from organ of Corti in cochlea (contains the sensory receptors for hearing)

Scala vestibuli  
(perilymph)

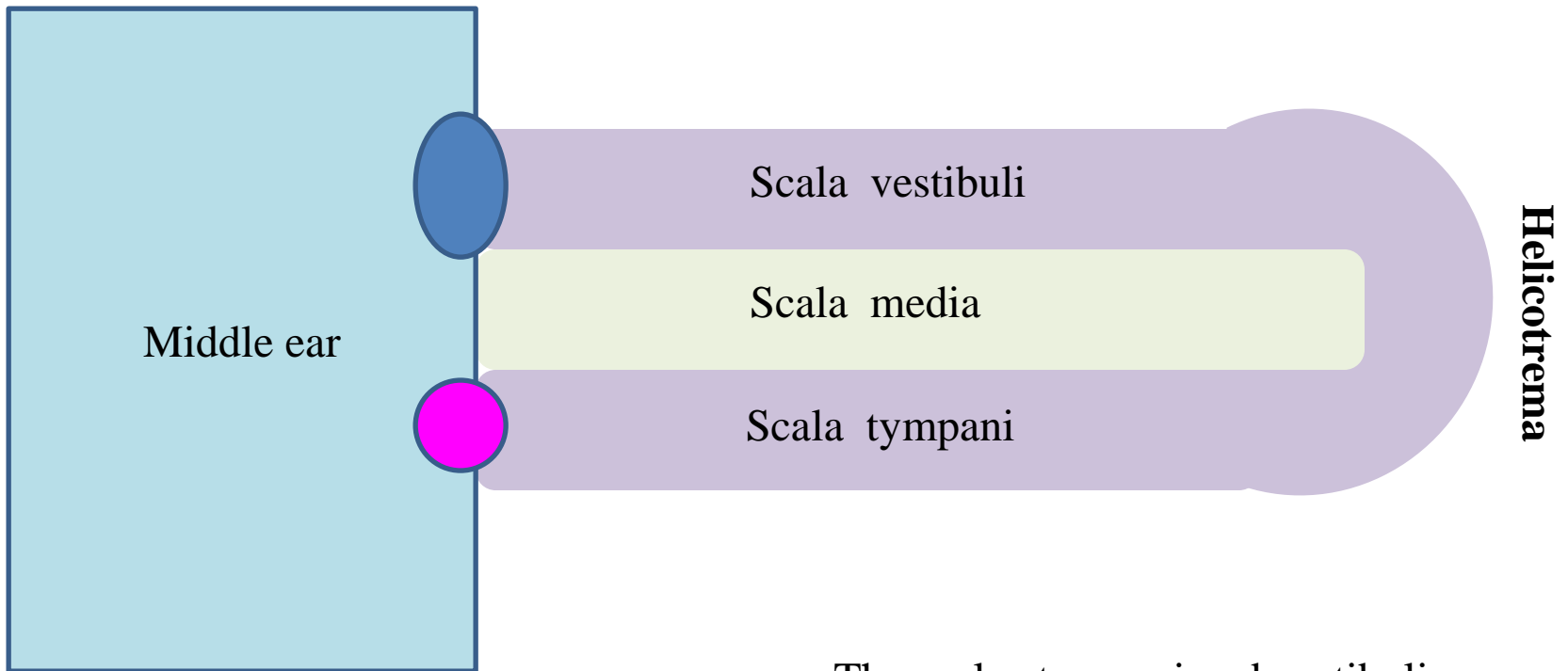
Scala media  
(Cochlear duct)  
(endolymph)

Scala tympani  
(perilymph)



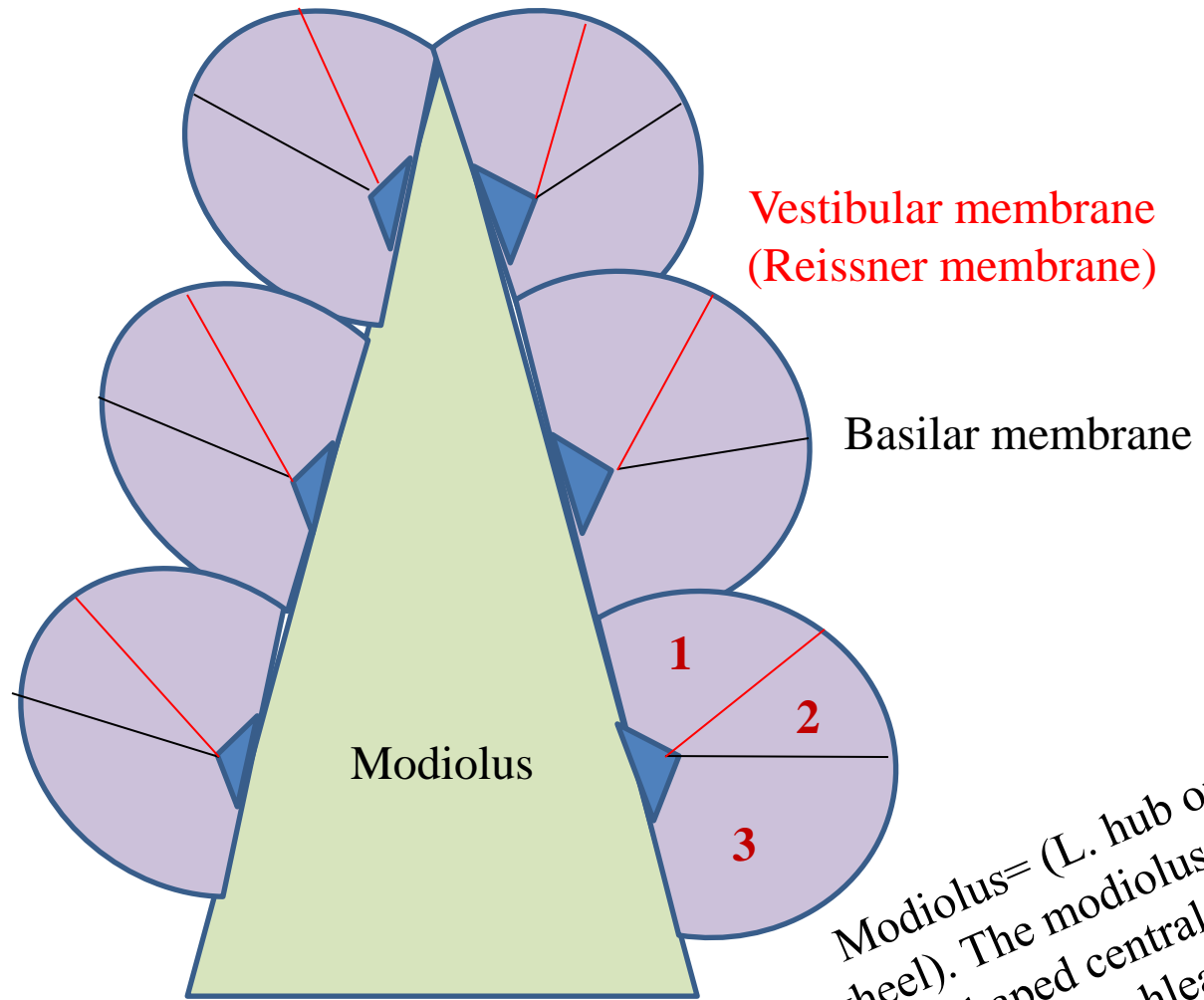
Section through  
cochlea

- ✓ The cochlear duct itself forms the middle compartment, or scala media, filled with endolymph. It is continuous with the saccule and ends at the apex of the cochlea.
- ✓ The larger scala vestibuli contains perilymph and is separated from the scala media by the very thin vestibular membrane (Reissner membrane)
- ✓ The scala tympani also contains perilymph and is separated from the scala media by the basilar membrane



The *scalae* tympani and vestibuli communicate with each other at the apex of the cochlea via the **helicotrema**

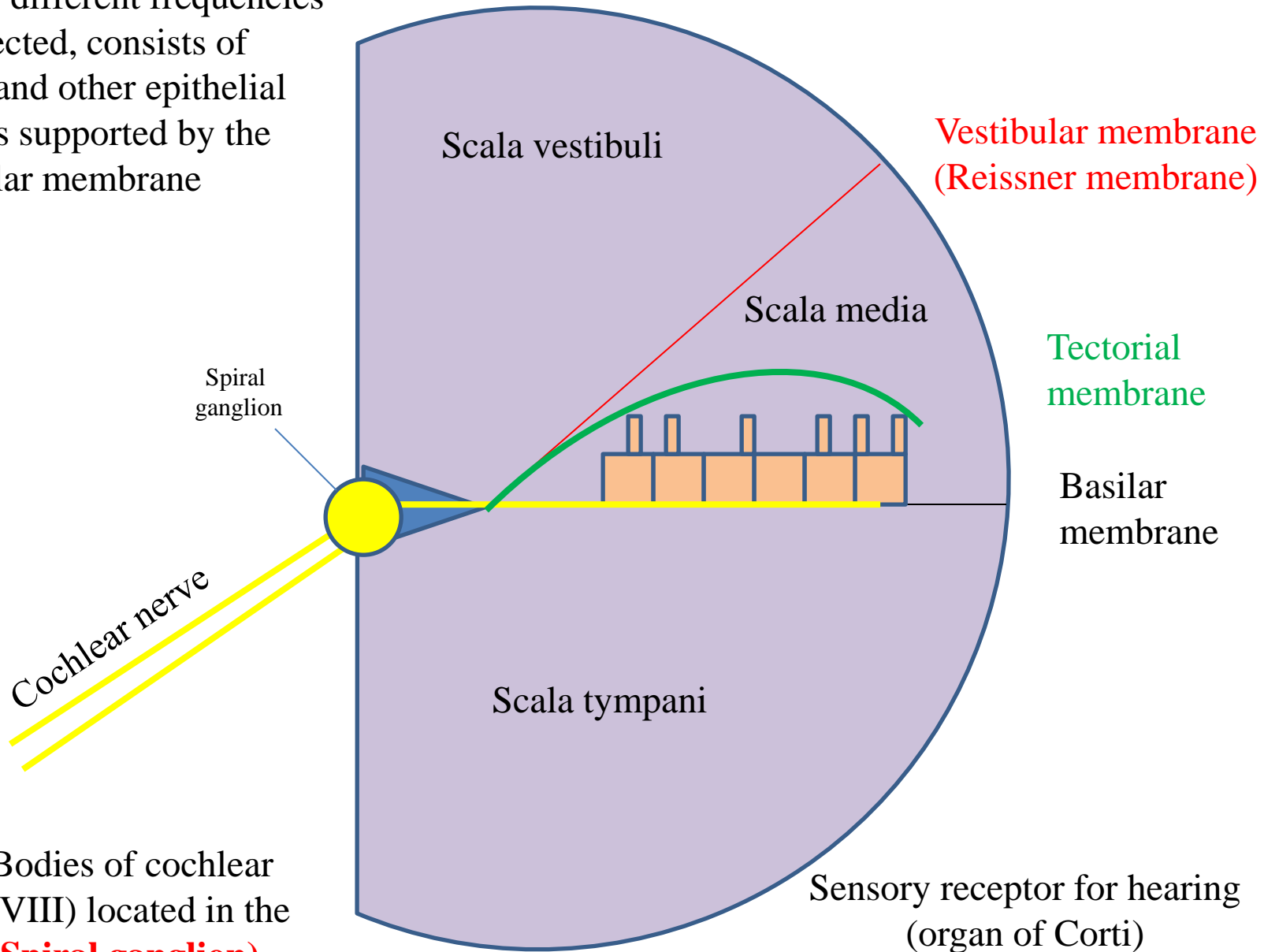
- 1: Scala vestibuli
- 2: Scala media (Cochlear duct)
- 3: Scala tympani



The cochlea is about 35 mm long and makes  $2\frac{3}{4}$  turns around a bony core called the **modiolus**

Modiolus= (L. hub of wheel). The modiolus is a conical shaped central axis in the cochlea. Cochlear nerve and spiral ganglion are situated inside it

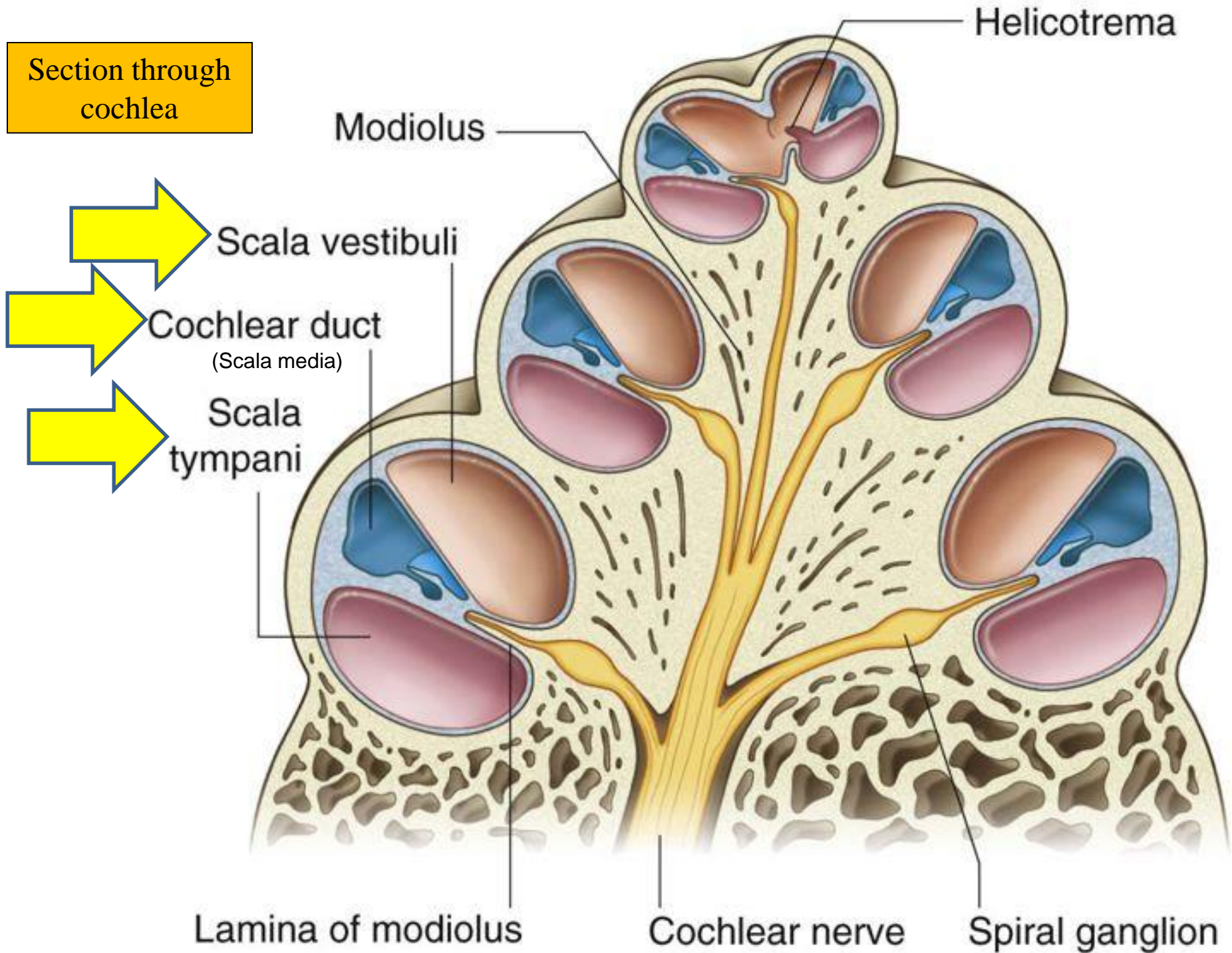
The **organ of Corti, or spiral organ**, where sound vibrations of different frequencies are detected, consists of hair cells and other epithelial structures supported by the basilar membrane



Note: Cell Bodies of cochlear Nerve (CN VIII) located in the Modiolus (**Spiral ganglion**)



Section through cochlea



Section through cochlea

Scala vestibuli

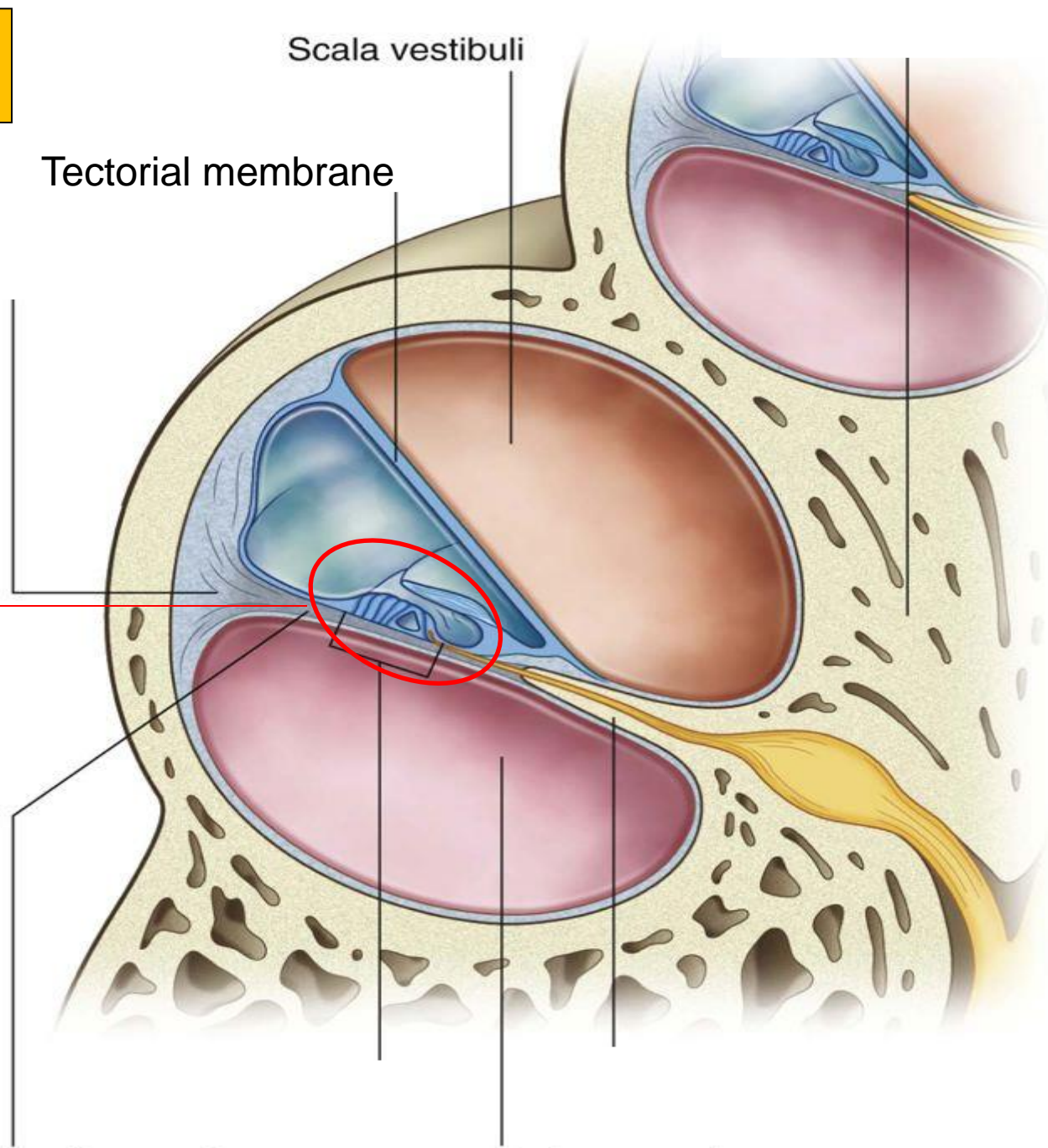
Tectorial membrane


Organ of corti

The auditory nerve (cochlear) carries the electrical signal to the brain, which turns it into a sound that we recognize and understand

Basilar membrane

Scala tympani





With the tectorial membrane removed, SEM shows the apical plate of the rat spiral organ through which rigid stereocilia bundles project into endolymph

The auditory hair cells are located within the spiral organ of Corti on the basilar membrane in the cochlea of the inner ear

Stereocilia (*hair bundles*) protrude from the apical surface of the cell into the fluid-filled cochlear duct.

The inner hair cells transform the sound vibrations in the fluids of the cochlea into electrical signals that are then relayed via the auditory nerve to the auditory brainstem and to the auditory cortex

Read only

The deflection of the hair-cell stereocilia opens mechanically gated ion channels that allow positively charged ions (primarily potassium) to enter the cell.



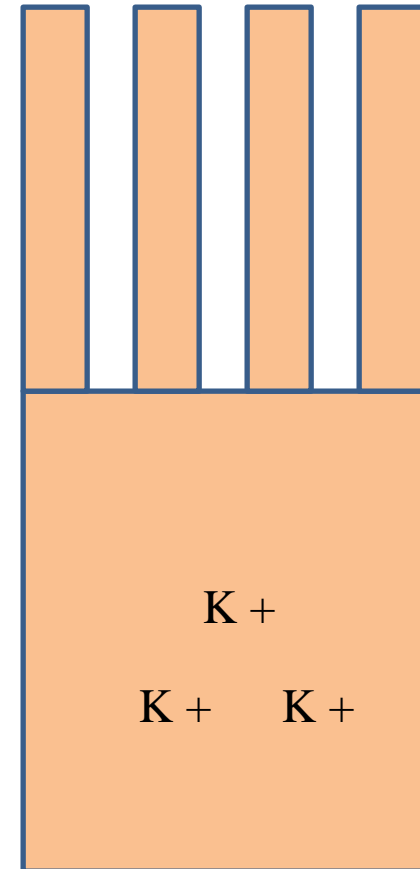
The influx of positive ions from the endolymph in the scala media depolarizes the cell, resulting in a receptor potential

*Damage to these hair cells results in decreased hearing sensitivity, and because the inner ear hair cells cannot regenerate, this damage is permanent*

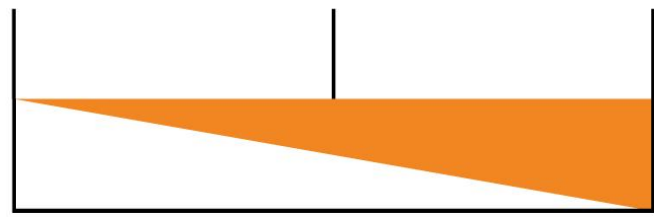
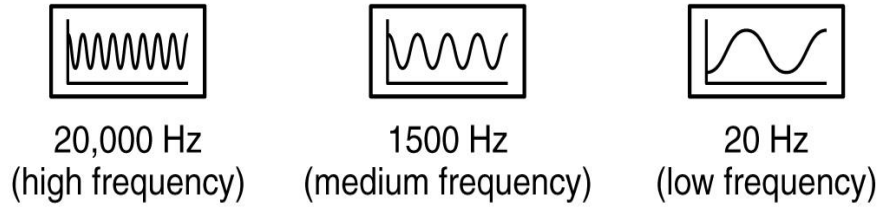
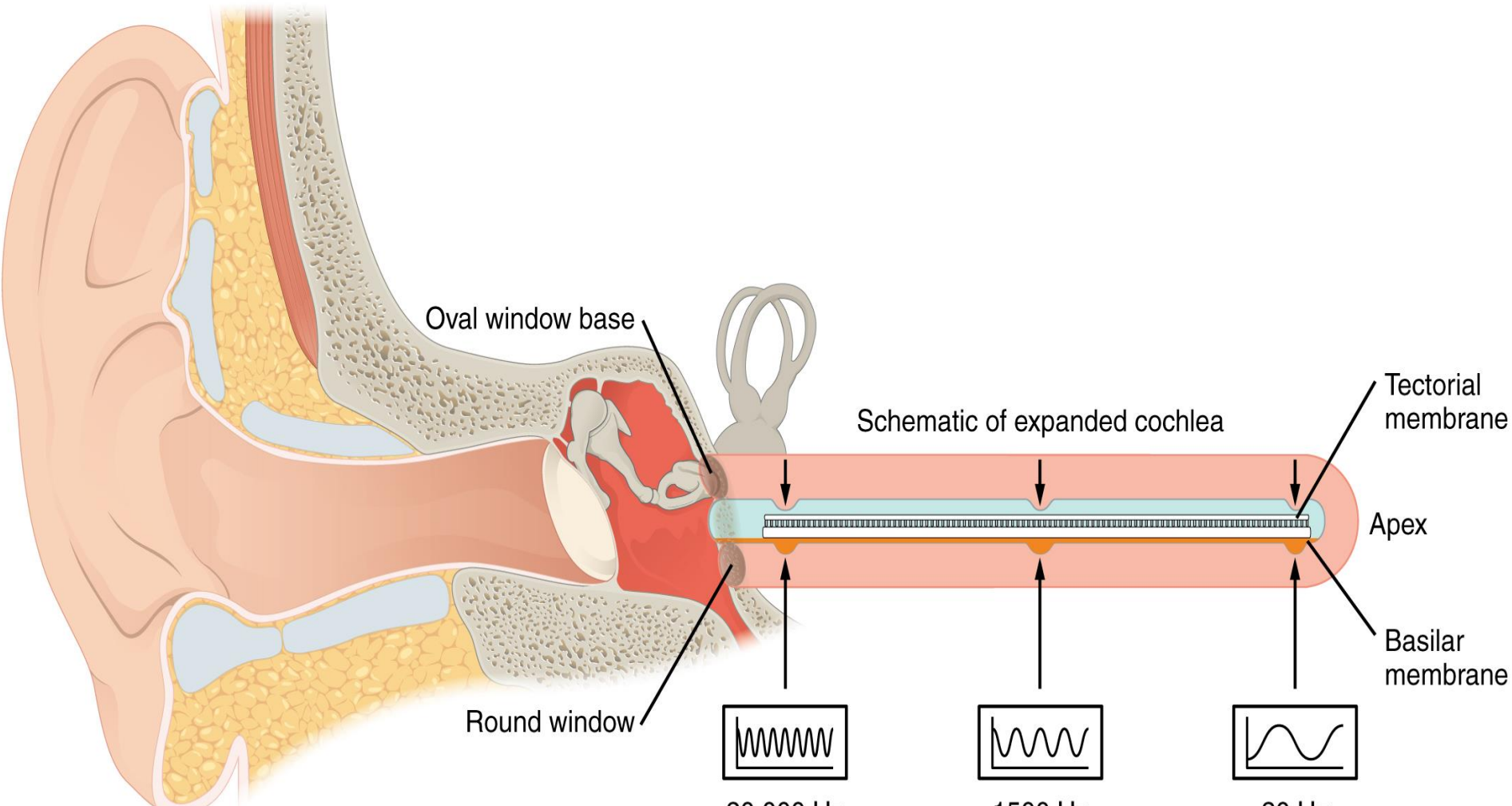
K<sup>+</sup> channels open



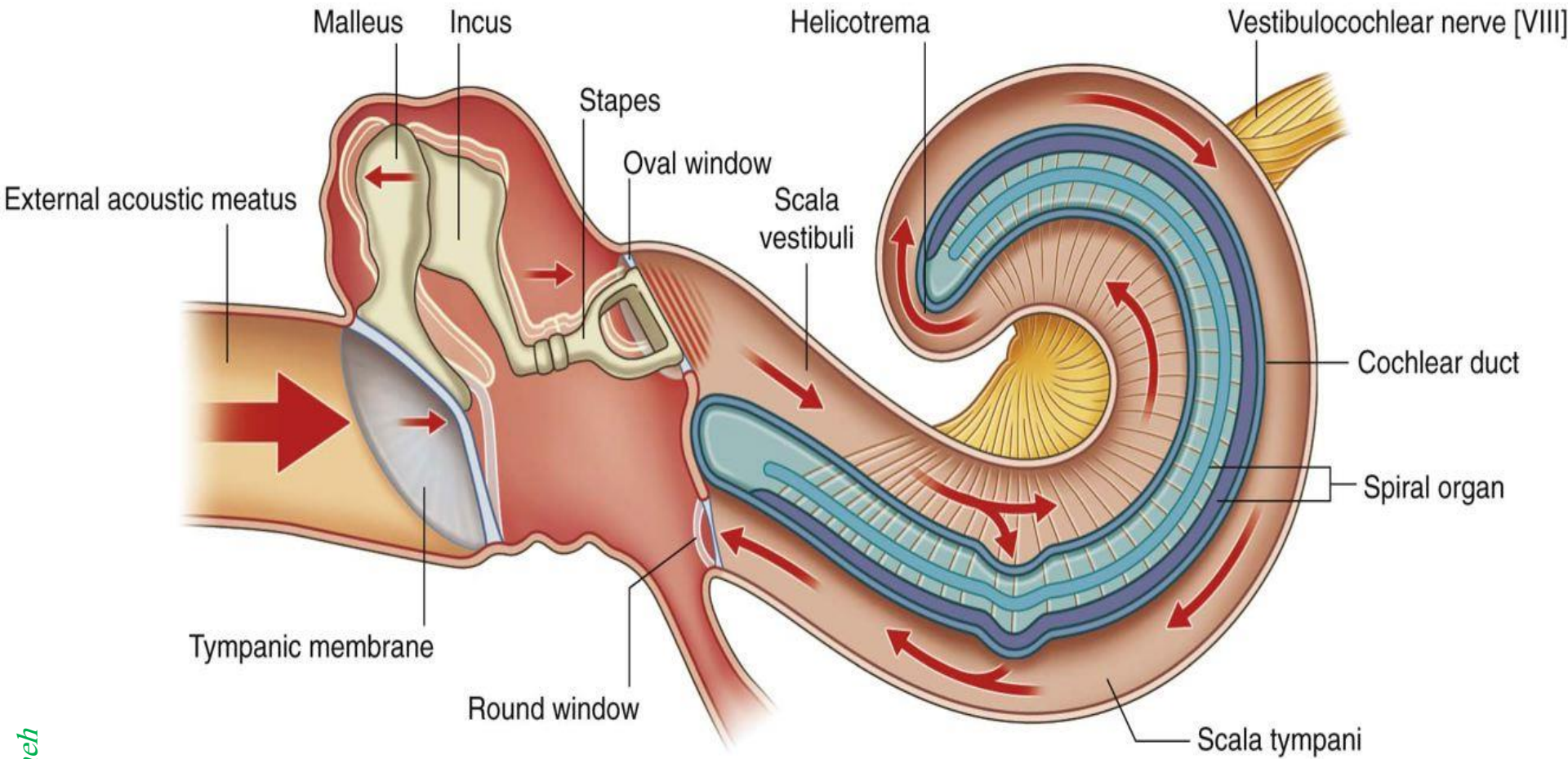
K<sup>+</sup> channels close



Note: hair cells detect movement



# Transmission of sound



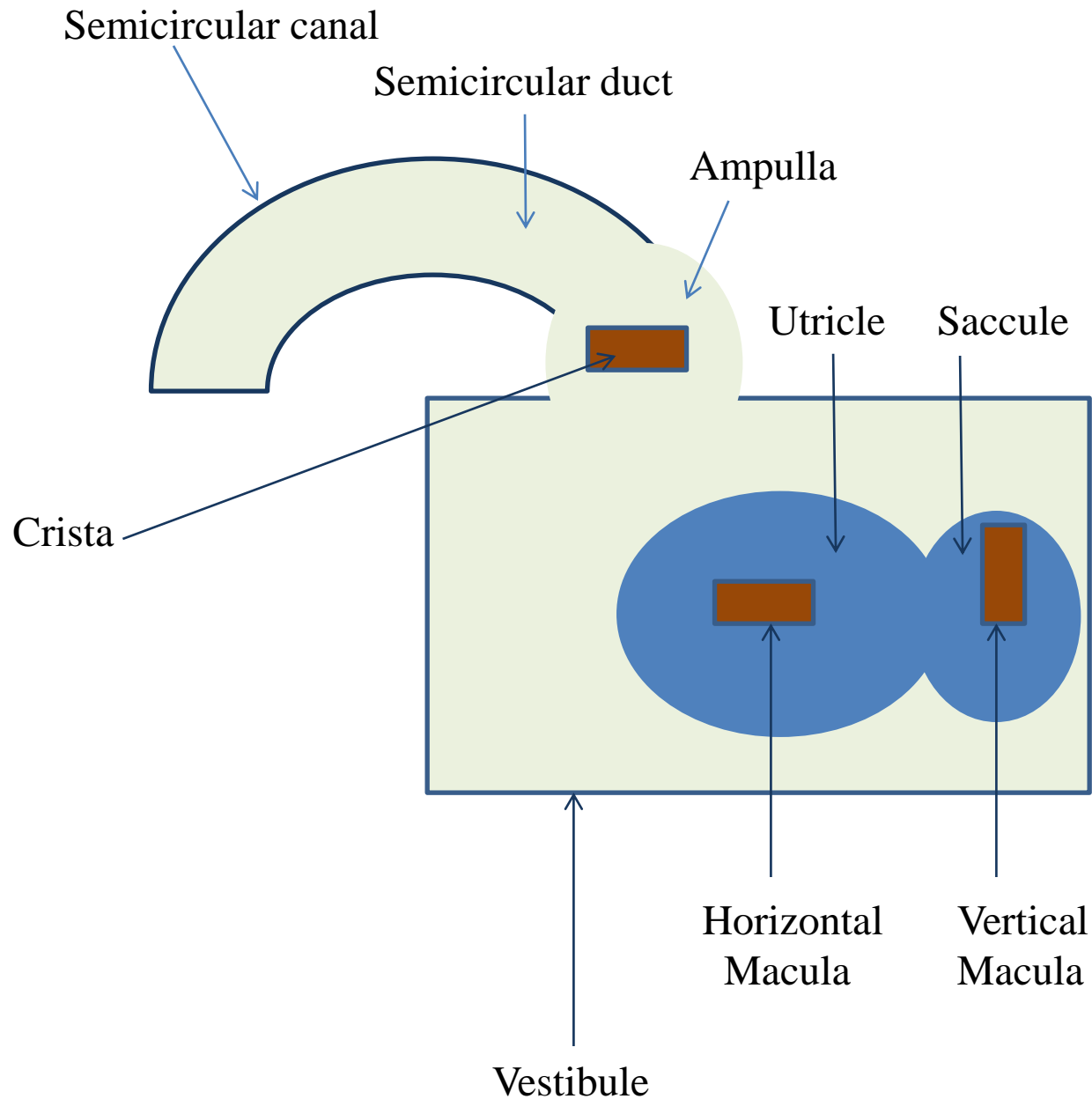
Problems of the vestibular system can result in **vertigo, or dizziness**, a sense of bodily rotation and lack of equilibrium.

Spinning the body produces vertigo due to overstimulation of the cristae ampullares of the semicircular ducts.

Overstimulation of the maculae of the utricle caused by repetitive changes in linear acceleration and directional changes can normally lead to motion sickness (sea sickness/ car sickness).



Sensory receptors for balance (saccul, utricle and semicircular ducts)

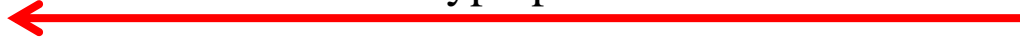

Maculae : detect linear acceleration of the head (static balance)  
Cristae: detect angular acceleration of the head (kinetic balance)

Depolarization



Hyperpolarization




Gelatinous layer



Bending of these stereocilia change membrane potential

Columnar hair cells



Supporting cells



 Sensory epithelium of saccule, utricle and semicircular ducts



