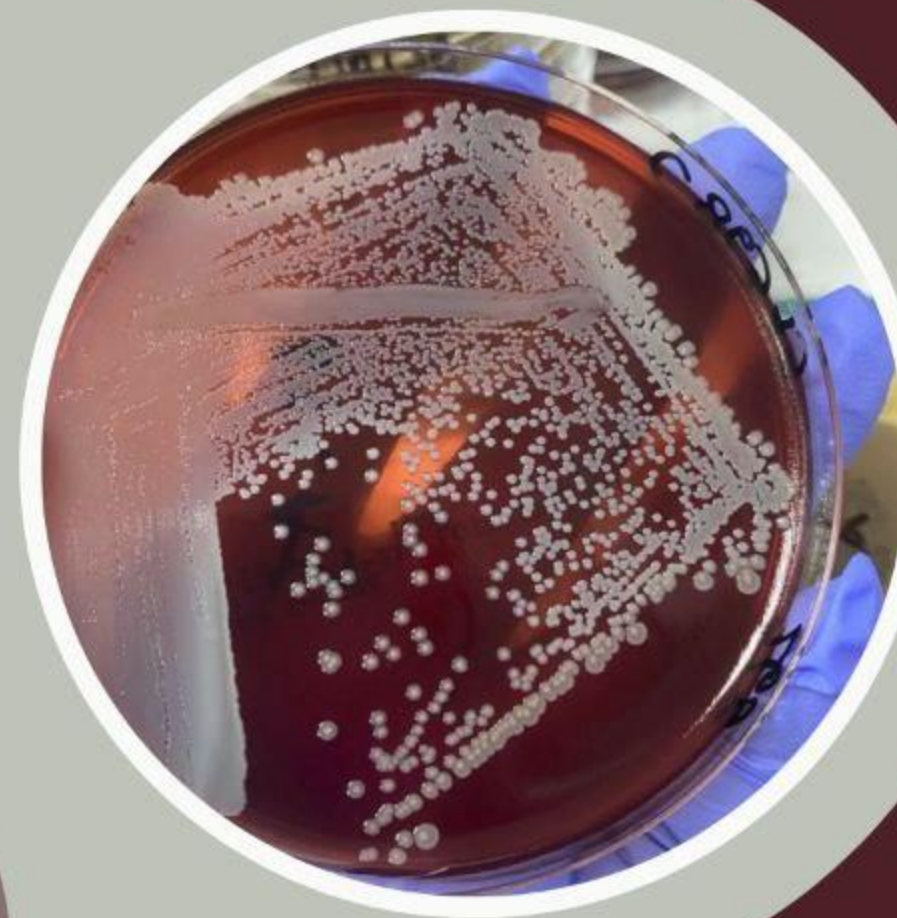



MSS

Microbiology

LEC no.5



Writer: Mohammed Al-Saidah

Corrector: Mahde Al-Sabbagh

Doctor: Malik Sallam

Cutaneous infections that manifest in vesicles, bullae, and purulent lesions

First of all, let's remember what these manifestations are:

Vesicle: <1 cm raised lesion filled with clear fluid
Bulla: >1 cm raised lesion filled with clear fluid

Usually related to herpes simplex, chickenpox, Zoster, Coxsackie, or enteroviruses

Purulent lesions: associated with pus, thus related to bacteria.

Malik Sallam, M.D., Ph.D.

School of Medicine

The University of Jordan

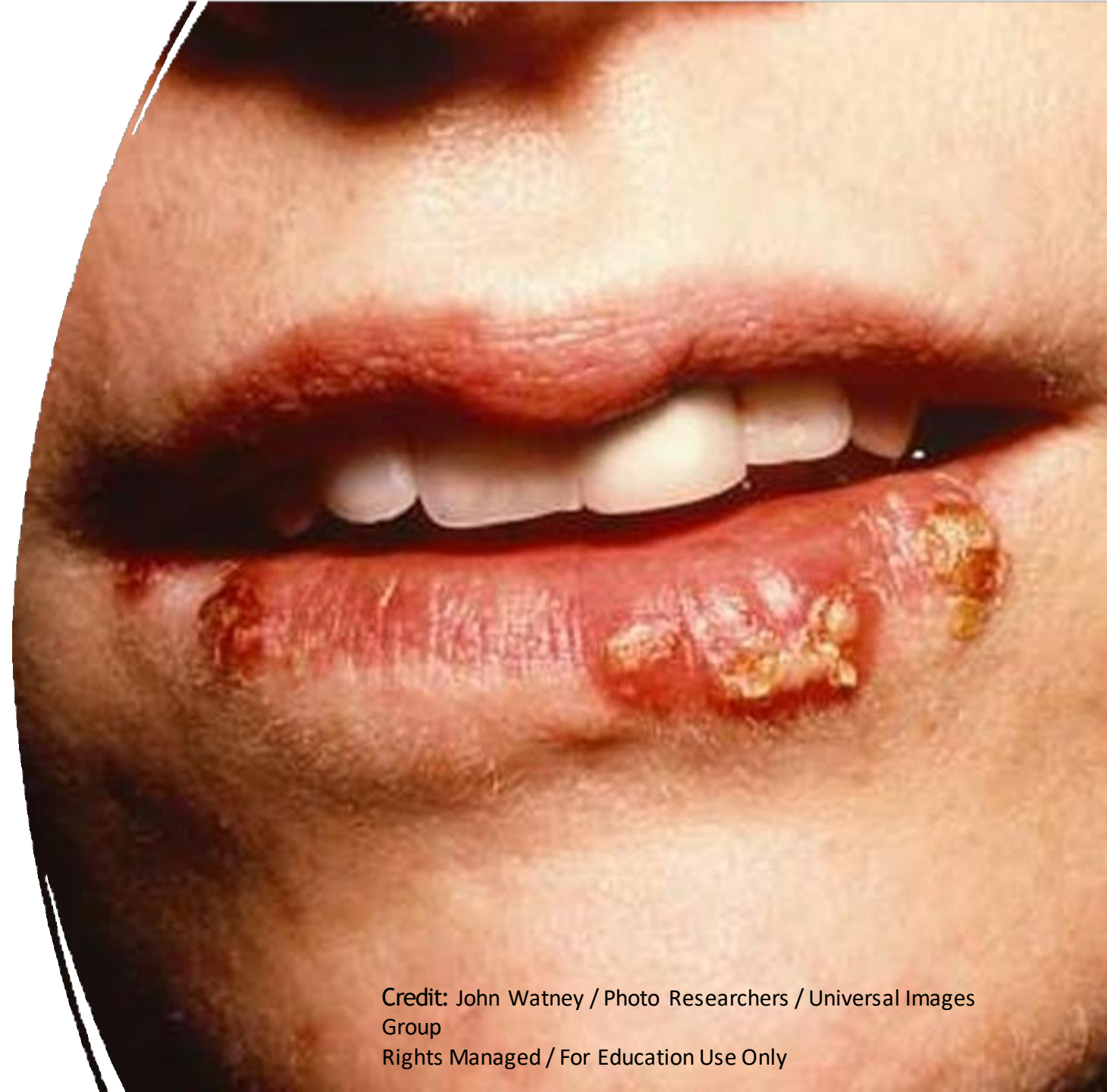Focus on the underlined topics, they are really important !

Starting with infections that manifest in vesicles:

Herpes simplex virus infections

- HSV-1 and HSV-2 cause vesicular infections, including cold sores, gingivostomatitis, vulvovaginitis, and balanitis.
- HSV-1 causes most infections above the waist. HSV-2 causes most infections below the waist.

Below the waist: Genital lesions



Credit: John Watney / Photo Researchers / Universal Images Group
Rights Managed / For Education Use Only

Herpes simplex virus - Clinical Manifestations

- Patients feel a tingling over the area just before lesions appear with mild fever.
- HSV-1 and HSV-2 usually produce grouped vesicles on an erythematous base. Lesions rupture and produce shallow ulcers with an irregular edge covered by a yellow crust.
- HSV-1 is the most common cause of cold sores and gingivostomatitis, whereas HSV-2 is the most common cause of genital herpes. HSV-1 can also cause genital herpes
- Over time, recurrences are usually less frequent and less severe.

HSV lesions don't appear directly as vesicles, They develop from:

Papules → Macules → **Vesicles (Characteristic lesion of HSV)** →
Vesicles rupture and become Ulcers

Herpes simplex virus - Epidemiology

- Primary infection with HSV-1 usually occurs in young children.
- Most adults are infected with HSV-1, while less than 10-20% of the entire population are infected with HSV-2.
- Lesions can result from a primary infection or from reactivation of latent virus in the dorsal root ganglia.
- Asymptomatic individuals infected with HSV-1 and HSV-2 can shed the virus and infect others.
- Transmission is by direct contact with saliva or through the sexual route.

Herpes simplex virus - Pathogenesis

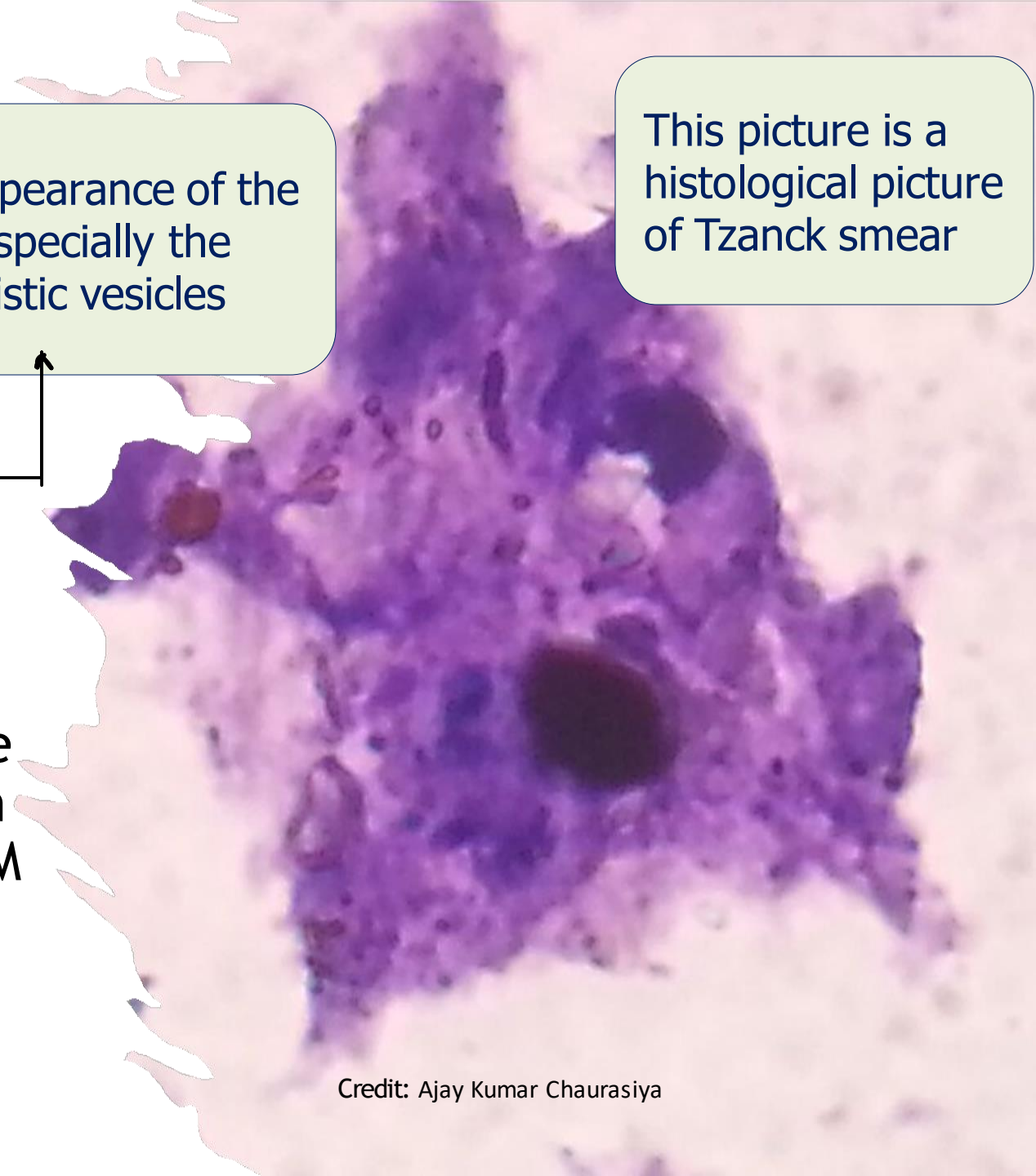
- HSV infections are the result of a cytotoxic T cell reaction.
- During primary infection, the virus invades sensory nerve endings and then migrates to the trigeminal ganglia (in HSV-1) or the sacral ganglia (in HSV-2) to establish a latent infection.
- HSV-1 and HSV-2 are lifelong infections.

Herpes simplex virus - Diagnosis

- The diagnosis is usually determined by clinical manifestations.
- **Tzanck smear** can be performed to reveal the presence of multinucleated giant cells with intranuclear inclusions.
- Serology can be used to determine if the patient has been infected with HSV with IgG indicating previous exposure and IgM indicating recent infection.
- Samples of the lesions can be obtained for PCR.

By the appearance of the lesions, especially the characteristic vesicles

This picture is a histological picture of Tzanck smear



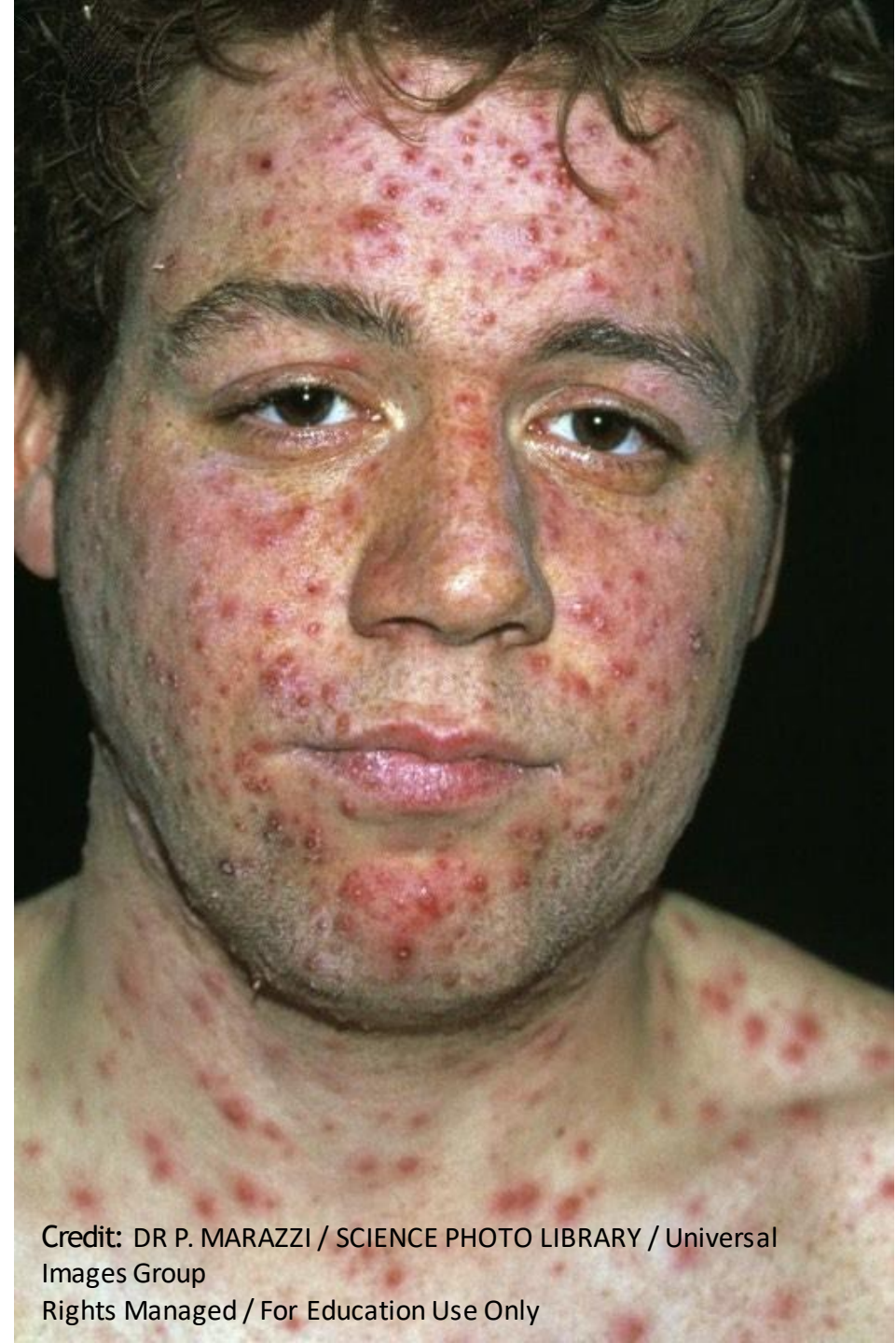
Herpes simplex virus - Treatment

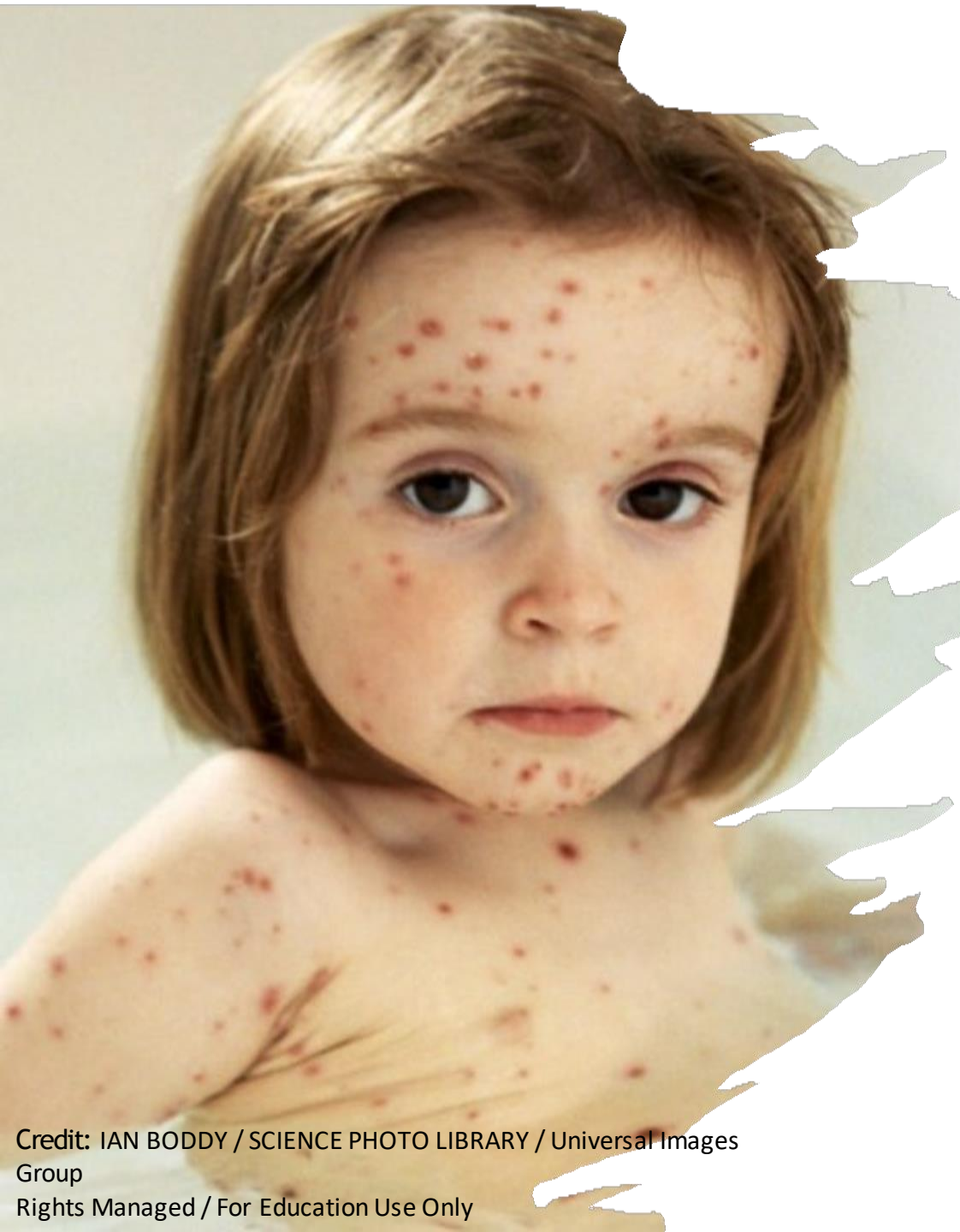- HSV lesions will usually resolve in less than 2 weeks without antiviral treatment.
- Optimum therapeutic results occur when antiviral treatment is administered during the prodromal phase.
- Antiviral agents can shorten the time to lesion healing and reduce the severity of the disease.
- **Acyclovir** can be given to treat the primary infection and to suppress recurrences of genital herpes. **Famciclovir and valacyclovir** can also be given to treat recurrent episodes of genital herpes.
- Herpes infections are lifelong and incurable.

Varicella Zoster virus (VZV) infections

Chickenpox: Primary infection
Shingles: Reactivation of latent virus

- Varicella (chickenpox) is a common childhood disease that results in widespread lesions. Zoster (shingles) is a localized recurrence (restricted to one or two dermatomes) of the VZV infection and is a common disease of older adults.
- Varicella vaccine is an attenuated live virus used in the prevention of varicella, while zoster vaccine is a recombinant subunit vaccine to prevent shingles.





Varicella - Clinical manifestations

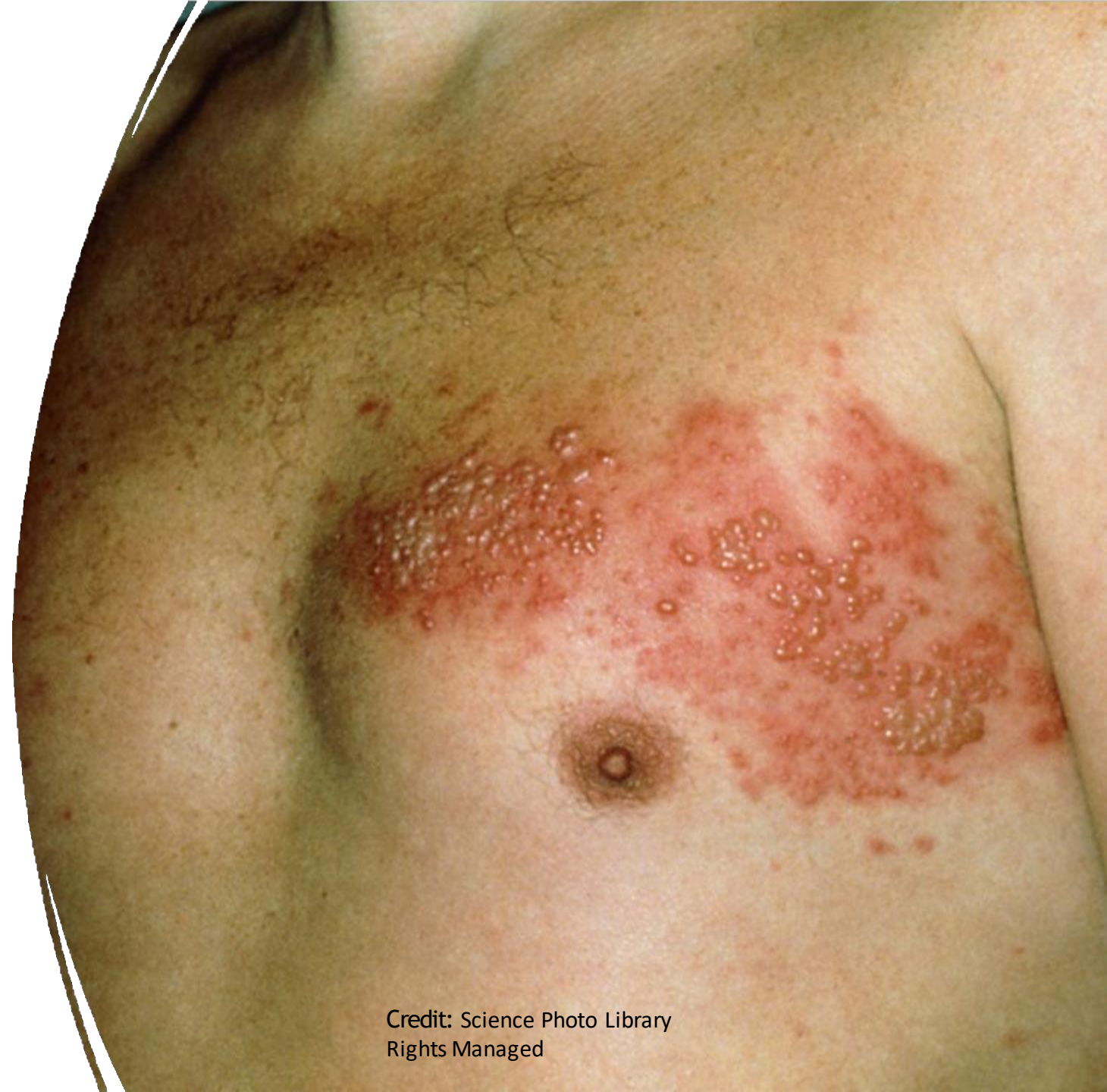- Crops of lesions progress from macules to papules, to vesicles, to pustules, to crusts with simultaneous presence of different stages of the rash.
- The vesicles are delicate and described as “**dewdrops on rose petals**”. A centripetal pattern develops where there are more lesions on the trunk than on the extremities. **Pruritus is common**.
- The disease is more severe in older children and adults, and symptoms include a high fever, headache, malaise, myalgias, and pulmonary involvement.

-Manifestations of Varicella (Papules, macules, vesicles , pustules) can appear together at the same time at any stage of the rash (not each one alone at a specific stage) which can be considered pathognomonic for chickenpox since other similar rashes like smallpox rash appear in a crop pattern (papules alone or macules alone etc..)

-Pruritis (itching) is a common symptom of Varicella, and the itching can lead to a secondary bacterial infection causing cellulitis.

Zoster - Clinical manifestations

- Groups of vesicles usually limited to one or two dermatomes.
- Vesicles become pustules that may coalesce to form larger bullae.
- Shingles are very painful, and pain persists for weeks, months, or years after the eruption clears (**postherpetic neuralgia**).



Varicella Zoster virus - Epidemiology

- Varicella in children is a self-limiting disease with mortality rate at 2 per 100,000 cases. In adults, more severe disease is seen (hospitalizations less than 20 per 1000 cases and mortality rate of 50 per 100,000 cases).
- The disease is highly contagious and is transmitted from person to person by droplet inhalation or direct contact.
- Zoster increases with age.

Varicella Zoster virus - Pathogenesis

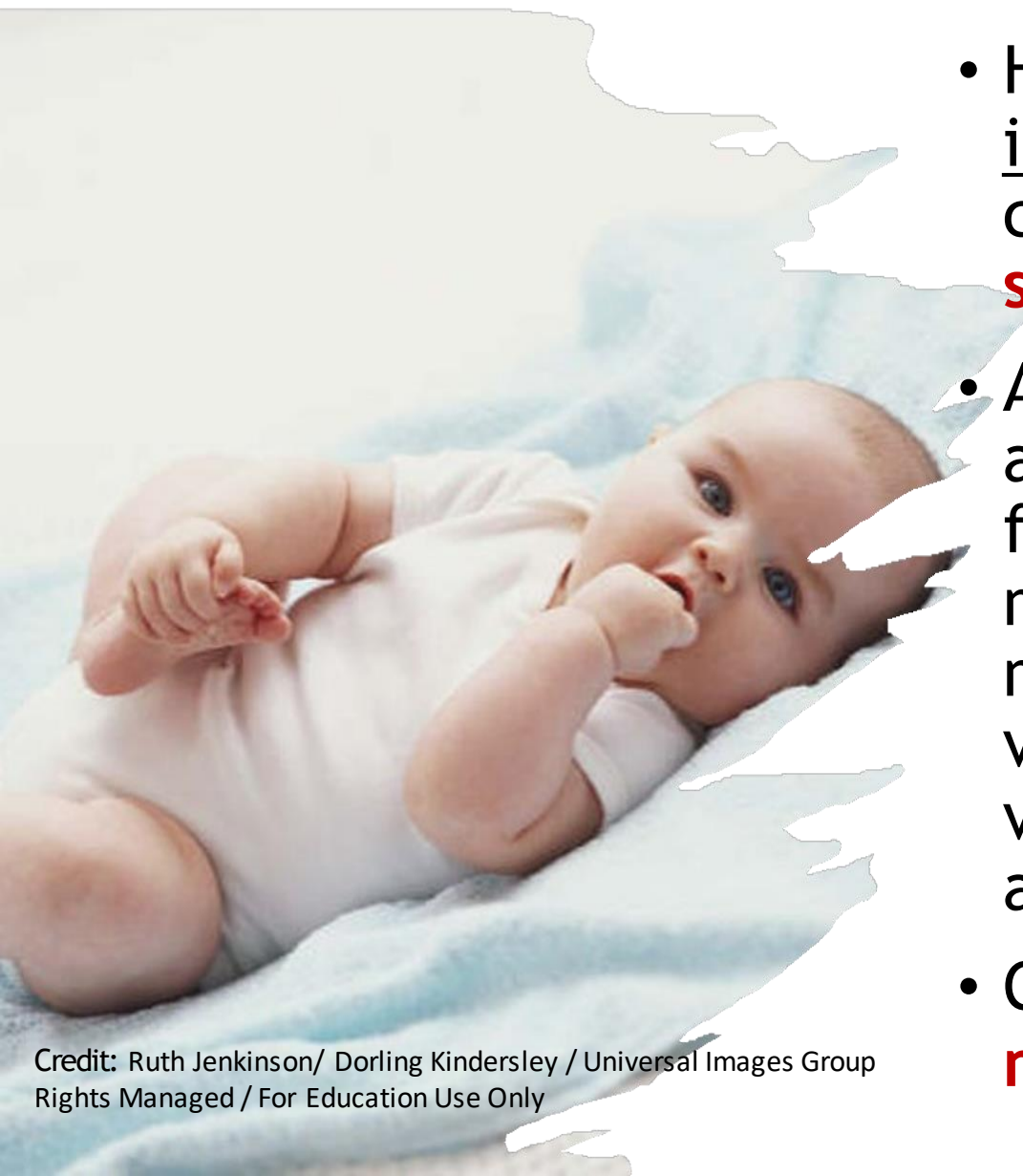- VZV multiplies in regional lymph nodes of the upper respiratory tract, followed by a primary viremia, replication in the internal organs and secondary viremia, which results in viral invasion of capillary endothelial cells and the epidermis.
- VZV infects the sensory ganglia of the cranial nerves and the spinal dorsal root ganglia with latency. Waning immunity to VZV can result in reactivation and the signs and symptoms of zoster.
- Secondary bacterial infections of skin lesions are the most common complication in children. The most common causes of these infections are *S. aureus* and *S. pyogenes*.

Varicella Zoster virus - Diagnosis, Treatment, and Prevention

- Diagnosis of varicella and zoster is based on clinical signs and symptoms. Tzanck smear and serology can be helpful.
- Varicella is mostly self-limiting managed with supportive care. Treatment with acyclovir is recommended for immunocompromised. In zoster, acyclovir, famciclovir, penciclovir, and valacyclovir can be effective.
- The Varivax vaccine is live-attenuated given to children at 12 to 15 months of age.
- Adults 50 years and older are recommended to get two doses of the shingles vaccine called Shingrix (recombinant zoster vaccine) to prevent shingles.

Shingrix Vaccine is for protection from Shingles , thus people who take this vaccine are already infected.

Hand, foot, and mouth disease (HFMD)

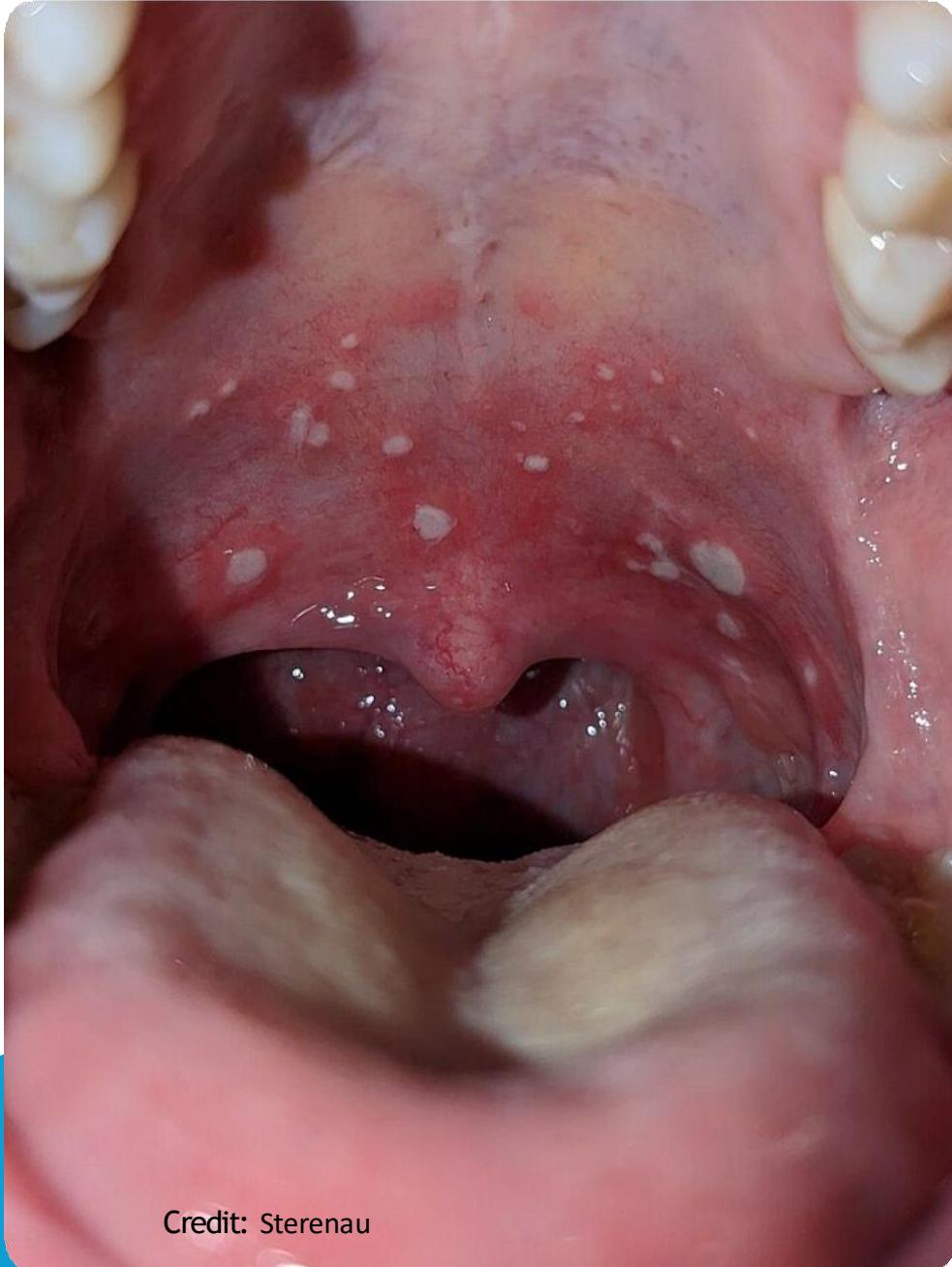


- HFMD is a viral infection that results in vesicles in the mouth, hands, and feet. The most common causes of HFMD are coxsackievirus A serotype 16 and enterovirus 71.
- A prodrome of low-grade fever, abdominal pain, and respiratory symptoms precedes vesicle formation. The mouth is affected first with multiple vesicles on the tongue, buccal mucosa, lips, and pharynx with rupture of the vesicles producing shallow ulcers. Multiple vesicles arise on the palms and soles, as well as the buttocks, lips, and buccal mucosa.
- Complications include aseptic meningitis or myocarditis.

HFMD -

Epidemiology/Pathogenesis/Diagnosis/Treatment/Prevention

- Coxsackieviruses are highly contagious and are a common cause of widespread outbreaks. Enteroviruses are transmitted from person to person by oral-oral and fecal-oral exposure.
- After ingestion, the virus replicates in the nasopharynx and ileum. The virus can spread via the bloodstream causing systemic illness.
- HFMD has a mild course. It can be asymptomatic.
- Diagnosis is based on clinical signs and symptoms or PCR.
- Supportive care is sufficient.
- Contact should be avoided in epidemic situations.



Credit: Sterenau

Herpangina

- Herpangina is an enanthem enterovirus infection that results in an acute febrile illness with small vesicular or ulcerative lesions on the posterior oropharynx.
- The most common cause of herpangina is coxsackievirus A, followed by echoviruses, and other enteroviruses.
- Other manifestations include a sudden onset of fever with sore throat, headache, and anorexia.

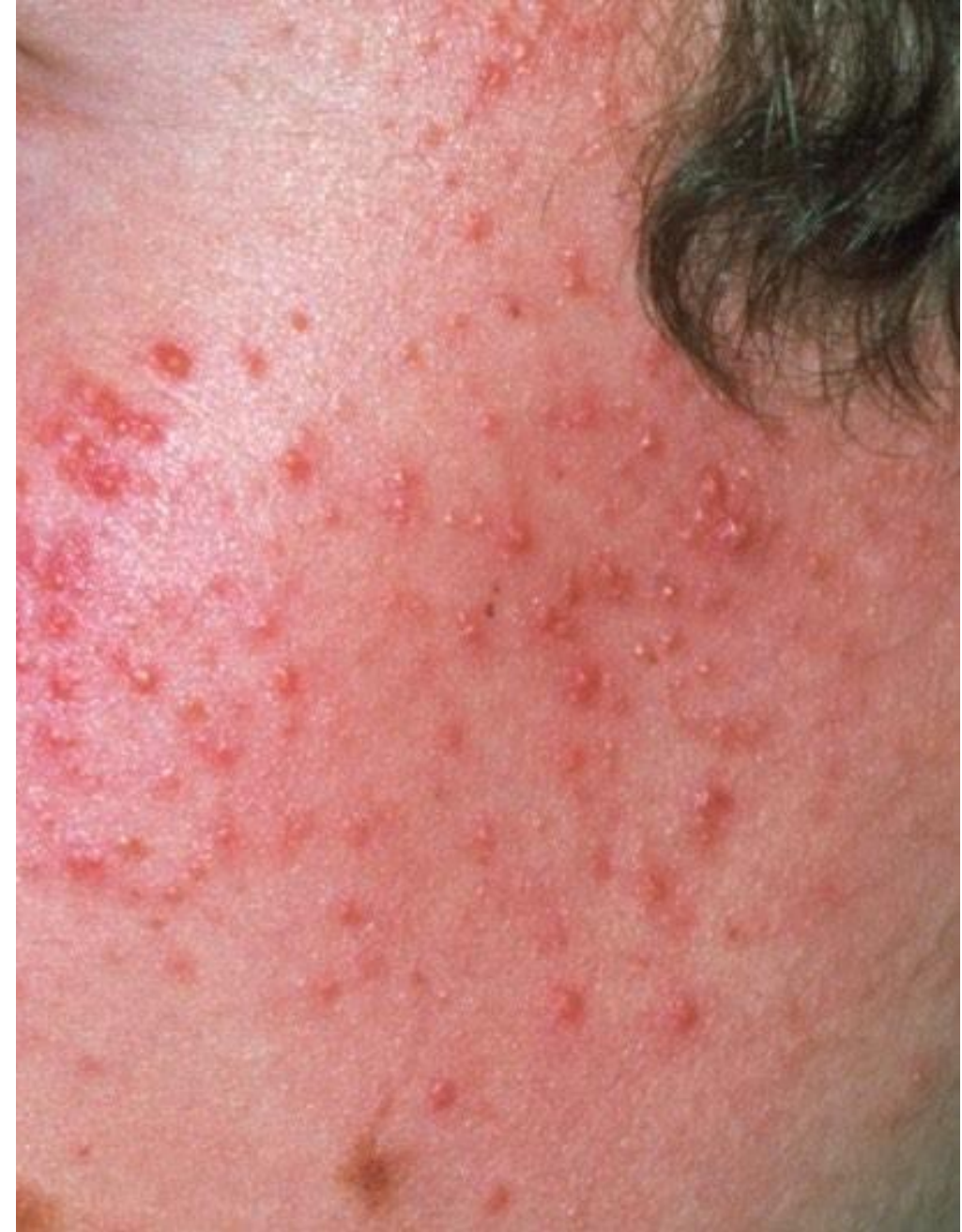Herpangina - Epidemiology, Diagnosis, and Treatment

- The lesions are self-limiting.
- Herpangina tends to occur in epidemics, most commonly in infants and children. It is more common in summer and autumn.
- These enteroviruses are transmitted from person to person by oral-oral and fecal-oral exposure.
- The diagnosis is clinical.
- Mouth rinses with topical anesthetics (lidocaine 2%) can reduce the oral pain.
- Good hygiene during epidemics can help to prevent infections.

No vaccine so far

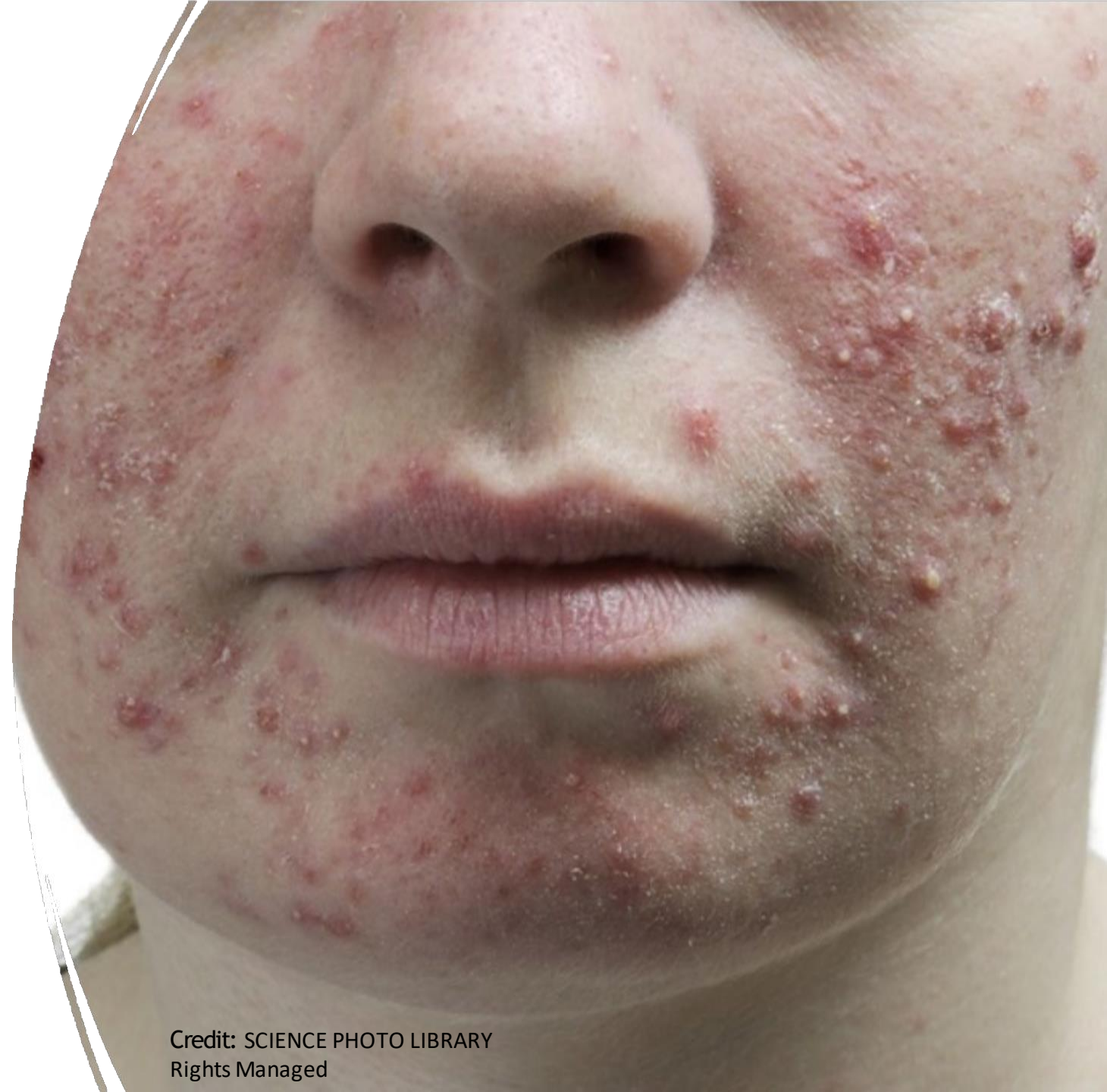Acne vulgaris

- Acne vulgaris (acne) is a disease that significantly affects most teenagers worldwide; with lifelong physical scars and emotional impact.
- *Propionibacterium acnes* is a gram-positive bacteria that is a major part of the skin microbiome. This bacterium and several other factors work together to cause acne.



Acne vulgaris - Clinical manifestations

- Several different types of acne lesions exist and include open or closed comedones, inflammatory papules, and pustules.
- Lesions are usually limited to the face, upper chest, and back.
- Scars from prior lesions may be present.



Acne vulgaris - Epidemiology

- Acne usually appears during puberty and affects 85-100% of the population.
- During adolescence, acne vulgaris is more common in boys than in girls; however, in adulthood, it is more common in women than in men.
- About 10-20% of adults may continue to experience acne.
- Acne occurs on the areas of skin with the densest population of sebaceous glands, including the face, the upper part of the chest, and the back.

Acne vulgaris - Pathogenesis, Diagnosis, and Treatment

- Four factors are responsible for the development of acne:
 1. Follicular epidermal hyperproliferation with subsequent plugging of the follicle
 2. Excess sebum
 3. The presence and activity of *P. acnes*
 4. Inflammation.
- Diagnosis of acne vulgaris is clinical. Just know that we use antibacterials
- Treatment includes the use of oral tetracycline or erythromycin, facial cleansing, and topical application of benzoyl peroxide, retinoic acid, or salicylic acid. Topical oils and excessive skin friction and facial scrubbing should be avoided.

Folliculitis, furuncles, and carbuncles

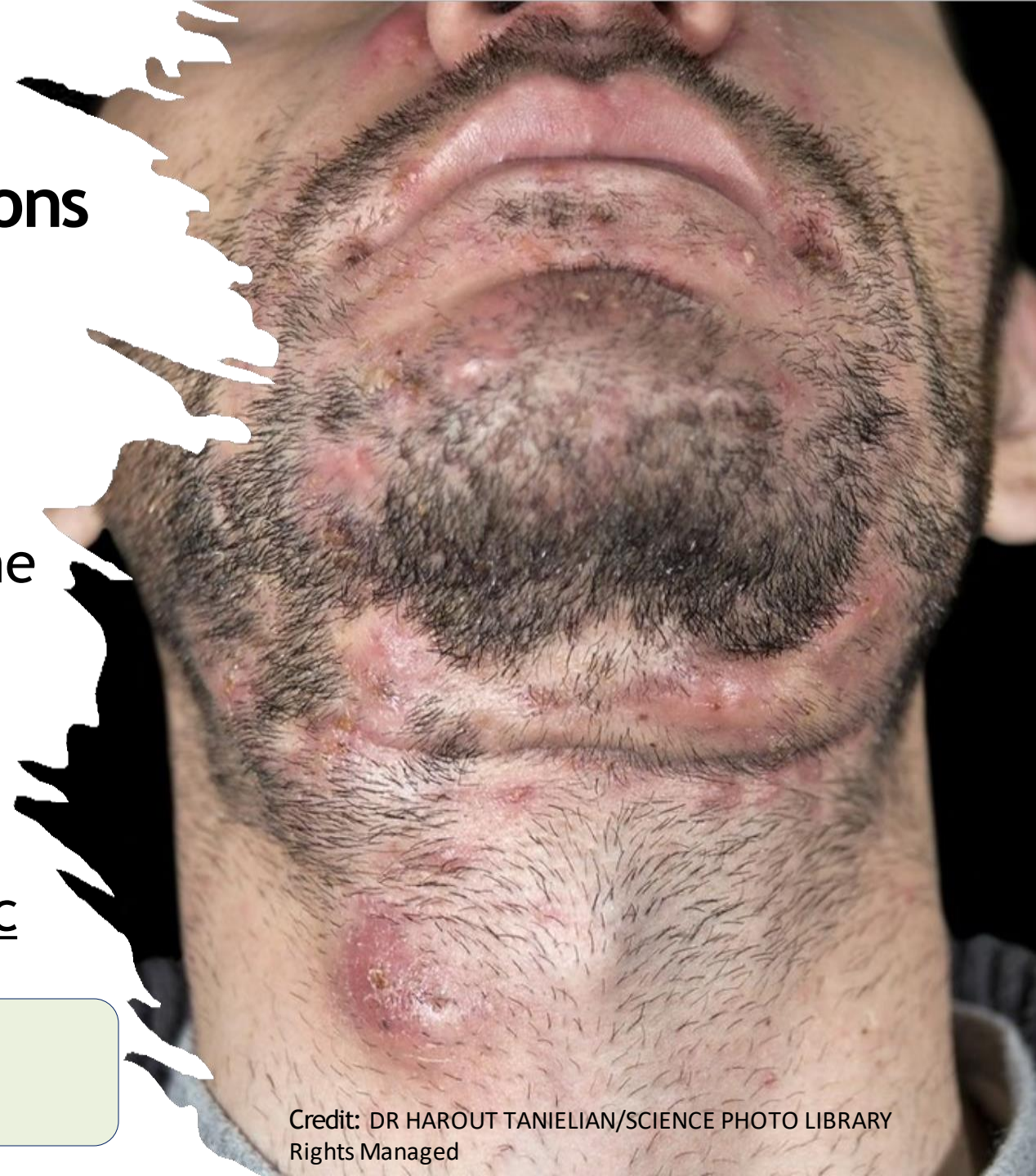- Folliculitis is a purulent bacterial infection of the hair follicle. Furuncles (boils) are deeper purulent lesions of hair follicles involving the skin and subcutaneous tissue. Carbuncles occur when several furuncles are connected subcutaneously by sinus tracts.
- *S. aureus* is the most common cause folliculitis, furuncles, and carbuncles.
- *Pseudomonas aeruginosa* is a common cause of folliculitis associated with a hot tub (hot-tub folliculitis).
- Less common causes of these lesions are *Candida*, anaerobic bacteria, and **diphtheroids**.

The pus formation in the 3 manifestations are due to hair clogging & inflammation

Folliculitis, furuncles, and carbuncles - Clinical manifestations

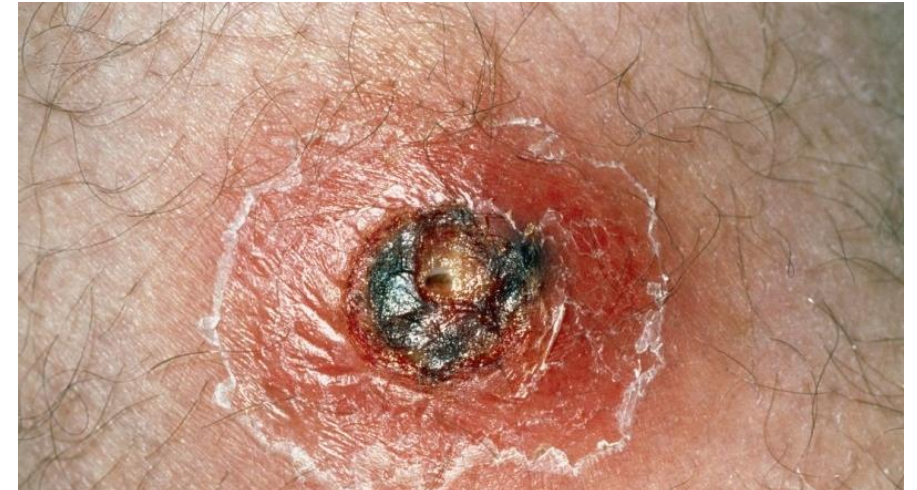- Folliculitis is a superficial pustule located at the orifice of the hair follicle.
- Lesions can be single or multiple and may occur at any hair-bearing site on the body.
- Lesions on the scalp may scar and cause permanent hair loss.
- Sycosis barbae is a deep folliculitis of bearded skin and is frequently a chronic condition.

Sycosis barbae is a special condition of folliculitis

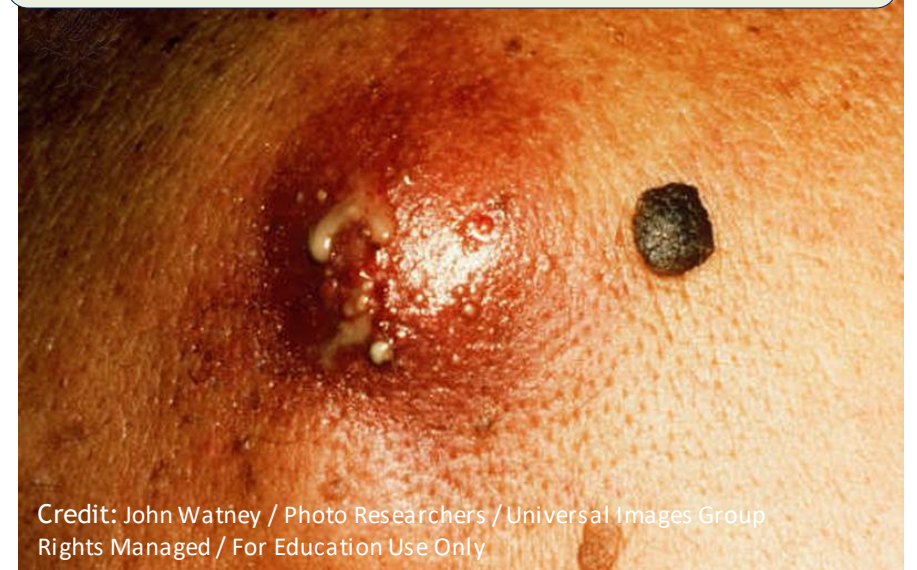

Folliculitis, furuncles, and carbuncles - Clinical Manifestations

- Furunculosis is a focal purulent inflammation of the skin and subcutaneous tissue.
- Carbunculosis is a deeper infection producing multiple adjacent draining sinuses. Lesions begin as folliculitis and may be single (furuncle) or multiple and contiguous (carbuncle).



Notice the excessive pus formation!



Credit: John Watney / Photo Researchers / Universal Images Group
Rights Managed / For Education Use Only

Folliculitis, furuncles, and carbuncles

- The overlying skin becomes very tender. The purulent lesions often rupture spontaneously and drain a purulent matter, bringing immediate relief of pain. Lesions can occur anywhere on hair-bearing skin and especially on buttocks, thighs, and abdomen. Carbuncles are usually found in the thick fibrous inelastic skin of the neck and upper back.
- Predisposed individuals are usually obese, diabetic, or do not practice good hygiene.

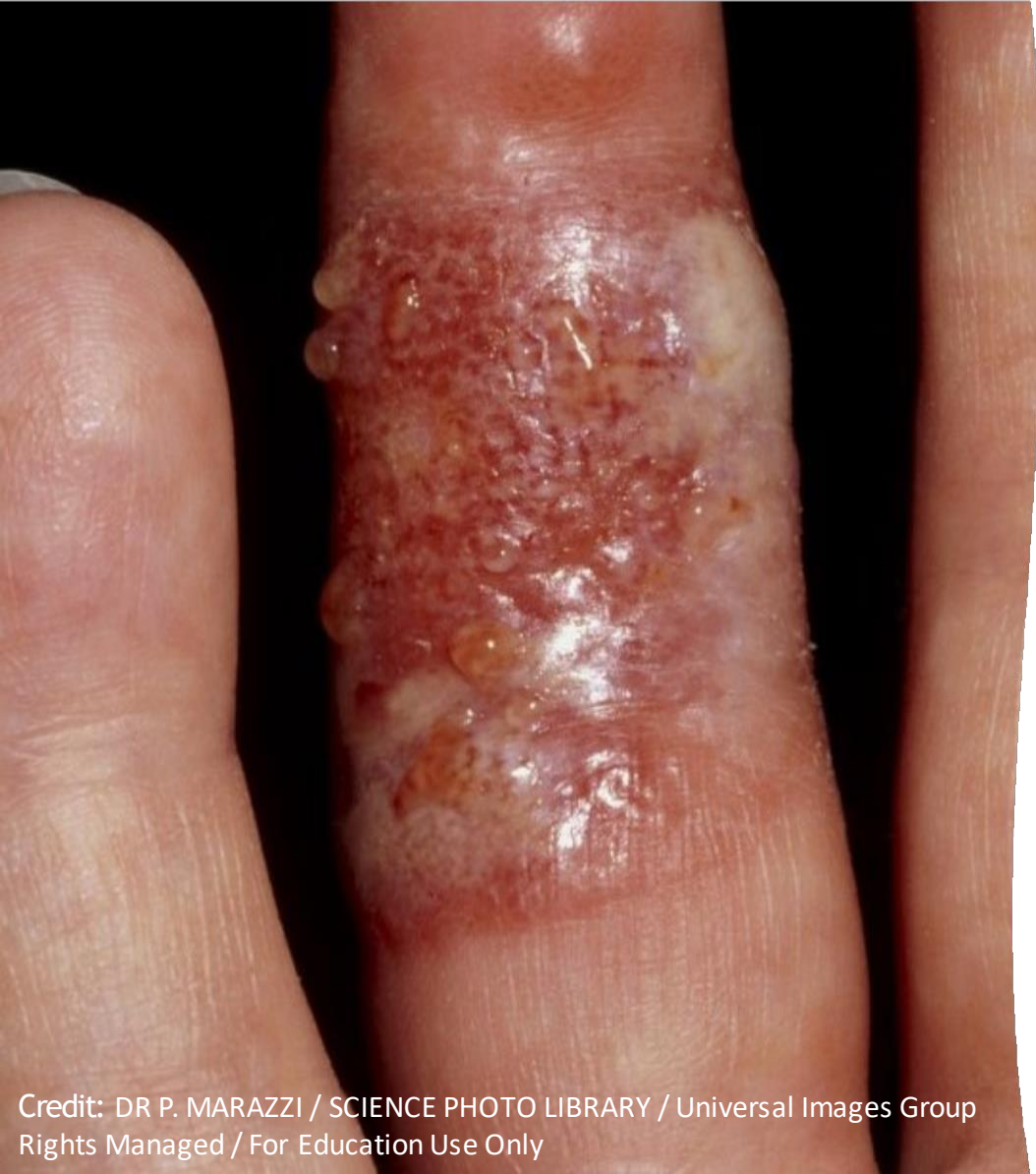Most important predisposition is poor hygiene

Folliculitis, furuncles, and carbuncles - Diagnosis, Treatment, and Prevention

- Diagnosis is usually determined based on clinical appearance of the skin lesions.
- Definitive diagnosis can be obtained by culturing the bacteria obtained from the purulent discharge or the erythematous base of the lesion.
- Treatment of larger lesions may require warm wet compresses and incision and drainage.
- Systemic antibiotics may be required in severe cases.
- Lesions can be prevented by improving hygienic conditions.

Vesicular lesion

Herpetic whitlow



- Herpetic whitlow is a viral infection of the tissue around the fingernails.
- HSV-1 causes 60% of the infections, and HSV-2 causes the remaining 40%.
- Grouped vesicles that coalesce often can be seen on the fingers near the nails, usually on the dominant hand.
- Lesions can spread and become pustular. Symptoms include intense itching or pain at the lesion site, headache or malaise, and regional lymphadenopathy.

Herpetic whitlow - Epidemiology/Pathogenesis

- HSV is introduced by direct contact of skin.
- At-risk persons include HCWs (e.g., nurses, dentists, and physicians) who may have contact with oral or genital lesions on patients and children with herpetic gingivostomatitis who suck their thumbs.
- In the general adult population, herpetic whitlow is most often due to autoinoculation from genital herpes and is most frequently secondary to infection with HSV-2.
- The virus enters via a break in the skin and causes edema, erythema, and local tenderness preceding the development of vesicular-pustular lesions.

Herpetic whitlow appears mostly on fingers

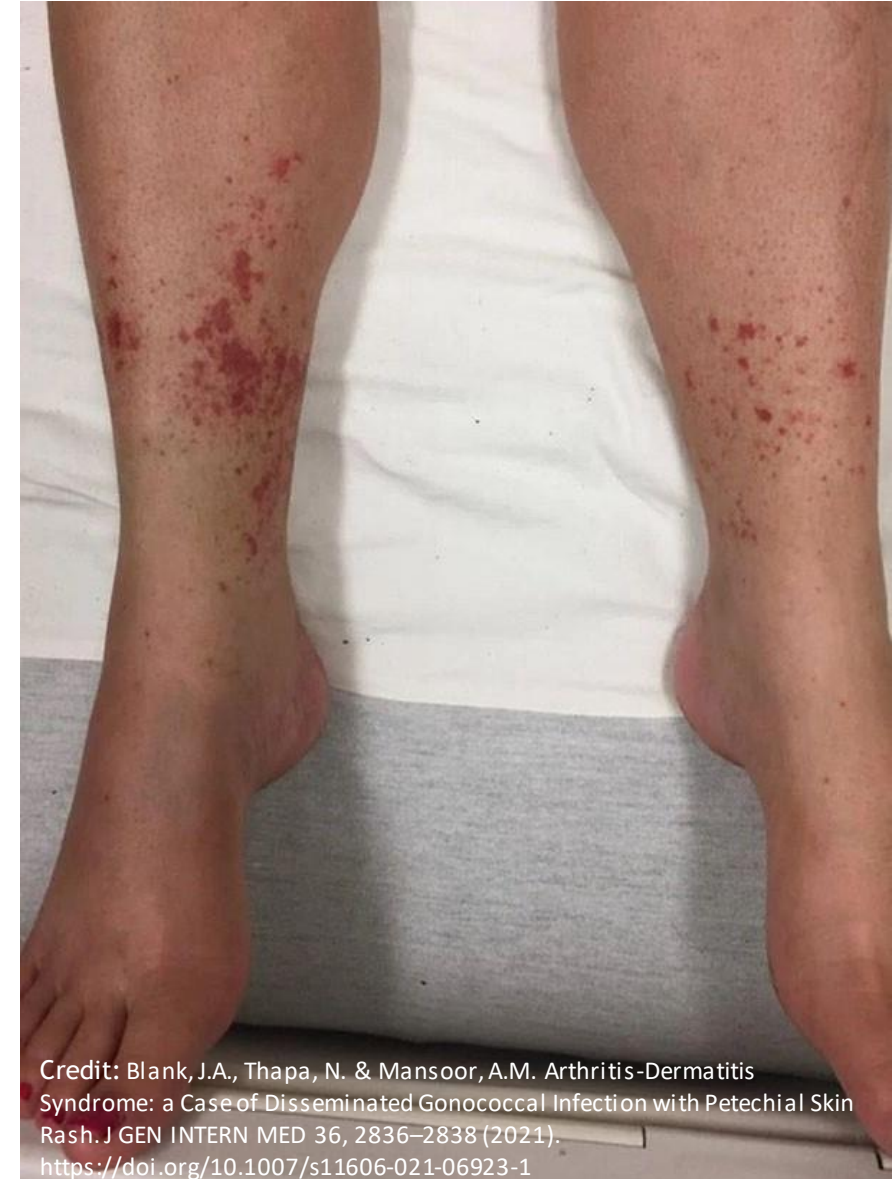Herpetic whitlow - Diagnosis

- Diagnosis of herpetic whitlow is based on clinical presentation.
- Definitive diagnostic testing includes the Tzanck test, viral cultures, or PCR.
- Treatment is usually symptomatic and includes analgesics.
- Topical acyclovir reduces the severity and duration of the lesions following a primary infection. Oral acyclovir given during the prodromal period may prevent recurrences. Gloves should be worn to avoid infections.

pustules,
vesicles, or
bullae

Gonococemia - Skin manifestations

- The skin lesions in gonococemia begin as tiny red papules or petechiae, which may evolve into purpuric pustules, vesicles, or bullae
- Widespread pustules on an erythematous or hemorrhagic base are characteristic.
- Lesions are scattered over distal extremities.
- Gonococemia is a disseminated STI.
- Treatment involves intravenous antibiotic therapy with ceftriaxone, cefotaxime, or ceftizoxime. Intimate contact with infected individuals should be avoided.



Credit: Blank, J.A., Thapa, N. & Mansoor, A.M. Arthritis-Dermatitis Syndrome: a Case of Disseminated Gonococcal Infection with Petechial Skin Rash. J GEN INTERN MED 36, 2836–2838 (2021).
<https://doi.org/10.1007/s11606-021-06923-1>

The presence of this type of lesion (tiny papule that evolve into pustules, vesicles, or bullae) is an indication of a disseminated gonococcal infection which is called Gonococemia.

That's it, good luck :)