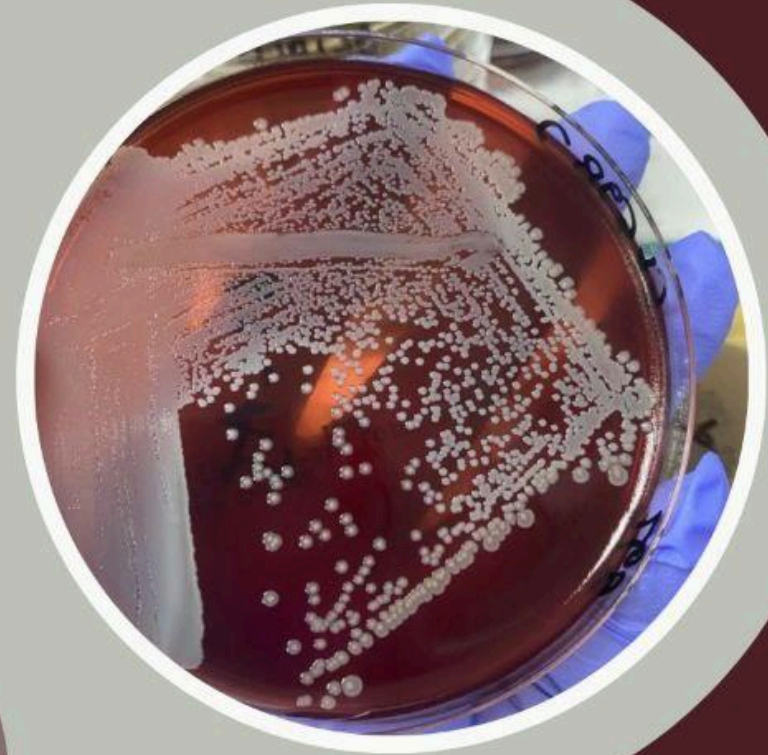



# MSS

## Microbiology

LEC no.6



**Writer: Mahmoud Jaradat**

**Corrector: Hala Mousa**

**Doctor: Malik Sallam**

# Cutaneous infections that manifest in petechial, hemorrhagic, ulcerative, and necrotic lesions

Malik Sallam, M.D., Ph.D.

School of Medicine

The University of Jordan

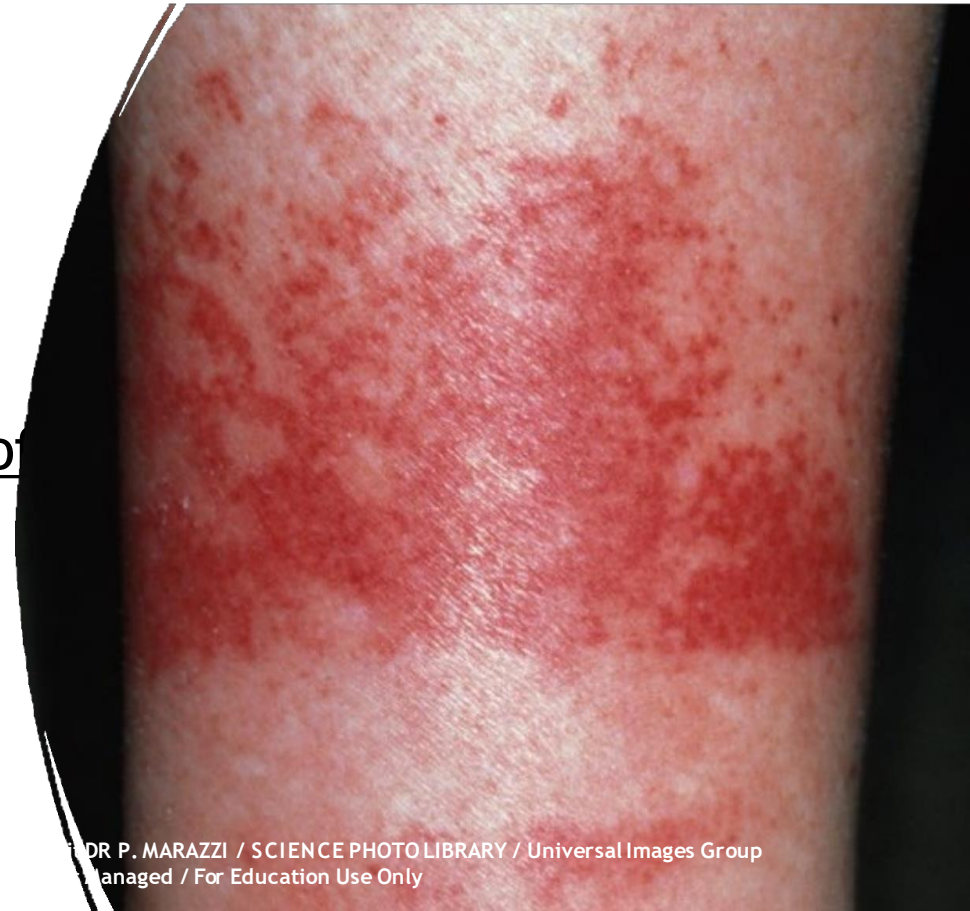Petechiae are very small lesions due to bleeding into the skin.

Purpura (similar lesions) but larger

Ecchymosis are dark spots that appear after hitting your hands for example due to bleeding, they become blue then turn into yellow.

# Overview

- Petechiae are flat lesions caused by intradermal or submucosal hemorrhage. Purpura are slightly larger while ecchymosis are larger > 1 cm.
- Ulcers of the skin are a localized excavation of the skin surface and are produced by sloughing of inflammatory necrotic tissue.
- Necrotic lesions result when cells in the skin die and are destroyed by the progressive degradative action of various enzymes. (By inflammation or microbial organisms in the case of infections)



# Diseases that cause petechial and hemorrhagic lesions

- Endocarditis
- Meningococccemia
- Gonococccemia
- Rocky Mountain spotted fever

Note that infections can manifest in many different types.

# Diseases that cause ulcerative and necrotic lesions

- **Impetigo** Impetigo (القوباء) it has ulcers
- **Ecthyma gangrenosum** Deeper ulcers
- **Gas gangrene** Necrotic lesions
- **Primary syphilis** Hard ulcers, indurated ulcers
- **Herpes simplex skin lesion** Vesicles then open to become ulcers
- **Burn or wound infections**

# Conditions and causes of infectious endocarditis

- Native heart valve: Viridans Streptococci, Staphylococcus aureus, Gram-negative bacilli, and the HACEK group.
- Prosthetic heart valve: Staphylococcus aureus, Coagulase negative Staphylococci, Viridans Streptococci, Gram-negative aerobic bacilli, fungi.
- Drug users: Staphylococcus aureus, Gram-negative bacilli Pseudomonas aeruginosa (the most common gram-negative bacillus causing IE), Viridans Streptococci, Enterococcus, Candida albicans.

It depends on the infecting bone organism that varies depending on the heart valves of endocarditis's patients.

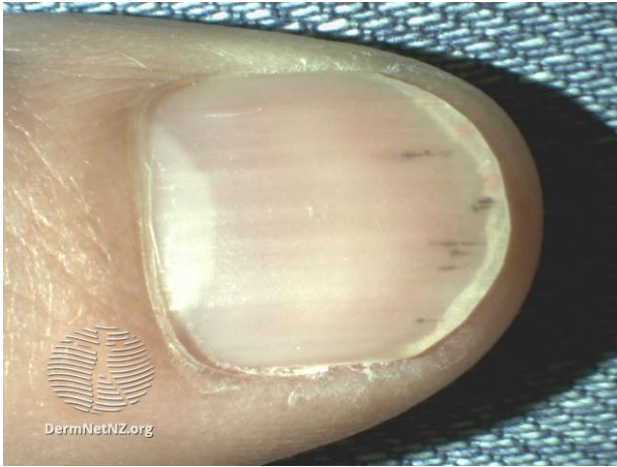
# Dermatologic manifestations of infective endocarditis

- Endocarditis is an infection of the heart valves characterized by vegetations that develop on the surface of the valves. The septic emboli are transported by the bloodstream and lodge in small vessels and cause **petechial skin lesions associated with the disease**.

IMPORTANT! What are the types of skin lesions associated with endocarditis ??

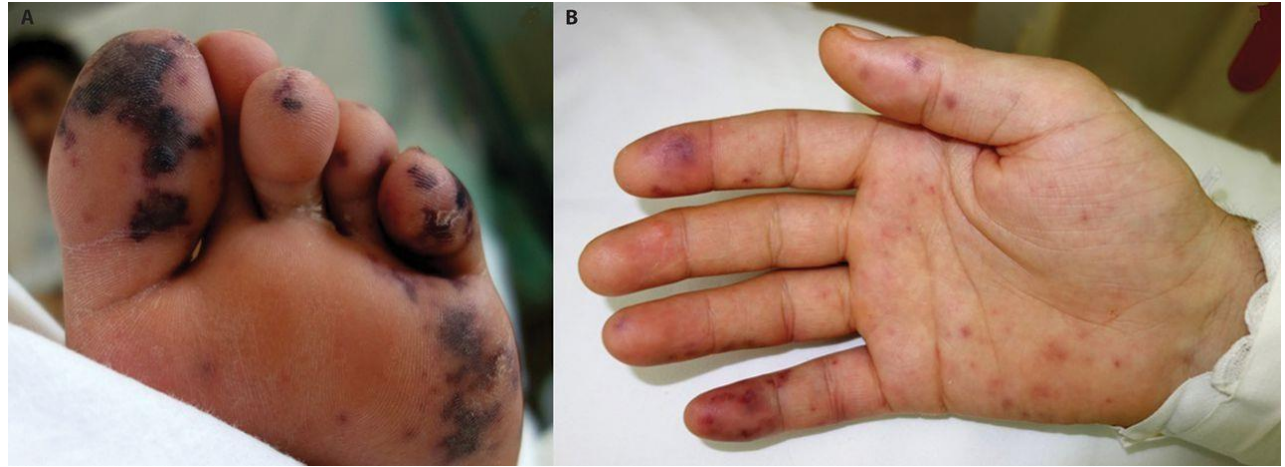- **Petechiae, splinter hemorrhages, Janeway lesions, and Osler nodes can occur.**
- **Splinter hemorrhages** are linear red-to-brown streaks that appear under the fingernails and toenails.
- **Janeway lesions** are small erythematous painless macules, plaques, or palpable purpura, and are usually observed on the palms and soles.
- **Osler nodes** are erythematous tender nodules 2-15 mm in diameter and are usually located on the pads of fingers and toes.

# Dermatologic manifestations of infective endocarditis



Credit DermNet: <https://dermnetnz.org/topics/splinter-haemorrhage>

Splinter hemorrhage



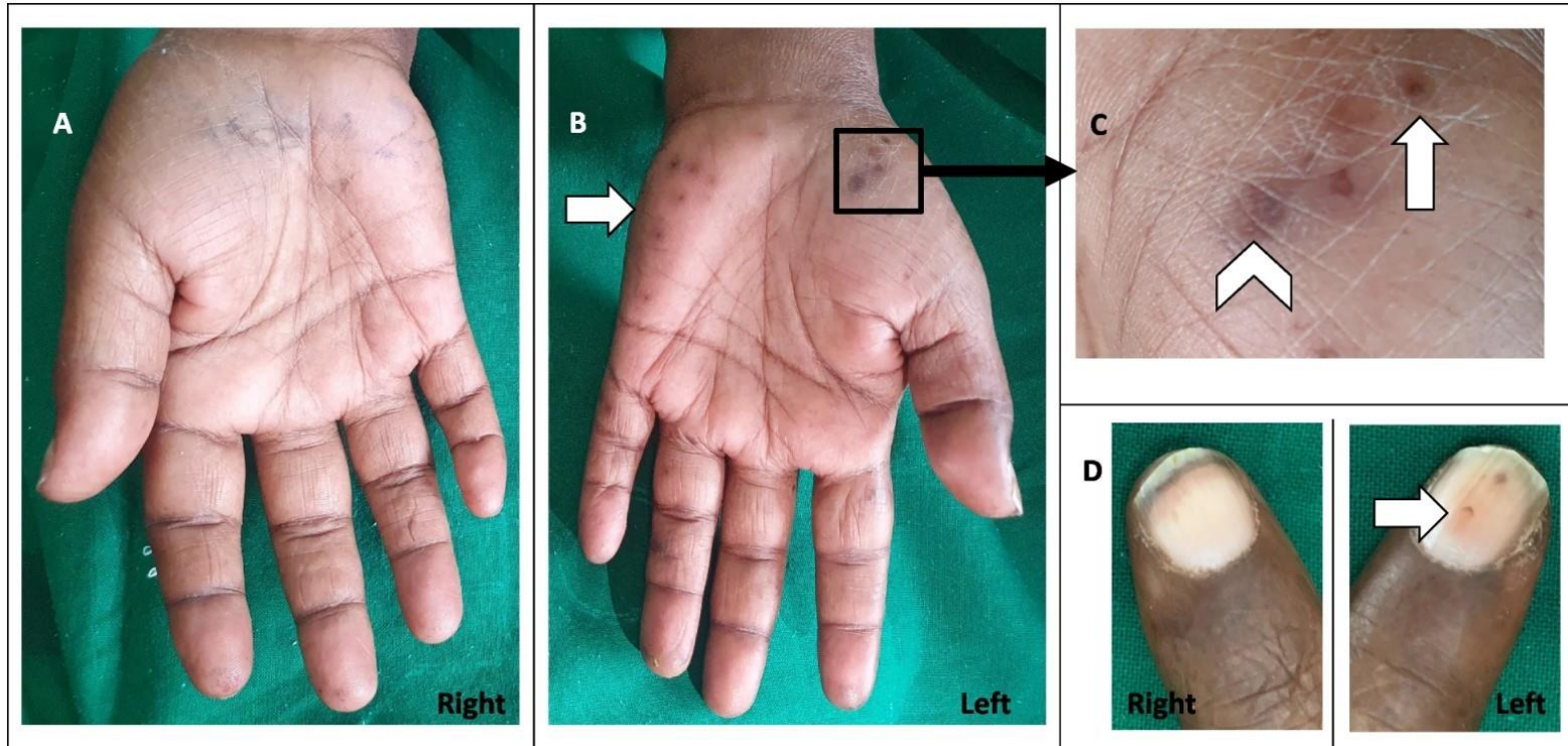
Credit Andrea Misin, Stefano Di Bella, Luigi Priolo and Roberto Luzzati , DOI: <https://doi.org/10.7861/clinmedicine.17-4-373> Clin Med August 2017

Janeway lesions on palms and soles



# Dermatologic manifestations of infective endocarditis

## Osler nodes



Right hand (A) is normal while the left hand (B) has Osler's nodes and Janeway lesions over the thenar and hypothenar eminences (arrow). The lesions over the thenar eminence are magnified in C which shows Osler's nodes (arrow) and Janeway lesions (arrowhead). Splinter haemorrhages of the left nailbed (arrow) and the normal nails of the right hand are shown in D

Credit: Ruwanpathirana, P., Athukorala, H., Weeratunga, P. et al. Unilateral Osler nodes, Janeway lesions and splinter haemorrhages associated with surgical arterio-venous fistula infection: a case report. *BMC Infect Dis* 23, 451 (2023). <https://doi.org/10.1186/s12879-023-08439-x>

# Pathogenesis

- Damage to the heart valve can result in the accumulation of platelets and fibrin. This sterile lesion serves as a site for bacteria to attach to in the bloodstream. The microbial infection begins on the surface of the heart valves and forms vegetations containing bacteria, white blood cells, platelets, and fibrin.
- These vegetations can dislodge from the valves and settle in blood vessels, lowering perfusion of the tissues and resulting in skin lesions (e.g., petechiae, splinter hemorrhages, Janeway lesions). Immune complexes also occur, resulting in various immunologic phenomena (e.g., Osler nodes).

## Diagnosis, Treatment, and Prevention

- Key signs include low-grade fever, fatigue, valvular insufficiency, a change in a pre-existing murmur or a new cardiac valvular murmur, tachycardia, petechiae, Osler nodes, splinter hemorrhages, and hemorrhagic retinal lesions (Roth spots are round or oval lesions with small white centers).
- Treatment of endocarditis includes administration of antibiotics
- In patients with prior heart valve damage, antibiotic prophylaxis prior to invasive dental procedures and genitourinary and gastrointestinal surgery is useful in preventing endocarditis.

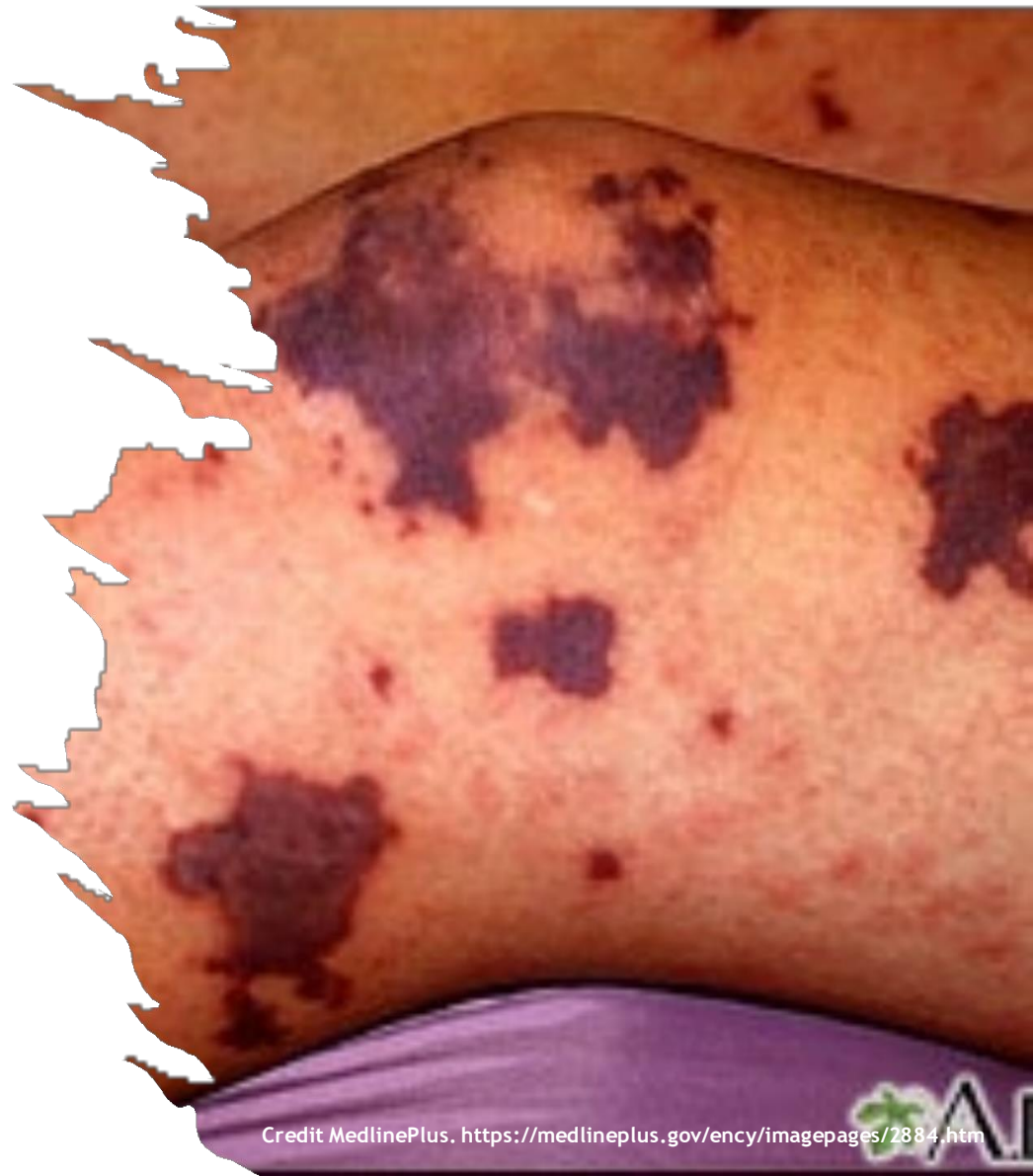When there are signs of meningitis associated with skin lesions then we suspect Meningococemia.

## Meningococemia

- Meningococemia is a life-threatening infection of the bloodstream that causes inflammation and damage to the walls of the blood vessels (vasculitis).
- Damage to the blood vessels can cause hemorrhage into the skin and is a sign of this bacteremia.
- The cause of meningococemia is *Neisseria meningitidis*, a gram-negative diplococcus.
- Capsular serogroups of the organism have been identified with five serogroups (A, B, C, Y, W-135) cause most cases of meningococemia.

# Meningococemia - Skin Manifestations

- Acute meningococemia produces erythematous macules, petechiae, purpura, and ecchymoses, with lesions commonly beginning on the trunk and legs.
- A confluence of petechial and purpuric lesions results in hemorrhagic patches, often with central necrosis.



Will be discussed in the third year.

# Meningococemia - Pathogenesis

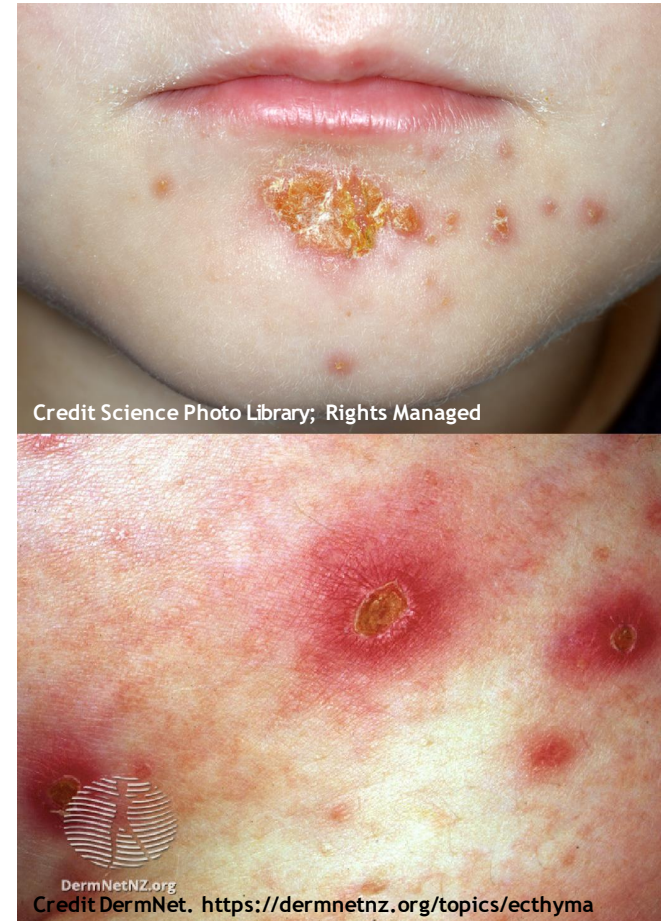- *N. meningitidis* uses pili to attach to mucosal epithelial cells.
- Once in the bloodstream, *N. meningitidis* damages the small blood vessels by direct invasion of endothelial cells and indirect damage following the release of endotoxin
- The capsule on the surface of the bacteria prevents white blood cells from phagocytizing and killing the organisms.
- Meningococcal endotoxin causes the release of proinflammatory cytokines, which can result in severe hypotension, reduced cardiac output, and increased endothelial permeability

# Meningococemia - Diagnosis, Treatment, and Prevention

- Diagnosis of meningococemia requires blood cultures.
- Gram stains revealing the gram-negative diplococci in samples from the skin lesions are usually diagnostic.
- If the patient is diagnosed with meningitis, cultures and Gram stains of the cerebrospinal fluid are also diagnostic.
- Treatment of meningococemia requires administration of antibiotics (e.g., penicillin G) and supportive care.
- A tetravalent (A, C, Y, W-135) meningococcal conjugate vaccine is available.

# Impetigo and Ecthyma

- **Non-bullous impetigo** is a superficial infection that causes shallow erosions in the skin that are covered by a **honey-colored crust**.
- **Bullous impetigo** occurs when the individual is infected with an epidermolytic toxin-producing strain of *Staphylococcus aureus*.
- **Ecthyma infections** extend deeper into the dermis, and when the crust is removed, a punched-out ulcer with a raised surrounding margin can be seen.





# Impetigo and Ecthyma - Skin Manifestations

- Non-bullous impetigo begins as small vesicles that rupture quickly to form purulent erosions covered with honey-colored, adherent thick crusts.
- Lesions usually occur on the face or extremities.
- Lesions are superficial and limited to the epidermis and are usually painless but may itch.
- Regional lymphadenopathy is common.

# Impetigo and Ecthyma - Skin Manifestations

- Bullous impetigo presents with large superficial fragile bullae on the trunk and the extremities.
- Only ruptured bullae usually are seen at the time of presentation.
- Other manifestations frequently seen in patients with bullous impetigo are fever, diarrhea, and generalized weakness. These manifestations usually are not seen in patients with non-bullous impetigo.
- Regional lymphadenopathy is uncommon in this form of impetigo.

# Impetigo and Ecthyma - Skin Manifestations

- Ecthyma is an ulcerative form of impetigo that extends deeper into the dermis. It begins as a vesicle or pustule overlying an inflamed area of skin that deepens into a dermal ulceration with overlying crust.
- The crust is gray-yellow and is thicker and harder than the crust of impetigo.
- When the crust is removed, a shallow punched-out ulcer with a raised surrounding margin can be seen. Lesions are painful; the patient also may develop regional lymphadenopathy.
- Secondary lymphangitis and cellulitis can occur.
- Ecthyma heals slowly and, unlike impetigo, usually results in scarring.

# Impetigo and Ecthyma - Epidemiology

- *S. aureus* colonizes the anterior nares of 30% of the general population. *S. pyogenes* colonizes the oropharynx of 3-10% of the general population.
- Person-to-person spread of these bacterial pathogens is more likely in populations living in crowded conditions and with poor hygiene.
- Ecthyma usually occurs on the lower extremities of diabetic patients and neglected elderly patients.
- Preexisting tissue damage (e.g., by insect bites or small trauma) and immunocompromised states predispose patients to the development of ecthyma.
- Impetigo and ecthyma are highly communicable to other sites (autoinoculation) or other persons (contagious).

# Impetigo and Ecthyma - Diagnosis

- Diagnosis of impetigo and ecthyma is based on the appearance of the lesions.
- Samples from the lesions can be Gram stained and cultured.
- A rising anti-DNase B titer indicates *S. pyogenes* involvement and raises concern about acute glomerulonephritis.

Mupirocin can be used for the eradication of MRSA (methicillin resistant *Staph aureus* )

## Impetigo and Ecthyma - Treatment and Prevention

- Impetigo can be treated by cleaning the wound with gentle abrasion.
- Topical treatment with mupirocin is adequate for single lesions or small areas of involvement.
- Systemic antibiotics (depending on the causative organism, *S.aureus* or *S.pyogens*) (e.g., cephalexin, erythromycin, dicloxacillin) are indicated for extensive involvement. Treatment of ecthyma by applying antibiotic ointment daily.
- To prevent spread of impetigo and ecthyma, avoid contact with the lesions. Good hygiene is important. Frequently changing bed linens, towels, and clothing can help in maintaining cleanliness.

Usually in neonates

# Staphylococcal Scalded Skin Syndrome

- A disease characterized by denudation of the skin caused by exfoliative exotoxin producing strains of the *Staphylococcus species*.
- It usually presents 48 hours after birth and is rare in children older than six years.
- The exfoliative toxins target the desmoglein 1 complex in the zona granulosa of the epidermis, resulting in **skin exfoliation**.
- SSS starts on the face and flexures (groin, axillae, neck) with erythema and fissures, followed by blisters and bullae.
- Antibiotics covering *Staphylococci* should be administered early

In Secondary syphilis, macules and condylomata lata (in the form of papules) appear.

## Primary Syphilis

- Syphilis is an STI that manifests in three stages as primary, secondary, and tertiary syphilis. The primary stage of syphilis results in an **indurated chancre**. Painless, Highly contagious
- A painless papule progresses to a singular painless ulcer (chancre), which has a raised and indurated border.
- Chancres can occur on the penis, anus, and rectum in men, and on the vulva, cervix, and perineum in women. Chancres may also occur on the lips or the oropharyngeal or anogenital mucous membranes, and rarely on the hands or other parts of the body. Other manifestations include regional lymphadenopathy 3-4 days after the chancre appears.



# Primary Syphilis - Pathogenesis

- *T. pallidum* enters through the mucous membranes or skin.
- After 3-4 weeks, a red papule erodes to form a painless ulcer (chancre) with an indurated base, which, when abraded, exudes a serous fluid containing numerous spirochetes.
- In all stages of disease, perivascular infiltration of lymphocytes, plasma cells, and, later, fibroblasts causes swelling and proliferation of the endothelium of the smaller blood vessels, leading to endarteritis obliterans.
- Regional lymph nodes enlarge without tenderness.

# Primary Syphilis - Diagnosis, Treatment, and Prevention

Treated with penicillin G

- Diagnosis of primary syphilis is based on physical examination, serologic tests, history of sexual contacts, and, if appropriate, darkfield examination of fluids from lesions for spirochetes.
- Benzathine penicillin is the antibiotic of choice in the treatment of primary and secondary syphilis.
- Over 50% of patients with early infectious syphilis, especially those with secondary syphilis, have a Jarisch-Herxheimer reaction (headache, fever, chills, myalgias, exacerbation of cutaneous lesions) within 6-12 hours of initial treatment.

# Burn and Wound Infections

- Once the integrity of the skin is compromised, any number of organisms can cause damage. [So they're more susceptible to skin infections.](#)
- Protecting the wound or burn sites from contamination is vital in proper healing of the damaged sites.
- The common causes of burn or wound infections include **S. aureus**, ***Pseudomonas aeruginosa***, and **S. pyogenes**.
- Infections of wounds and burns by *S. aureus*, *P. aeruginosa*, and *S. pyogenes* results in tissue ulceration and degradation at the wound or trauma site. Other manifestations can include sepsis, septic shock, fever, and delayed wound healing.

# Burn and Wound Infections

- *P. aeruginosa* commonly contaminates water. *S. aureus* and *S. pyogenes* are part of the normal flora.
- Once the skin barrier is compromised, bacteria can contaminate the wound or burn and cause a destructive infection.
- Burns or other wounds provide a highly nutritious medium for bacteria.
- Colonization may be limited to the **eschar** (non-viable skin debris on the surface), invade deeper tissues, or spread systemically through lymph and blood (septicemia).
- In burn patients, septicemia is often polymicrobial. Normal neutrophil function is a key determinant to limiting the severity of the infection.

Usually more than one organism  
cause the infection and are isolated

## Burn and Wound Infections - Diagnosis

- The wound or burn site should be sampled and cultured to determine the specific organism that is the cause of the infection.
- In *P. aeruginosa* infections, there may be a foul-smelling green-pigmented discharge, and necrosis may be evident (ecthyma gangrenosum).
- *S. aureus* causes an insidious tissue-degrading infection that can eventually enter the bloodstream.
- *S. pyogenes* infection can result in rapid tissue degradation with severe toxicity.

Also AST (antimicrobial susceptibility tests)  
should be performed

# Burn and Wound Infections - Treatment and Prevention

- Oral dicloxacillin is effective for treating both *S. pyogenes* and *S. aureus* infections.
- Imipenem-cilastatin or meropenem have been shown to be effective in treating *P. aeruginosa* infections.
- Burn patients must have fluids and electrolytes restored intravenously as well as protection from infection of the burn sites.

Usually in diabetics

# Ecthyma gangrenosum

- Ecthyma gangrenosum is a skin lesion that can occur following septic infections with ***P. aeruginosa***.
- Other bacteria and fungi occasionally have been associated with ecthyma gangrenosum.
- Lesions of ecthyma gangrenosum begin as red macules that enlarge and become slightly elevated papules, which become hemorrhagic and centrally necrotic with purple-to-black coloration.

# Ecthyma gangrenosum

Swap for culture is taken and it will probably reveal *S.aeruginosa*

- Ecthyma gangrenosum occurs in bacteremia patients.
- At-risk groups for ecthyma gangrenosum include immunocompromised **neutropenic patients**.
- The lesions of ecthyma gangrenosum occur following perivascular bacterial invasion of arteries and veins in the dermis and subcutaneous tissues producing a necrotizing vasculitis.
- If no fluid is present, the eschar should be elevated, and the underlying tissue swabbed for a Gram stain. Blood should be collected for culture to detect bacteremia.



Pseudomonas is usually multi drugs resistant

## Ecthyma gangrenosum - Treatment and Prevention

- Treatment of ecthyma gangrenosum usually requires the use of anti-pseudomonal penicillin, aminoglycosides, fluoroquinolones, third-generation cephalosporins, or aztreonam.
- Empiric therapy includes anti-pseudomonal penicillin (piperacillin) in combination with an aminoglycoside (gentamicin).
- Definitive therapy after the organism has been identified and antibiotic sensitivity results are known.

Ceftazidime (third generation of cephalosporins) has anti pseudomonal activity

# Activities' questions and solutions:

The septic emboli are transported by the bloodstream and lodge in small vessels and cause petechial skin lesions associated with infective endocarditis ✓

Impetigo is a superficial infection that causes shallow erosions in the skin that are covered by a honey-colored crust ✓

In primary syphilis, a painful papule progresses to a singular painful ulcer with a raised and indurated border that is termed chancre x

Osler nodes are erythematous tender nodules 2-15 mm in diameter and are usually located on the pads of fingers and toes in infective endocarditis ✓

Acute meningococemia produces erythematous macules, petechiae, purpura, and ecchymoses, with lesions commonly beginning on the trunk and legs ✓

Scalded skin syndrome is an acute exfoliating disease of the skin as a result of *Pseudomonas aeruginosa* endotoxin x

Janeway lesions are small erythematous painless macules, plaques, or palpable purpura, and are usually observed on the palms and soles in infective endocarditis ✓

Splinter hemorrhages are linear red-to-brown streaks that appear under the fingernails and toenails in infective endocarditis ✓

Ecthyma gangrenosum is a skin lesion that occur following septic infections with *Pseudomonas aeruginosa* ✓

The common causes of burn or wound infections include *Staphylococcus aureus*, *Pseudomonas aeruginosa*, and *Streptococcus pyogenes* ✓

**Thanks for listening!**