

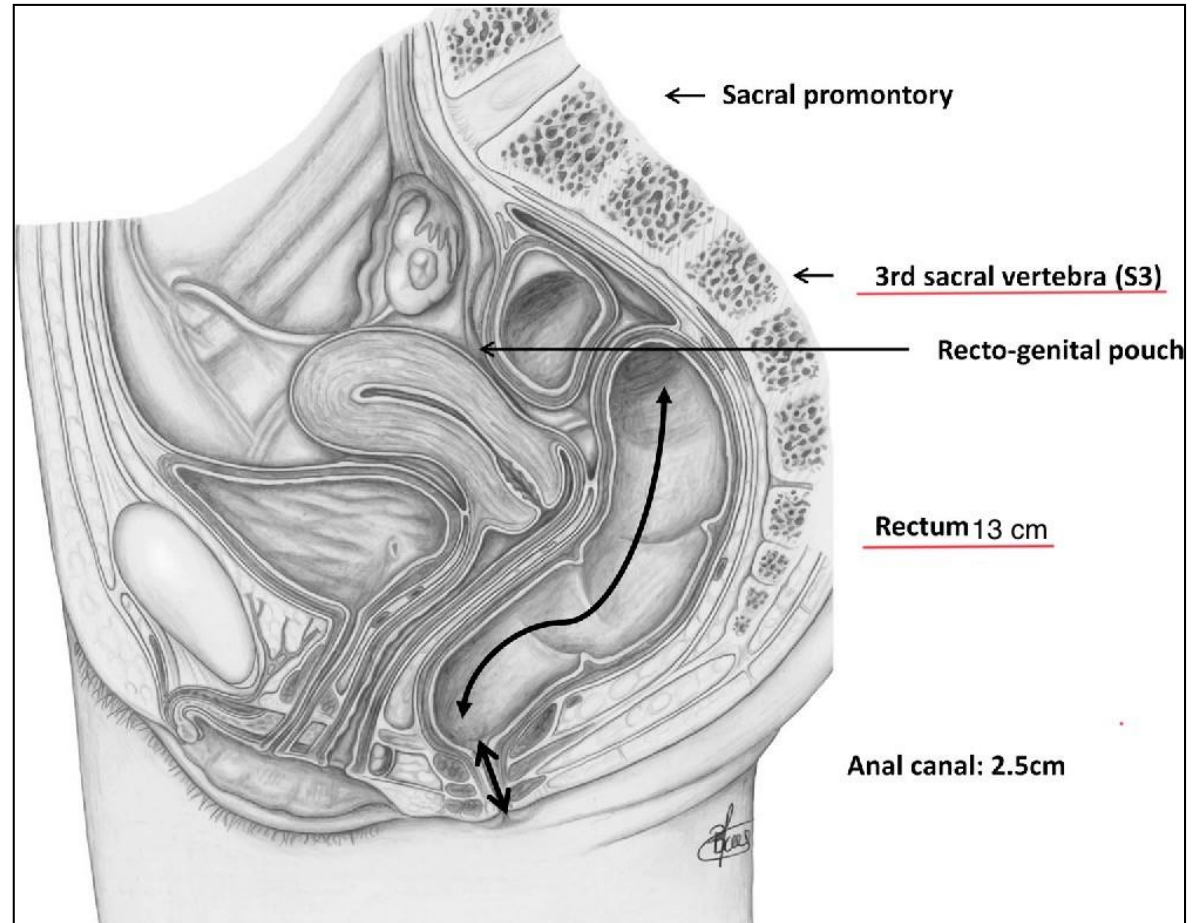
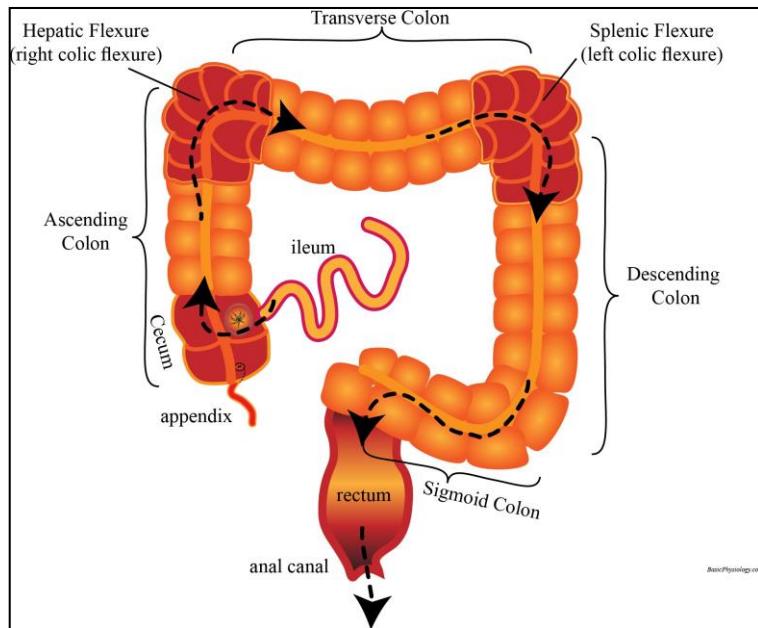
# The sixth practical lab of the 5th week Sun 25/04

1. Rectum
2. Anal canal
3. Posterior Abdominal wall
4. Liver
5. Gallbladder
6. Pancreas
7. Spleen

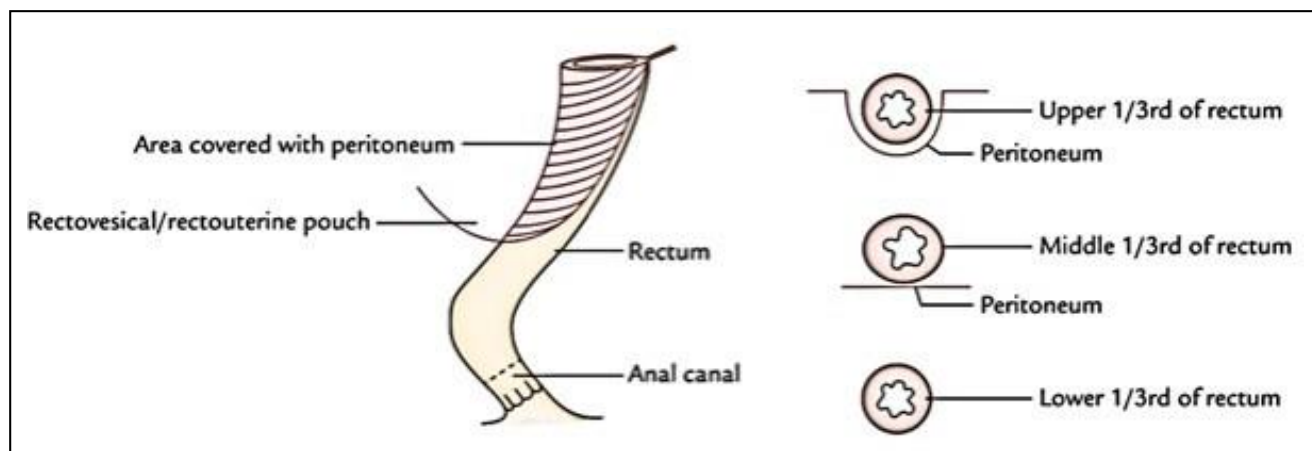
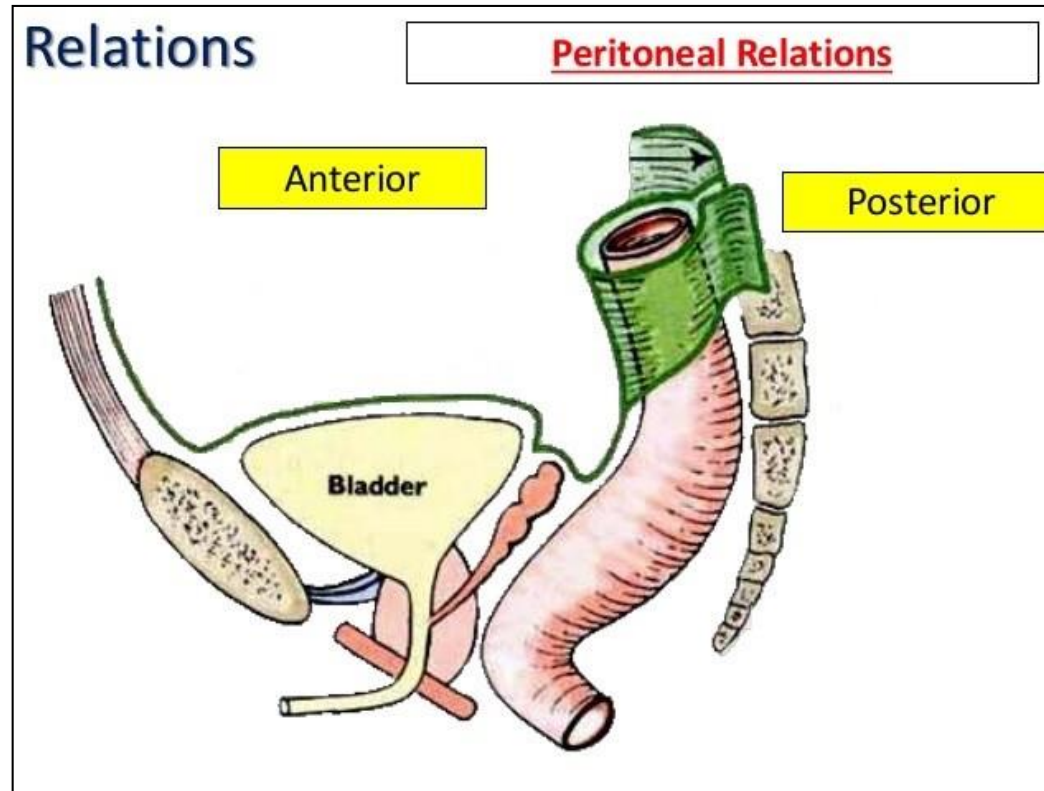
# ✦ Rectum

- The students should know and identify the :
  1. Site and Position
  2. Peritoneal Relations
  3. Relations
  4. Blood supply

# • Site and Position of the rectum



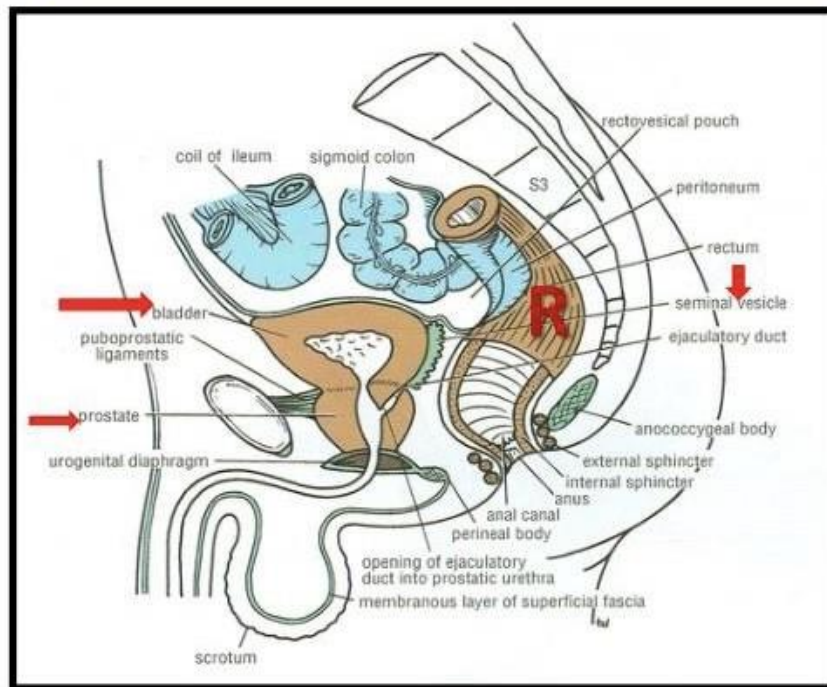
# • Peritoneal Relations of the rectum



# • Relations of the rectum

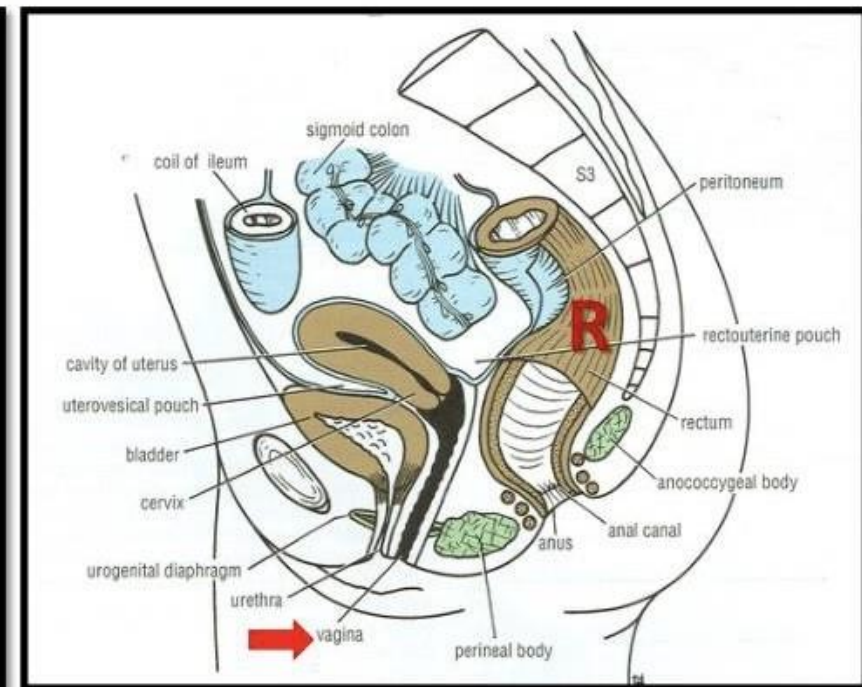
## MALE PELVIS

- ❑ **Anterior:** seminal vesicles, posterior surfaces of urinary bladder & prostate gland
- ❑ **Posterior:** sacrum & coccyx



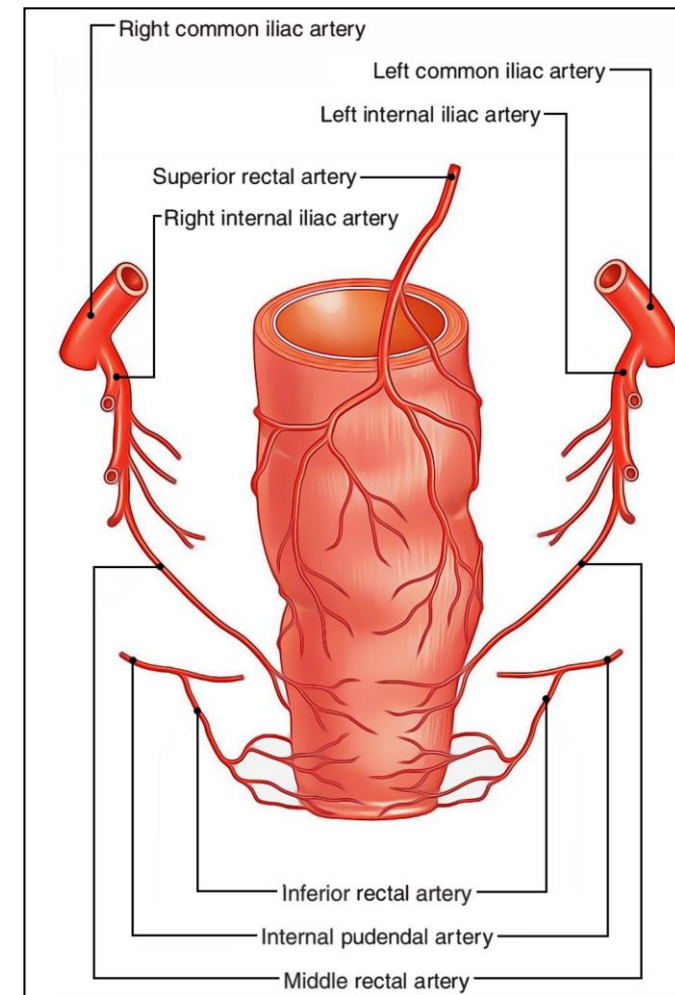
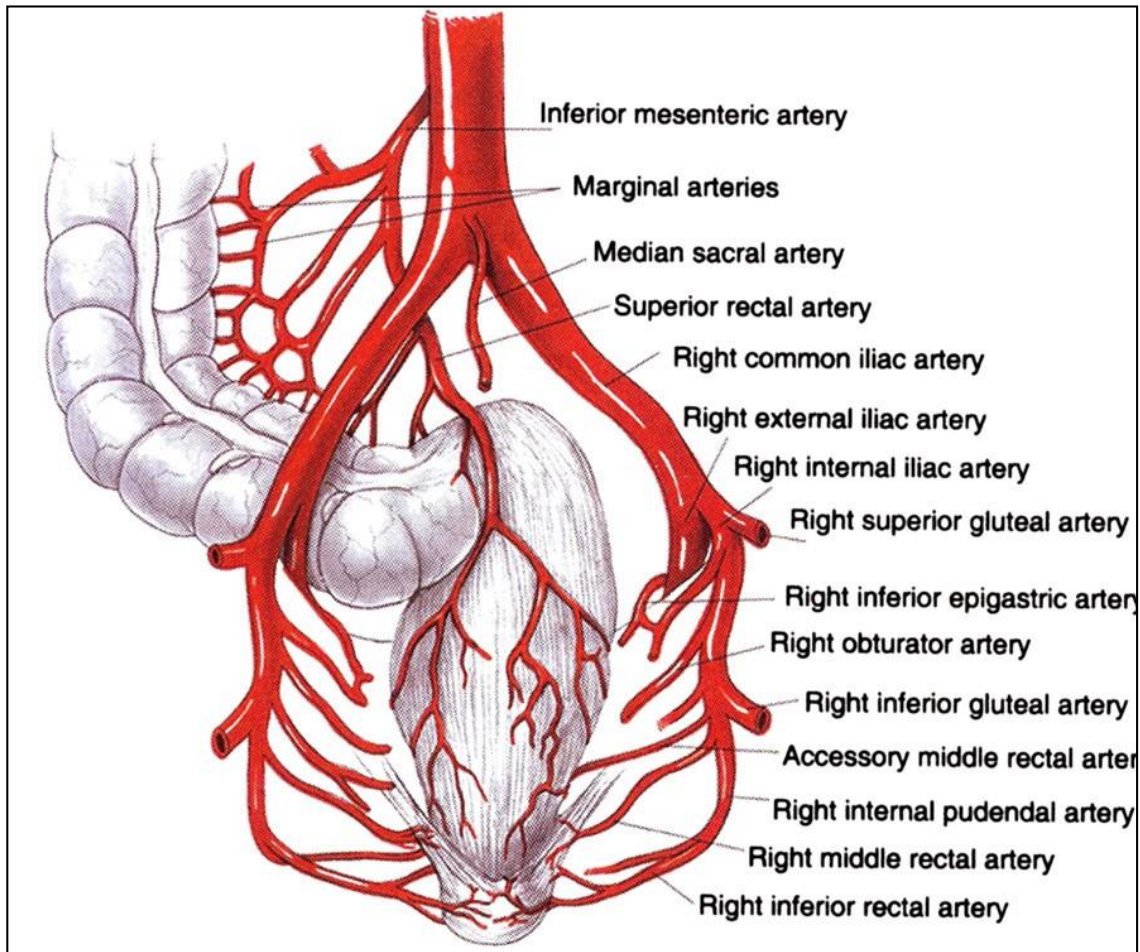
## FEMALE PELVIS

- ❑ **Anterior:** posterior wall of vagina
- ❑ **Posterior:** sacrum & coccyx



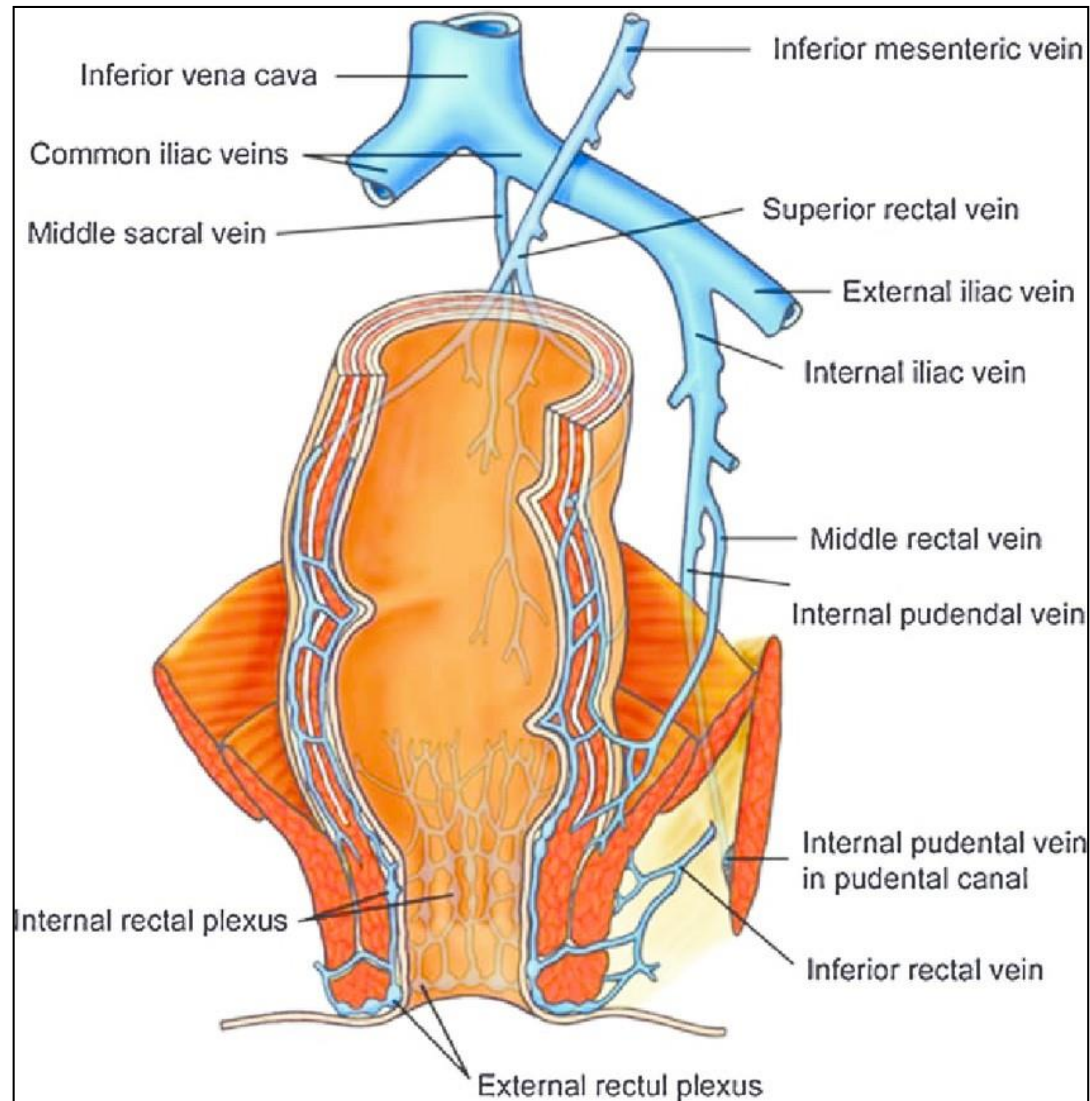
# • Blood supply of the rectum

## • Arterial supply



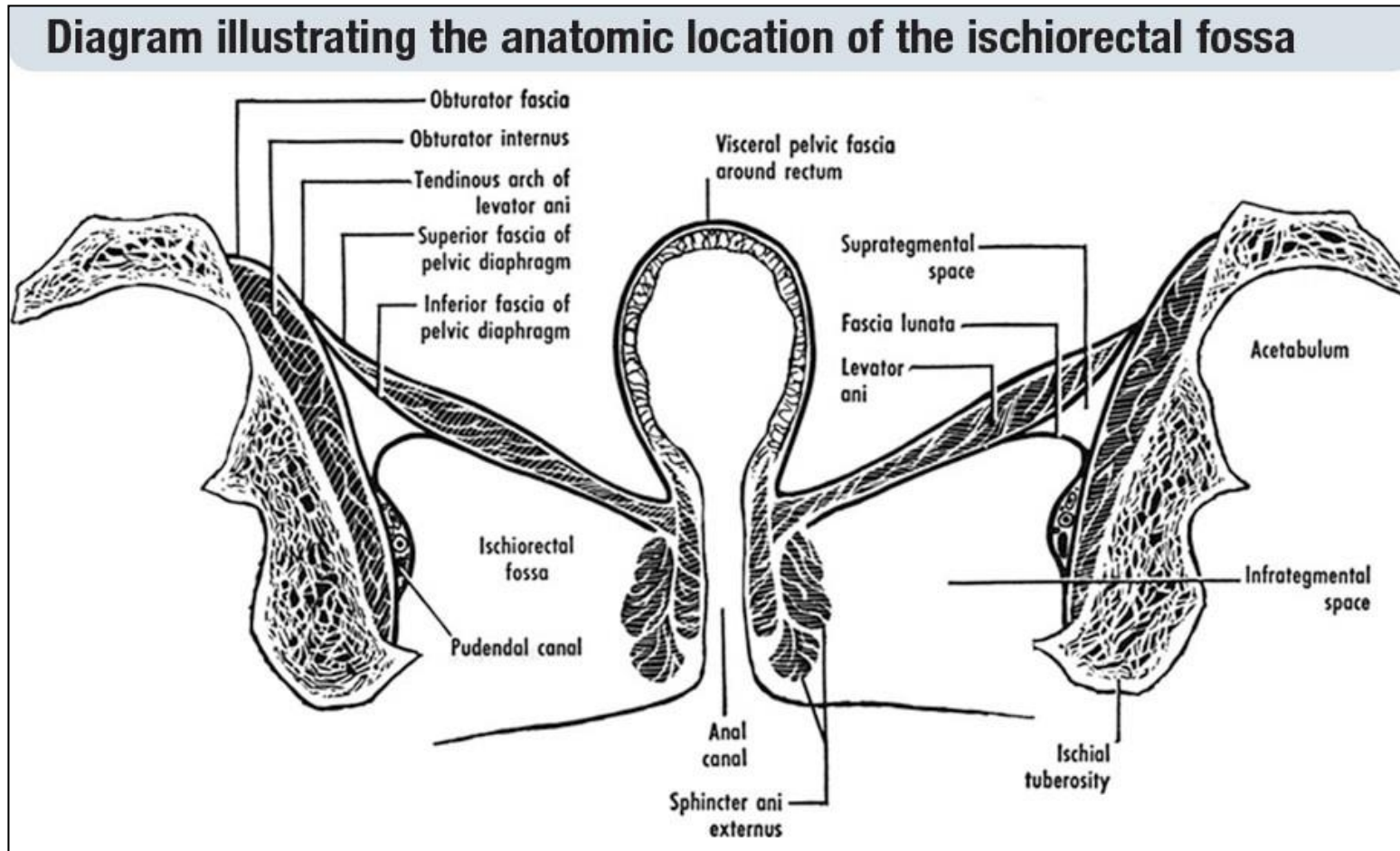
# • Blood supply of the rectum

## • Venous drainage



# • Ischiorectal Fossa

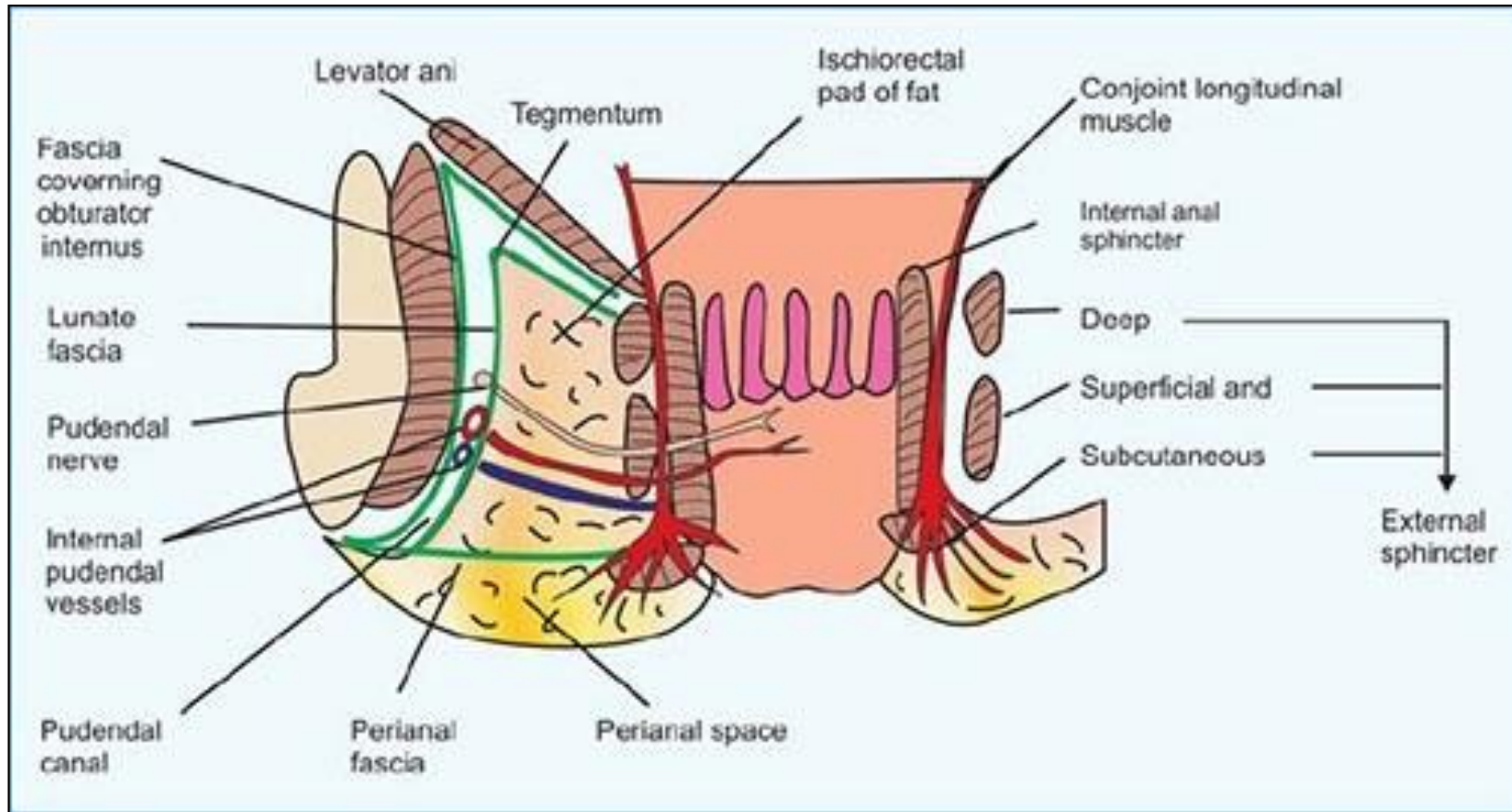
## • Boundaries





# • Ischioirectal Fossa

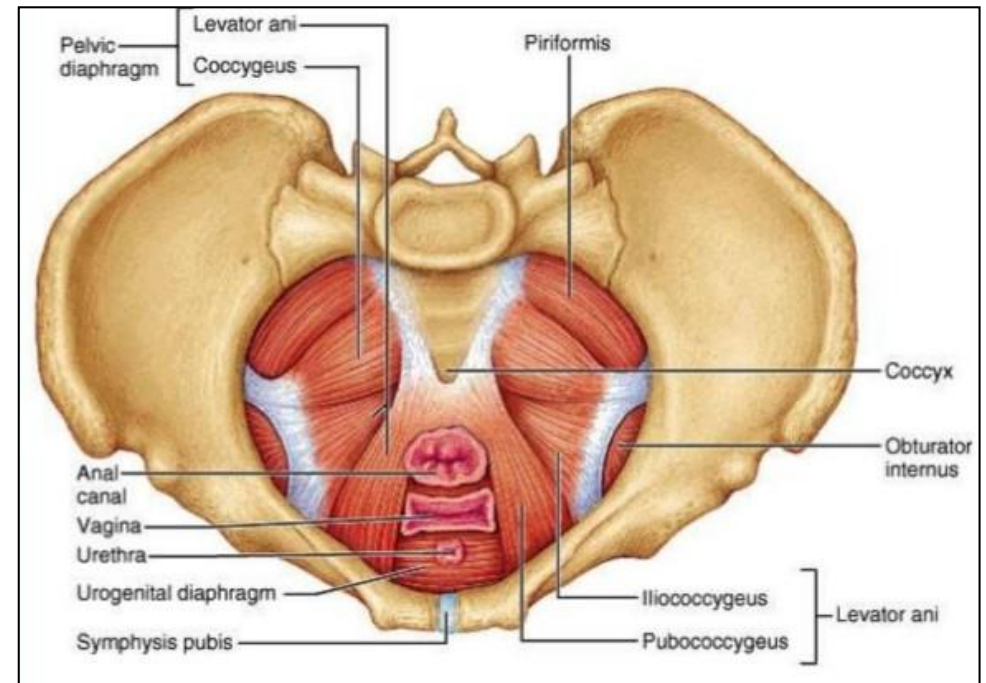
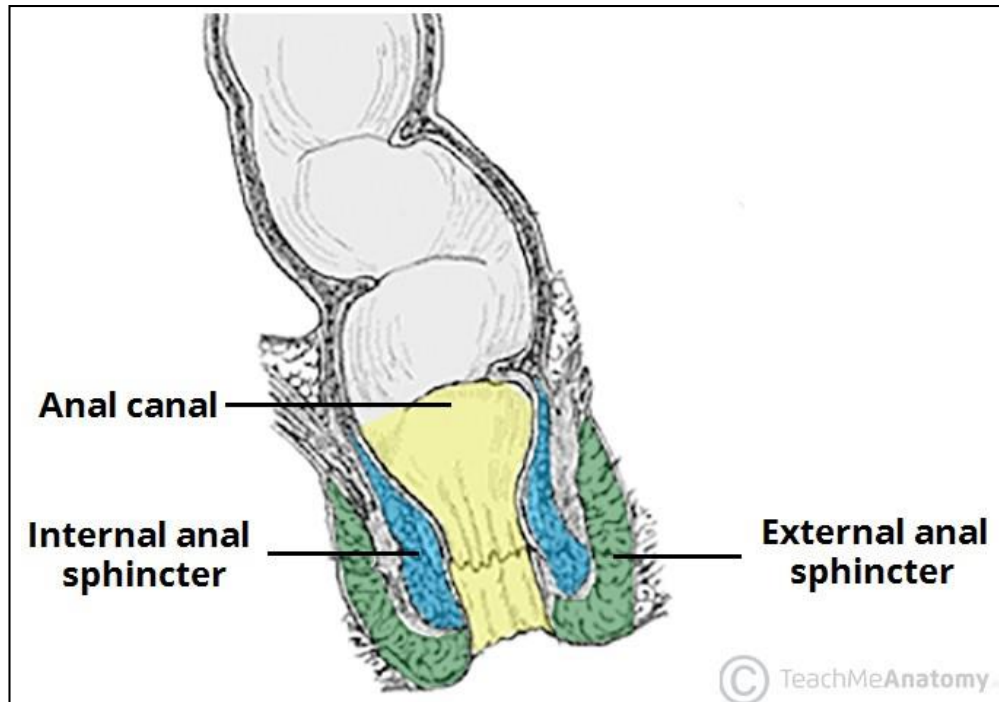
## • Contents



## ✦ Anal canal

- The students should know and identify the :
  1. Site and Position
  2. Peritoneal Relations
  3. Relations
  4. Blood supply

# • Site and Position of the Anal canal



# • Peritoneal Relations of the Anal canal

## Relations of anal canal

### Anteriorly

#### In male

- perineal body
- membranous urethra
- bulb of penis

#### In female

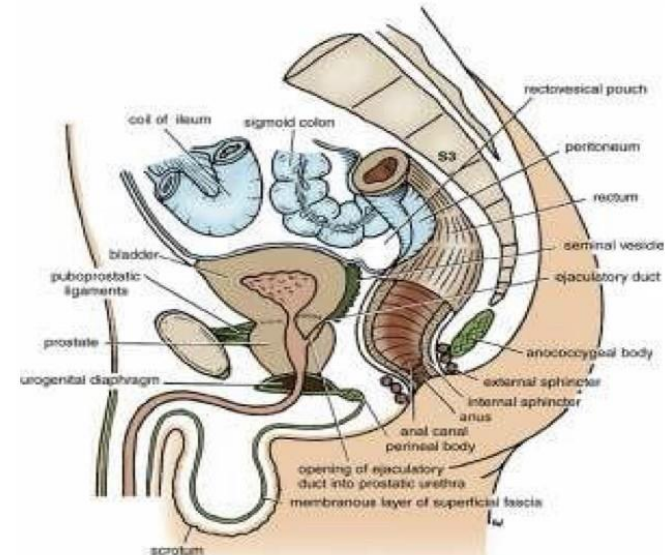
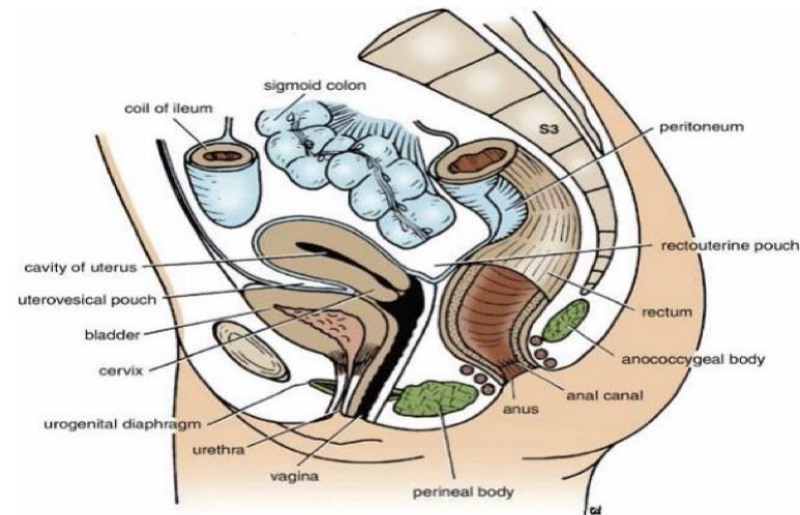
- lower end of the vagina

### Posteriorly

- anococcygeal ligament
- tip of the coccyx

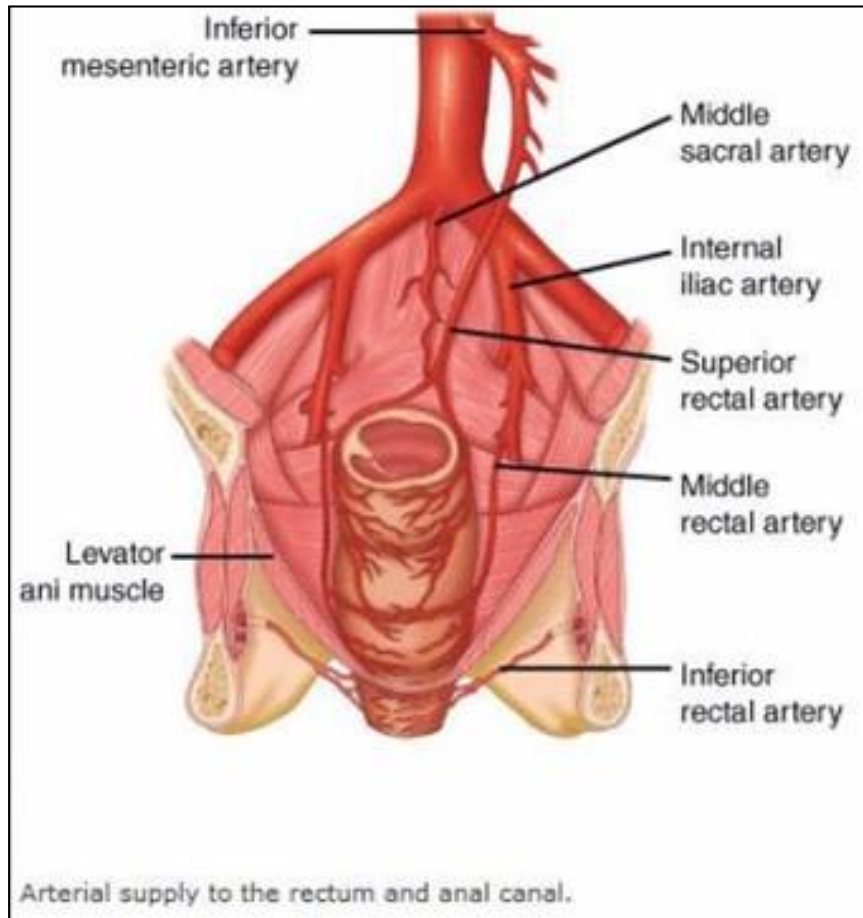
### laterally

- ischiorectal fossae.

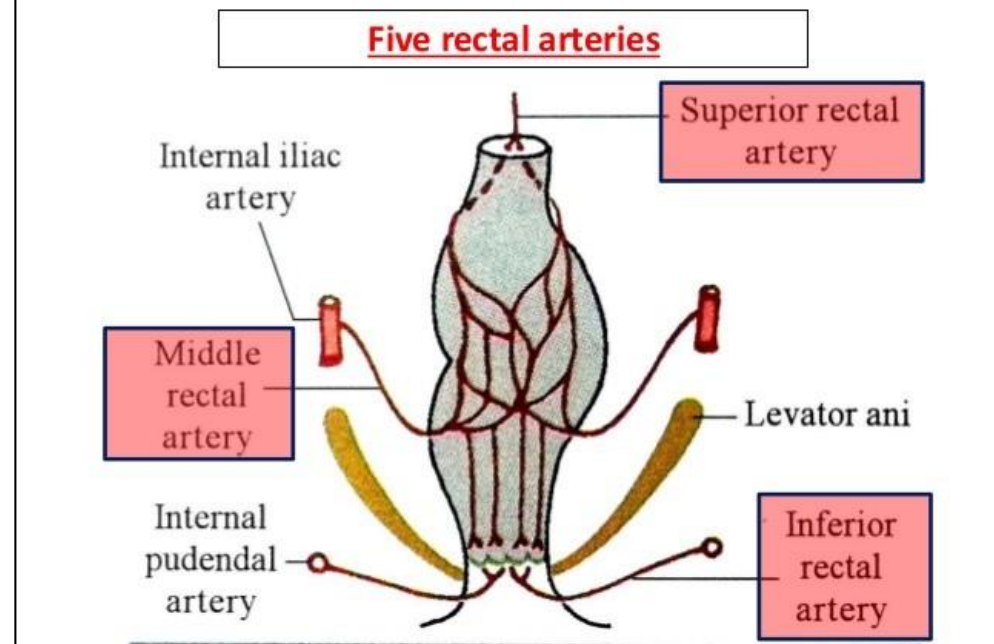


# • Blood supply of the Anal canal

## • Arterial supply

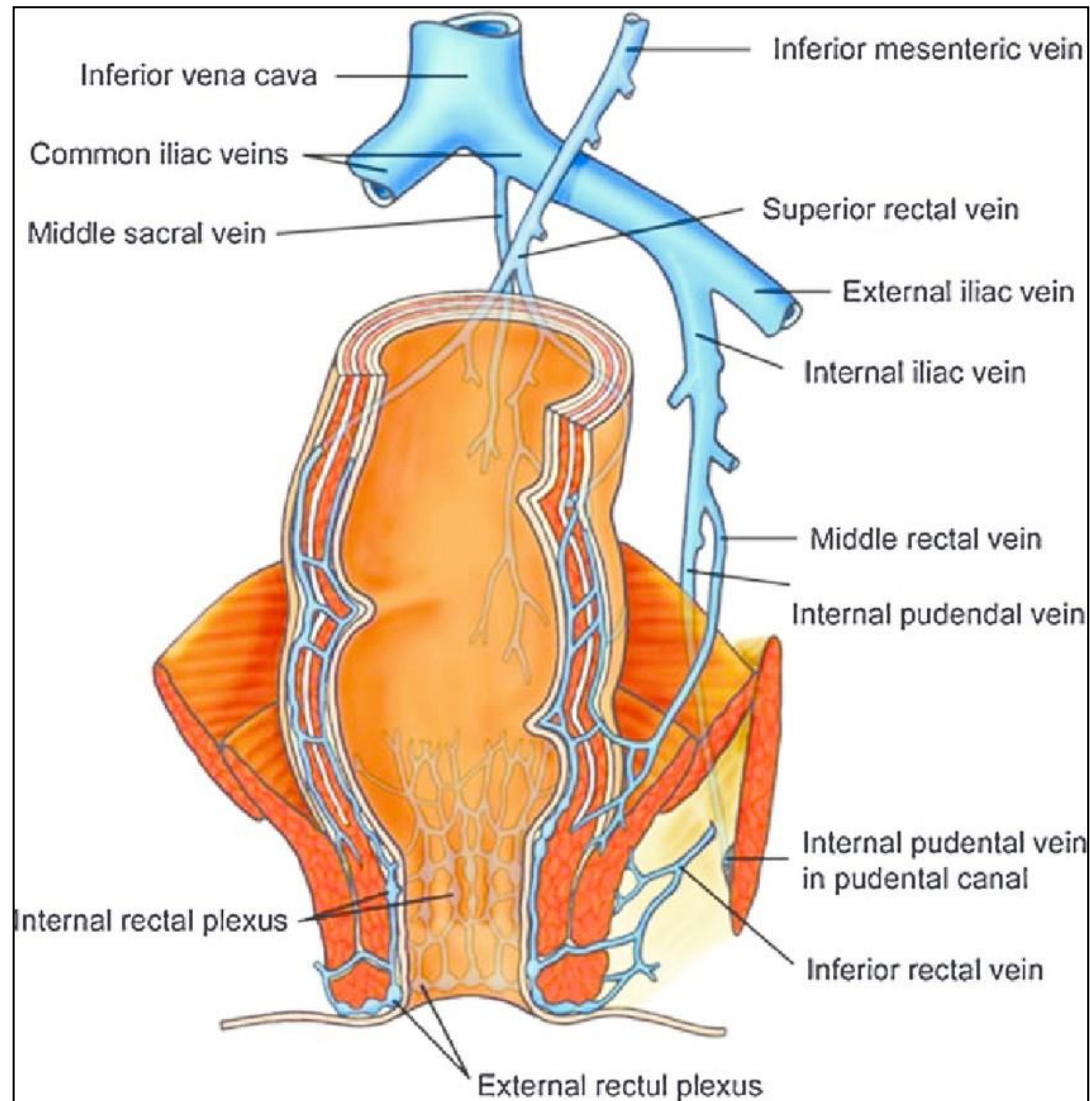


## Arterial Supply



# • Blood supply of the Anal canal

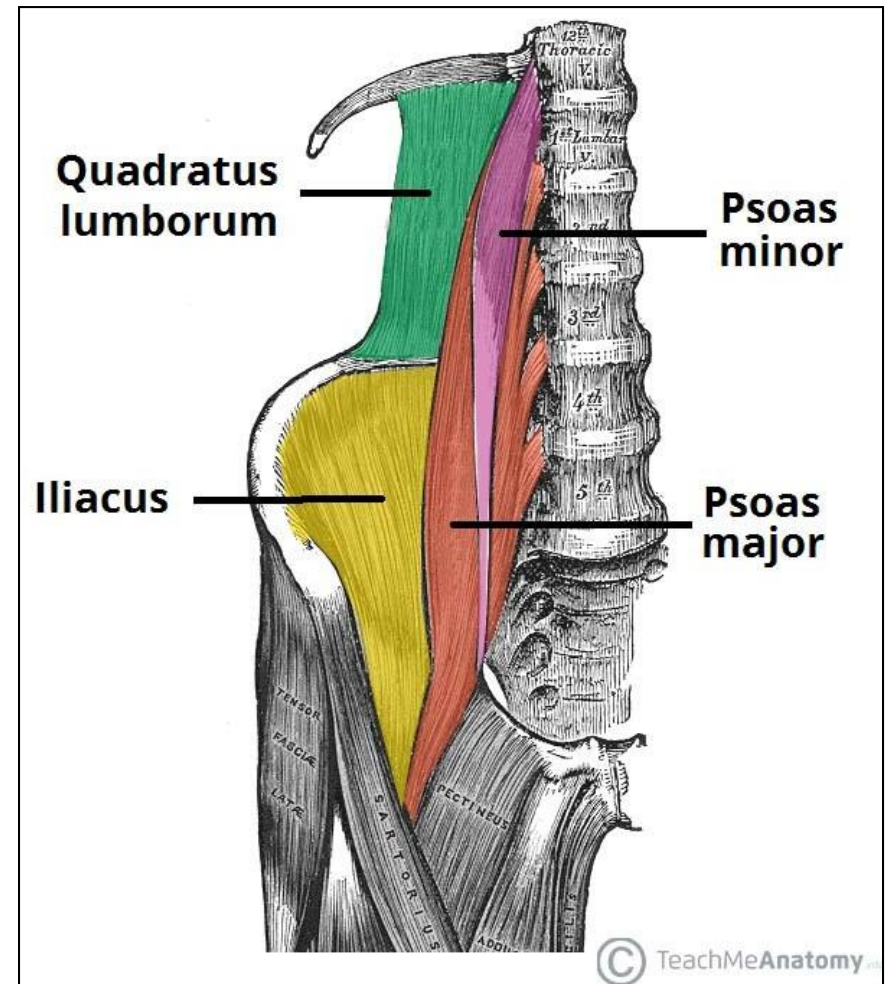
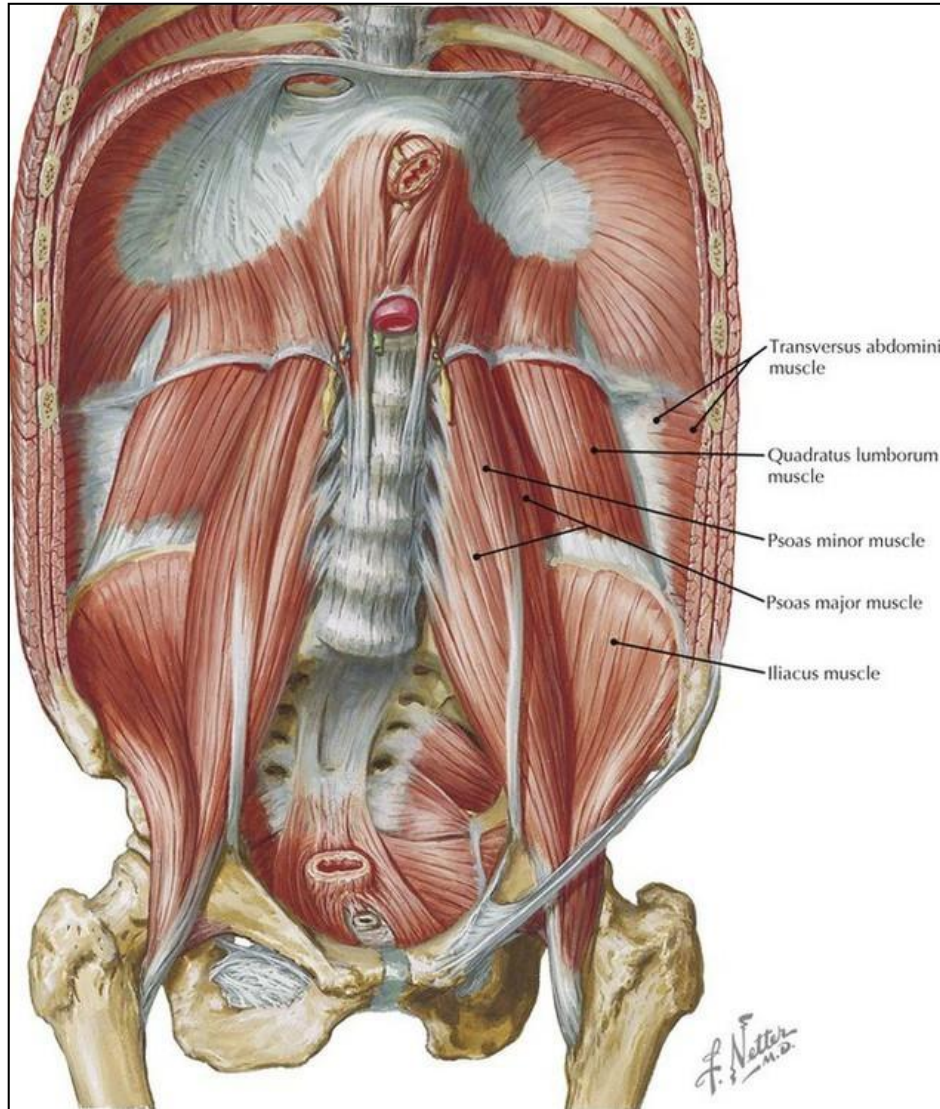
## • Venous drainage



## ✦ Posterior Abdominal wall

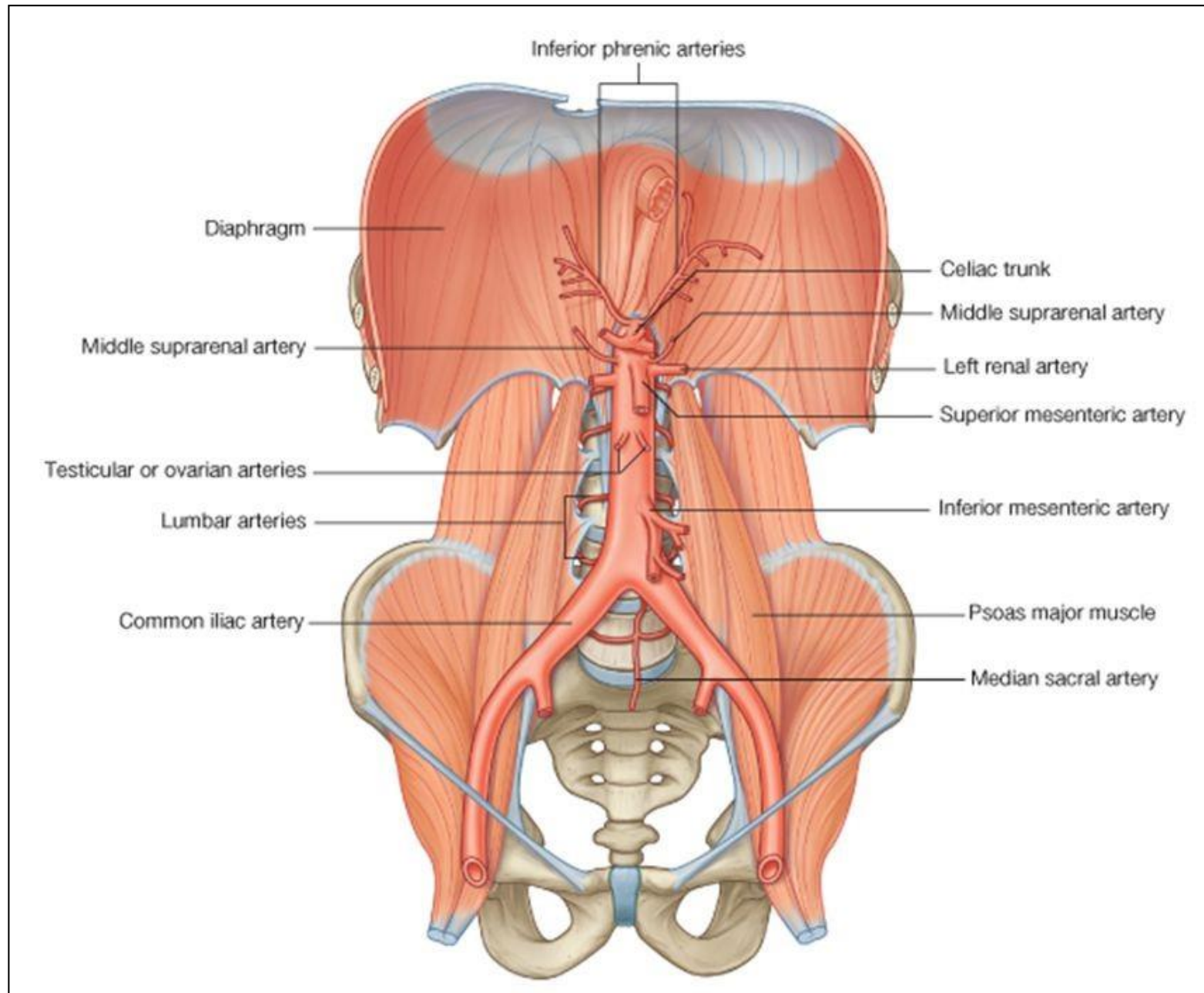
- The students should know and identify the :
  1. Muscles
  2. Blood supply
  3. Nerves

# • Muscles of post.abdominal wall

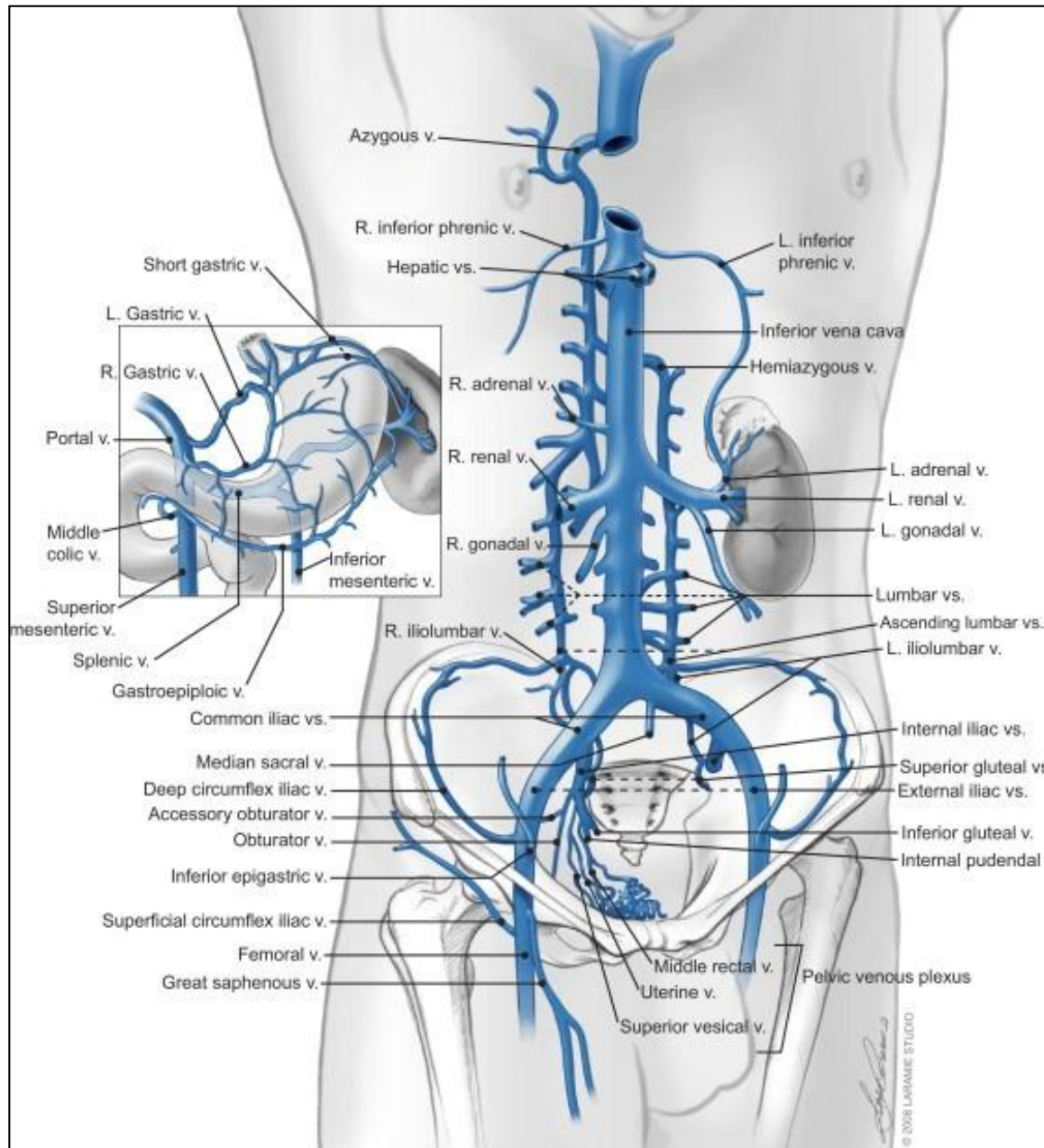




# • Arteries on the Posterior Abdominal Wall

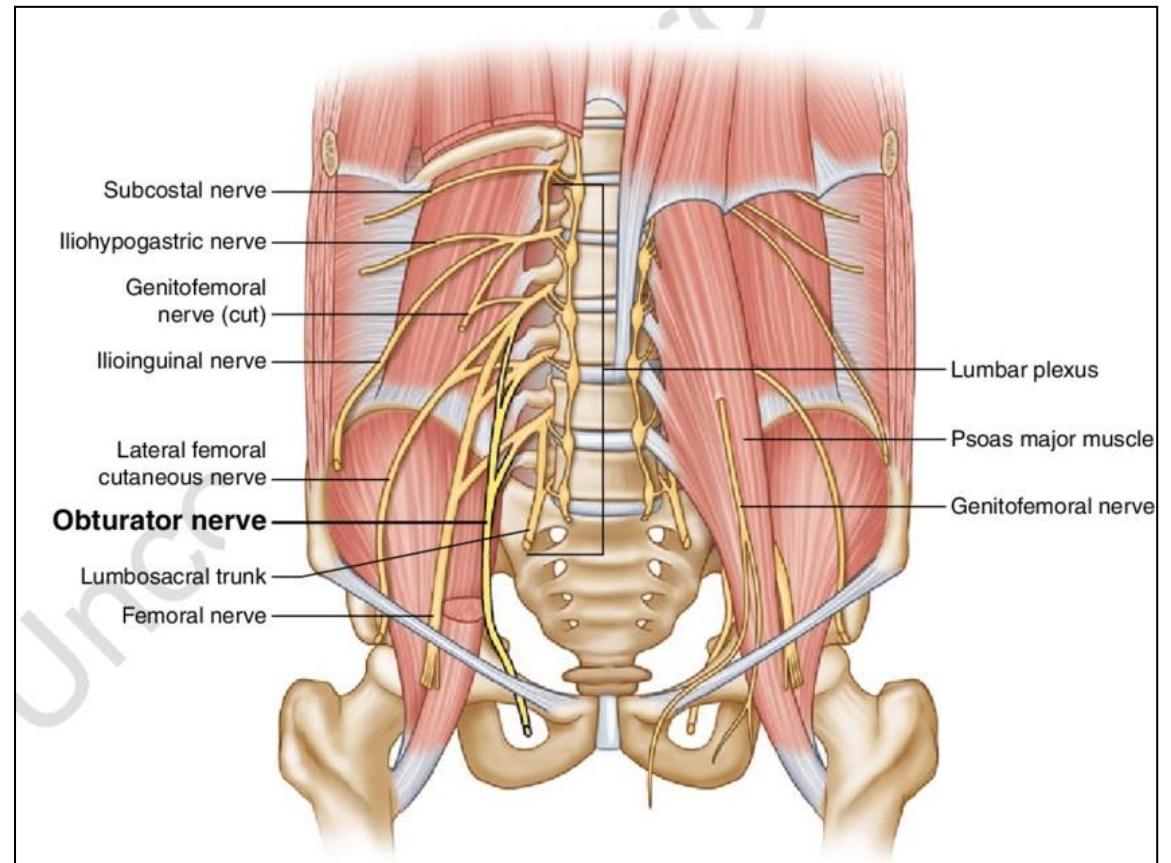
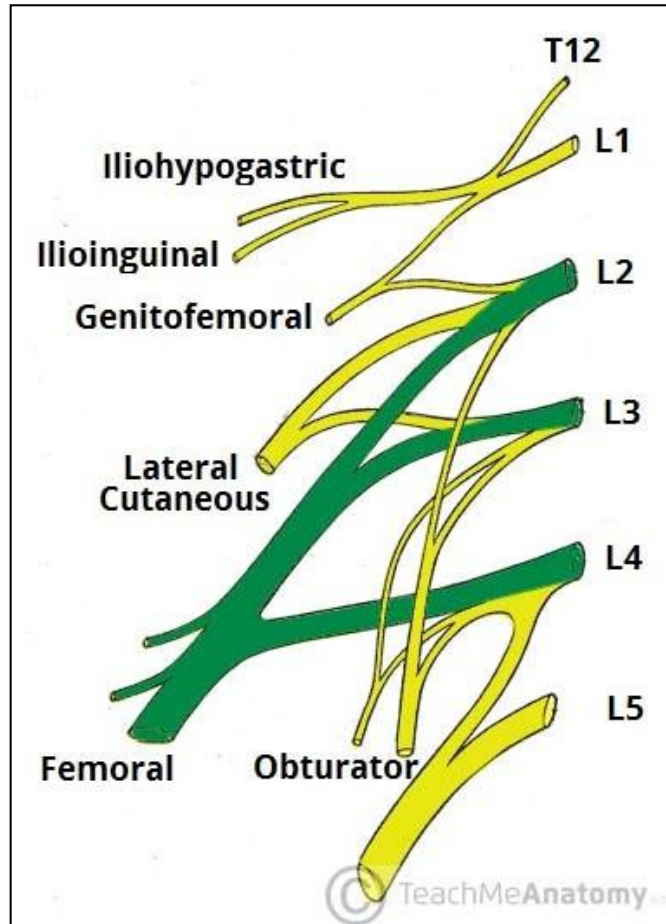


# • Veins on the Posterior Abdominal Wall



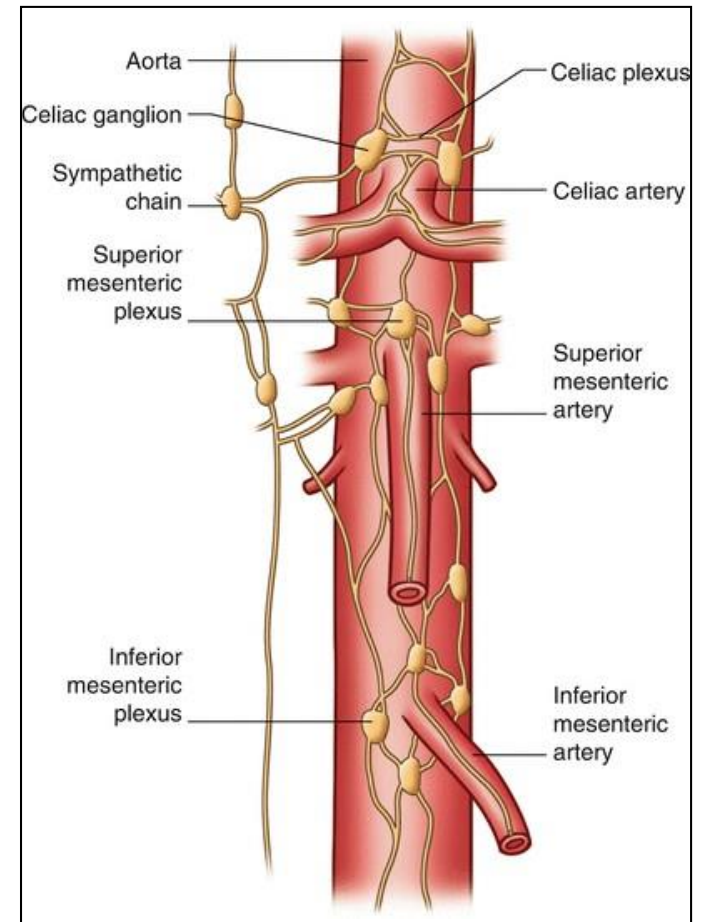
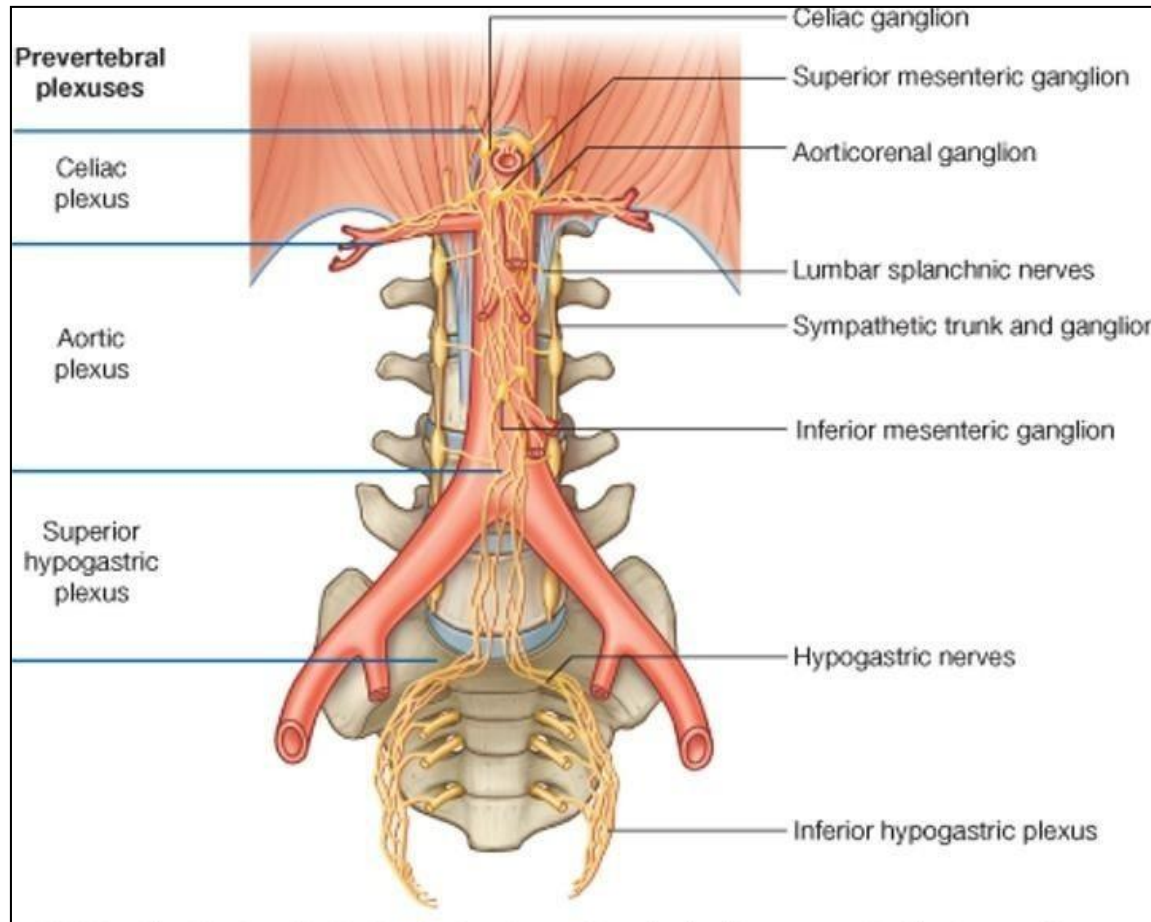
# • Nerves on the Posterior Abdominal Wall

## • Lumbar Plexus



# • Nerves on the Posterior Abdominal Wall

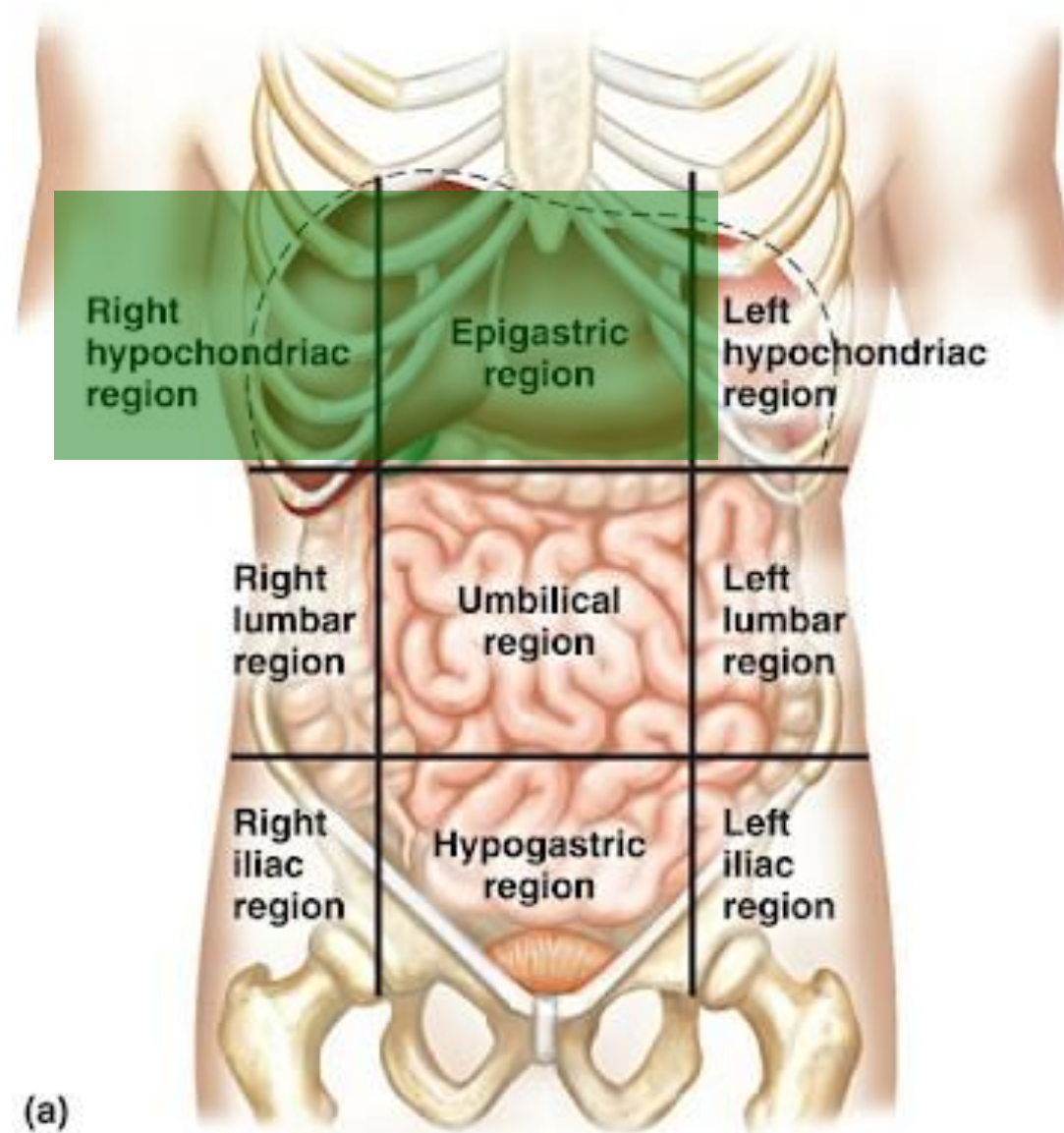
- Sympathetic Trunk (Abdominal Part)



# ✦ Liver

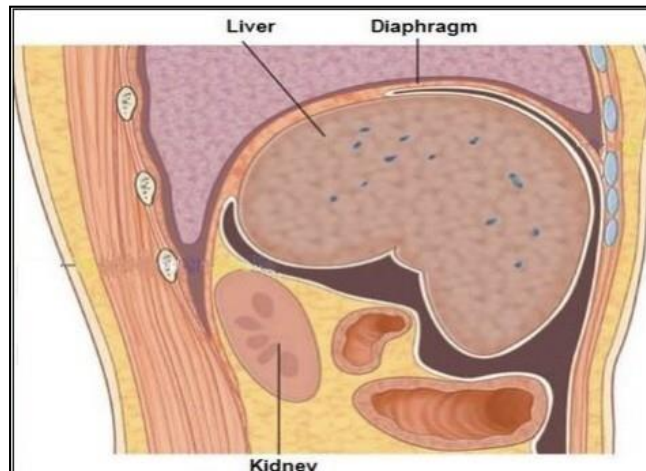
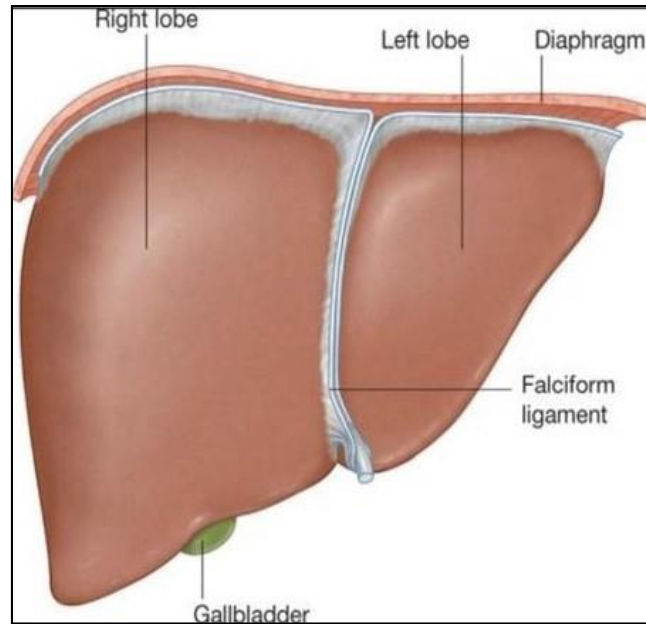
- The students should know and identify the :
  1. Site
  2. Surfaces
  3. Relation and impression of liver surfaces
  4. Ligaments
  5. Porta hepatis
  6. Blood supply

- Site of the liver

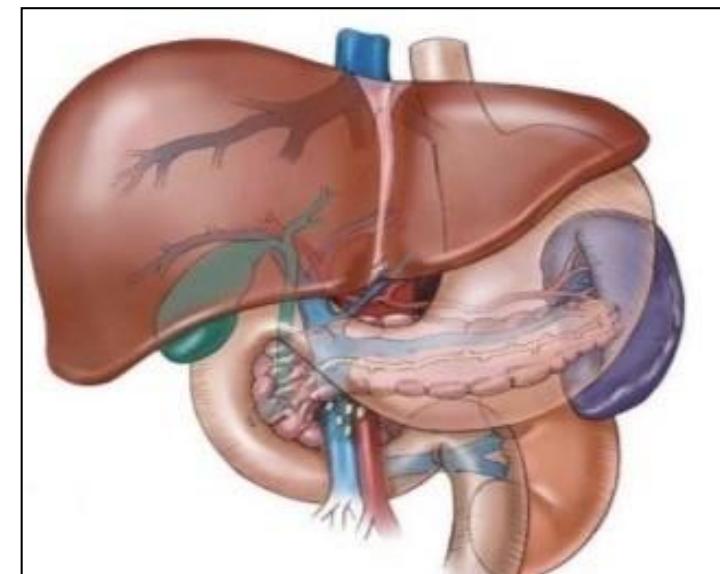
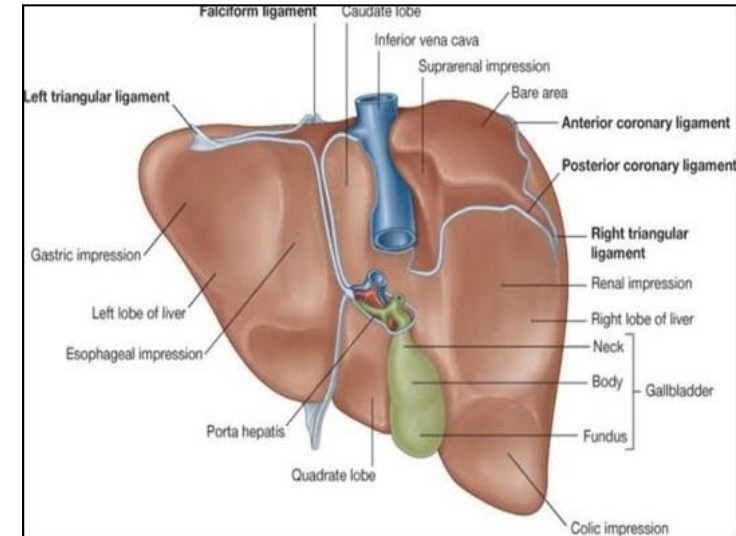


# • Surfaces of the liver

- Diaphragmatic surface:  
(superior, anterior and right lateral surface)

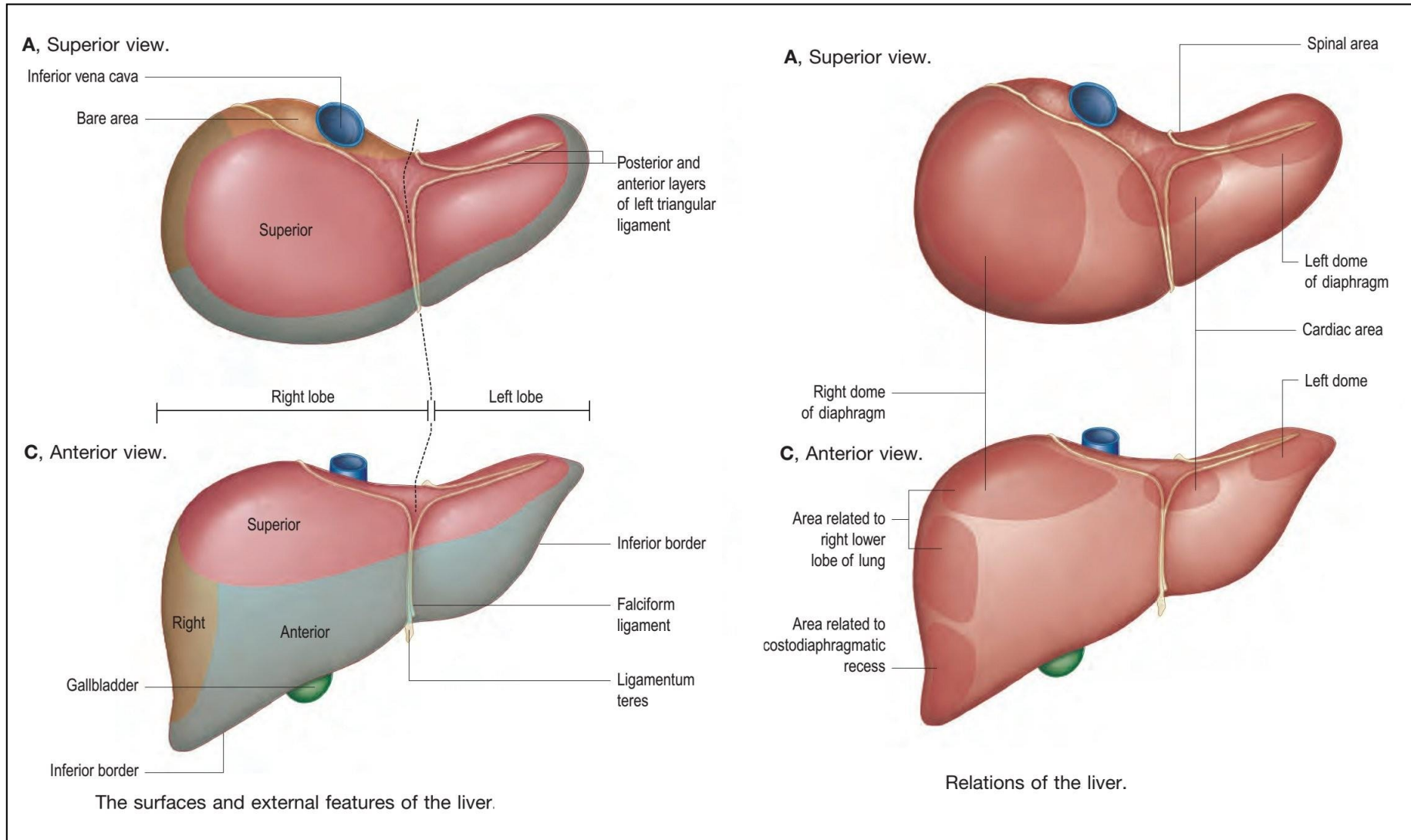


- Visceral surface:  
(posteroinferior surface)



# • Relation and impression of liver surfaces

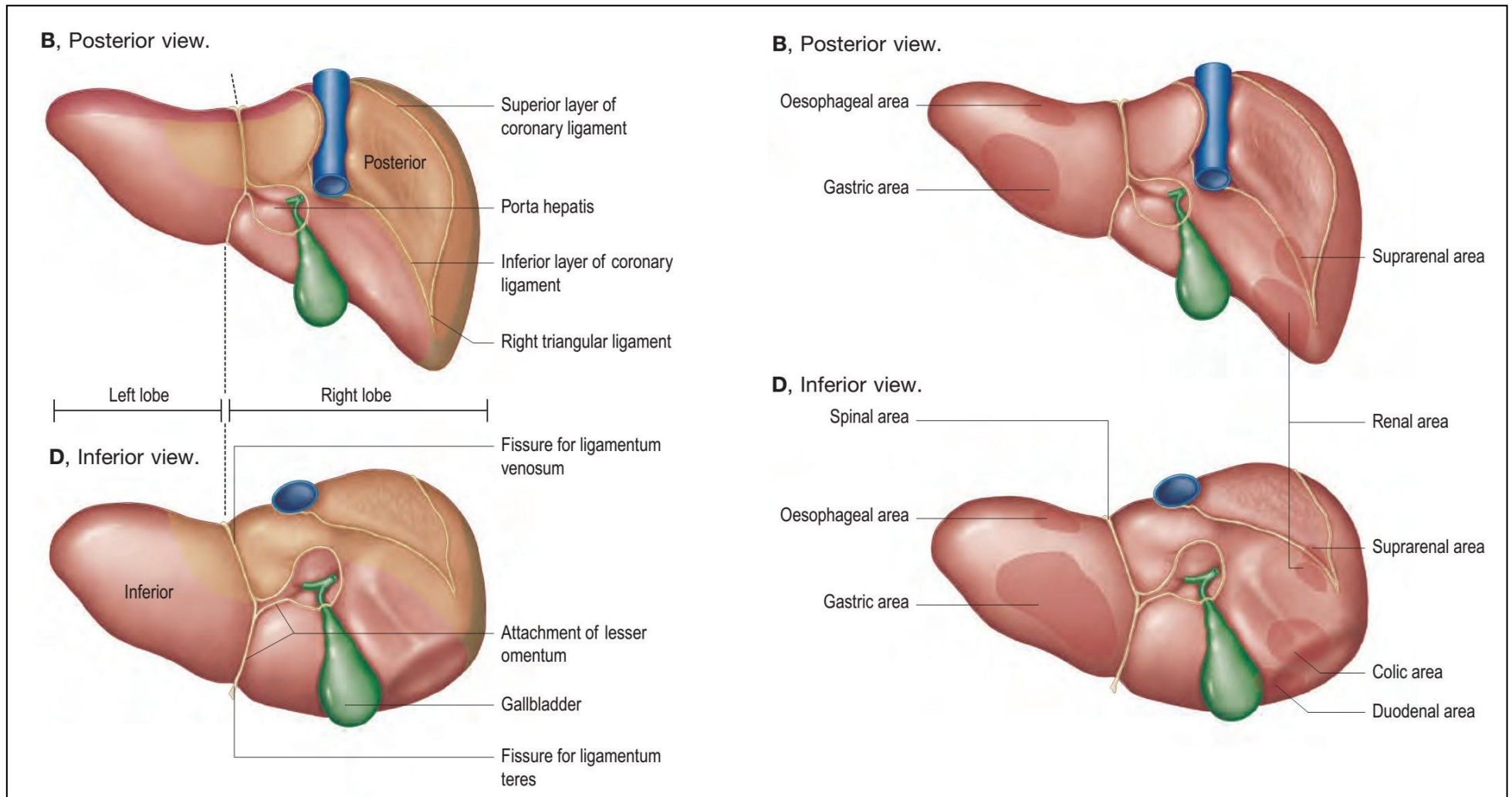
- superior and anterior surface:





# • Relation and impression of liver surfaces

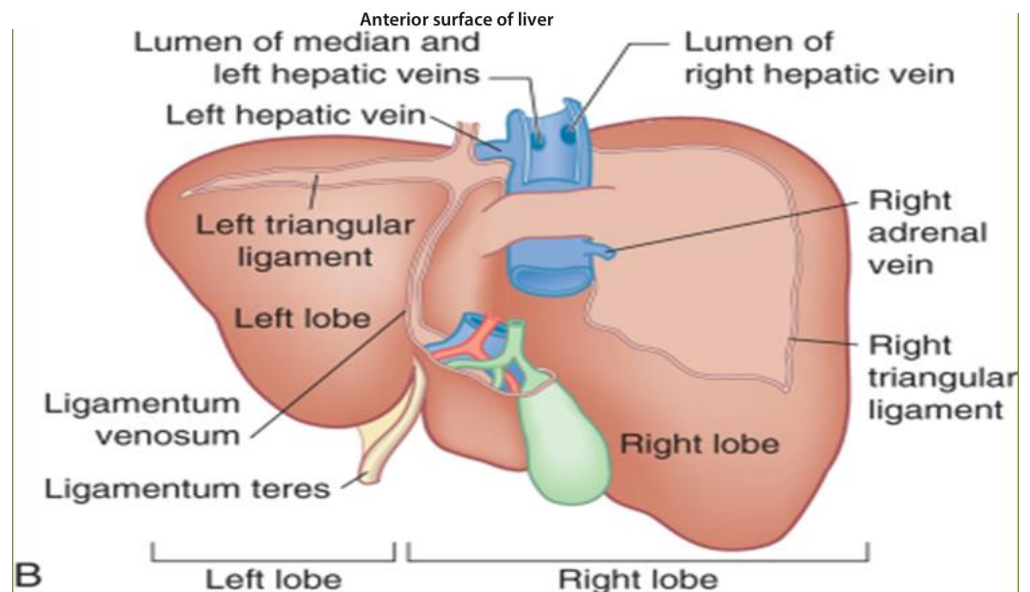
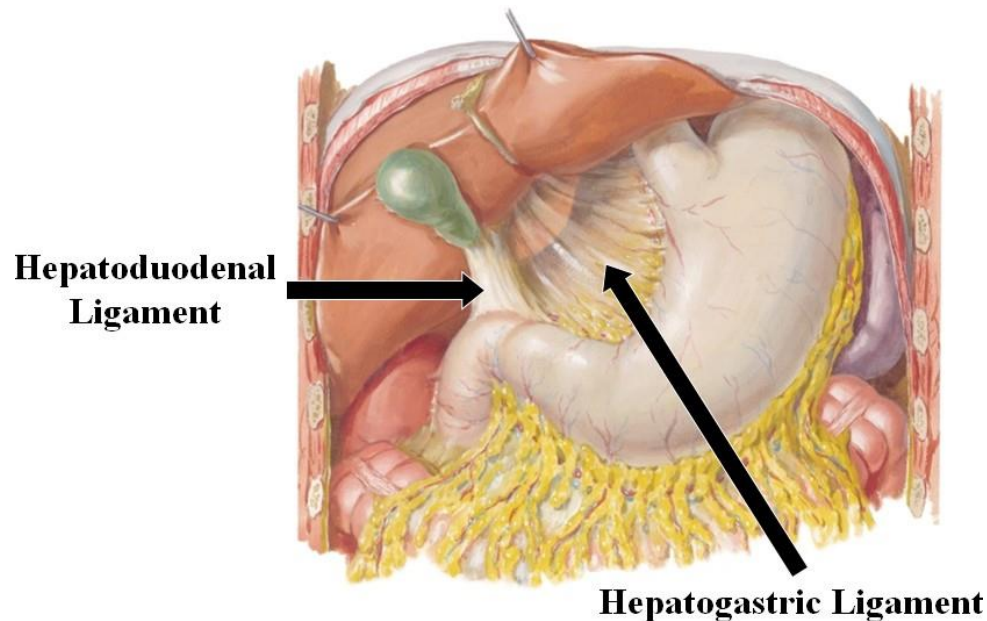
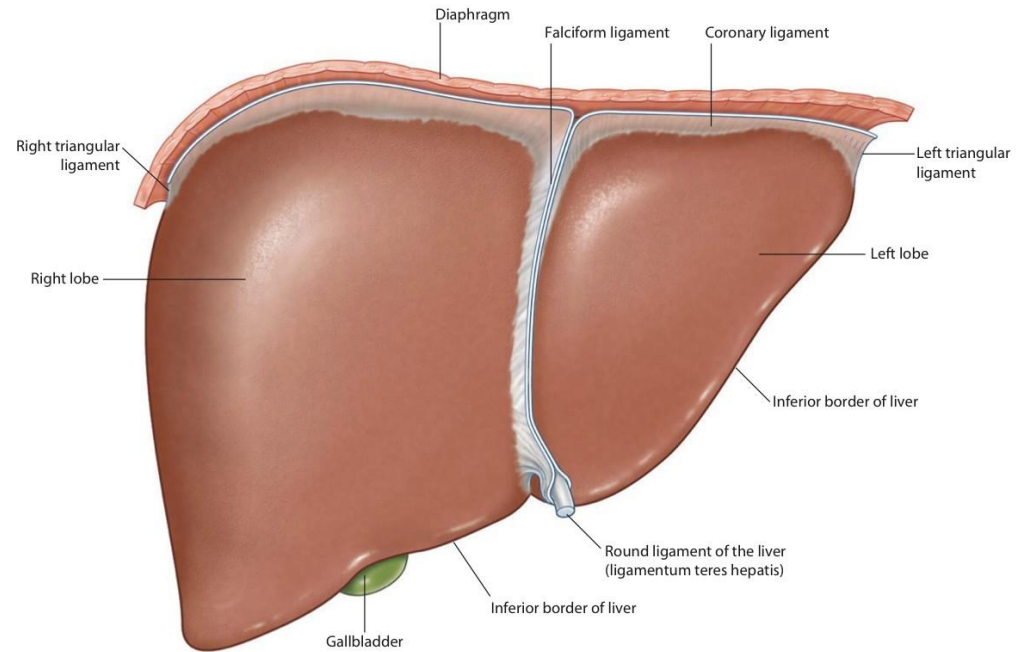
## • Posterior and inferior surface:



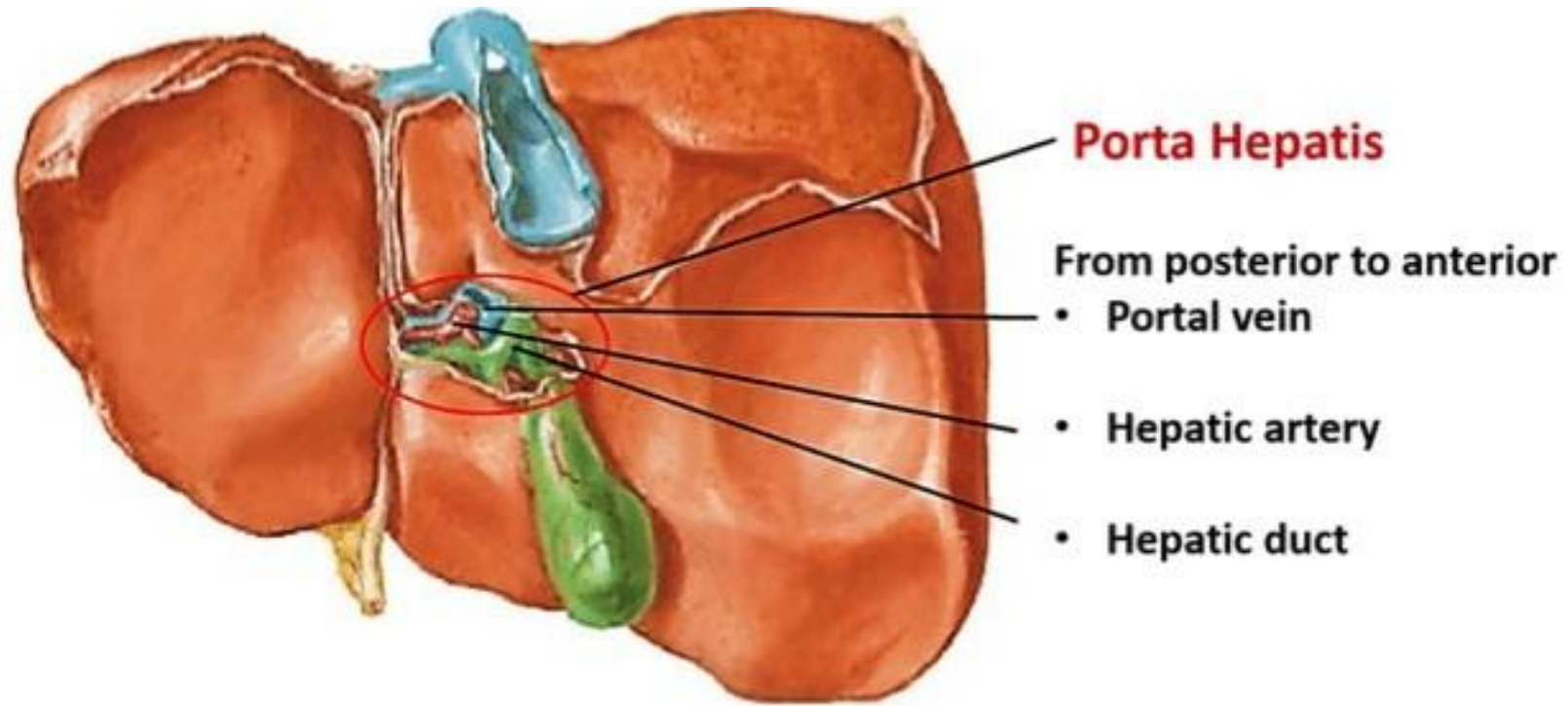
# • Ligaments of the liver

## • The students should observe the following :

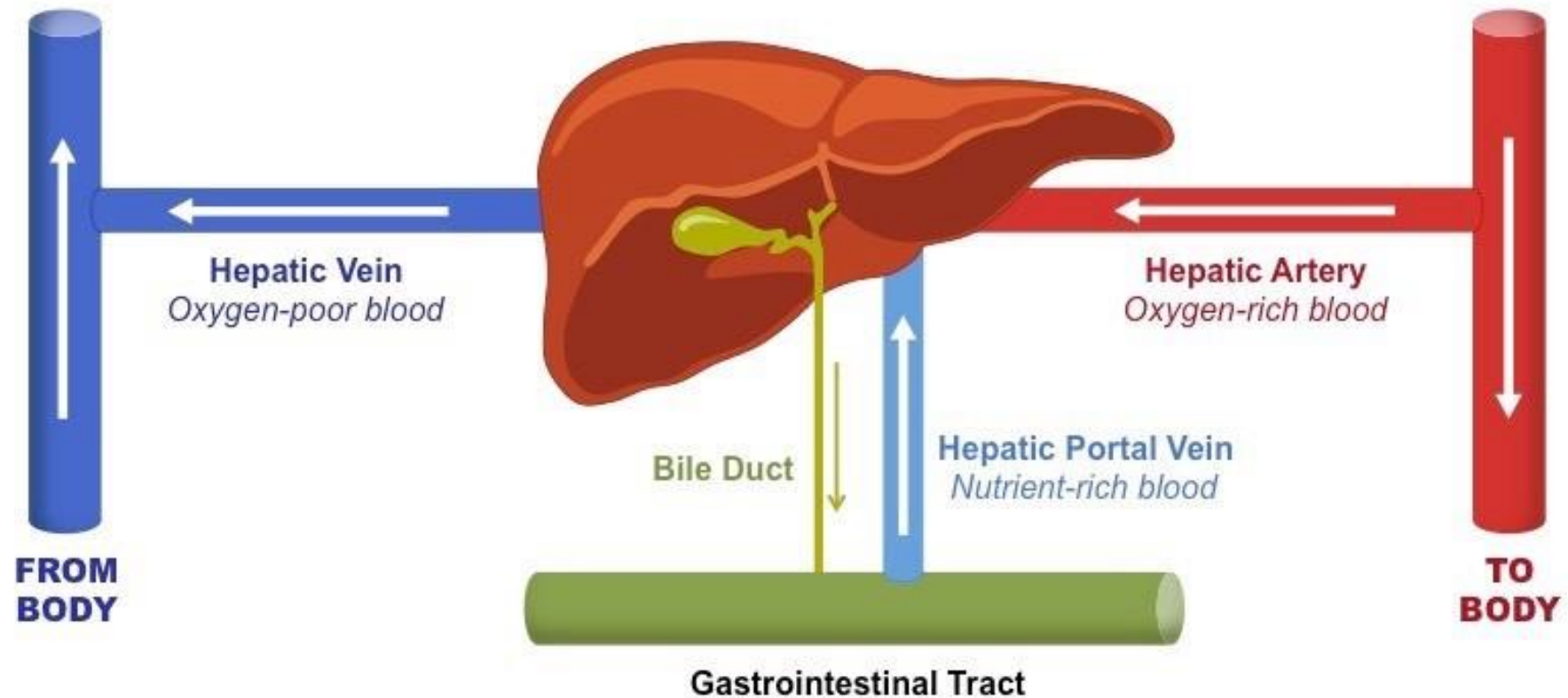
1. The falciform ligament of liver
2. The ligamentum teres hepatis
3. The coronary ligament
4. The right triangular ligament
5. The left triangular ligament
6. The hepatogastric ligament
7. The hepatoduodenal ligament
8. The Ligamentum Venosum



- Porta hepatis of the liver

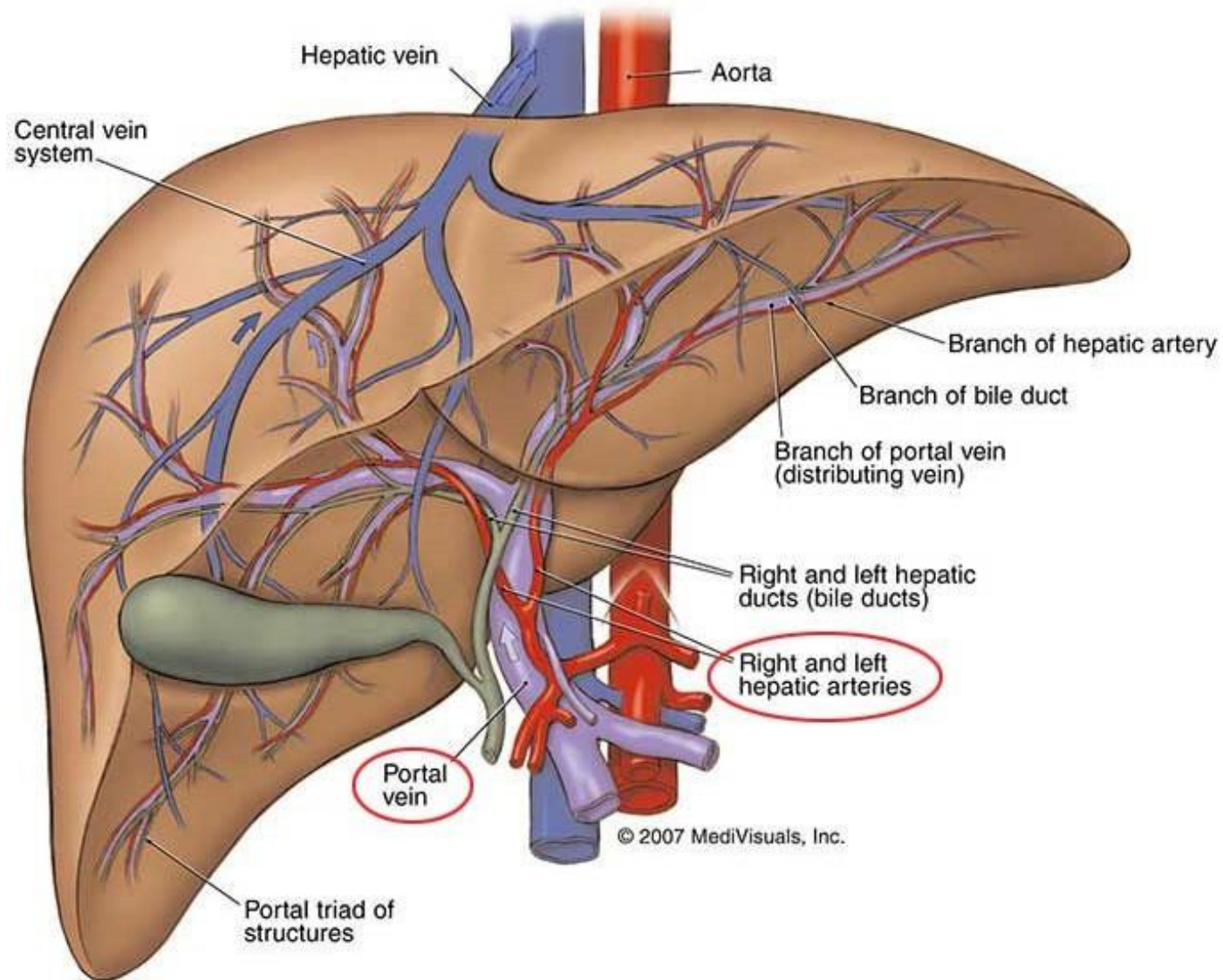


- Blood supply of the liver



# • Blood supply of the liver

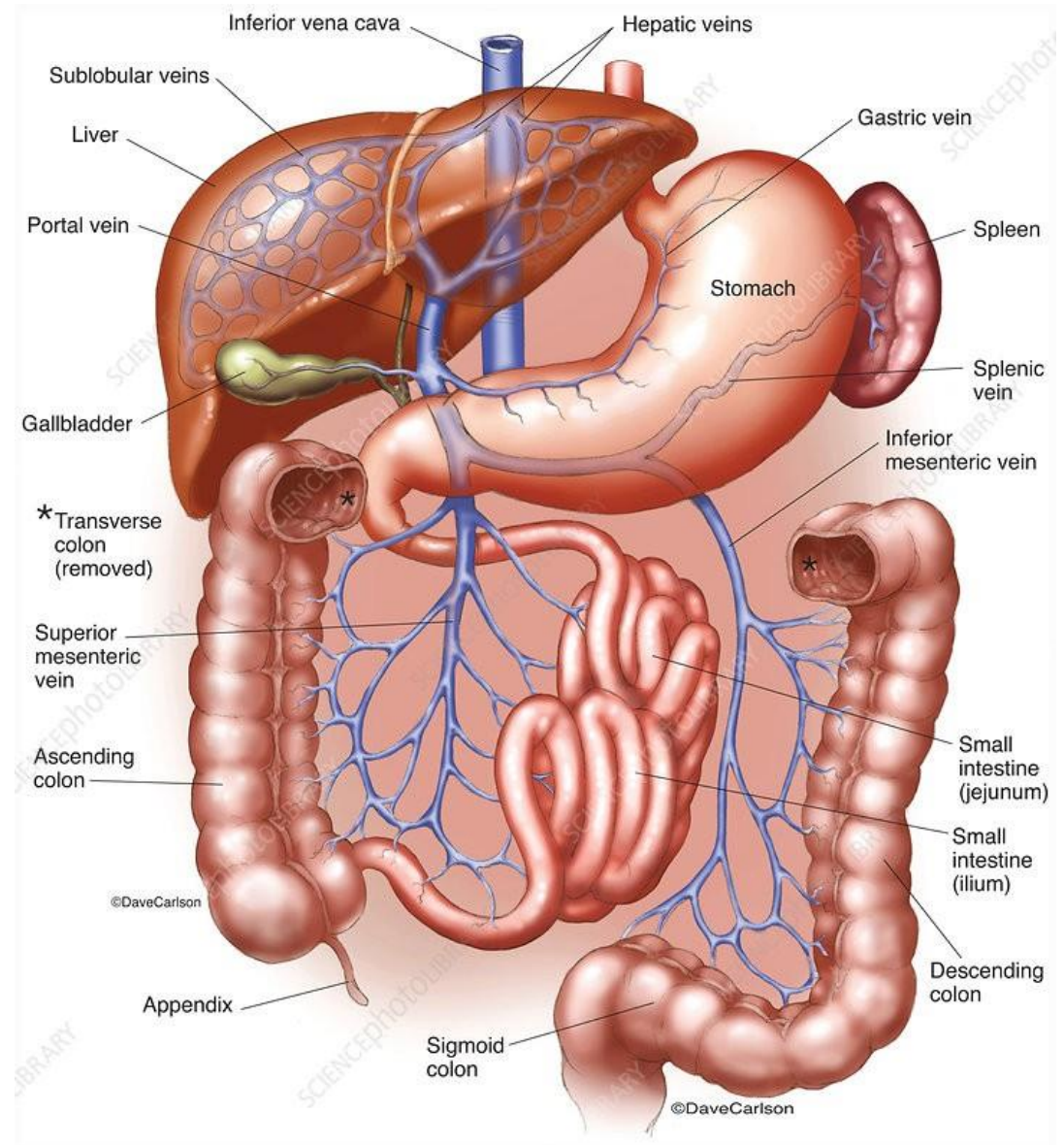
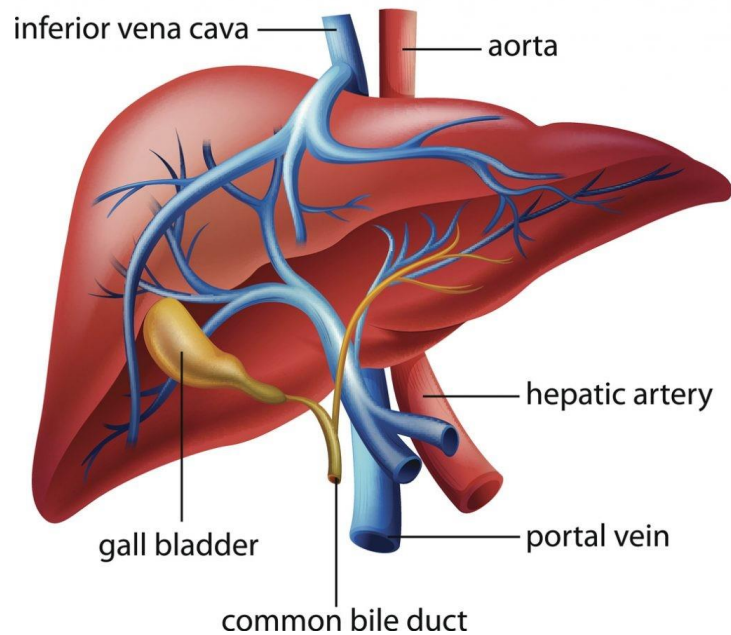
- Arterial supply



# • Blood supply of the liver

- Venous and portal drainage

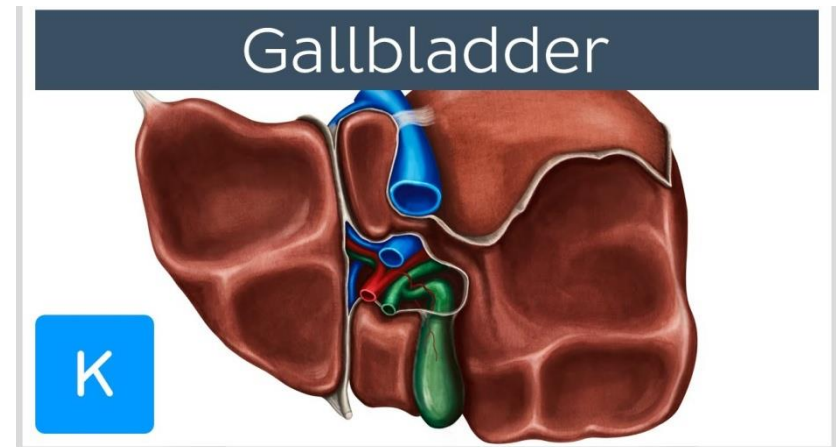
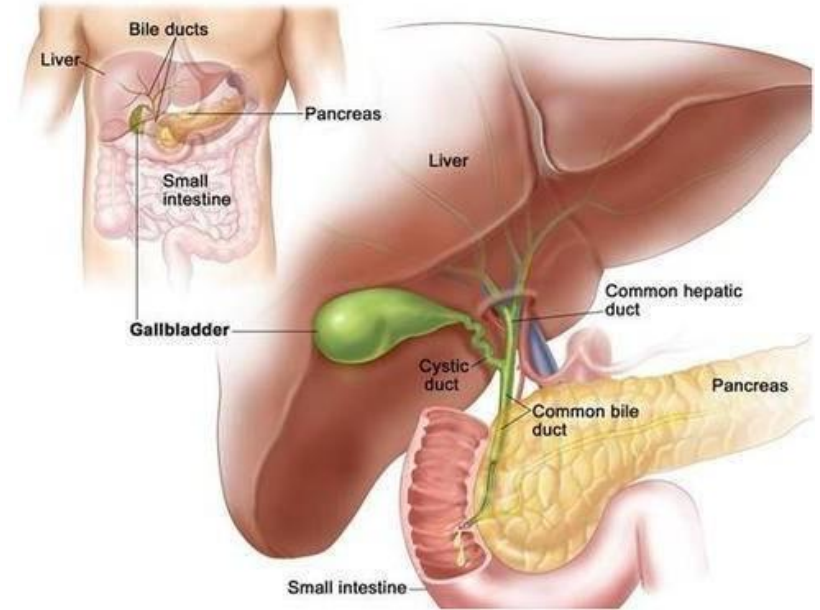
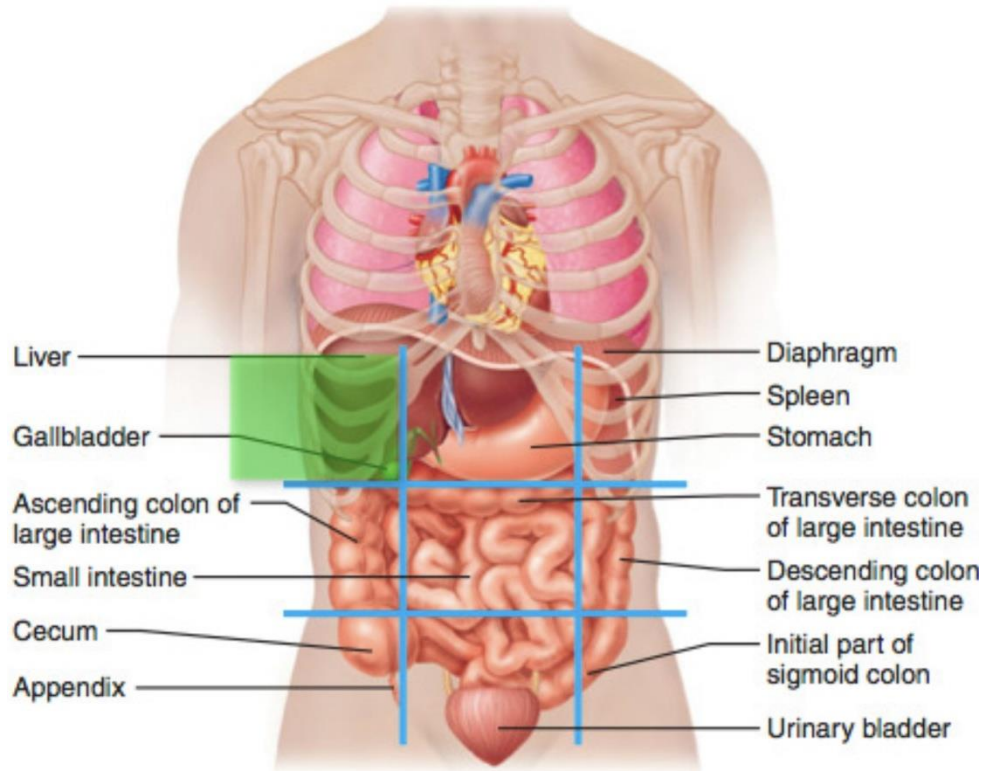
## Human Liver Anatomy



# ✦ Gallbladder

- The students should know and identify the :
  1. Site
  2. Structure Of Gallbladder
  3. Blood supply
  4. Common bile duct

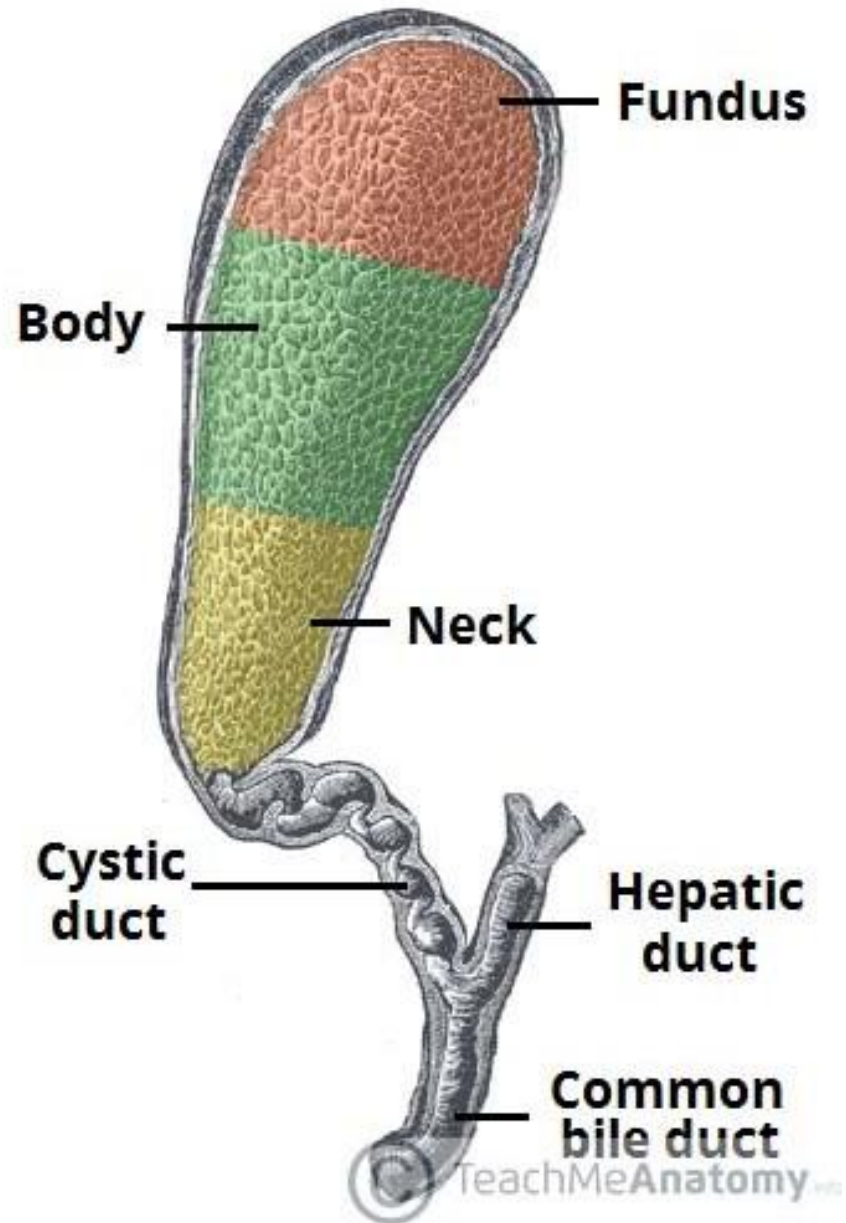
# • Site of the Gallbladder



- Between quadrate and right lobes

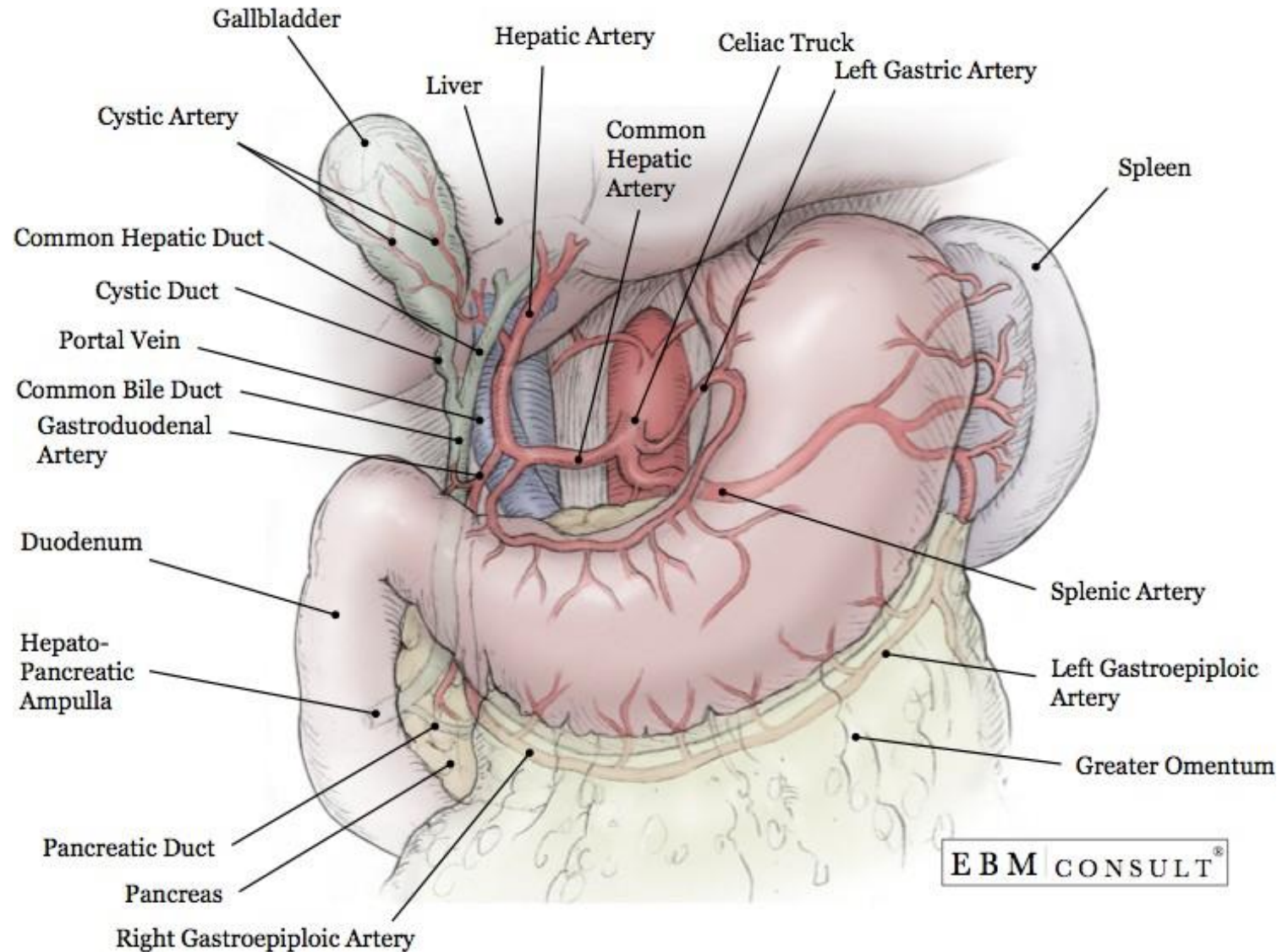


- **Structure Of Gallbladder**



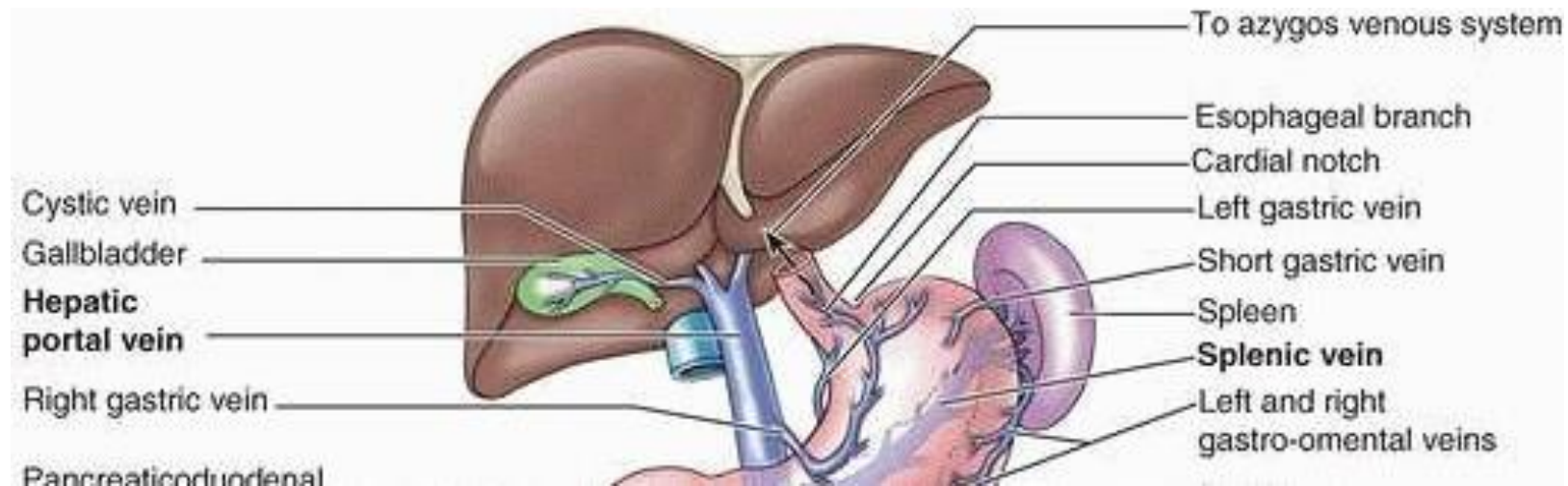
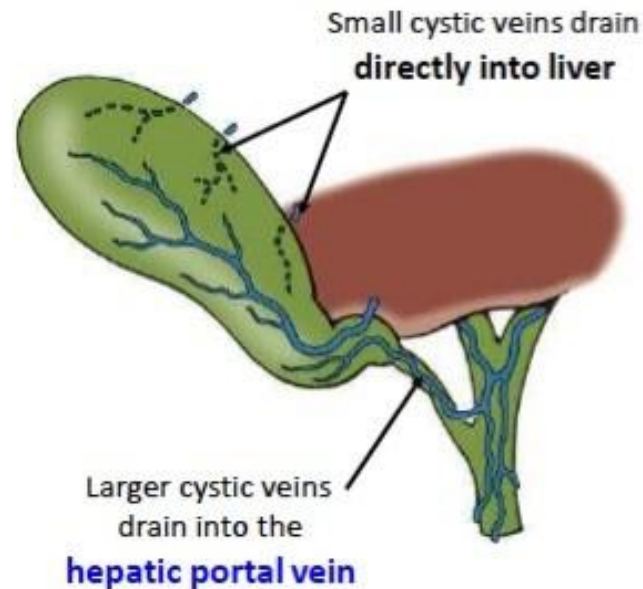
# • Blood supply of the Gallbladder

- Arterial supply



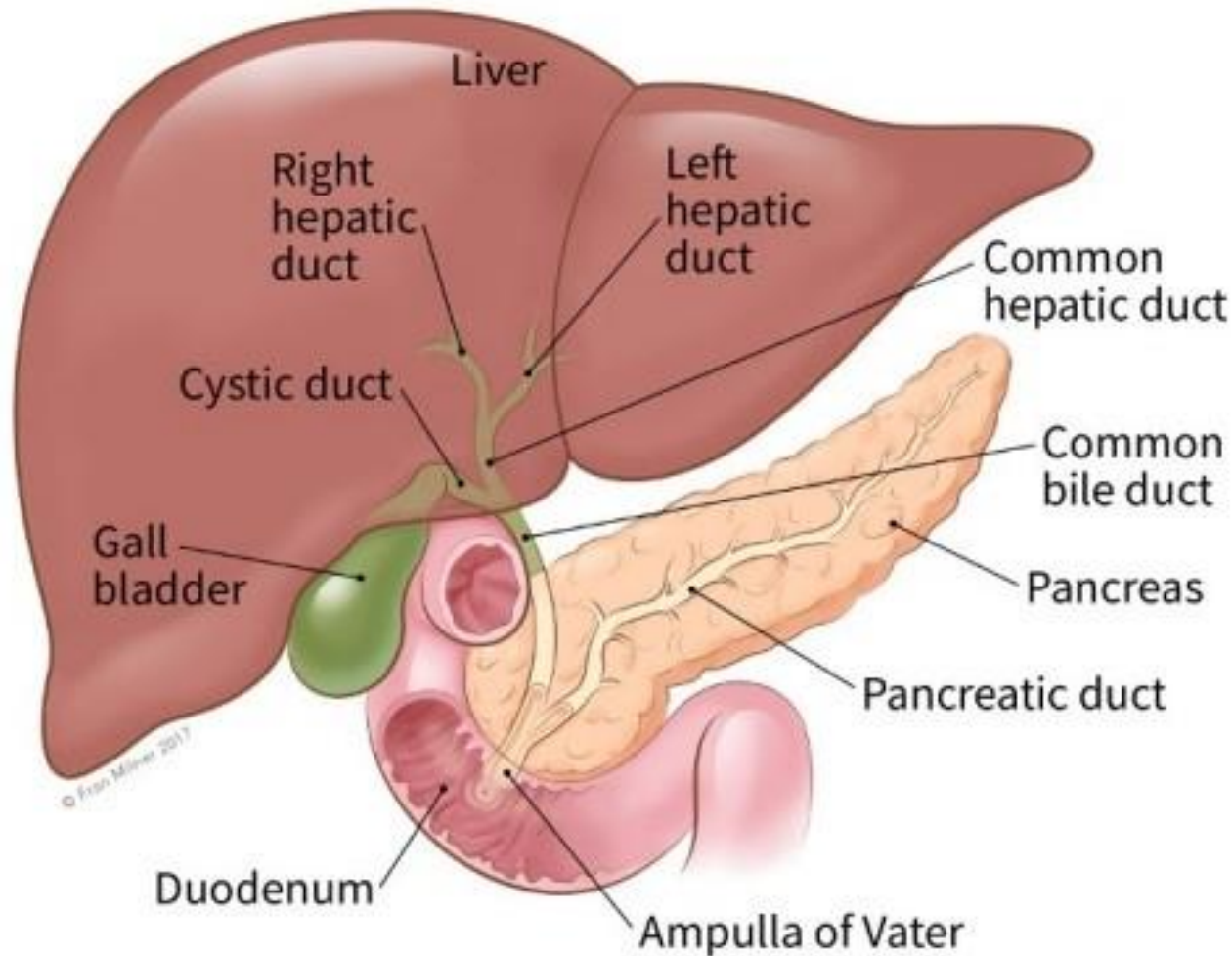
# • Blood supply of the Gallbladder

- Venous drainage



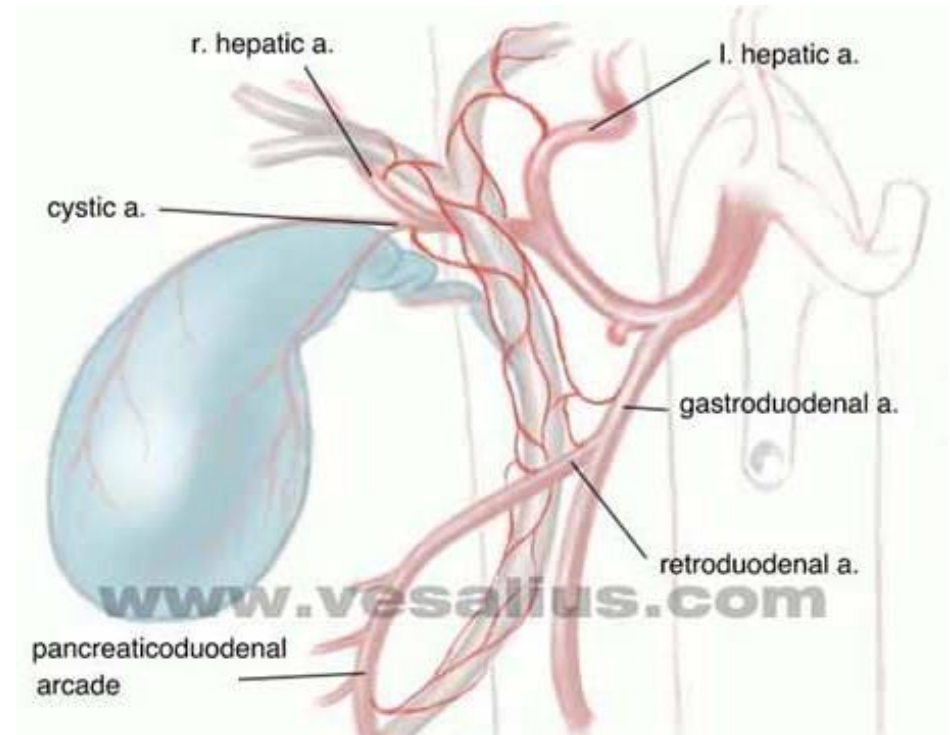
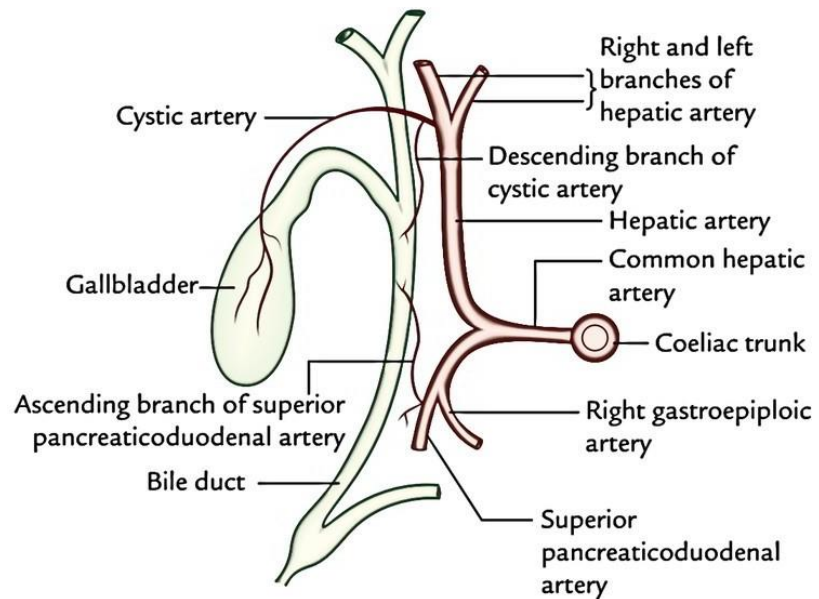
# • Common bile duct

- Relation of common bile duct
- End in the half second part of duodenum at ampulla of Vater



# • Common bile duct

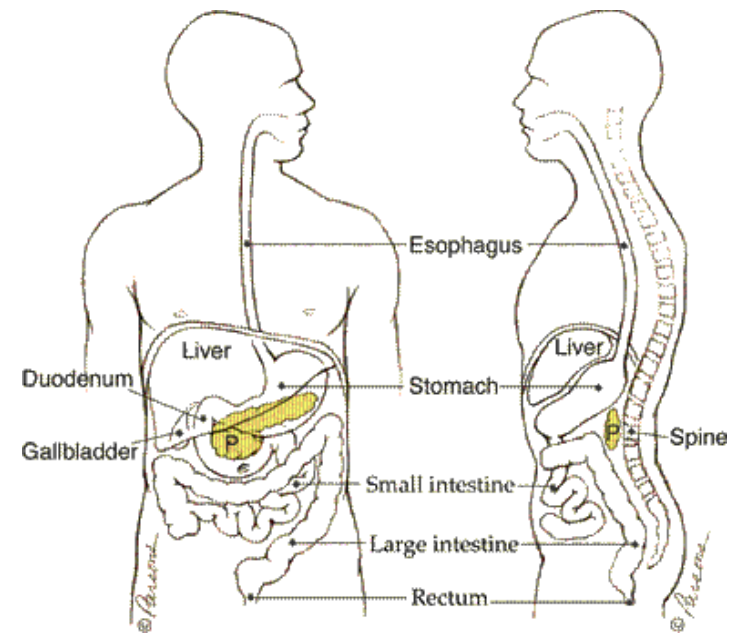
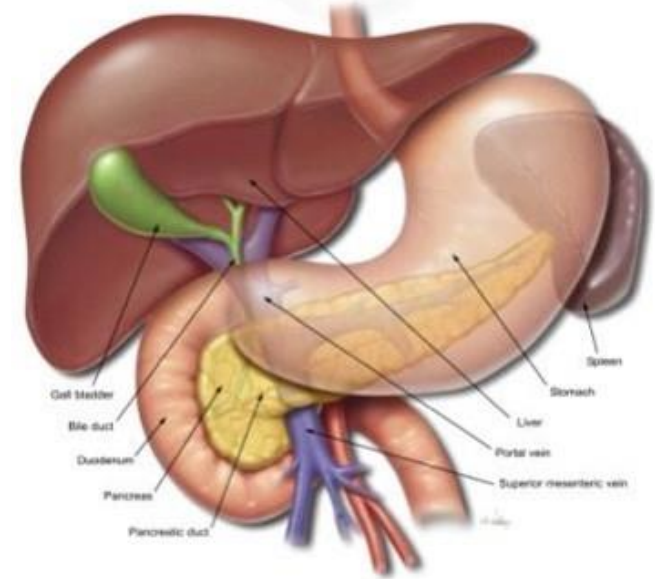
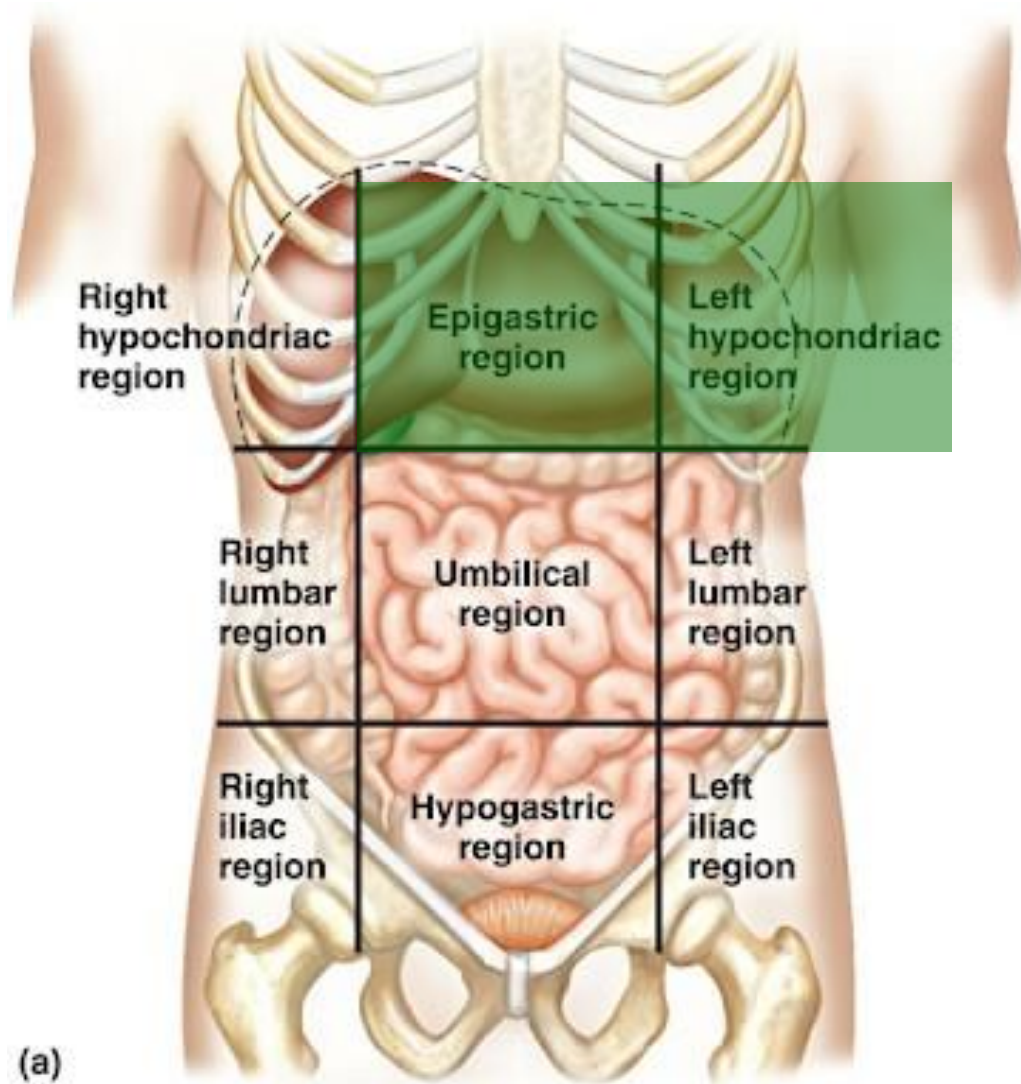
## • Arterial supply



# ✦ Pancreas

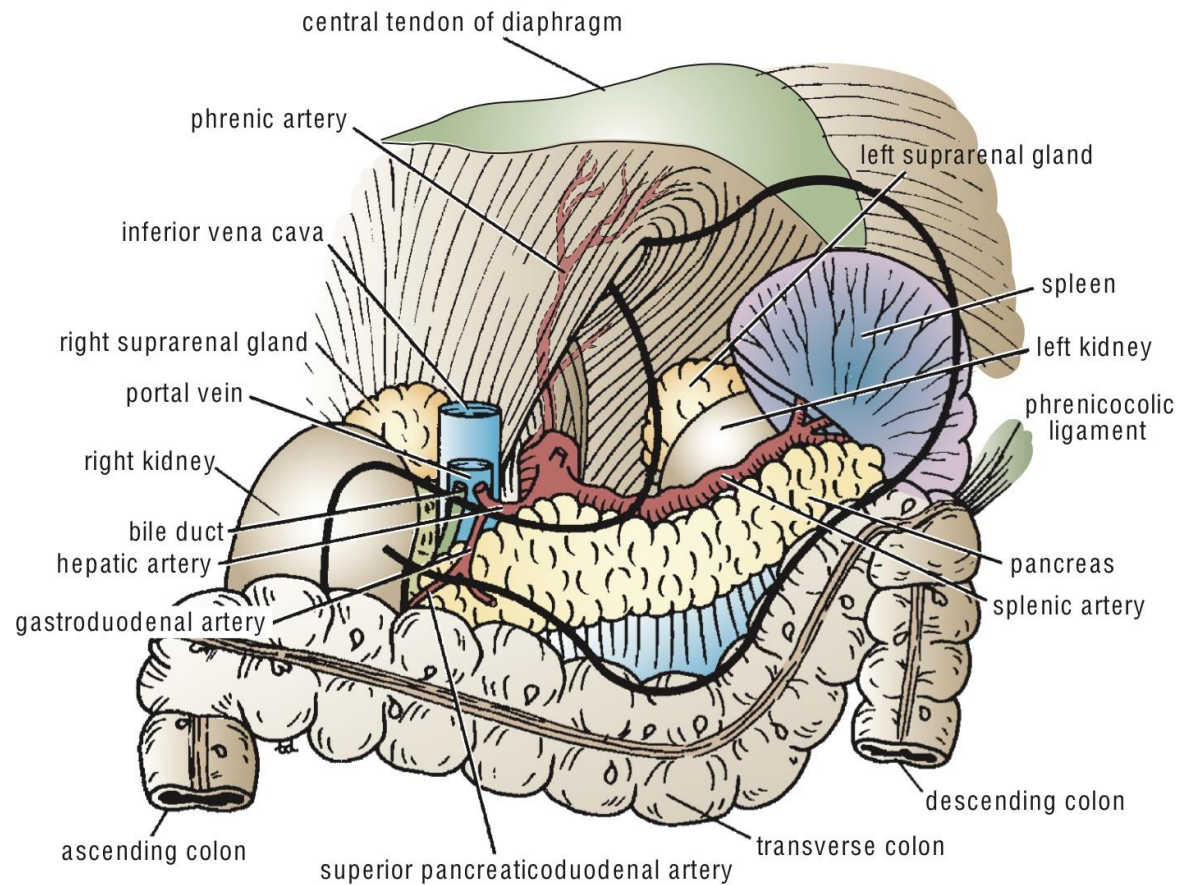
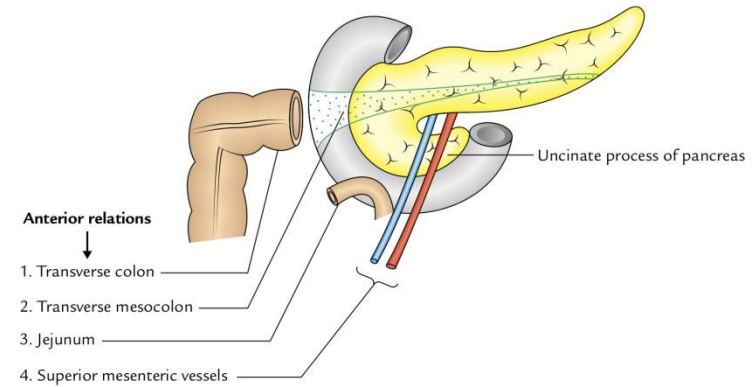
- The students should know and identify the :
  1. Site
  2. Relations
  3. parts of the Pancreas
  4. Pancreatic ducts
  5. Blood supply

# • Site of the Pancreas



# • Relations of the Pancreas

- Anterior relation:
  1. Transverse colon
  2. Transvers mesocolon
  3. Lesser sac
  4. Stomach

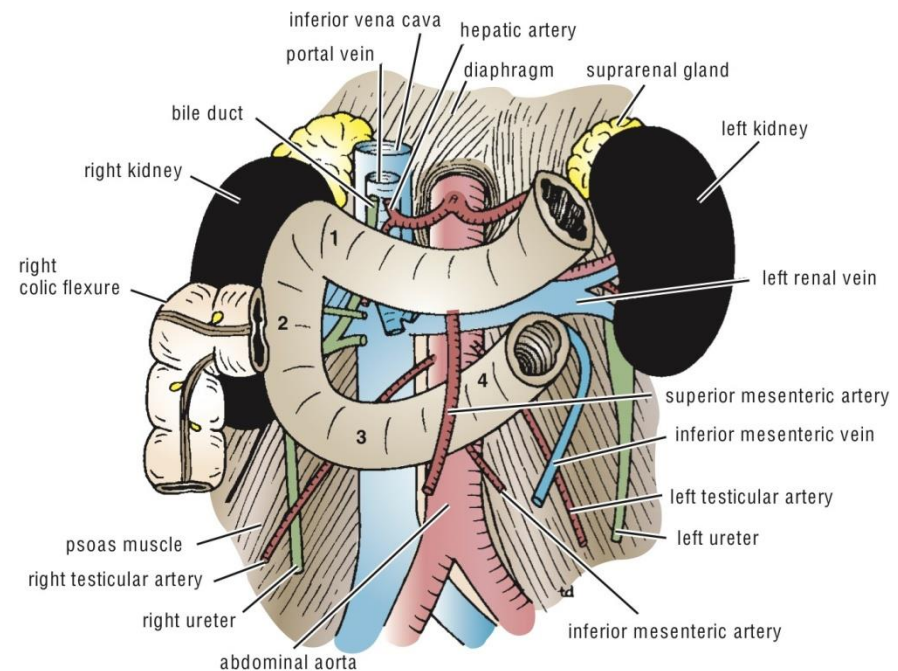
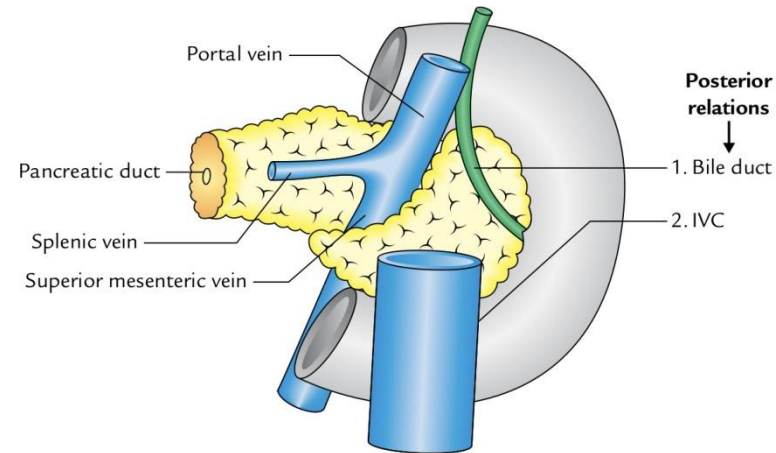




# • Relations of the Pancreas

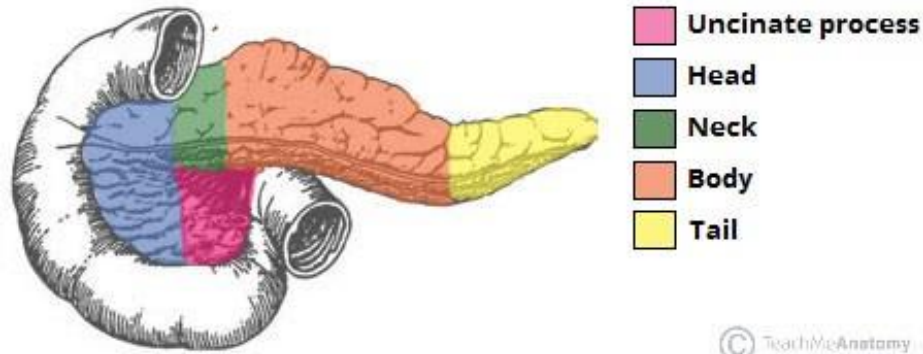
## • Posterior relation

1. Bile duct
2. Portal vein
3. Splenic vein
4. IVC
5. Aorta
6. origin of Sup.mesentric.a
7. Lt.Psoas muscle
8. Lt.Suuprarenal gland
9. Left kidney
10. Hilum of the spleen

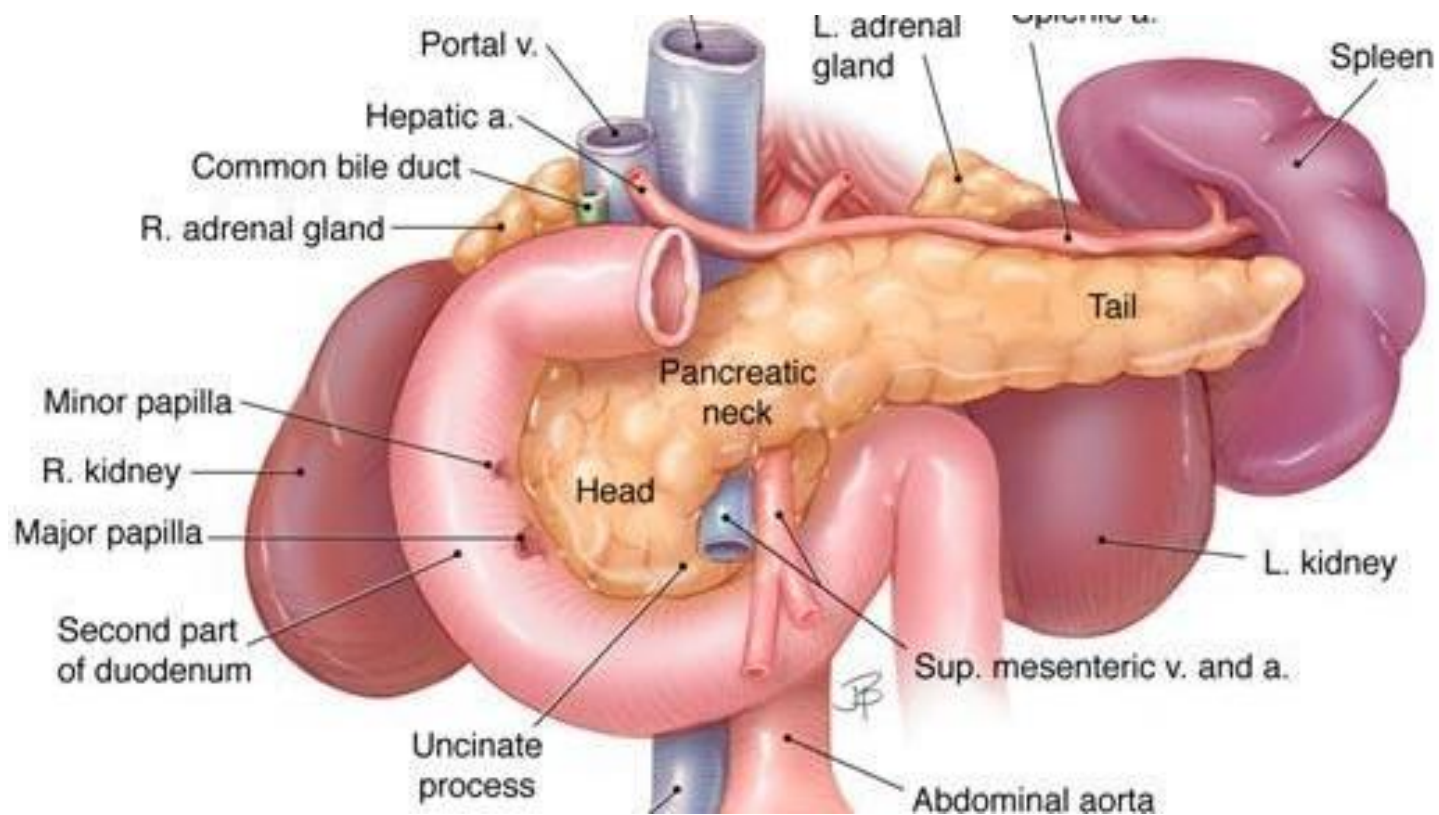


Posterior relations of the duodenum and the pancreas

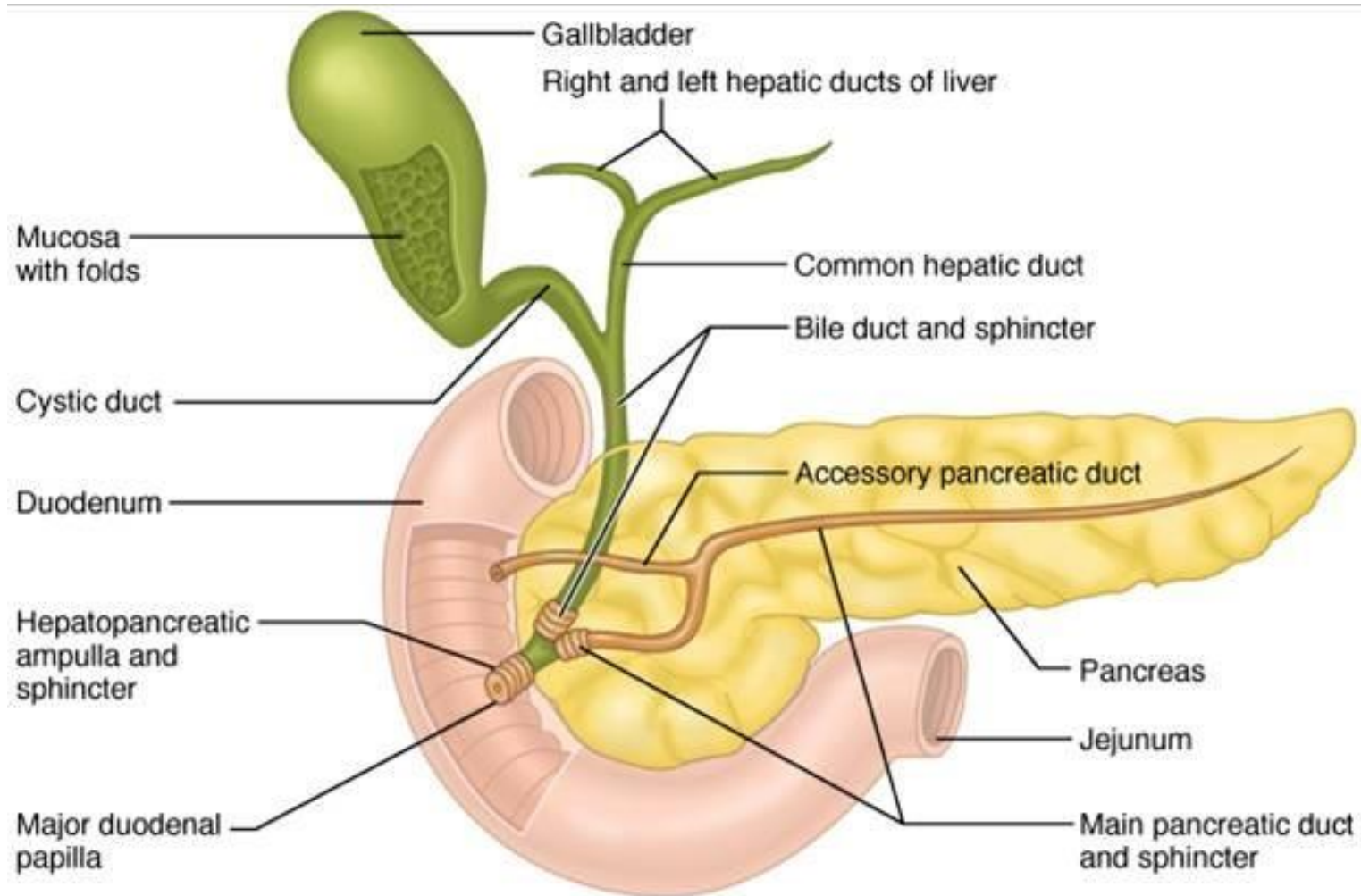
# • Parts of the Pancreas



© TeachMeAnatomy

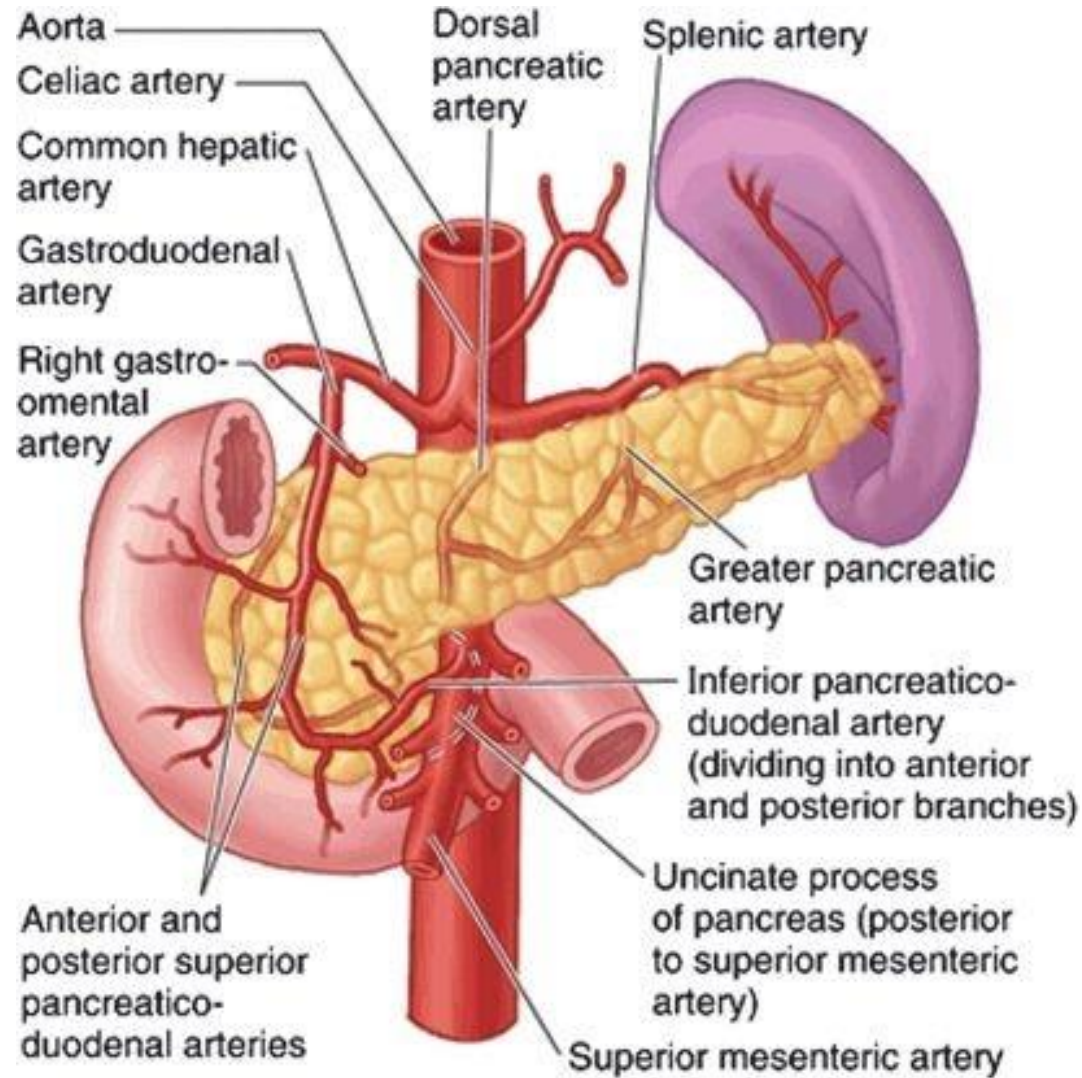


# • Pancreatic ducts



# • Blood supply of the Pancreas

- Arterial supply

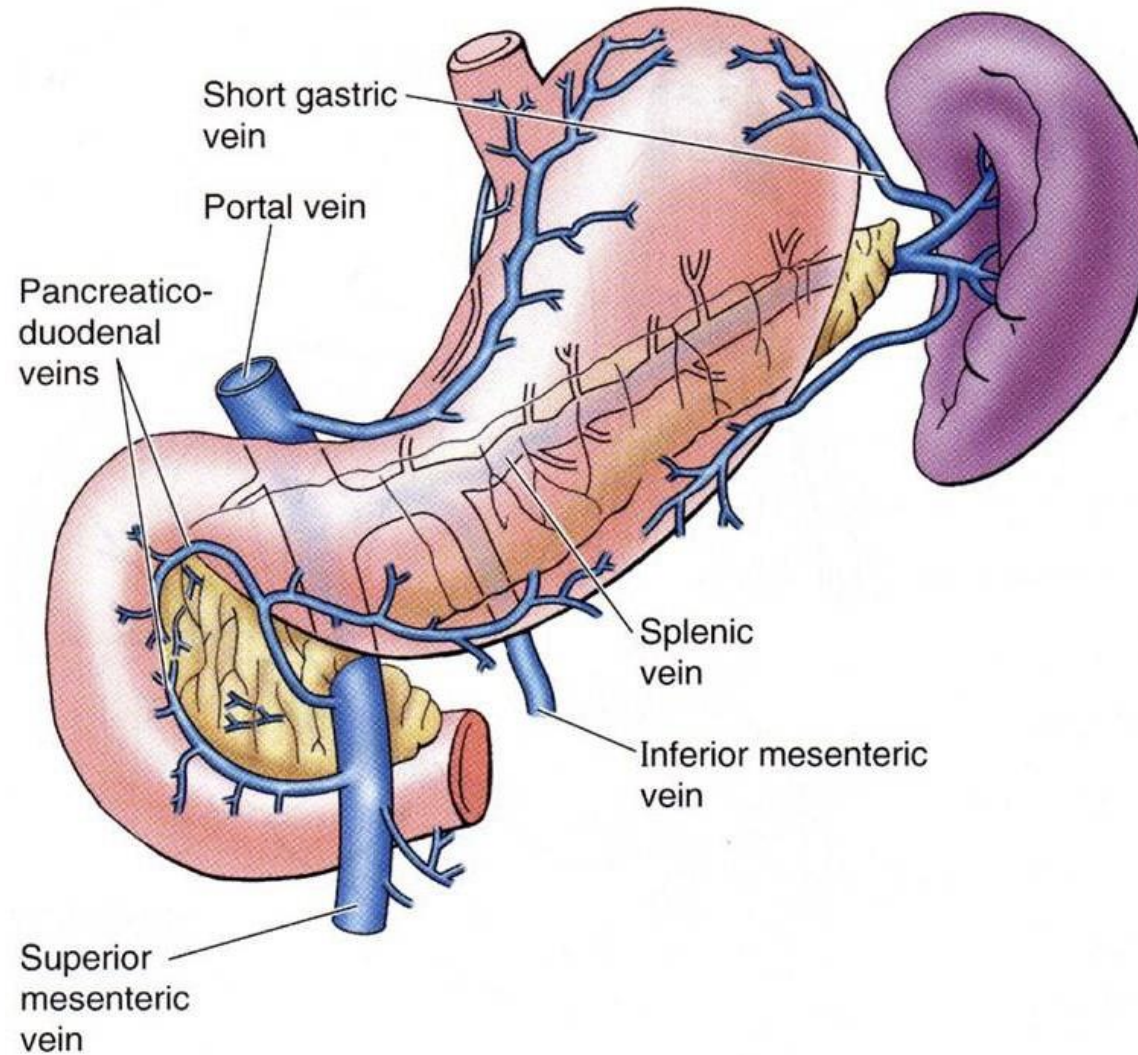


**Arteries**

**Anterior view**

# • Blood supply of the Pancreas

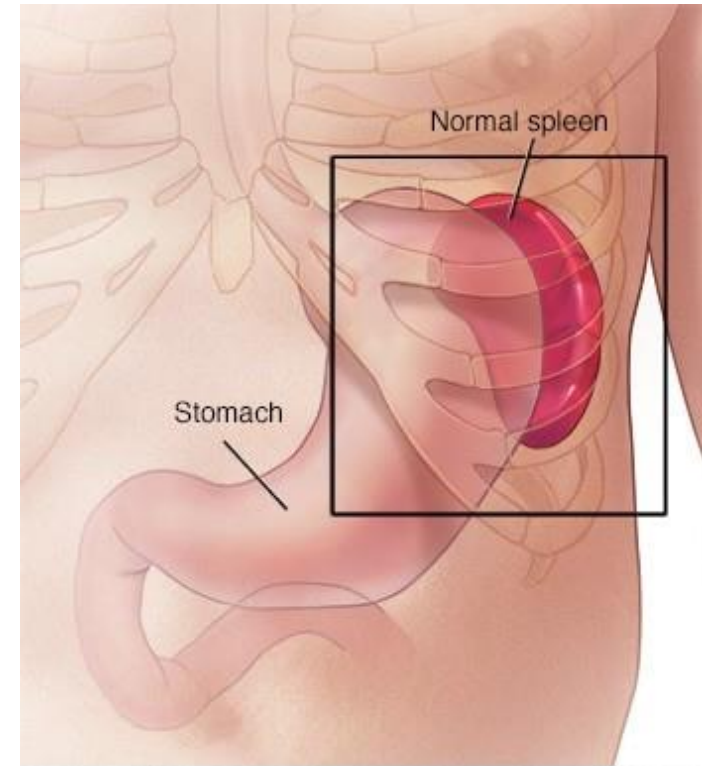
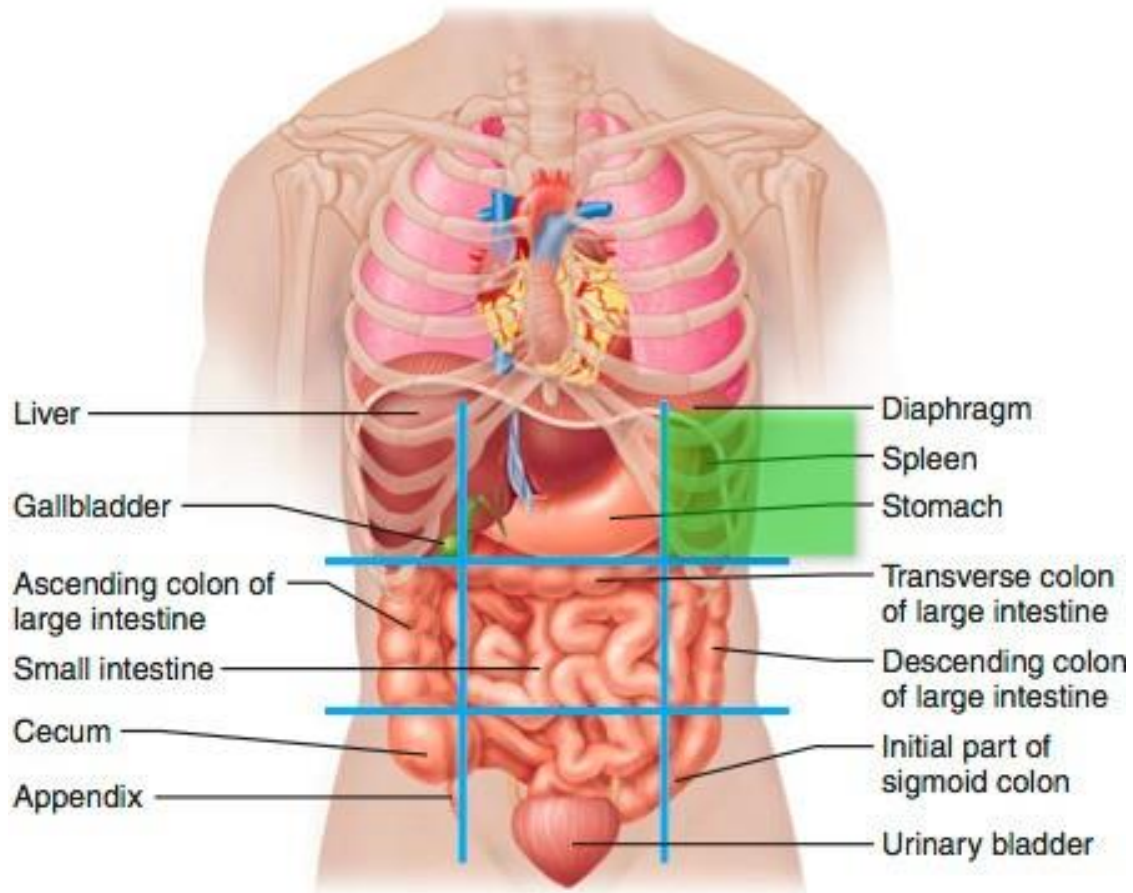
- Venous drainage



# ✦ Spleen

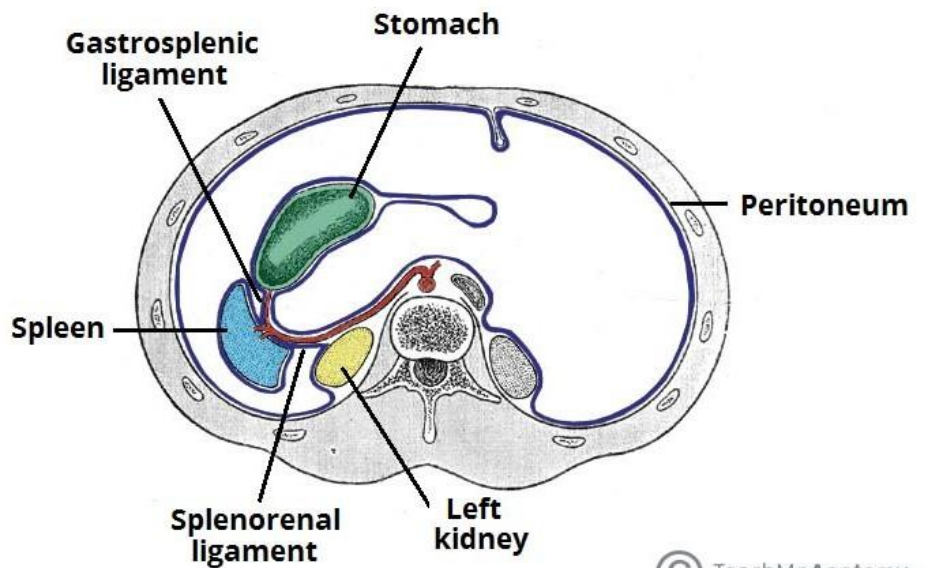
- The students should know and identify the :
  1. Site
  2. Peritoneal Relations
  3. Surfaces of the Spleen
  4. Borders of spleen
  5. Blood supply

# • Site of the Spleen



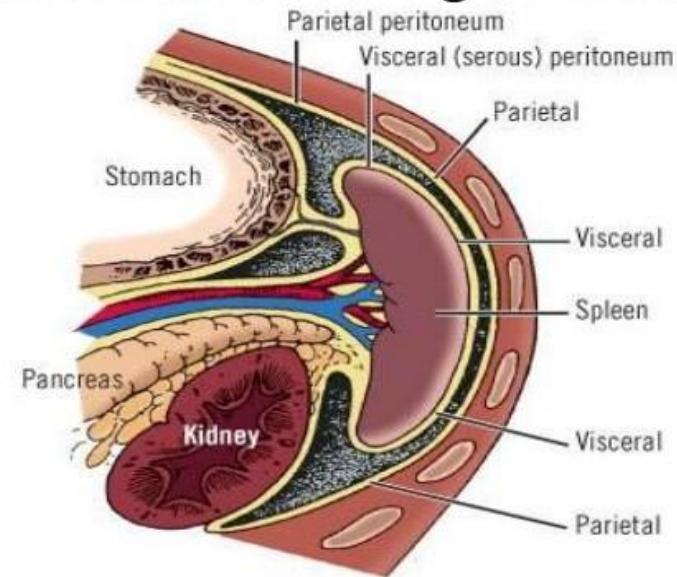
# • Peritoneal Relations of the Spleen

- intraperitoneal



© TeachMeAnatomy.com

## Peritoneal covering of the spleen

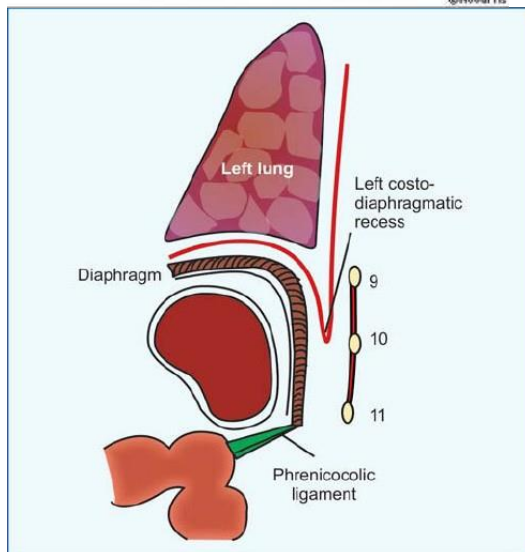
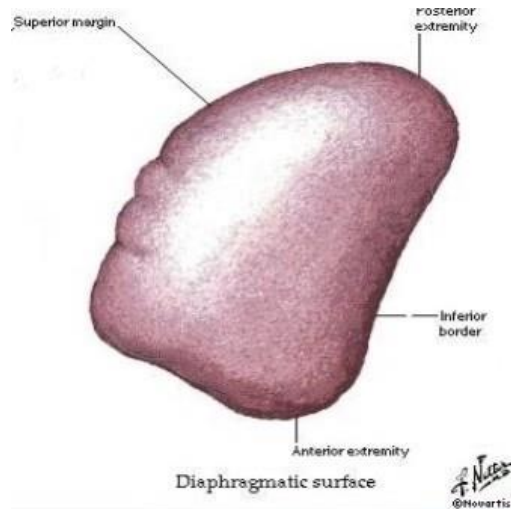


Copyright ©2006 by The McGraw-Hill Companies, Inc.  
All rights reserved.

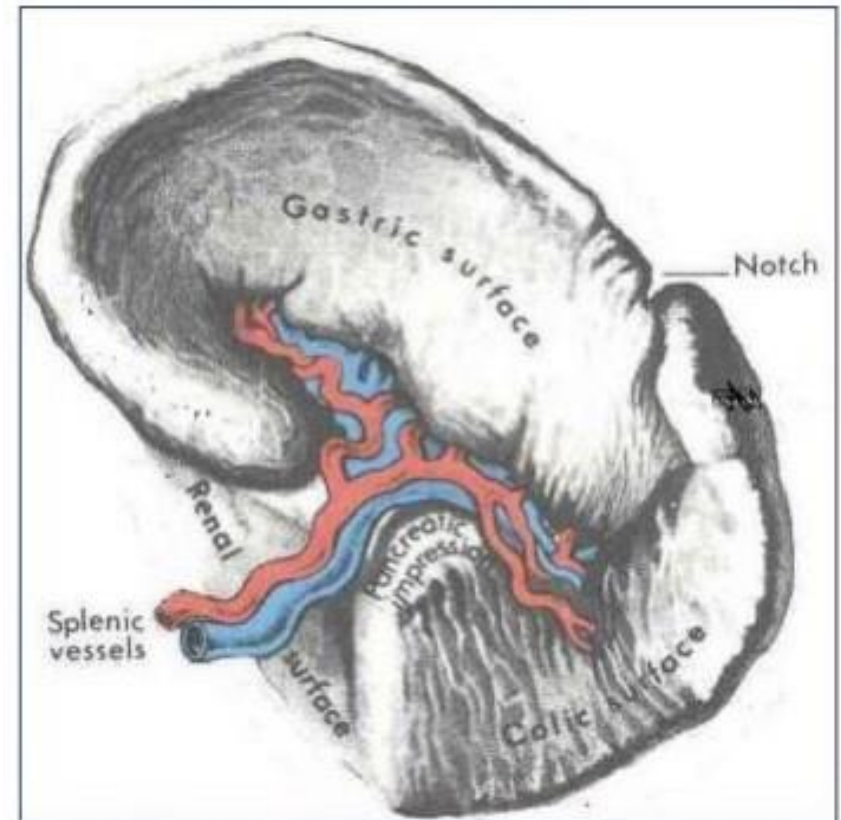


# • Surfaces of the Spleen

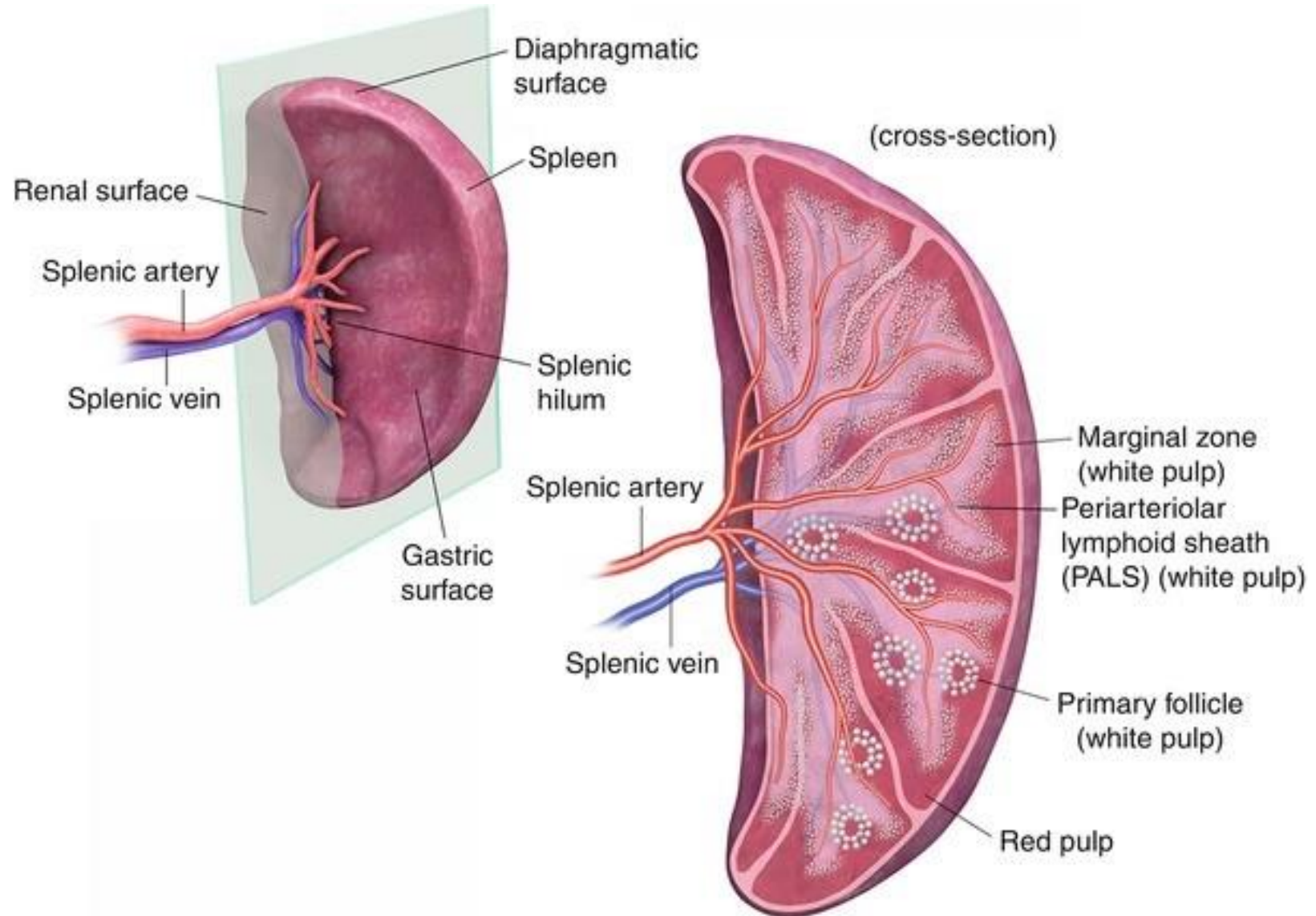
- Diaphragmatic surface:
  - has convex, smooth surface
  - Diaphragm separates it from (Pleura & lung - Ribs 9,10 ,11 )



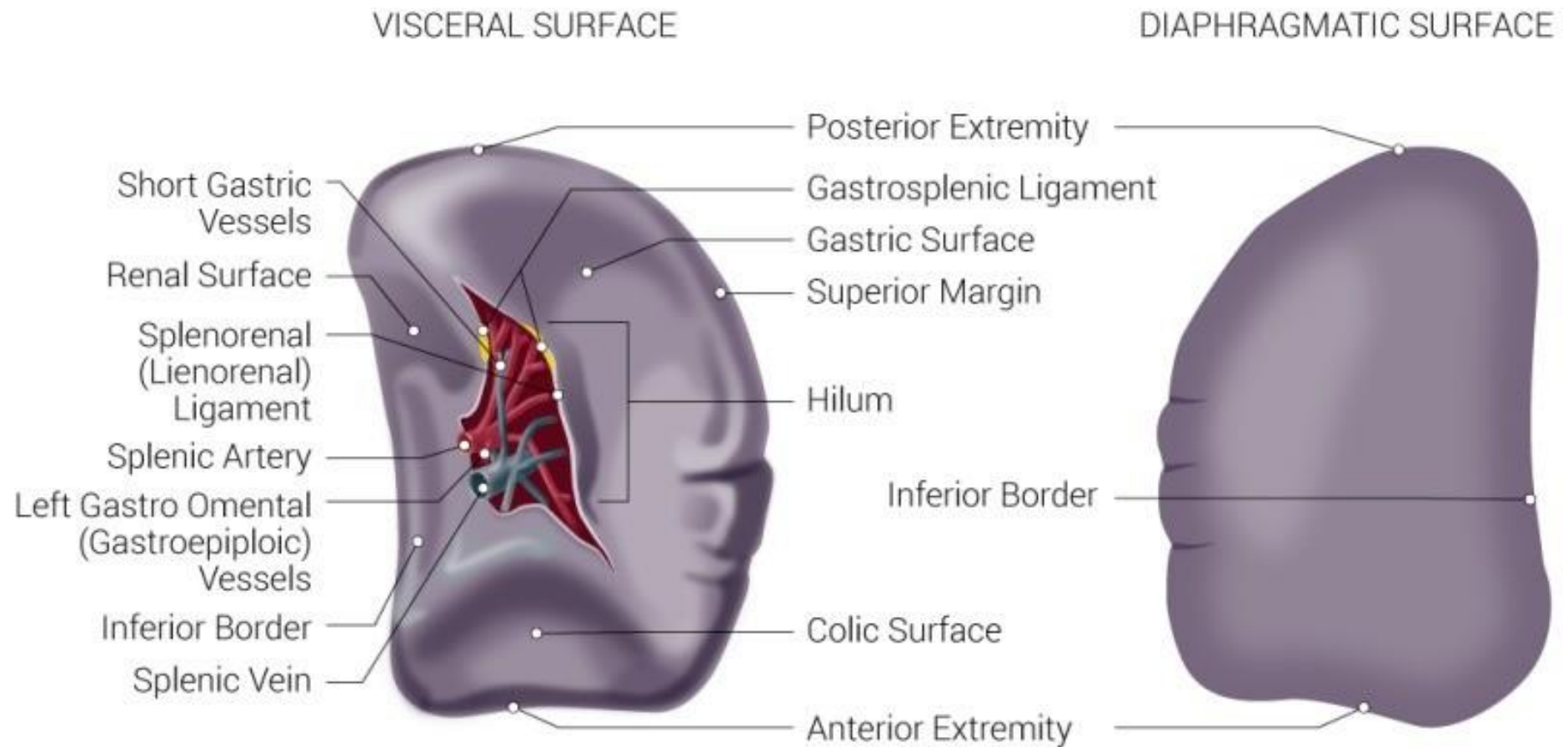
- Visceral surface:
  - has (Colic surface/Pancreatic surface)



# • Hilum of spleen

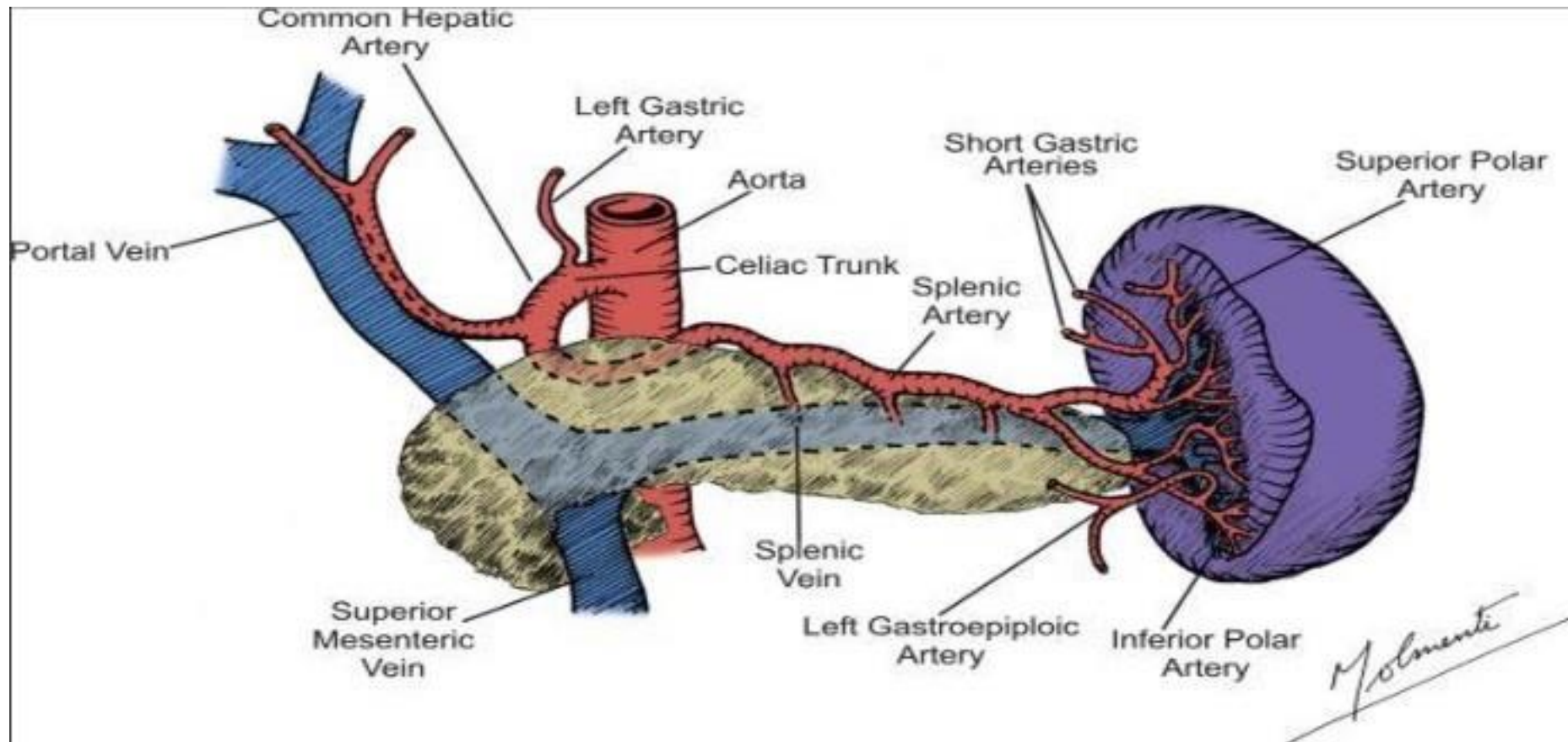


# • Borders of the spleen



# • Blood supply of the spleen

- Arterial supply



# • Blood supply of the spleen

- Venous drainage

