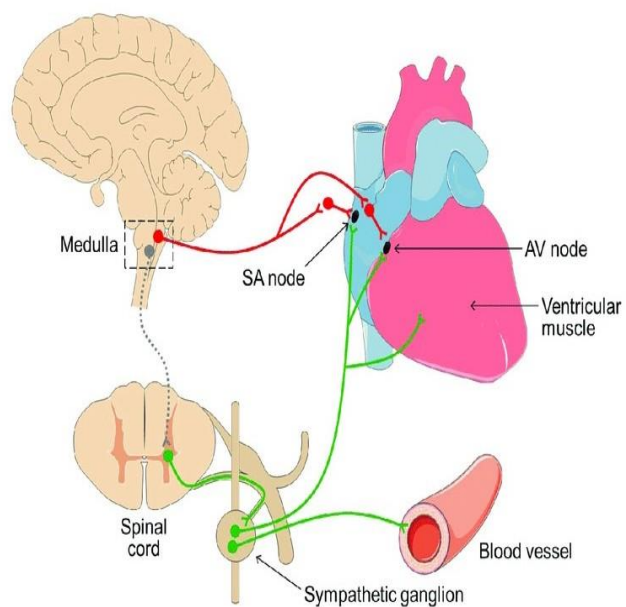

Heart Innervation and surface anatomy

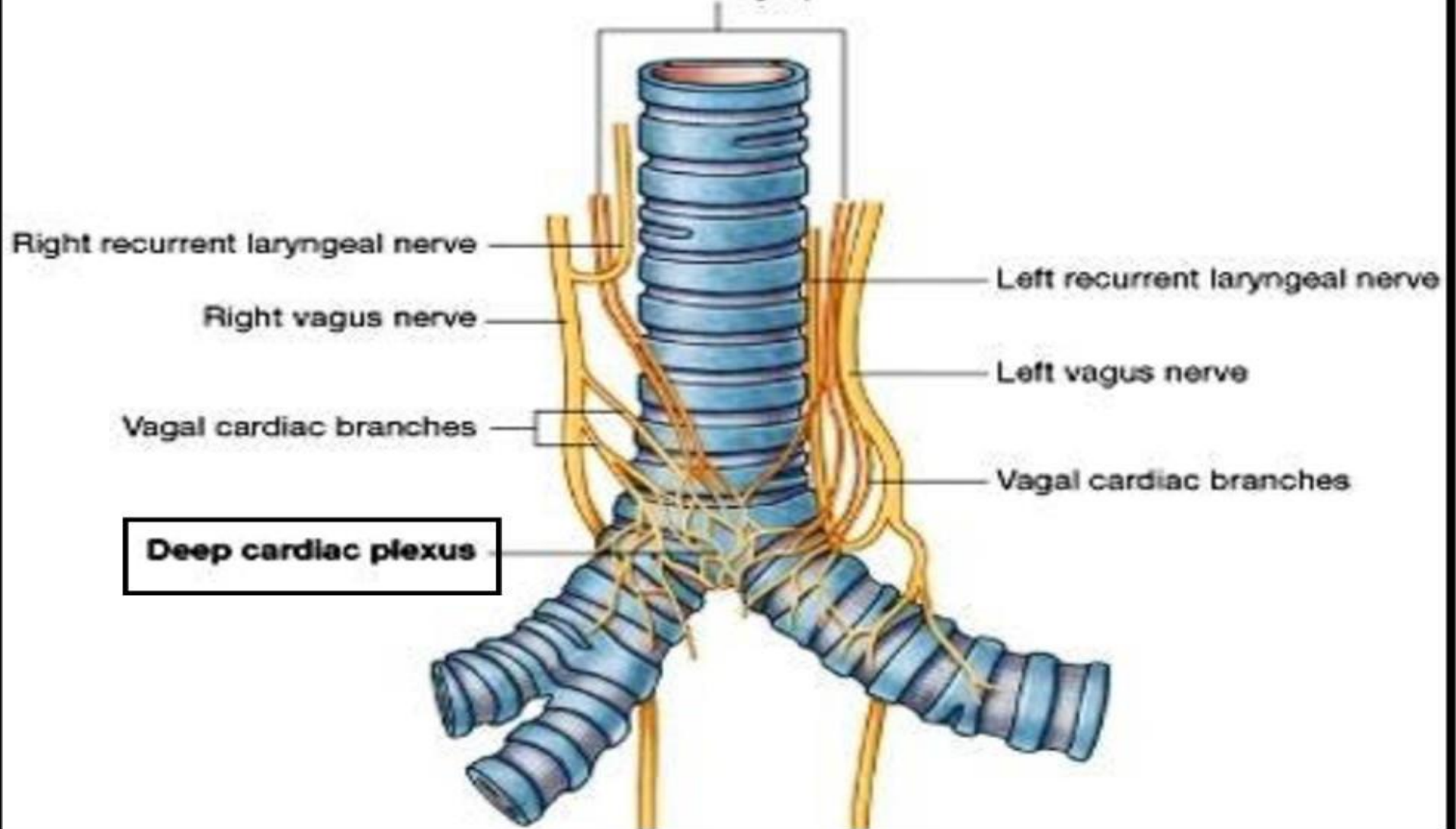
DR. AHMED SALMAN

Associate professor of anatomy & embryology

Heart Innervation

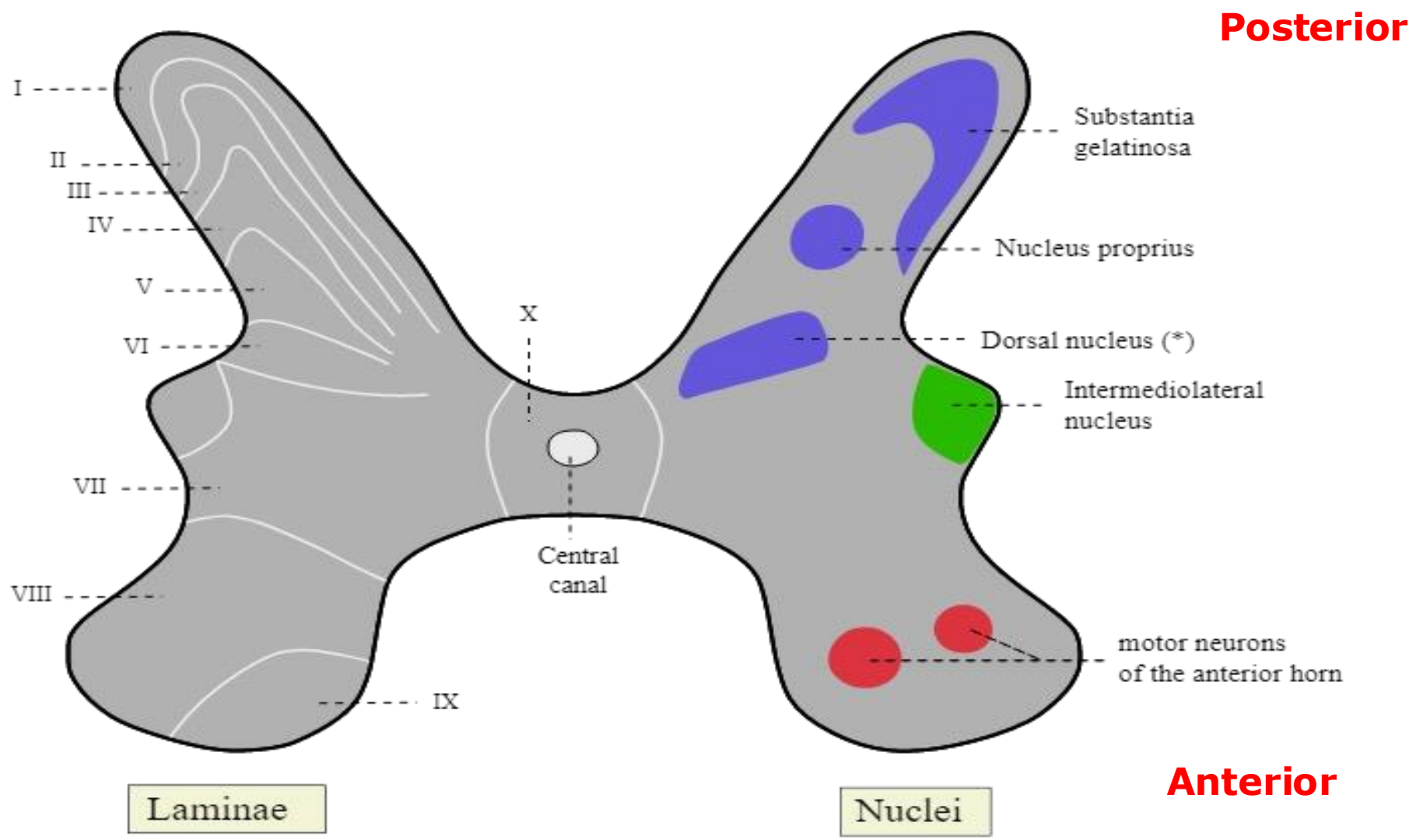
- ❖ The heart is supplied by autonomic nervous system through cardiac plexus
- ❖ The cardiac plexus is divided into superficial and deep parts
- ❖ The cardiac plexus is located the on anterior surface of the bifurcation of the trachea
- ❖ It is formed of both sympathetic and parasympathetic fibers as well as visceral afferent fibers

Cardiac nerves from sympathetic trunk

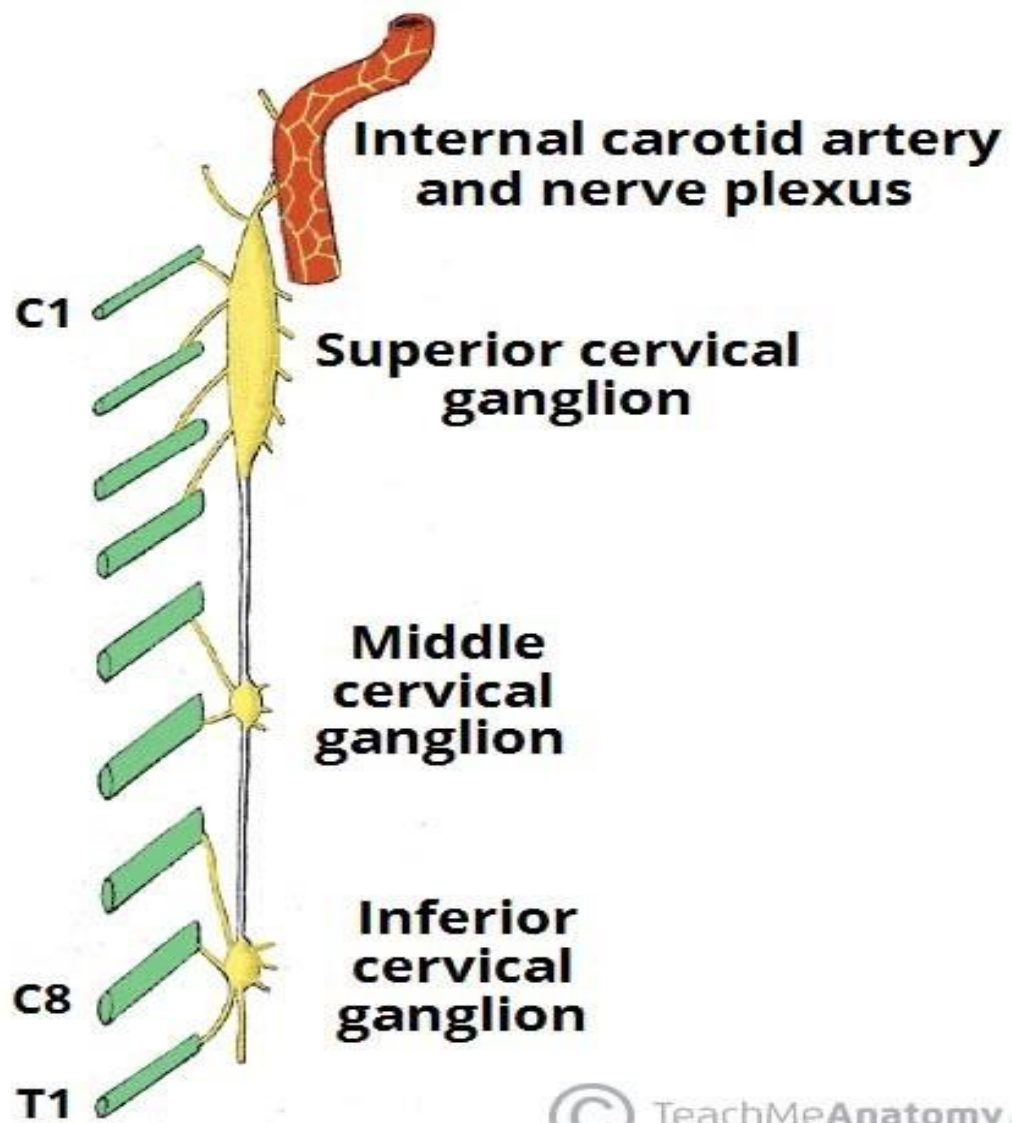


The sympathetic supply

- Preganglionic fibers from cell bodies in the intermediolateral cell columns (IMLs) of the superior five or six thoracic segments of the spinal cord
- Preganglionic fibers relay at cervical and superior thoracic ganglia of the sympathetic trunks.
- Postganglionic fibers traverse cardio **pulmonary splanchnic nerves** and the cardiac plexus to end in the SA and AV nodes
- Sympathetic stimulation causes increased heart rate, impulse conduction, force of contraction and increased blood flow through the coronary vessels to support the increased activity.



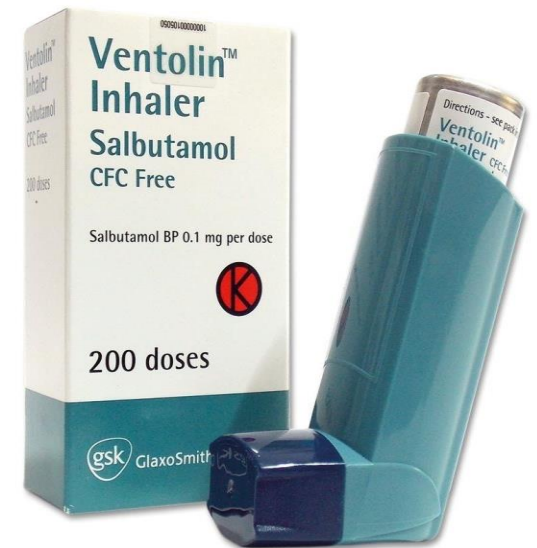* Posterior thoracic nucleus or Column of Clarke





Most adrenergic receptors on coronary blood vessels are b2-receptors, which, when activated, cause relaxation (or perhaps inhibition) of vascular smooth muscle and, therefore, dilation of the arteries (Wilson-Pauwels et al., 1997).

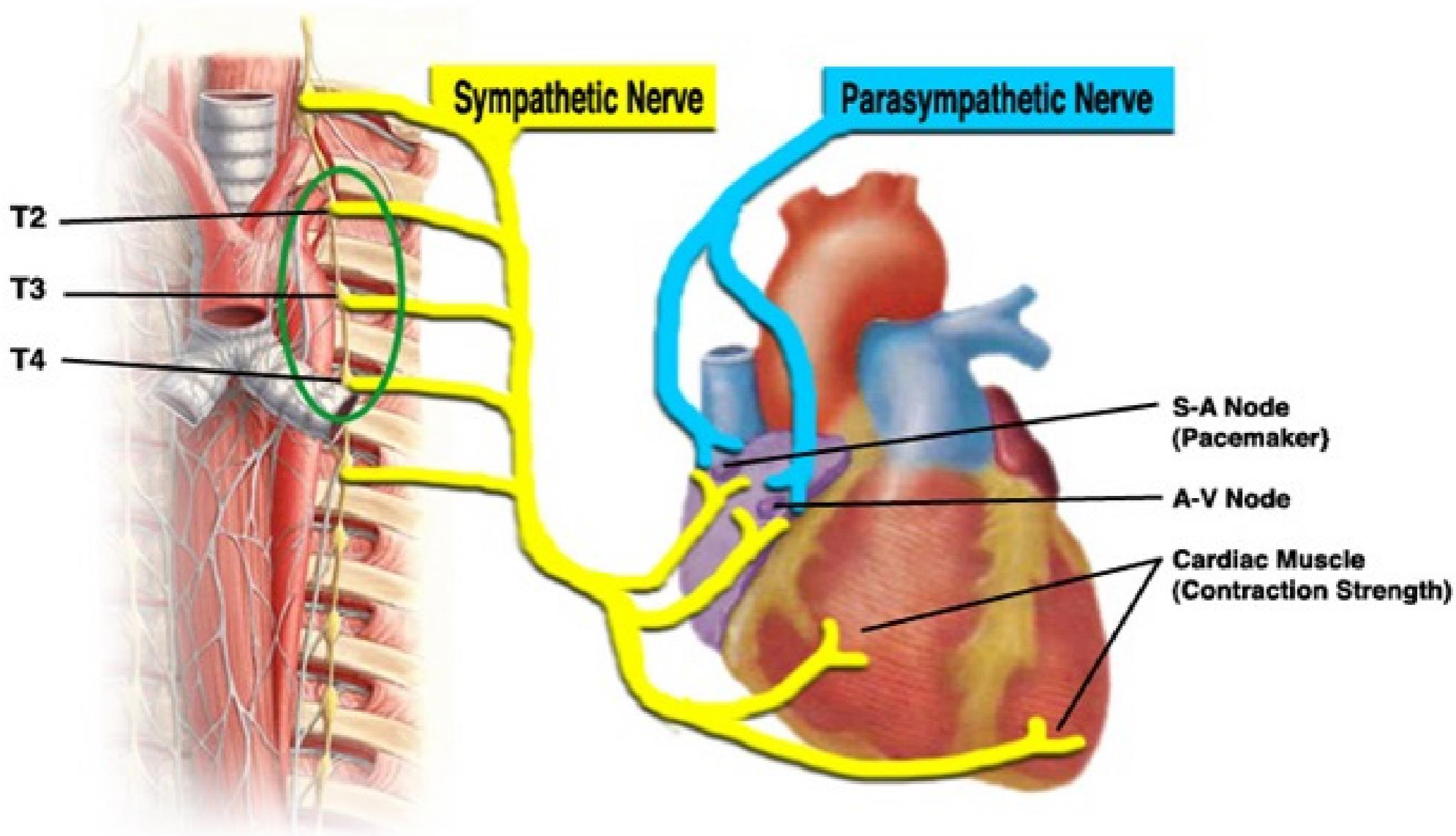
This supplies more oxygen and nutrients to the myocardium during periods of increased activity



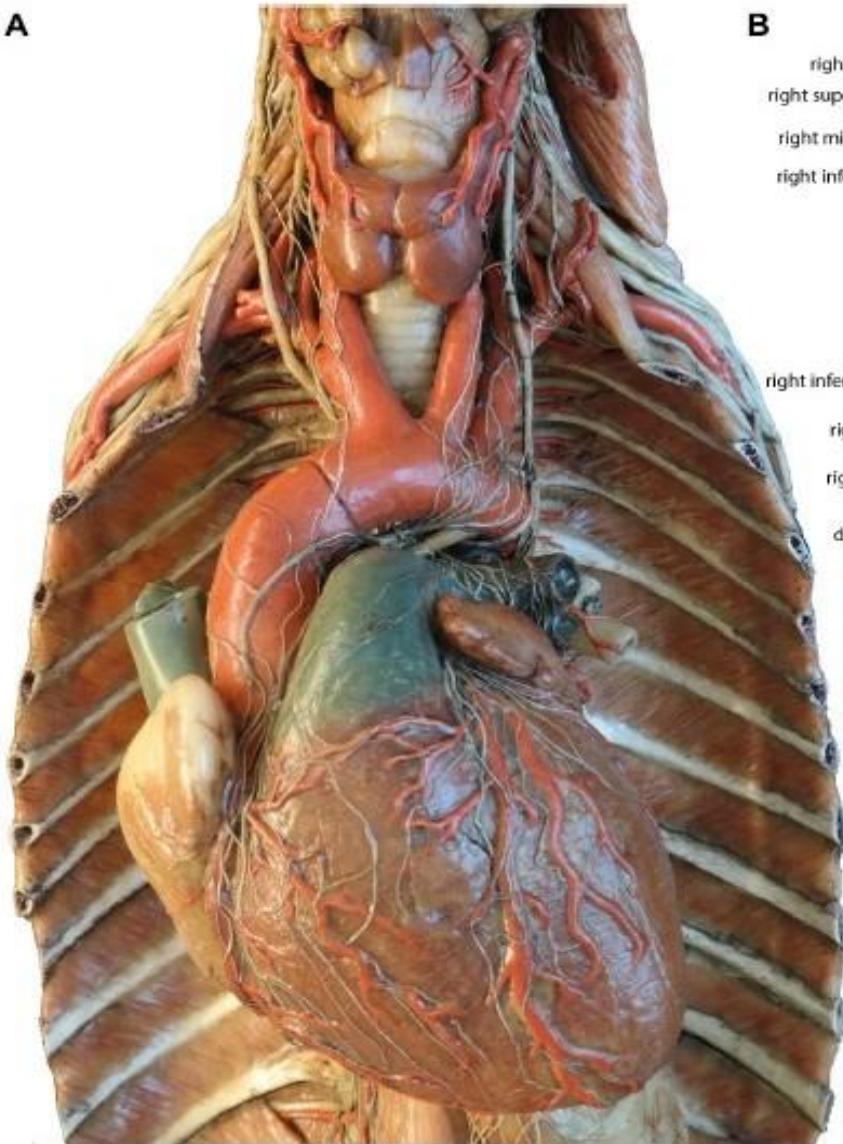
The parasympathetic supply

- Preganglionic fibers from the vagus nerves relay in cardiac plexus and nerve cells in atrial wall and interatrial septum near the SA and AV nodes and along the coronary arteries
- Parasympathetic stimulation slows the heart rate, reduces the force of the contraction, and constricts the coronary arteries, saving energy between periods of increased demand.

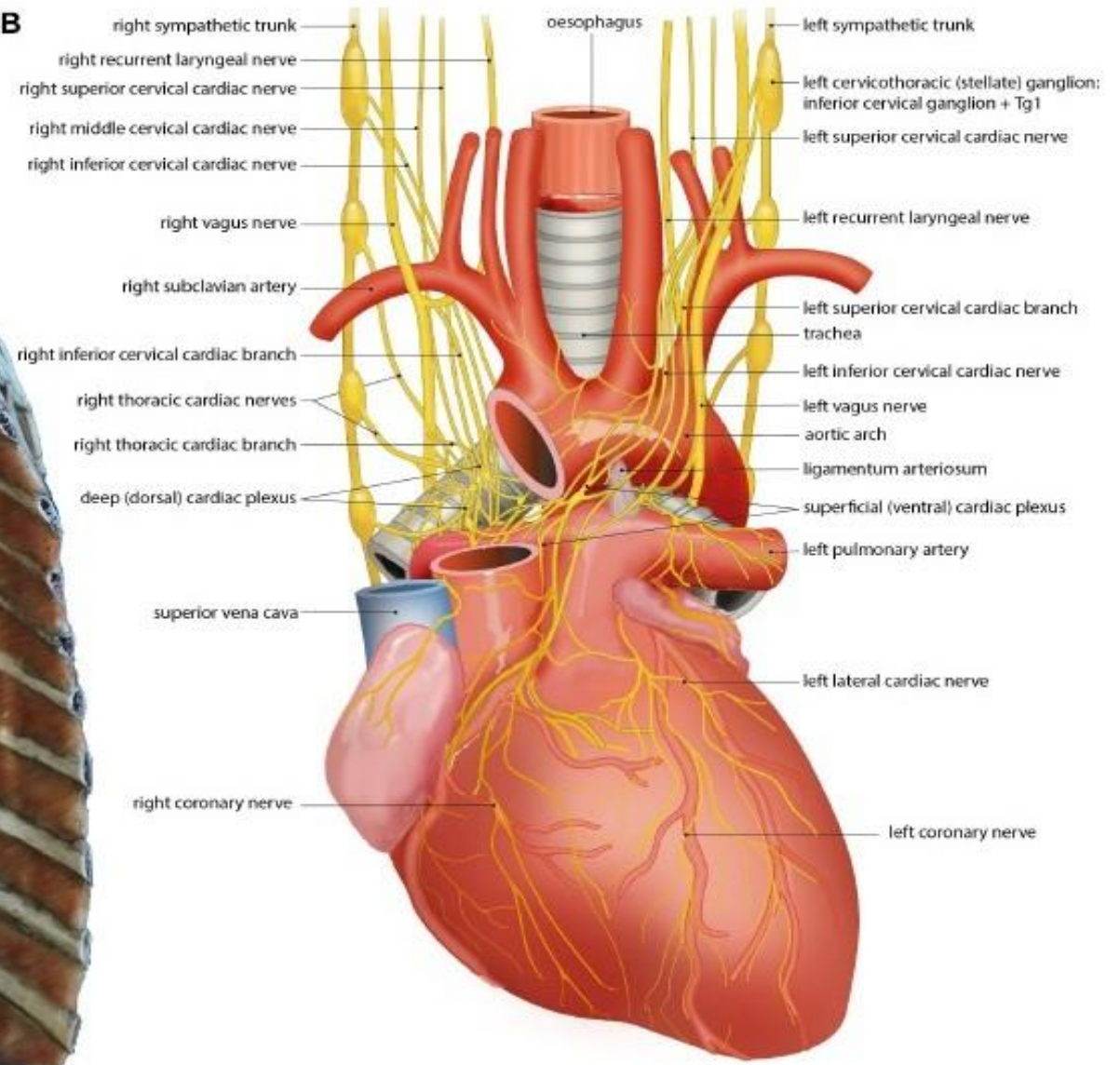




A



B

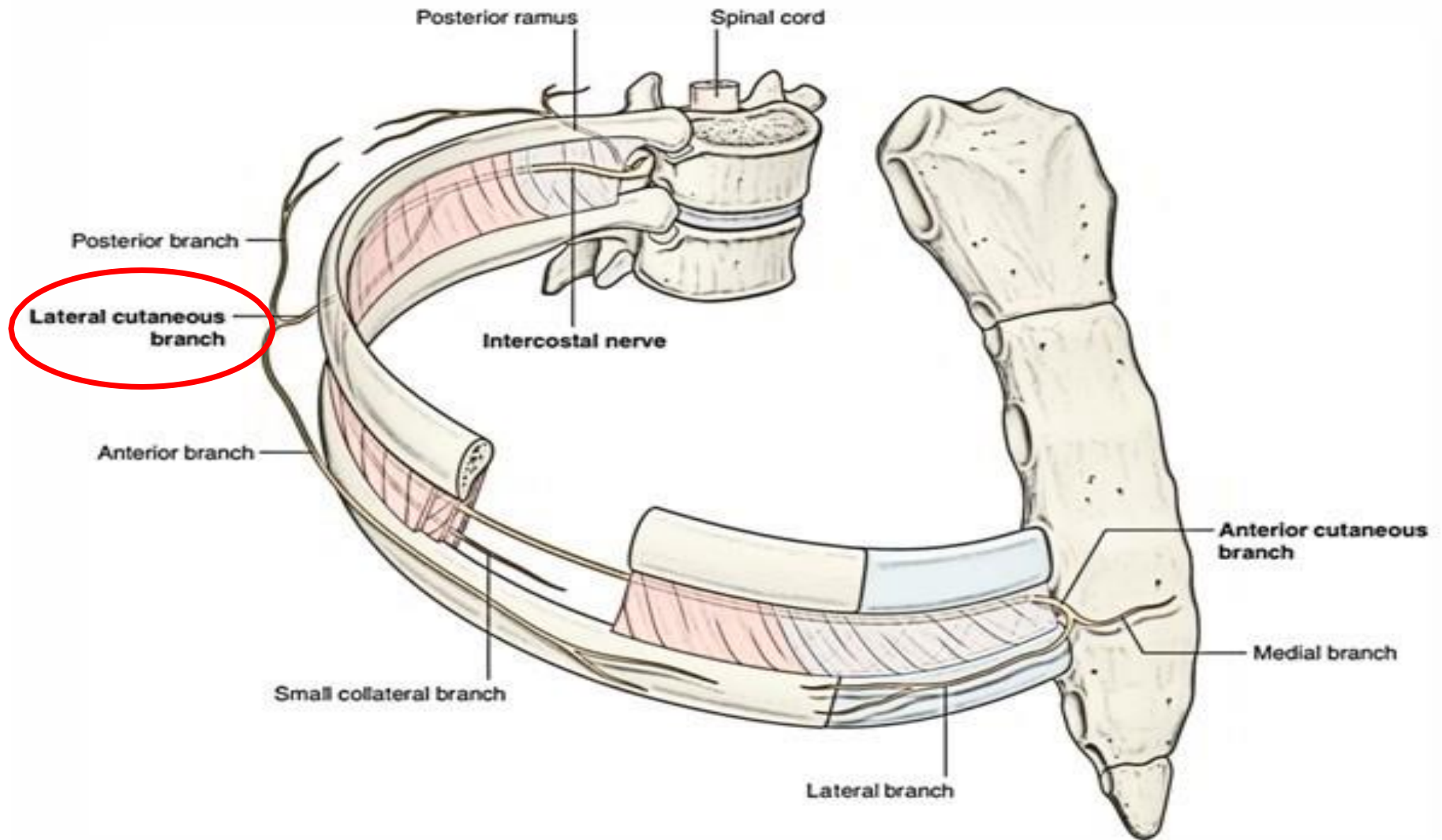


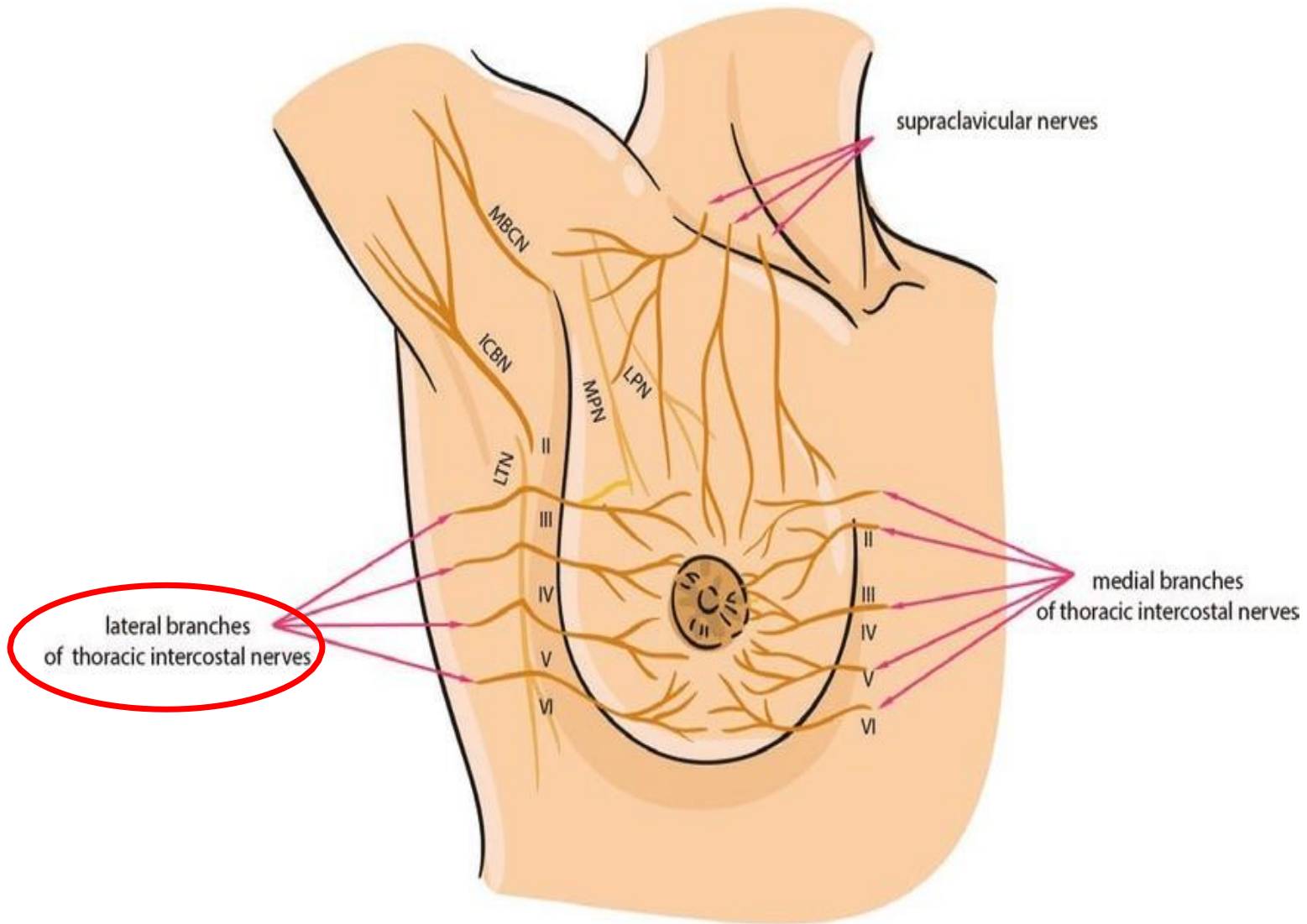
Cardiac Pain

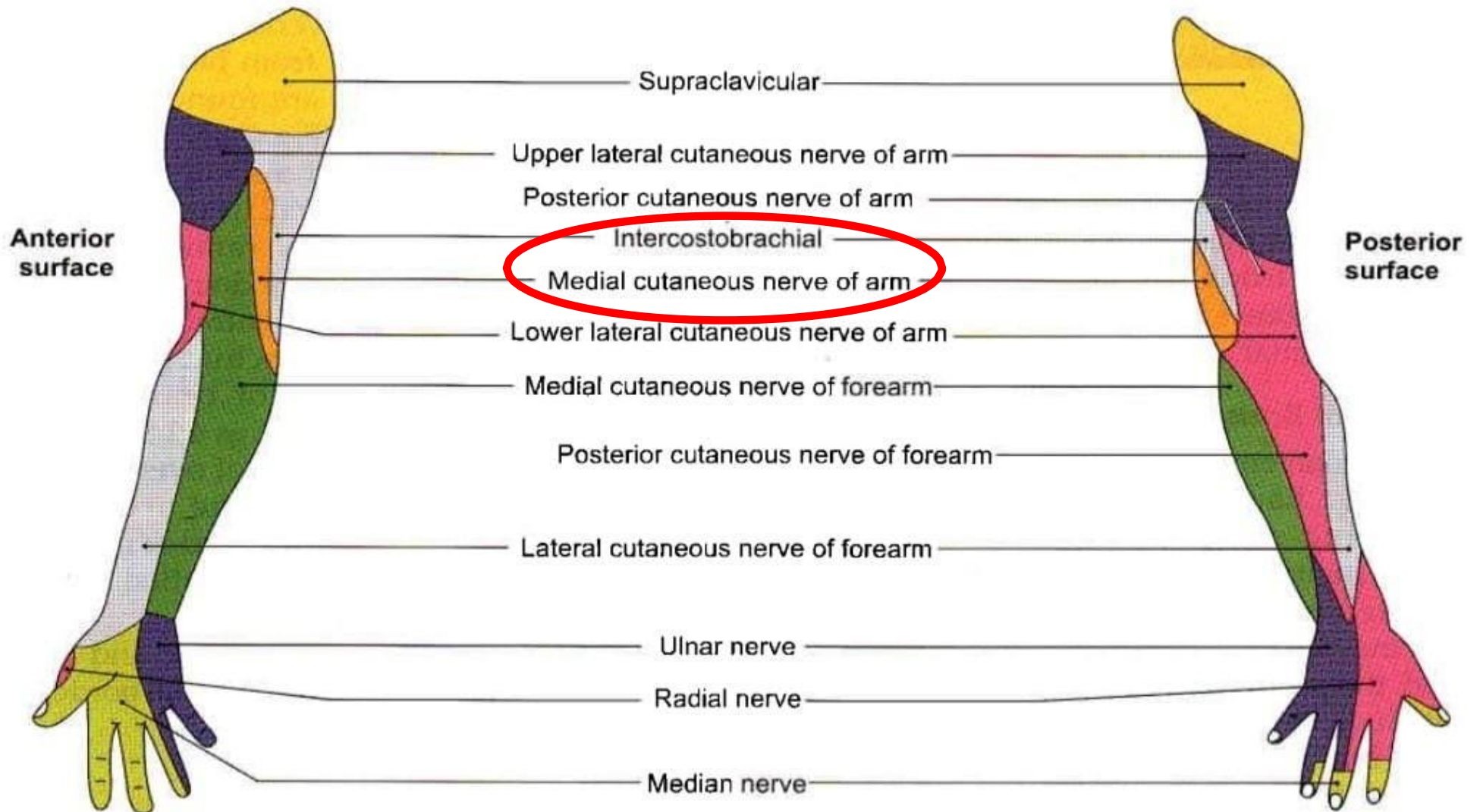
- The nature of the pain varies ,from a mild discomfort to a severe crushing pain
- The heart is insensitive to touch, cutting, cold, and heat; however, ischemia and the accumulation of metabolic products stimulate pain endings in the myocardium

- ✓ The afferent pain fibers run with thoracic cardiac branches of the sympathetic trunk.
- ✓ These sensory fibers enter the spinal cord through the posterior roots of the upper four thoracic nerves (T1-T4)
- ✓ The pain is not felt in the heart, but is referred to the skin areas supplied by the upper four thoracic nerves
- ✓ The skin areas supplied by the upper four intercostal nerves and by the intercostobrachial nerve (T2) are therefore affected.
- ✓ The intercostobrachial nerve communicates with the medial cutaneous nerve of the arm and is distributed to skin on the medial side of the upper part of the arm
- ✓ Pain felt on the left side of chest , left side of neck ,left shoulder and medial side of left arm

Intercostobrachial nerve is the lateral cutaneous branch of the second intercostal nerve







Myocardial infarction involving the inferior wall or diaphragmatic surface of the heart often gives rise to discomfort in the epigastrium.

The afferent pain fibers run with the sympathetic nerves and enter the spinal cord in the posterior roots of T7, T8, and T9

This gives a referred pain to epigastric region

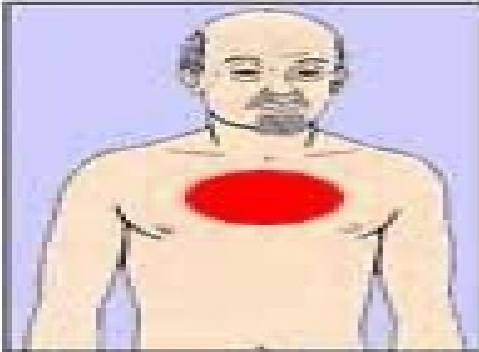
**RESPECT ANY EPIGASTRIC PAIN ESPECIALLY IN
HIGH RISK PATIENT**



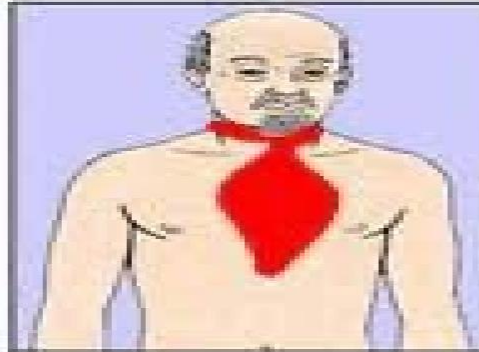
Is the heart pain can felt in the right side, both sides, or the back ?

Synaptic contacts may also be made with connector neurons, which conduct impulses to neurons on the right side of comparable areas of the spinal cord.

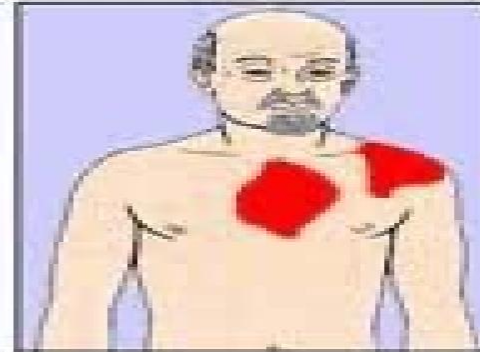
Location of chest pain during angina or heart attack



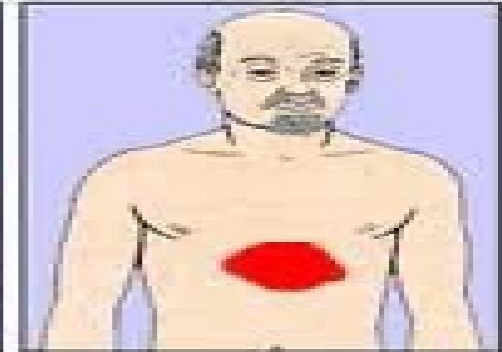
Upper chest



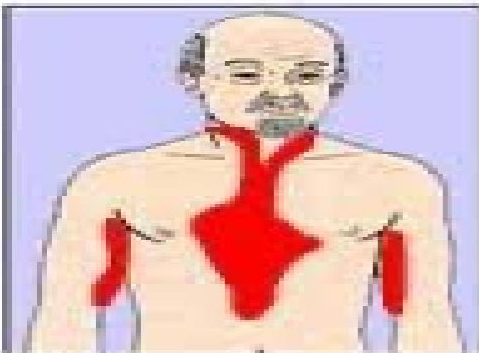
Substernal radiating to neck and jaw



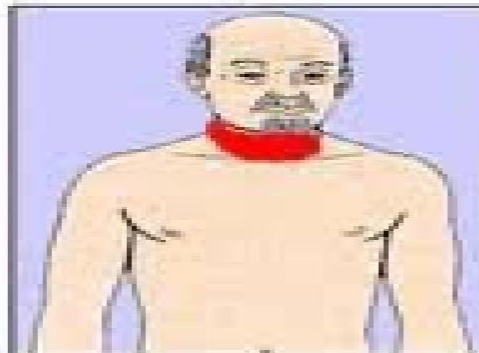
Substernal radiating down left arm



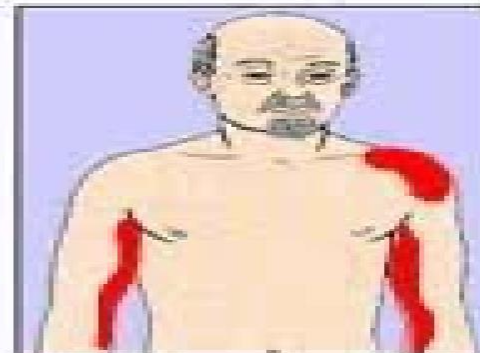
Substernal radiating down left arm



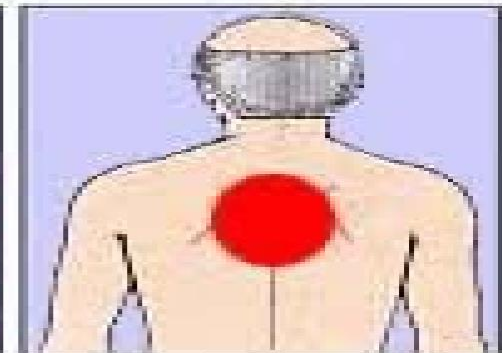
Epigastric radiating to neck, jaw, and arms



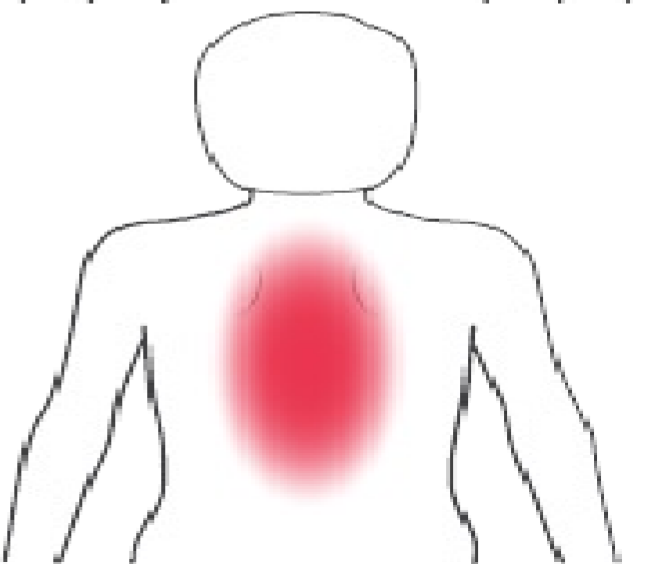
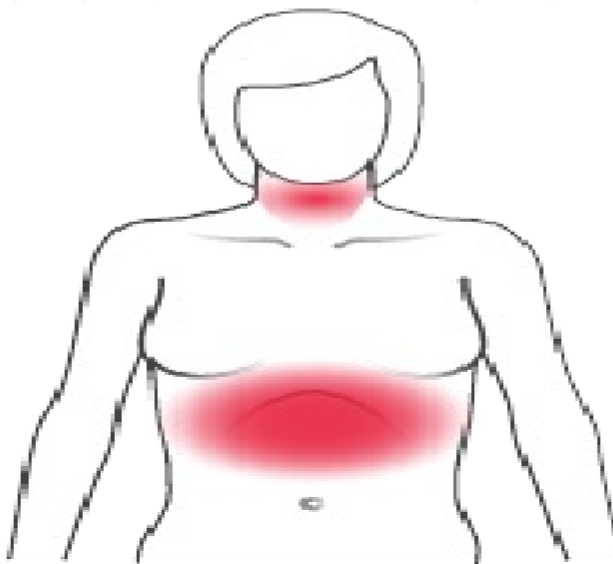
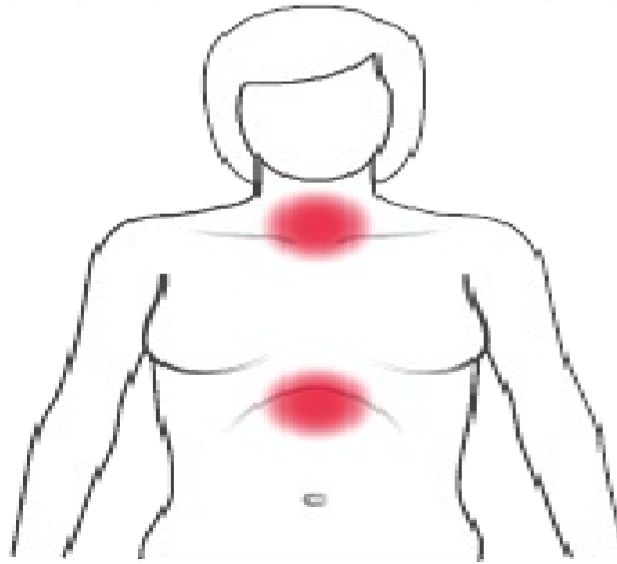
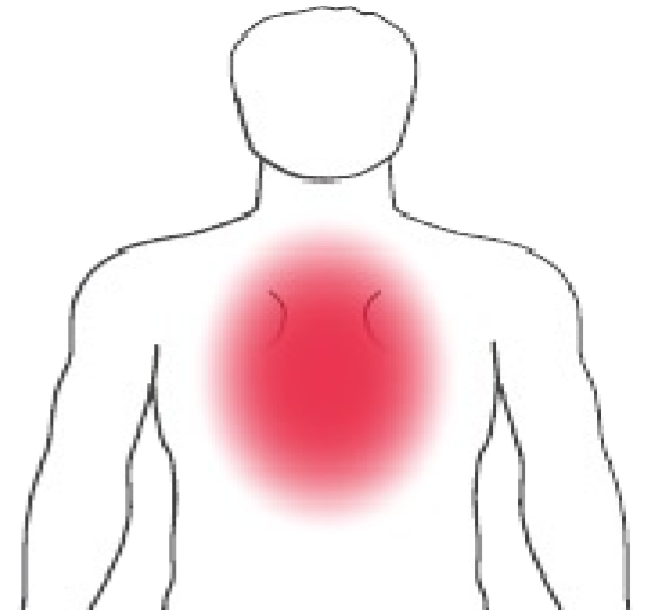
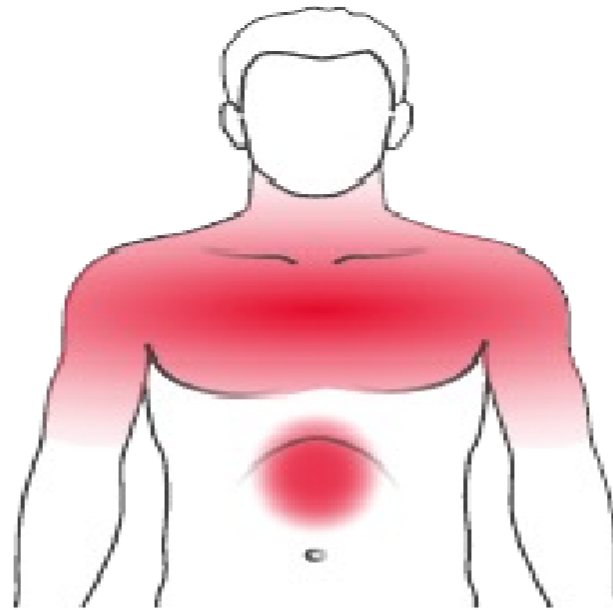
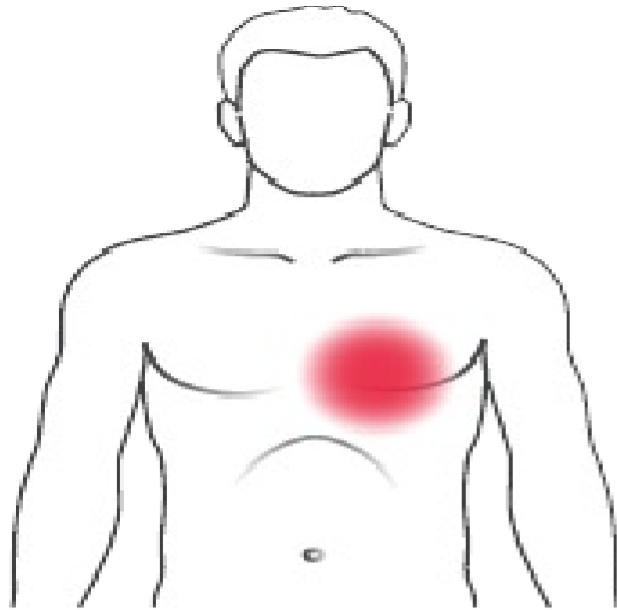
Neck and Jaw



Left shoulder and down both arms

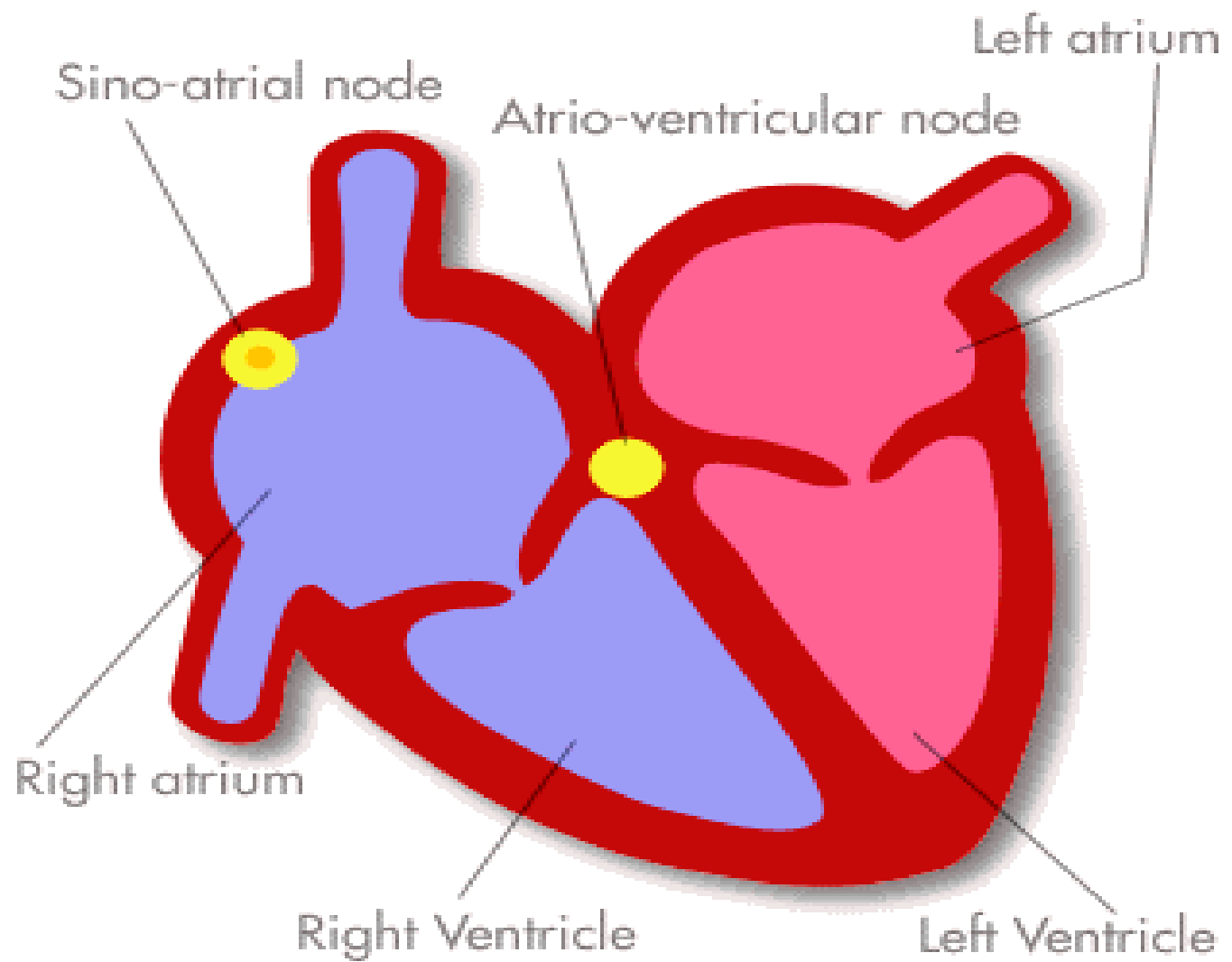


Intrascapular



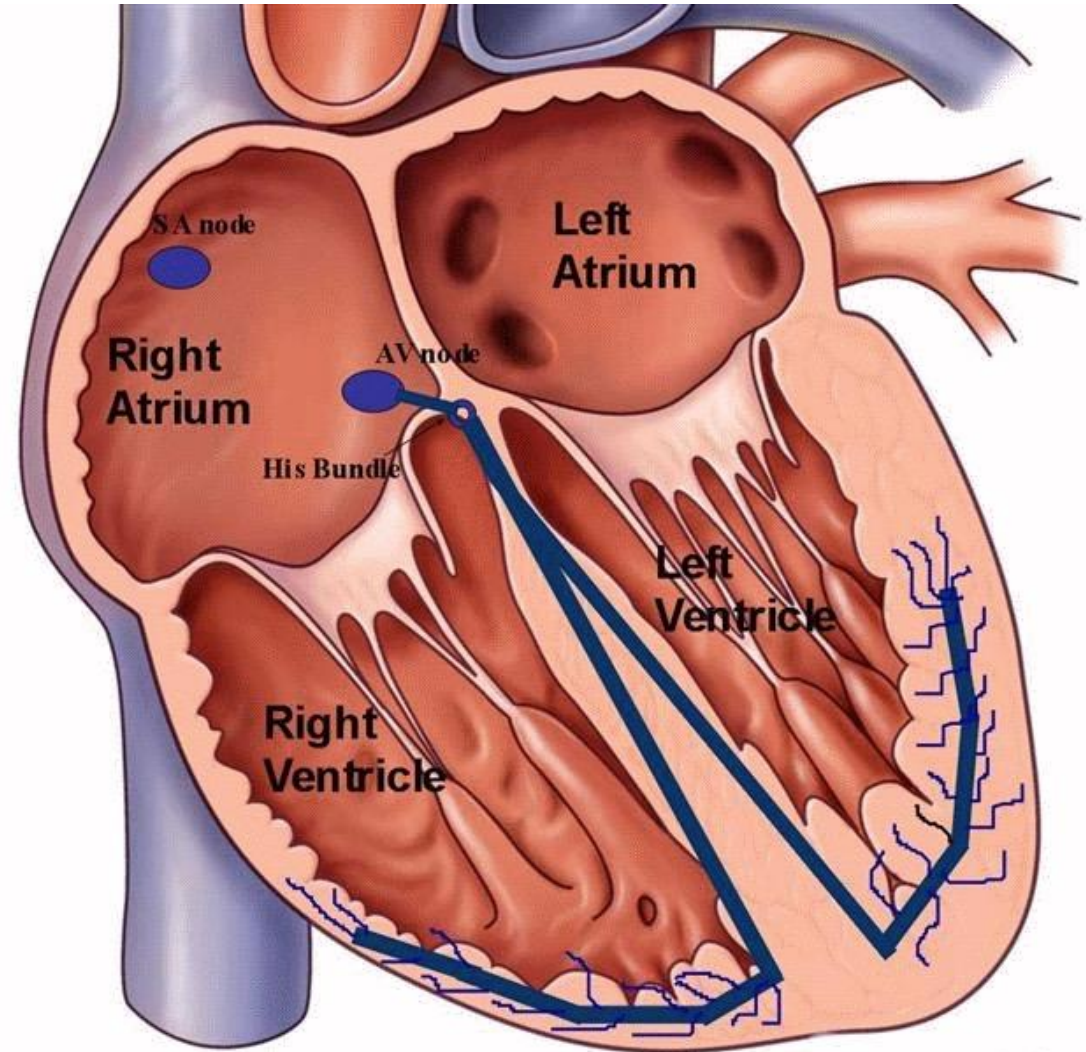
The conducting system of the heart

- ❑ It is formed of modified myocardial fibers called Purkinje fibers that are responsible for initiation, conduction and maintenance of cardiac muscle
- ❑ Atria contract first and together, to be followed later by the contractions of both ventricles together
- ❑ The slight delay in the passage of the impulse from the atria to the ventricles allows time for the atria to empty their blood into the ventricles before the ventricles contract.



It consists of

- ❑ The sinuatrial node(S.A)
- ❑ The atrioventricular node (A.V)
- ❑ The atrioventricular bundle
- ❑ Right and left terminal branch



1 Sinuatrial (S.A) node

- ✓ Is the pacemaker of the heart
- ✓ It initiates and regulates the impulses of the heart contractions
- ✓ It is an ellipsoid band of modified myocardial fibers and associated fibroelastic connective tissue
- ✓ It extends from the anterolateral aspect of the opening of the superior vena cava into the upper part of the crista terminalis

Internodal conduction tracts:

These are fine bundles of modified myocardial fibers connecting the sinuatrial (S.A.) node with the atrioventricular (A.V.) node

They are arranged as follows:

I. Anterior internodal tract:

It arises from the **upper end** of the S.A. node and passes **in front** of the superior vena caval opening and it divides into two bundles:

- A. A bundle penetrating the interatrial septum to reach the wall of the left atrium and is called **Bachmann's bundle**.
- B. The other bundle descends on the right side of the interatrial septum to reach A.V. node

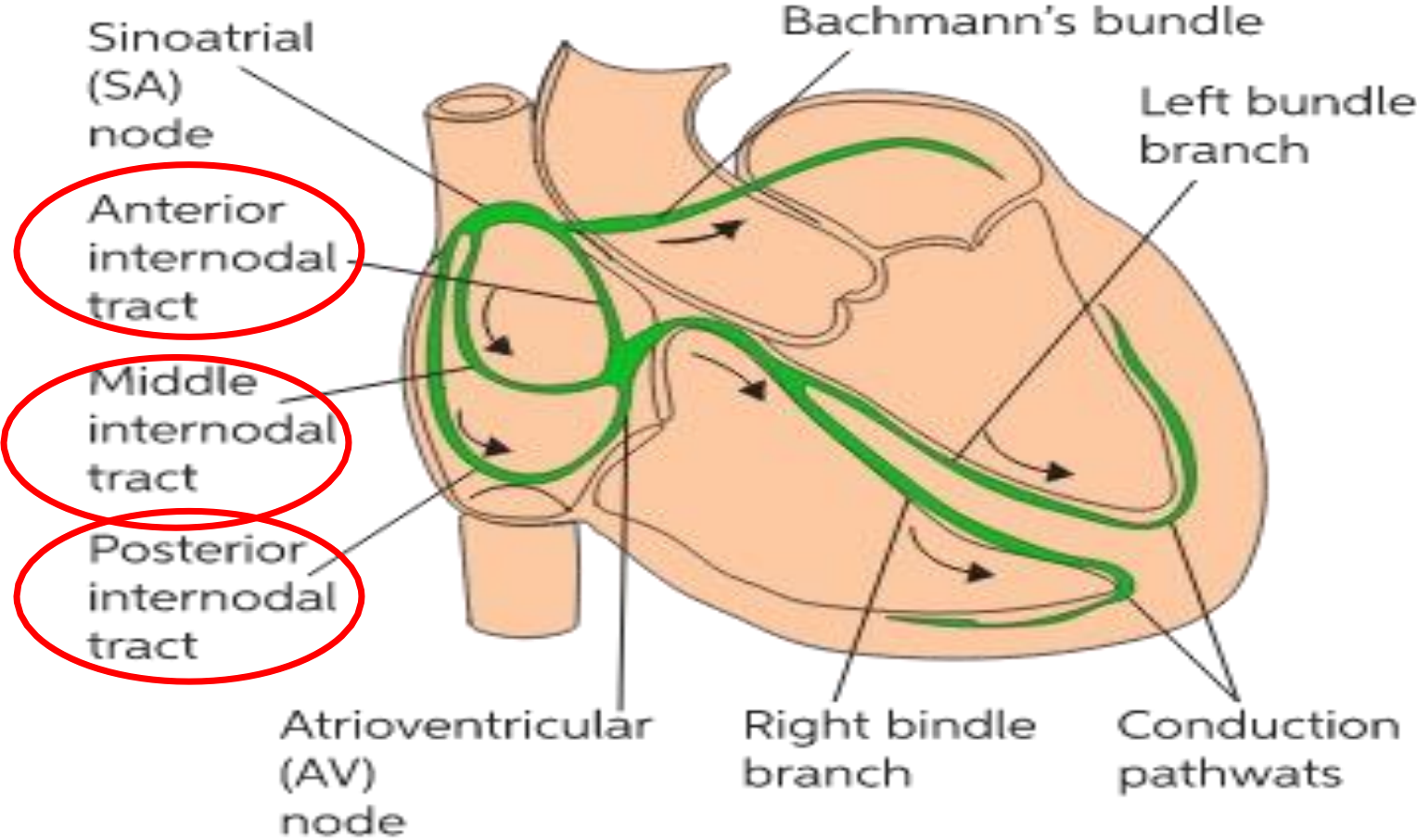
B. Middle internodal tract

It arises from the **postero superior** aspect of the S.A. node and curves **posteriorly** behind the orifice of the Superior vena cava to reach the A.V. node

C. Posterior internodal tract

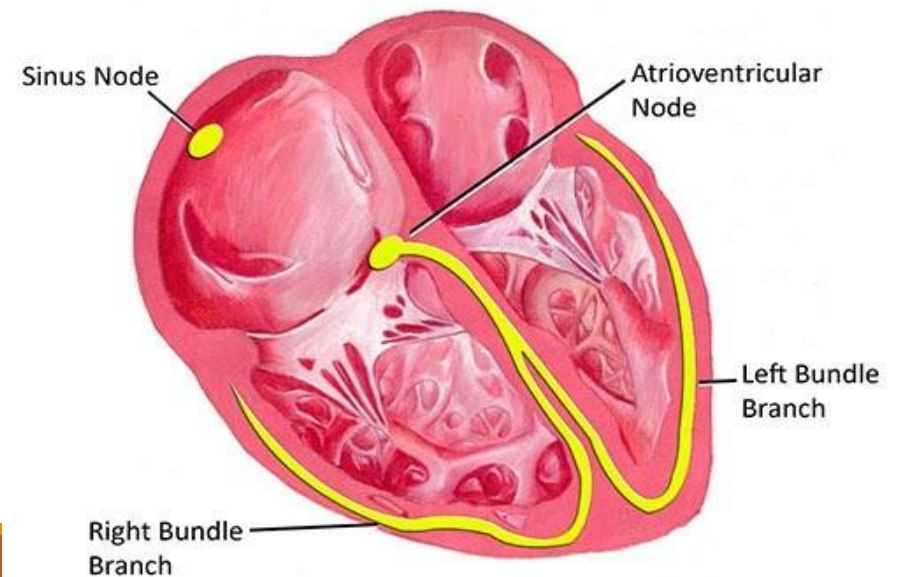
It arises from the **postero inferior** aspect of the S.A, node and descends through the crista terminalis and the valve of inferior vena cava to reach A.V. node

The electrical system of the heart



2- Atrio ventricular (A.V.) node

- It is a collection of nodal tissue but it is smaller than the SA node
- It lies on the right side of the lower part of the interatrial septum just above the septal leaflet of the tricuspid valve close to the opening of the coronary sinus
- Its anatomical landmarks are the boundaries of the triangle of Koch
- It receives the impulse from the SA node through the internodal tract and distributes the signal to the ventricles through the AV bundle (of His)



Triangle of Koch

Boundaries

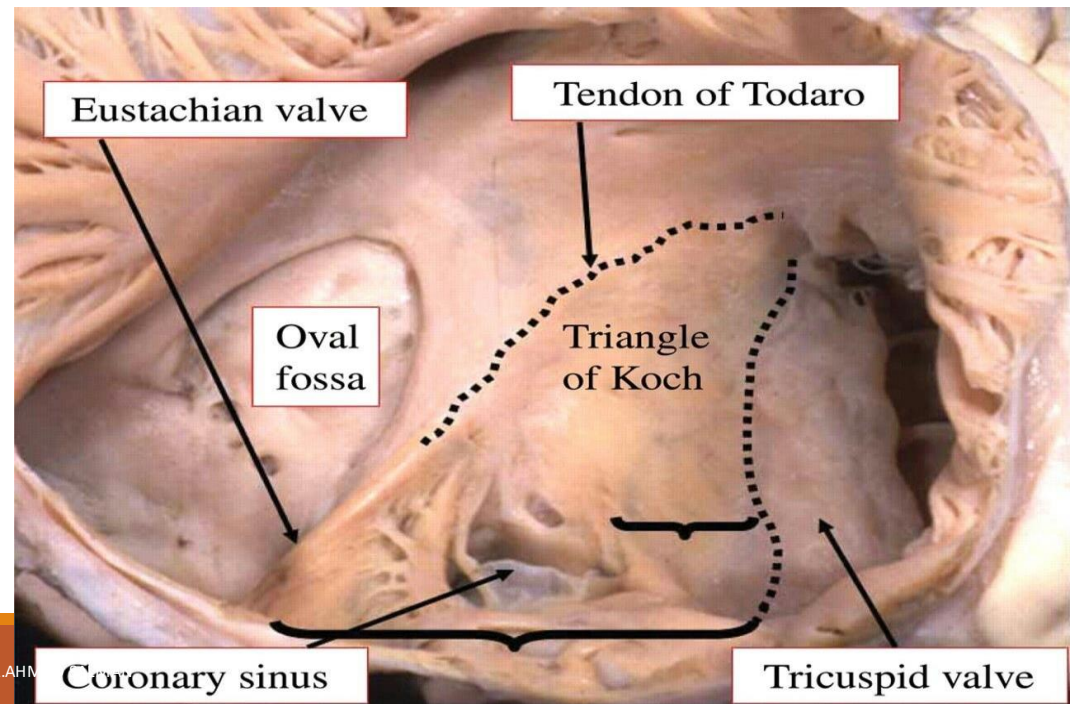
Septal leaflet of the tricuspid valve

Tendon of Todaro (a tendinous structure connecting the valve of the inferior vena cava ostium to the central fibrous body)

Ostium of the Coronary Sinus - posterior aspect of the atrial septum

This triangle is used as an anatomical landmark for location of the atrioventricular node during electrophysiology procedures such as pacing or ablation.

REED ONLY



3- Antioventricular (AV) bundle


- ❖ Is a short bundle of modified myocardial fibers which begins from A.V. node and passes through fibrous skeleton of heart along membranous part of the interventricular septum
- ❖ It divides into right and left bundles at the junction of the membranous and muscular parts of the IVS
- ❖ These branches proceed on each side of the muscular IVS deep to the endocardium and then ramify into subendocardial branches (Purkinje fibers) which extend into the walls of the respective ventricles.

A. The right bundle

It stimulates the muscle of the IVS, the anterior papillary muscle through the septomarginal trabecula (moderator band), and the wall of the right ventricle.

B. The left bundle

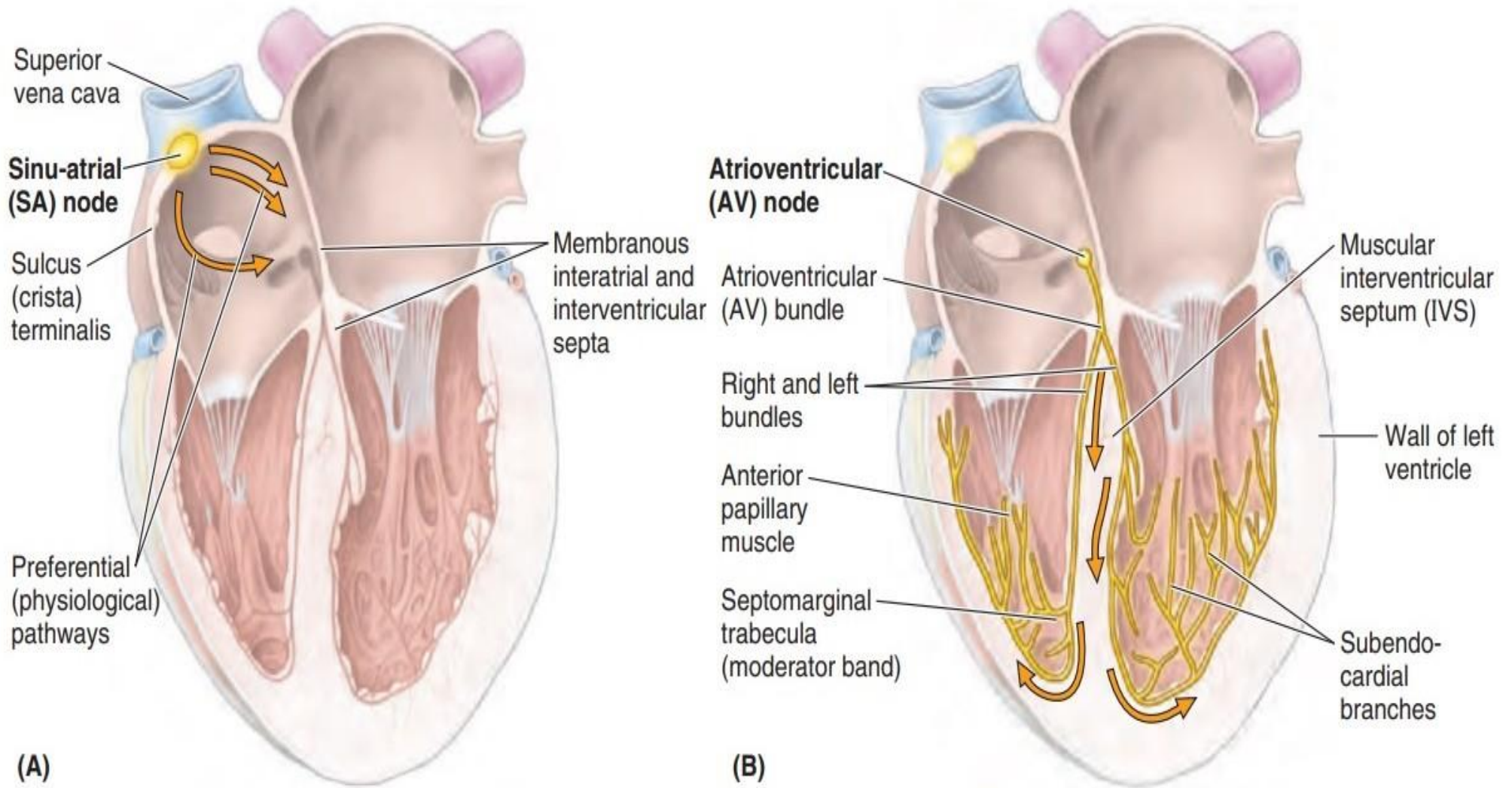
It divides near its origin into approximately six smaller tracts, which give rise to subendocardial branches that stimulate the IVS, the anterior and posterior papillary muscles, and the wall of the left ventricle



In ventricular septal defect (VSD) cases , the AV bundle usually lies in the margin of the VSD.

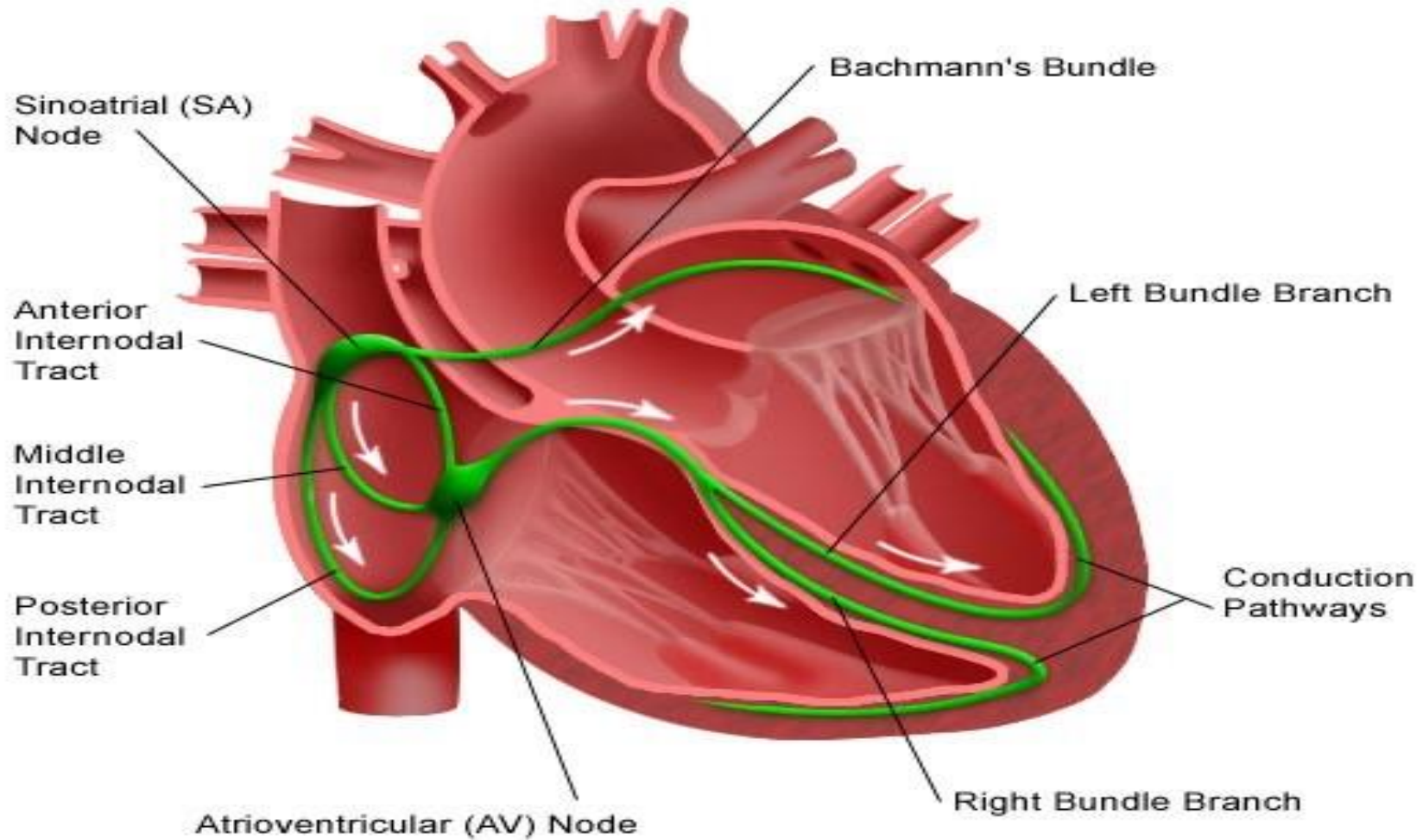
Obviously, this vital part of the conducting system must be preserved during surgical repair of the defect.

Destruction of the AV bundle would cut the only physiological link between the atrial and ventricular musculature, also producing a heart block



Anteriosuperior views

Electrical System of the Heart

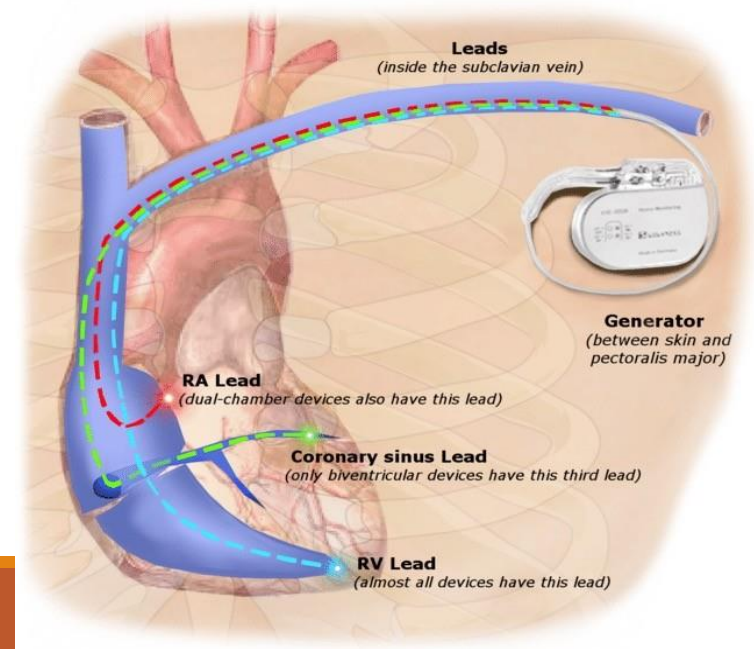


Artificial Pacemaker

REED ONLY

An artificial pacemaker is a small electrical device commonly fitted to monitor and correct heart rate and rhythm. It is inserted into the chest under the left clavicle, with wires connected to the heart via the venous system.

The most common indication for a pacemaker is bradycardia. Once inserted, the pacemaker monitors the heart rate, and only fires if the rate becomes too slow. Pacemakers can also be used to treat some tachycardias, certain types of heart block and other rhythm abnormalities.

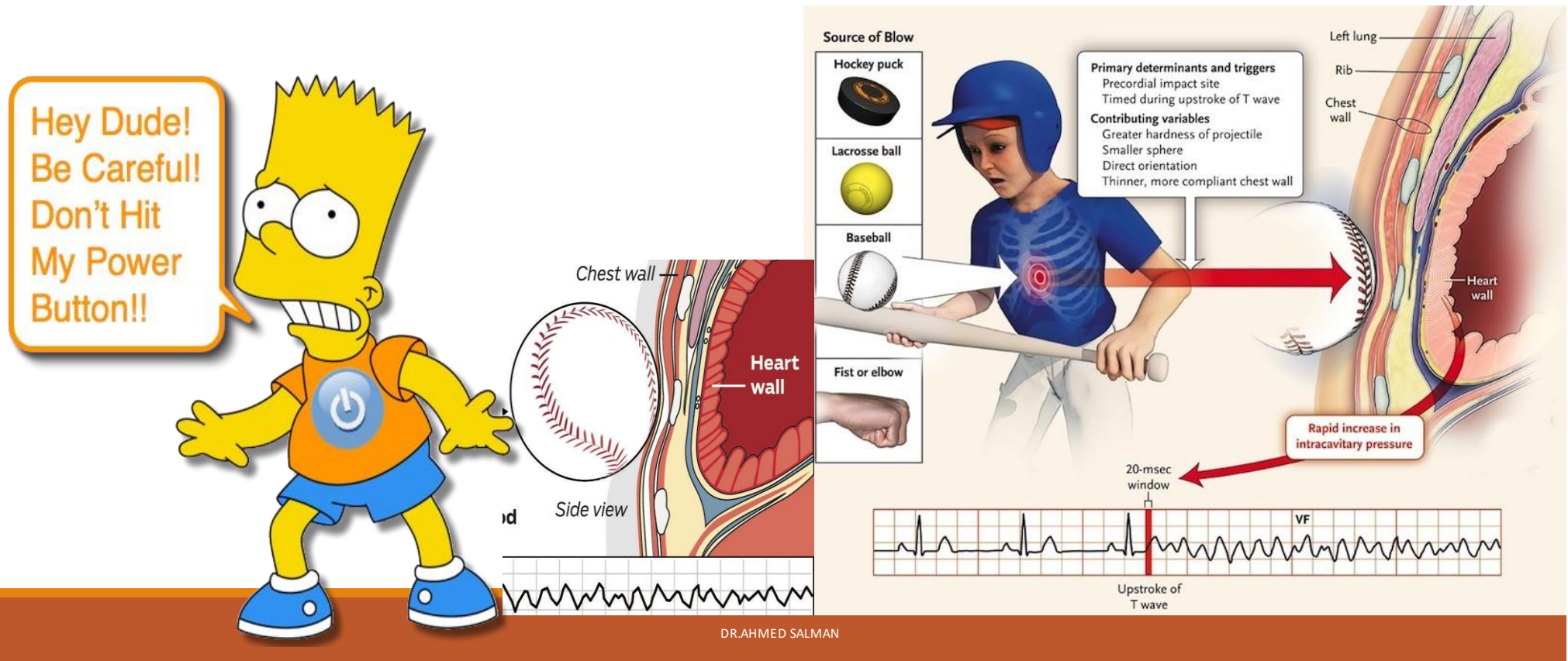


Commotio Cordis

This condition results in ventricular fibrillation and sudden death.

It is caused by a blunt non penetrating blow to the anterior chest wall over the heart

It occurs most commonly in the young and adolescents and is often sports-related.

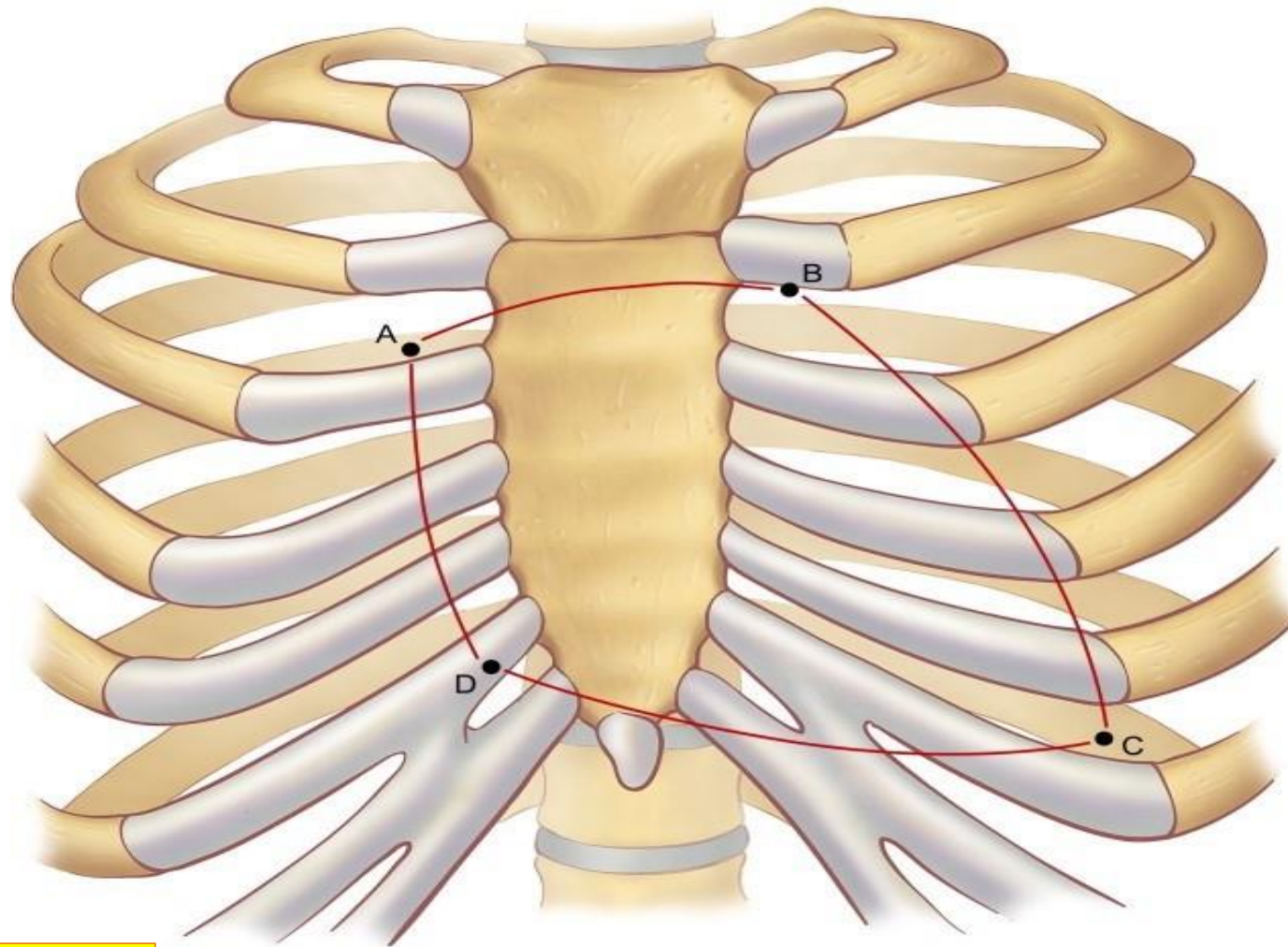


Surface Anatomy

Surface anatomy of the heart

- **Point A:** Upper border of right 3rd costal cartilage (1 inch) from midline.
- **Point B:** Lower border of left 2nd costal cartilage (1.5 inch) from midline.
- **Point C (apex):** in the left 5th intercostal space (3.5 inches) from midline.
- **Point D:** on the right 6th costal cartilage (1/2 inch) from midline.

$$2+3 = 5$$



$$0.5+1+1.5 = 3$$
$$+0.5=3.5$$

- A Upper border of right 3rd costal cartilage.
- B Lower border of left 2nd costal cartilage.
- C Apex beat at left 5th intercostal space, lateral to mid-clavicular line.
- D Middle of right 6th costal cartilage

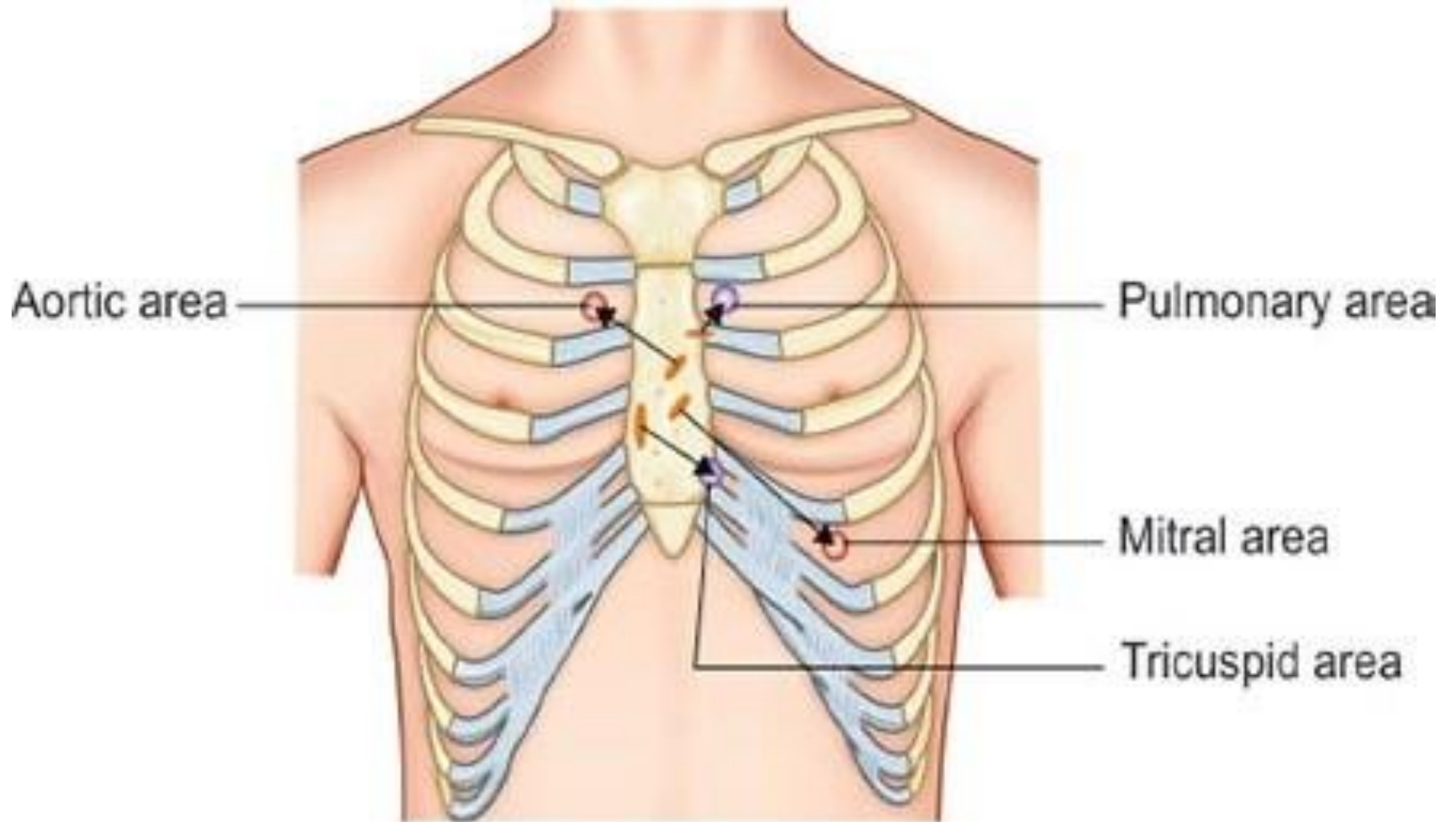
Heart Auscultation

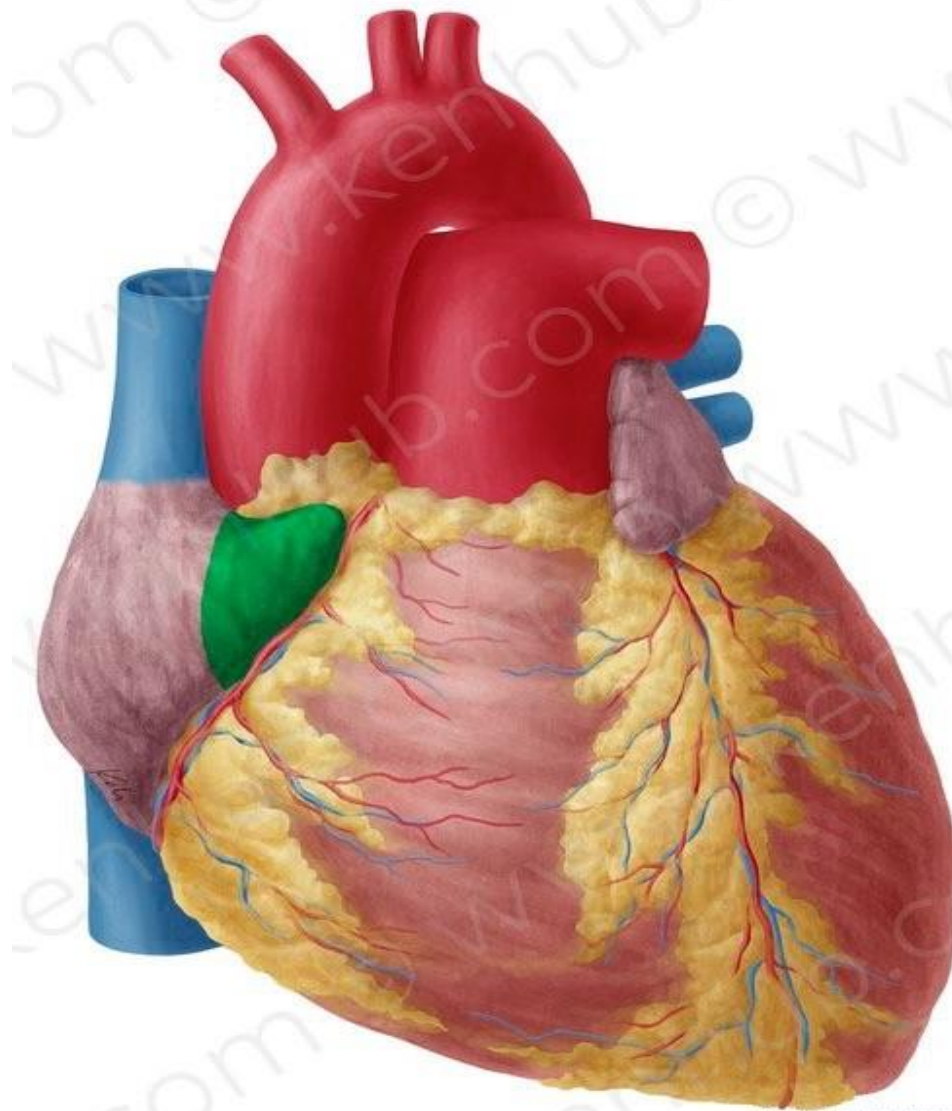
1. Pulmonary valve: left 2nd intercostal space .
2. Aortic valve: right 2nd intercostal space .
3. Mitral valve: Left 5th intercostal space midclavicular line
4. Tricuspid valve: Lower left sternal border at the 4th intercostal space

Surface anatomy of cardiac valves

REED ONLY

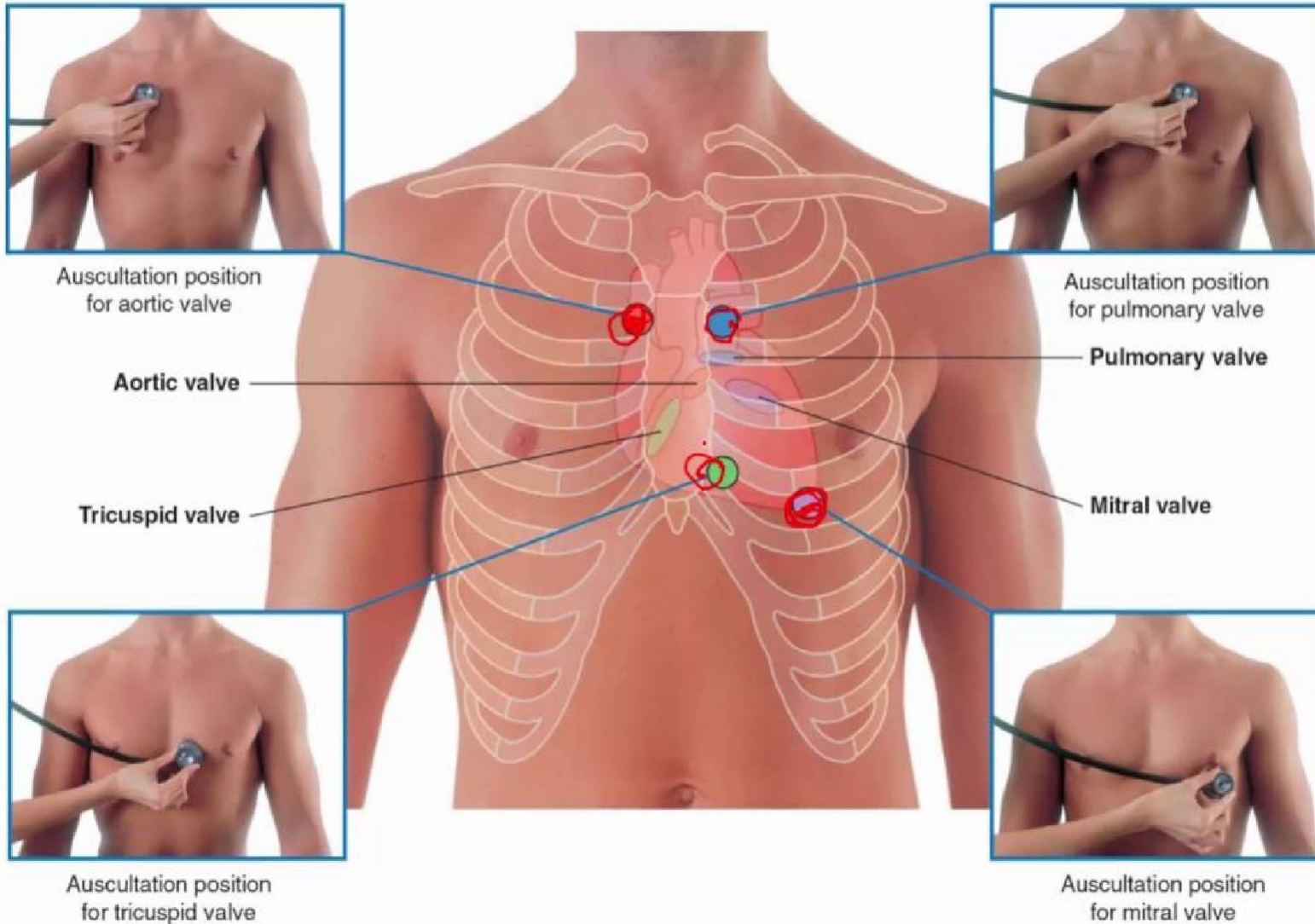
- **Pulmonary valve:** on the left 3rd sternocostal junction.
- **Aortic valve:** Behind left margin of sternum opposite to 3rd intercostal space.
- **Mitral valve:** Behind left half of sternum opposite to the left 4th costal cartilage.
- **Tricuspid valve:** on the midline of the sternum opposite the 4th intercostal space.





© www.kenhub.com





© Elsevier Ltd. Drake et al : Gray's Anatomy for Students www.studentconsult.com

