

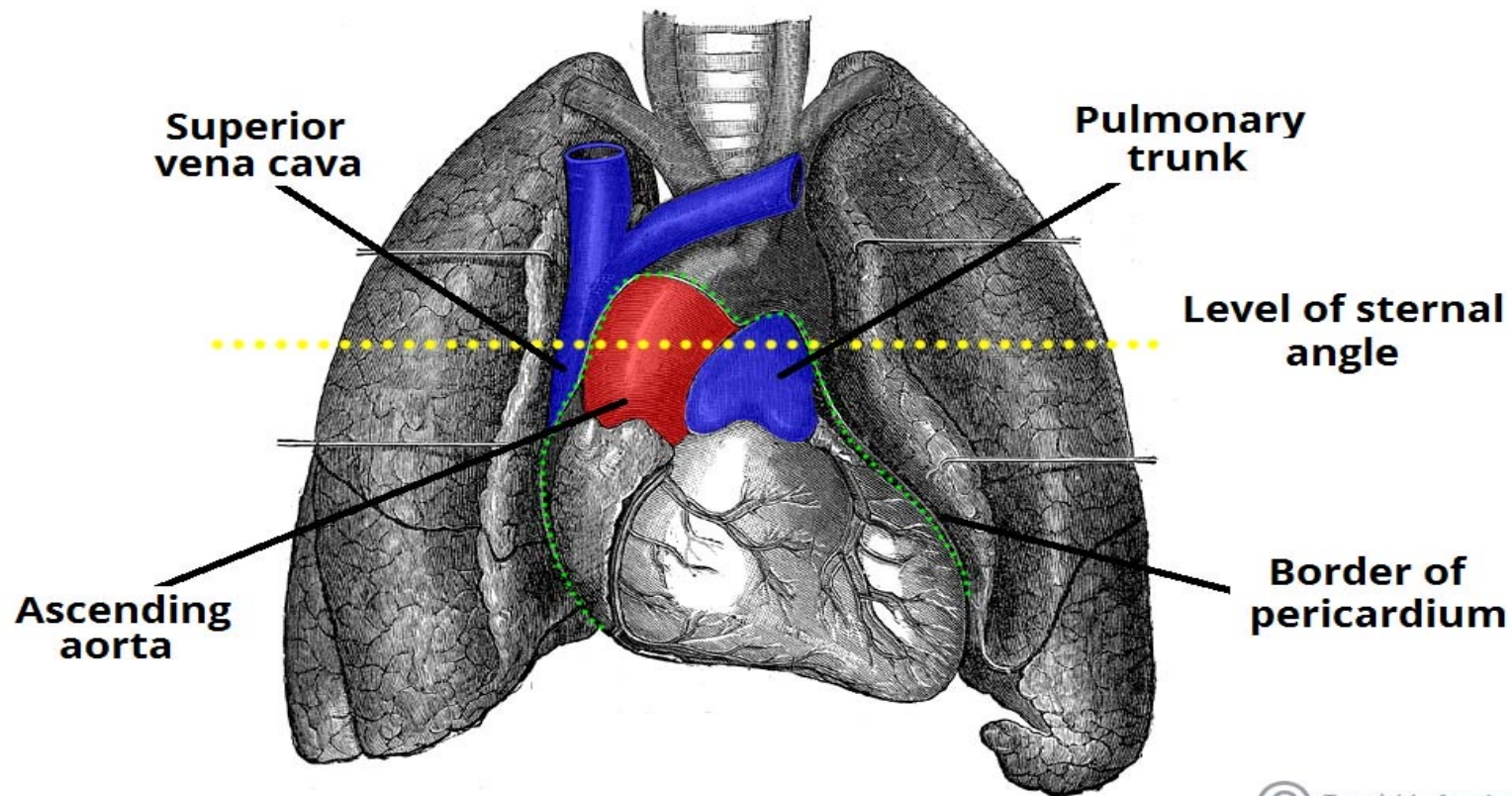


Middle mediastinum

DR. AHMED SALMAN

Associate professor of anatomy & embryology

The middle mediastinum contains the pericardial sac which contains the heart and roots of its great vessels :ascending aorta, pulmonary trunk, and SVC ;passing to and from the heart.



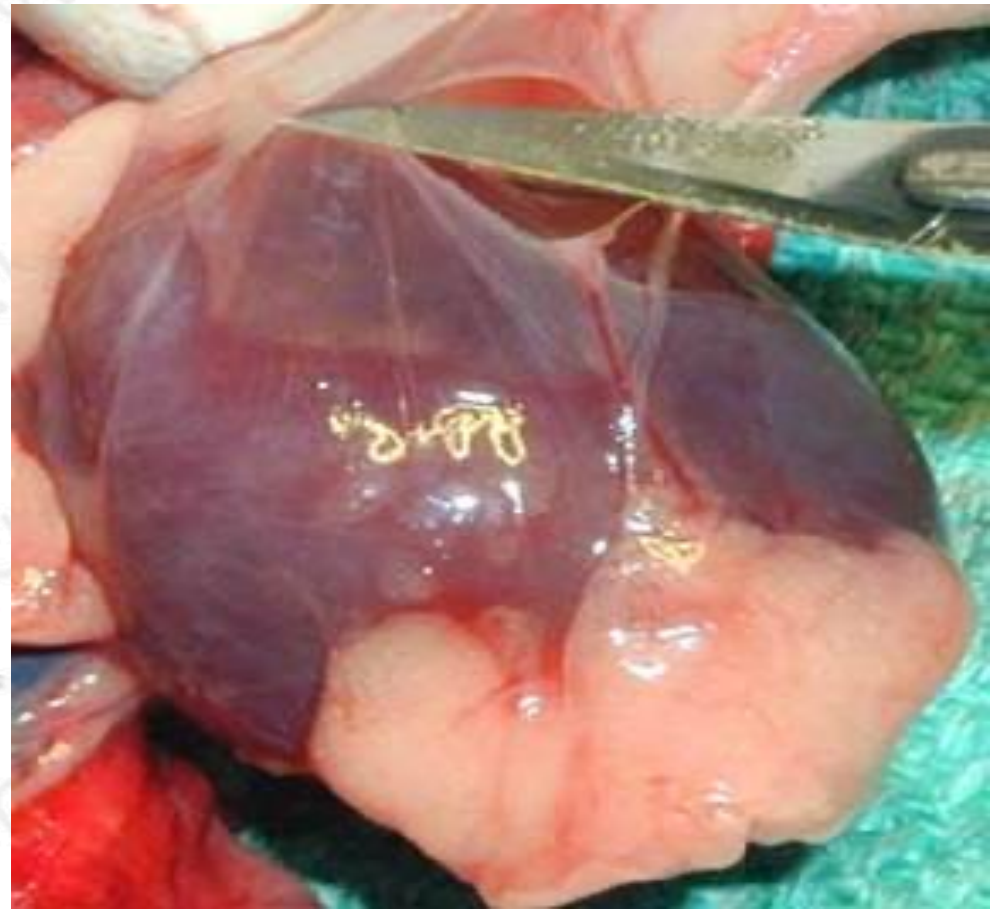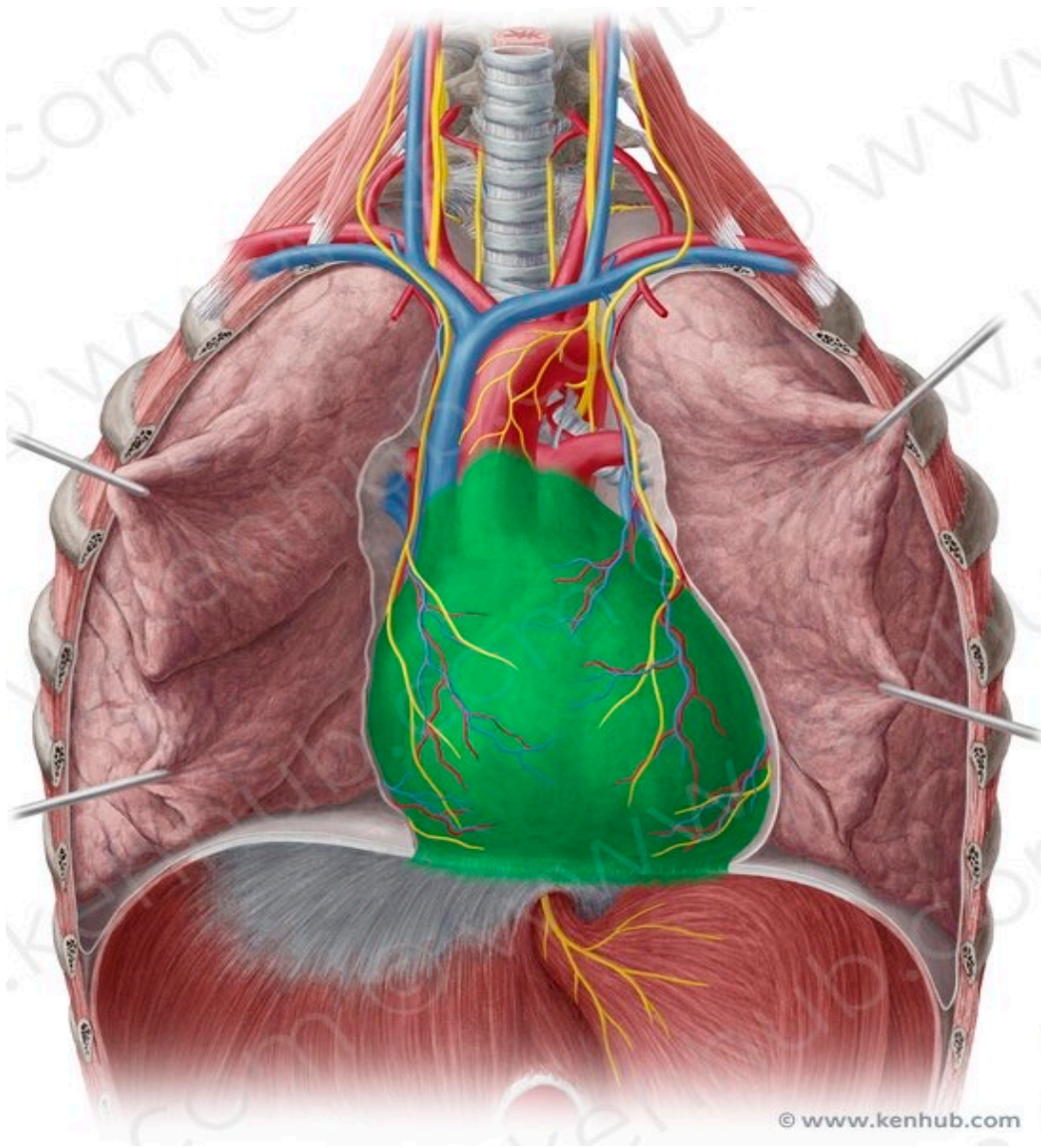
Pericardium

The pericardium is a closed fibroserous membrane that covers the heart and the beginning of its great vessels

It is composed of two layers ; The outer tough layer, the fibrous pericardium and inner serous layer.

Function of the pericardium

- 1-Restrict excessive movements of the heart.
- 2-Serve as a lubricated container in which the different parts of the heart can contract.



© www.kenhub.com

Layers of pericardium

I- The fibrous pericardium is the outer tough layer

Attachment :

Superiorly : Continuous with the tunica adventitia of the great vessels

Inferiorly : Continuous with the central tendon of the diaphragm ,which is called **pericardiophrenic ligament**

Anteriorly : Attached to the posterior surface of the sternum by the **sternopericardial ligaments**

Posteriorly : Bound by loose connective tissue to structures in the posterior mediastinum.

So ,the heart is bonded in its place inside this fibrous sac.

N.B. The fibrous pericardium protects the heart against sudden overfill

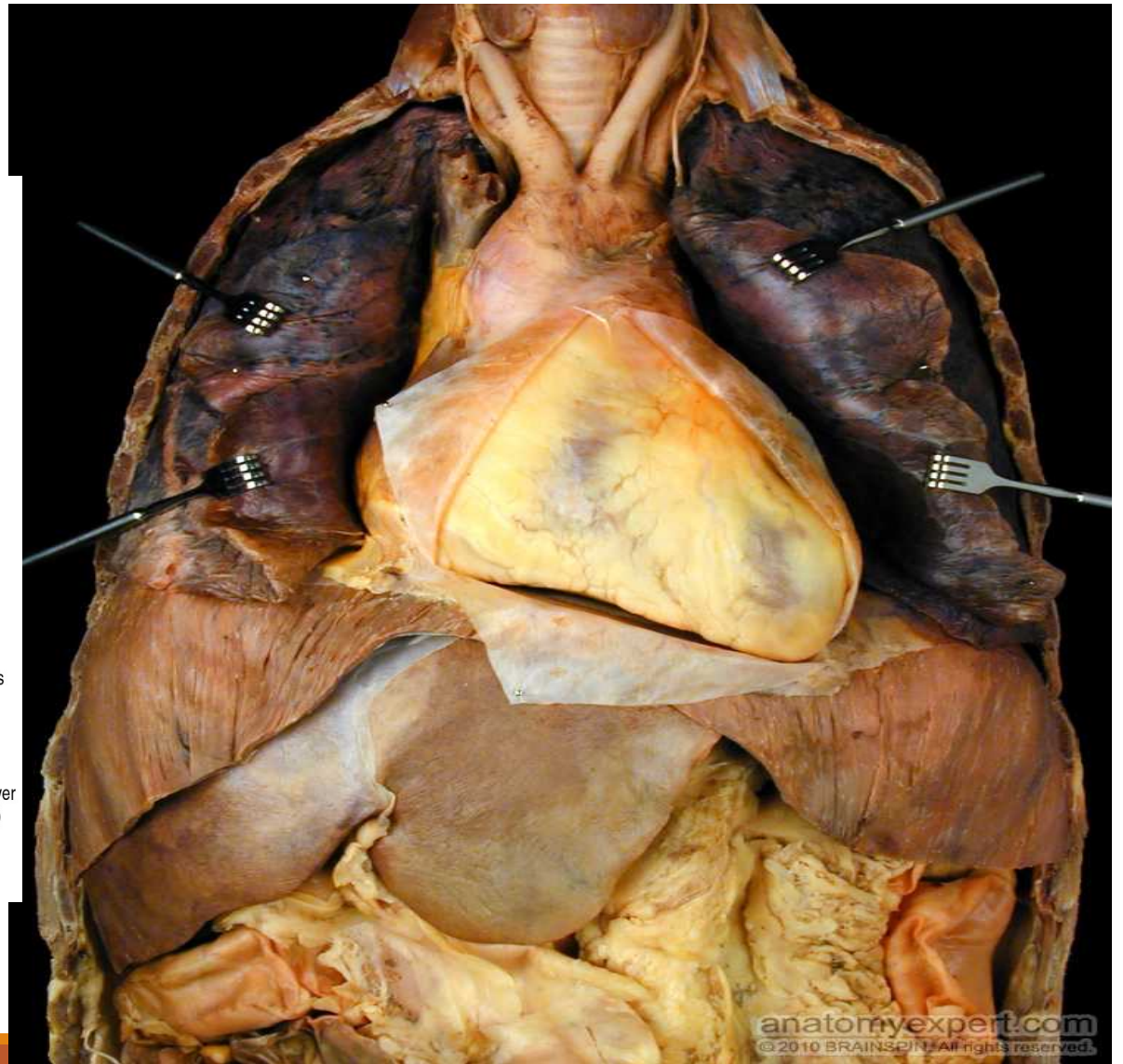
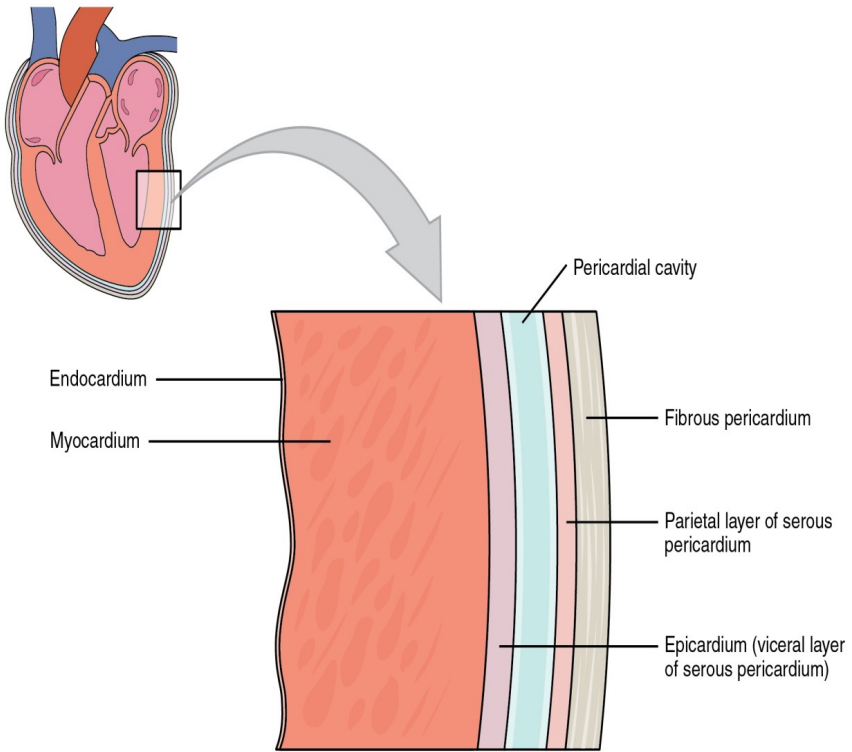
II- The serous layer is composed of two layers with a space in between

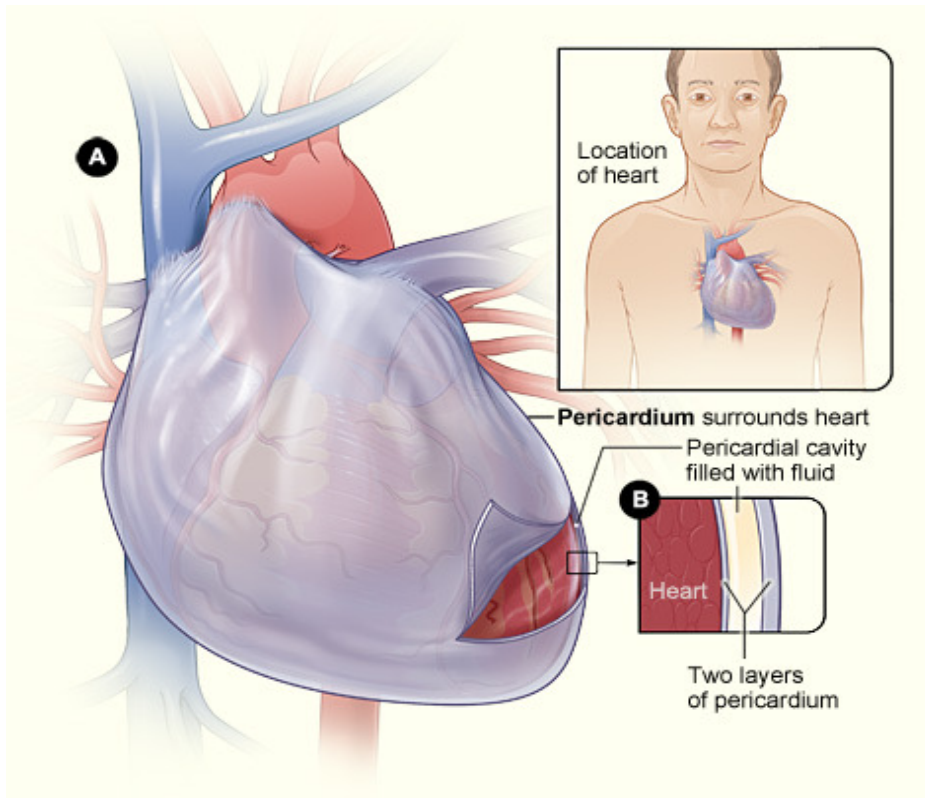
1- The parietal layer of serous pericardium: it lines the inner surface of the fibrous pericardium

2- Visceral layer : it is a reflection of parietal layer at the great vessels (aorta, pulmonary trunk and veins, and superior and inferior venae cava)

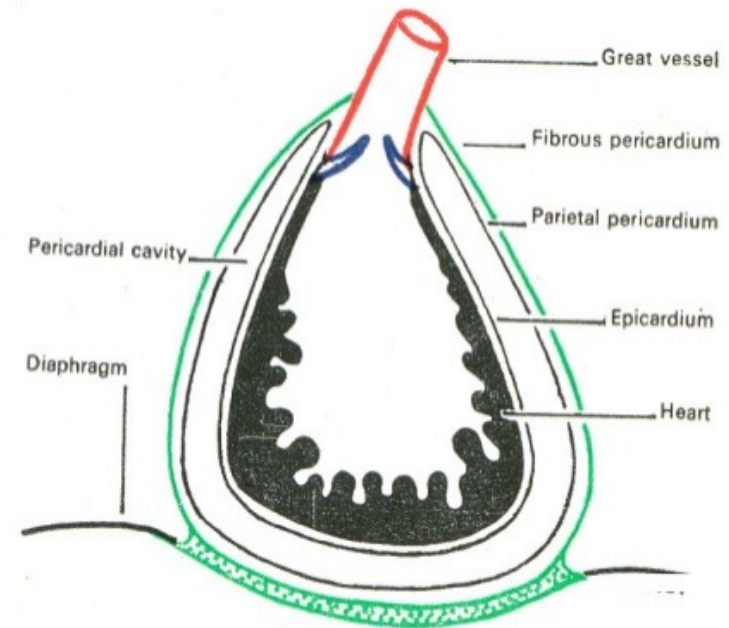
The visceral layer of serous pericardium forms the epicardium, the outermost of three layers of the heart wall.

3- Pericardial sac : It is the space between the 2 layers of serous pericardium. Contains a thin film of fluid that acts as a lubricant for movements of the heart





Layers of Pericardium



Pericardium

Fibrous Pericardium

- It is tough conical outer sac of pericardium.
- It is firmly attached to the diaphragm.
- It fuses with the outer coats

Serous Pericardium

It is thin transparent double - layered sac that lies within the fibrous pericardium.

The pericardial cavity

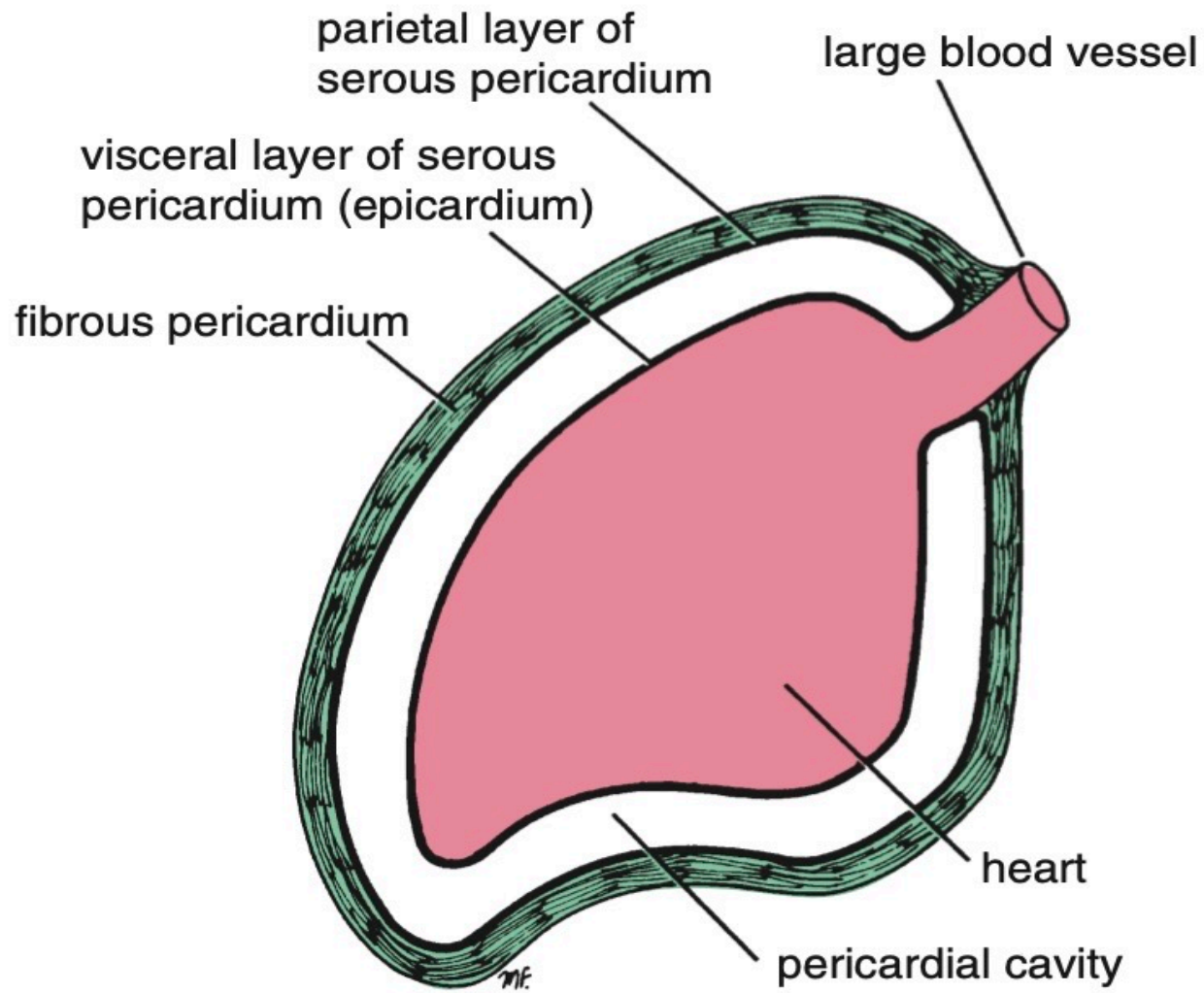
It is the space between the 2 layers of serous pericardium. Contains a thin film of fluid that acts as a lubricant for movements of the heart

Parietal

lines the inner surface of the fibrous pericardium

Visceral

Adheres to the heart and forms its outer covering



Pericardial sinuses

It is a reflection of pericardial parietal and visceral layers

1- Transverse sinus

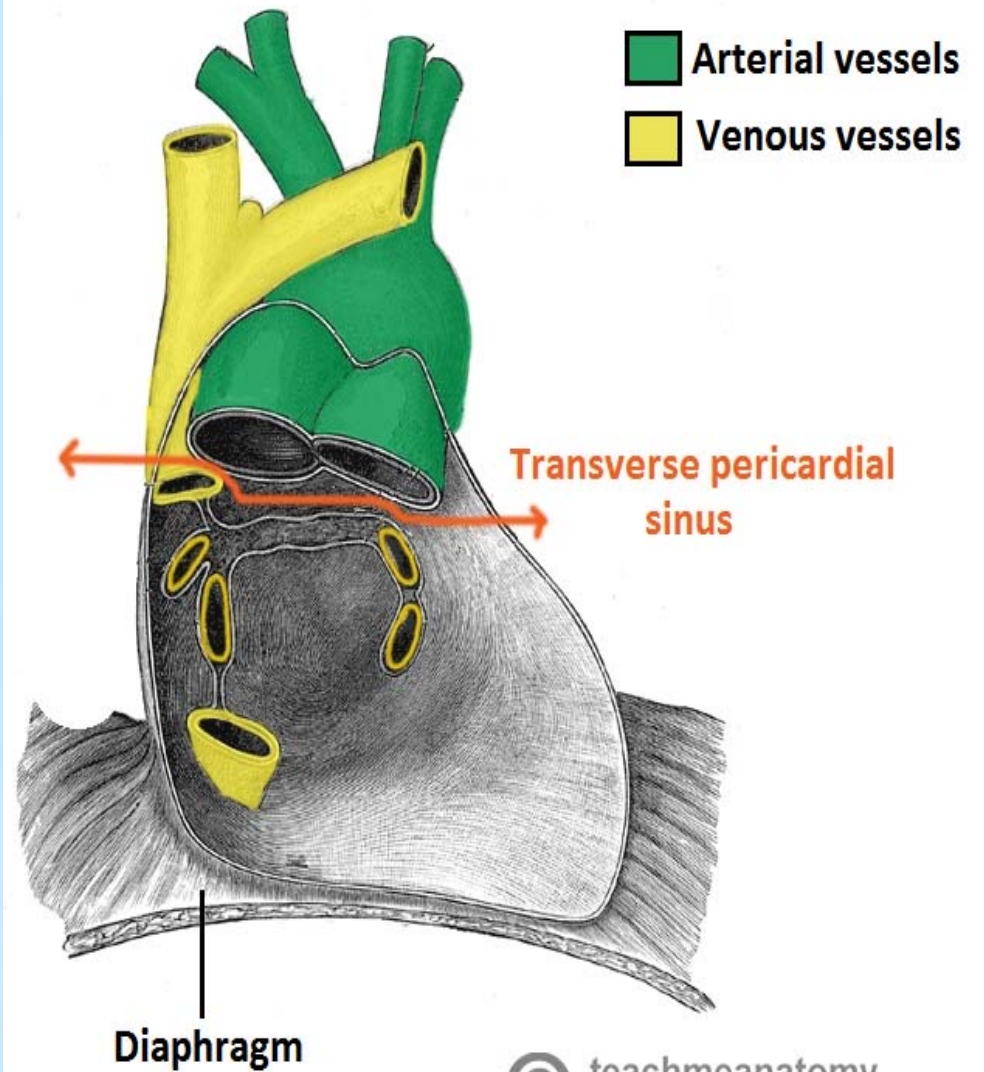
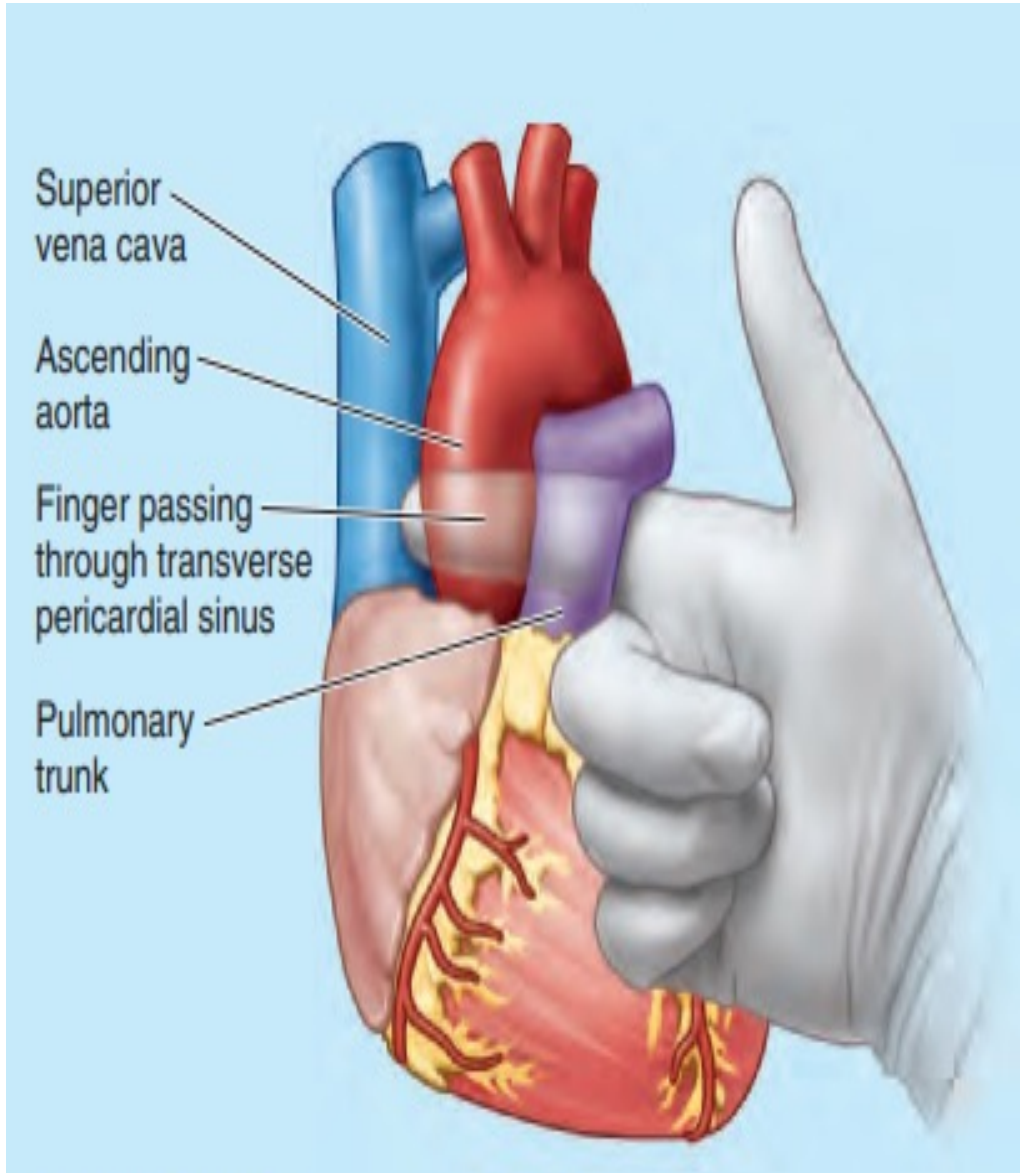
Boundaries:

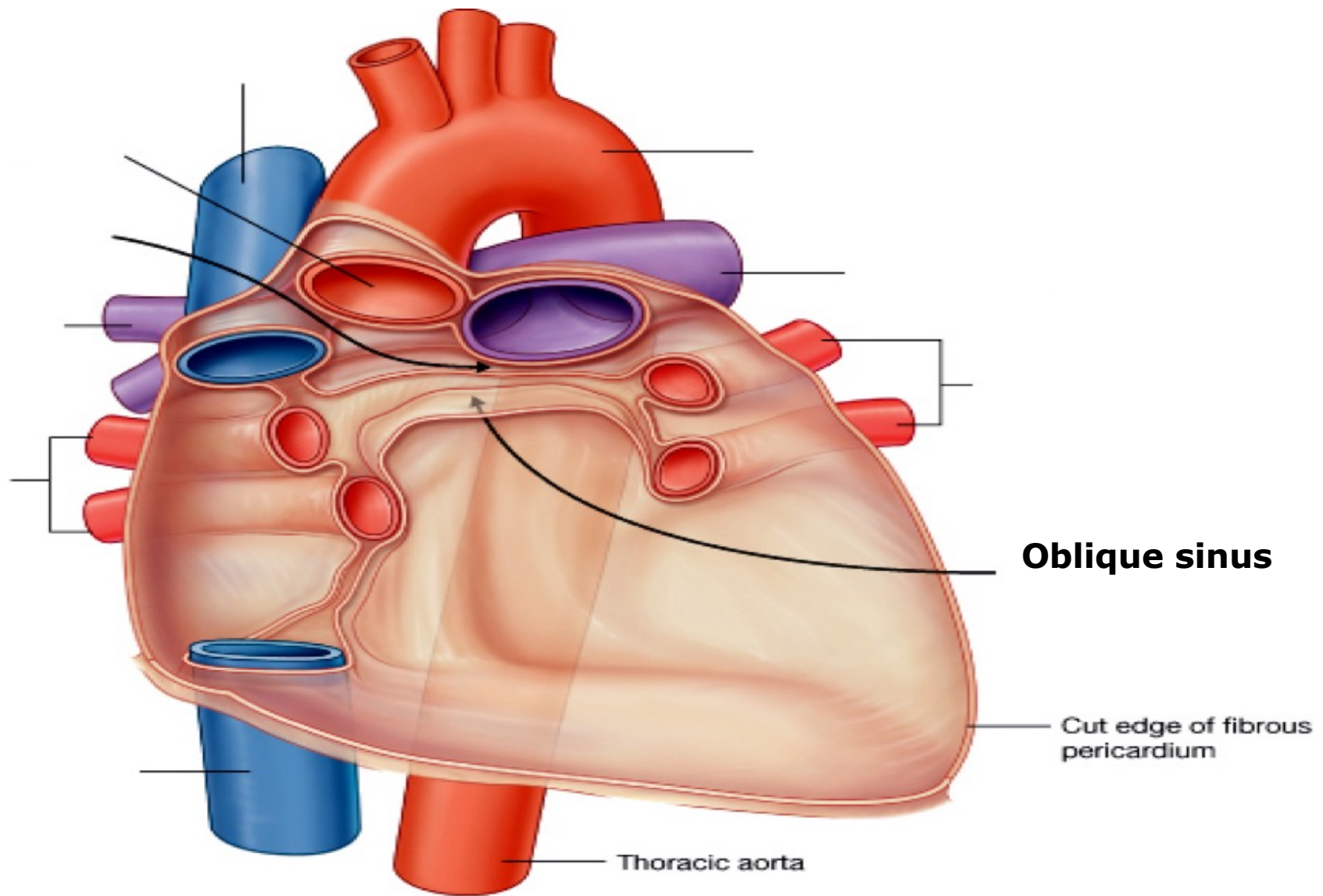
- Anterior: Ascending aorta and pulmonary trunk.
- Posterior: SVC .
- Inferior : Atria of the heart

2- Oblique sinus

Boundaries:

- **Anterior:** Visceral pericardium covering back of left atrium.
- **Posterior:** Parietal pericardium covering esophagus.
- **Superior:** Reflection of visceral to become parietal pericardium.
- **Inferior:** Opened and continuous with pericardial cavity.
- **Laterally:** Pericardial reflection surrounding pulmonary veins and IVC.






Clinical importance of The transverse pericardial sinus

In cardiac surgery , After the pericardial sac is opened anteriorly, a finger can be passed through the transverse pericardial sinus posterior to the ascending aorta and pulmonary trunk .

By passing a surgical clamp or a ligature around these large vessels, inserting the tubes of a coronary bypass machine, and then tightening the ligature, surgeons can stop or divert the circulation of blood in these arteries while performing cardiac surgery, such as coronary artery bypass grafting.



Arterial supply of the pericardium

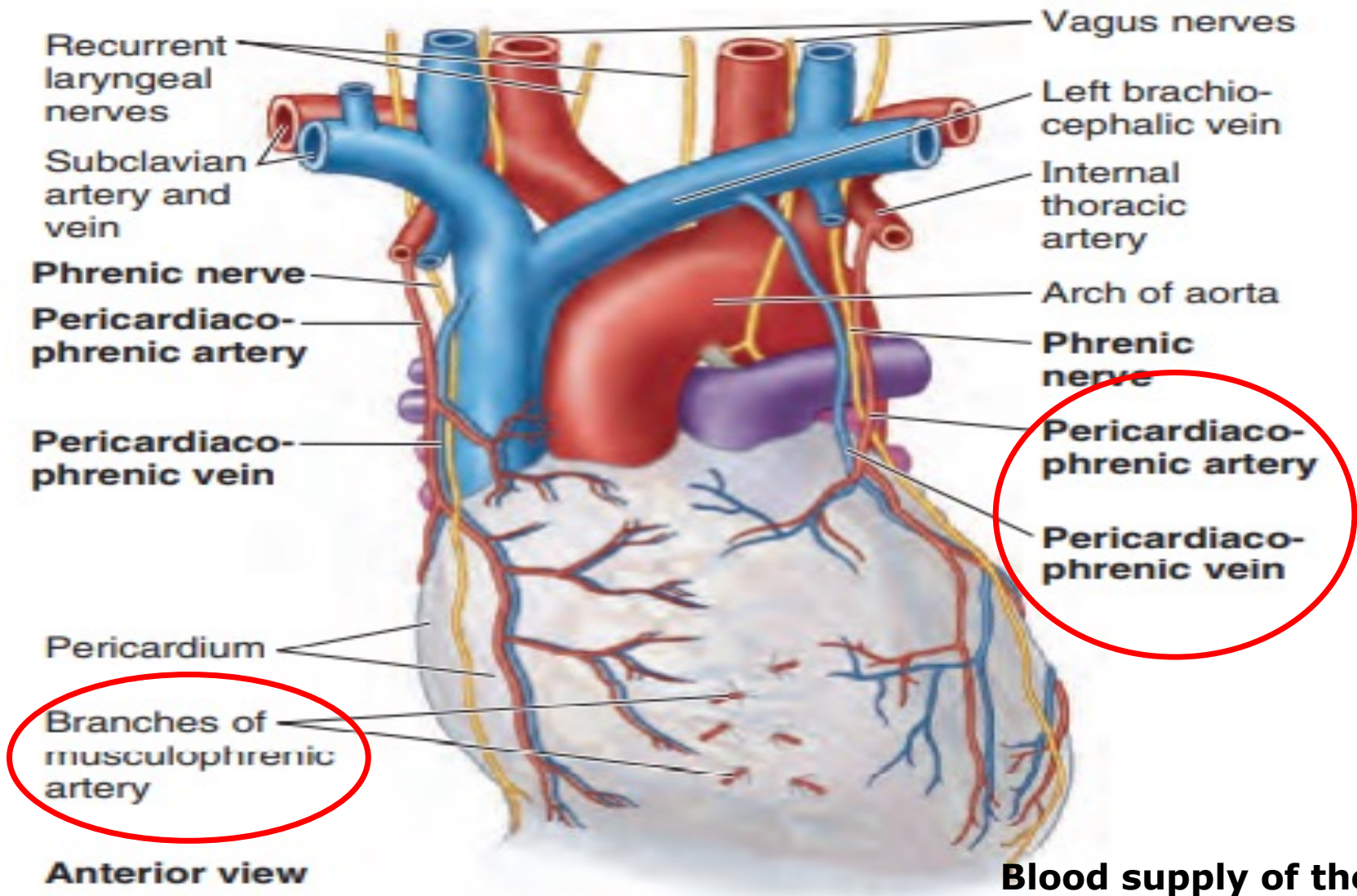
1. Pericardiophrenic artery, which is slender branch of the internal thoracic artery (the main blood supply)

Smaller contributions of blood come from

2. Musculophrenic artery, a terminal branch of the internal thoracic artery.
3. Bronchial, esophageal, and superior phrenic arteries, branches of the thoracic aorta.
4. Coronary arteries (visceral layer of serous pericardium only).

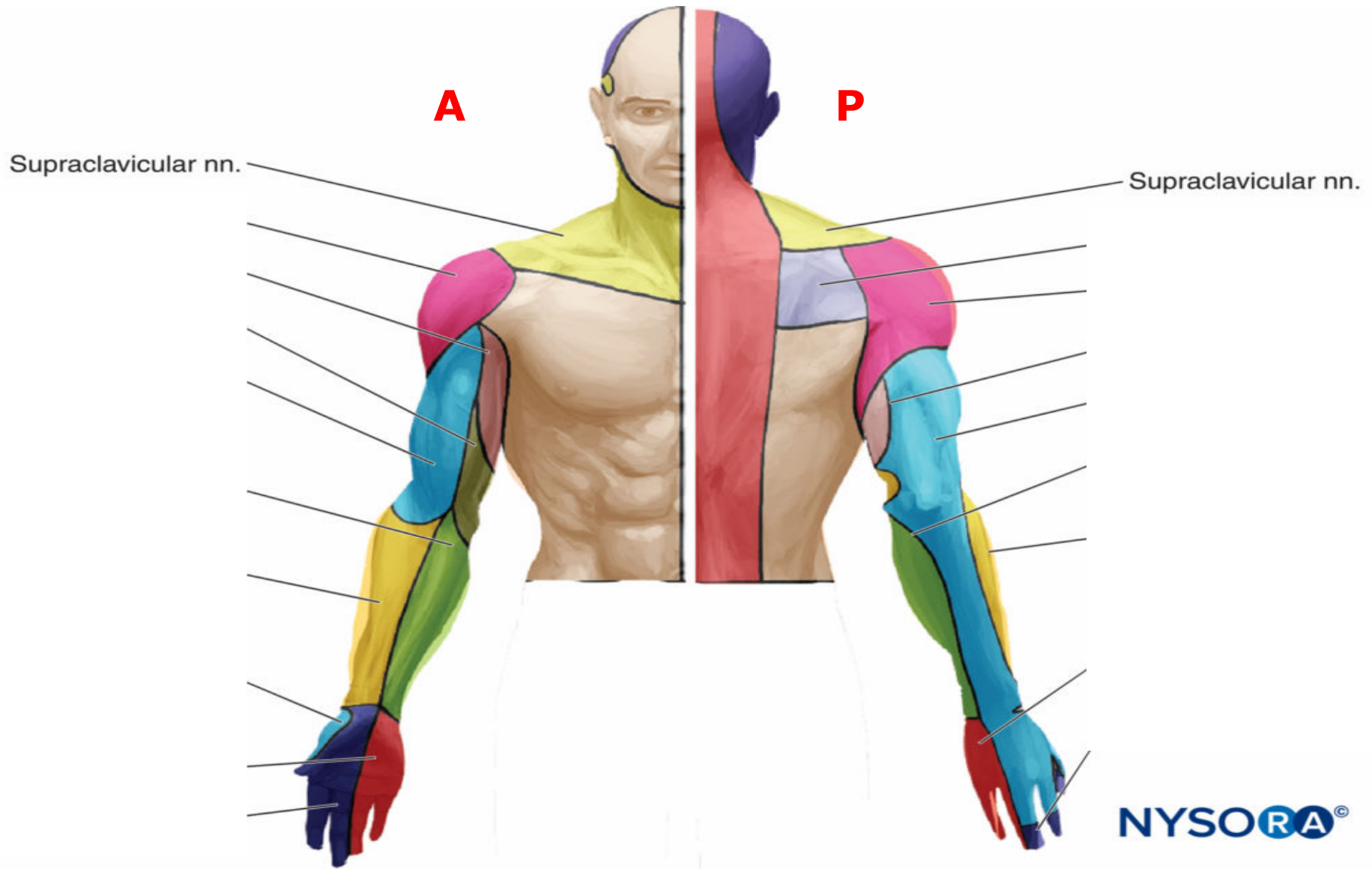
Venous drainage of the pericardium

Pericardiophrenic veins, tributaries of the brachiocephalic (or internal thoracic) veins



Nerve supply of the pericardium

- ❖ The fibrous pericardium and the parietal layer of the serous pericardium are supplied by the phrenic nerves (C3–C5)
- ❖ The visceral layer of the serous pericardium is innervated by branches of the sympathetic trunks and the vagus nerves.
- ❖ Pericardial pain sensations is referred to the skin of the ipsilateral supraclavicular region ,top of the shoulder of the same side ,(C3–C5 dermatomes)
- ❖ C3–C5 dermatomes is supplied by supraclavicular nerves



Pericarditis

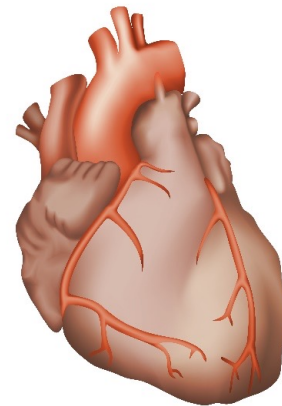
Is inflammation of pericardial sac, which cause chest pain

Pericarditis pain usually occurs behind the breastbone (sternum) or on the left side of the chest.

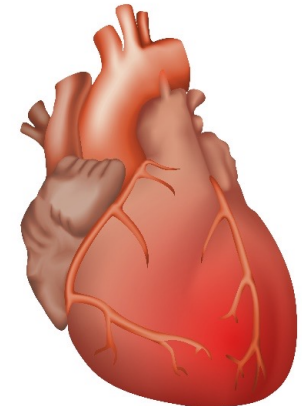
The pain may:

- Spread to the left shoulder and neck
- Get worse when coughing, lying down or taking a deep breath
- Get better when sitting up or leaning forward
- https://www.youtube.com/watch?v=5_EkVuMeNRA

Normal heart



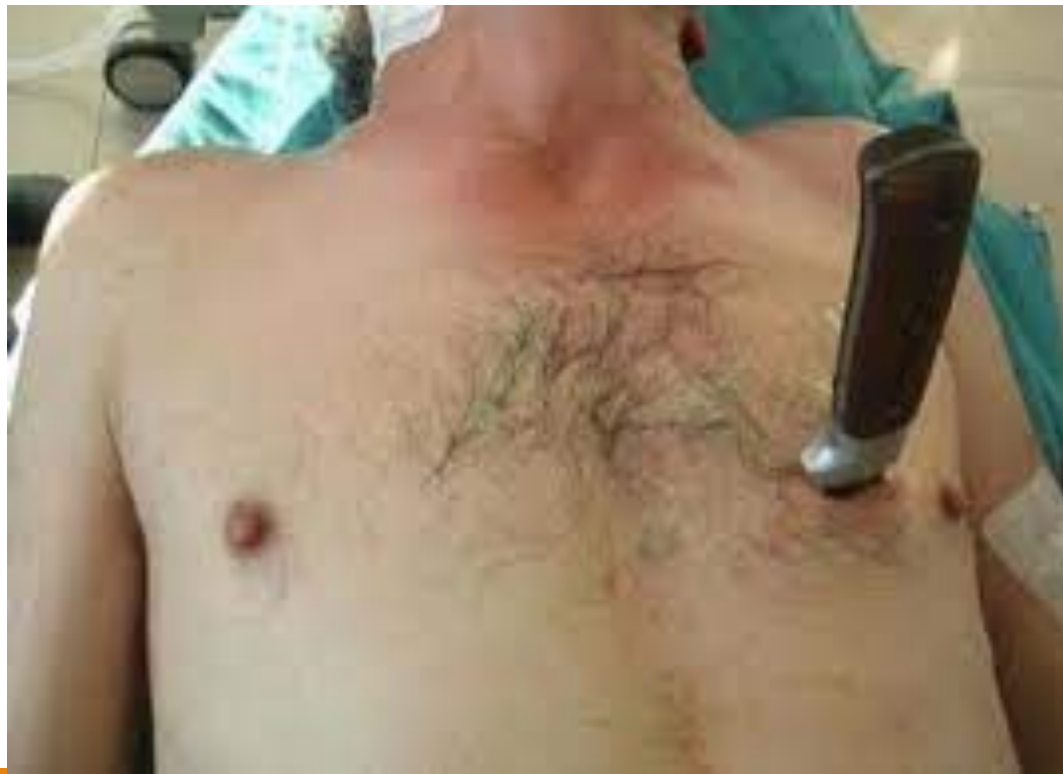Pericarditis



A 25 years old male patient came to emergency by a penetrating wound in his chest wall.

The knife reached the heart and there was a sever bleeding .He died shortly.

What is the common cause of death ?

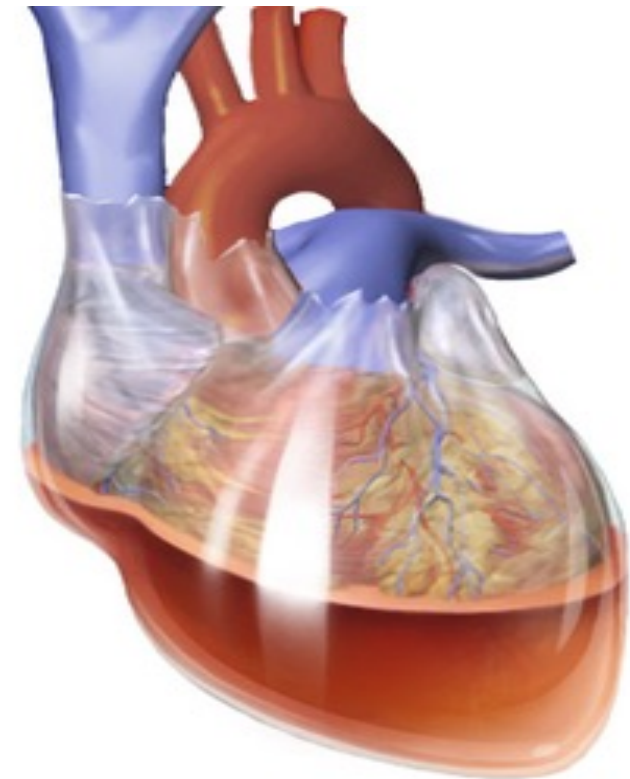
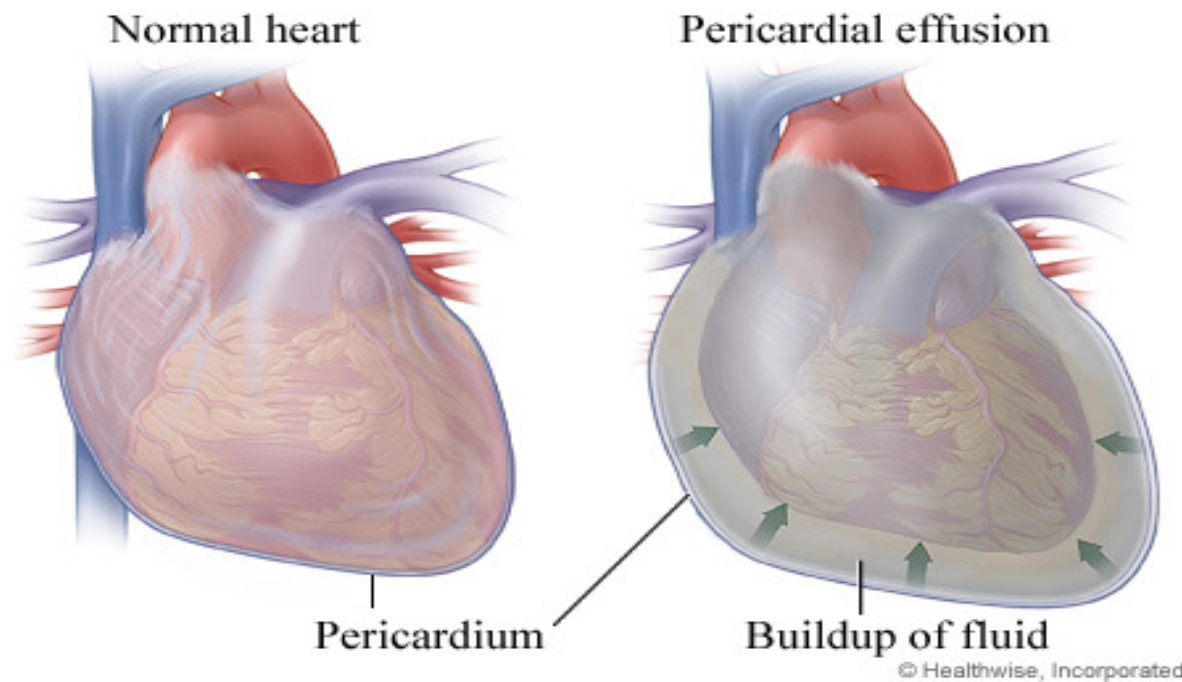


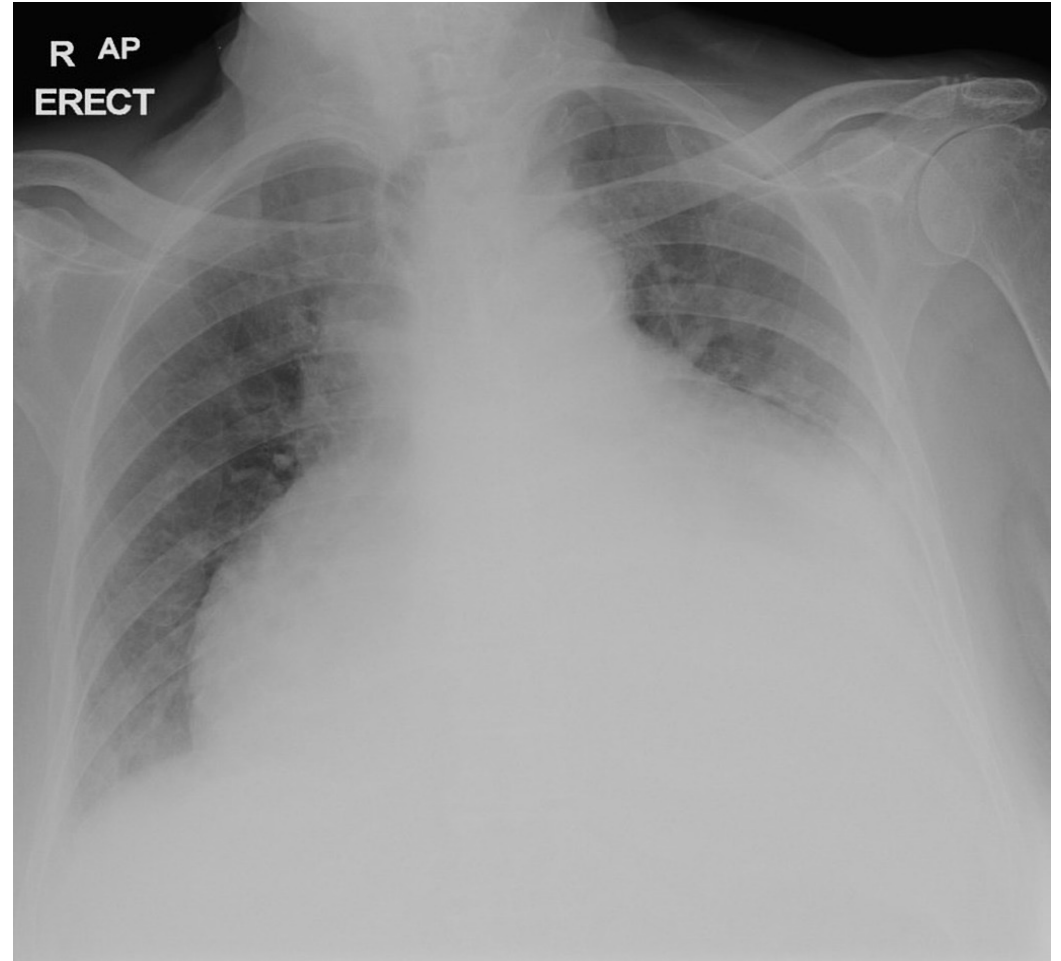
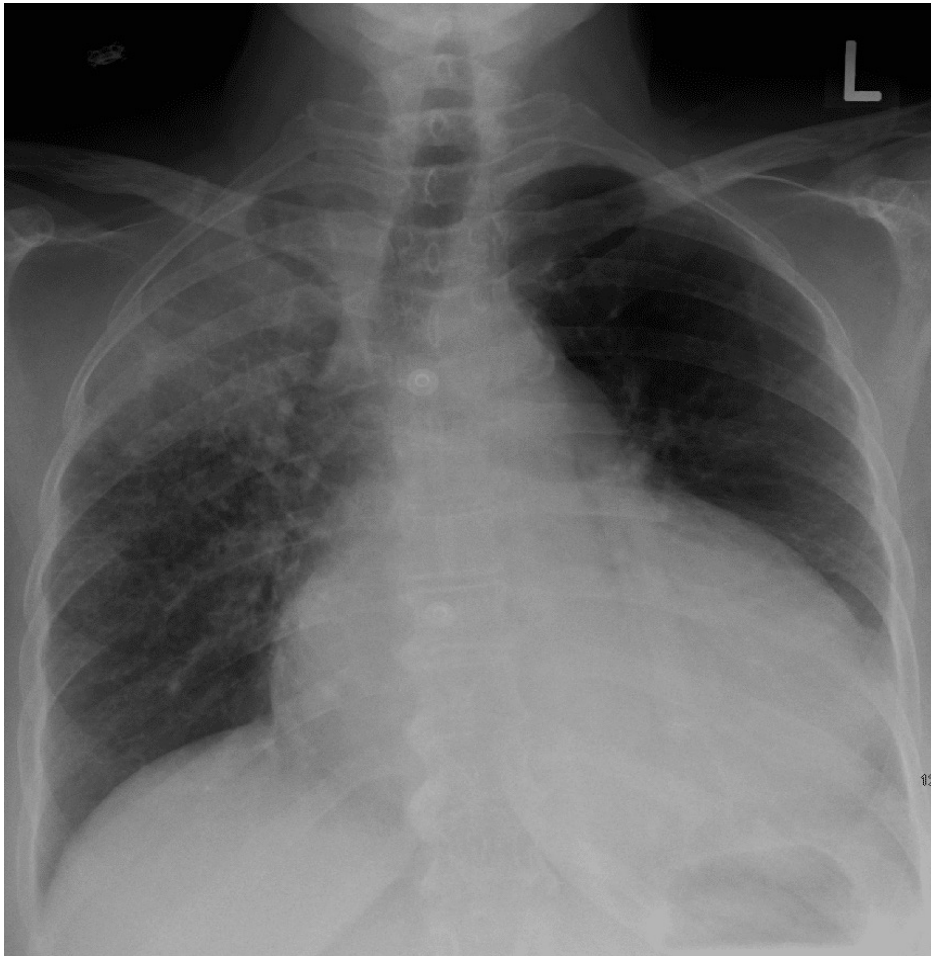
Pericardial effusion

Means increase the fluid between the parietal and visceral layers of the pericardium

Cardiac tamponade

Is a rapid accumulation of excess fluid within the pericardial sac ,which leads to compresses the heart and heart failure.





Chest X ray of Pericardial effusion

Pericardiocentesis: pericardial effusion is usually removed by inserting a needle in the left 5th or 6th intercostal spaces close to the sternum to avoid piercing left lung and pleura.

