



# Cardiovascular System - Pathology Practical 2023-24

**3<sup>rd</sup> year medical students**

Dr. Nisreen Abu Shahin

*It has been modified by*

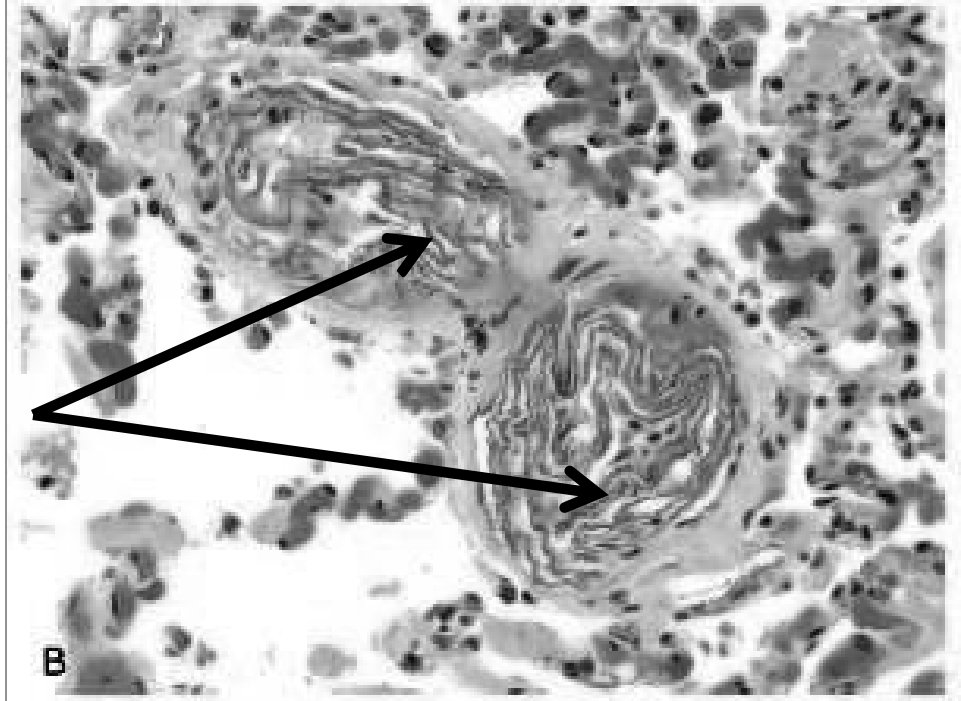
*Reenas Al - Khresat*

A 26 years old pregnant woman had a complicated Caesarian section. 12 hours after delivery of her baby, she started to develop shortness of breath, decreased consciousness, and seizures. She died a few hours later. Autopsy was performed. This is a microscopic section from her lung. What is the most likely cause of her death?

Amniotic fluid embolus: keratin and fetal squamous epithelial cells in pulmonary arterioles

- High Mortality Rate
- Very rare complication of labor
- Occurs as a result of infusion of amniotic fluid into maternal circulation via tears in placental membranes and rupture of uterine veins.

Microscopic Findings upon autopsy:  
fetal squamous cells, lanugo hair, fat, mucin  
microcirculation

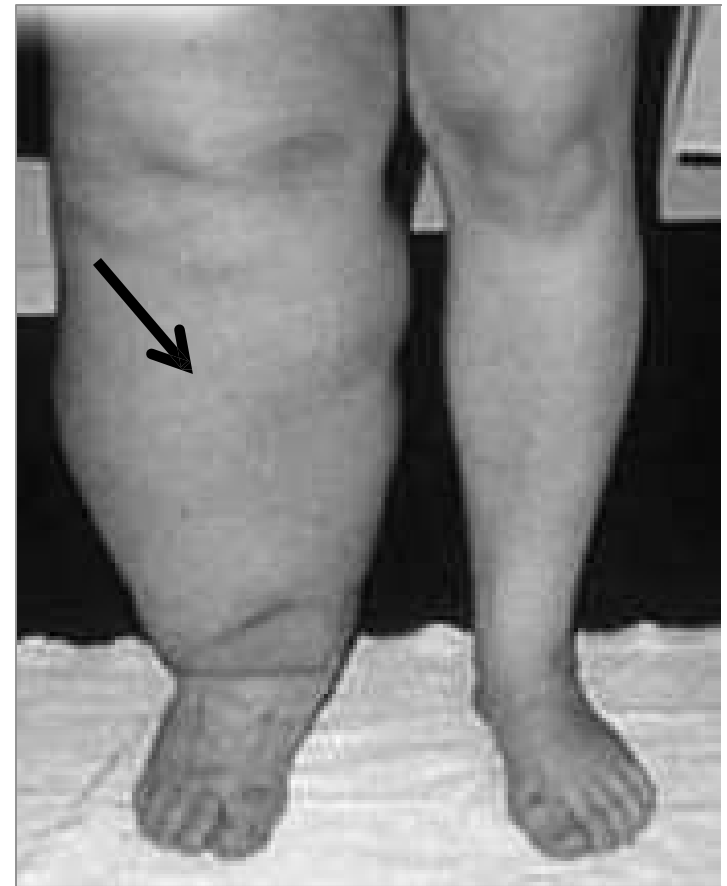

Additional notes from SLIDES ONLY !!!

# Lymphedema

Types? Give examples on causes :

- 1-Primary: congenital  
( example is cystic hygroma)
- 2- secondary: neoplasms filariasis;  
fibrosis; post treatment effect .....



- 1- Primary (congenital) lymphedema → lymphatic agenesis or hypoplasia (underdeveloped).  
2- Secondary (obstructive) lymphedema → blockage of a previously normal lymphatic

Additional notes from SLIDES ONLY ! !

Examples (on causes that might lead to secondary lymphedema include) :

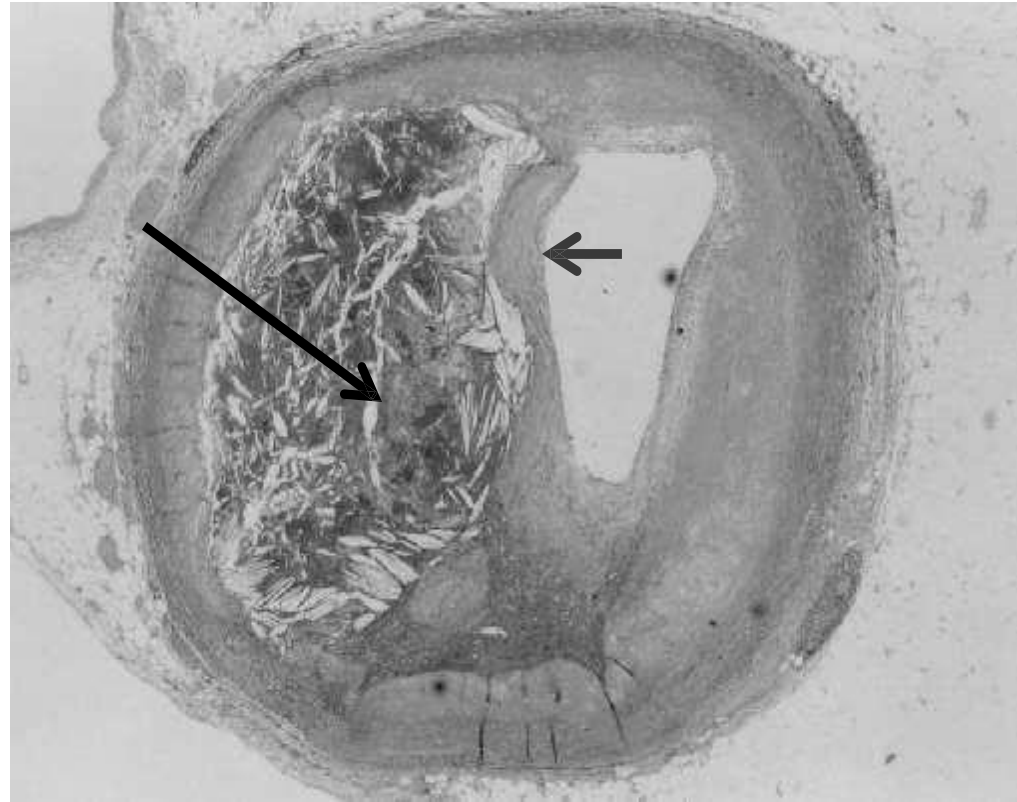
- Malignant tumors
- Surgical procedures removing lymph nodes (e.x: the surgical procedure that is used to treat breast cancer which includes removal of the tumor, breast tissue and the ipsilateral axillary lymph node)
- Post-irradiation
- Fibrosis at the site of the affected lymphatic
- Filariasis (parasitic infection that leads to inflammation)
- Postinflammatory thrombosis and scarring

# Atherosclerosis- atheroma

Red arrow?  
Fibrous cap

**black arrow?** lipid  
or necrotic center

What do the whitish  
needle- like structures  
represent?  
Cholesterol crystals



- The white area is the remaining part of the lumen which is very small
- Atheromatous plaque = raised lesion with a core of lipid (cholesterol and cholesterol esters) covered by a firm, white fibrous cap

Additional notes from SLIDES ONLY !!!

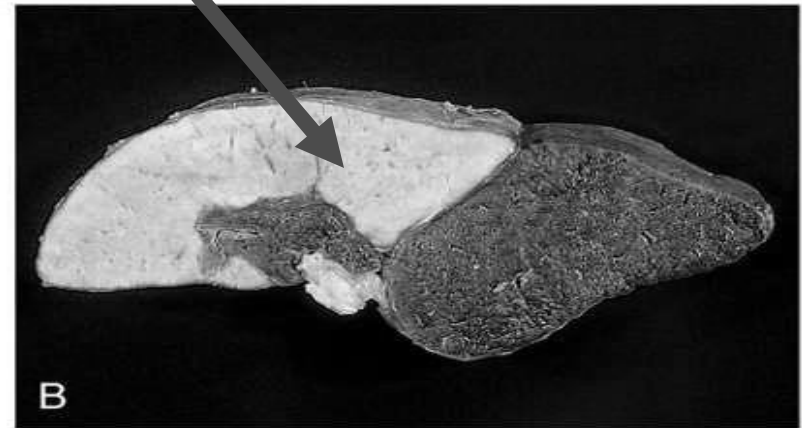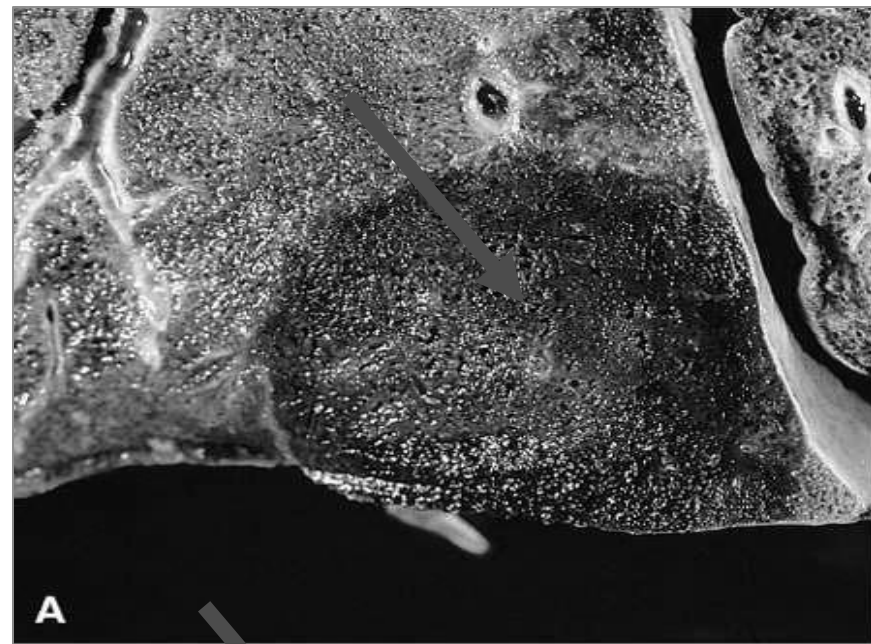
# Infarction

lung (A), and spleen (B)

What type of infarct do you see in

A? red

B? white



© Elsevier. Kumar et al: Robbins Basic Pathology 8e - www.studentconsult.com

## RED INFARCTS (congested with blood): ●

- occur in any of the following scenarios:
  - (1) venous occlusions (e.g. ovarian torsion)
  - (2) loose tissues (e.g. lung)
  - (3) tissues with dual circulations (e.g. lung and small intestine)
  - (4) previously congested tissues: develops because of sluggish venous outflow
  - (5) when flow is re-established to a site of previous arterial occlusion and necrosis

## WHITE INFARCTS: ●

(small amount of blood or no blood at all)

- Occur with: Arterial occlusions in Solid organs (such as heart, spleen, and kidney).

Additional notes from SLIDES ONLY !!!

# Aortic aneurysm

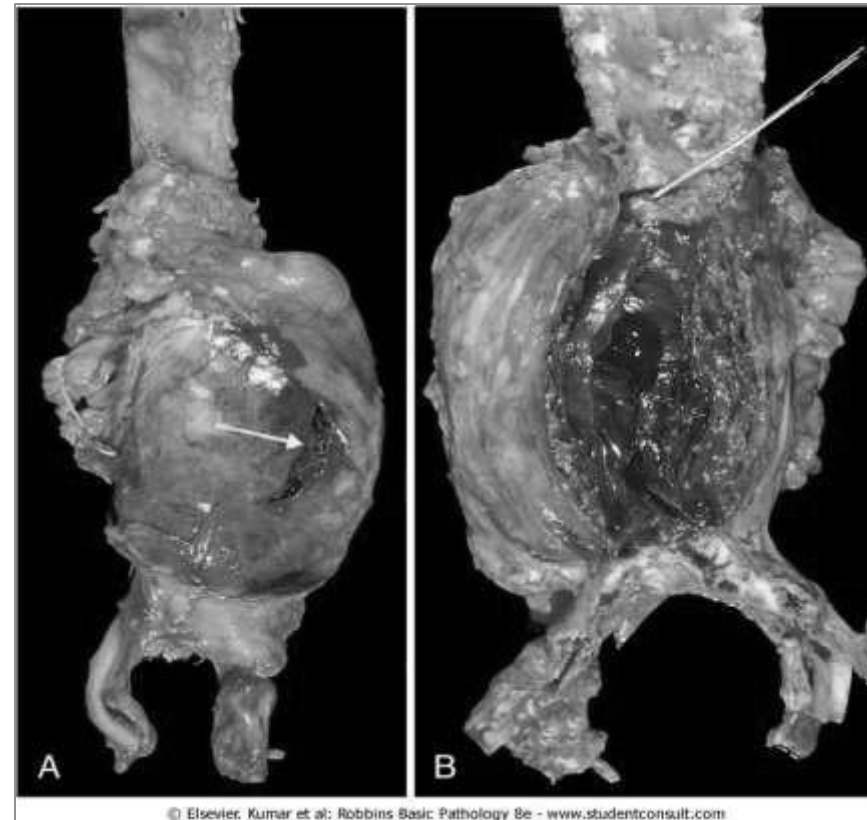
What part of aorta is involved ?  
abdominal

Name complications that you recognize in :

Picture A, white arrow? rupture  
picture B? thrombosis

- 1- m/c in men
- 2- rarely < age 50
- 3- Atherosclerosis is a major cause of AAA

Usually below renal arteries and above bifurcation of aorta can be saccular or fusiform



Additional notes from SLIDES ONLY !!!

# Aortic dissection

A microscopic section from the aorta:

The special histochemical stain in this microscopic section of aorta shows elastic fibers in black color.

What is the most likely diagnosis?  
Aortic dissection

What does the star represents?  
Blood collecting within the media

Name a major precipitating factor ?  
hypertension



Complications are :  
- massive hemorrhage  
-Cardiac tamponade (hemorrhage into the pericardial sac)

Additional notes from SLIDES ONLY !!!

## Pathogenesis

- 1- Hypertension is the major risk factor
  - pressure-related mechanical injury and/or ischemic injury to the arterial wall
- 2- inherited or acquired connective tissue disorders causing abnormal vascular ECM
  - (e.g., Marfan syndrome, Ehlers-Danlos syndrome, vitamin C deficiency, copper metabolic defects)

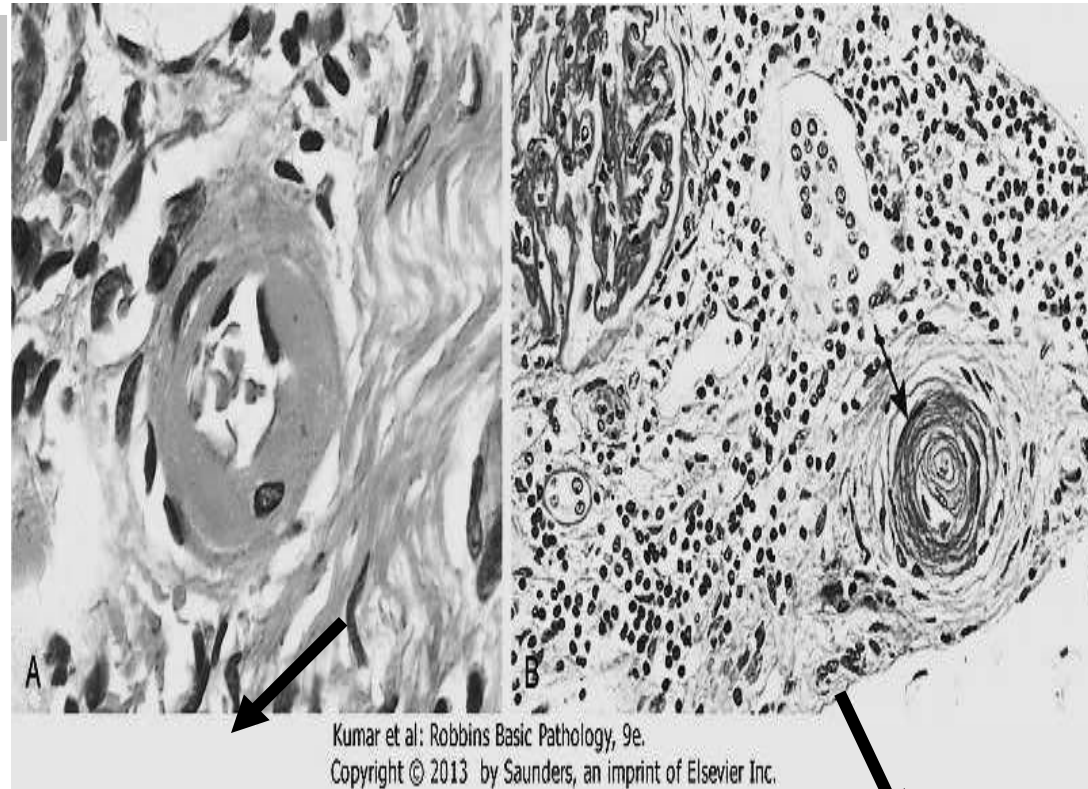
# Arteriolosclerosis: types

arrow in A? hyaline  
arteriolosclerosis  
causes? HTN, DM,  
Aging

arrow in B?

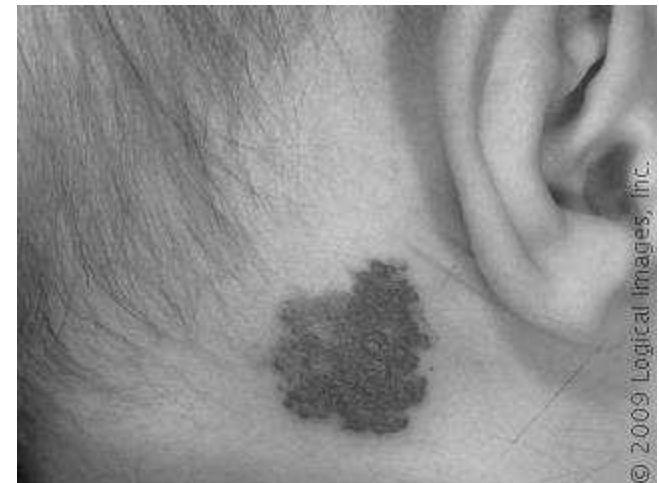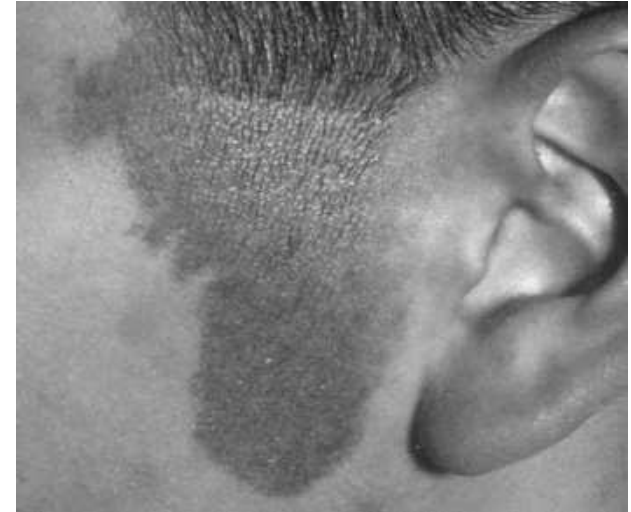(onion skin)  
Hyperplastic  
arteriolosclerosis

causes? Malignant  
HTN





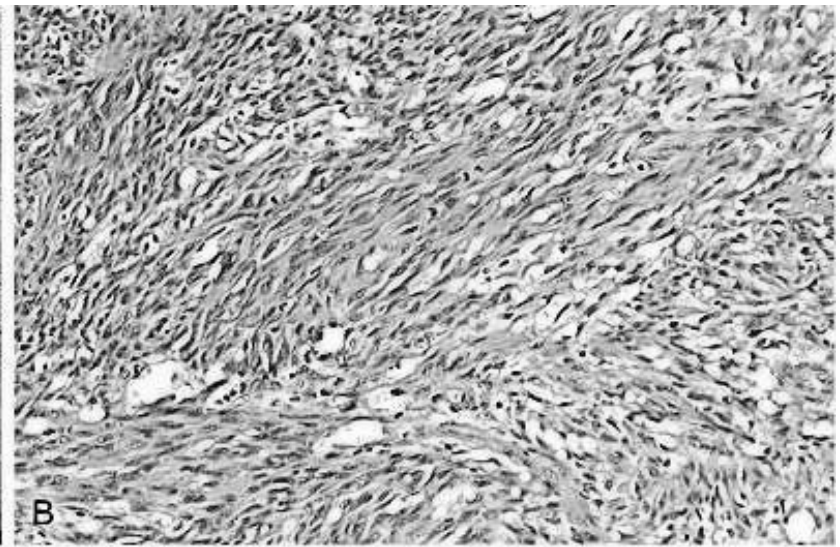
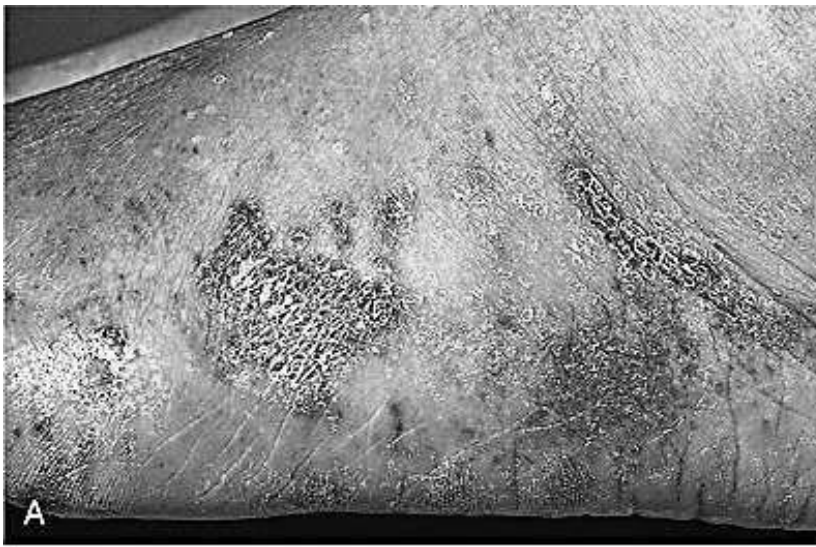A lady is bringing her 1- year old baby girl to a paediatrics clinic. She is worried about a reddish lesion that is present posterior to the baby's ear. The mother describes the lesion as a blood colored plaque, present since birth, and its colour is fading as the baby grows up. What is the most likely diagnosis? Strawberry hemangioma of newborn



strawberry hemangiomas of newborn (juvenile hemangioma):

- m/c head & neck
- Usually regress with time

Additional notes from SLIDES ONLY ! !



Kumar et al: Robbins Basic Pathology, 9e.  
Copyright © 2013 by Saunders, an imprint of Elsevier Inc.

A 38 years old (HIV + ) man is going to a dermatologist complaining of multiple red-purple skin plaques and nodules on his feet; he said that the skin lesions increased in size and number and spread proximally overtime. Below are pictures of the lesions (A) and microscopic features (B). What is the most likely diagnosis?

Kaposi sarcoma

#### Kaposi Sarcoma (KS)

- Avascular neoplasm caused by human herpesvirus- 8 = HHV-8.
- AIDS-associated (epidemic) KS is an AIDS-defining illness (used as a criterion for diagnosis of AIDS).
- The most common HIV-related malignancy .
- Multiple red-purple skin plaques or nodules, usually on the distal lower extremities; progressively increase in size and number and spread proximally.