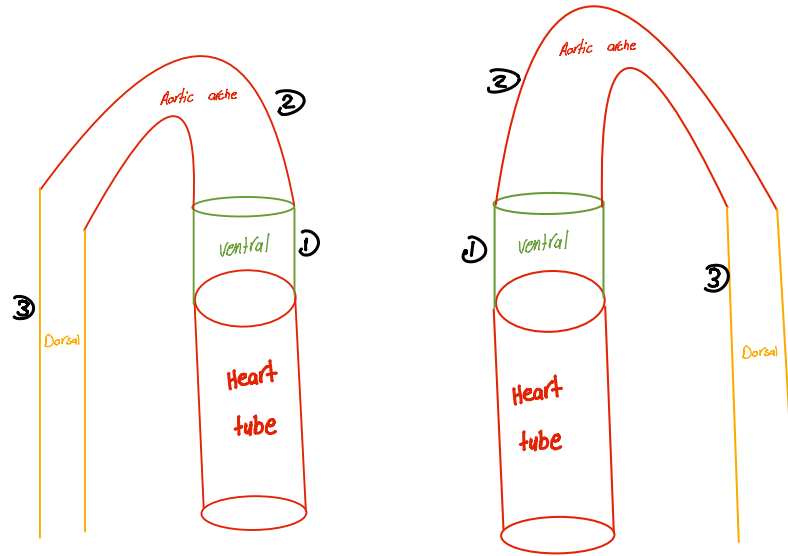
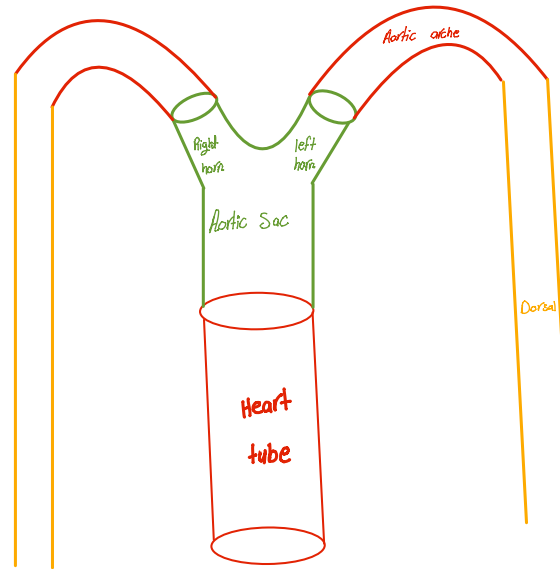


بالبدایة خالص یبقی مندی 2 Heart tube جن Heart tube من دون بیطلی منہا Aorta احنہ بنقسما لثلاث مناطق

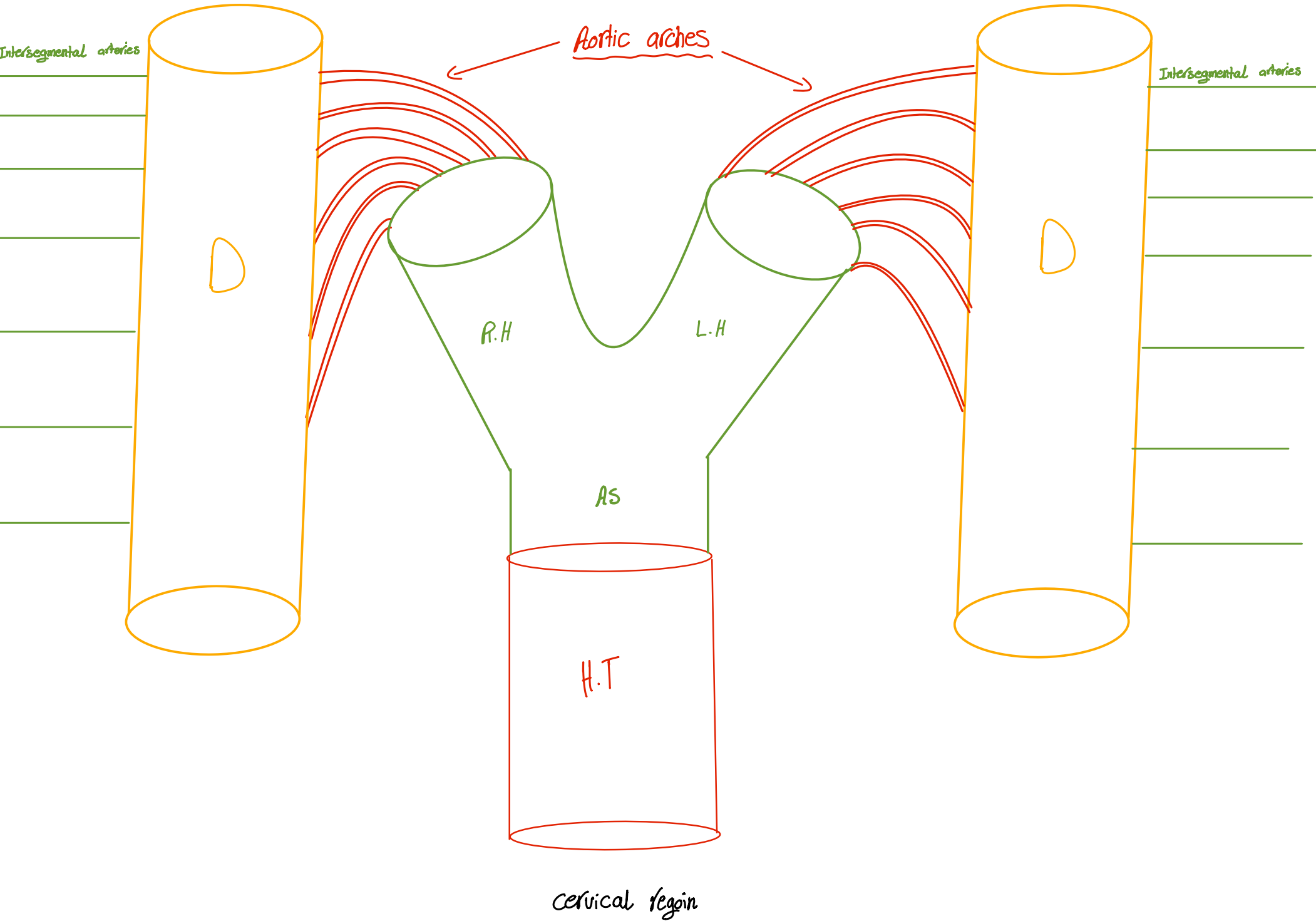


بیمیز اسم fusion to gather



یبقی ال vessels تاغت ال body کلا بیطلی من ثلاث اماکن Aortic sac , Aortic arch , Dorsal aorta

طبعا مينه بمثل الـ H.T آخر حاجة من الـ Bulbus cordis الي هي francus arteriosus

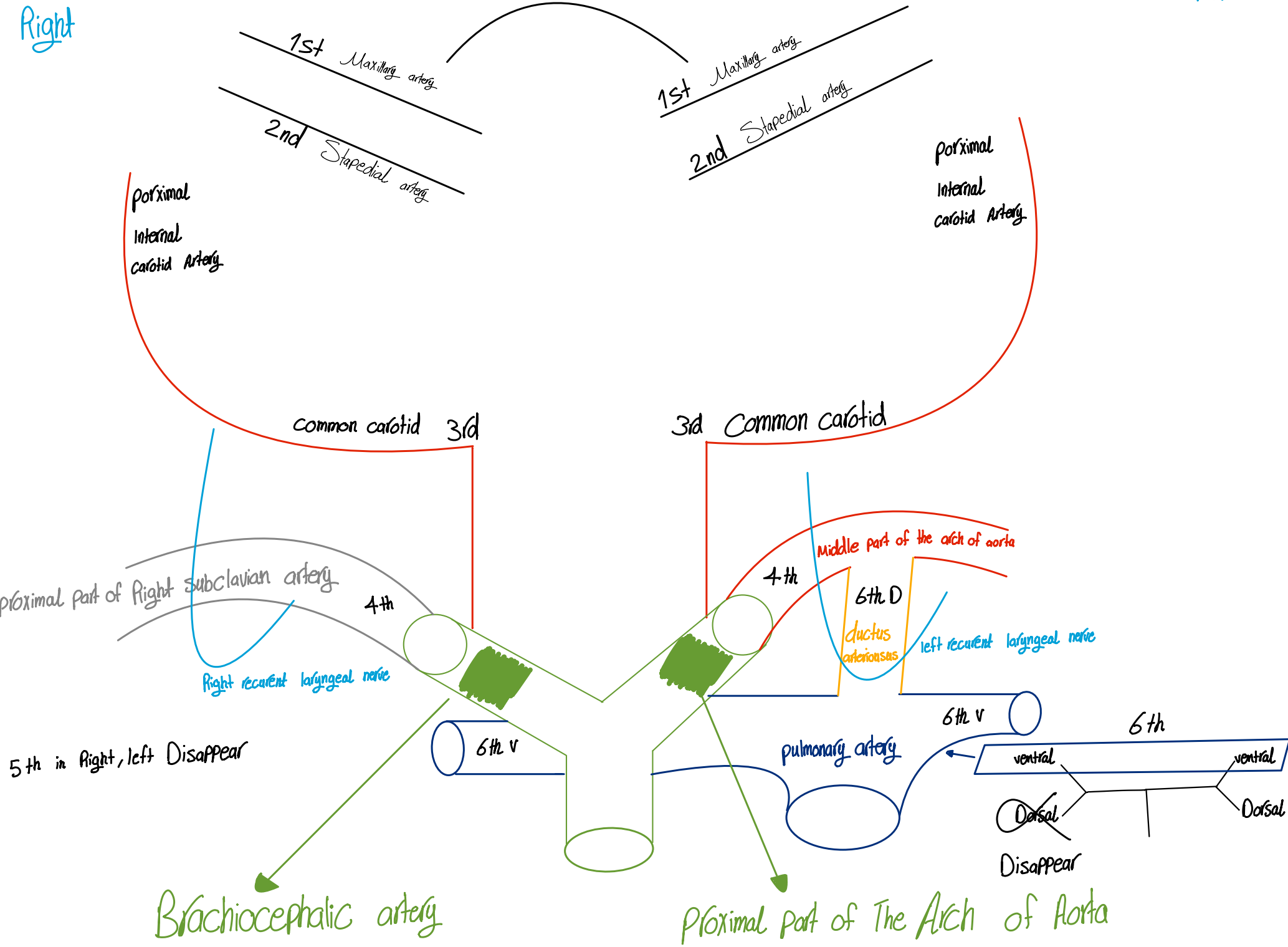


cervical region

Right

left

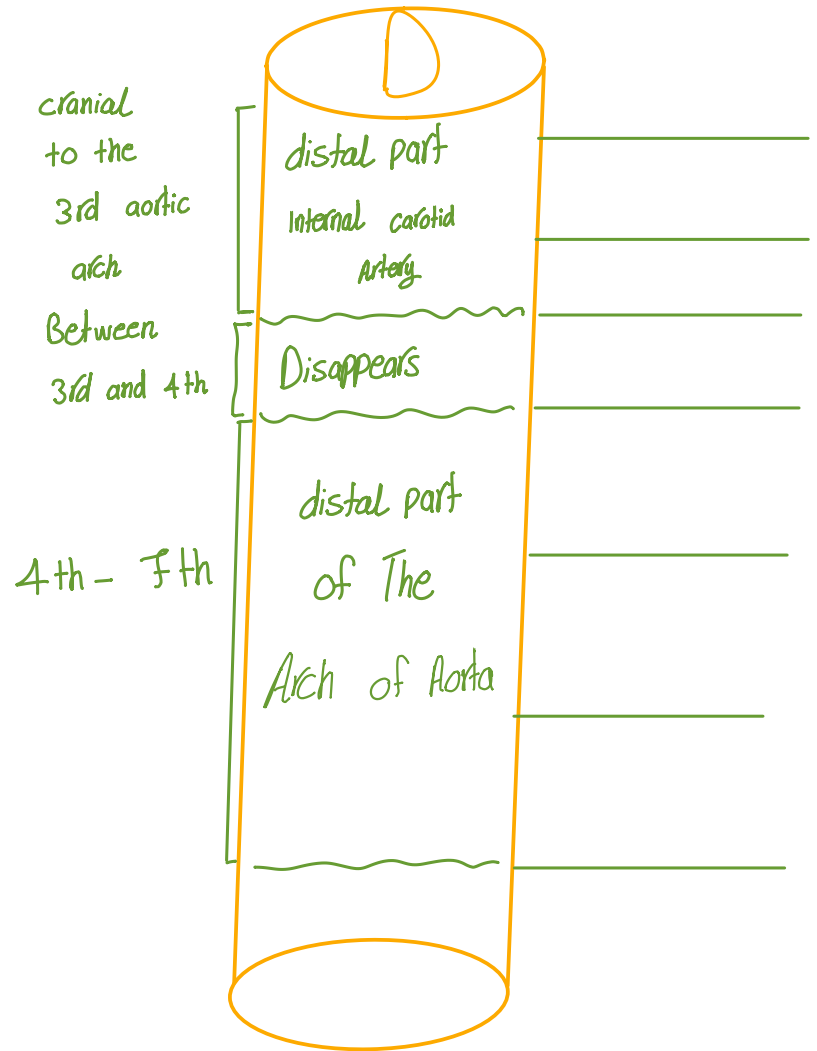
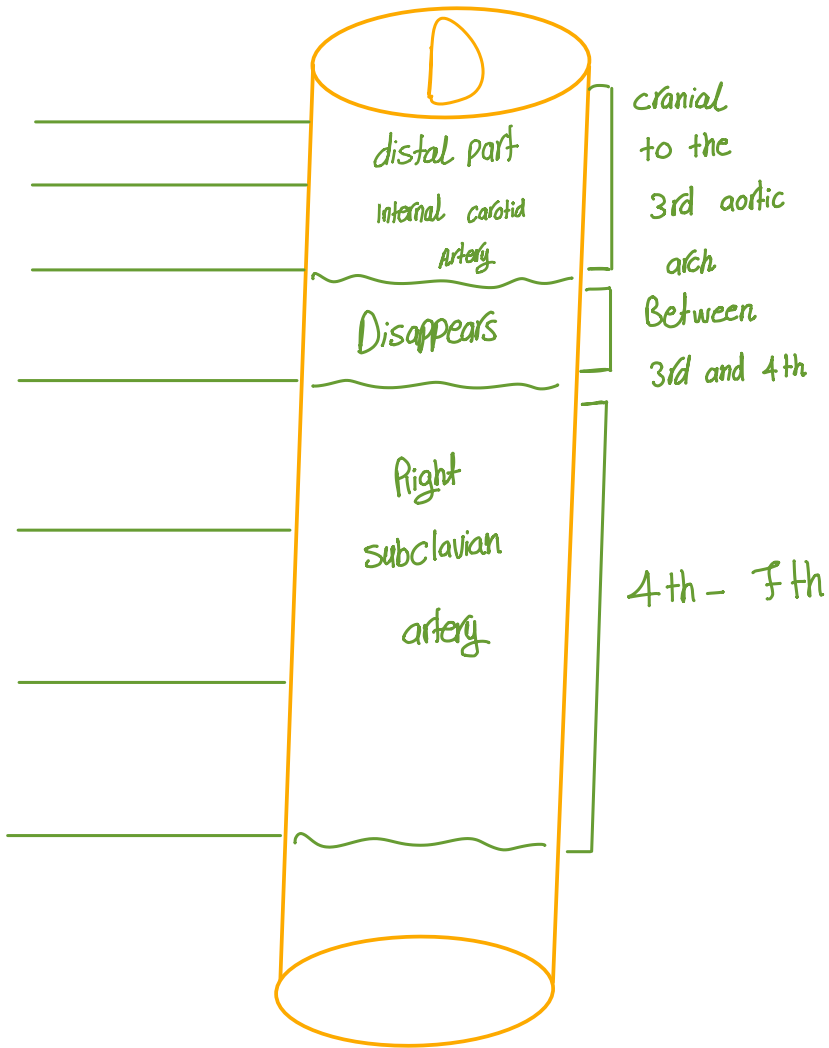
بعدین بختفوا

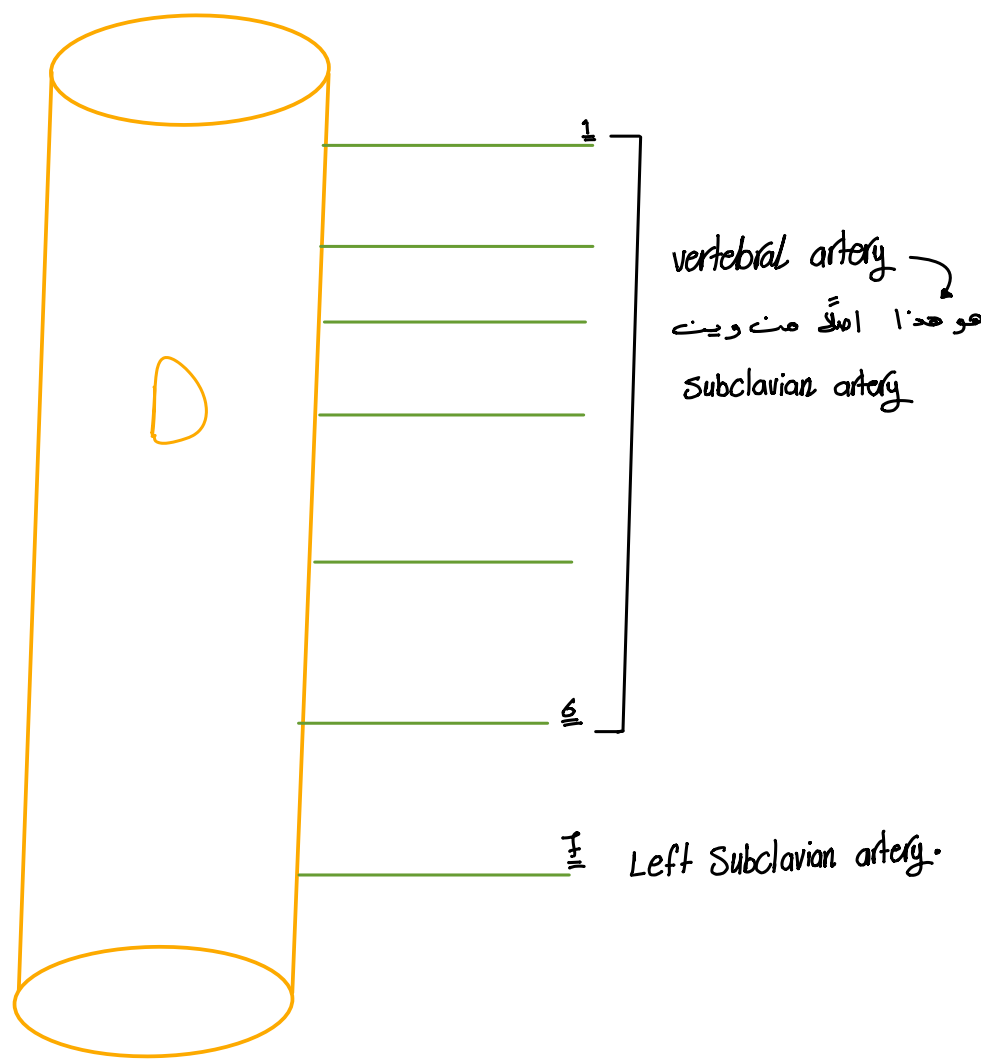
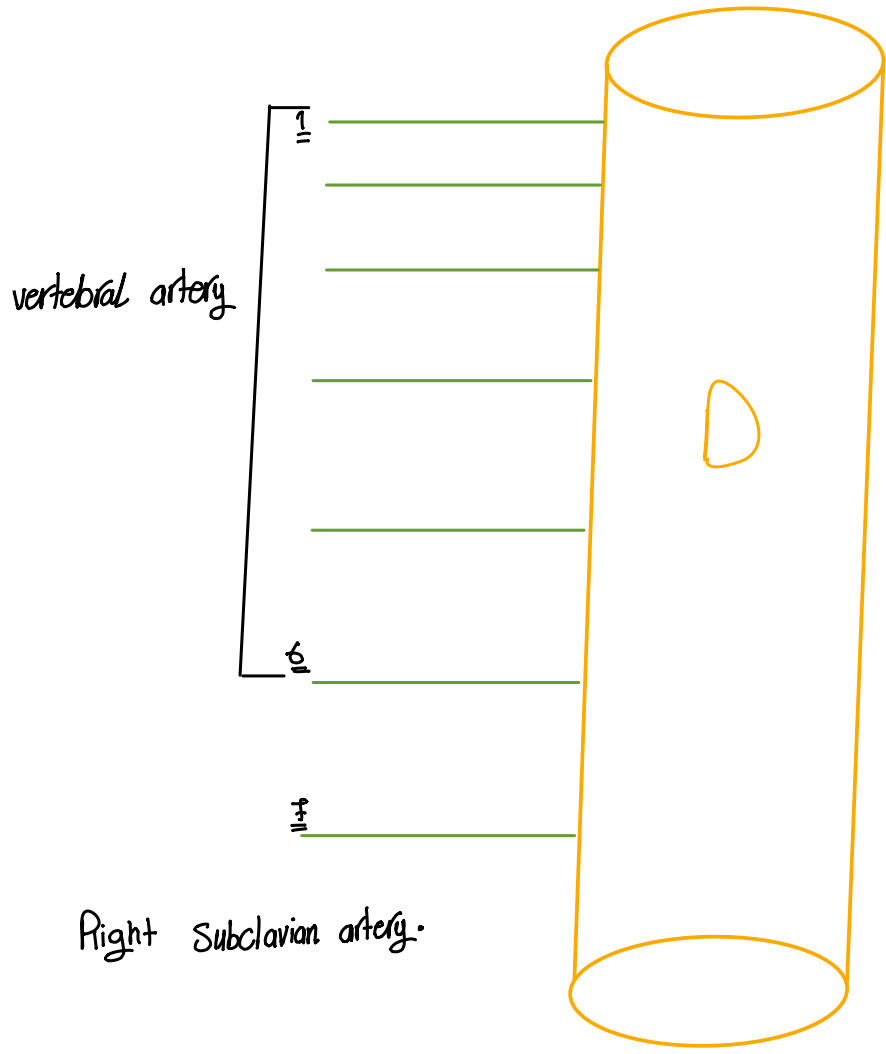


Right

# Dorsal Aorta

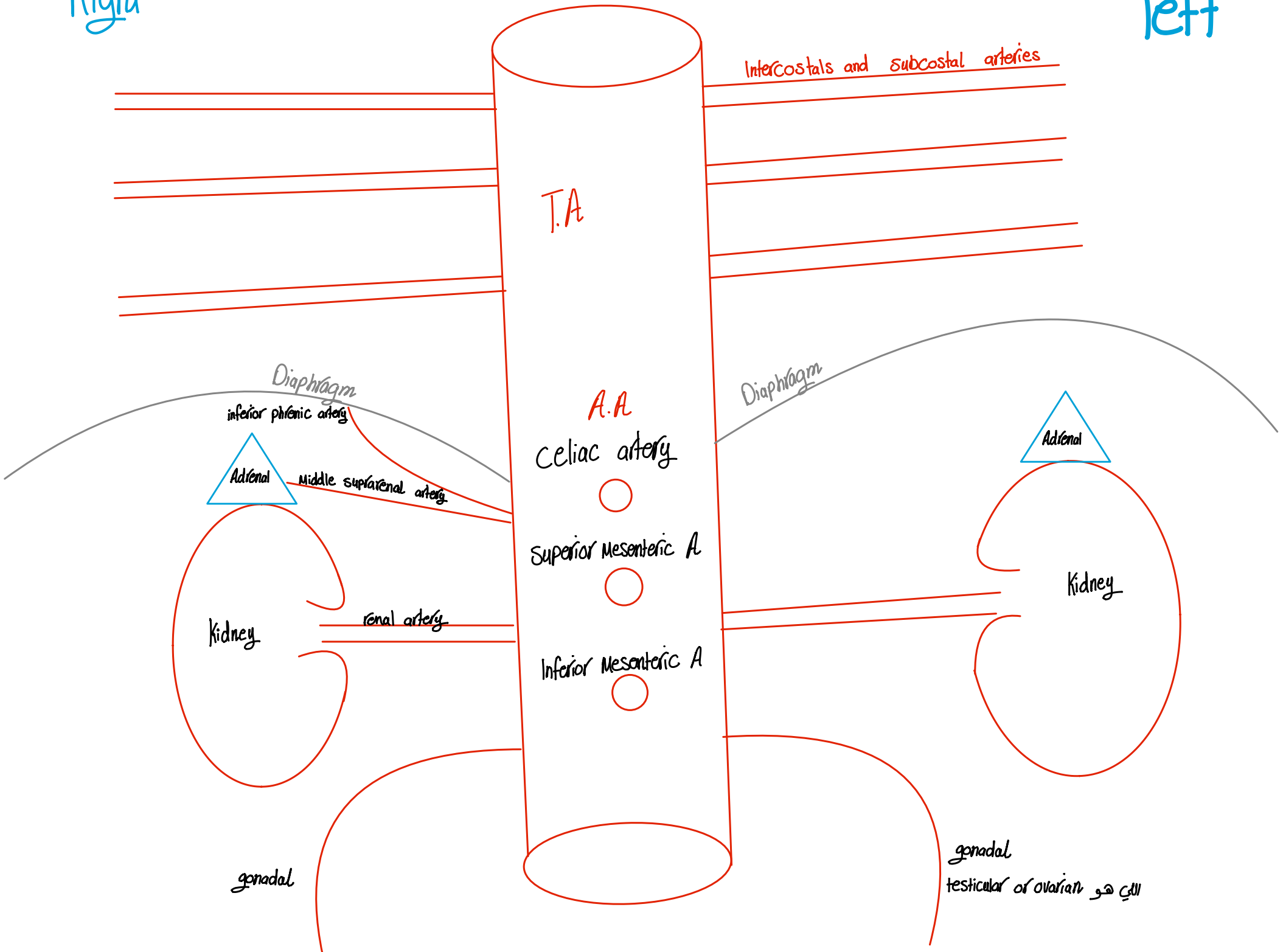
left





Right

left

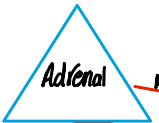

T.A

Intercostals and subcostal arteries

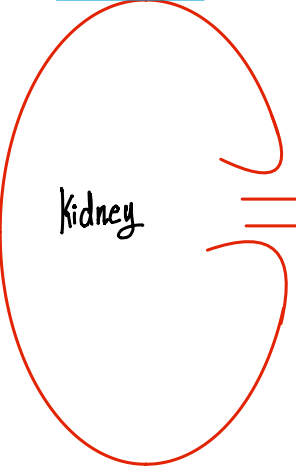
Diaphragm

inferior phrenic artery



Adrenal

middle suprarenal artery



Kidney

renal artery

gonadal

A.A

Celiac artery



Superior Mesenteric A



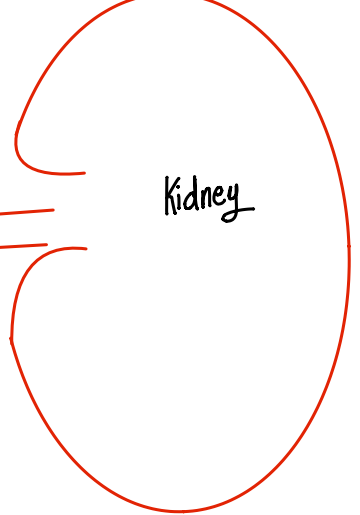
Inferior Mesenteric A



Diaphragm



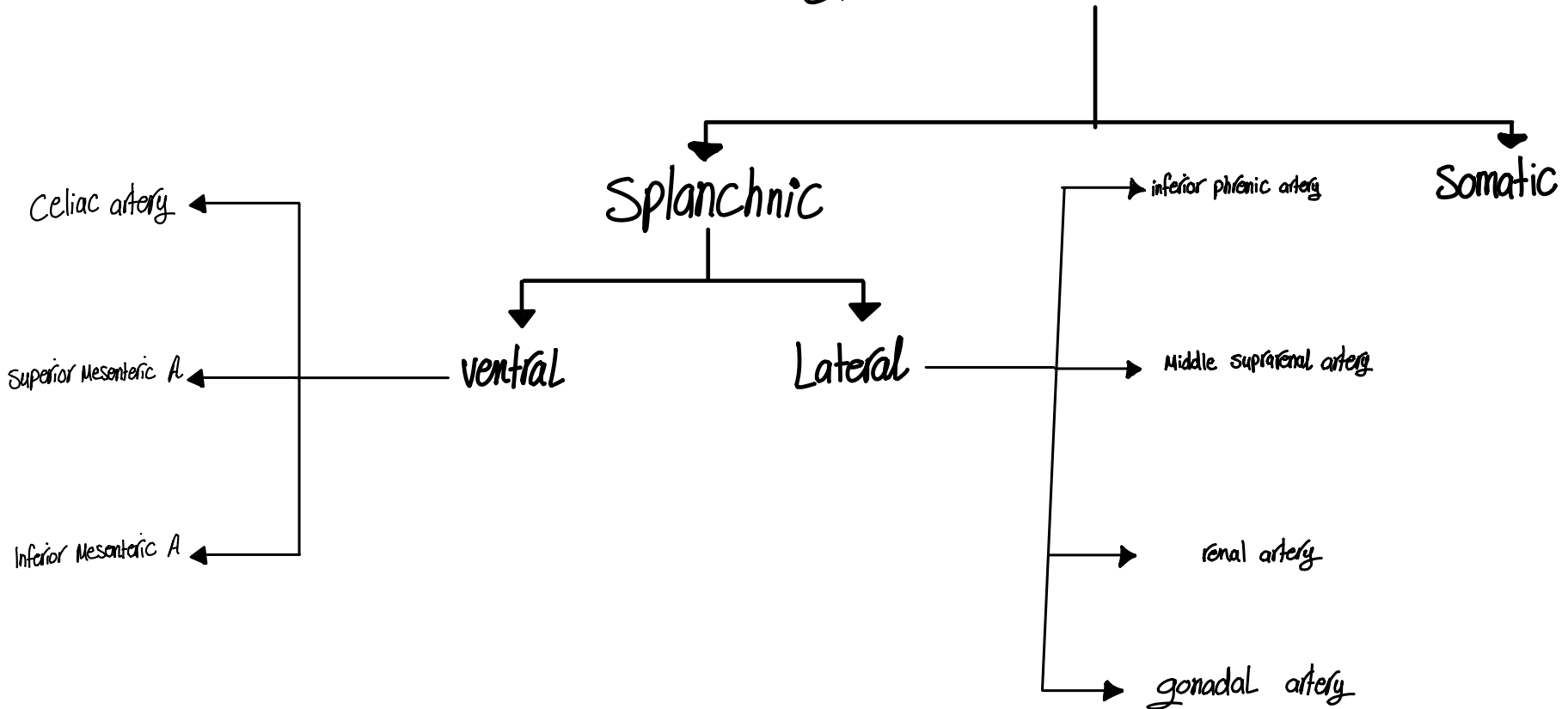
Adrenal



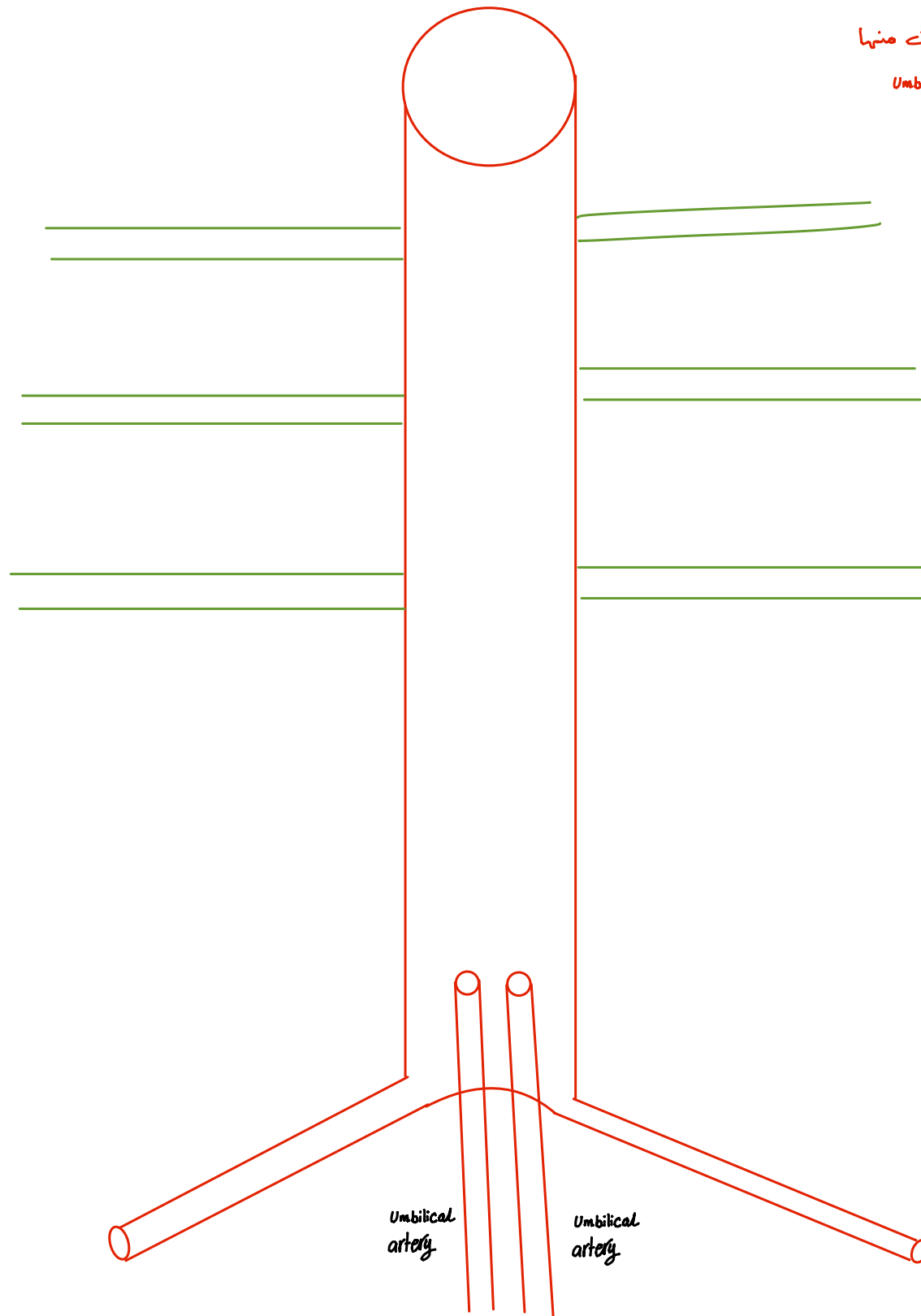
Kidney

gonadal testicular or ovarian  
الذي هو

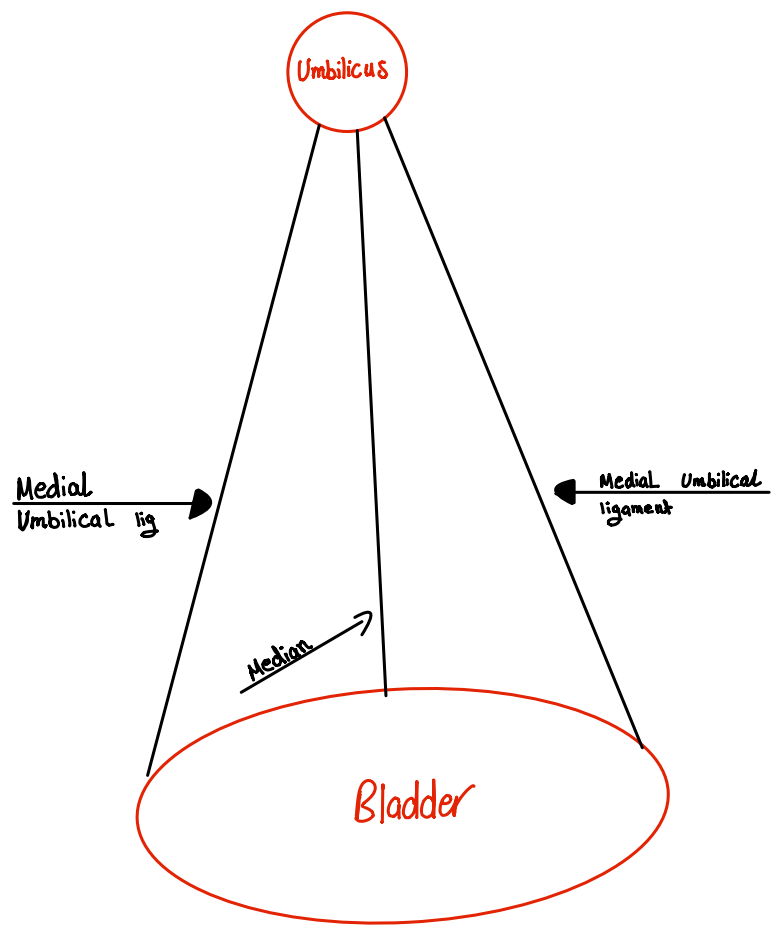
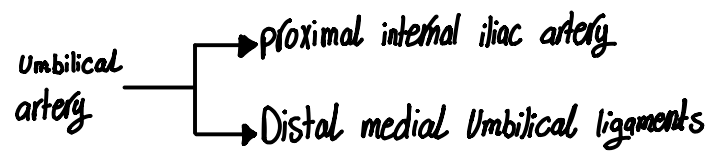
# Branches from dorsal aorta

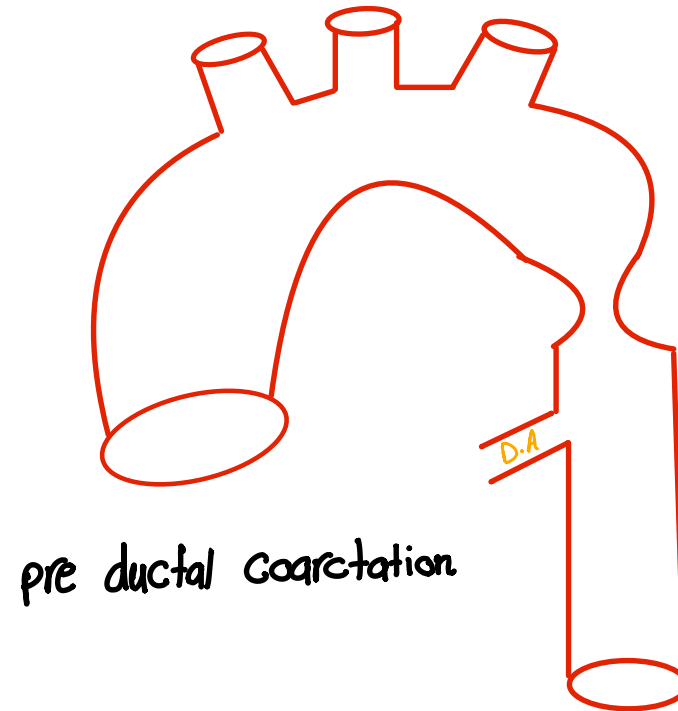
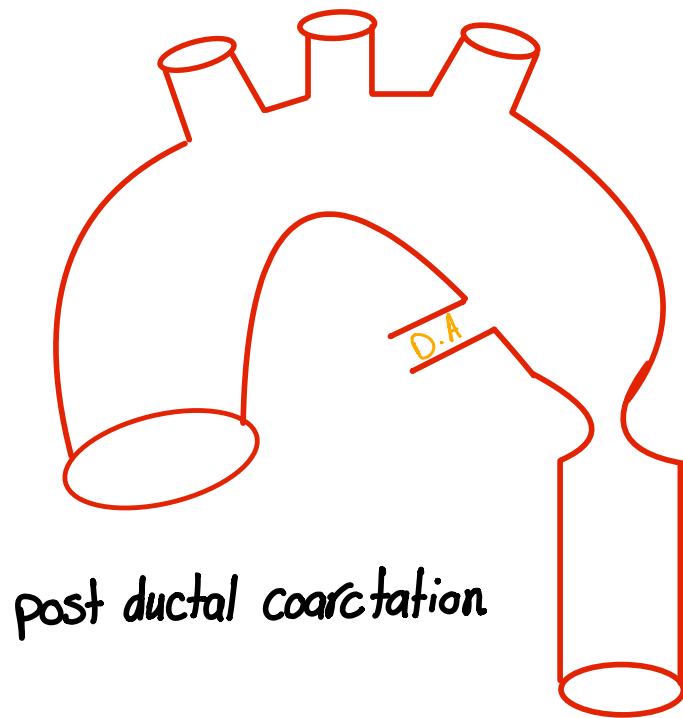


هنا تفاصيل الرسمة انا متأكد انها متمكنة منها  
بسم الدكتور قال اهم اشئ الـ *Umbilical artery*









بس هي مش (ح) تفرق معنا بالحالتيه ميت اللى بتأثر *upper limb or lower* طبيعاً او *lower*

- Clinically, absent or diminished pulses in the femoral arteries of both lower limbs is a sign of aortic coarctation
- To compensate for the diminished volume of blood reaching the lower part of the body, a collateral circulation develops, with dilatation of the internal thoracic, subclavian, and posterior intercostal arteries.
- The dilated intercostal arteries erode the lower borders of the ribs, producing characteristic notching, which is seen on radiographic examination



Molham Heissat @Heissat02 · 22s

...

عندما أتأملك، أجد أن عيني تخوض نزهة حقيقية بين تفاصيلك



ملهم محمد حياضك