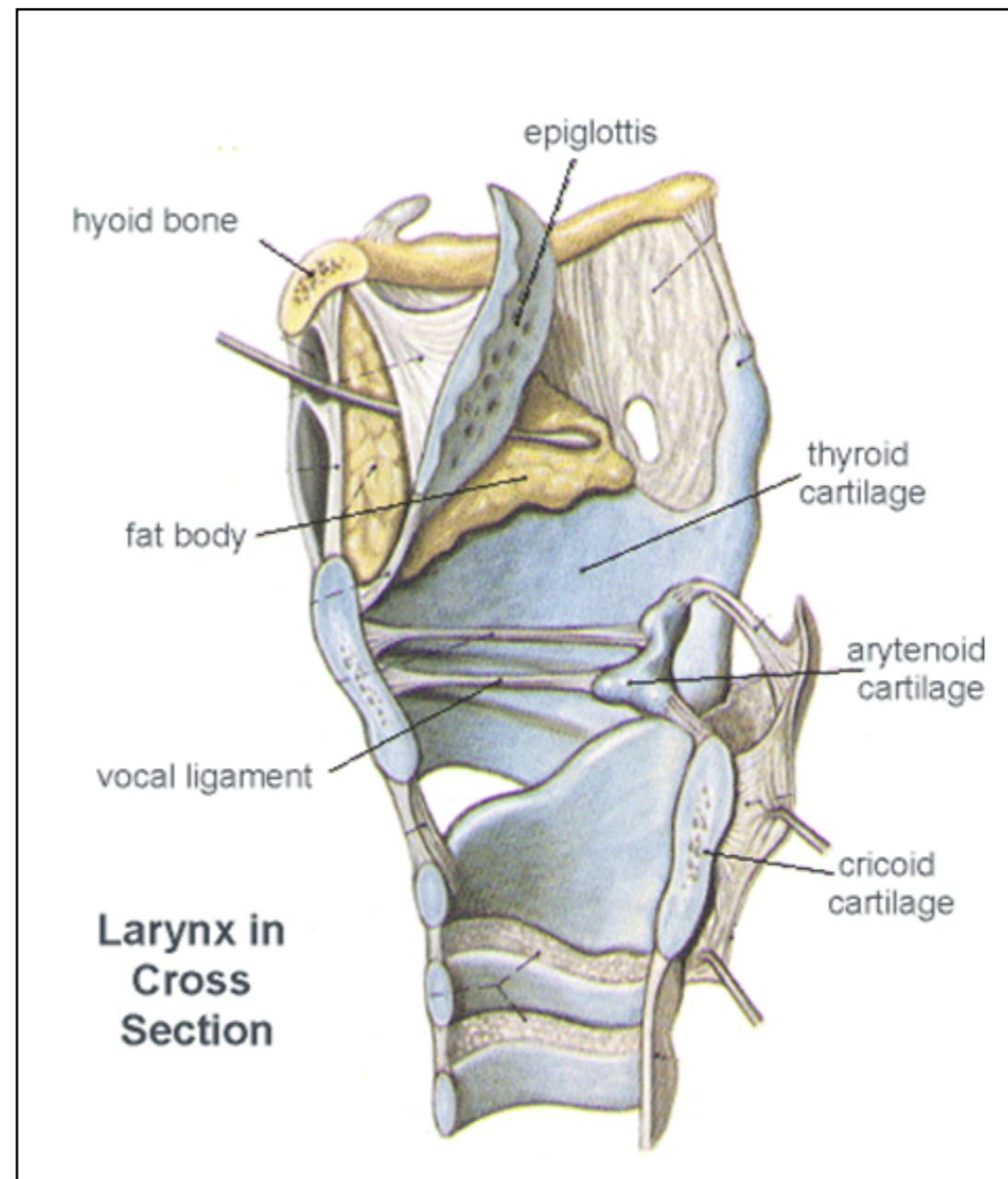


Lab / Second Week

- 1. Larynx.**
- 2. Vocal Cord.**

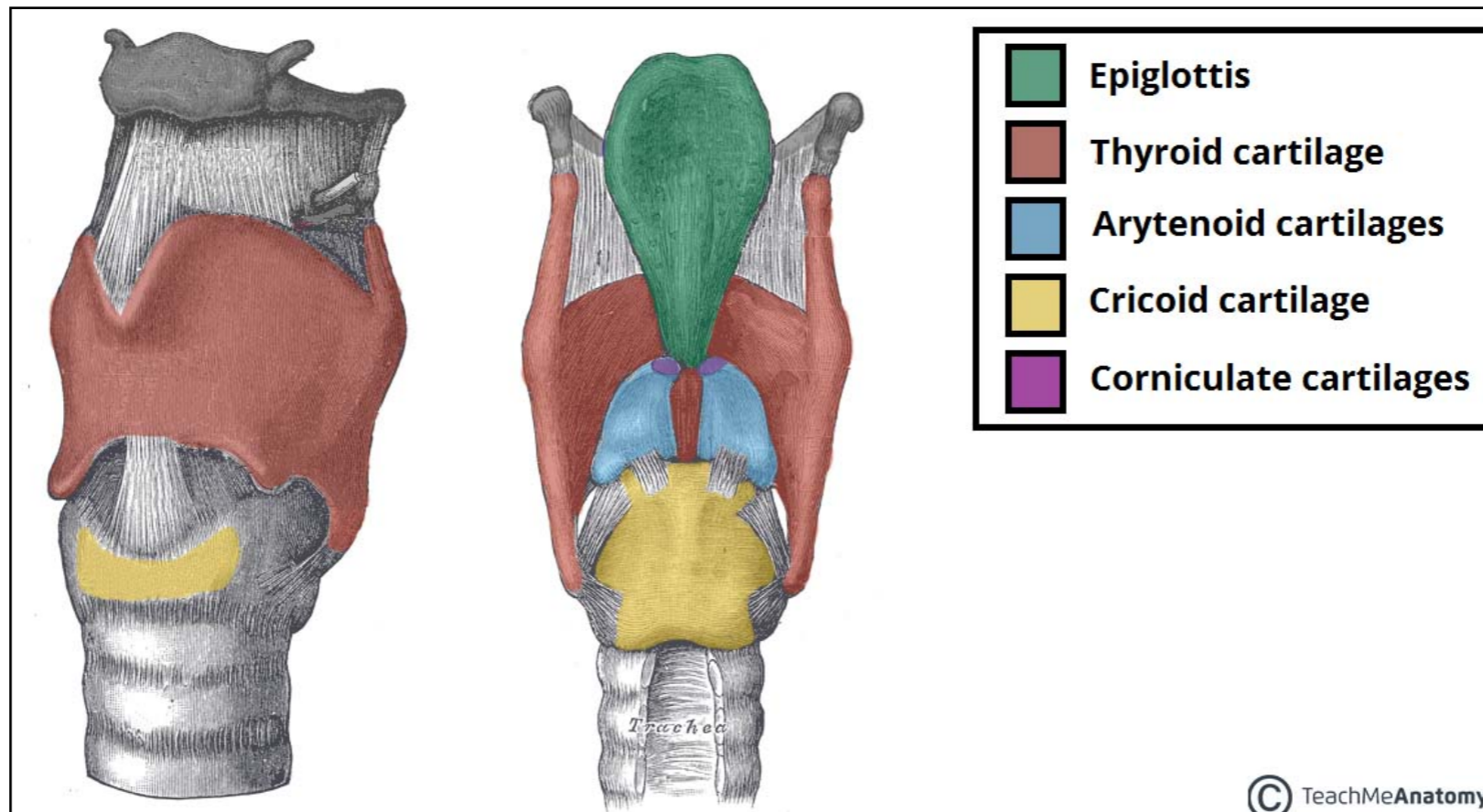
✦ Larynx.

- The students should know the parts of the Larynx :
 1. Cartilage
 2. Mucosa
 3. Ligaments
 4. Muscles



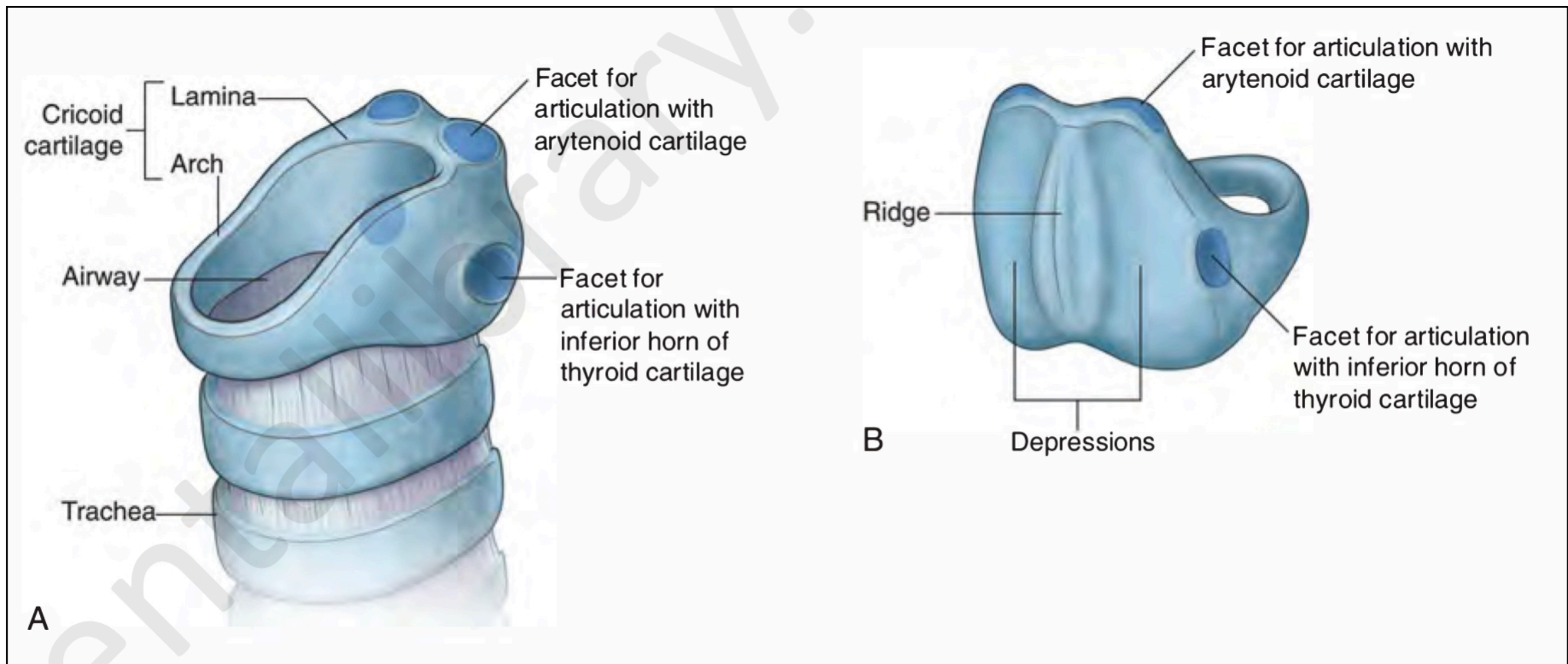
• Cartilages of the larynx

- The students should know the single cartilages :
 1. Epiglottis
 2. Cricoid
 3. Thyroid
- The students should know the paired cartilages :
 1. Arytenoid
 2. Cuneiform
 3. Corniculate



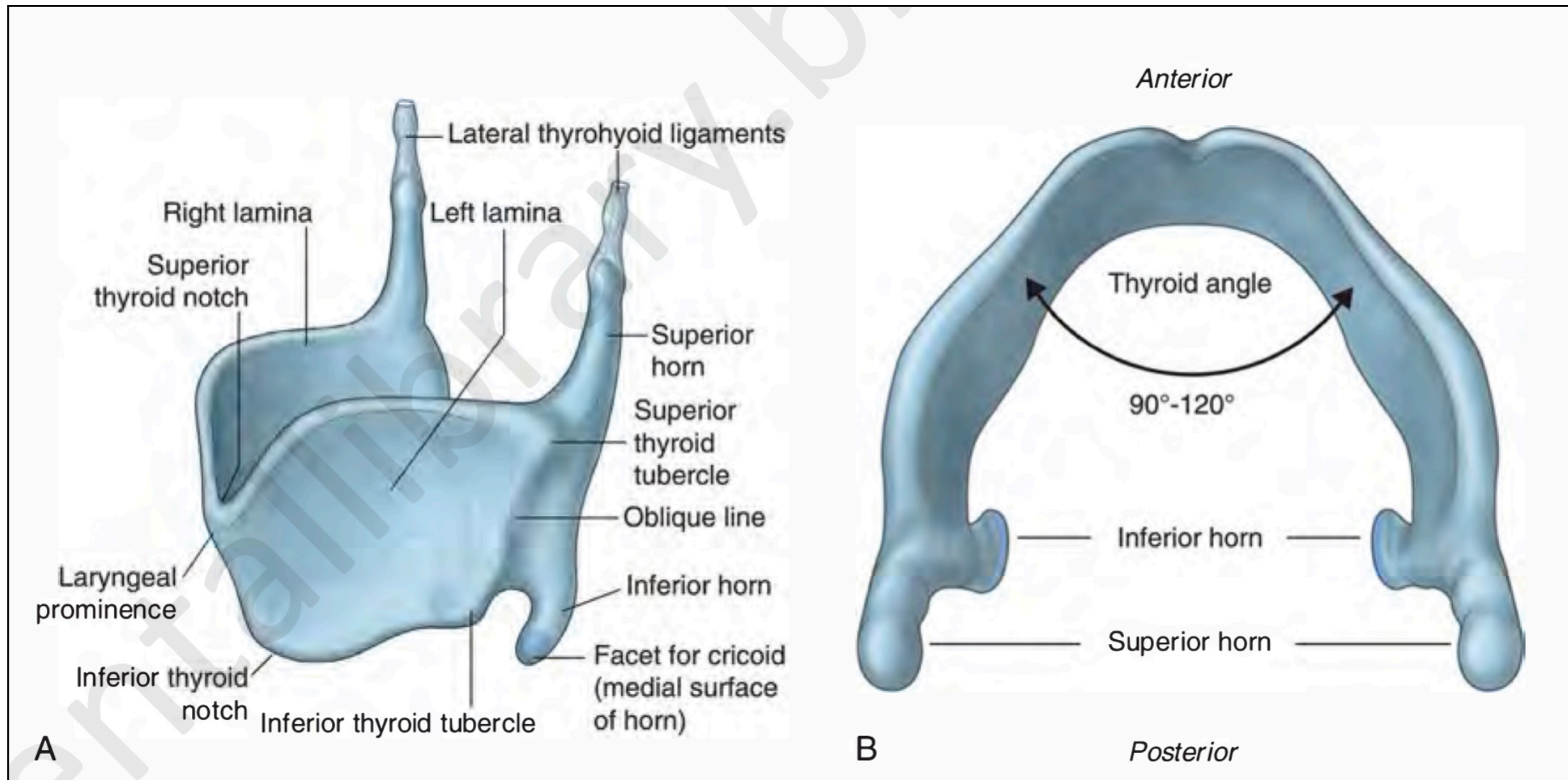
• Cartilages of the larynx

- The students should know the parts of cricoid cartilage :



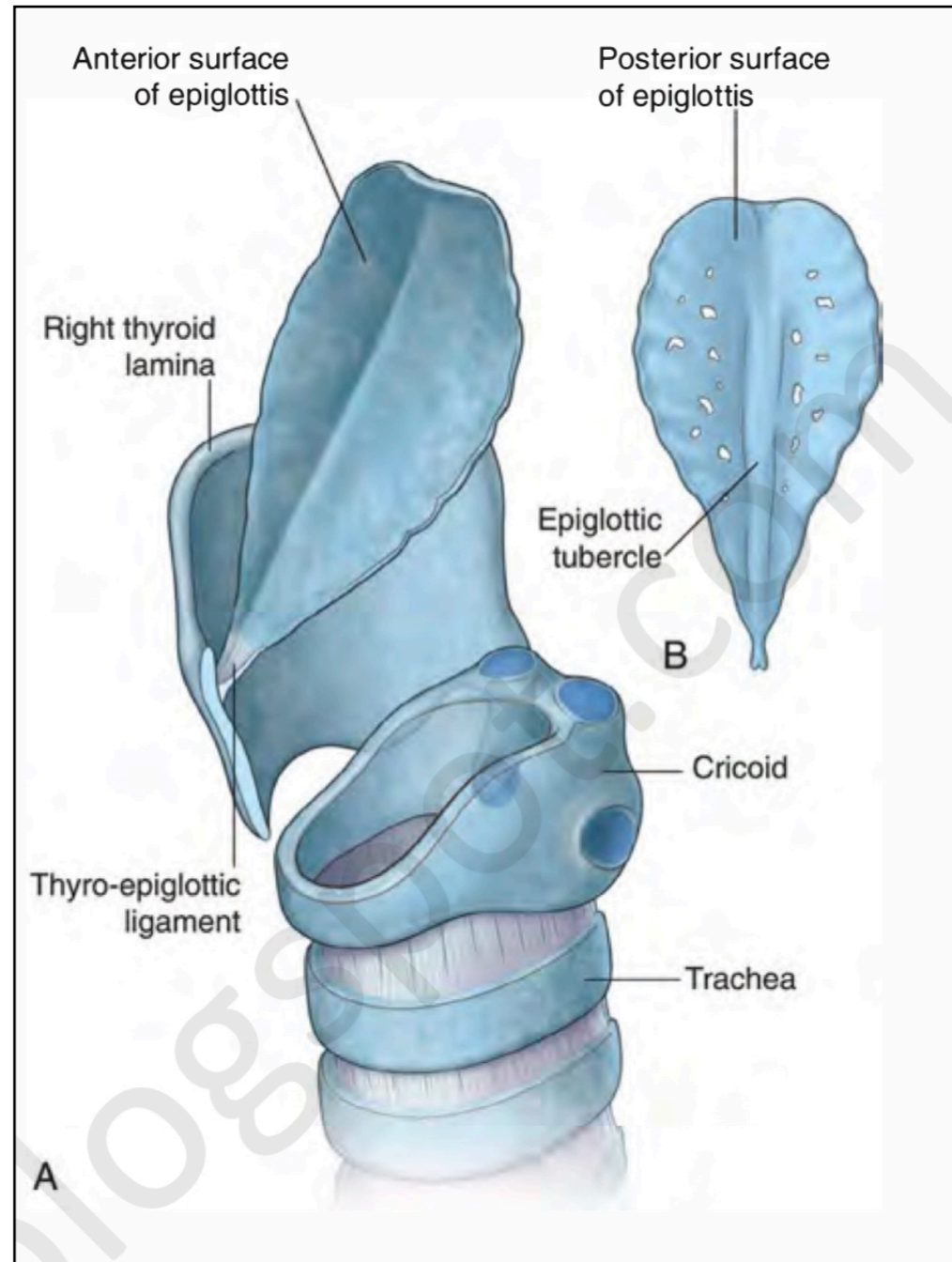
• Cartilages of the larynx

- The students should know the parts of thyroid cartilage :



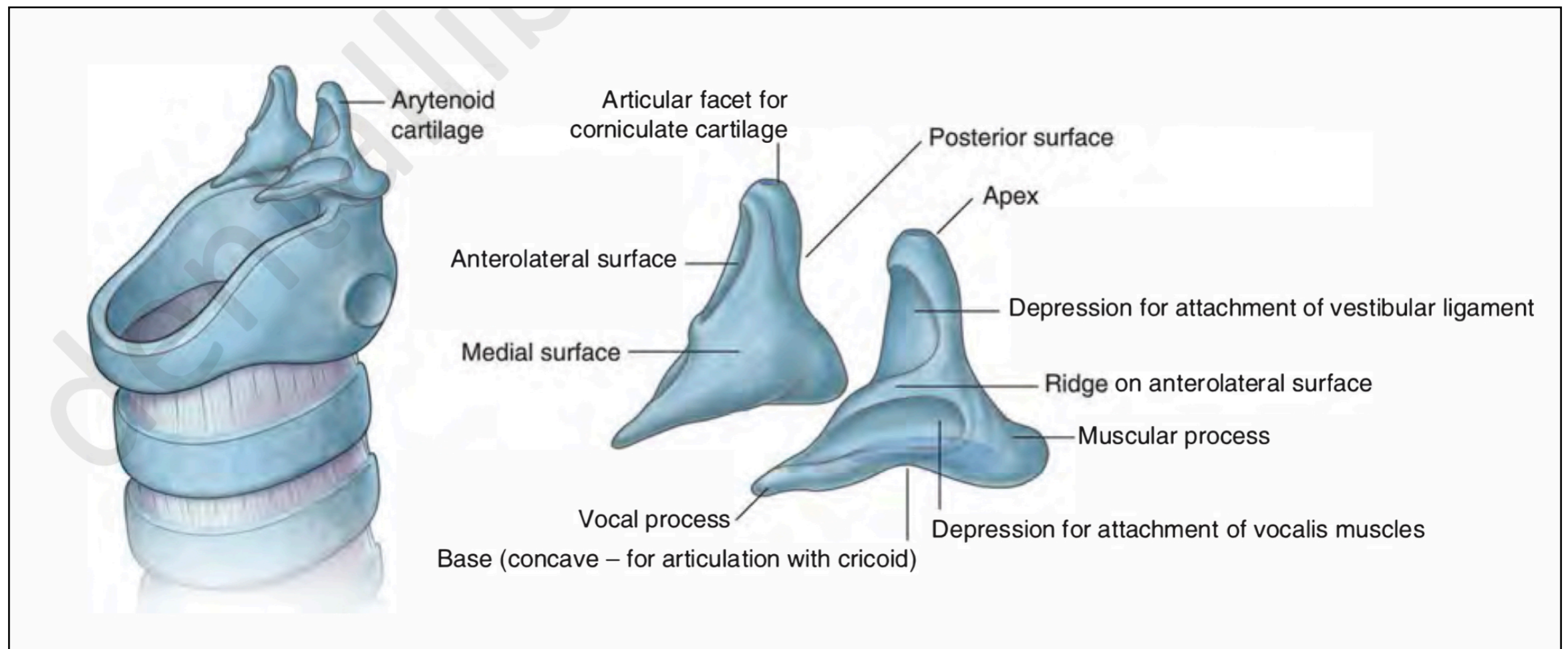
• Cartilages of the larynx

- The students should know the parts of epiglottis cartilage :



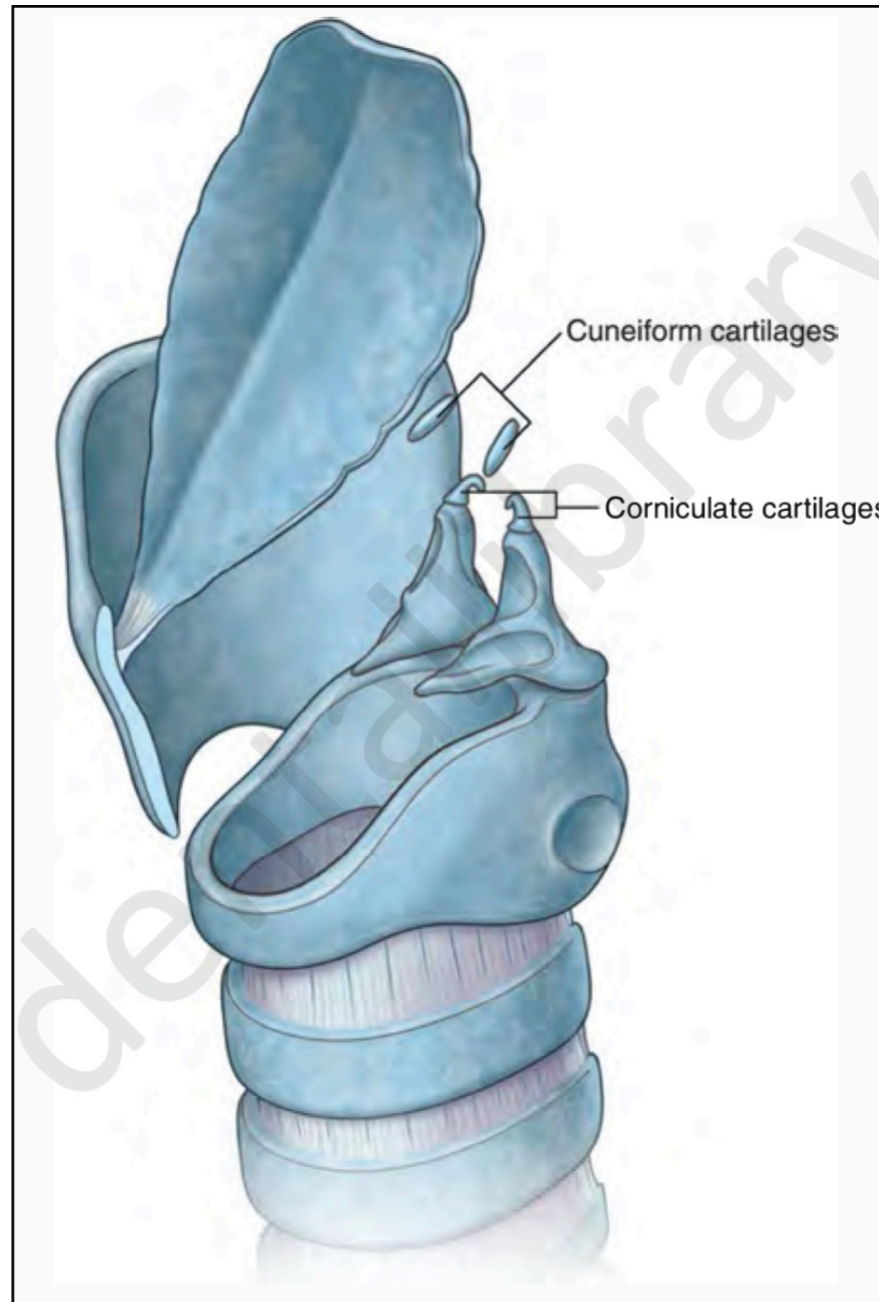
• Cartilages of the larynx

- The students should know the parts of Arytenoid cartilage :



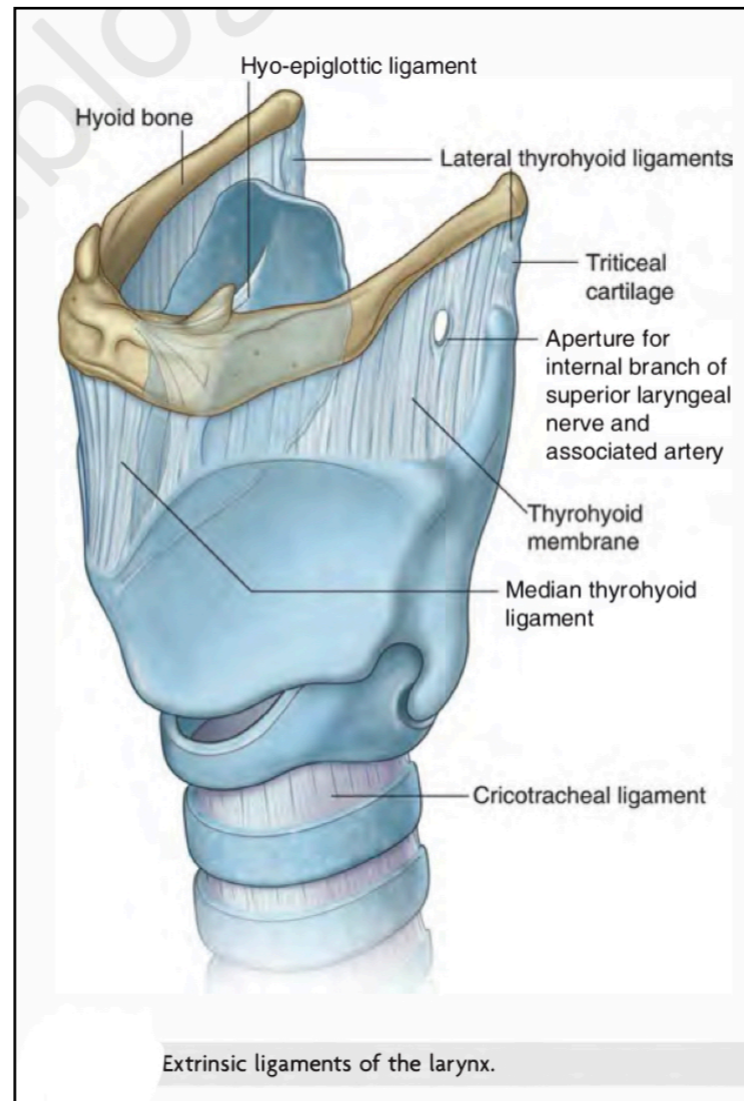
• Cartilages of the larynx

- The students should know the parts of Corniculate and Cuneiform cartilages :



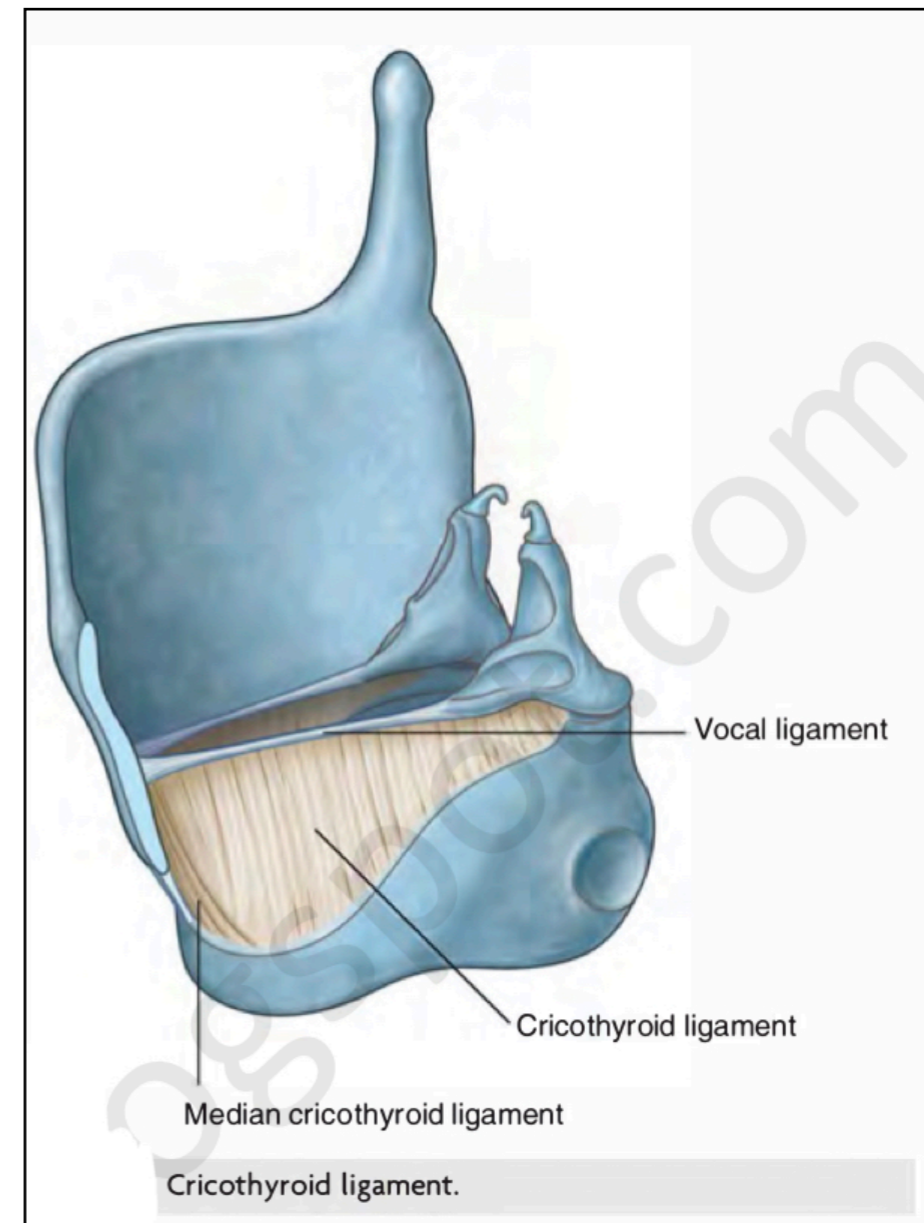
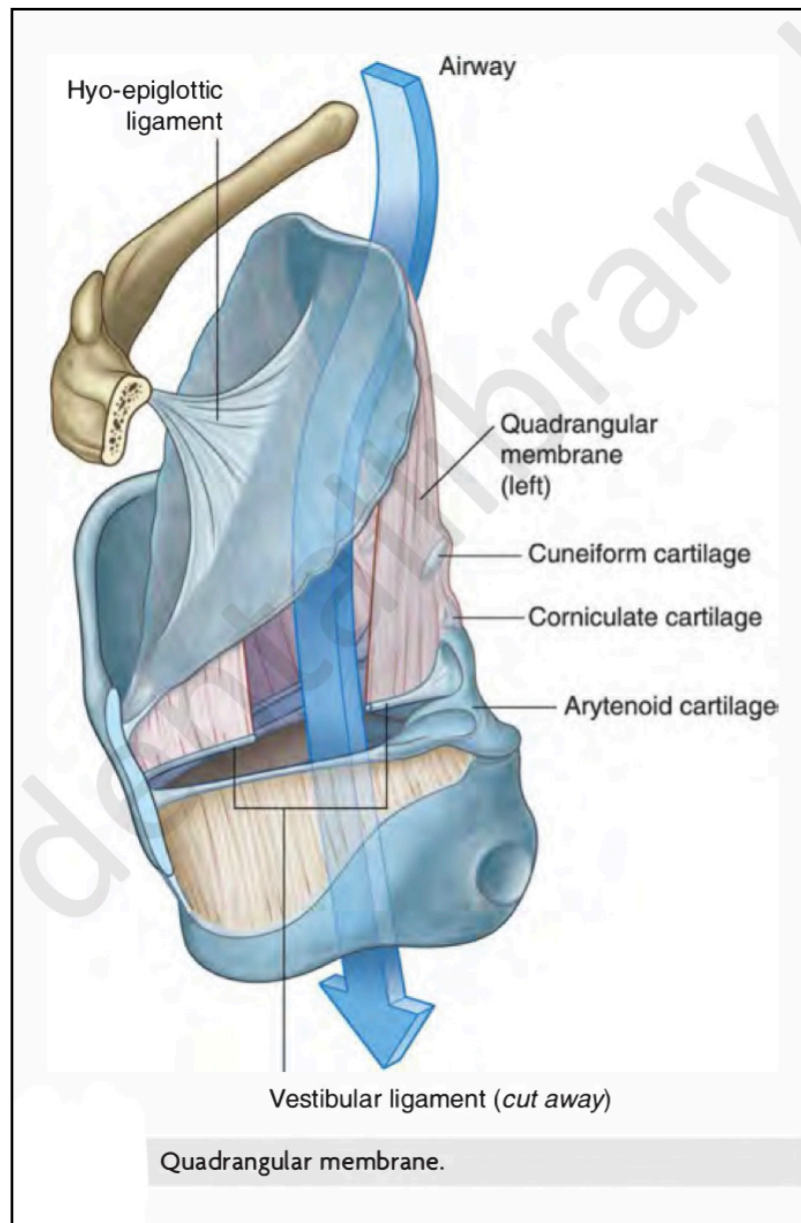
• Ligaments of the larynx

- The students should know the Extrinsic ligaments :
 1. Cricotracheal ligament
 2. The hyo-epiglottic ligament
 3. Thyrohyoid ligament and membrane
- What is the structures which pass through the membrane ?



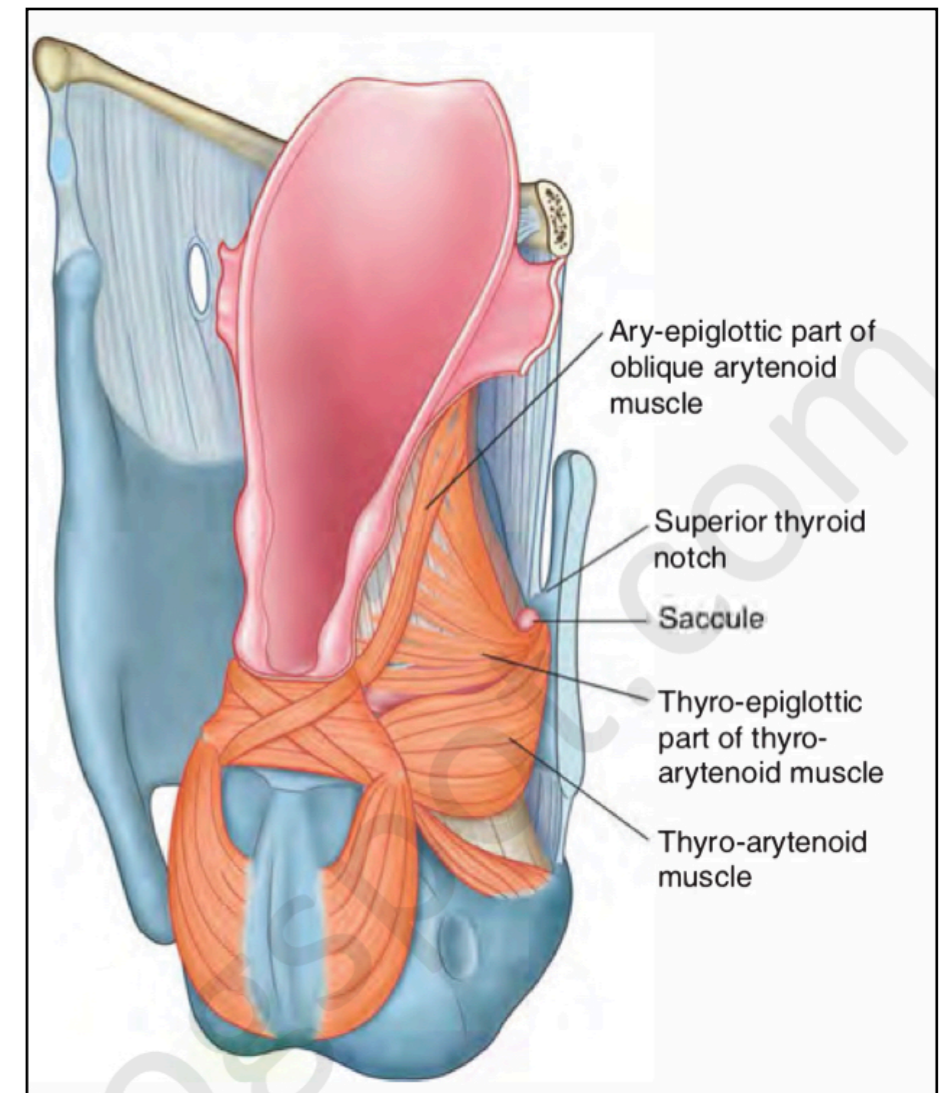
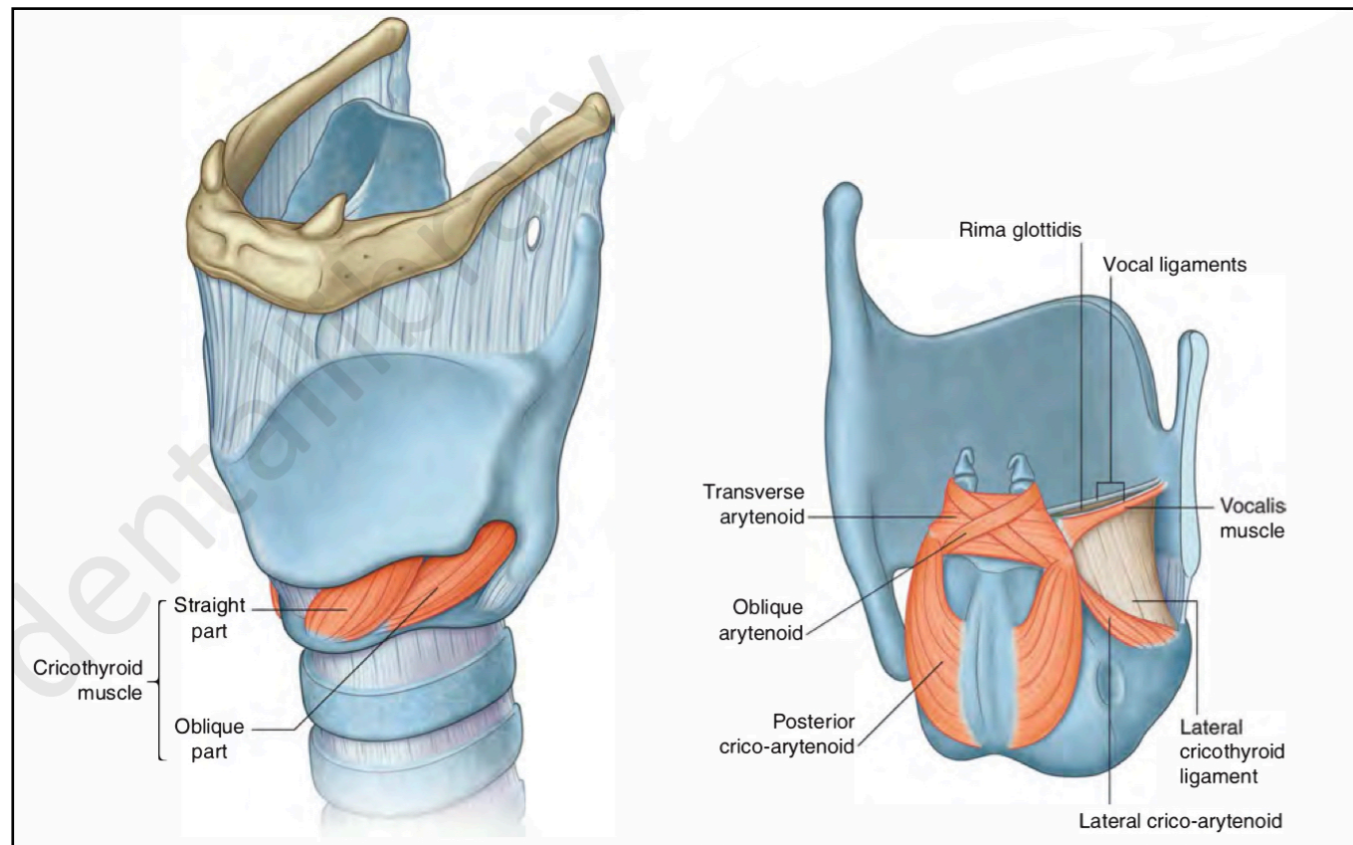
• Ligaments of the larynx

- The students should know the Intrinsic ligaments (membranes) :
 1. cricothyroid ligament (conus elasticus)
 2. quadrangular membrane



• Muscles of the larynx

- The students should know the Intrinsic muscles (origin/ insertion/ nerve supply/ action) :
 1. Cricothyroid muscles
 2. Posterior crico-arytenoid muscles
 3. Lateral crico-arytenoid muscles
 4. Transverse arytenoid
 5. Thyroarytenoid (vocalis)
 6. Oblique arytenoid
 7. Thyroepiglottic (aryepiglottic muscles)



• Muscles of the larynx

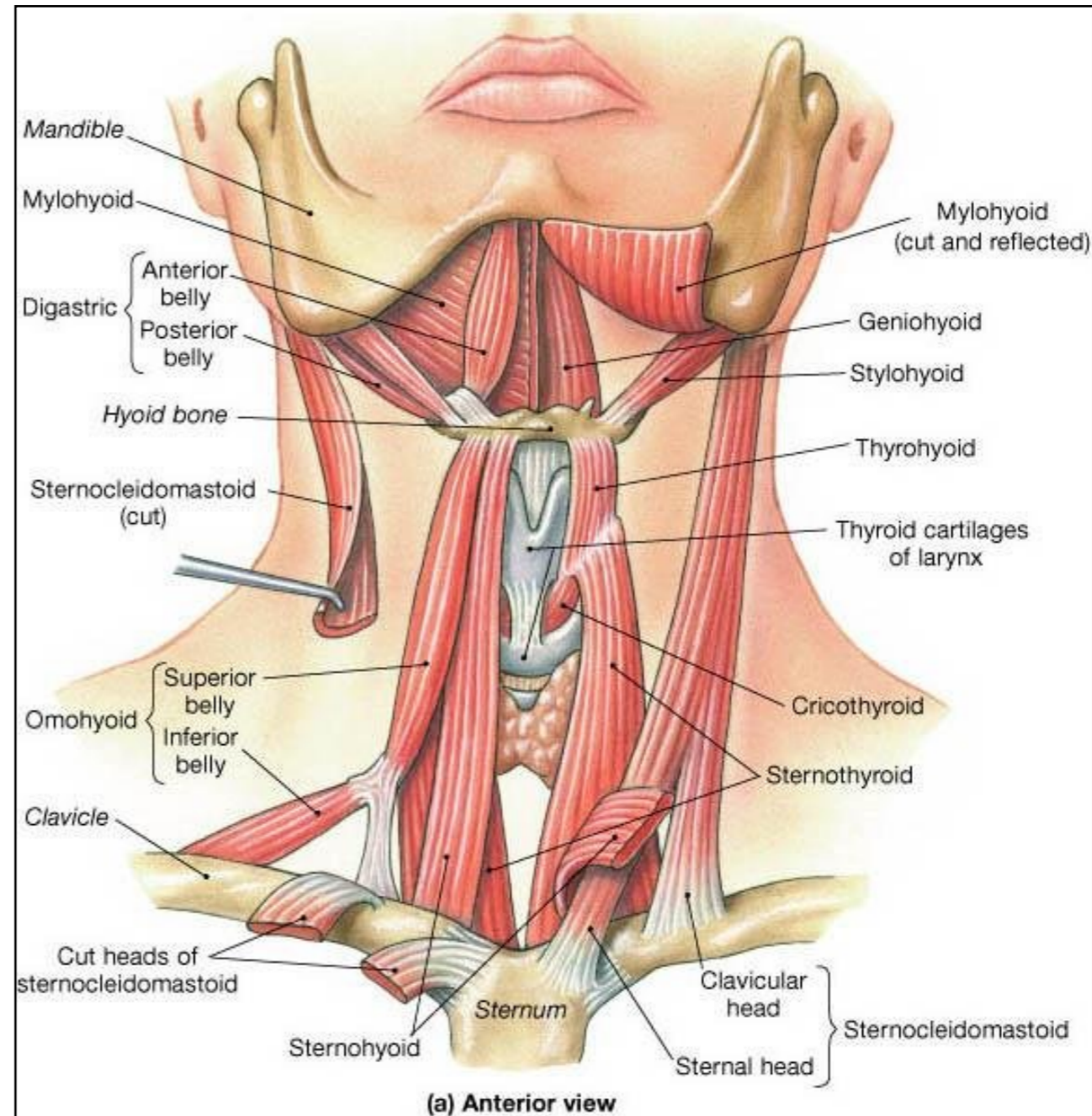
- The students should know the extrinsic muscles :

- Elevators of the larynx:

1. Digastric muscle
2. Stylohyoid
3. Mylohyoid
4. Geniohyoid

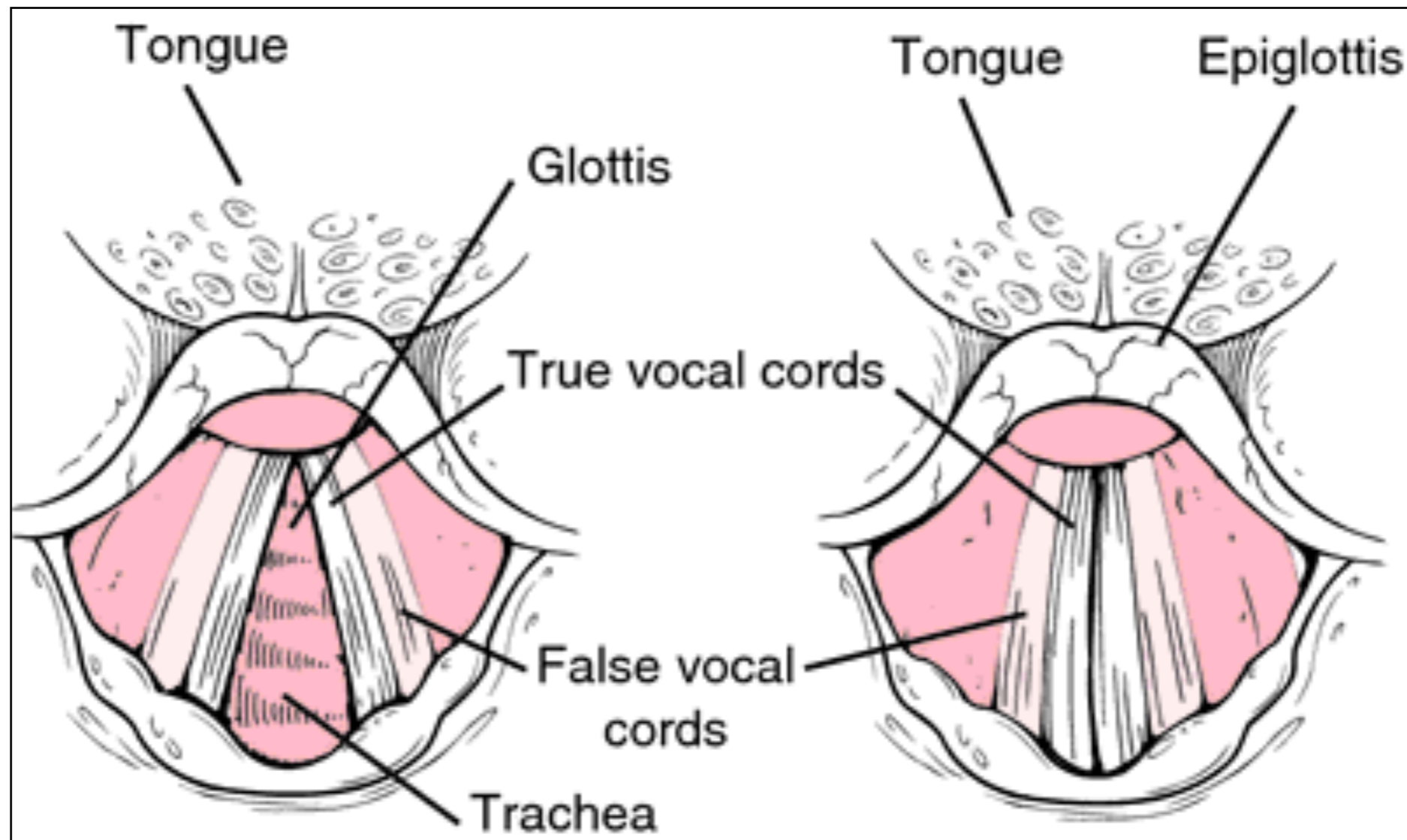
- Depressors of the larynx :

1. Sternothyroid
2. Sternohyoid
3. Omohyoid



✦ Vocal Cords.

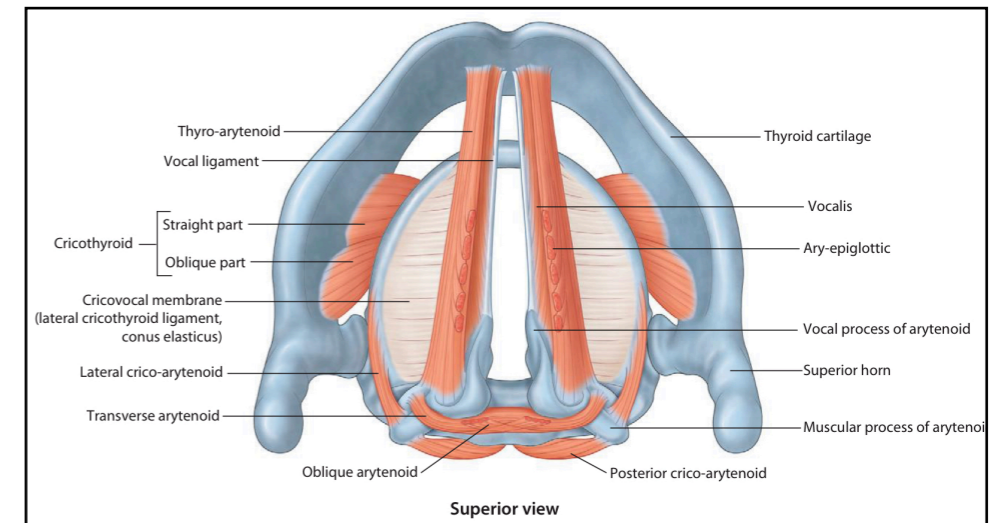
- The students should observe the different between true and false vocal cords :



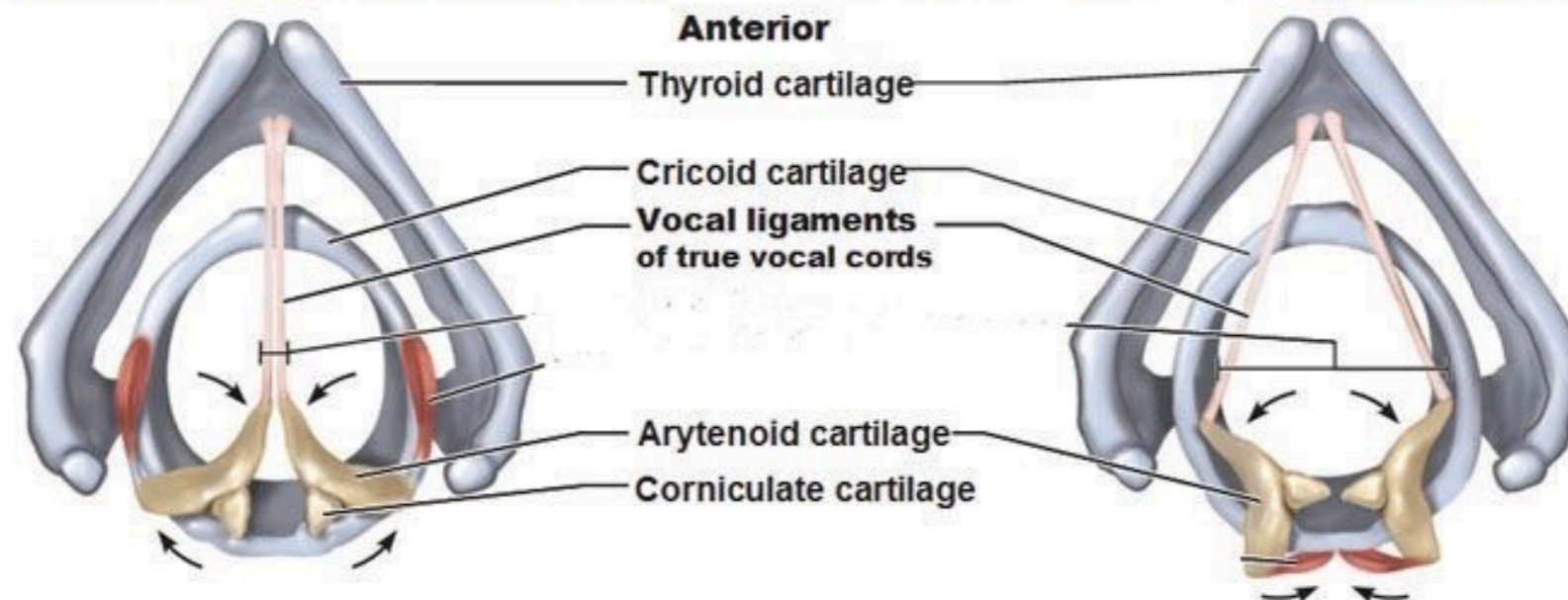
✦ Vocal Cords.

- The students should know the characters of the true vocal cord :

1. Vocal ligament
2. Mucous membrane (stratified squamous)
3. Vocalis muscle
4. No submucosa.
5. Avascular.
6. No lymphatic drainage.

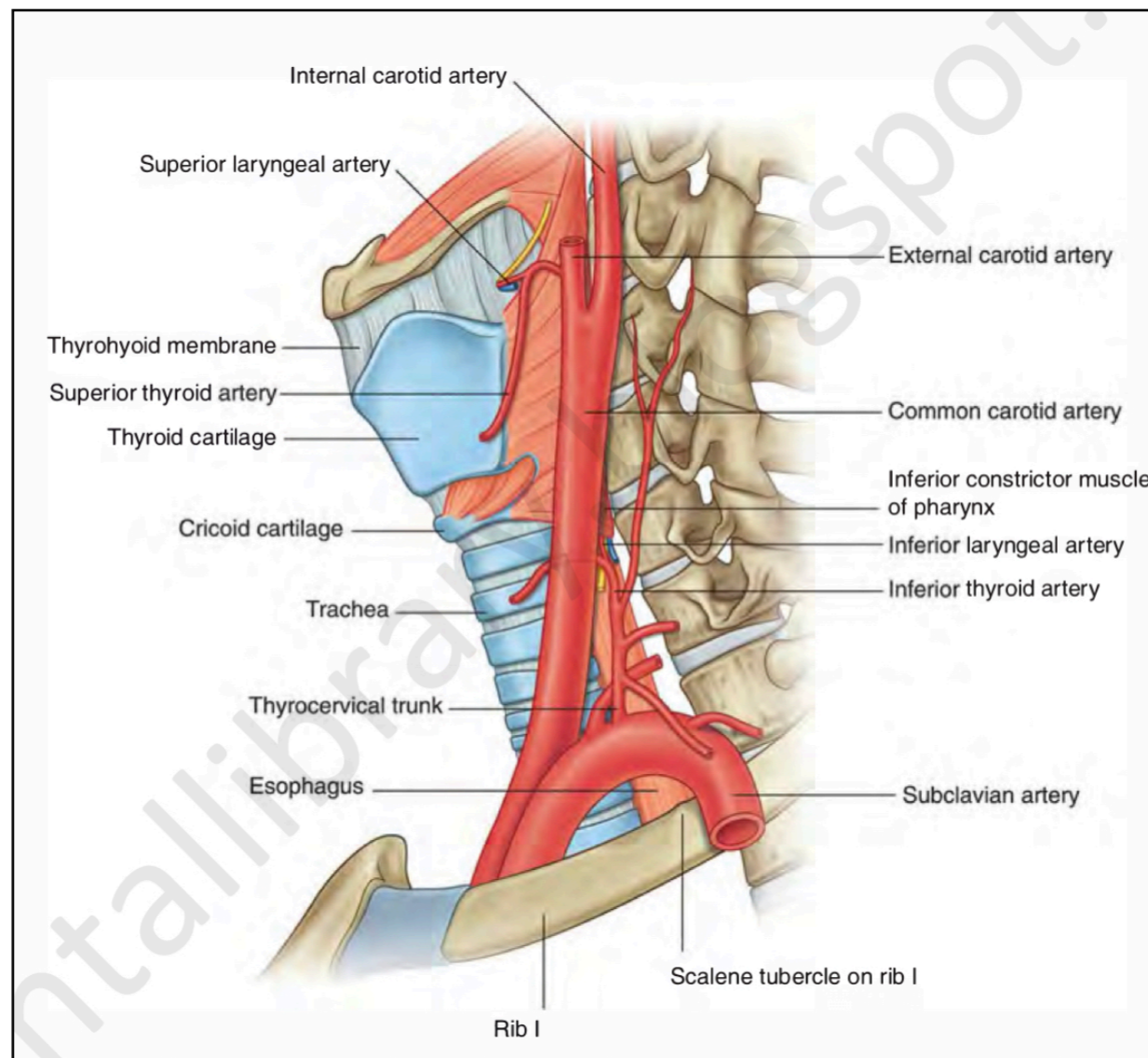


True Vocal Cords (= "Folds" or "Ligaments")



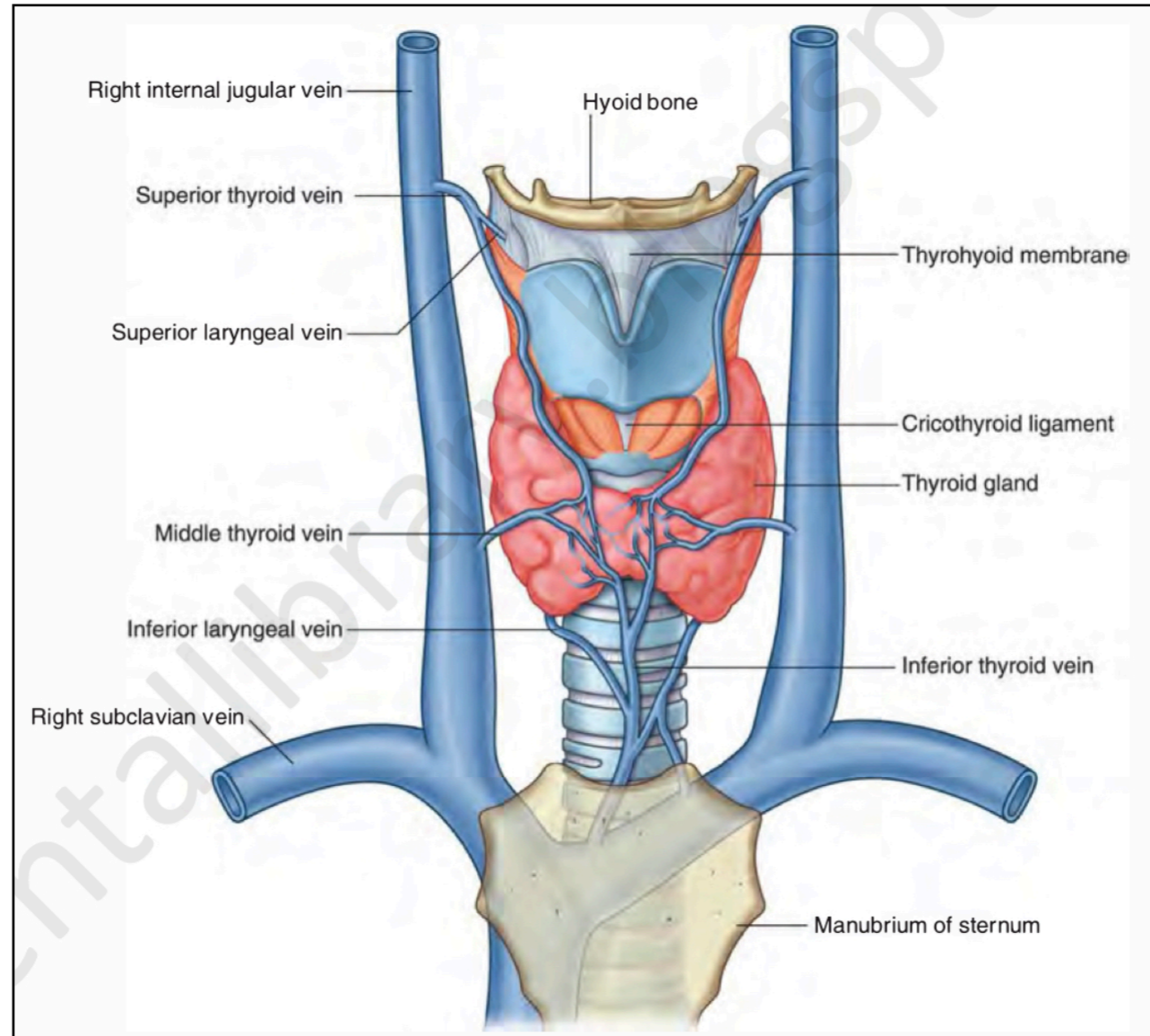
• Blood and nerve supply

- The students should know the arterial supply of the larynx :
 1. Superior laryngeal artery.
 2. Inferior laryngeal artery.



• Blood and nerve supply

- The students should know the venous drainage of the larynx:



• Blood and nerve supply

- The students should know the nerve supply of the larynx:
 1. Superior laryngeal nerves.
 2. Recurrent laryngeal nerves.
- The students should know the results of injury of recurrent laryngeal nerve

