

CNS pathology  
Third year medical students

Dr Heyam Awad

**brain haemorrhage**

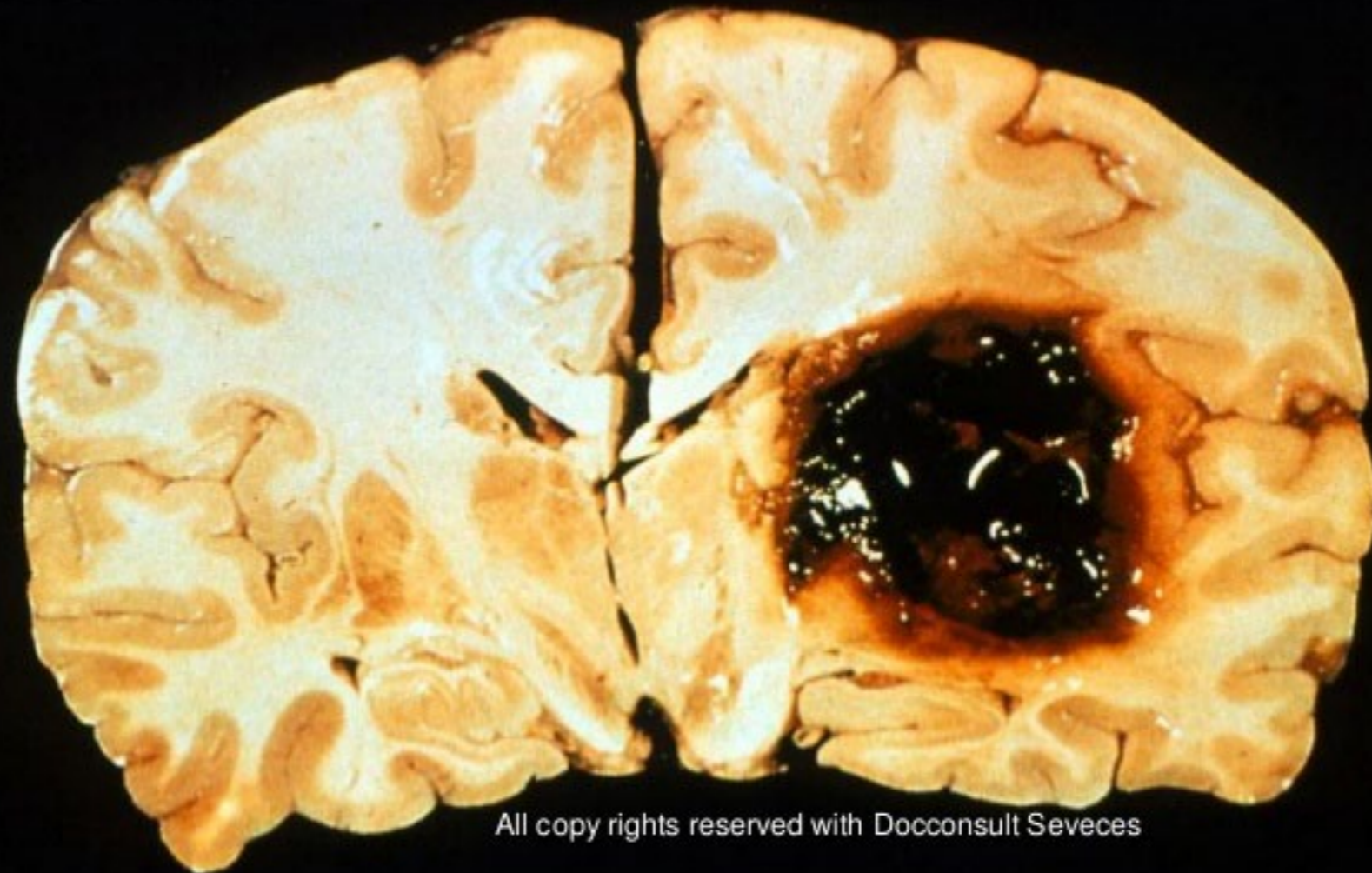
# Case 1

- Mr H ( 65 years old) was enjoying a vacation in Hawaii with his wife to celebrate their 30th marriage anniversary. While having dinner he told his wife that he felt a sudden headache but continued eating!! a few minutes later he collapsed and unfortunately died.



- Mr H was taken to hospital where death was confirmed.
- His wife mentioned he had hypertension and diabetes/
- Autopsy showed intracranial hemorrhage.

## AUTOPSY OF INTRACEREBRAL HEMORRHAGE



All copy rights reserved with Doconsult Seveces

- What is the cause of death.
- What is the underlying cause?

# case 2

- A 32 year old male, known of having HIV infection, had neurological symptoms which on investigation were found to be due to an intracerebral haemorrhage
- Cause?