

# **Introduction To Clinical Medicine**



**Past papers – 4<sup>th</sup> week**

***Done by: Malek Abu Rahma***

The **colored question numbers** are mentioned more than once so focus on them



# Chapter 10

## endocrine system

**1. Which of the following is specific for graves' disease:**

- A) Lid lag
- B) Lid retraction
- C) Pretibial myxedema

**ANSWER : C**

**2. not in hyperthyroidism**

- A) amenorrhea
- B) proximal muscle weakness
- C) delayed relaxation of knee reflex
- D) diarrhea

**ANSWER : C**

**3. wrong match**

- A) Pressure speech with hypothyroidism
- B) Goitre with euthyroid,hypo,hyperthyroidism
- C) midsystolic murmur with hyperthyroidism

**ANSWER : A**

**4. The least specific sign to GRAVES**

- A) pretibial myxedema
- B) thyroid actopachy
- C) bruit around thyroid
- D) lid lag
- E) exophthalmos

**ANSWER : D**



# Chapter 10

## endocrine system

**5. all of the following produces diffuse goiter except :**

- A) malignancy
- B) puberty
- C) graves

**ANSWER : A**

**6. All of the following are specific for Grave's disease except:**

- A) acropachy
- B) exophthalmos
- C) periorbital edema
- D) myxedema
- E) ophthalmoplegia

**ANSWER : C**

**7. Wrong match:**

- A) Pressure speech with hypothyroidism
- B) Goitre with euthyroid patients
- C) midsystolic murmur with hyperthyroidism
- D) hashimoto with diffuse neck swelling

**ANSWER : A**

**8. 33-year-old pharmacist presented with low TSH and high T4. Exophthalmos was also noted, what is the diagnosis:**

- A) Iatrogenic thyrotoxicosis
- B) Toxic multimodular goiter
- C) Graves disease

**ANSWER : C**



# Chapter 10

## endocrine system

9. 20-year-old lady presented to your clinic with heat intolerance of 3 months duration, Associated with weight loss despite normal appetite, diarrhea, amenorrhea, hand tremor, on examination vital signs was HR 105, RR 20, TEMP 37.4, BP 140/70, fine tremors on both hands, hyperreflexia, all of the following suggest the diagnosis of hyperthyroidism, except :

- A) Acropachy
- B) Goiter
- C) Exophthalmos
- D) Dry skin
- E) Pretibial myxedema

**ANSWER : D**

10. One of the following produces diffuse goiter:

**ANSWER : Graves disease**

11. Clinical case of benign single thyroid nodule. what of the following is wrong?

**ANSWER : This nodule is typically fixed to its surrounding structures**

12. Which of the following is wrong about thyroid:

**ANSWER : Most patients with goiters are hyperthyroid patients**



# Chapter 10

## endocrine system

13. Not found in hypothyroidism:

ANSWER : Oligomenorrhea

14. Wrong about thyroid gland and its diseases:

ANSWER : Goiter indicates hyperthyroidism in most cases

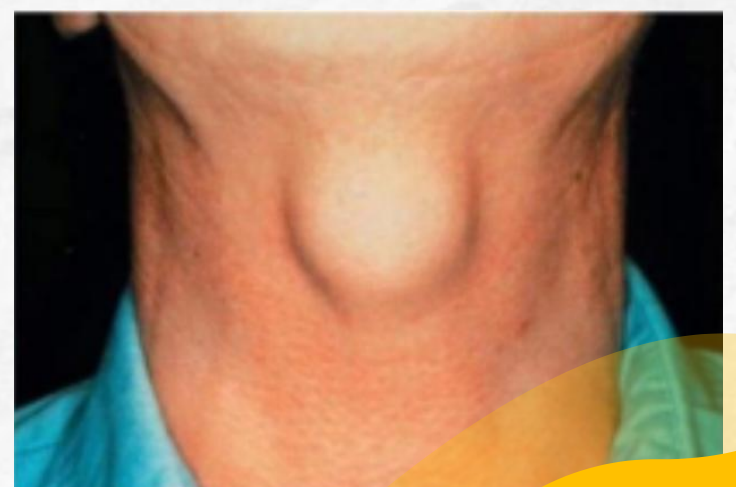
15. all of the following are mismatched except :

ANSWER : graves disease >> digital acropachy

16. A 60 year old lady presented to the clinic with one month history of enlarging anterior neck swelling (see the attached photo). She is clinically and biochemically euthyroid. One of the following findings is more likely present during physical examination :

- A) Bradycardia
- B) Delayed relaxation of the ankle reflex
- C) Upward movement of the swelling with tongue protrusion
- D) Exophthalmos
- E) Hypertension

ANSWER : C





# Chapter 13

## musculoskeletal system

**17. Severe constant and diffuse low back pain, normal examination with diurnal variation, what is the most likely to be the diagnosis:**

- A) Fibromyalgia
- B) Reactive arthritis
- C) Osteoarthritis

**ANSWER : A**

**18. finger extension on the PIP, flexion on the DIP:**

- A) Swan
- B) Mallet
- C) Boutonniere

**ANSWER : A**

**19. Which of the following is not in the range of motion of the wrist:**

- A) Flexion
- B) Extension
- C) Internal rotation
- D) Abduction
- E) Adduction

**ANSWER : C**

**20. A 26-year-old female patient with diabetes presented with feeling numbness and paresthesia on the lateral two fingers, and she denies feeling anything in the palm, she also presented with wasting of thenar muscles, what is the nerve compressed and where:**

- A) Ulnar nerve at the wrist
- B) Radial nerve at the wrist
- C) Median nerve at the elbow
- D) Median nerve at the wrist

**ANSWER : D**



# Chapter 13

## musculoskeletal system

**21. Which of the following is the correct test for medial meniscus:**

- A) Extension, external rotation and valgus stress
- B) Flexion 90 degrees, external rotation and valgus stress
- C) Flexion 30 degrees, external rotation and valgus stress
- D) Flexion 90 degrees, internal rotation and varus stress
- E) Flexion 30 degrees, internal rotation and varus stress

**ANSWER : B**

**22. Case: Woman.... awakens and after 5-10 she feels stiffness in her DIP joints, the pain worsens after using tools her garden, she has a history of RA:**

- A) Gout
- B) Osteoarthritis

**ANSWER : B**

**23. Wrong about knee examination:**

- A) Patellar tap used to test moderate effusion
- B) Patellar tap is used to detect patellar dislocation or instability

**ANSWER : B**

**24. Wrong about median nerve:**

- A) Apply innervation to do OK sign.
- B) Snuffbox supplied by median nerve

**ANSWER : B**



# Chapter 13

## musculoskeletal system

**25. All of the following bone conditions are associated with pathological fracture, EXCEPT:**

- A) Osteoporosis
- B) Paget syndrome
- C) Diabetes mellitus

**ANSWER : C**

**26. Which of the following does not show Raynaud's sign:**

- A) Rheumatic fever
- B) SLE
- C) Rheumatoid arthritis

**ANSWER : A**

**27. A 75 Y.O patient present to the clinic, he is obese (BMI:32), complaining of knee pain that increases after exercise and moving, pain can be relieved by NSAID, it started 2 years ago, but it progressed in the last 2 months. What's your diagnosis?**

- A) Osteoarthritis
- B) Rheumatoid arthritis
- C) Reactive arthritis

**ANSWER : A**

**28. years old male complains of lower back pain and decreased lumber motility, stiffness in the morning, decreased stiffness over the day and with movement?**

- A) Ankylosing spondylitis
- B) Rheumatoid arthritis
- C) Osteoarthritis
- D) Psoriatic arthritis

**ANSWER : A**



# Chapter 13

## musculoskeletal system

**29. patient come with sudden very painful joint + erythema+ redness + he is on dialysis**

- A) gout
- B) Rheumatoid arthritis
- C) SLE
- D) osteoarthritis
- E) septic arthritis

**ANSWER : A**

**30. Raynaud's syndrome occur in all of the following except**

- A) SLE
- B) Rheumatoid arthritis
- C) Rheumatic fever
- D) systemic sclerosis
- E) sjogren syndrome

**ANSWER : C**

**31. choose the right sentence**

- A) locking is incomplete movement due to pain
- B) Heberden nodes in PIP
- C) Bouchard nodes in DIP
- D) pseudolocking is incomplete movement due to anatomical block
- E) Boutonniere deformity is flexion on PIP + hyperextension on DIP

**ANSWER : E**

**32. knee resistance to varus on 0 and 30 degree flexion, what is affected**

- A) Anterior cruciate ligament
- B) medial collateral
- C) lateral collateral
- D) medial menisci
- E) lateral menisci

**ANSWER : C**



# Chapter 13

## musculoskeletal system

**33. joint not involved in rheumatoid arthritis**

- A) MCP
- B) PIP
- C) cervical spine
- D) lumbar spine
- E) wrist joints

**ANSWER : D**

**34. Case of knee joint pain+ all other normal but reported urethritis 2 days ago+ conjunctivitis**

- A) reactive arthritis
- B) gout
- C) rheumatoid arthritis

**ANSWER : A**

**35. wrong about gout**

- A) monoarthritis
- B) chills and rigors are associated symptoms

**ANSWER : B**

**36. joint pain with pitting and nail separation from nail bed?**

- A) rheumatoid arthritis
- B) reactive arthritis
- C) pseudogout
- D) psoriatic arthritis

**ANSWER : D**



# Chapter 13

## musculoskeletal system

**37. child with fever + joint pain + recent gastroenteritis ?**

- A) reactive arthritis
- B) septic arthritis
- C) rheumatoid arthritis
- D) gout

**ANSWER : B**

**38. A 20-year-old male student, presented to clinic complaining of low back pain of 6 weeks duration. Pain is worse in the morning, associated with stiffness and inability to get out of the bed, which gets better through the day. On physical exam, Shober's test was positive. Which of the following is the most likely diagnosis ?**

- A) Systemic lupus erythematosus
- B) Felty's syndrome
- C) Systemic sclerosis
- D) Rheumatoid arthritis
- E) Ankylosing spondylitis

**ANSWER : E**

**39. Which of the following clinical test and its interpretation is mismatched ?**

- A) Lachman test : Anterior cruciate ligament injury
- B) Valgus stress test : Lateral collateral ligament injury
- C) Patella apprehension test : patella dislocation
- D) Bulge test : knee effusion
- E) McMurray test : Meniscal tear

**ANSWER : B**

**40. An 18 year old female patient presented with acute right knee pain, that started suddenly 1 day ago, associated with moderate knee swelling, hotness, and redness, no history of recent trauma, her vital signs are as follows: temperature is 38.3, pulse: 110, blood pressure: 125/75, respiratory rate: 18, what is the most likely diagnosis ?**

- A) Reactive arthritis
- B) Rheumatoid arthritis
- C) Osteomyelitis
- D) Septic arthritis
- E) Gout

**ANSWER : D**



# Chapter 13

## musculoskeletal system

**41. A 43-year-old female, complaining of dysphagia of 2 months duration. When doing physical exam, you noticed ulcers on the tip of the fingers and tight tethered skin around the mouth. What would be reasonable to screen for in this patient :**

- A) Systemic lupus erythematosus
- B) Felty's syndrome
- C) Ankylosing spondylitis
- D) Systemic sclerosis
- E) Rheumatoid arthritis

**ANSWER : D**

**42. A 22 year old football professional athlete sustained a right knee trauma during the match 2 days ago, presented to your clinic with right knee pain and swelling, upon clinical examination of his knee, you want to examine the medial meniscus, how would you examine it ?**

- A) Knee in passive flexion, plus varus and internal rotation
- B) Knee in passive flexion, plus valgus and external rotation
- C) Knee in passive flexion up to 90 degrees, plus posterior translation of the tibia
- D) Knee in passive flexion up to 30 degrees, fixing the distal femur plus anterior translation of the tibia
- E) Knee in passive flexion up to 90 degrees, plus anterior translation of the tibia

**ANSWER : B**

**43. An 11 years old male child, medically free, presented to the ER complaining of left elbow pain due to trauma. On physical exam: the child is unable to do OK sign by his left hand. X-ray done show elbow fracture .What is the most likely nerve has been injured ?**

- A) Posterior Interosseous nerve
- B) Anterior Interosseous nerve
- C) Radial Nerve
- D) Median Nerve
- E) Ulnar Nerve

**ANSWER : B**

**44. A 30 year old male patient work in a lumberjack, sustaining a deep cut wound in his forearm, while examining his peripheral nerves, to examine the ulnar nerve motor function :**

- A) Ask the patient to supinate his arm
- B) Ask the patient to extend his index and middle fingers
- C) Ask the patient to flex the distal phalanx of his thumb
- D) Ask the patient to flex his wrist
- E) Ask the patient to abduct his index and middle fingers

**ANSWER : E**



# Chapter 13

## musculoskeletal system

45. A 55-year-old lady, complains of hand swelling and pain of 2 weeks duration, associated with morning stiffness that lasts for about an hour. Pain is relieved by movement. On exam, there were swelling of MCPS and PIPS of in multiple fingers, tenderness, and sponginess. All the following may also be found in such patient except :

- A) Pleural effusion
- B) Heberden nodule
- C) Lung nodules
- D) Swan neck deformity
- E) Ulnar deviation

**ANSWER : B**

46. A 25 year old female patient presented with right knee pain since 2 years, associated with recurrent swelling, no history of trauma, she had a positive family of rheumatoid arthritis, which of the following features is not suggestive of rheumatoid arthritis ?

- A) Bouchard's nodes
- B) Wrist ulnar deviation
- C) Palmar erythema
- D) Episcleritis
- E) Splenomegaly

**ANSWER : B**

47. A 35-year-old man presents with progressive breathlessness and non-productive cough. He has history of polyarthralgia and bilateral painful dusky red lesions over the shins of both tibias. What is the most likely diagnosis ?

- A) Pneumonia
- B) Asthma
- C) Bronchiectasis
- D) Sarcoidosis
- E) Cystic fibrosis

**ANSWER : D**

48. All are seronegative arthritis except:

- A) rheumatoid arthritis
- B) psoriatic arthritis

**ANSWER : A**



# Chapter 13

## musculoskeletal system

**49. All are associated with reactive arthritis except:**

- A) otitis media
- B) conjunctivitis
- C) mouth ulcers
- D) genital ulcers
- E) right knee effusion

**ANSWER : A**

**50. The true statement about rheumatoid nodules:**

- A) can occur in the lung
- B) they're tender
- C) they're hard
- D) located at the flexor surface of the forearm
- E) they are seronegative for rheumatoid factor

**ANSWER : A**

**51. Clinical case in which 25 year old male presented to ER complaining knee pain of 1 day duration associated with erythema and hotness, least likely diagnosis:**

- A) RA
- B) septic arthritis
- C) gout
- D) hemophilia

**ANSWER : A**

**52. A 14 years old boy, presented with high- spiking fevers in the evening of 2 weeks duration, accompanied by a salmon- coloured skin rash, and arthralgia. The most likely diagnosis of the following is :**

- A) Reactive arthritis
- B) Psoriatic arthritis
- C) SLE
- D) Felty Syndrome
- E) Still's disease

**ANSWER : E**



# Chapter 13

## musculoskeletal system

**53. Case of rheumatoid arthritis, which is not accurate:**

- A) Can be associated with malar rash
- B) Can be mono, oligo, or polyarticular

**ANSWER : A**

**54. A patient presented with cough of 9 months duration, physical exam revealed tightening of skin around the lips and late fine crackles, what is the most likely Dx:**

- A) Sjögren with....
- B) systemic sclerosis with pulmonary fibrosis
- C) systemic sclerosis with pulmonary effusion

**ANSWER : B**

**55. Pain in knee, on examination varus stress increased pain and displaced the knee outside, which is the structure most likely injured:**

- A) Meniscus tear
- B) medial collateral ligament
- C) lateral collateral ligament
- D) patellar dislocation

**ANSWER : C**

**56. A 54-year-old patient that undergoes hemodialysis presented to the clinic with pain in their elbow joint that began last night, and they were barely able to move the joint, even putting it on the bed was painful. Physical exam revealed erythema, redness, effusion in the joint. What is the most likely cause?:**

- A) Gout
- B) Osteoarthritis

**ANSWER : A**



# Chapter 13

## musculoskeletal system

**57. Which of the following indicates isolated tear of lateral collateral ligament of knee joint:**

- A) with the knee fully extended, applying a varus will make a cleft laterally
- B) with the knee 30 flexed, applying a varus will make a cleft laterally

**ANSWER : B**

**58. A 35 year old pregnant lady complaining from right hand pain and numbness of 2 months duration without history of trauma, all of the following support your diagnosis of carpal tunnel syndrome, except :**

- A) thenar muscle atrophy
- B) tinel's sign
- C) reproduction of symptoms by reverse prayer sign
- D) loss of opposition of thumb
- E) forment's sign

**ANSWER : E**

**59. A wife house cut her wrist parallel to wrist crease and proximal to it, all of the following can be found except:**

- A) partial cut of FDS tendon as the patient can't flex her DIP of middle finger
- B) complete cut of FDS tendon as the patient can't flex her ring finger to her palm
- C) cut of FDS and FDP as the patient can't flex her index finger at all
- D) ulnar nerve cut as the patient lost sensation on ulnar side of the hand
- E) median nerve cut as the patient lost sensation on radial side of index

**ANSWER : A**

**60. Wrong about carpal tunnel syndrome:**

- A) it can radiate to arm
- B) typical at Night
- C) affect adductor of thumb
- D) most common entrapment neuropathy

**ANSWER : C**



# Chapter 13

## musculoskeletal system

**61.** A 17 year old male with a recent history of a treated urinary tract infection 3 weeks ago presented to clinic due to redness and burning sensation in the eyes in addition to pain in his right knee that was swollen, red, tender and hot upon examination. What is the MOST likely cause of his knee symptoms ?

- A) Reactive arthritis
- B) Ankylosing spondylitis
- C) Gout arthritis
- D) Septic arthritis
- E) Rheumatic fever

**ANSWER : A**

**62.** A 27-year-old patient presented with numbness and paresthesia in the palm, durkan test is positive, increases at night (not sure), relieved by ترمي ايدها what is the diagnosis:

**ANSWER : Carpal tunnel syndrome**

**63.** Wrong statement:

**ANSWER : Nail pitting & onycholysis can be present with rheumatoid arthritis**

**64.** Regarding the innervation of the hand, the wrong statement:

**ANSWER : adductor muscles of the thumb are supplied by radial nerve**



# Chapter 13

## musculoskeletal system

**65. Vitiligo**

**ANSWER : Autoimmune destruction of melanocytes**

**66. All of the following can be seen in a patient with carpal tunnel syndrome except:**

**ANSWER : loss of sensation over thenar muscles**

**67. Ankyloising spondylitis, all are true except:**

**ANSWER : loss of neck lordosis**

**68. Clinical case in which patient has severe knee pain, tenderness, swelling, fever and malaise:**

**ANSWER : Septic arthritis**



# Chapter 13

## musculoskeletal system

69. Clinical case in which a patient is present with arthritis and has a history of diarrhea and vomiting. which of the following is wrong?

**ANSWER :** It is associated with positive rheumatoid factor

70. Clinical case in which patient with anterior deviation of tibia with past history of trauma, the injury is in:

**ANSWER :** Anterior cruciate ligament

71. Clinical case in which patient with pain upon internal rotation and varus of the leg:

**ANSWER :** Trauma in lateral meniscus

72. Clinical case in which patient with numbness in thumb, index and middle finger indicating:

**ANSWER :** Median nerve entrapment



# Chapter 13

## musculoskeletal system

**73. Clinical case of osteoarthritis, which of the following is least likely to see?**

**ANSWER : Bouchard nodes on the extensor surface of the forearm**

**74. True about knee:**

**ANSWER : suprapatellar pouch is an extension of synovial membrane beneath quadriceps**

**75. Not part of the wrist joint:**

**ANSWER : Ulnoradial joint**

**76. Causes splenomegaly and leg ulcers:**

**ANSWER : rheumatoid arthritis**



# Chapter 13

## musculoskeletal system

**77. Sudden toe pain with redness, tenderness, hotness:**

**ANSWER : acute gouty attack**

**78. Patient with morning stiffness for less than 10 minutes with crepitation:**

**ANSWER : Osteoarthritis**

**79. A patient with carpal tunnel syndrome, after having surgery to remove the pressure over the median nerve, will have all of the following return back to normal except:**

**ANSWER : Wasting of the thenar muscles**

**80. 33-year-old female who is one month postpartum presented with pain exaggerated by movement of the wrist and thumb, what is the diagnosis:**

**ANSWER : De Quervain's tenosynovitis**



# Chapter 13

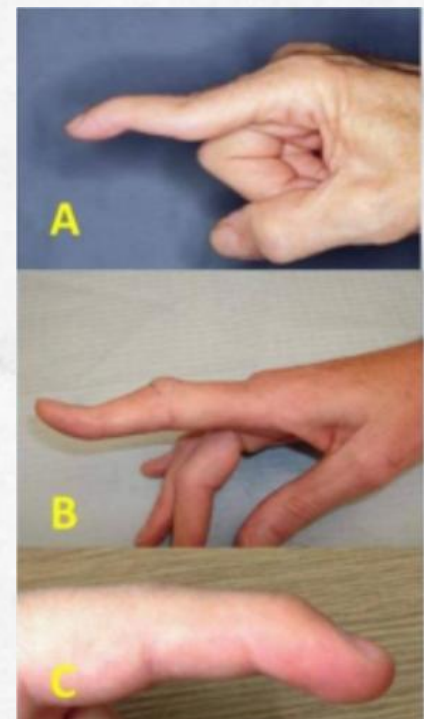
## musculoskeletal system

81. all of the following matches are true except:

**ANSWER : abductor pollicis brevis : radial nerve**

82. Match each image (A-C) with the proper deformity name :

- A) Mallet finger
- B) Zig Zag deformity
- C) PIP Subluxation
- D) Boutonniere deformity
- E) Swan neck deformity

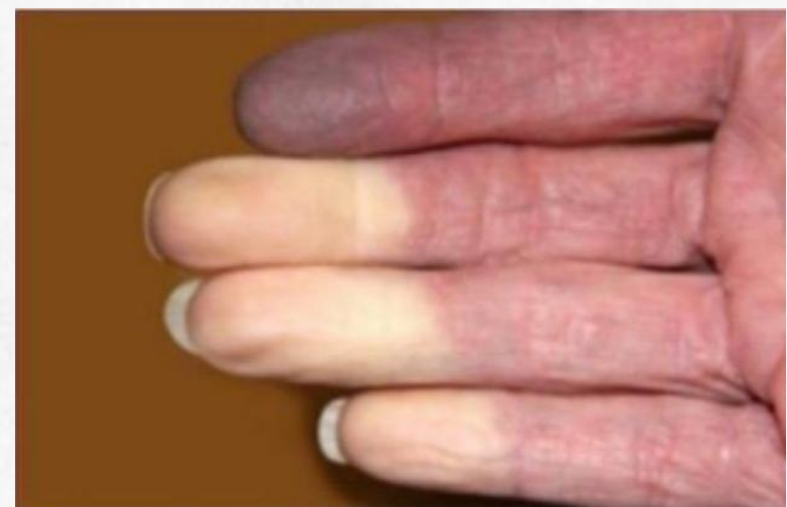

**ANSWER : Image A: e   Image B: d   Image C: a**

83. A 43 years old female patient, presented with this change of her finger colors .

**This clinical sign is called :**

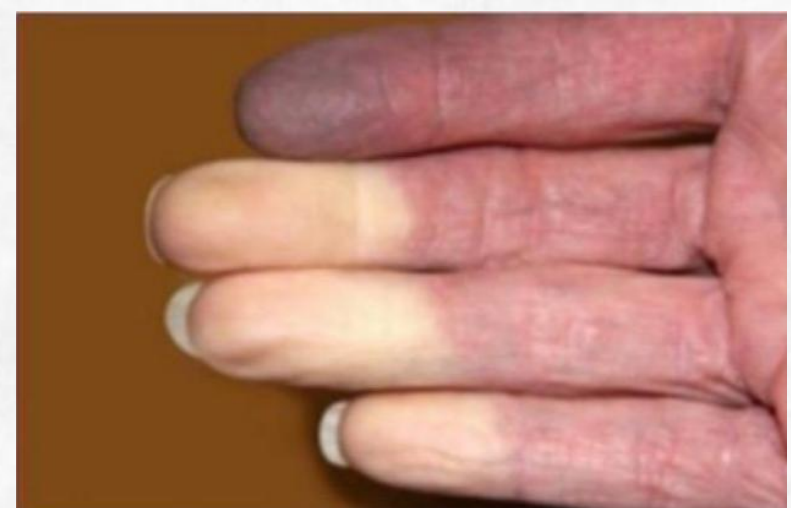- A) complex regional pain syndrome
- B) Chilblain
- C) Raynauds
- D) Peripheral neuropathy
- E) Thrombangitis obliterans



**ANSWER : C**

84. is/are not of the possible causes

- A) Connective tissue diseases
- B) Drugs
- C) Power tools
- D) Upper limb deep vein thrombus
- E) Peripheral arterial disease



**ANSWER : D**

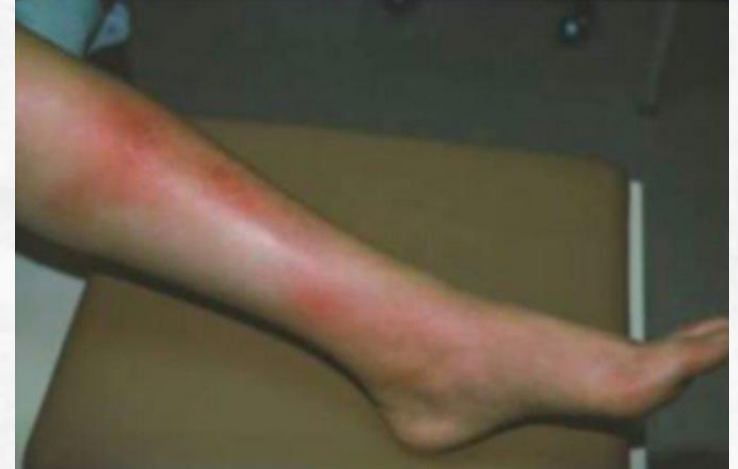

# Chapter 13

## musculoskeletal system

85. A 30 years old female patient presented with this painful skin lesion on her left lower limb . The most likely diagnosis is :

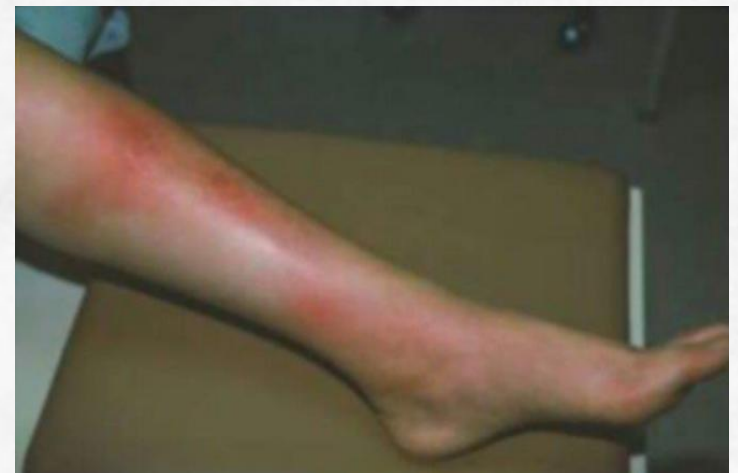- A) Lichen planus
- B) Erythema nodosum
- C) Pyoderma gangrenosum
- D) Erythema multiforme
- E) Erythema marginatum



**ANSWER : B**

86. This skin lesion is most likely associated with :

- A) Sarcoidosis
- B) Multiple sclerosis
- C) Liver cirrhosis
- D) Candida infection
- E) Psoriasis



**ANSWER : A**



اللهم سلم غزاة وأهلها من كل سوء وشر، اللهم انصرهم وثبت أقدامهم وكن لهم ناصرًا ومعينًا

لا تنسوني من صالح دعائكم

***Malek Abu Rahma***

**The End**  
**Good Luck シ**