

# Physical examination

## General + Lymph node

Alanoud Helalat

### • Opening steps for every examination:

- ✓ introduce yourself + Patient name
- ✓ privacy
- ✓ hygiene
- ✓ environment (light, temp, ....)
- ✓ Chaperon
- ✓ patient Consent
- ✓ Position <sup>(posture)</sup>
  - Ant: examination → 45°, head on pillow
  - post: examination → sitting upright
- ✓ exposure (neck to umbilicus)
- ✓ explain what you will do

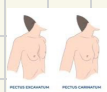مرحباً أنا العبد هلالات طالبة طب  
سنة رابعة، بتسجلي الفحص /  
أخذ المسيرة الرقمية منك؟

سأعرفني بإسكن؟  
• بتعرف انت ديت؟  
• الدنيا صبح او ليل؟  
• بتعرف مني هذا؟

Patient is conscious,  
alert & oriented to  
place, time & person

### • General inspection:

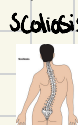
From foot of bed



From right of Patient



- ✓ Chest deformities → (Pectus carinatum, pectus excavatum)
- ✓ Bilateral symmetrical chest
- ✓ Pattern of breathing
- ✓ Chest shape



Sternocleidomastoid



Intercostals



- ✓ Facial expression
- ✓ Respiratory distress, breathing effortlessly
- ✓ (Sitting in tripod position, pursed lips)

- ✓ Normal eyeballs
- ✓ Clothing is appropriate to weather
- ✓ Medical devices/equipments

(Inhaler, cannula, Foley's catheter)

- ✓ Cyanosis (Central, peripheral)
- ✓ No muscle wasting
- ✓ Audible sounds
- ✓ (Wheeze, stridor, hoarseness)

Respiratory rate & heart rate

- ✓ Skin lesions



## Comments:

The patient is sitting at 45 degrees, Comfortable, conscious, alert, oriented to place time and person, No attachment to medical equipment, No audible sounds, No abnormal odors, No skin discoloration, No cyanosis, No chest deformities like Kyphosis / scoliosis / pectus excavatum / pectus carinatum / barrel chest), abdomiothoracic breathing pattern, No distress signs (intercostal retraction, using of accessory muscles, pursed lips, Tripod position, tachypnea)

- Vital Signs: BP,  $\uparrow$  heart rate, RR, Temp,  $\uparrow$  O<sub>2</sub> saturation, BMI by pulse oximeter
- Stature
- Gait
- Pain Score "Patient looks comfortable"

✓ Jaundice



✓ Pallor



- ✓ engaged in conversation (No signs of apathy or withdrawal)
- ✓ Breathing odours (uremia, fetor hepaticus)
- ✓ Chest scars
- ✓ Normal hair distribution
- ✓ Normal ant. post. diameter "by looking"

## Face

### eyes

- ✓ Pallor
- ✓ Jaundice
- ✓ Conjunctiva
- ✓ Horner Syndrome
  - 1. Miosis
  - 2. Ptosis
  - 3. Anhidrosis

### Nose

- ✓ Nose flaring
- ✓ Cyanosis

### Cheeks

- ✓ plethora (redness)

### Mouth & tongue

- ✓ oral hygiene
- ✓ Central Cyanosis
- ✓ Tooth caries
- ✓ Beefy & raw tongue
- ✓ ulcers / dry mucous membranes (for hydration)
- ✓ Tongue deviation
- ✓ Glossitis / macroglossia
- ✓ Palate deformities

### Superior vena cava obstruction signs

- Face & neck swelling
- Dyspnea
- head pressure
- Cyanosis or plethora
- stridor

## Neck

- ✓ Scars
- ✓ Swelling
- ✓ Accessory muscles
- ✓ JVP
- ✓ Dilated/engorged veins
- ✓ Lymph nodes / thyroid gland
- ✓ masses
- ✓ Cricosternal distance
- ✓ Tracheal deviation
- ✓ Visible pulsation

## Speech

- ✓ Full sentences
- ✓ Cough

→ The distance to normal 3-4 fingers

→ slightly deviated to rt / lt.  
→ No tracheal deviation, the trachea is in the midline

## Hands

### ① Inspection

- ✓ Tar staining
- ✓ Tremor
- ✓ Flapping tremor

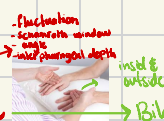

- ✓ vitiligo
- ✓ Amputation
- ✓ deformities (ulnar deviation)
- ✓ skin creases pigmentation
- ✓ Coarse skin



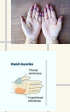### ② Palpation

- ✓ Clubbing
- ✓ Temperature

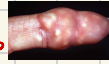

→ Bilateral warm hands

- ✓ Peripheral cyanosis
- ✓ Muscle wasting
- ✓ Nail discoloration
- ✓ Palmar erythema
- ✓ wrist tenderness (RA?)



- ✓ Tight skin
- ✓ Ca<sup>2+</sup> deposits
- ✓ ulcers
- ✓ Pitting / Koilonychia / leukonychia
- ✓ Scars / swelling



- ✓ Capillary refill
- ✓ Radial pulse
- ✓ Tenderness \*eye-eye contact
- ✓ Dry or wet



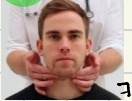## Hydration assessment:

- ① signs of dehydration:
- ✓ Dry mucus membrane
  - ↓ urine output
  - Tachypnea or hypotensive
  - loss of skin turgor

- ② edema: localized or general

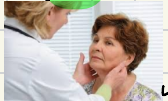## Lymph nodes:

Standing post. to patient



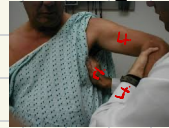- ✓ Submental
- ✓ Submandibular
- ✓ Tonsillar
- ✓ Preauricular
- ✓ Supraclavicular
- ✓ deep cervical
- ✓ Scalene

Standing Ant. to patient



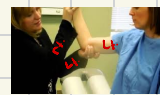- ✓ Occipital
- ✓ Post. auricular
- ✓ Post. cervical
- ✓ Base of the neck L-N

Axillary



- ✓ Ant. folds
- ✓ Post. folds
- ✓ lateral
- ✓ medial

Epitrochlear



I have to examine abdominal & lower limb

Alanoud  
Helalat

General & Lymph node ✓