

# NEONATAL INTESTINAL OBSTRUCTION

---

ABEER ALDIAB, MBBS ,JBPS,EBPS,FRCS ENG (PAED SURG)

- 
- Age : neonatal , infantile , children
  - Organ : duodenal , small bowel , colon
  - Cause : ischemic , inflammatory , mechanical ( adhesions , congenital bands)

- 
- **Intestinal atresia**
  - **Malrotation**
  - **Meconium ileus**
  - Meconium plug
  - **Hirschsprung disease**
  - **Anorectal malformations**
  - **Necrotizing enterocolitis**
  - Inguinal hernia


# INTESTINAL ATRESIA

---

- Abnormal formation of the bowel resulting in discontinuation of the bowel length ... complete or partial obstruction
- Can occur any where

# ESOPHAGEAL ATRESIA / TRACHEOESOPHAGEAL FISTULA (EA/TEF)

---



# DUODENAL ATRESIA

---



- 
- 1 per 5000– 10,000 live births
  - Affecting boys more commonly than girls.
  - Associated anomalies in 45–65% of cases.
  - Most commonly trisomy 21 (half of the cases) , cardiac malformations ( 25–30% ) ,GI anomalies ( 25-30% ).
  - Approximately 45% of babies are premature, and about one-third exhibit growth retardation.

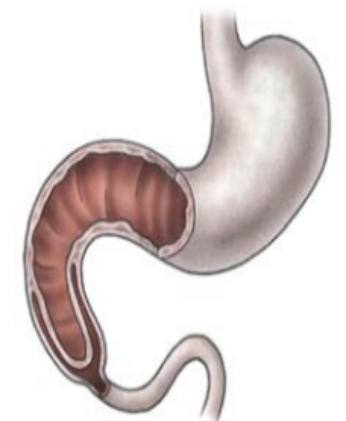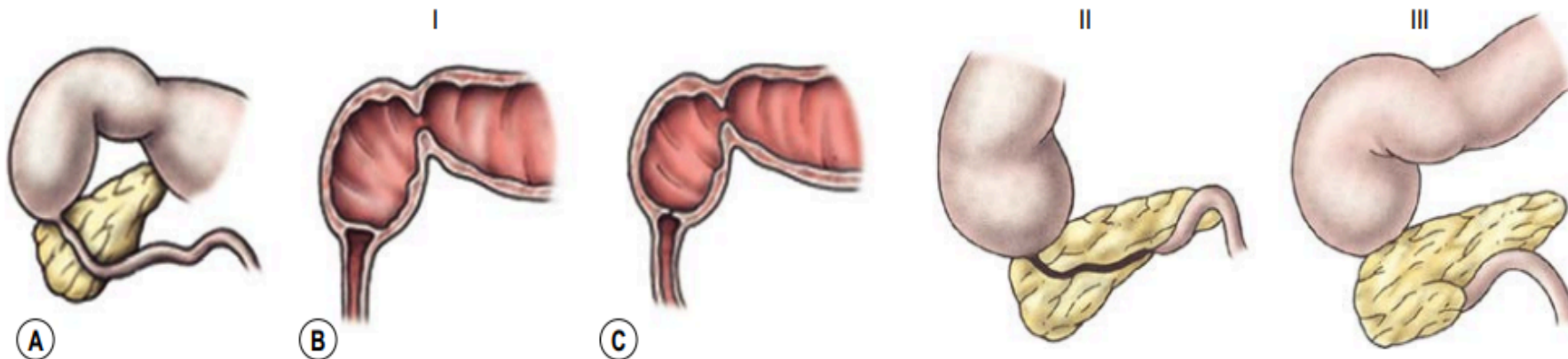
# TYPES

- Congenital Duodenal obstructions are classified into complete or incomplete obstruction

Incomplete obstruction (type I) as fenestrated web or diaphragm and stenosis and most involve the third and/ or fourth part of the duodenum.

complete obstruction ( type II : 2 ends connected with fibrous cord , type III :complete separation )

- ~85% of obstructions located distal to the ampulla.



windsock" deformity

# DIAGNOSIS

---

- Antenatally :

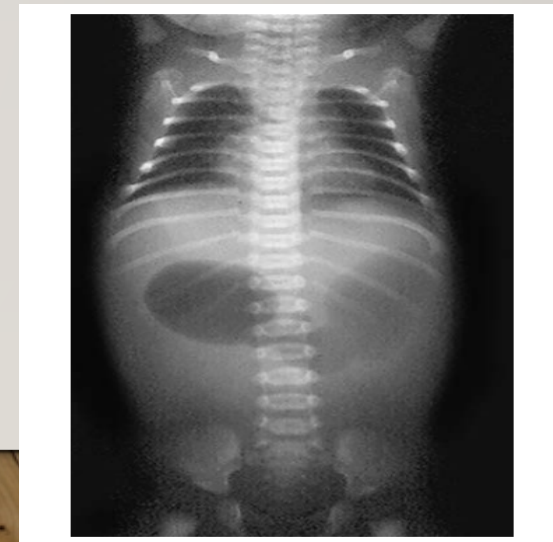
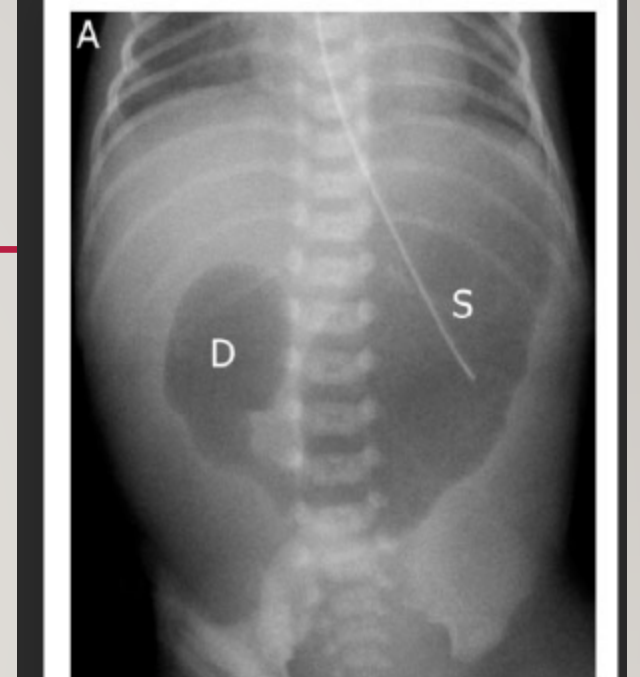
polyhydramnios (32–81% with complete obstruction )

Double bubble sign ( up to 44% )

- Postnatally:

Classic presentation is that of bilious emesis within the first hours of life in an otherwise stable neonate +/- upper abdominal distension .

On exam : abdomen is scaphoid.



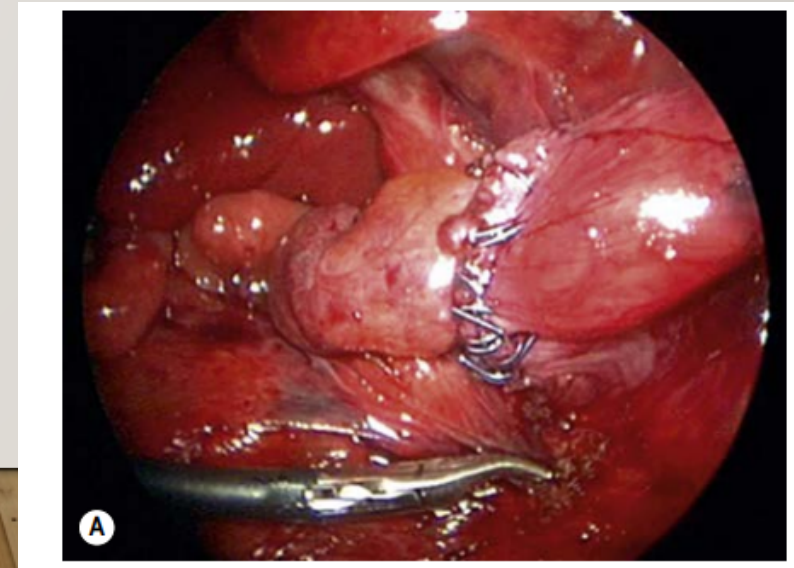
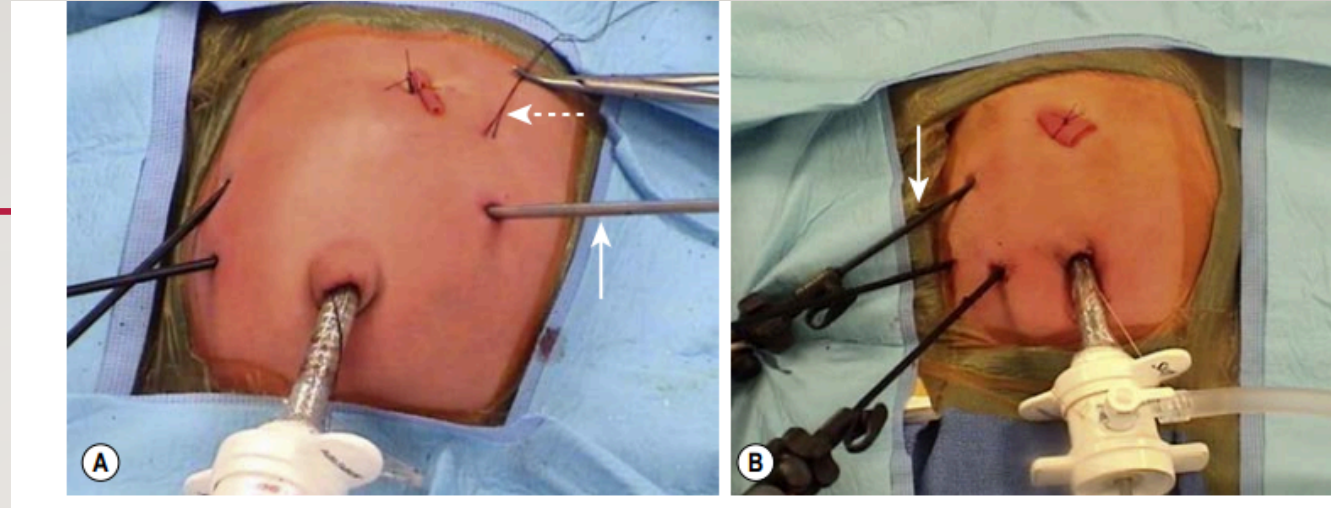
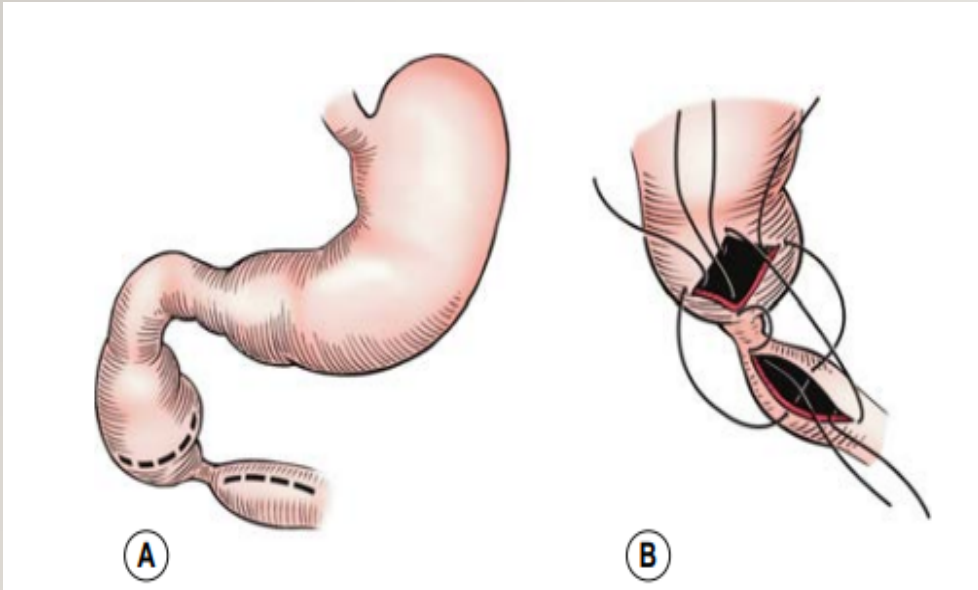
# MANAGEMENT

---

- Resuscitation with correction of fluid balance and electrolyte abnormalities
- NPO + IV access
- Gastric decompression with NG
- **Echocardiography prior to any operation.**
- Not an urgent operation unless malrotation with concurrent volvulus cannot be excluded.

- Surgery :

MIS ( laparoscopic) or open  
(diamond-shaped) duodenuodensotomy



- 
- Early postoperative mortality is low (3–5%) and its related to associated congenital abnormalities.
  - Long-term survival 90%.
  - Long-term complications have been noted following repair and include delayed gastric emptying, severe gastroesophageal reflux, bleeding peptic ulcer, megaduodenum, duodenogastric reflux, gastritis, blind-loop syndrome, and intestinal obstruction related to adhesions.

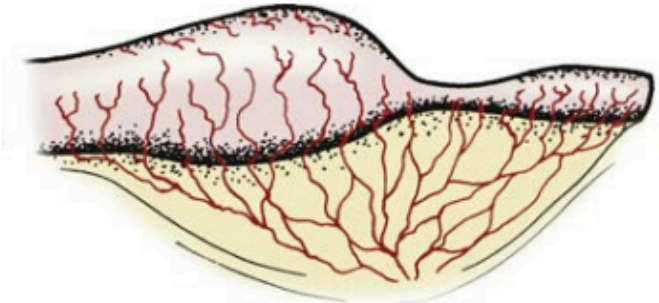
# SMALL BOWEL ATRESIA

---

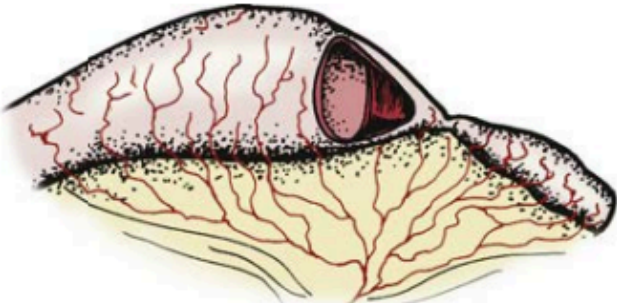


- 
- 1 in 3000-5000 live births.
  - It occurs equally in males and females
  - 1/3 of infants are premature
  - Majority of cases are sporadically
  - Intrauterine ischemic insult to the midgut
  - Affecting single or multiple segments of the already developed intestine

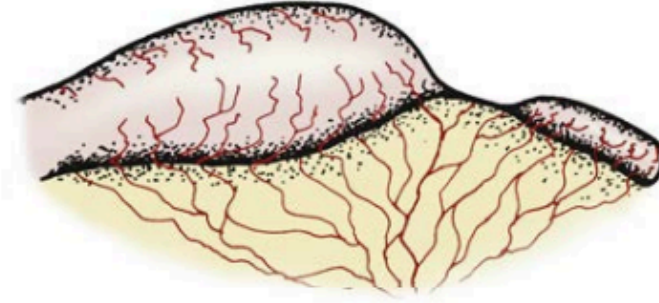
# TYPES



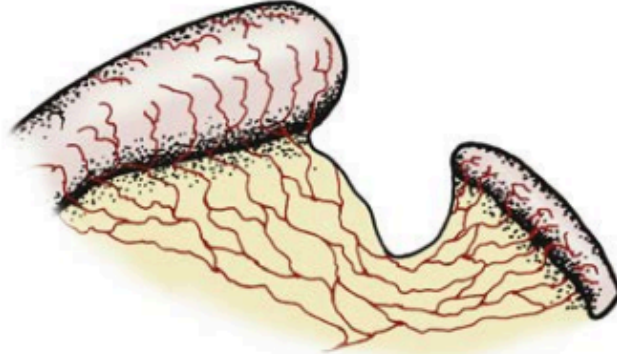
(A) Stenosis



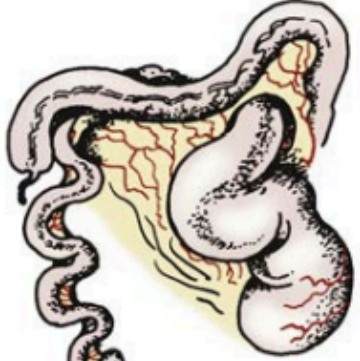
(B) Type I



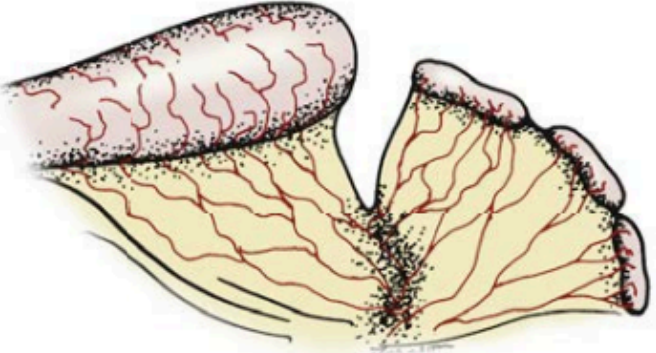
(C) Type II



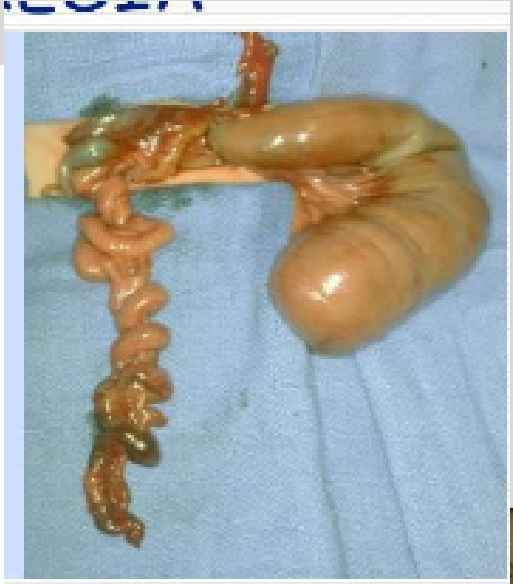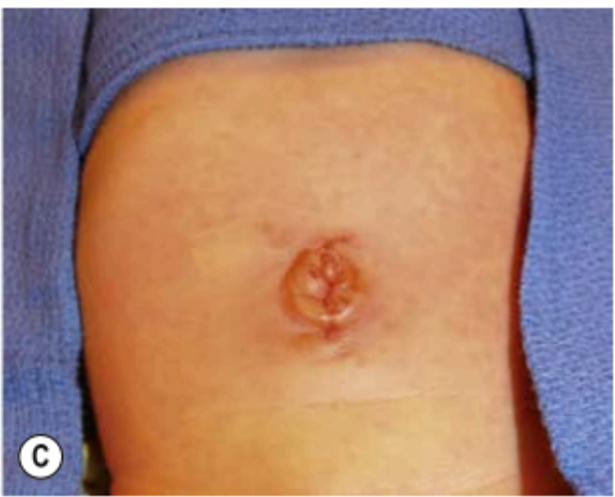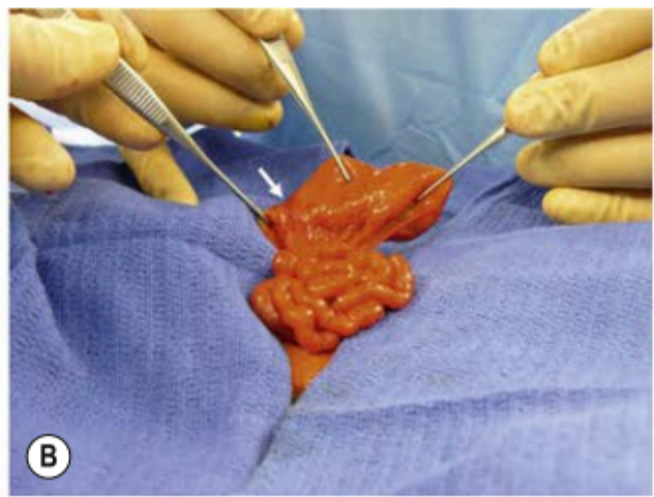
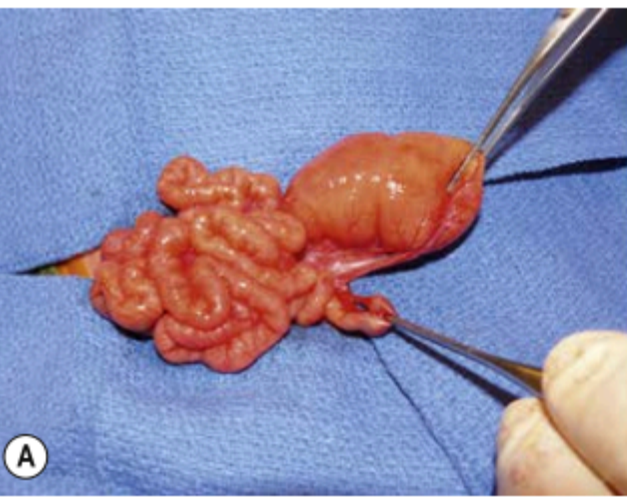
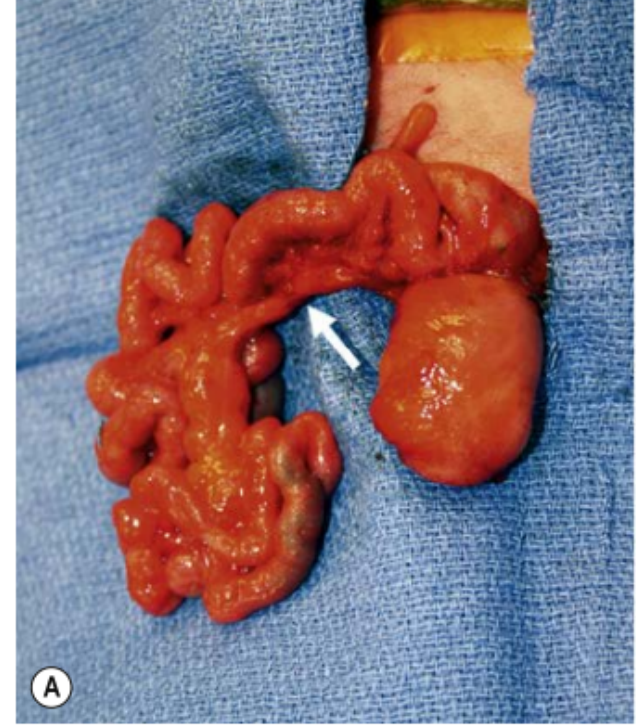
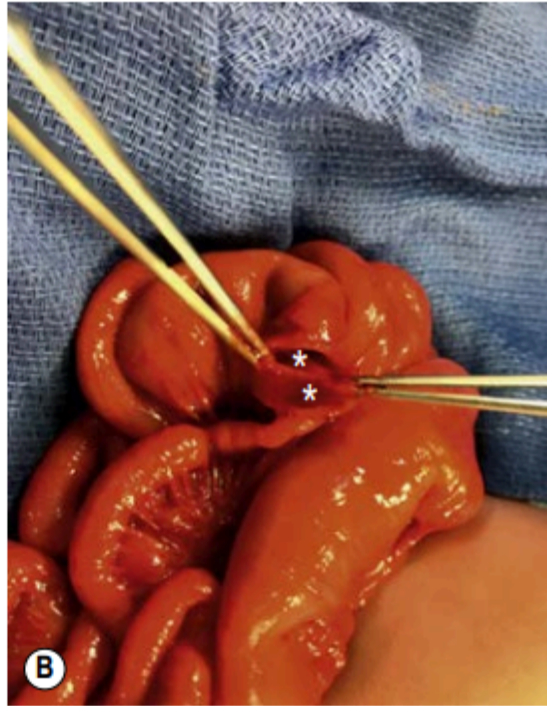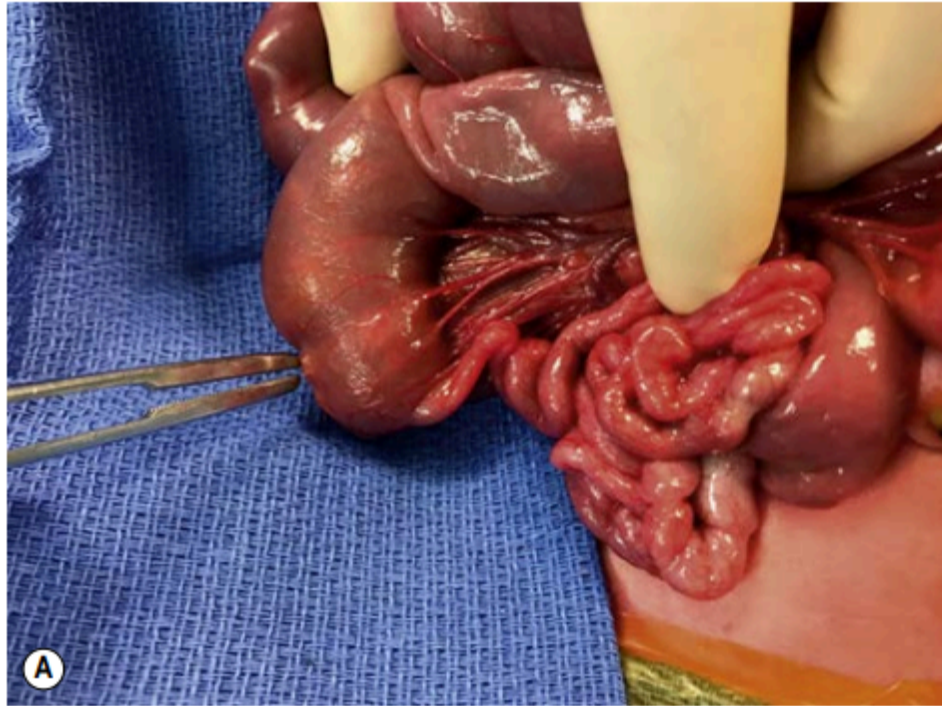
(D) Type III (a)



(E) Type III (b)



(F) Type IV



# PRESENTATION

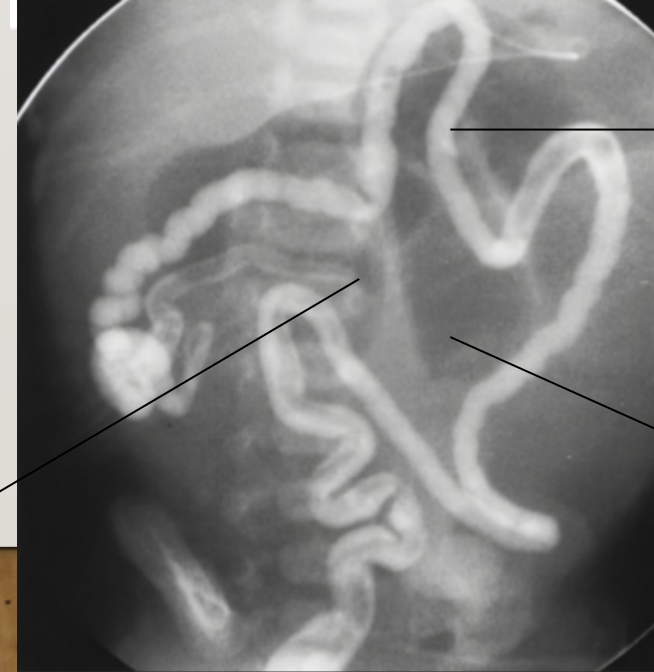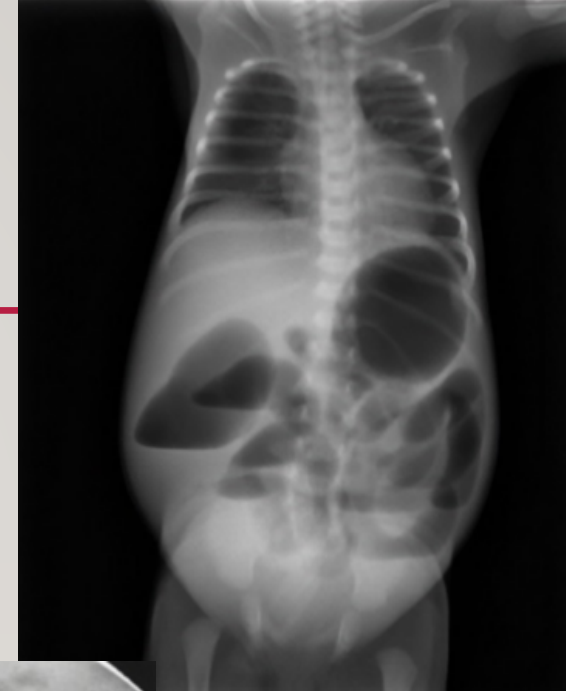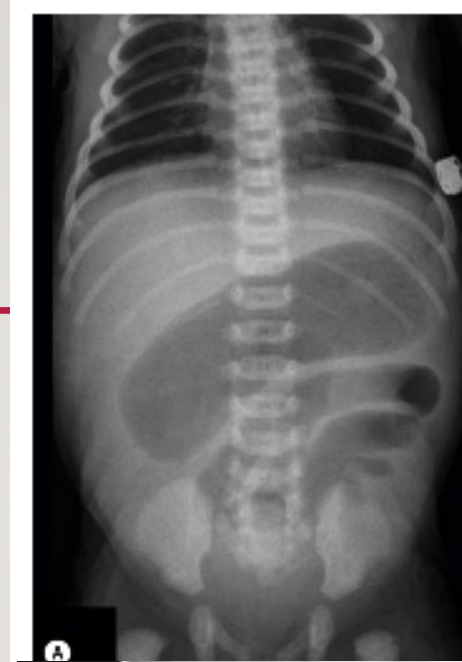---

- **Antenatal:**
- polyhydramnios ( more prominent with proximal atresia ).
- Dilated bowel loops
- echogenic bowel
  
- **Post natally :**
- Bilious vomits
- Distension (depends on the level of the obstruction)
- Might pass minimal amount of meconium

# DIAGNOSIS

---

- Abd Xray
- Lower contrast study /contrast enema  
it help with the diagnosis and rule out other  
differential diagnosis ( like HD and meconium ileus/  
plug )



MICROCOLON

No contrast going back into dilated loop

Dilated proximal bowel loops

# MANAGEMENT

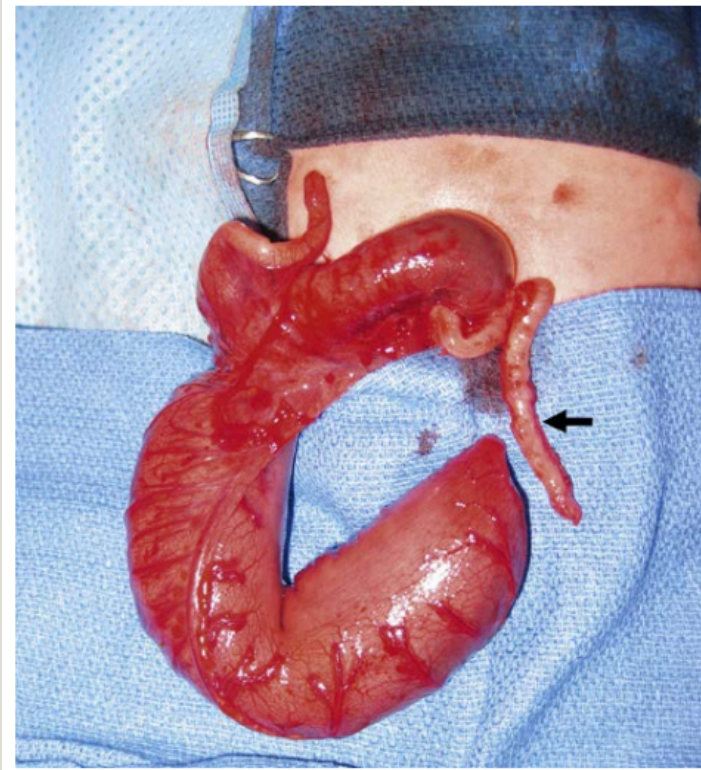
---

- Resuscitation
- NPO
- IV access + fluid
- Correct electrolyte
- Gastric decompression with NG

Surgery ( deliver all bowel and rule out other atresia ,assess the viability and length of remaining bowel , resection and anastomosis )

# COLONIC ATRESIA

---




- 
- Account for 2–15% of all GI atresias.
  - 1 in 20,000 live births
  - Mostly its an isolated anomaly however 1/3 of the babies have associated congenital lesions.

- 
- Three types:

Type I : consists of mucosal atresia with an intact bowel wall and mesentery

Type II: the atretic ends separated by a fibrous cord

Type III : the atretic ends are separated by a V-shaped mesenteric gap

- Type III is most common type, while types I and II are seen more commonly distal to the splenic flexure
- 

- 
- Abdominal distention, bilious emesis, and failure to pass meconium.

- Diagnosis :

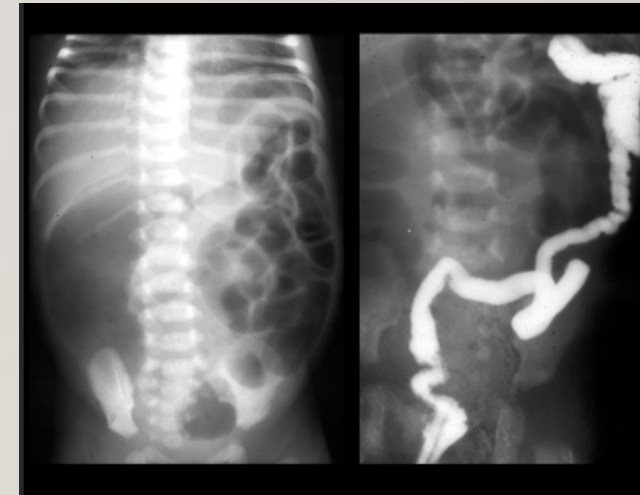Abd Xray : dilated bowel loops of large bowel often associated with a “ground-glass” appearance of meconium mixed with air

Contrast enema : small diameter distal colon that comes to an abrupt halt at the level of the obstruction

- Management:

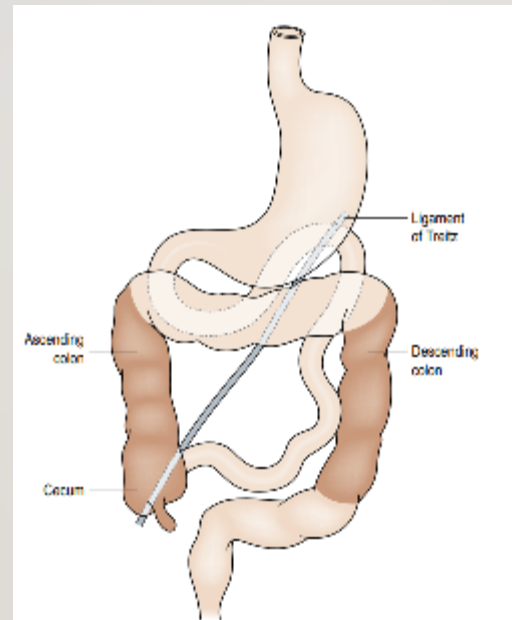
1. Resection and primary anastomosis

2. Staged approach (colostomy with mucous fistula followed by anastomosis)




# MALROTATION

---

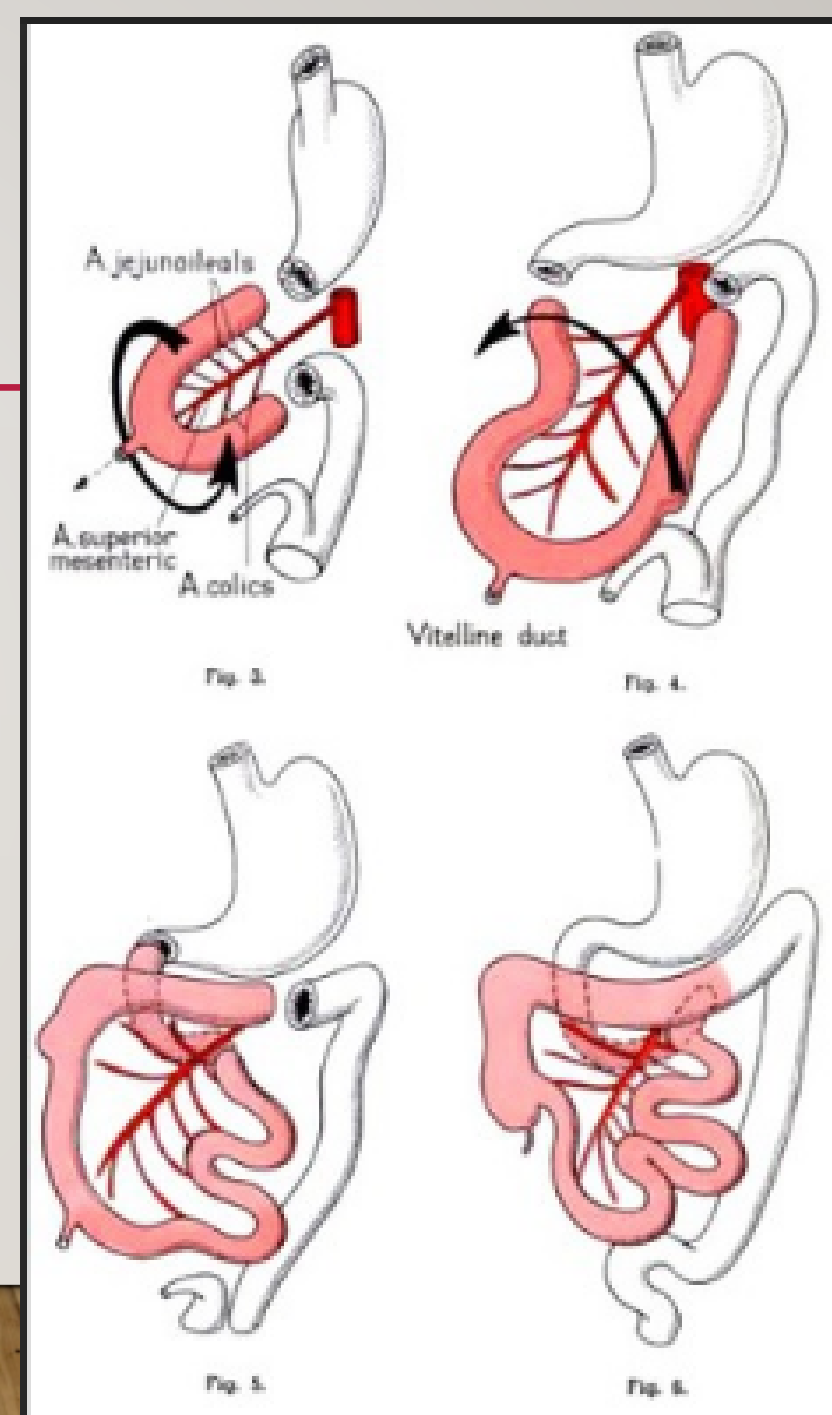


Normal anatomy

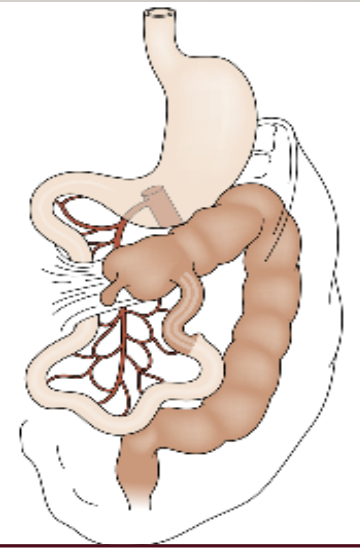
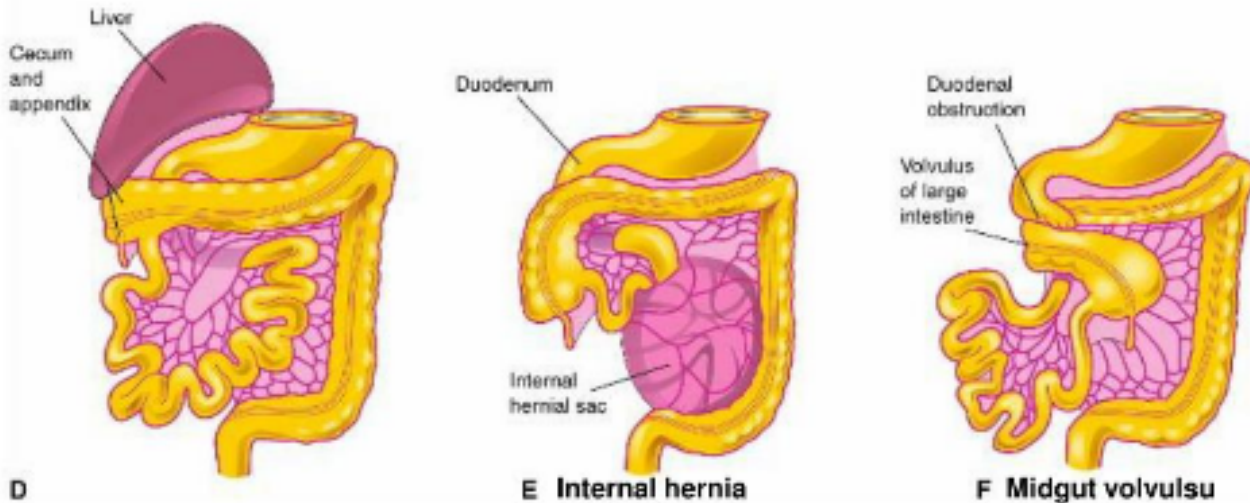
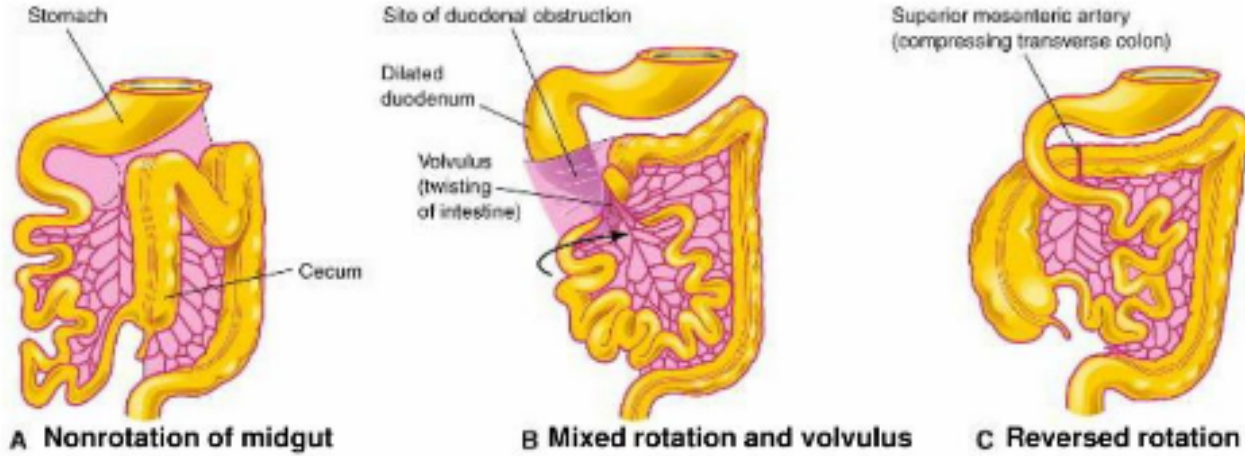


# EMBRYOLOGY

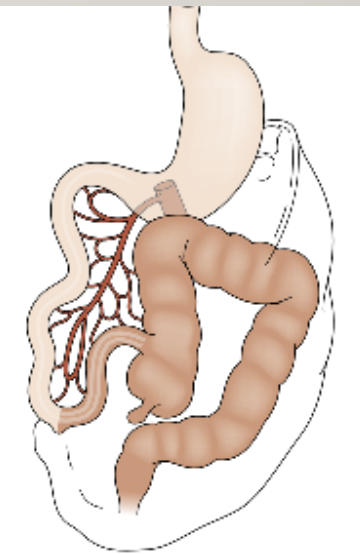
- midgut maturation involves four stages: (1) herniation, (2) rotation, (3) retraction, (4) fixation
- Embryology
- In total bowel rotates 270 degree counter clock wise around the SMA axis



# ITS A THE SPECTRUM



Incomplete rotation



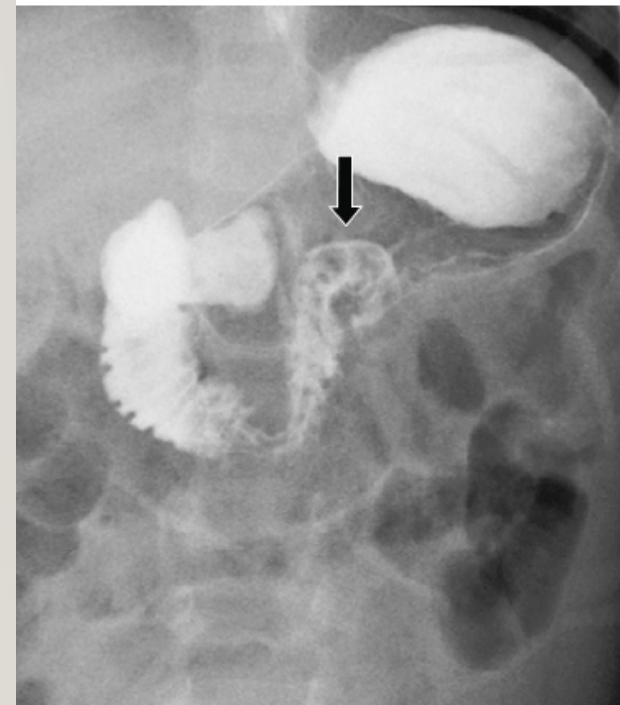
Nonrotation

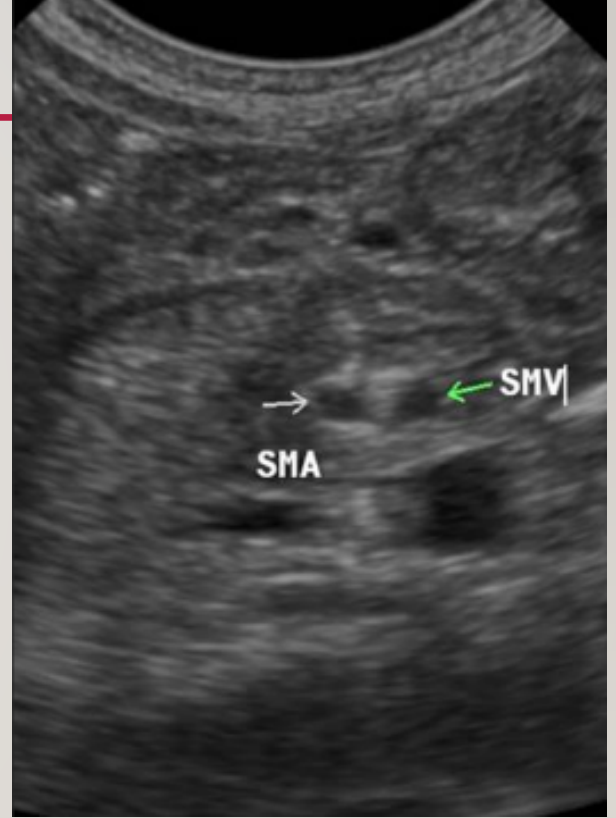
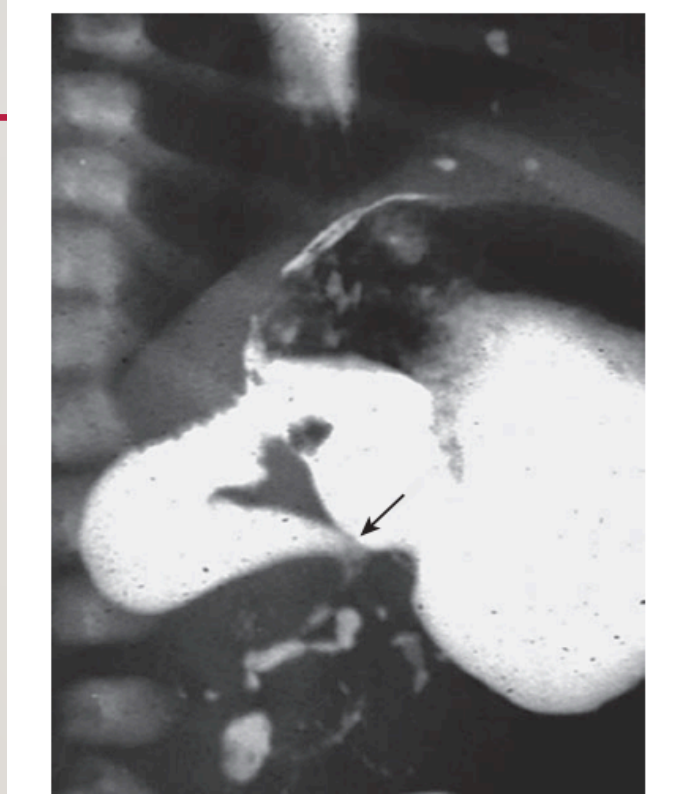
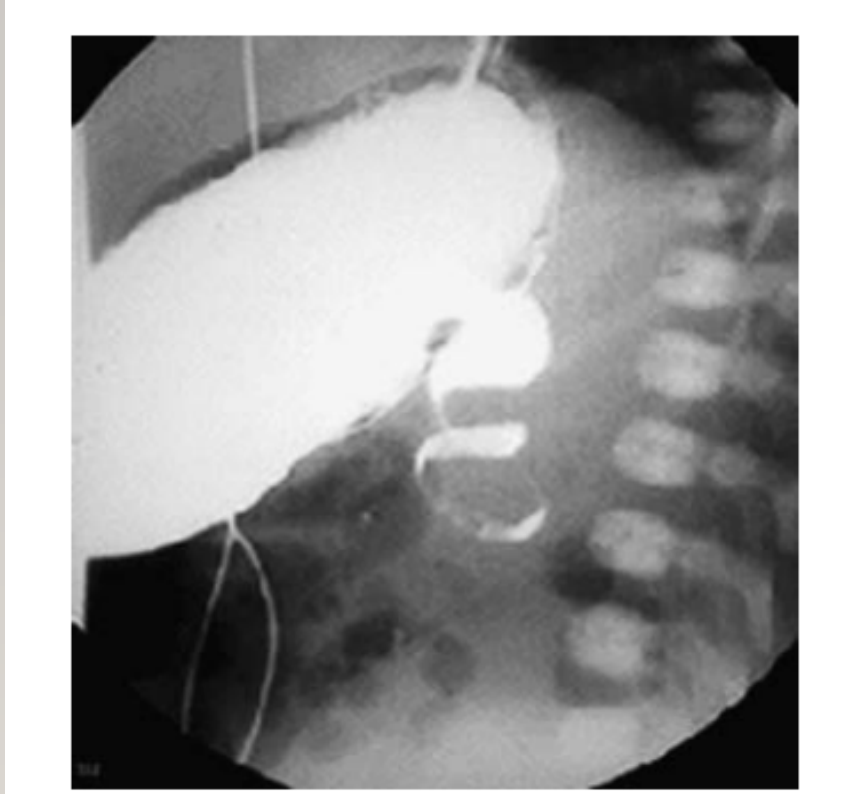- 
- 1 in 6000 live births
  - Classic malrotation with midgut volvulus often develops in a previously healthy term neonate.
  - Up to 75% of present during the first month of life and 15% will present within the first year.
  - Sudden onset of bilious vomiting is the cardinal sign of neonatal intestinal obstruction, and malrotation with volvulus must be the presumed diagnosis until proven otherwise

# DIAGNOSIS

---

- **The upper contrast study is the gold standard study**
- Color Doppler US





“Coil spring” or “corkscrew” configuration with incomplete obstruction and the “beak” appearance in the duodenum with complete obstruction

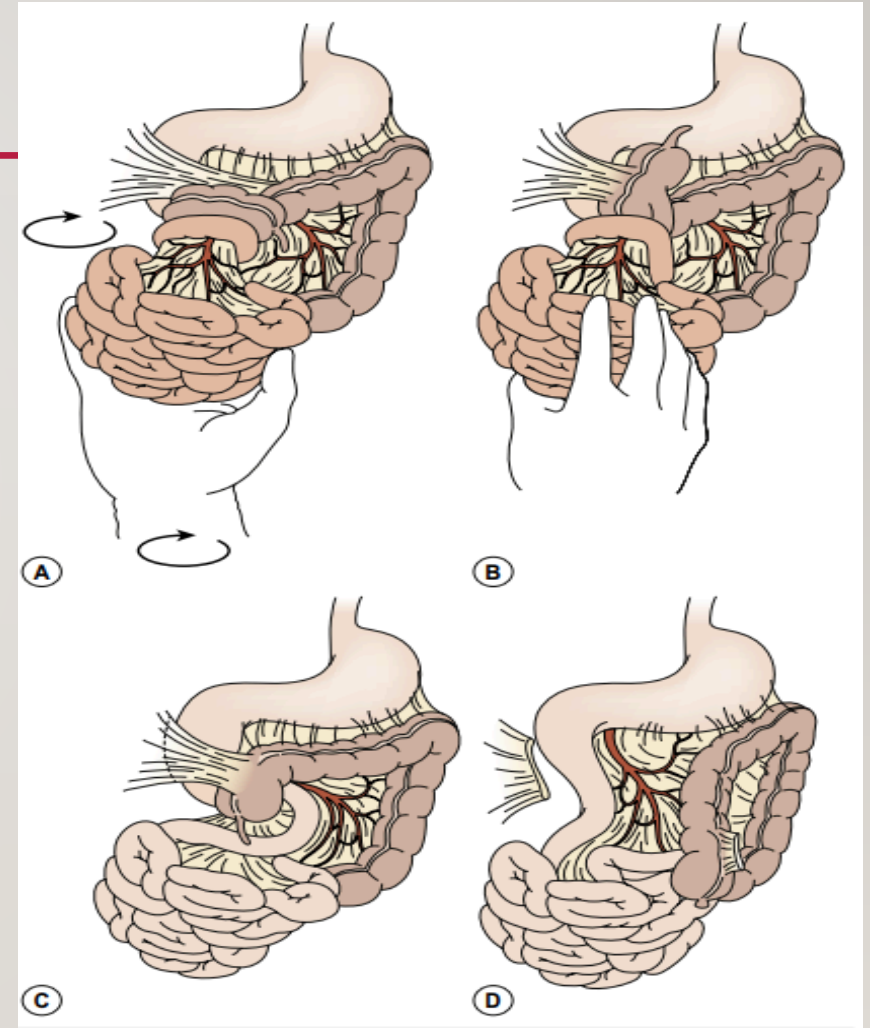
Dilated duodenum with inversion of the SMA and vein (the whirlpool sign) in cases of acute volvulus

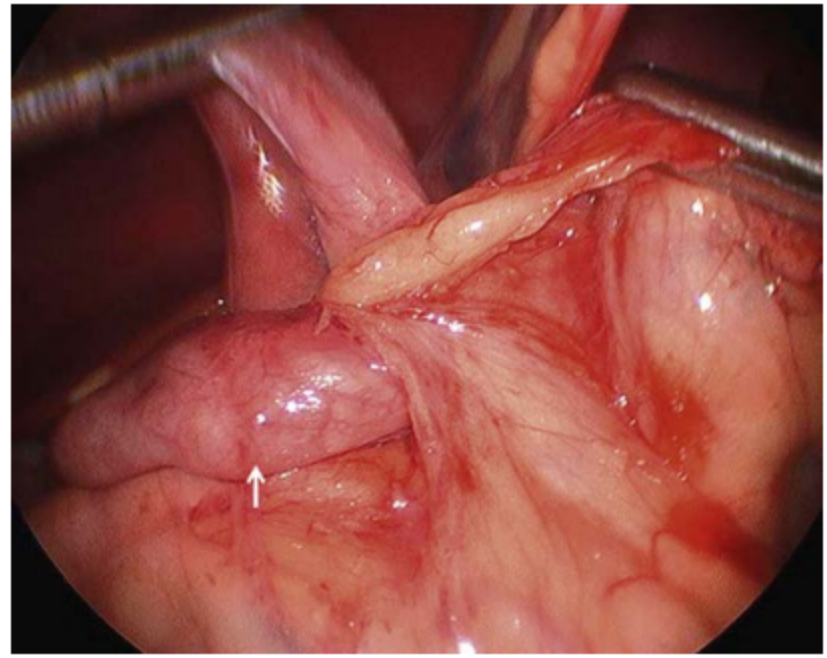
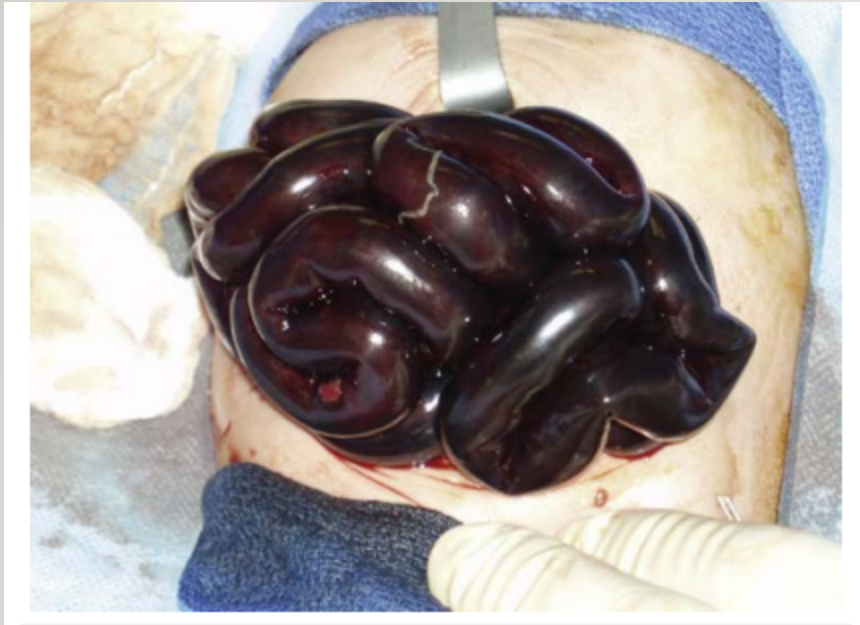# MANAGEMENT

- Resuscitation , gastric decompression , broad spectrum Abx
- Surgery : open/laparoscopic

## Box 31.1 Six Key Elements in Operative Correction of Malrotation

1. Entry into abdominal cavity and evisceration (open)
2. Counterclockwise detorsion of the bowel (acute cases)
3. Division of Ladd cecal bands
4. Broadening of the small intestine mesentery
5. Incidental appendectomy
6. Placement of small bowel along the right lateral gutter and colon along the left lateral gutter



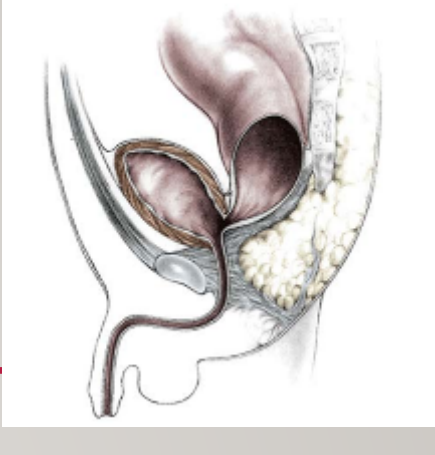
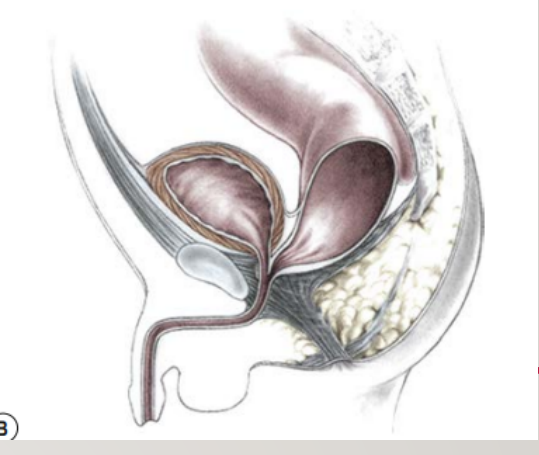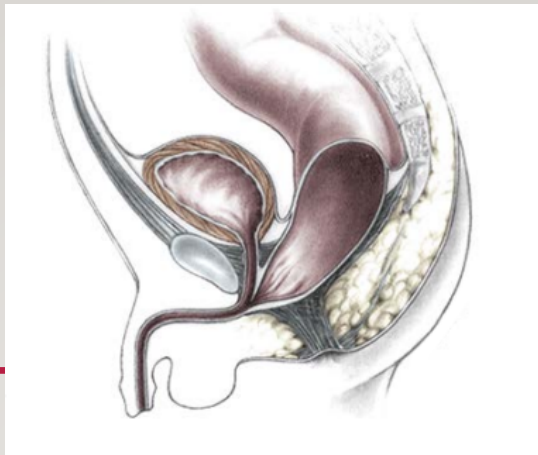

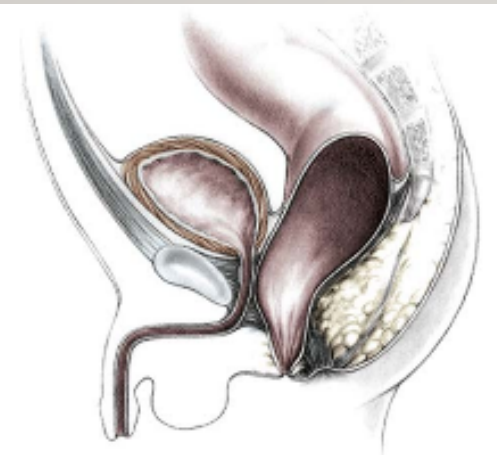
# ANORECTAL MALFORMATION (ARM)

---



- 
- 1 in 4000–5000
  - slightly more common in males
  - The estimated risk for a couple having a second child with an anorectal malformation is approximately 1%
  - Present as imperforate anus either with fistula (to GU tract ) or without fistula (5%, Down syndrome )



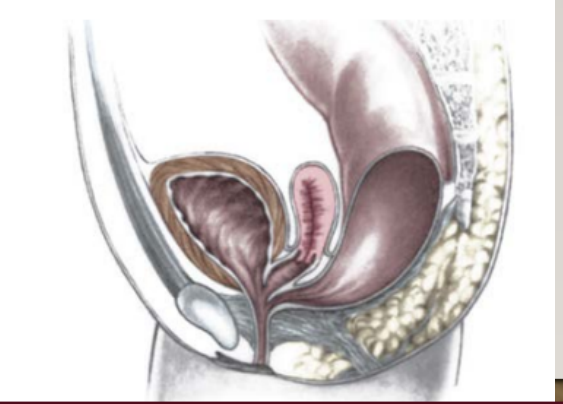
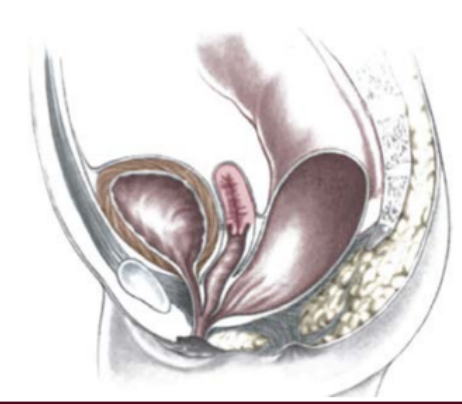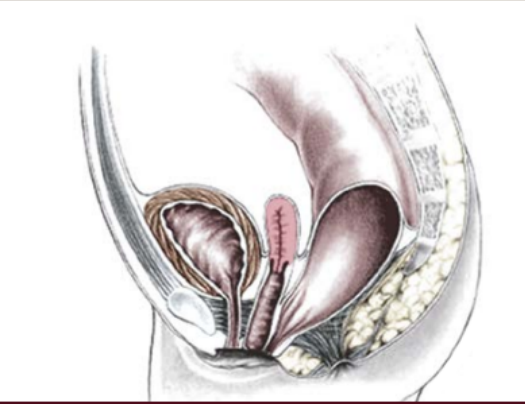
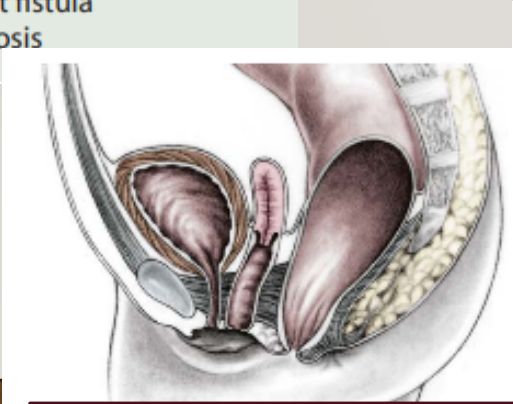
Recto perineal fistula

**Rectourethral bulbar fistula**

Rectourethral prostatic fistula

Rectobladder neck fistula

- Males**
- Rectoperineal fistula
  - Rectourethral bulbar fistula
  - Rectourethral prostatic fistula
  - Rectobladderneck fistula
  - Imperforate anus without fistula
  - Rectal atresia/rectal stenosis
- Females**
- Rectoperineal fistula
  - Rectovestibular fistula
  - Cloaca
  - Complex malformations
  - Imperforate anus without fistula
  - Rectal atresia/rectal stenosis



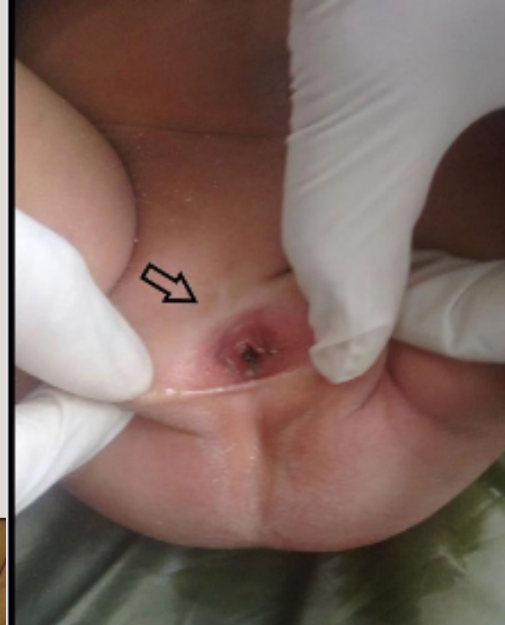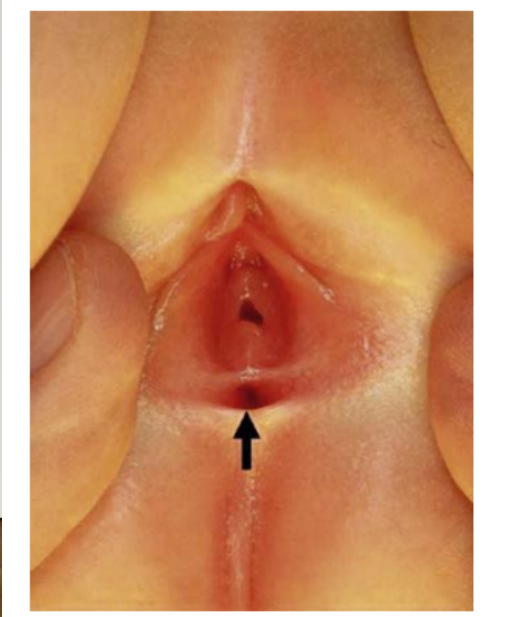
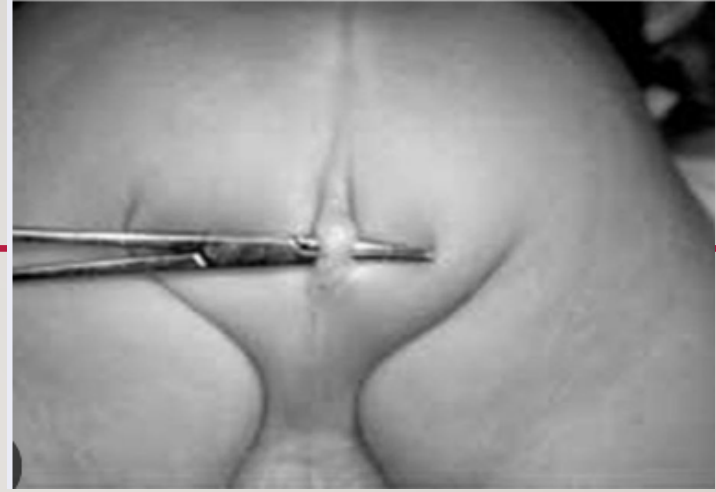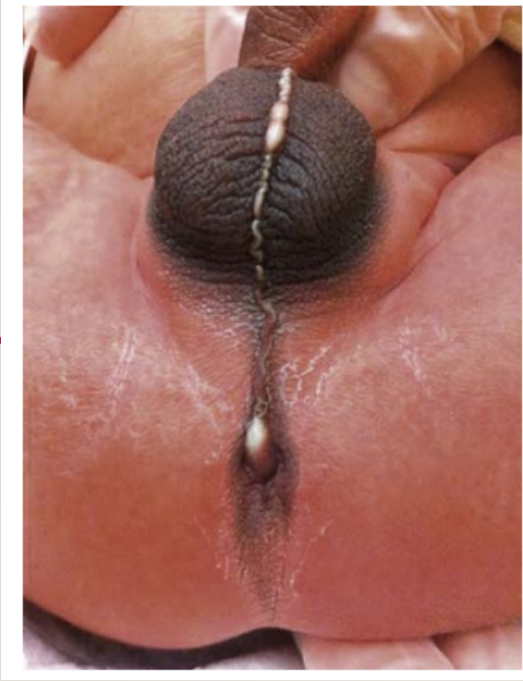
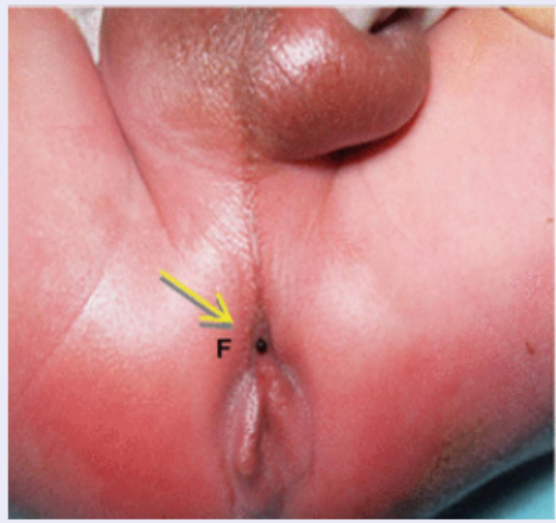
Recto perineal fistula

**Rectovestibular fistula**

cloaca ( short channel )

cloaca ( long channel)

- 
- Clinical examination is the most important step and you can diagnose most cases ( except with rectal atresia type/ normal looking anus)
  - Initial management :
    - Nasogastric tube (for decompression, & to rule out esophageal atresia)
    - NPO + IV fluids
    - Antibiotic prophylaxis
    - Watchful waiting (for 12-24 hrs)
    - Rule out VACTERL associations



## MALE Anorectal Malformation

Newborn male infant

No anus seen at birth

Inspect perineum @ 24 hours

Meconium in urine or cross-table lateral film showing rectum further than 1 cm

Stoma

Divided proximal sigmoid colostomy with skin-bridge and mucous fistula

Distal colostogram @ 8–10 weeks

Rectum reachable through posterior sagittal incision

PSARP

Exam of anus to determine size of anoplasty

Rectum NOT reachable through posterior sagittal incision

Laparoscopic assisted PSARP

Dilations started at 2 weeks post op

Meconium on perineum or cross table lateral film showing rectum within 1 cm

Primary PSARP

### VACTERL SCREENING:

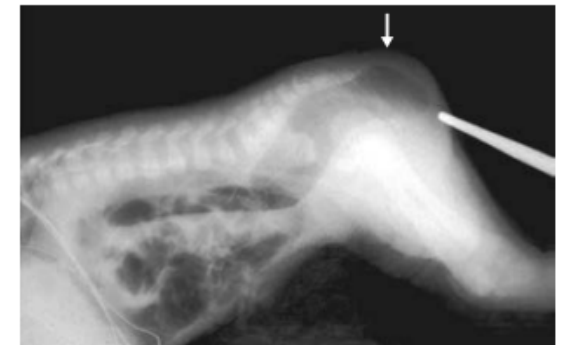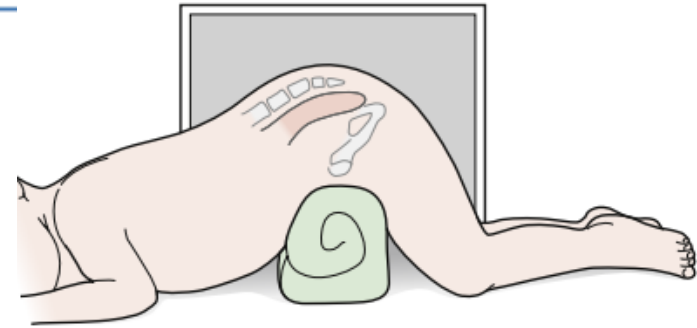
- **Spinal radiograph**
- **Sacral radiographs**
  - AP & Lateral
- **Spinal & Pelvic US** (<3 months old)
- **MRI spine** (>3 months old) or if spinal USS abnormal
- **ECHO**
- **NG tube** and AXR to confirm in stomach
- **Renal USS**
- **Limbs radiographs** (as clinically indicated)

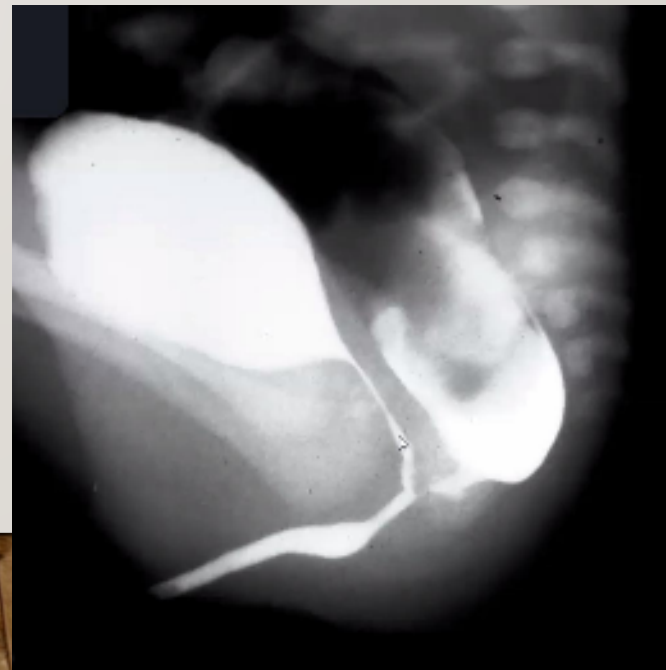
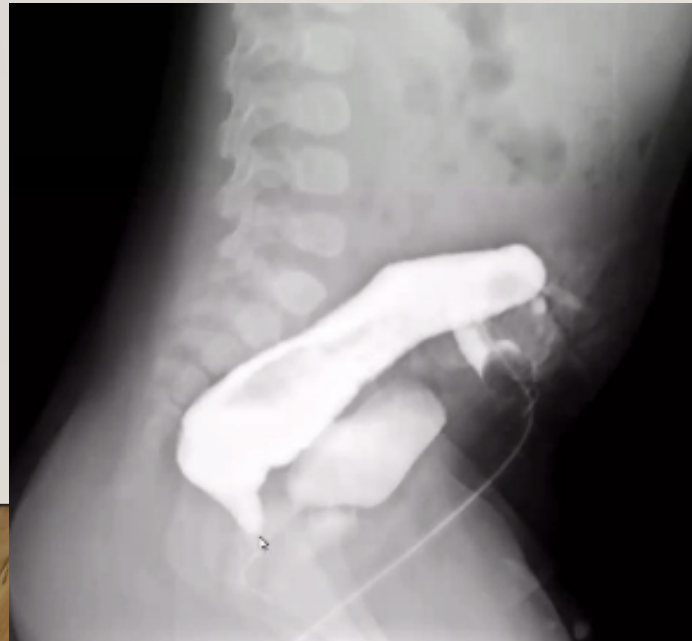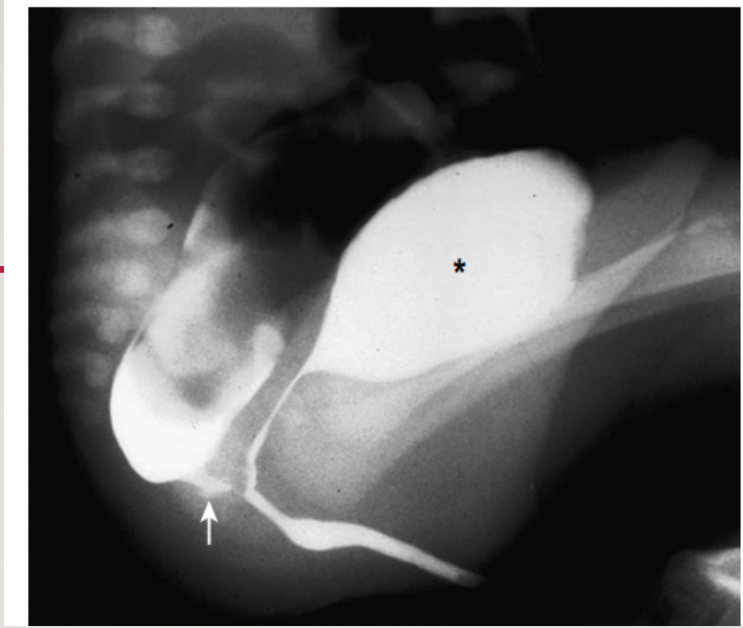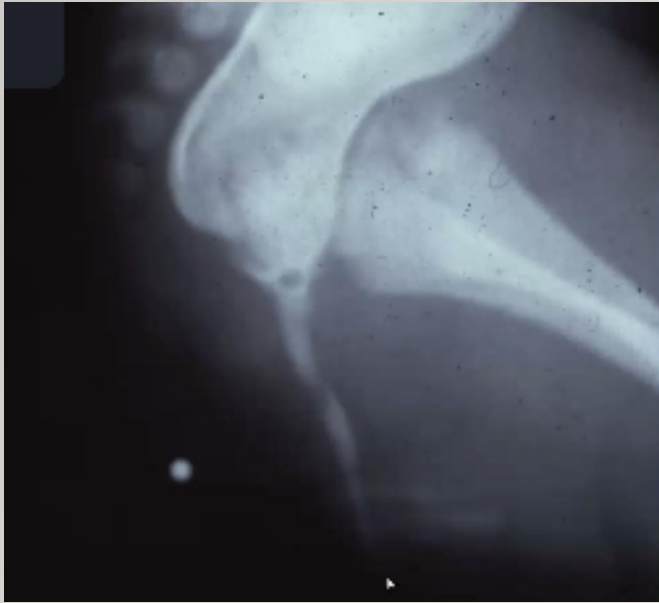
### Follow up:

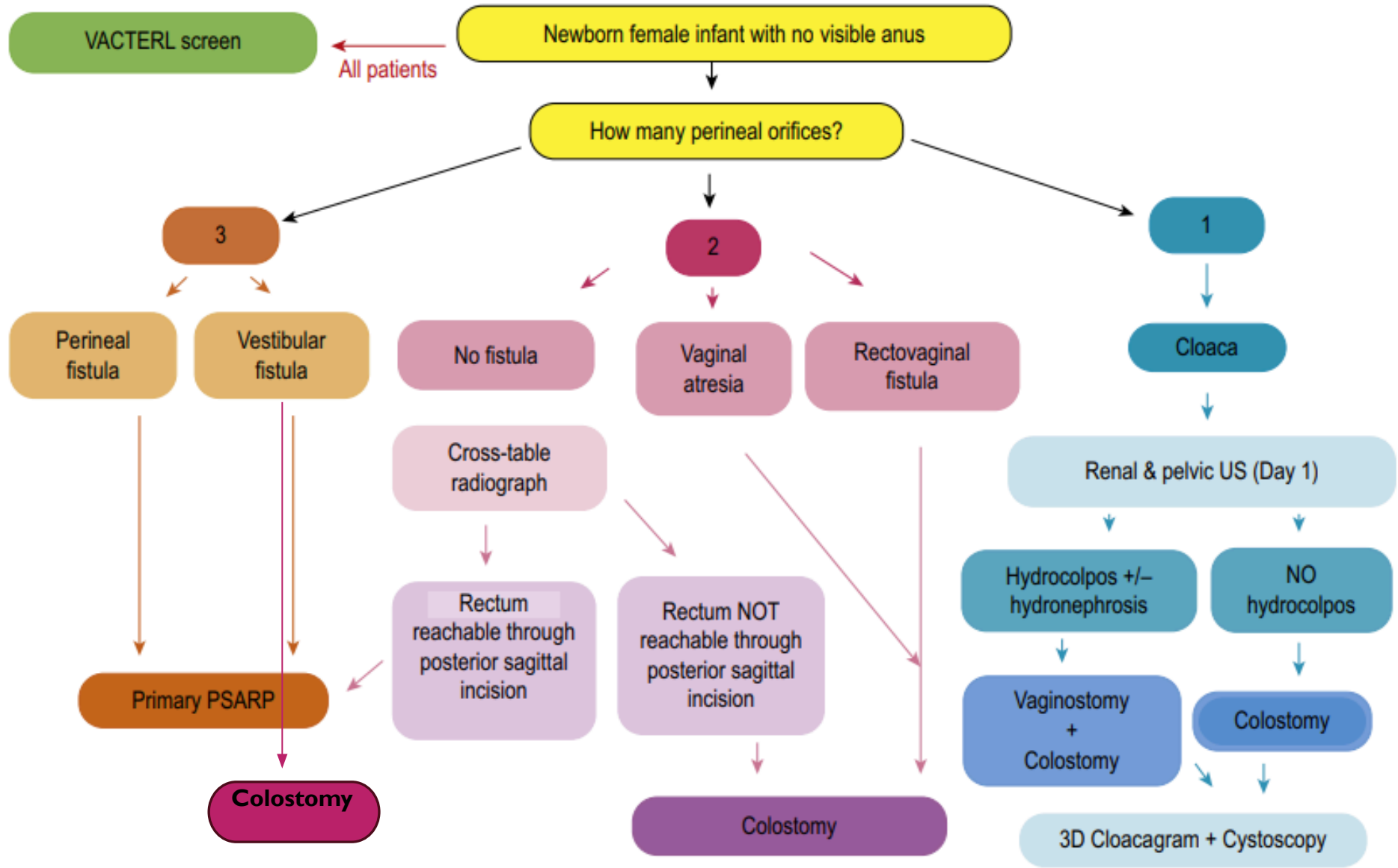
- 6 months
- 1 year
- Annually
- Continenence assessment @ 4 years

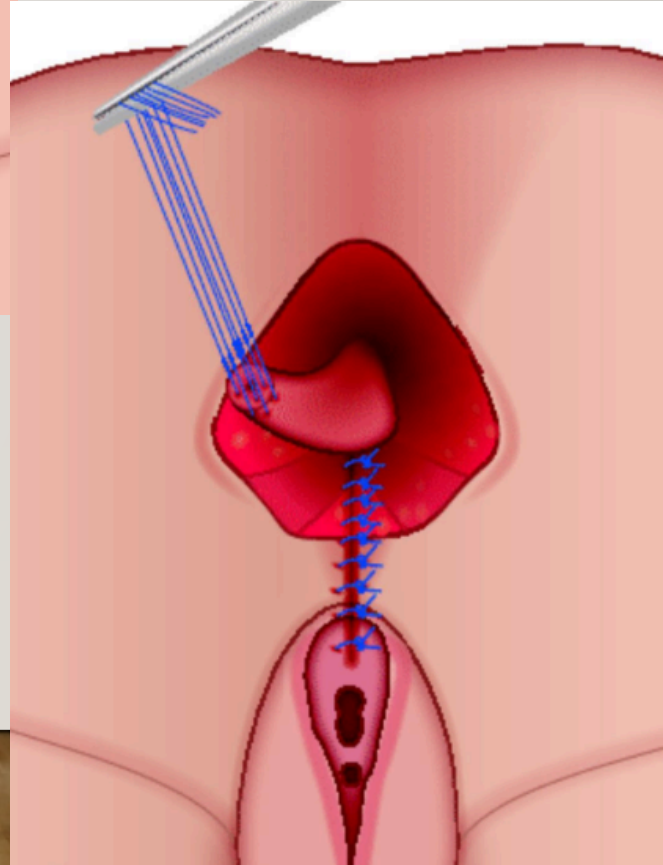
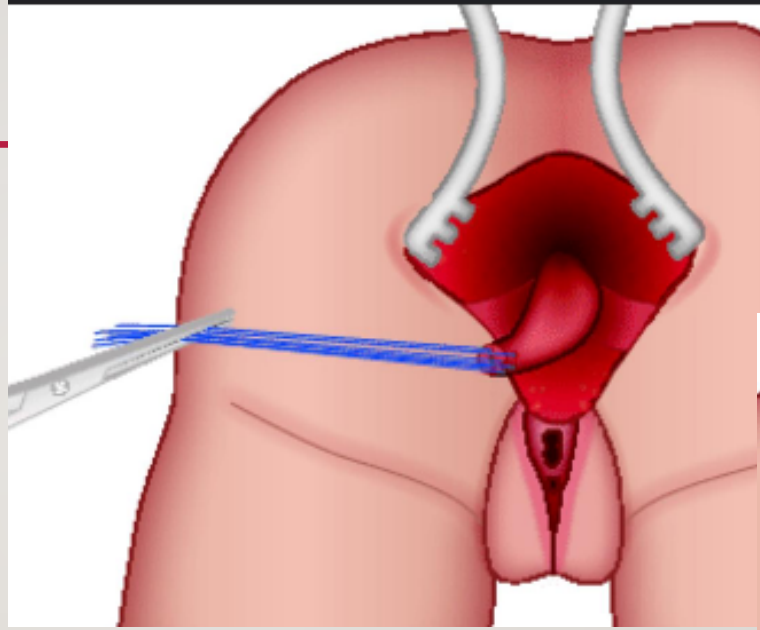
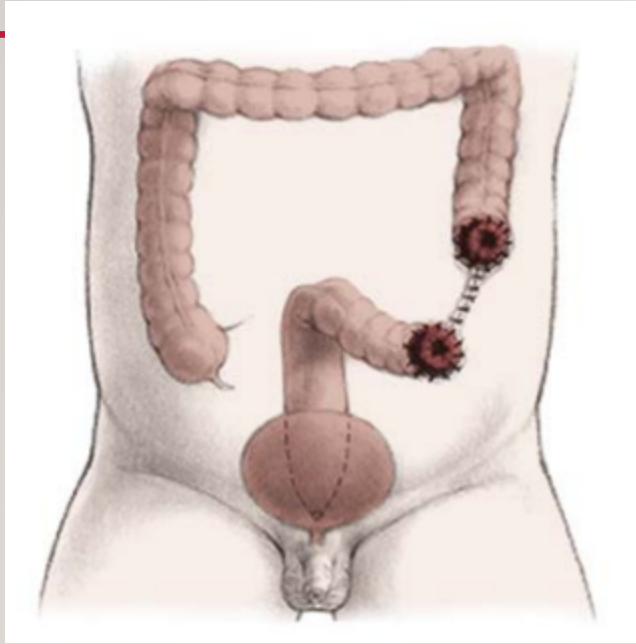
Sacral deformities are the most frequently associated defect.

Spinal abnormalities genitourinary defects varies from 20–54%









# OUTCOME

---

- Fecal and urinary Incontinence  
(high in high anorectal malformation , associated sacral and spinal abnormality )
- Constipation :in low type malformation
- Recurrent fistula

# HIRSCHSPRUNG DISEASE

---



- 
- Absence of ganglion cells in the myenteric and submucosal plexuses of the intestine
  - 1 in 5000 live births
  - ↪ 80% of children have a “transition zone” in the rectum or rectosigmoid colon
    - ↪ 10% have more proximal colonic involvement
- 5–10% have total colonic aganglionosis with variable involvement of the distal small intestine.

Near total intestinal aganglionosis is rarely encountered

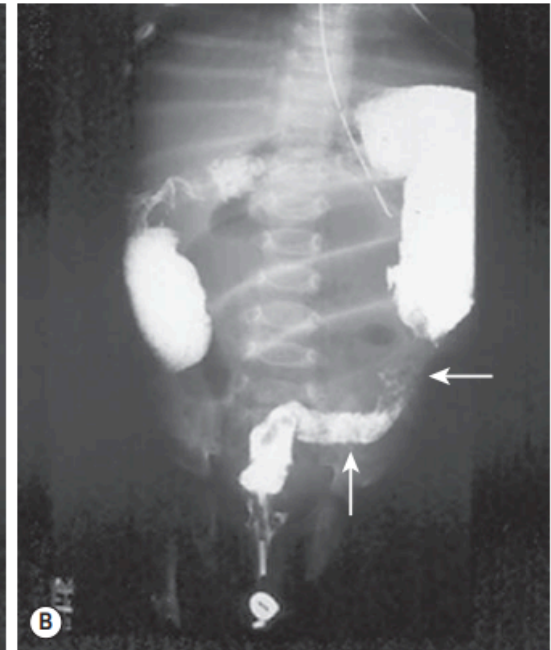
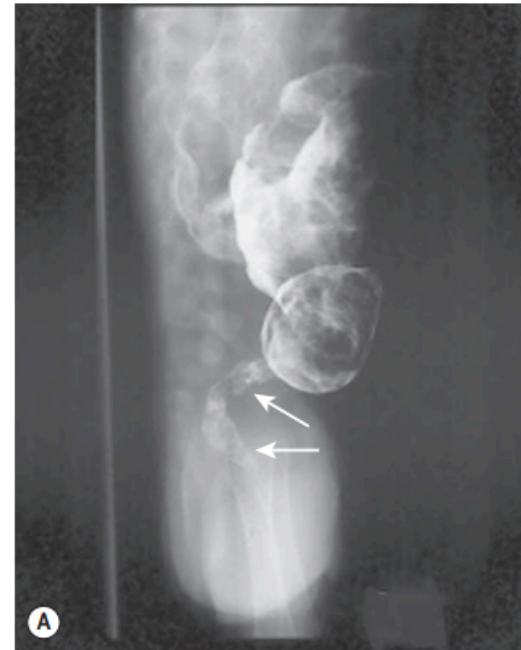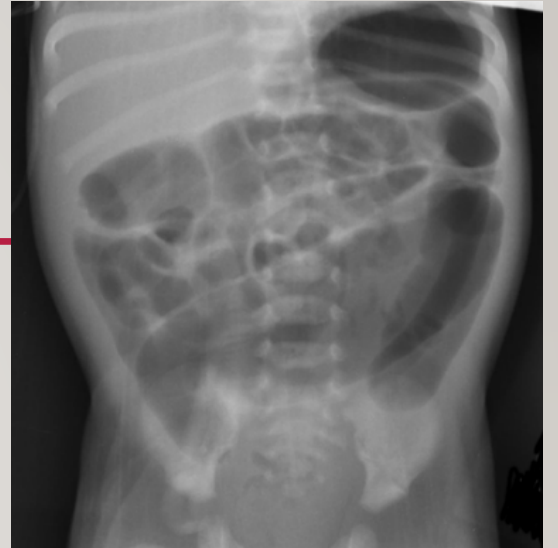- 
- Associated syndromes : trisomy 21, congenital central hypoventilation syndrome, Goldberg–Shprintzen syndrome, Smith–Lemli– Opitz syndrome, neurofibromatosis, and neuroblastoma , MEN2 , Neurocristopathy (e.g Waardenberg-Shah syndrome).
  - Associated with heart disease , malrotation , UT anomalies , CNS anomalies.
  - Genetic :most common is the RET proto-oncogene (esp familial and long-segment involvement) .other like SOX10, EDNRB, GDNF , EDN3, ECE1, NTN, SIP1

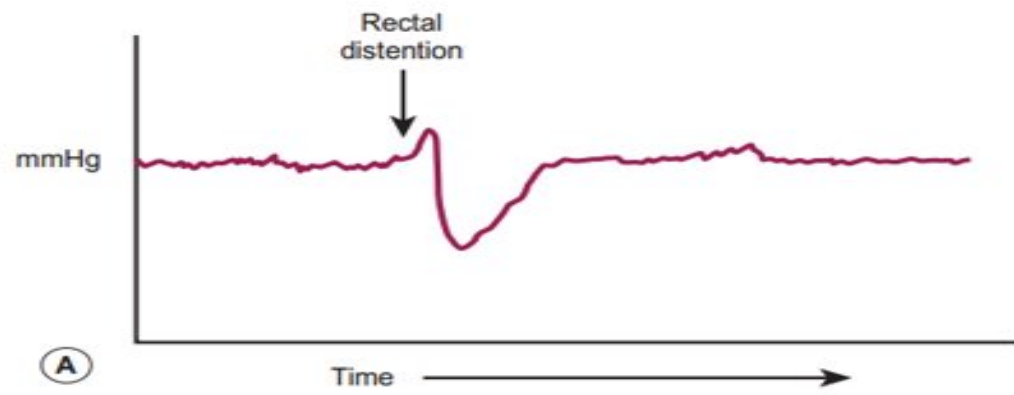
# DIAGNOSIS

---

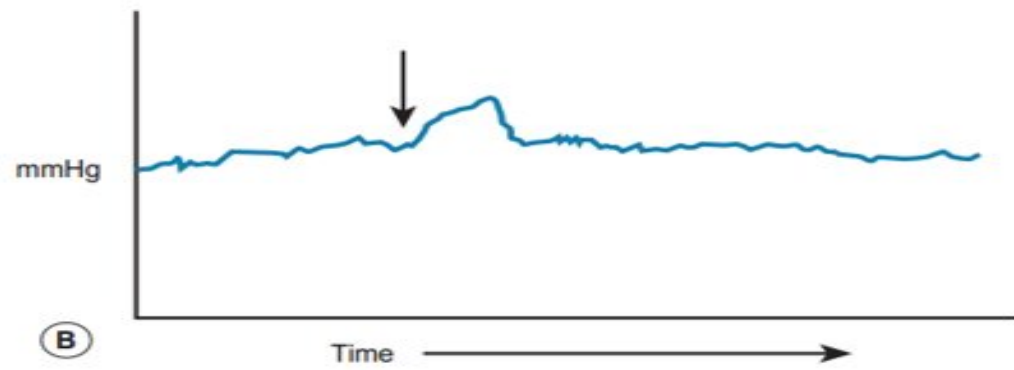
- Prenatal diagnosis of HD is rare
- Abdominal distension, bilious vomiting, and feeding intolerance. Delayed passage of meconium beyond the first 24 hours is present in approximately 90%.
- ↳ 10% of neonates with HD present with Hirschsprung-associated enterocolitis (HAEC)
- Patients presenting later in childhood have severe chronic constipation

- 
- Abd Xray
  - Lower contrast study/ enema.
  - Anorectal manometry
  - **Rectal biopsy ( suction or strip ) is the gold standard**





(A)



(B)

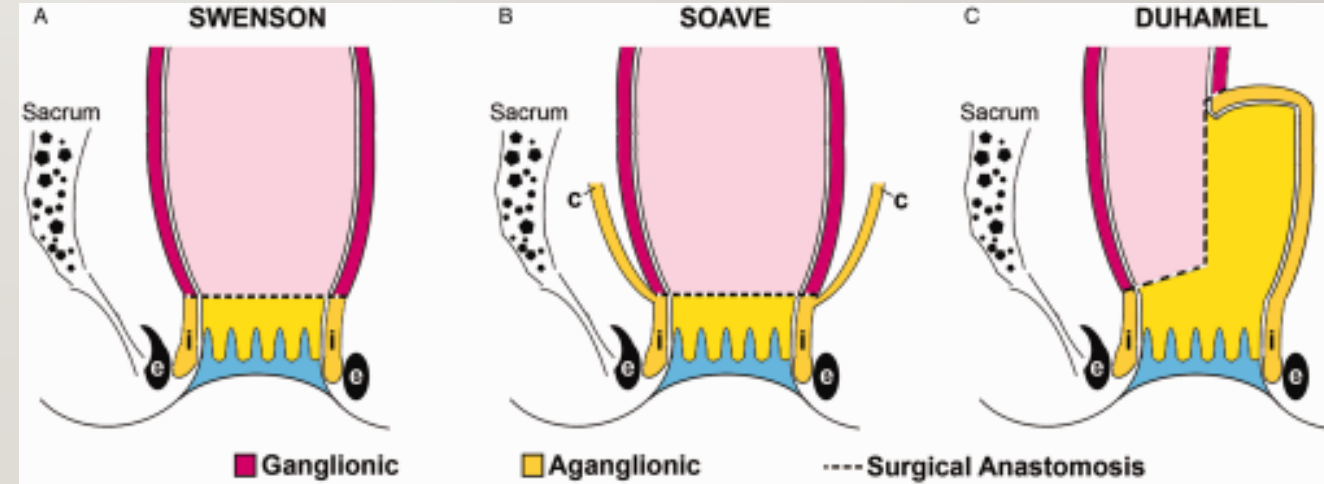
# MANAGEMENT

- Rectal washouts
- Colostomy (if unstable baby ,failure of washout , enterocolitis )
- Antibiotics ( enterocolitis)
- **Definitive management :**

## Pull-through procedure

- Swenson's pull-through
- Duhamel's retrorectal pull-through
- Soave's endorectal pull-through
- Trans-anal pull-through

Lap or  
open



# LONG TERM OUTCOME

---

- Obstructive symptoms (mechanical obstruction, recurrent or acquired aganglionosis, disordered motility in the residual colon or small bowel, internal sphincter achalasia, or functional megacolon caused by stool-holding behaviour )
- Fecal soiling ( abnormal sphincter function, abnormal sensation, or pseudo-incontinence)
- Enterocolitis (Clostridium difficile or rotavirus and other . more common in younger children, longer segment disease, and trisomy 21 )
- Hirschsprung associated inflammatory bowel disease (unknown etiology , Risk factors for this condition include long-segment disease and trisomy 21)

# MECONIUM ILEUS

---

- One of the most common causes of intestinal obstruction in the newborn ( accounting for 9–33% of IO )
- Extremely viscid, protein-rich, inspissated meconium causing an intraluminal obstruction in the distal ileum( usually at the ileocecal valve)
- It is often the earliest clinical manifestation of cystic fibrosis (CF), occurring in approximately 16% of patients with CF
- CF , AR disease due to mutations in the CF transmembrane regulator (CFTR) gene , located at chromosome 7q31
- most common mutation is F508del



# DIAGNOSIS

---

- Antenatally :

Fetal US : hyperechoic, intra-abdominal mass ( inspissated meconium ) , dilated bowel, and nonvisualization of the gallbladder

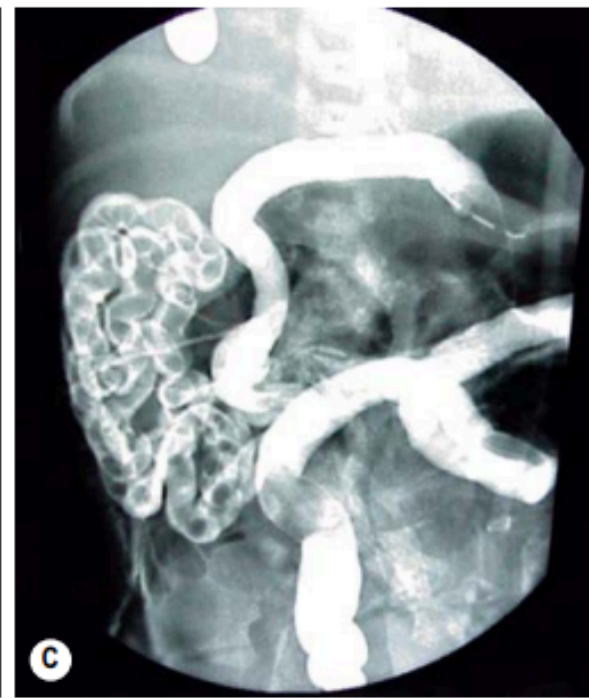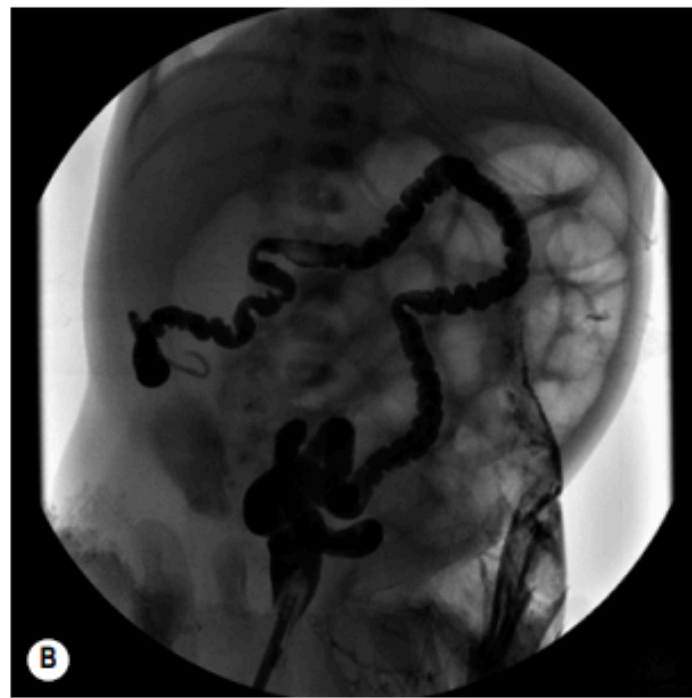
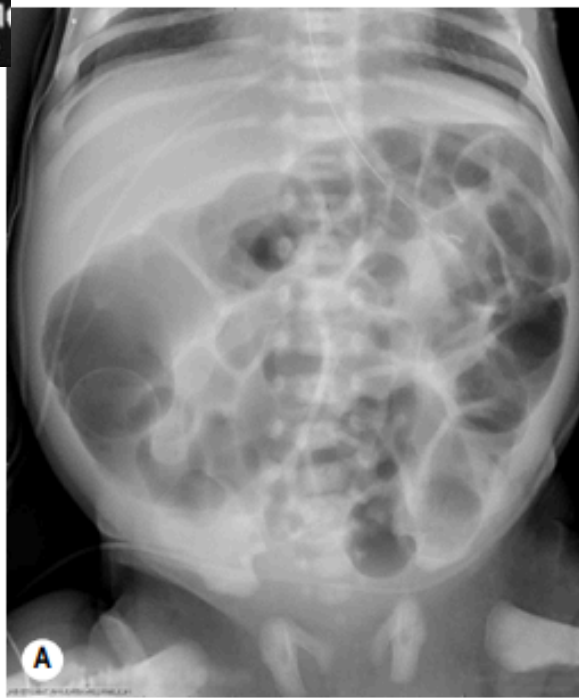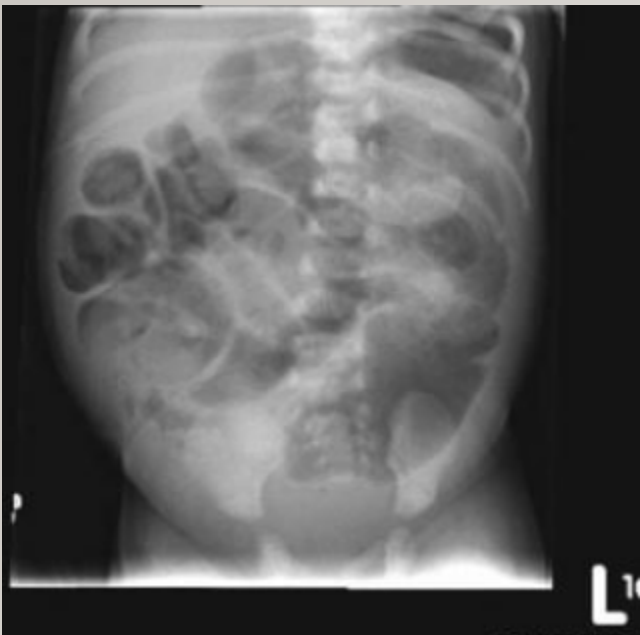Presence of family history

# CLINICAL PRESENTATION :

---

- Usually healthy immediately after birth. However, within 1–2 days, they develop abdominal distension and bilious emesis.
- Normal meconium will not be passed.
- Eventually, dilated loops of bowel become visible on exam and have a “doughy” character that indent on palpation.
- The rectum and anus are often narrow, a finding that may be misinterpreted as anal stenosis..

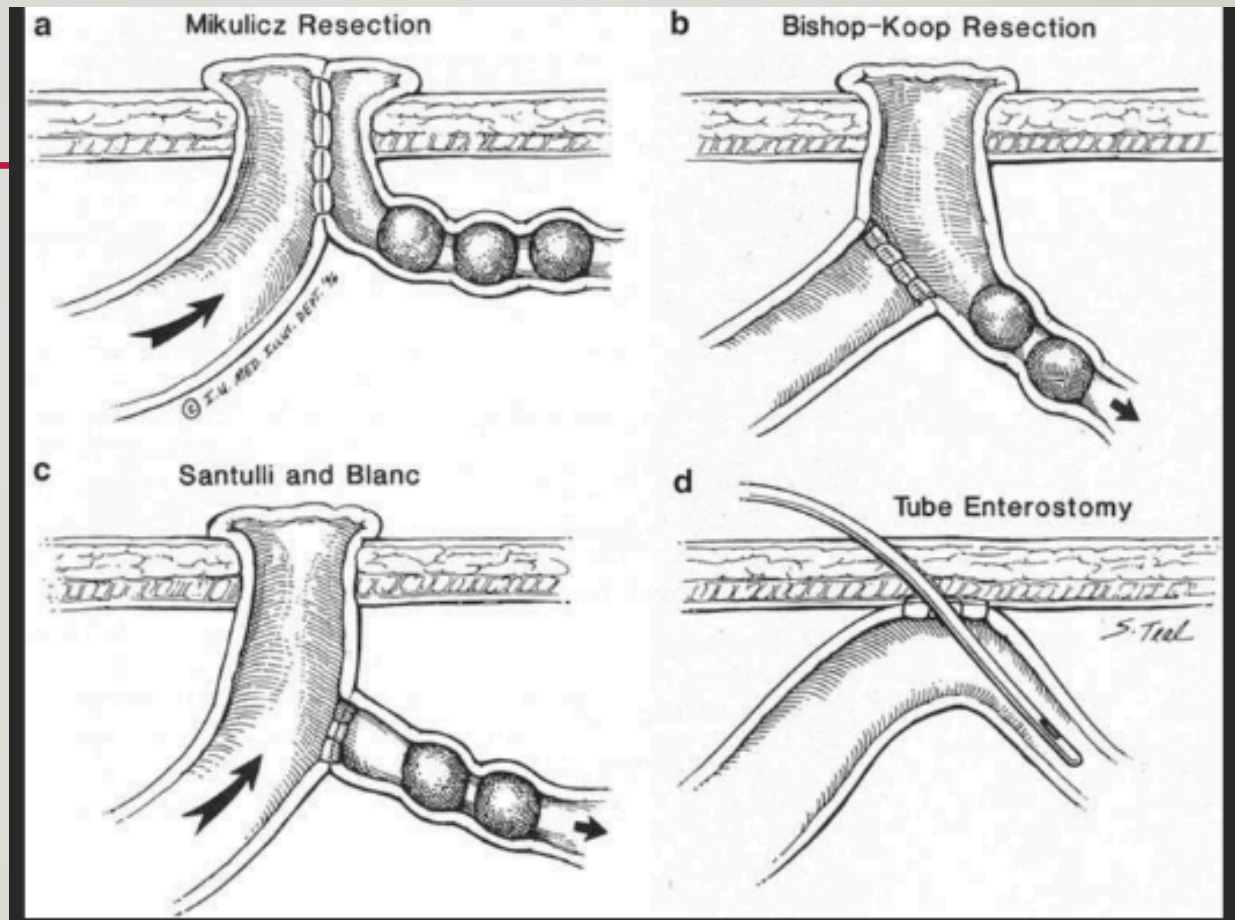
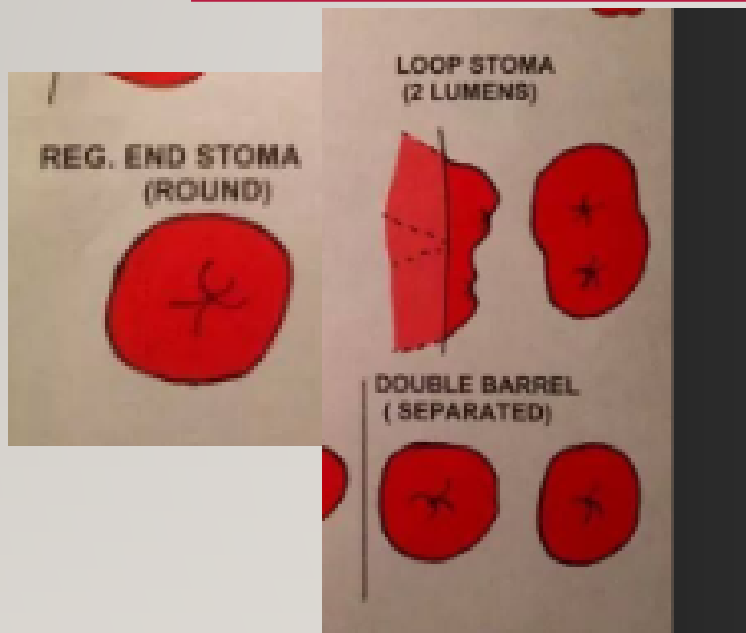
- 
- Infants with complicated MI present with symptoms within 24 hours of birth or even immediately after birth as a result of in utero perforation or bowel compromise.
  - Signs of peritonitis, including distension, tenderness, abdominal wall edema and erythema +/- of sepsis,
  - A palpable mass suggests pseudocyst formation, which results from in utero bowel perforation



# MANAGEMENT

---

- Conservative : simple MI
  - Water-soluble contrast enema , success rate  $\approx 2/3$  cases
- Surgery:
  - **Simple MI: failed conservative**  
Enterotomy and irrigation (N-acetylcysteine or normal saline) followed by enterotomy closure OR enterostomy tube Or ileostomy formation
  - **Complicated MI:** Resection of ischemic bowel + diverting stoma or primary anastomosis



---

## Postoperative care:

- Nutrition
- N-acetylcysteine (10%) enterally (5–10 mL)
- Enteral pancreatic enzymes (e.g., Creon®, Pancrease®)
- Antibiotics
- Involvement of CF team ( Resp/GI/Genecisit/social worker )

# COMPLICATION OF MI AND CF

---

- Respiratory problems
- Gastroesophageal reflux
- Biliary tract disease
- Distal Intestinal Obstruction Syndrome ( DIOS )
- Appendicitis
- Fibrosing colonopathy
- Intussusception : 1% of children with CF with the average age of onset of 9.5 years