

# PRIMARY LIVER NEOPLASMS

SALAM DARADKEH

Department of General Surgery

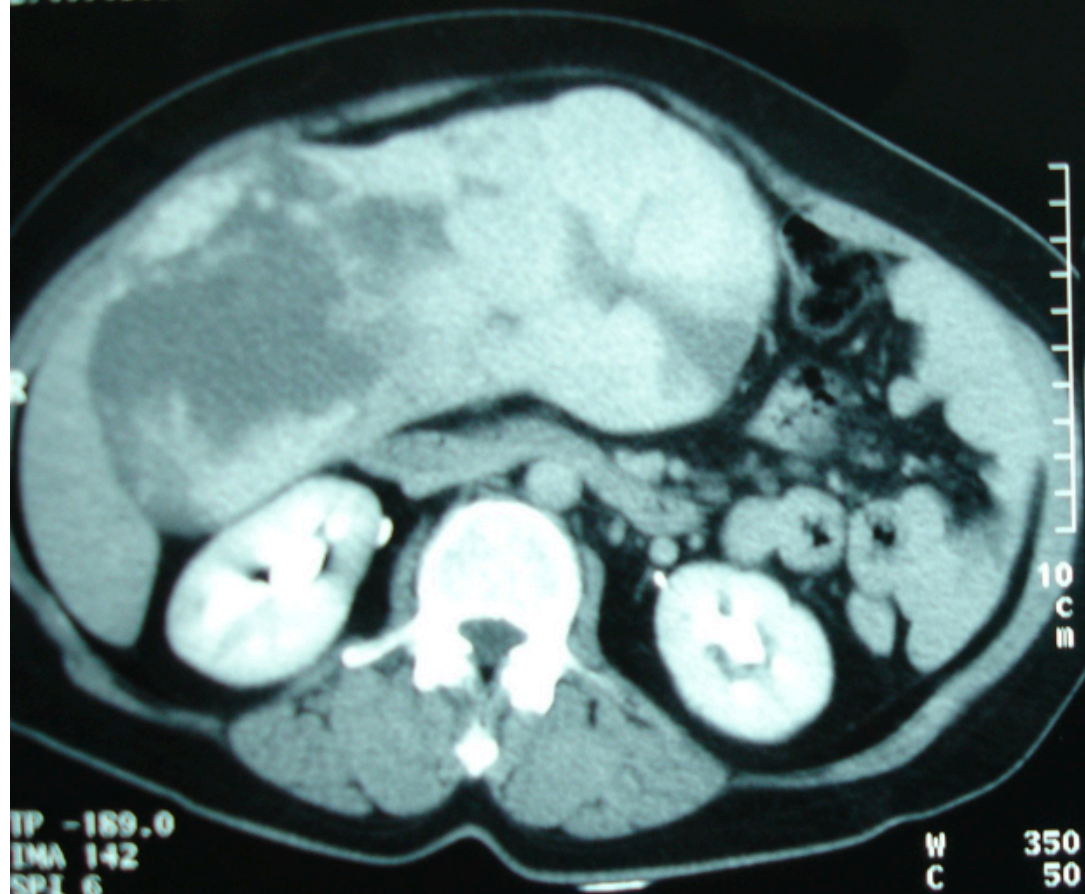# Classifications

- **BENIGN:**
  - Hemangioma
  - Adenoma
  - Focal nodular hyperplasia(FNH)
- **MALIGNANT:**
  - Hepatocellular carcinoma.
  - Cholangiocarcinoma.
  - Hepatoblastoma.
  - Sarcoma.
  - Others.

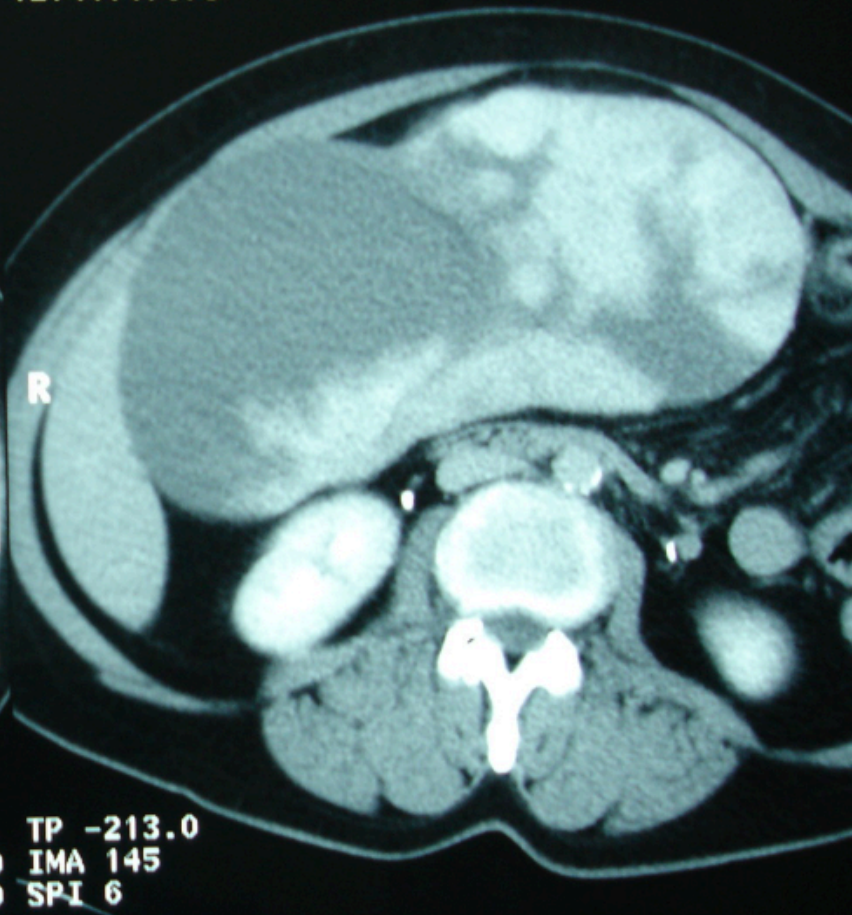
# Hemangioma

- Most common benign tumors.0.5-5%
- Variable sizes, single or multiple,more than 6cm Giant
- Mostly asymptomatic, pain,heaviness,early satiety,complications.
- Diagnosis: US,CT,MRI,Angiography,Isotopic scan. Needle Bx contraindicated.
- Management: observation,resection,embolization.

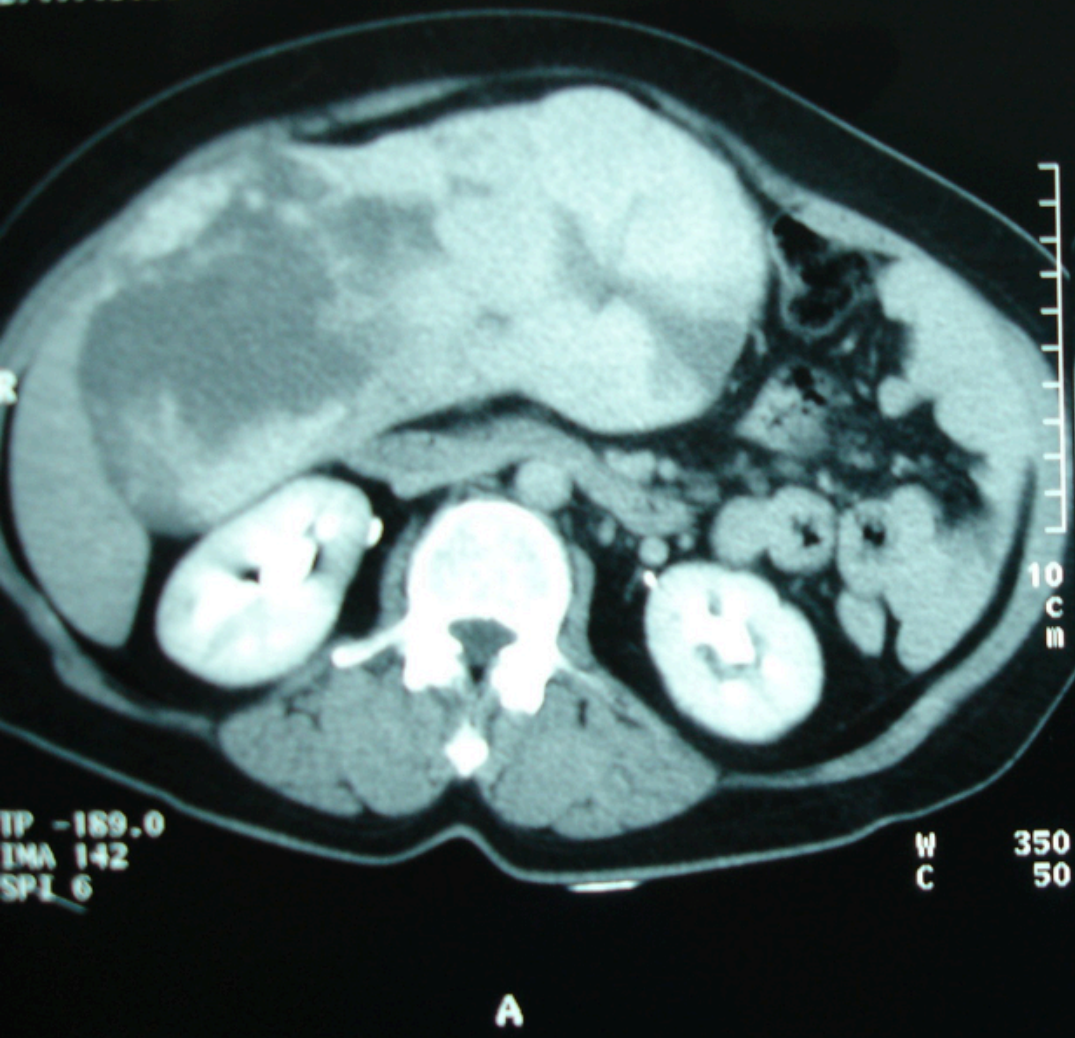
4-JUL-2008  
12:41:15.53



24-JUL-2008  
12:41:17.79

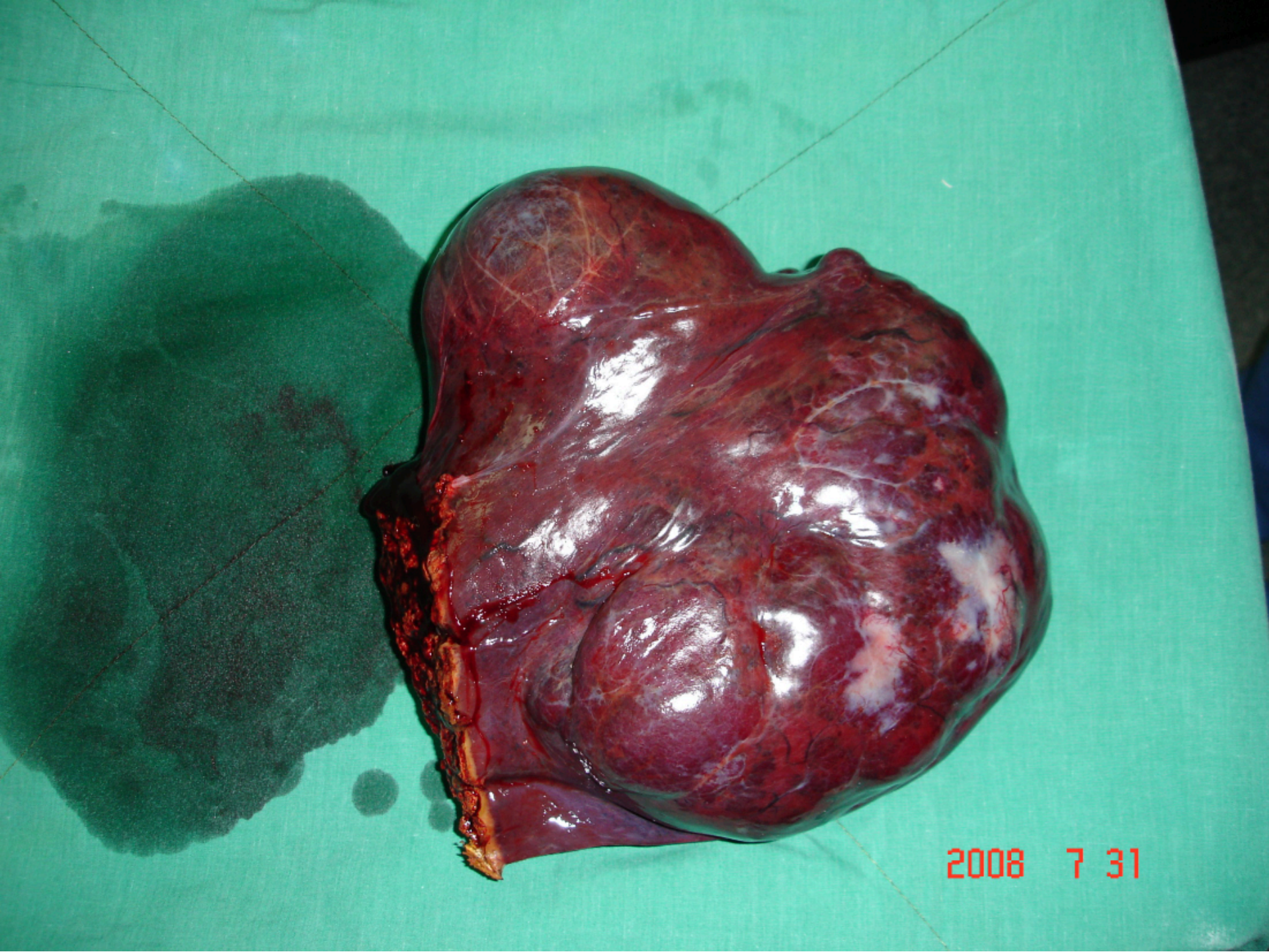


24-JUL-2008  
12:51:53.82



24-JUL-2008  
12:51:56.06

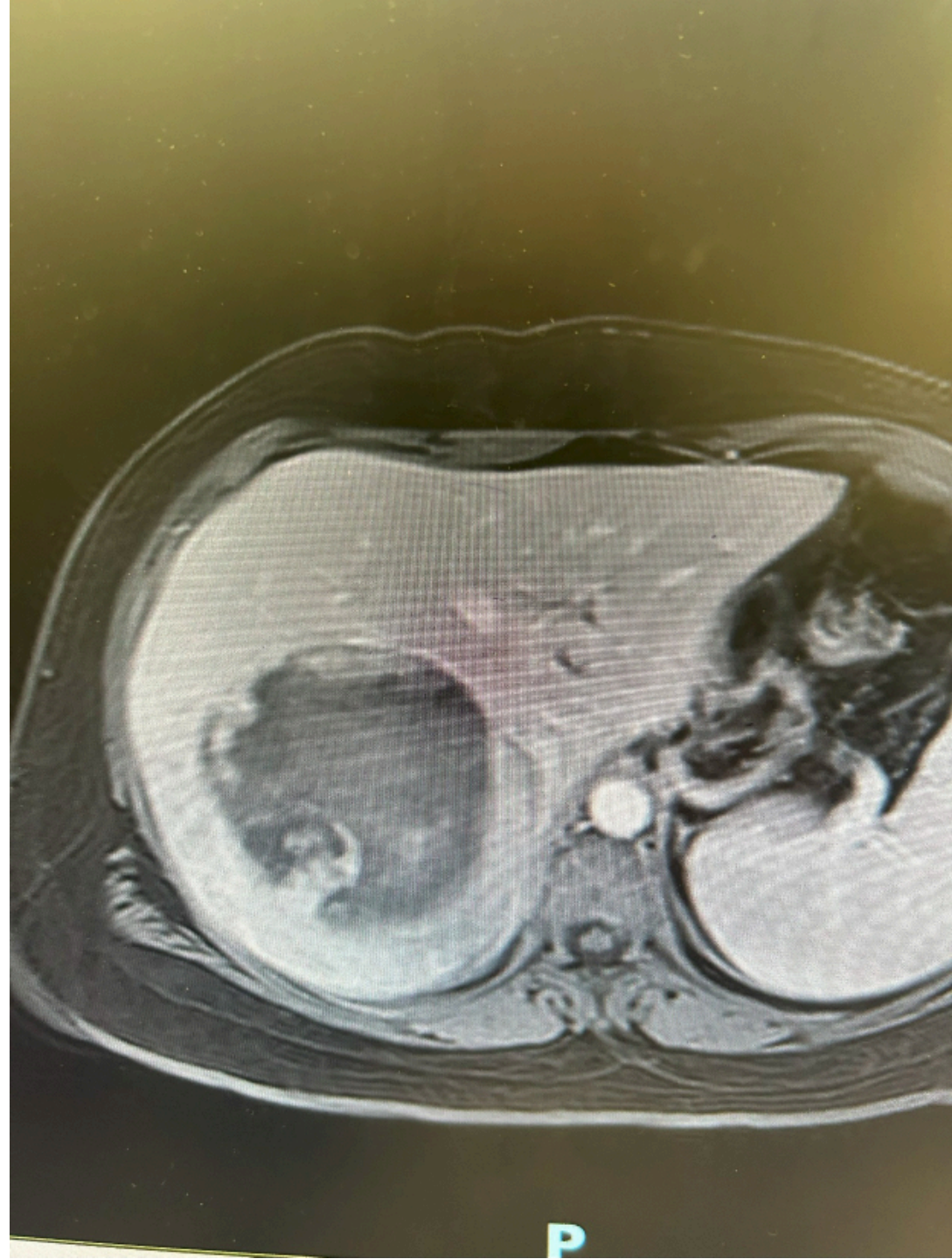2008 7 31



2008 7 31

## HCA

- RARE, young females 20-40 years, linked to hormonal therapy(ocp,hrt).
- Can happen in males.
- Hypervascular lesion , if big can be complicated: hemorrhage,rupture, degeneration to ca.
- Diagnosis: US,CT,MRI, NEEDLE BX and histopathology.
- Management: stop hormonal therapy, resection.



P

## FNH

- No tendency to malignancy
- Central scar(fibrosis)
- Affect both sexes, result from congenital arteriovenous malformation.
- Diagnosis: US,CT,MRI, RARELY needle BX.
- Management: observation, surgery if diagnosis is unclear.

# HEPATOCELLULAR CARCINOMA(HCC)

- MOST COMMON PRIMARY MALIGNANCY. UP TO 20/100000
- MORE COMMON IN MALE/FEMALE
- GEOGRAPHIC VARIATION(HIGH IN SOUTH EAST ASIA AND TROPICAL AFRICA).
- INCREASING IN THE WEST(STEATOHEPATITIS).
- 5<sup>TH</sup> MOST COMMON CANCER WORLDWIDE
- 3d MOST COMMON CAUSE OF CANCER DEATH
- HEP.B TREATMENT &VACCINATION REDUCED THE INCIDENCE

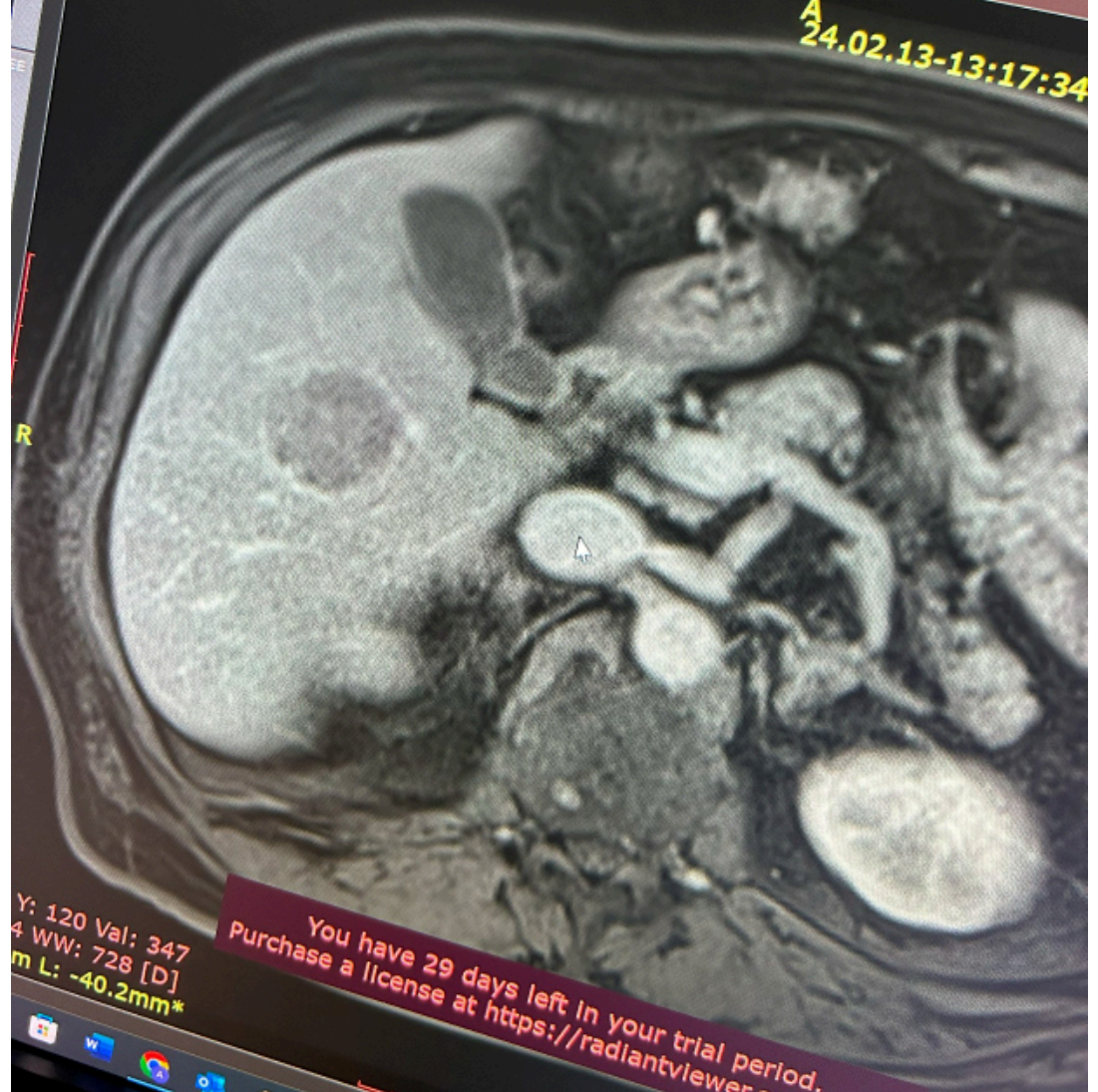
You have 29 days left in your trial  
Purchase a license at <https://radiantviewer.com/>

WL: 512 WW: 1034 [D]  
T: 5.0mm L: -42.4mm\*

Shamal Abdulwafa Ahmed (66y) - 2/13/2024 1:56:30 PM - t1\_vibe\_fs\_tra\_bh

Im: 25/60  
Se: 18

A  
24.02.13-13:17:34



Y: 120 Val: 347  
4 WW: 728 [D]  
m L: -40.2mm\*

You have 29 days left in your trial period.  
Purchase a license at <https://radiantviewer.com/>



## RISK FACTORS

- HEPATITIS B & C
- CIRRHOSIS REGARDLESS OF THE ETIOLOGY.
- ALCOHOLISM
- HEMOCHROMATOSIS
- WILSON'S DISEASE
- AFLATOXIN
- OTHERS: DM, ADENOMA

## PATHOLOGY

- GRADES: WELL DIFFERENTIATED, MODERATE, POOR
- NO RELATION BETWEEN DEGREE OF DIFF. AND PROGNOSIS.
- GROSS PATHOLOGY:
  - HANGING
  - PUSHING TYPE: WELL DEMARCATED AND CONTAINS FIBROUS CAPSULE
  - INFILTRATIVE
  - SMALL TYPE
  - MULTINODULAR

## PATHOLOGY-SPREAD

- TO LYMPH NODES
- PERITONEUM
- LUNGS
- BONE
- ADRENALS

MES;AD MOHAMMAD SLEIMAN

OP KH  
01-JAN-1945  
04-AUG-2008  
11:51:22.80  
TP -424.0  
IMA 113  
SPI 5

A

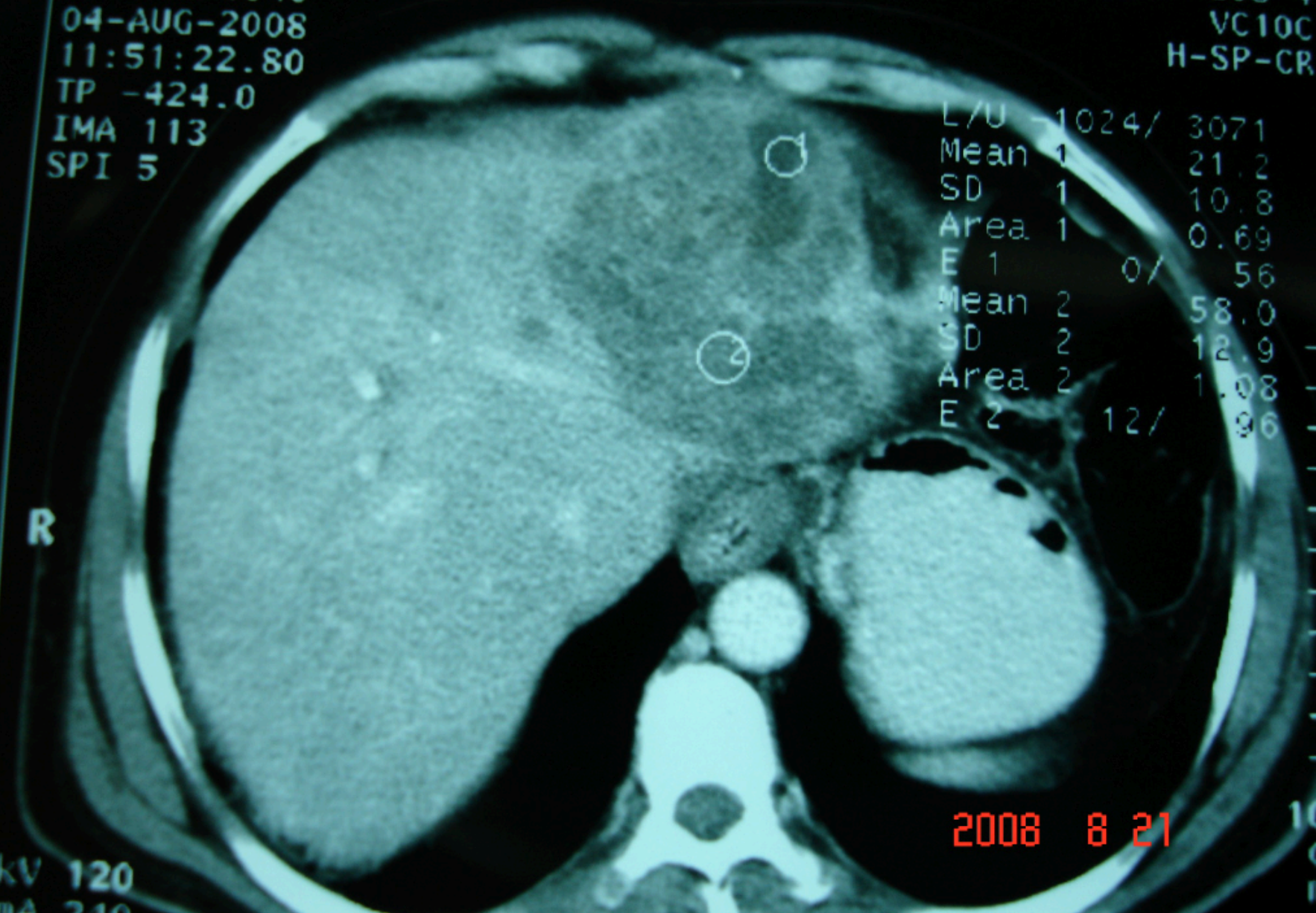
ISLAMIC HOSPITAL  
SOMATOM PLUS 4  
VC10C  
H-SP-CR

L/U	-1024/	3071
Mean 1		21.2
SD 1		10.8
Area 1		0.69
E 1	0/	56
Mean 2		58.0
SD 2		12.9
Area 2		1.08
E 2	12/	96

R

2008 8 21

kV 120  
mA 240



## DISTINCT VARIANTS

- FIBROLAMELLAR: ENCAPSULATED,? BETTER PROGNOSIS
- MIXED HEPATOCELLULAR –CHOLANGIOCELLULAR
- CLEAR CELL
- PLEOMORPHIC OR GIANT CELL VARIANT
- CHILDHOOD VARIANT

BRAHIM MOHAMMAD 21 Y/O  
A

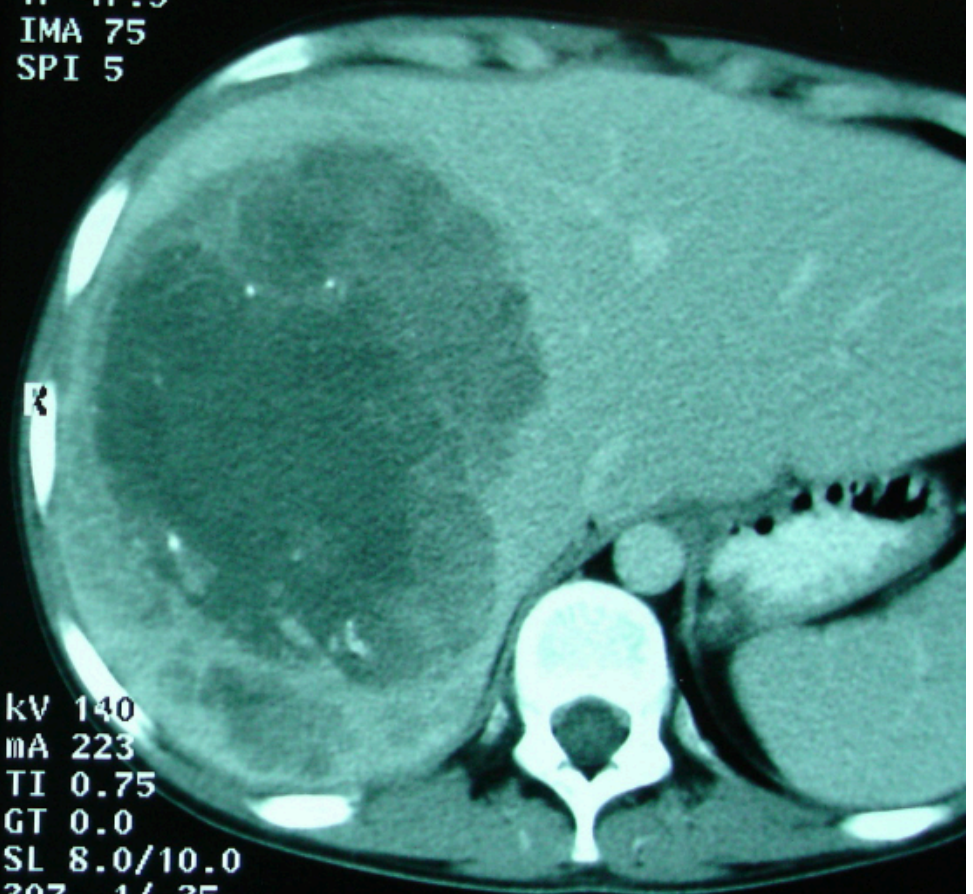
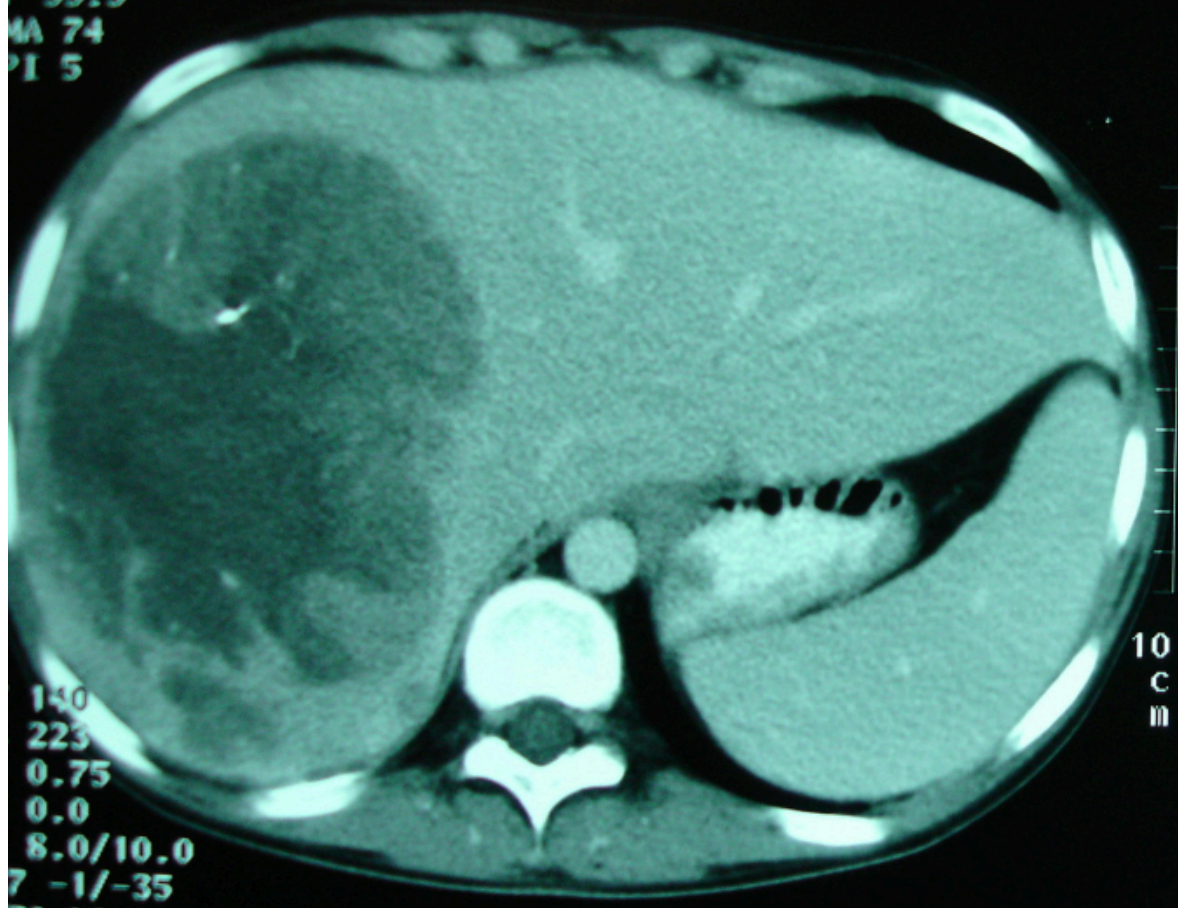
JORDAN UNIVERSITY HOSP  
SOMATOM PLUS 4  
VC10C  
H-SP-CR

IBRAHIM MOHAMMAD 21 Y/O  
A

JORDAN UNIV  
SOM

7-APR-2003  
13:58:59.18  
P 55.5  
MA 74  
PI 5

07-APR-2003  
13:58:59.78  
TP 47.5  
IMA 75  
SPI 5



140  
223  
0.75  
0.0  
8.0/10.0  
7 -1/-35  
50 10  
11330

10  
C  
m  
KV 140  
mA 223  
TI 0.75  
GT 0.0  
SL 8.0/10.0  
307 -1/-35  
AB50 L0  
1011030

60 SEC PORTAL VENOUS PHASE

W 300  
C 50

60 SEC PORTAL VENOUS PHASE

BRAHIM MOHAMMAD 21 Y/O  
A

JORDAN UNIVERSITY HOSP  
SOMATOM PLUS 4  
VC10C  
H-SP-CR

IBRAHIM MOHAMMAD 21 Y/O  
A

JORDAN UNIVER  
SOMAT

2005A 9 16

7-APR-2003

BRAHIM MOHAMMAD 21 Y/O  
A

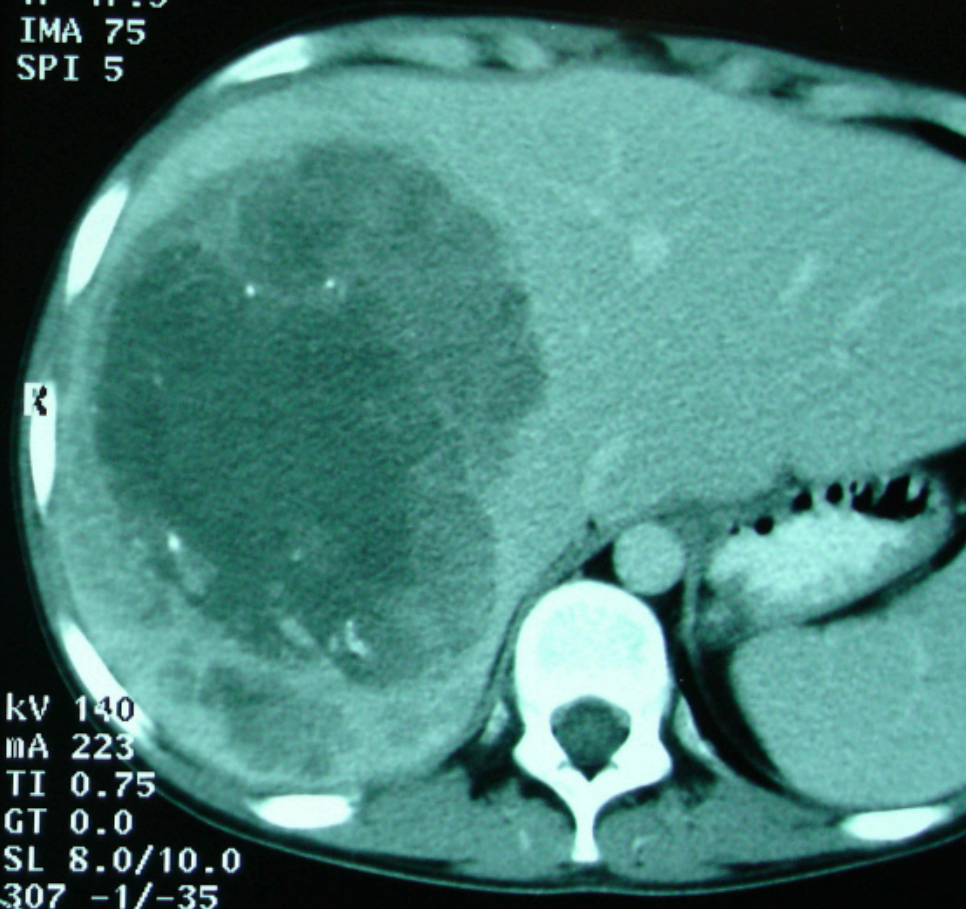
JORDAN UNIVERSITY HOSP  
SOMATOM PLUS 4  
VC10C  
H-SP-CR

IBRAHIM MOHAMMAD 21 Y/O  
A

JORDAN UNIV  
SOM

07-APR-2003  
13:58:59.18  
P 55.5  
MA 74  
PI 5

07-APR-2003  
13:58:59.78  
TP 47.5  
IMA 75  
SPI 5



140  
223  
0.75  
0.0  
8.0/10.0  
7 -1/-35  
50 10  
11330

kV 140  
mA 223  
TI 0.75  
GT 0.0  
SL 8.0/10.0  
307 -1/-35  
AB50 L0  
1011030

60 SEC PORTAL VENOUS PHASE

W 300  
C 50

60 SEC PORTAL VENOUS PHASE

BRAHIM MOHAMMAD 21 Y/O  
A

JORDAN UNIVERSITY HOSP  
SOMATOM PLUS 4  
VC10C  
H-SP-CR

IBRAHIM MOHAMMAD 21 Y/O

JORDAN UNIVER  
SOMAT

2005A 9 16

07-APR-2003

60 SEC PORTAL VENOUS PHASE

51  
VC10C  
H-SP-CR

60 SEC PORTAL VENOUS PHASE

IBRAHEM KRESHAT 22Y  
HS#613625

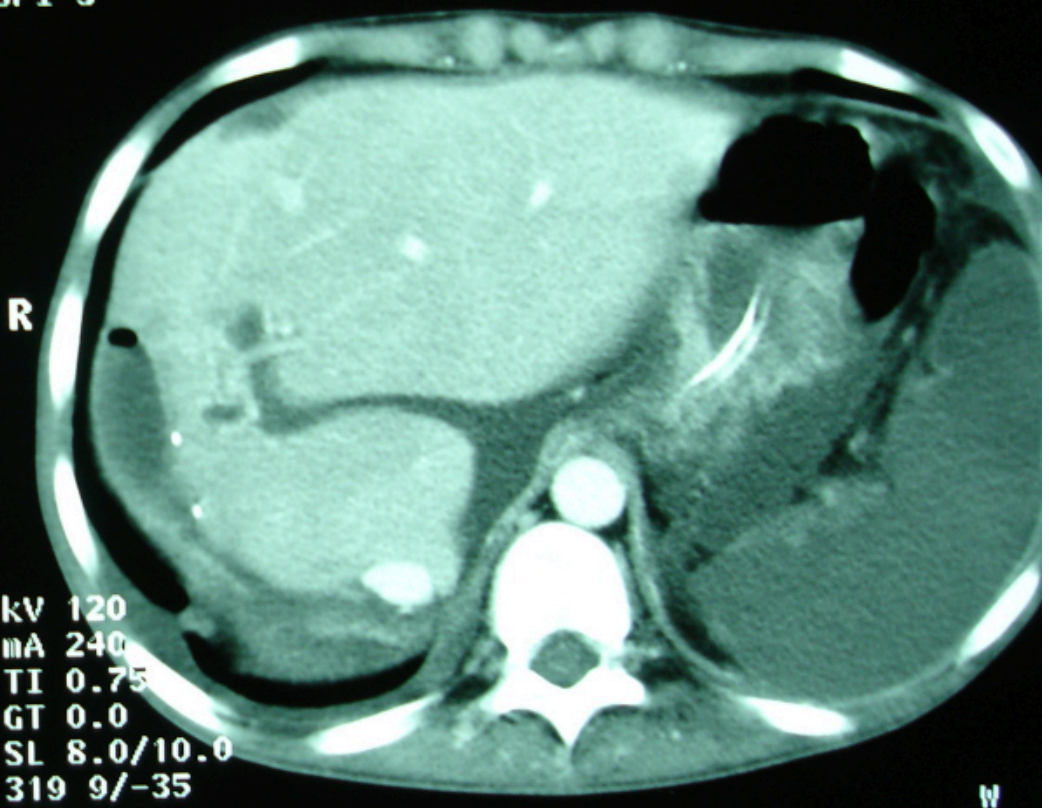
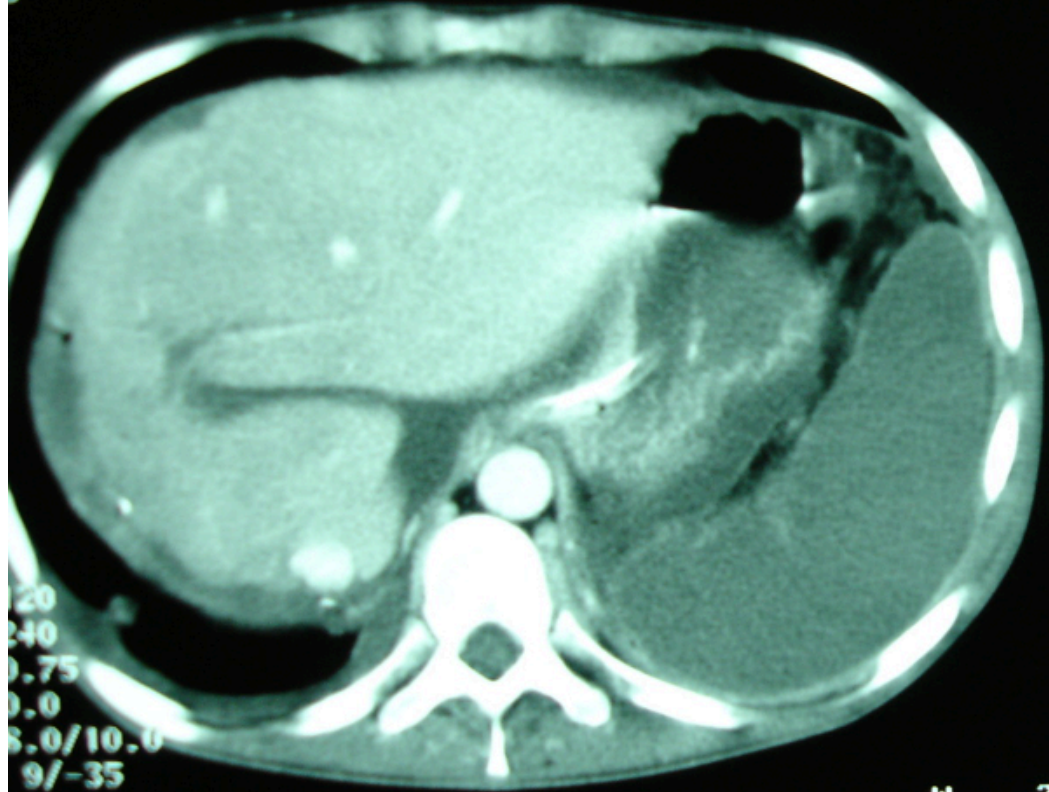
JORDAN UNIVERSITY HOSP  
SOMATOM PLUS 4  
VC10C  
H-SP-CR

IBRAHEM KRESHAT 22Y  
HS#613625

JORDAN UNIVERSITY  
SOMATOM PLUS 4  
VC10C  
H-SP-CR

MAY-2003  
11:36:58  
172.5

12-MAY-2003  
11:07:37.18  
TP -480.5  
IMA 12  
SPI 3



120  
240  
0.75  
0.0  
8.0/10.0  
9/-35  
0 LO  
TO>0

W 350  
C 51

kV 120  
mA 240  
TI 0.75  
GT 0.0  
SL 8.0/10.0  
319 9/-35  
AB50 LO  
12119>0

60 SEC PORTAL VENOUS PHASE

IBRAHEM KRESHAT 22Y  
HS#613625

JORDAN UNIVERSITY HOSP  
SOMATOM PLUS 4  
VC10C  
H-SP-CR

IBRAHEM KRESHAT 22Y  
HS#613625

JORDAN UNIVERSITY  
SOMATOM PLUS 4  
VC10C  
H-SP-CR

MAY-2003  
11:07:39.58

12-MAY-2003  
11:07:39.58

2005 9 16

IBRAHIM HOH'D HOSHTAFH  
Reg.No: CV 80-01-01

HS: 0 0  
VS: 0 0

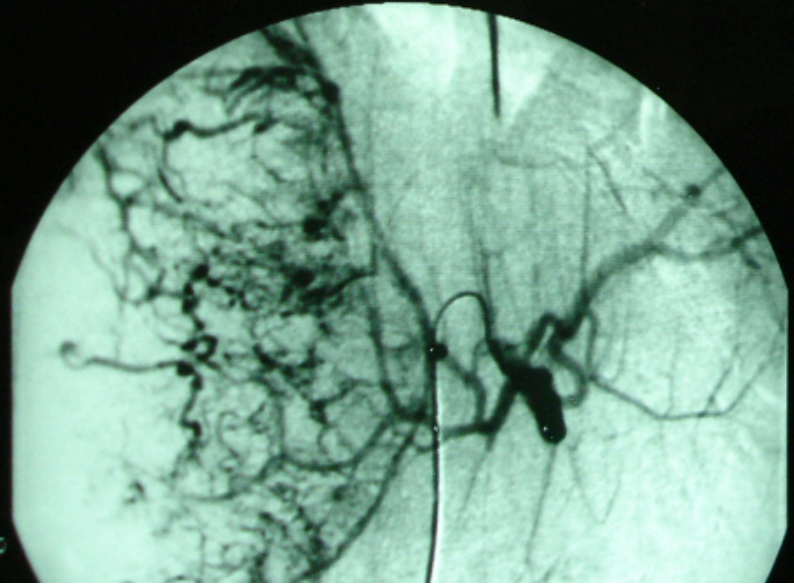


Image: 2 I-image: 4.00 s  
Mask: 2 T-mask: 1.48 s  
Acquisition: 60kV 188 mA

IBRAHIM HOH'D HOSHTAFH  
Reg.No: CV 80-01-01

HS: 0 0  
VS: 0 0

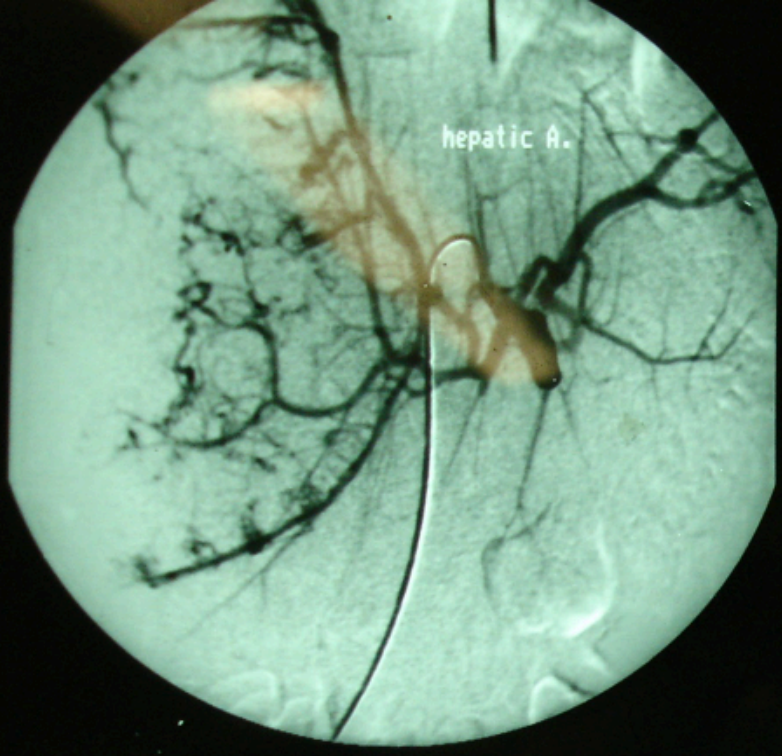
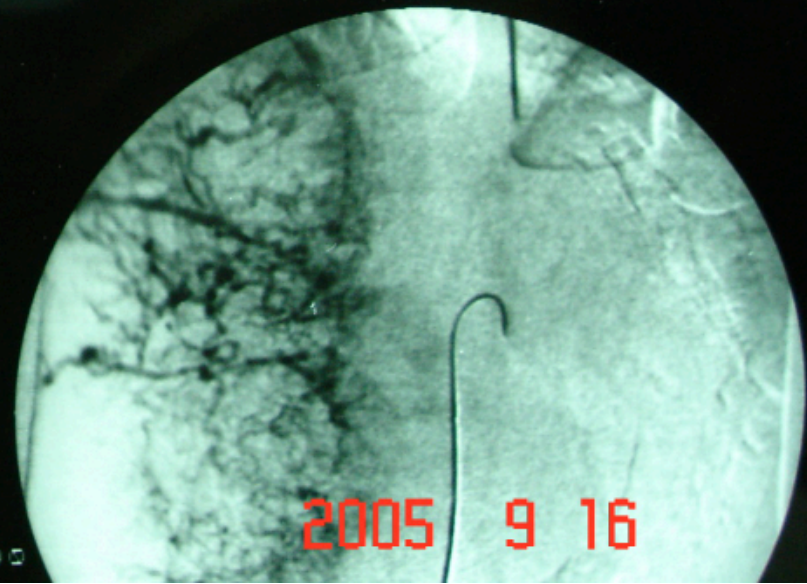


Image: 5 I-image: 3.00 s  
Mask: 2 T-mask: 1.48 s  
Acquisition: 60kV 188 mA

19-01 Run: 4 Zoom: 1.00  
IBRAHIM HOH'D HOSHTAFH  
Reg.No: CV 80-01-01

HS: 0 0  
VS: 0 0



Date: 02-09-01 Run: 4 Zoom: 1.00  
IBRAHIM HOH'D HOSHTAFH  
Reg.No: CV 80-01-01

HS: 0 0  
VS: 0 0

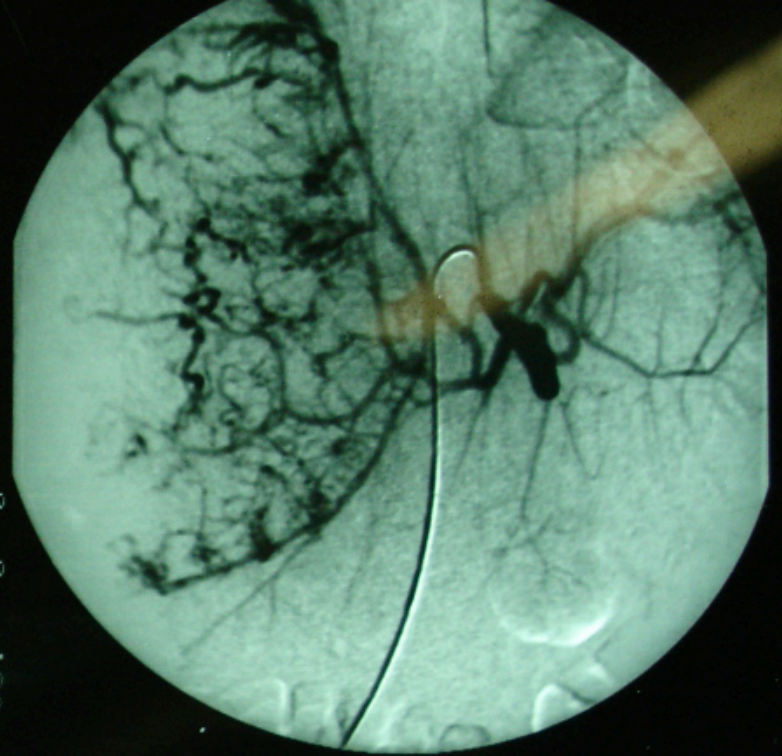


Image: 10 I-image: 5.52 s

## CLINICAL PRESENTATION

- RIGHT UPPER QUADRANT PAIN, WEIGHT LOSS, PALPABLE MASS
- ANOREXIA, NAUSEA, LETHARGY
- RARELY HEPATIC DECOMPENSATION IN A KNOWN CIRRHOTIC OR UNRECOGNIZED CIRRHOSIS.
- MORE RARELY HEMOPERITONEUM DUE TO RUPTURE LEADING TO HYPOVOLEMIC SHOCK.
- RARELY, BUDD-CHIARI, OBSTRUCTIVE JAUNDICE, HEMOBILIA, PARANEOPlastic SYNDROME: HYPOGLYCEMIA, HYPERCALCEMIA, ERYTHROCYTOSIS.
- SOMETIMES INCIDENTAL : FOLLOW UP OF PATIENTS WITH RISK FACTORS

## DIAGNOSIS-IMAGING

- TRIPHASIC CT SCAN: EARLY ARTERIAL FILLING AND DELAYED VENOUS WASHOUT.
- MRI.
- ULTRASONOGRAPHY.
- PET/CT.

## DIAGNOSIS-LABS

- TUMOR MARKER: AFP SPECIFIC IF MORE THAN 400 ng/dl.
- NOT ALWAYS RAISED IN CLASSICAL HCC, IN 30% NEGATIVE
- NORMAL IN FIBROLAMELLAR VARIANT

## HOW TO MAKE DIAGNOSIS

- IF CIRRHOSIS IS PRESENT, OR HBV OR HCV ARE PRESENT, WITH ELEVATED AFP THE DIAGNOSIS IS MADE WITHOUT BIOPSY.
- IF NO CIRRHOSIS, AFP IS NOT HIGH, HBV, HCV ARE NEGATIVE, PROCEED TO BIOPSY
- PORTAL VEIN THROMBOSIS WITH THE PRESENCE OF LIVER LESION: HCC

## MANAGEMENT-CURATIVE

- RESECTION: FEASIBLE WHEN THERE IS NO CIRRHOSIS OR CHILD-PUGH A CIRRHOSIS OR FIBROLAMELLAR VARIANT.
- TRANSPLANTATION: CRITERIA, SINGLE LESION LESS THAN 5 CM, OR 3 LESIONS EACH LESS THAN 3 CM.
- PREFERABLY CADAVERIC DONOR.

## MANAGEMENT -PALLIATIVE

- RF:
- CHEMOEMBOLIZATION: conventional,beads,Y-90(TACE)
- ETHANOL INJECTION:
- SORAFENIB:
- SYSTEMIC CHEMOTHERAPY:
- EXTERNAL BEAM RADIATION: TARGETED
- TARE
- HISTOTRIPSY(HIFU)

# PROGNOSIS

- WITH CIRRHOSIS: POOR SURVIVAL IS 3-6 MONTHS FROM DIAGNOSIS/NO TREATMENT.
- IF TREATED SURVIVAL IS BETTER, GOES TO YEARS
- WITH TRANSPLANTATION: 80% EXCEED 5 YEARS, IF INDICATIONS RESPECTED.
- IF NO CIRRHOSIS, AND RESECTION: CURED.

## CHOLANGIOCARCINOMA

- 2<sup>nd</sup> MOST COMMON PRIMARY LIVER CANCER.
- ARISES FROM BILIARY EPITHELIUM
- NOT THE COMMONEST SITE FOR CHOLANGIOCARCINOMA
- DIAGNOSED USUALLY LATE UNTIL THERE IS BILIARY OBSTRUCTION AND JAUNDICE, THAT'S WHY PROGNOSIS IS POOR.
- IF DIAGNOSED(NEEDELE BX) RESECTION IS THE IDEAL TREATMENT.
- RISK FACTORS: PSC,ORIENTAL CHOLANGIOHEPATITIS

# HEPATOBLASTOMA

- LIVER CANCER OF INFANTS AND CHILDREN.
- DIAGNOSIS: PALPABLE ABDOMINAL MASS, BX, INCREASED AFP MORE THAN 500ng/dl.
- ARISES FROM IMMATURE LIVER CELLS
- TWO TYPES: EPITHELIAL TYPE, MIXED EPITHELIAL AND MESENCHYMAL TYPE.
- CO-EXISTE WITH OTHER SYNDROMES: TRI 18,21, FAP
- CAN GIVES METASTASES.

## HEPATOBLASTOMA-TREATMENT

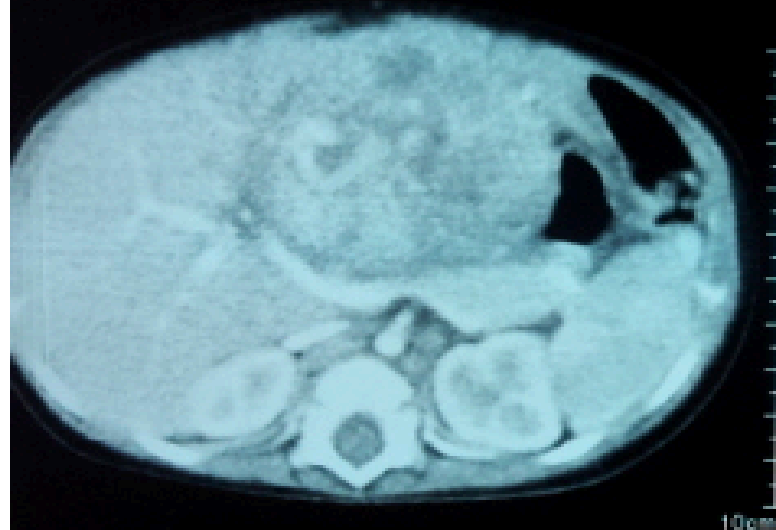
- NEOADJUVANT CHEMOTHERAPY
- SURGICAL RESECTION.
- LIVER TRANSPLANTATION.
- PROGNOSIS: IF METASTASIS-----POOR

IF RESPONSE TO NEOADJUVANT CHEMO.FOLLOWED BY RESECTION OR TRANSPLANTATION SURVIVAL IS CLOSE TO 100%.

130  
mAs 24  
ref mAs 130  
TI 0.6  
GT 0.0  
SL 5.0/16x1.2/p0.8  
193.7/0  
B41s L3C0 A2

Post Contrast

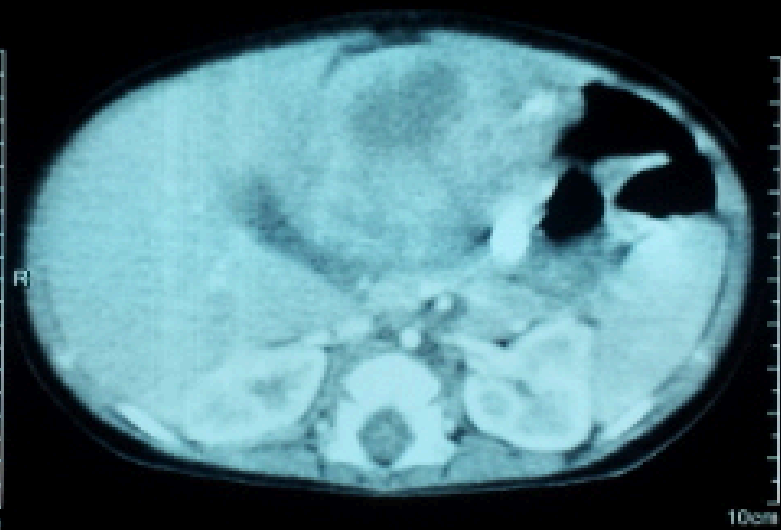
Rad, Reimas Nasser Abdu  
A  
11.0000212958  
106-Nov-2011, F, 9M  
# 967SGH000147865  
02-Sep-2012  
10:18:16.18  
3 IMA 31  
SPI 3  
SP -291.4



kV 130  
eff mAs 24  
ref mAs 130  
TI 0.6  
GT 0.0  
SL 5.0/16x1.2/p0.8  
193.7/0  
B41s L3C0 A2

Post Contrast

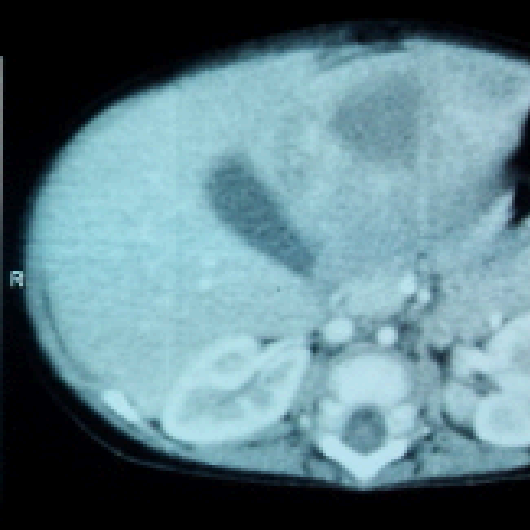RAD Hadi, Reimas Nasser Abdu  
A  
Emotion 16 SY01.0000212958  
CT 2006G 106-Nov-2011, F, 9M  
# 967SGH000147865  
02-Sep-2012  
10:18:16.18  
3 IMA 30  
SPI 3  
SP -291.4



kV 130  
eff mAs 24  
ref mAs 130  
TI 0.6  
GT 0.0  
SL 5.0/16x1.2/p0.8  
193.7/0  
B41s L3C0 A2

Post Contrast

RAD Hadi, Reimas Nasser Abdu  
A  
Emotion 16 SY01.0000212958  
CT 2006G 106-Nov-2011, F, 9M  
# 967SGH000147865  
02-Sep-2012  
10:18:16.38  
3 IMA 31  
SPI 3  
SP -296.4



130  
mAs 24  
ref mAs 130  
TI 0.6  
GT 0.0  
SL 5.0/16x1.2/p0.8  
193.7/0  
B41s L3C0 A2

Post Contrast

Rad, Reimas Nasser Abdu  
A  
11.0000212958  
106-Nov-2011, F, 9M  
# 967SGH000147865  
02-Sep-2012  
10:18:16.18  
3 IMA 31  
SPI 3  
SP -291.4

kV 130  
eff mAs 24  
ref mAs 130  
TI 0.6  
GT 0.0  
SL 5.0/16x1.2/p0.8  
193.7/0  
B41s L3C0 A2

Post Contrast

RAD Hadi, Reimas Nasser Abdu  
A  
Emotion 16 SY01.0000212958  
CT 2006G 106-Nov-2011, F, 9M  
# 967SGH000147865  
02-Sep-2012  
10:18:16.18  
3 IMA 30  
SPI 3  
SP -291.4

kV 130  
eff mAs 24  
ref mAs 130  
TI 0.6  
GT 0.0  
SL 5.0/16x1.2/p0.8  
193.7/0  
B41s L3C0 A2

Post Contrast

RAD Hadi, Reimas Nasser Abdu  
A  
Emotion 16 SY01.0000212958  
CT 2006G 106-Nov-2011, F, 9M  
# 967SGH000147865  
02-Sep-2012  
10:18:16.38  
3 IMA 31  
SPI 3  
SP -296.4

