



# Pediatric Solid Tumors

RAED AL-TAHER, M.D.

# The International Classification of Childhood Cancer, Third Edition\* (ICCC-3-2017 update\*\*)

*Don't memorize this slide*

- I. Leukemias, myeloproliferative diseases, and myelodysplastic diseases
- II. Lymphomas and reticuloendothelial neoplasms
- III. CNS and miscellaneous intracranial and intraspinal neoplasms
- IV. **Neuroblastoma** and other peripheral nervous cell tumors
- V. Retinoblastoma
- VI. **Renal tumors**
- VII. Hepatic tumors
- VIII. Malignant bone tumors

\* E. Steliarova-Foucher, C. Stiller, B. Lacour, and P. Kaatsch, "International Classification of Childhood Cancer, third edition," *Cancer*, vol. 103, no. 7, pp. 1457-1467, 2005.

\*\* [Click here to show the ICCC-3-2017 update.](#)

IX. **Soft tissue and other extrasosseous sarcomas**

X. **Germ cell tumors, trophoblastic tumors, and neoplasms of gonads**

# The International Classification of Childhood Cancer, Third Edition (ICCC-3)

## Neuroblastoma

Mysterious embryonal tumor | Arising from neuroblasts | Unpredictable behavior

## Nephroblastoma Wilms' Tumor

Highly malignant renal tumor | Derived from embryonic tissue |  
Reasonable prognosis due to successful multimodal therapy



# Neuroblastoma

Mysterious embryonal tumor | Arising from neuroblasts | Unpredictable behavior

# Neuroblastoma

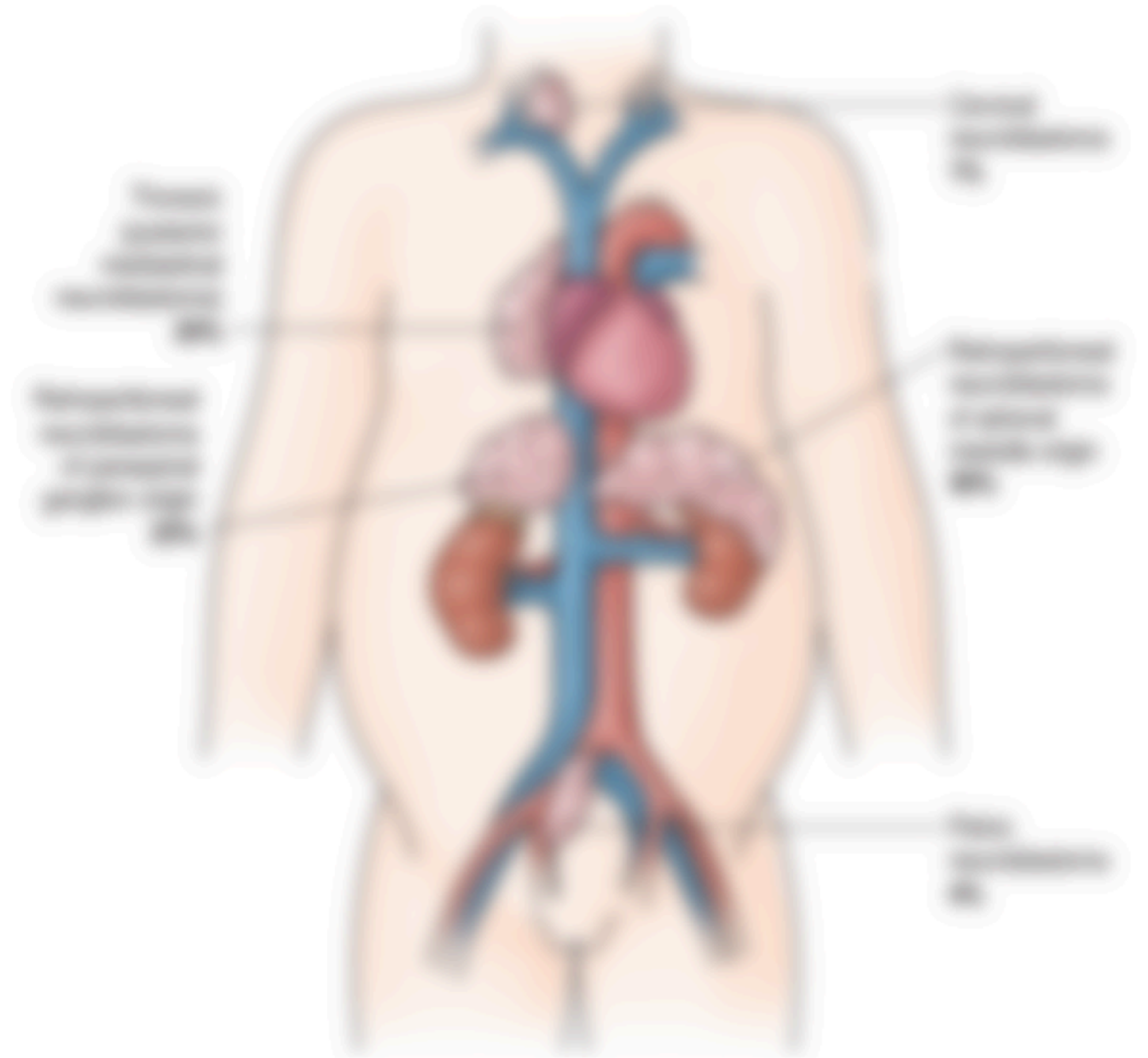
- ▶ A spectrum of neuroblastic tumors (including neuroblastomas (97%), ganglioneuroblastomas, and ganglioneuromas).
- ▶ Arise from primitive sympathetic ganglion cells.
- ▶ Have the capacity to synthesize and secrete catecholamines.

# Neuroblastoma

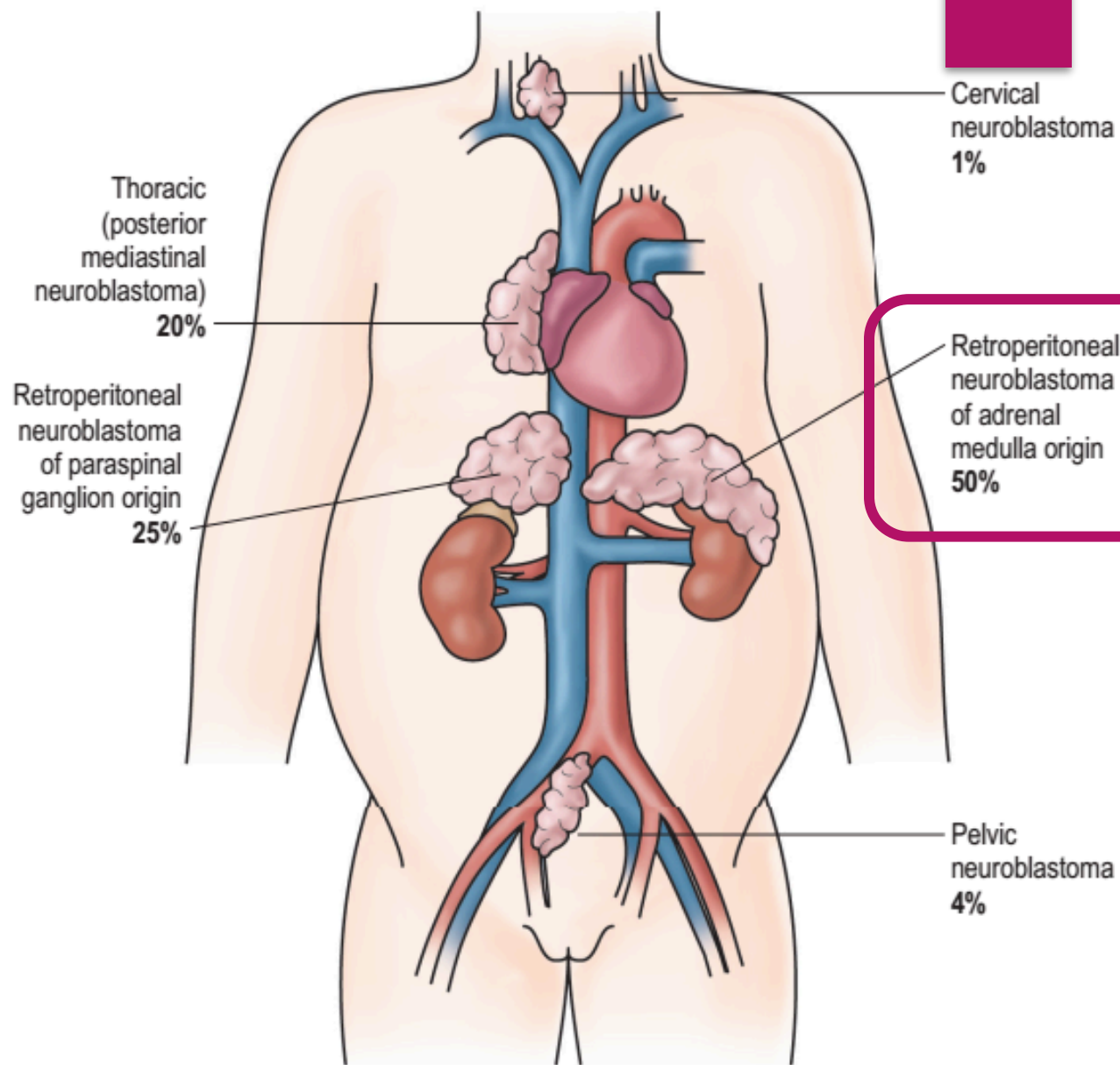
- ▶ 5–10% of all childhood cancers
- ▶ Age of onset
  - Infancy ~30%
  - **1–4 years ~50%**
  - 10–14 years ~5%
- ▶ M > F (slight)

# Neuroblastoma

- ▶ Sites of Origin
  - **Adrenal medulla (~50%)**
  - Abdominal sympathetic ganglia (~25%)
  - Posterior mediastinum (~20%)
  - Pelvis (~3%)
  - Neck (~3%)



# Primary sites for neuroblastoma



# Neuroblastoma

## ► Presenting symptoms

- Palpable **abdominal mass**
- Children often appear **sick**, lethargic with fatigue
- Bone **pain**
- Weight loss
- Fever, sweating and anemia

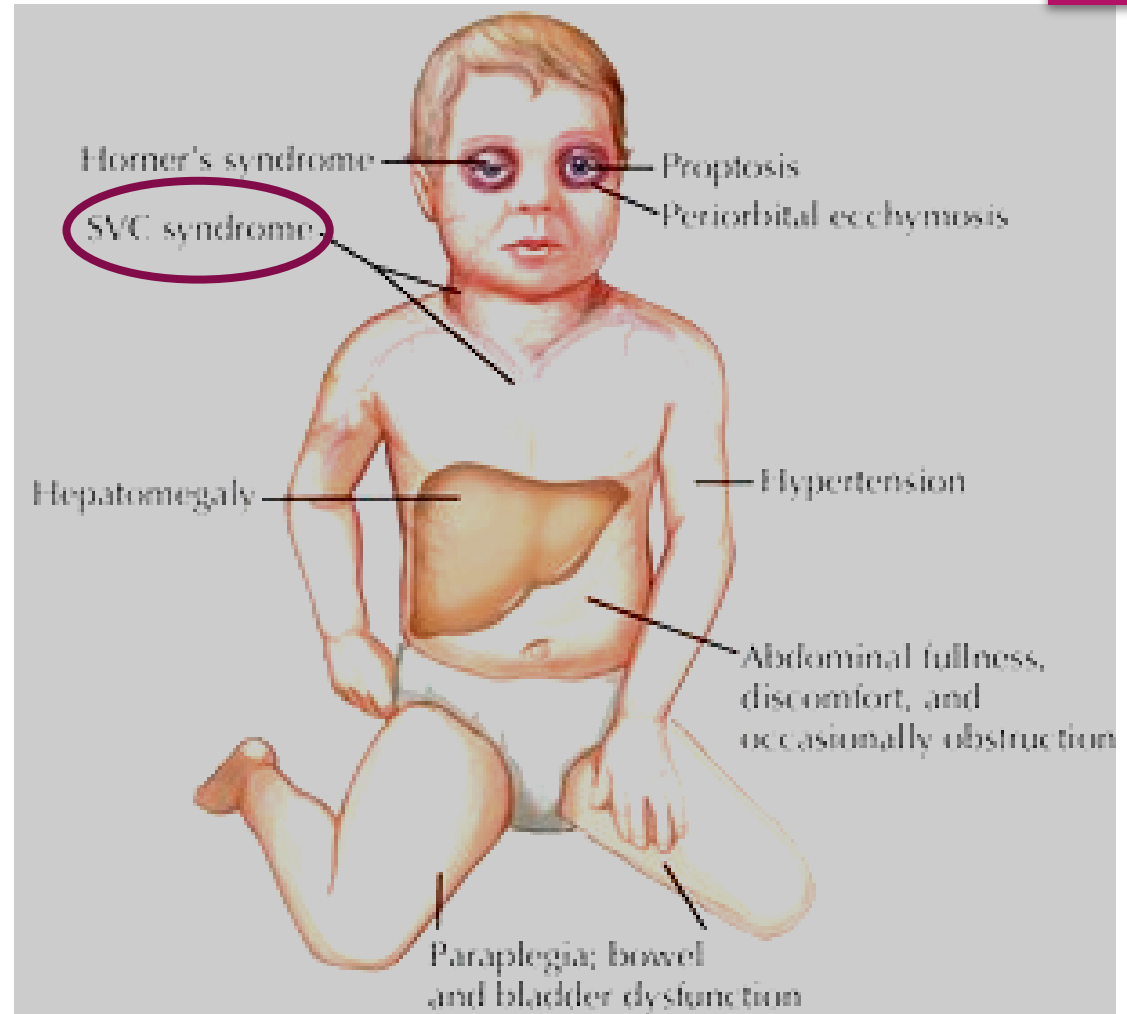
# Neuroblastoma

## ► Unusual but Characteristic Features

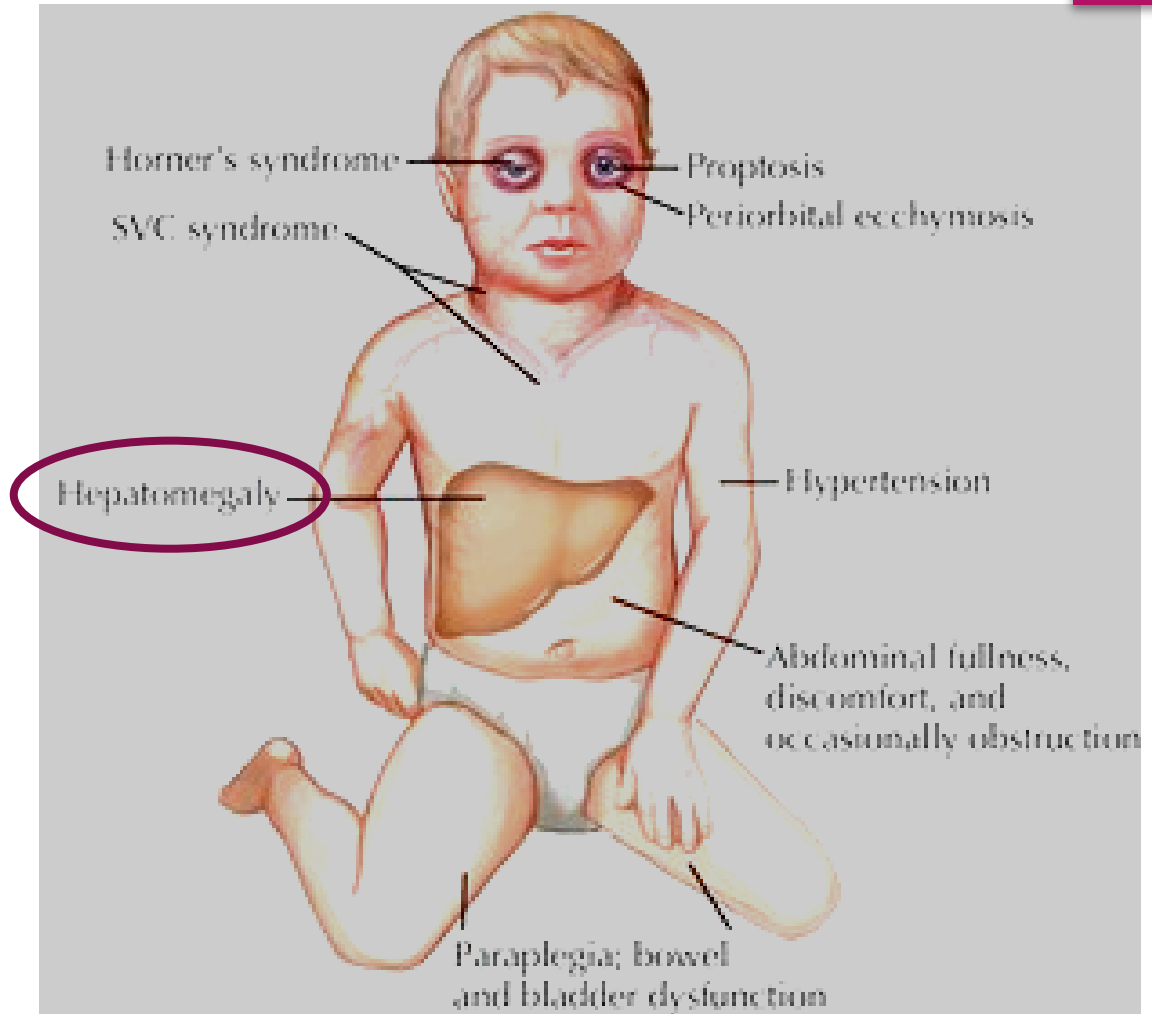
- Periorbital ecchymosis or proptosis (raccoon eyes) retro-orbital secondaries
- Horner's syndrome<sup>1</sup> apical thoracic tumors
- Progressive cerebellar ataxia and trunk opsomyoclonus
- Dancing eye syndrome
- Progressive paraplegia extradural cord compression
- Hypertension (~25%) catecholamine production or renal artery compression
- Skin nodules stage MS disease
- Diarrhea (VIP) release

1. miosis, ptosis, and hemifacial anhidrosis

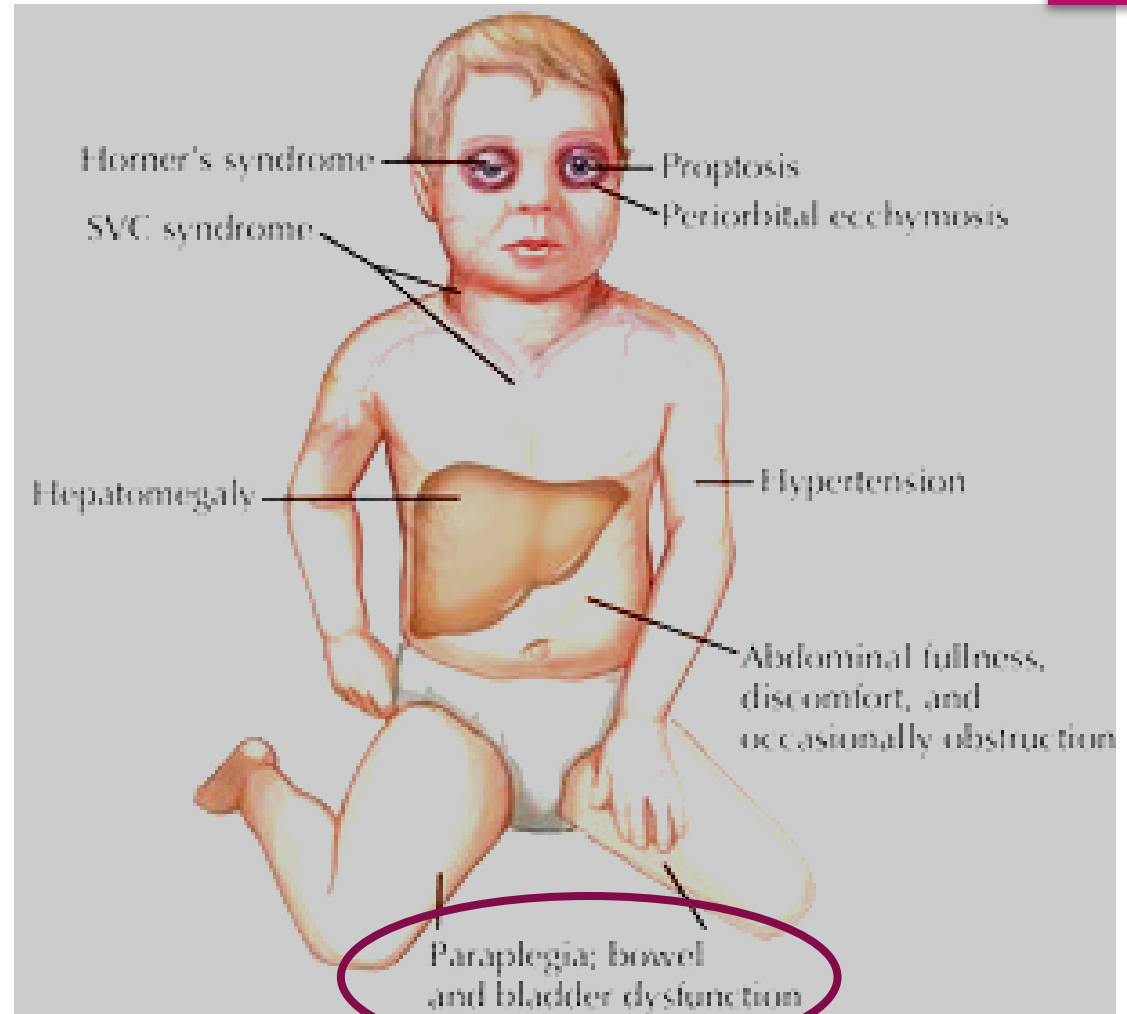
# Characteristic Features



# Characteristic Features



# Characteristic Features



# Neuroblastoma

## ► Investigations

- ↑↑ Vanillylmandelic acid (VMA) and homovanillic acid (HVA) in serum and urine (metabolites of catecholamines)
- ↑ ferritin
- ↑ lactate dehydrogenase (LDH)
- ↑ Neuron specific enolase (NSE)

# Neuroblastoma

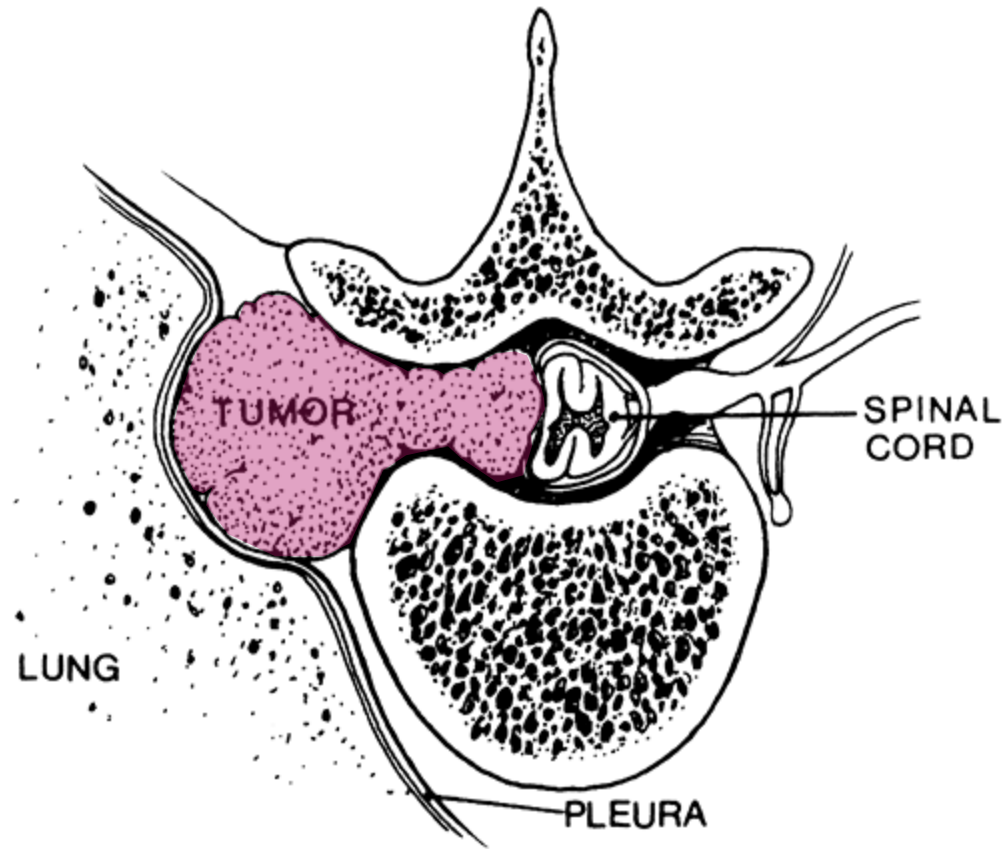
## ► Imaging

- AXR tumor calcification (~50%)
- US solid vs. cystic | renal vein and caval involvement

## ► Staging studies

- CT/MRI scans anatomy of tumor | metastases | intraspinal extension (“dumb-bell” tumor)
- Bone imaging MIBG<sup>1</sup> scan
- Bone marrow Bx

1. meta-iodobenzylguanidine



intraspinal extension (“dumb-bell” tumor)

# Neuroblastoma

## ▶ Investigations

- Tissue Biopsy *percutaneous or open*

# Neuroblastoma

## ▶ Pathology

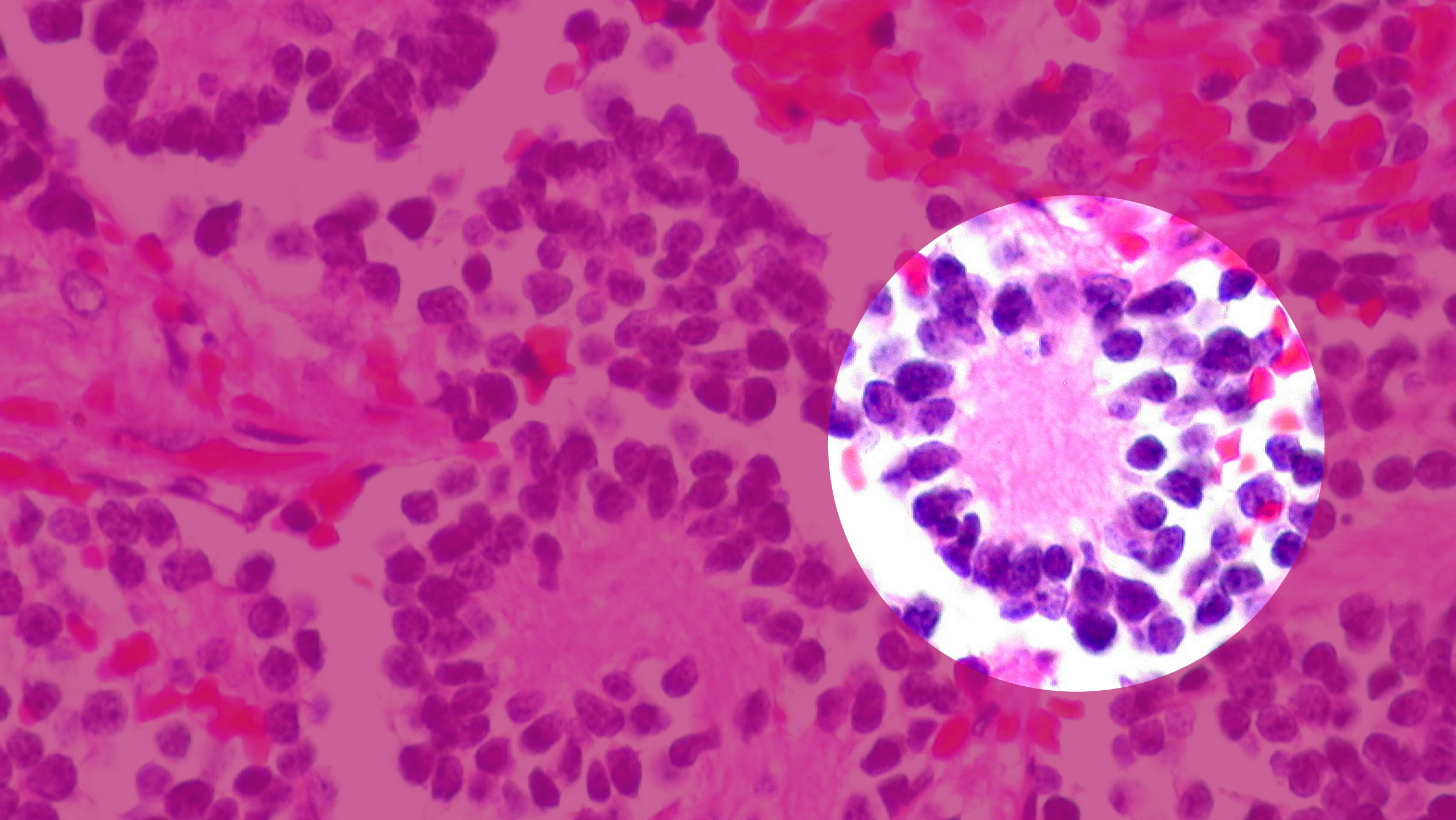
Histological appearance is as sheets of **dark blue round cells** with scanty cytoplasm, embedded in a delicate vascular stroma.

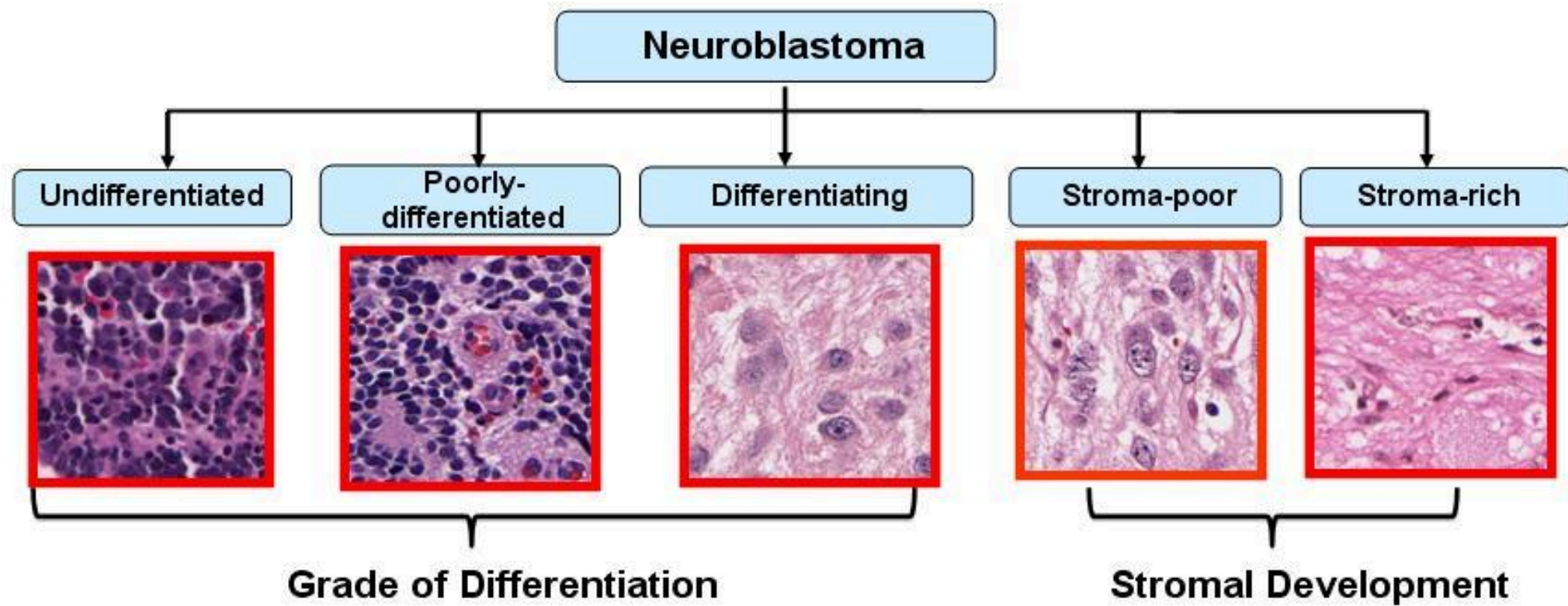
The background of the slide is a microscopic image of neuroblastoma tissue. It shows numerous small, round, blue-stained cells (neuroblasts) arranged in a characteristic ring-like pattern around a central neurofibrillary core, a feature known as rosette formation. The cells have dense, hyperchromatic nuclei and scant cytoplasm. The overall appearance is that of a highly cellular tumor with a distinct architectural pattern.

# Neuroblastoma

## ▶ Pathology

- Characteristic ring of neuroblasts around a neurofibrillary core (**rosette formation**) differentiate from other blue, round cell tumors (e.g., Ewing's sarcoma, lymphoma and rhabdomyosarcoma).





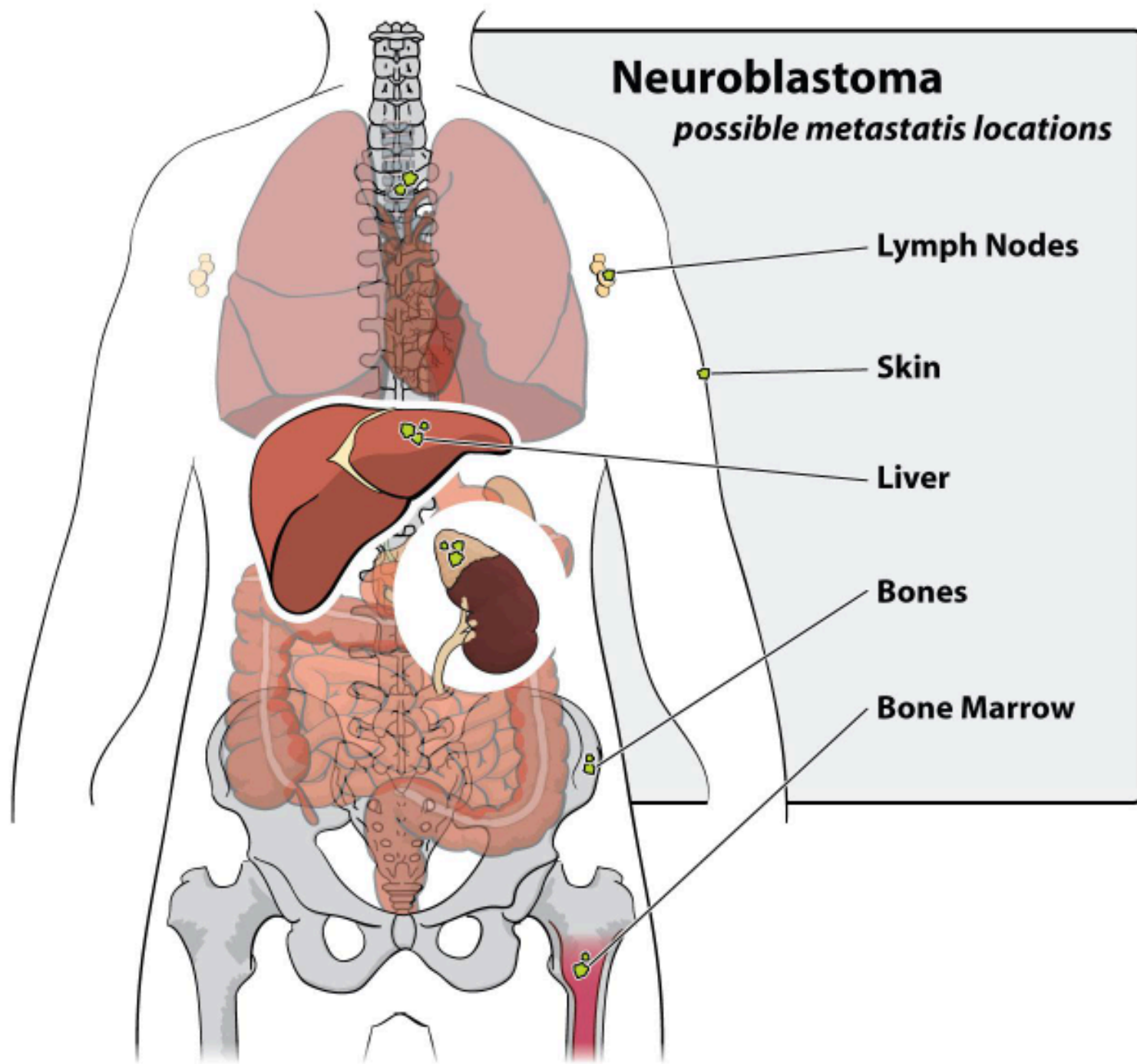
# Neuroblastoma

## ▶ Pathology

- Tends to spread with **local extension** and **encasement** of major vessels.
- May **metastasize** to lymph nodes, bones, bone marrow, liver and skin.
- Secondary spread is usually associated with large primaries (except stage MS tumors).

# Neuroblastoma

*possible metastatis locations*



# Diagnostic criteria

**A definitive diagnosis requires one of the following:\***

- ▶ A clear histologic diagnosis **OR** increased urine (or serum) catecholamines or their metabolites.
- ▶ Evidence of metastases to bone marrow **AND** elevation of urinary or serum catecholamines or their metabolites.

# Neuroblastoma

## ▶ Cytogenetics and Prognostic Factors

- MYCN gene amplification (poor prognosis)
- DNA ploidy (poor prognosis)
- Multidrug resistance-associated protein (MRP) (poor prognosis)
- Ch 17q gain, Ch 1p deletion
- Expression of the H-ras oncogene (low-stage disease)
- CD44 expression (good prognosis)
- TRKA expression (good prognosis)

# Staging

- ▶ The International Neuroblastoma Risk Group Staging System (INRGSS)\*

\*Monclair T, Brodeur GM, Ambros PF, et al. The International Neuroblastoma Risk Group (INRG) Staging System: An INRG Task Force Report. *J Clin Oncol* 2009; 27:298. Copyright © 2009 American Society of Clinical Oncology.

## International Neuroblastoma Risk Group Staging System

Stage	Description
L1	Localized tumor not involving vital structures as defined by the list of IDRFs (below) and confined to one body compartment
L2	Locoregional tumor with presence of one or more IDRFs
M	Distant metastatic disease (except stage MS)
<b>MS</b>	<b>Metastatic disease in children younger than 18 months with metastases confined to skin, liver, and/or bone marrow</b>

### IDRFs in neuroblastic tumors

#### Ipsilateral tumor extension within two body compartments

- Neck-chest, chest-abdomen, abdomen-pelvis

#### Neck

- Tumor encasing carotid and/or vertebral artery and/or internal jugular vein
- Tumor extending to base of skull
- Tumor compressing the trachea

#### Cervicothoracic junction

- Tumor encasing brachial plexus roots
- Tumor encasing subclavian vessels and/or vertebral and/or carotid artery
- Tumor compressing the trachea

#### Thorax

- Tumor encasing the aorta and/or major branches

- Tumor compressing the trachea

### Thorax

- Tumor encasing the aorta and/or major branches
- Tumor compressing the trachea and/or principal bronchi
- Lower mediastinal tumor, infiltrating the costovertebral junction between T9 and T12

### Thoraco-abdominal

- Tumor encasing the aorta and/or vena cava

### Abdomen/pelvis

- Tumor infiltrating the porta hepatis and/or the hepatoduodenal ligament
- Tumor encasing branches of the superior mesenteric artery at the mesenteric root
- Tumor encasing the origin of the coeliac axis, and/or of the superior mesenteric artery
- Tumor invading one or both renal pedicles
- Tumor encasing the aorta and/or vena cava
- Tumor encasing the iliac vessels
- Pelvic tumor crossing the sciatic notch

### Intraspinal tumor extension whatever the location provided that:

- More than one third of the spinal canal in the axial plane is invaded and/or the perimedullary leptomenigeal spaces are not visible and/or the spinal cord signal is abnormal

### Infiltration of adjacent organs/structures

- Pericardium, diaphragm, kidney, liver, duodenopancreatic block, and mesentery

### Conditions to be recorded, but **not** considered IDRFs

- Multifocal primary tumors
- Pleural effusion, with or without malignant cells
- Ascites, with or without malignant cells

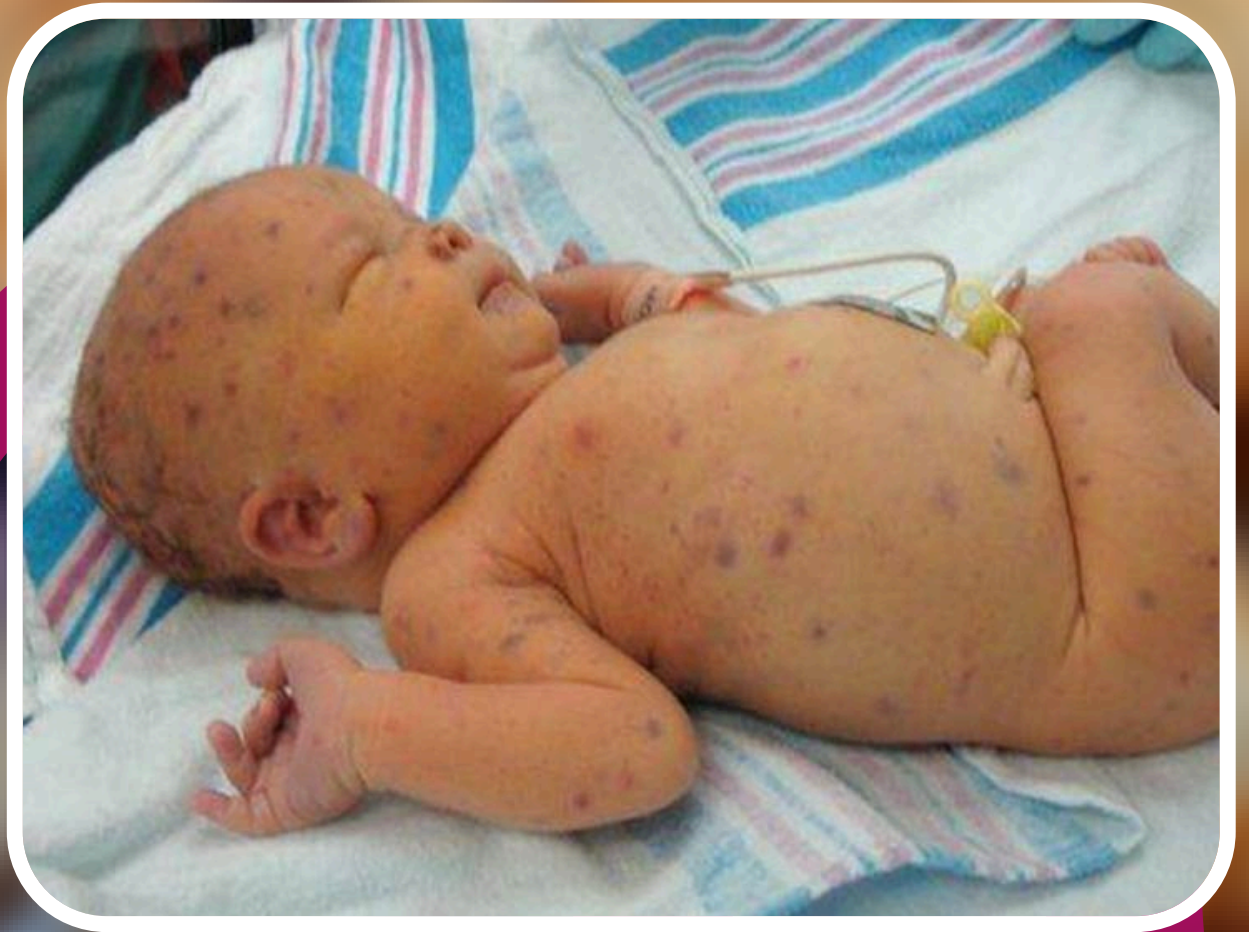*Don't memorize this slide*

# Neuroblastoma

## Stage MS Neuroblastoma

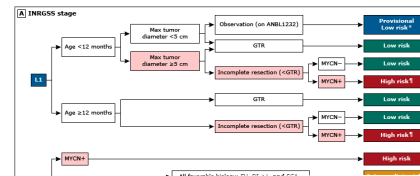
- ~30% of infantile neuroblastoma
- Spontaneous **regression** is possible
- > 80%  **survive** without any specific treatment
- Features:
  - ✓ Hepatosplenomegaly (may cause respiratory failure | can be treated with low dose radiotherapy or cyclophosphamide)
  - ✓ Subcutaneous nodules ('Blueberry muffin' spot)
  - ✓ Positive bone marrow





**Subcutaneous nodules ('Blueberry muffin' spot)**

The INRGSS staging is then combined with molecular, pathologic, and other clinical characteristics to assign the patient to a specific risk group<sup>\*</sup>, which impacts selection of therapy.



*\*Irwin MS, Naranjo A, Zhang FF, et al. Revised Neuroblastoma Risk Classification System: A Report From the Children's Oncology Group. J Clin Oncol 2021; 39:3229. DOI: [10.1200/JCO.21.00278](https://doi.org/10.1200/JCO.21.00278).*



[Click here to show the source](#)

# Prognosis

depends upon prognostic factors, risk stratification, extent and site of metastases, and treatment received

## ▶ **Low-risk disease**

- Event-free survival rates > 85%
- Overall survival ~100%

## ▶ **Intermediate-risk disease**

- Long-term survival rates >90%

## ▶ **High-risk disease**

- Long-term survival rates ~50%

# Neuroblastoma

- ▶ Management
  - **Tumor biopsy** (confirm Dx | assess MYCN status)
  - **Surgical resection alone**
    - ✓ low risk group
    - ✓ absence of IDRF preresection

IDRF: image defined risk factors

# Neuroblastoma

## ► Management

### ▪ **Neoadjuvant chemotherapy** □ **Surgery**

+/- radiotherapy (for residuals)

- ✓ Intermediate risk group
- ✓ Intraspinal extension | apical thoracic tumors

# Neuroblastoma

- ▶ Management (High risk group) *in the following sequence*
  - 1. Induction therapy** Chemotherapy, ALK inhibition, MIBG, monoclonal antibodies
  - 2. Local control** Surgery, Radio-therapy (RT)
  - 3. Consolidation** Chemotherapy, Autologous hematopoietic stem cell transplantation, RT
  - 4. Immunotherapy** Dinutuximab & others

# Screening

Universal screening of infants for neuroblastoma with urine catecholamines is **not recommended**.

Data suggest that this approach does not reduce mortality.



# Nephroblastoma

## Wilms' Tumor

Highly malignant renal tumor | Derived from embryonic tissue |  
Reasonable prognosis due to successful multimodal therapy

# Wilms' Tumor

- ▶ The most common pediatric **renal tumor**
- ▶ The second most common intra-abdominal malignancy (after neuroblastoma)
- ▶ ~10% of all pediatric malignancies

# Wilms' Tumor

- ▶ Median age of onset: 3.5 years
- ▶ M:F ratio = 0.9:1 (unilateral) | 0.6:1 (bilateral)
- ▶ Solitary 88% | multifocal 12%
- ▶ Unilateral 93% | bilateral 7% (synchronous 85% | metachronous 15%)

# Wilms' Tumor

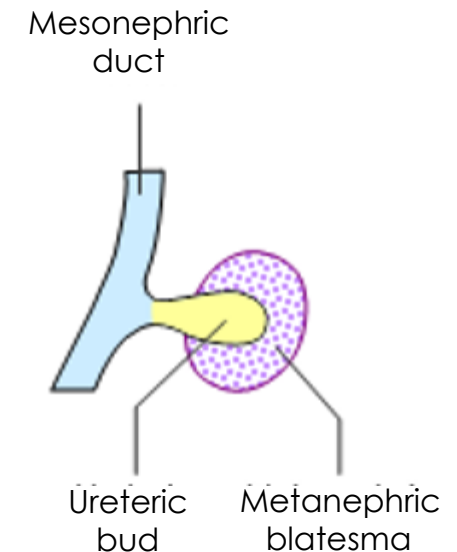
## ▶ Clinical Patterns

- **Sporadic** (>90%)
- Association with congenital anomalies (~5% | GU anomalies)
- Familial/hereditary (1–2% | multiple | bilateral | earlier age of onset)
- Syndromic (<1% | Overgrowth phenotypic syndromes (as BWS) | Nonovergrowth phenotypic syndromes (as WAGR & Denys–Drash syndrome))

# Wilms' Tumor

## ▶ Pathogenesis

- Arises from fetal undifferentiated metanephric blastema tissue.
- Mutations of the WT1, WT2, p53, FWT1 & 2 genes



# Wilms' Tumor

## ▶ Clinical Features

- Usual presentation is a small child with:
  - ✓ **an asymptomatic abdominal mass (80%)**
  - ✓ abdominal pain (30-40%)
  - ✓ hematuria (~20%)
  - ✓ HTN (25%)

# Wilms' Tumor

## ▶ Clinical Features

- Rarer features include:

- ✓ UTI
- ✓ Fever (from tumor necrosis)
- ✓ Anemia
- ✓ Varicocele
- ✓ Acute abdomen with tumor hemorrhage or rupture  
(So, on PEx, avoid vigorous palpation!)

# Wilms' Tumor

## ► Investigations

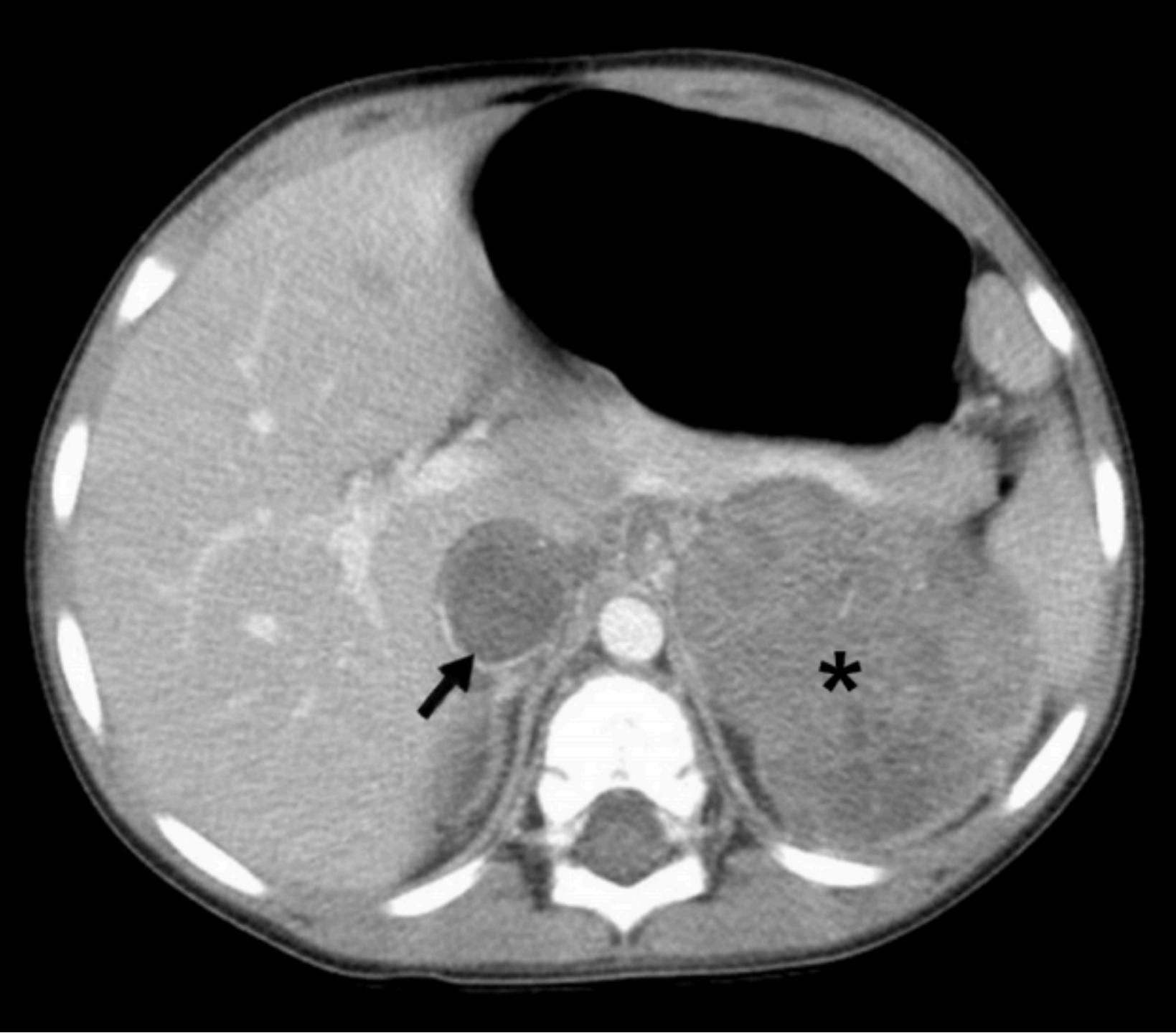- Serum Cr & Urine analysis
- LFT (? liver mets)
- $\beta$ FGF, Renin, Erythropoietin
- Cytogenetics studies

$\beta$ FGF: Basic fibroblast growth factor

# Wilms' Tumor

## ► Imaging studies

- US
- **CT Scan/MRI** staging, extension into renal veins and cava (~40%)
- Bone and brain scan to identify mets
- Echocardiogram right atrial involvement
- Arteriography preoperative embolization in large tumors, solitary kidney, bilateral tumors, or tumor in a horseshoe kidney
- DMSA bilateral WT to assess individual renal function



# DIFFERENTIAL DIAGNOSIS

## ▶ Neuroblastoma

## ▶ Other kidney tumors (rare):

- Clear cell sarcoma
- Rhabdoid tumor
- Congenital mesoblastic nephroma
- Renal cell carcinoma
- Renal medullary carcinoma

can be differentiated from Wilms tumor by imaging studies and tissue histology

# Wilms' Tumor

## ► Management options:

- Neoadjuvant chemotherapy
  - Surgery (SIOP-UMBRELLA Protocol)
    - ✓ downstage the tumor
    - ✓ ↓ operative morbidity
- Surgery □ adjuvant chemotherapy (COG)

Both treatment approaches have excellent and comparable clinical outcomes\*

\*D'Angio GJ. Pre- or postoperative therapy for Wilms' tumor? J Clin Oncol. 2008 Sep 1;26(25):4055-7. doi: 10.1200/JCO.2008.16.5316. PMID: 18757319

# Wilms' Tumor

- ▶ Surgery
    - **Nephrectomy** including perinephric fascia and regional lymph nodes
    - **Partial Nephrectomy:**
      - ✓ Bilateral WT
      - ✓ Contralateral pre-existing abnormality of kidney
      - ✓ WT in single kidney
      - ✓ WT with nephroblastomatosis
- Venous extension *venotomy & removal*
  - Hepatic or pulmonary metastatectomies

# Staging of WT\*

Stage	Children's Oncology Group (COG) (before chemotherapy)	International Society of Paediatric Oncology (SIOP) (after chemotherapy)
I	Tumor is limited to the kidney and completely excised	Tumor is limited to the kidney or surrounded with fibrous pseudocapsule if outside of the normal contours of the kidney; the kidney capsule or pseudocapsule may be infiltrated with the tumor, but it does not reach the outer surface and is completely resected (resection margins "clear")
	Tumor was not ruptured before or during removal	Tumor may be protruding into the pelvic system and "dipping" into the ureter (but not infiltrating their walls)
	Vessels of the renal sinus are not involved beyond 2 mm	Vessels of the renal sinus are not involved
	No residual tumor apparent beyond the margins of excision	Intrarenal vessel involvement may be present
II	Tumor extends beyond the kidney but is completely excised	Tumor extends beyond the kidney or penetrates through the kidney capsule and/or fibrous pseudocapsule into perirenal fat but is completely resected (resection margins "clear")
	No residual tumor is apparent at or beyond the margins of excision	Tumor infiltrates the renal sinus and/or invades blood and lymphatic vessels outside of the kidney parenchyma but is completely resected
	Tumor thrombus in vessels outside of the kidney is stage II if the thrombus is removed en bloc with the tumor	Tumor infiltrates adjacent organs or vena cava but is completely resected
	Although tumor biopsy or local spillage confined to the flank were considered stage II in the past, such events are now considered stage III	
III Residual tumor confined to the abdomen	Lymph nodes in the renal hilum, in the periaortic chains, or beyond are found to contain tumor	Incomplete excision of the tumor, which extends beyond resection margins (gross or microscopical tumor remains postoperatively)
	Diffuse peritoneal contamination by the tumor	Any abdominal lymph nodes are involved
	Implants are found on the peritoneal surfaces	Tumor rupture before or intraoperatively (irrespective of other criteria for staging)
	Tumor extends beyond the surgical margins either microscopically or grossly	Tumor has penetrated through the peritoneal surface
	Tumor is not completely resectable, because of local infiltration into vital structures	Tumor thrombi present at resection margins of vessels or ureter; transected or removed piecemeal by surgeon
		Tumor has been surgically biopsied (wedge biopsy) prior to preoperative chemotherapy or surgery
		Regional lymph node involvement was considered stage II in the previous International Society of Paediatric Oncology staging system
IV	Presence of hematogenous metastases or metastases to distant lymph nodes	Hematogenous metastases (lung, liver, bone, brain, etc) or lymph node metastases outside of the abdominopelvic region
V	Bilateral kidney involvement at the time of initial diagnosis	Bilateral kidney tumors at diagnosis

\*Metzger ML, Dome JS. Current therapy for Wilms' tumor. *Oncologist* 2005; 10:815. Copyright ©2005 AlphaMed Press.

*Don't memorize this slide*

# Wilms' Tumor

## ▶ **Histopathology**

- Favorable histology (90%)  
tubular epithelial, blastemal, and stromal elements
- Unfavorable histology (10%)  
anaplasia (focal or diffuse nuclear enlargement)

# Wilms' Tumor

## ► Prognosis

- Stage I–III : SR >90%

- Stage IV : SR ~70%

- Most important prognostic factors:

- ✓ **Stage** (**low** vs high)

- ✓ Tumor histology (**favorable** vs unfavorable)

- ✓ Age at diagnosis (**better survival in older children** vs ↓ survival in infants)

- ✓ Recurrence (**worse**)

# Screening

- ▶ **Screening** for Wilms tumor with serial abdominal **ultrasonography** is performed **in high-risk patients** (eg, children with BWS or WAGR syndrome).