

HYDATID CYST OF THE LIVER

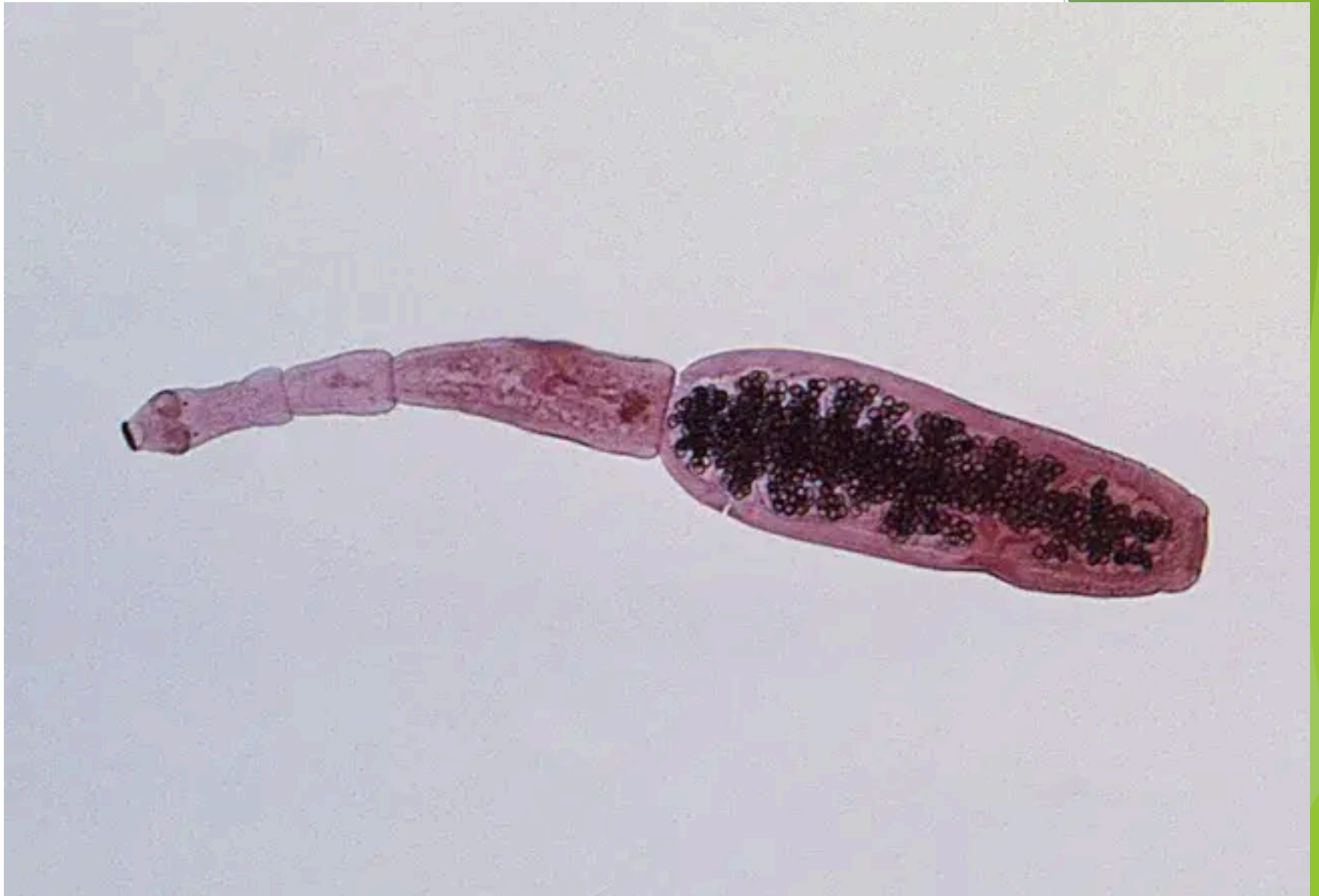Salam Daradkeh

DEPARTMENT OF GENERAL SURGERY

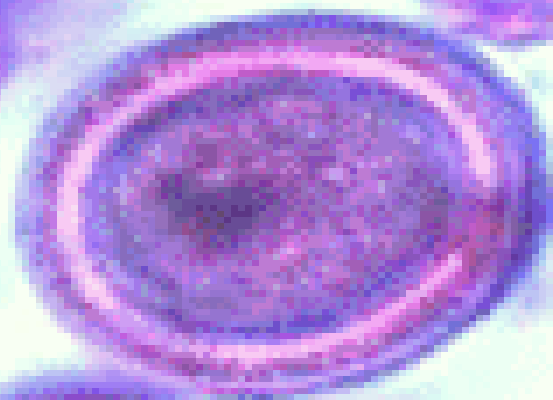
Echinococcus granulosus
adult



(By P.W. Pappas and S.M. Wardrop; original by P. Darben)

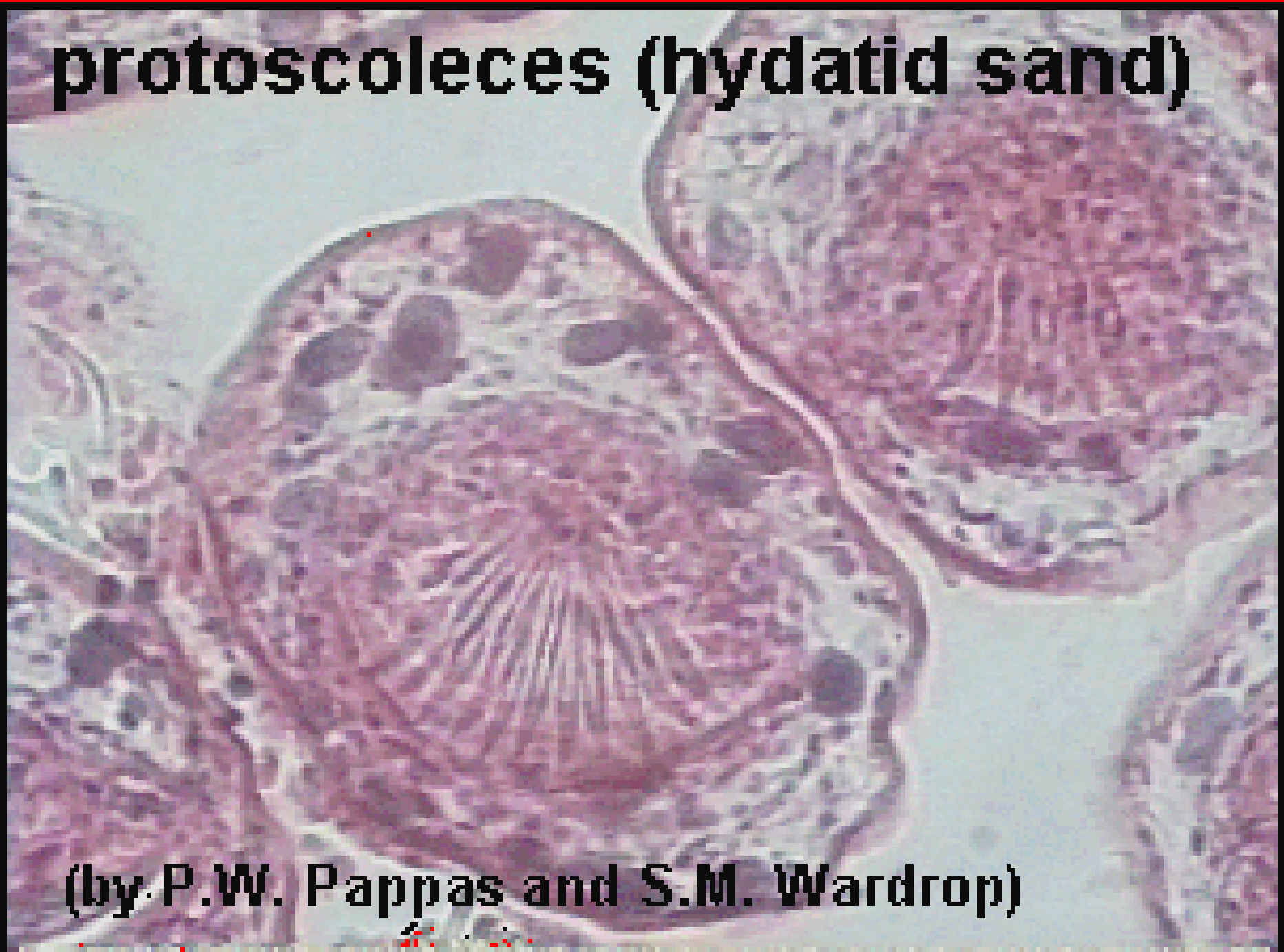


Echinococcus granulosus egg




(By P.W. Pappas and S.M. Wardrop;
original by P. Darben)

protoscoleces (hydatid sand)




(by P.W. Pappas and S.M. Wardrop)

The adult tapeworm is found in the small intestine of the canine (definitive) host.




Eggs are passed in the host's feces.


The eggs are ingested by an intermediate host. Many species of warm blooded vertebrates can be infected.



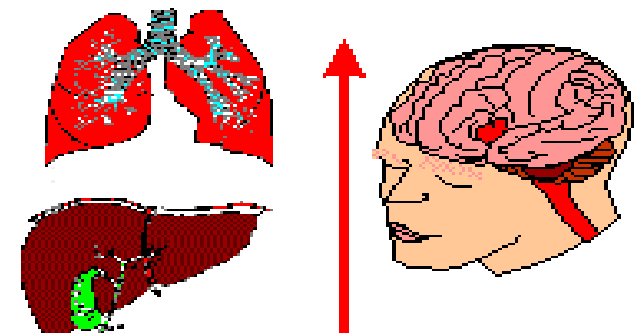
The protoscolex attaches to the host's intestine and develops into a tapeworm.

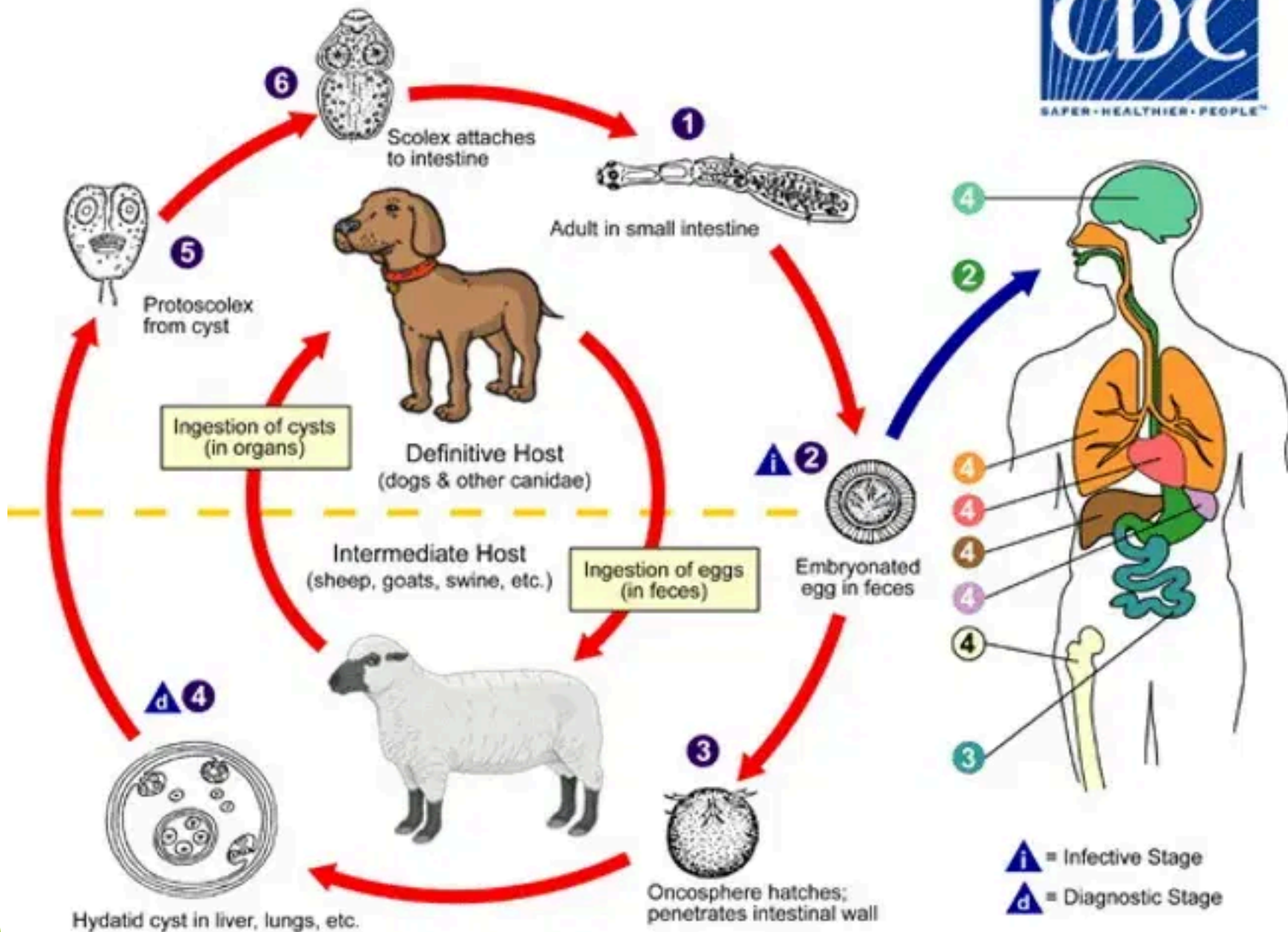



The definitive host is infected when it ingests the hydatid cyst (protoscoleces).



The larva develops into a hydatid cyst.







VP

S

CLINICAL FEATURES

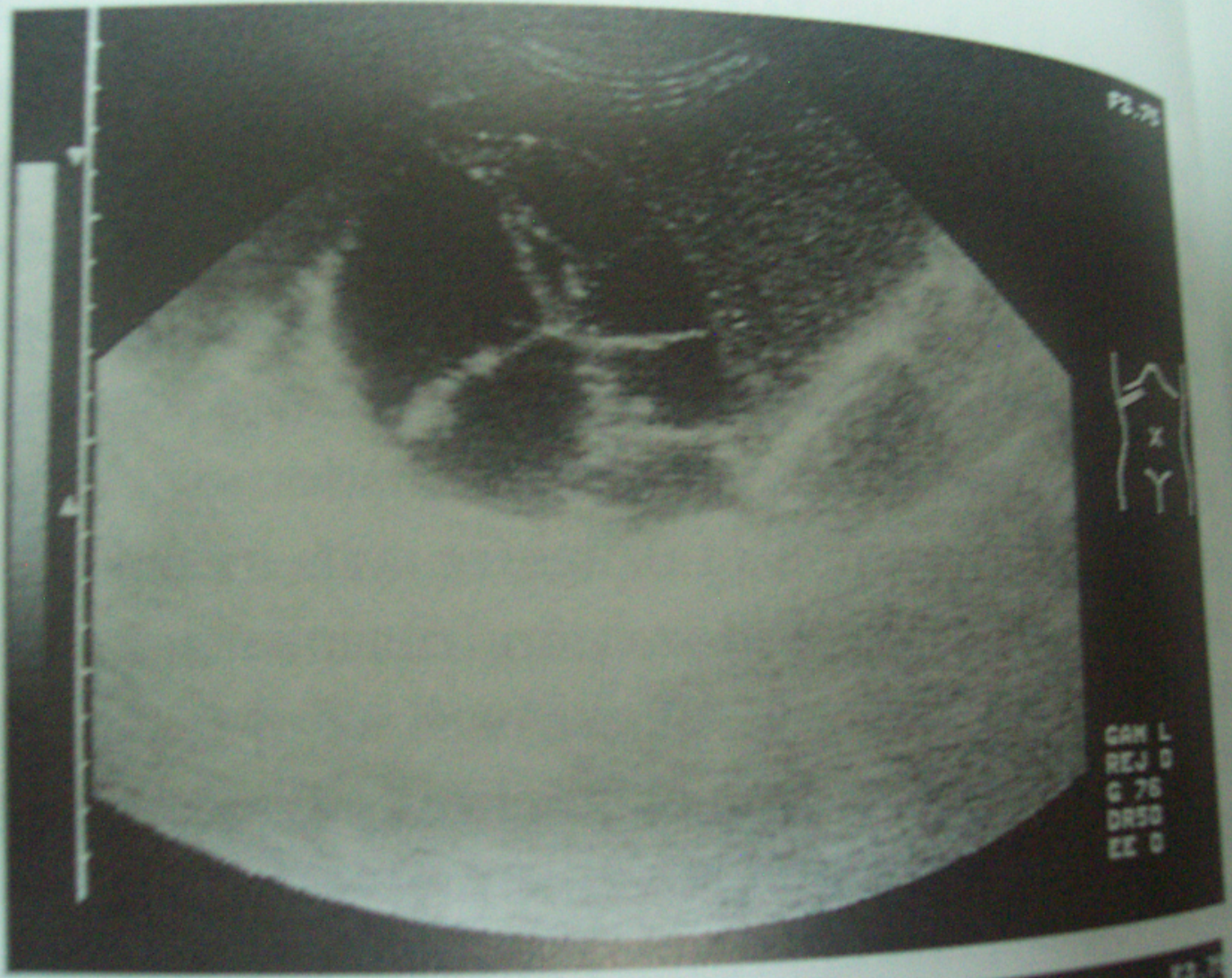- ▶ **LATENCY:** (Asymptomatic, Abdominal pain).
- ▶ **SUPPURATION:** 11%-27%. E.COLI
- ▶ **PRESSURE EFFECTS:** LIVER TISSUE, HILUM, HEPATIC VEINSetc.

Clinical Features

- ▶ **RUPTURE:**
 - **Obscure:** rupture of the endocyst.
 - **Communicant Rupture:** biliary tree, bronchial tree.
 - **Free Rupture:** free body cavities or adjacent organs.(1-4%)

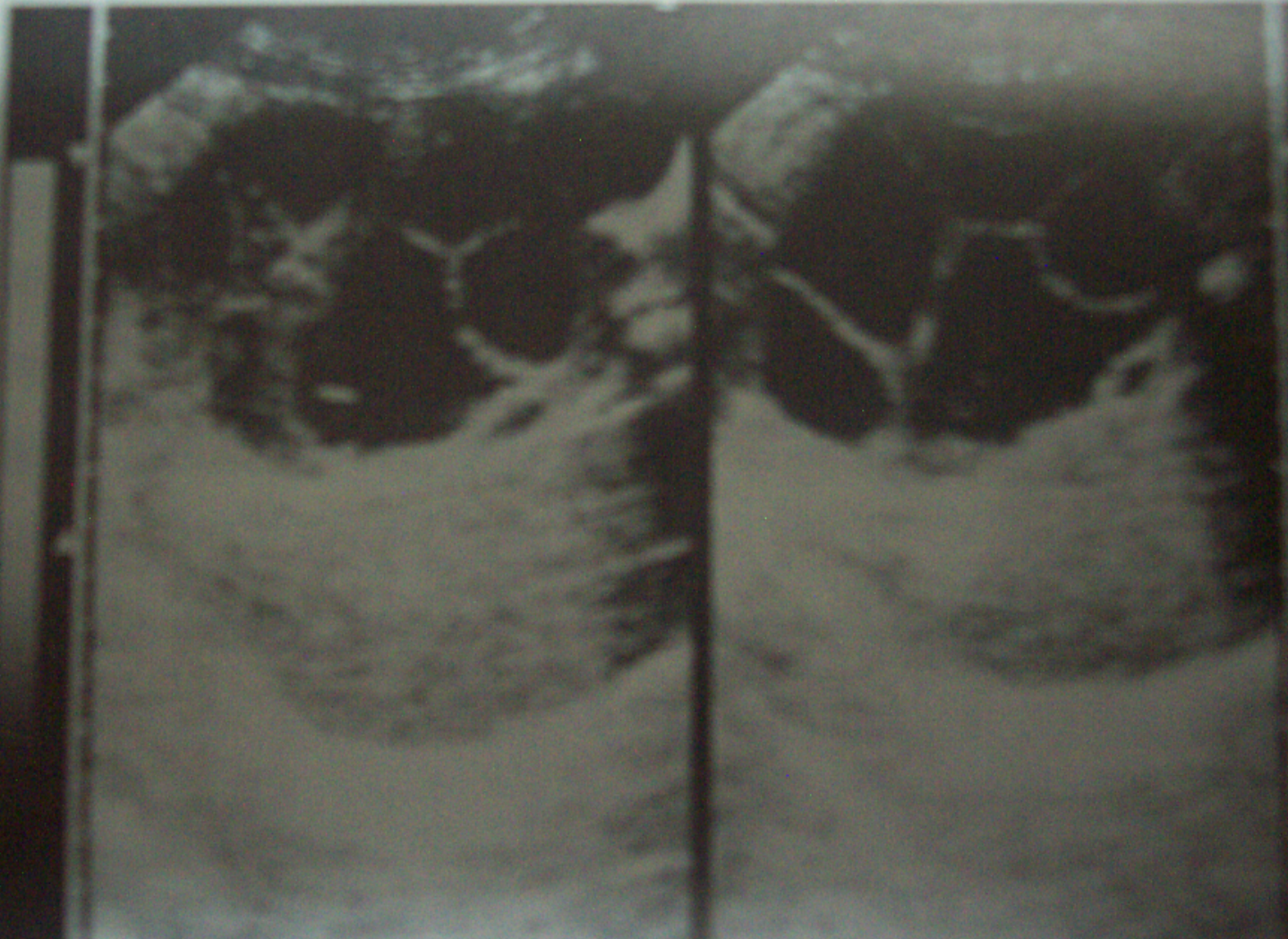
DIAGNOSIS- IMAGING

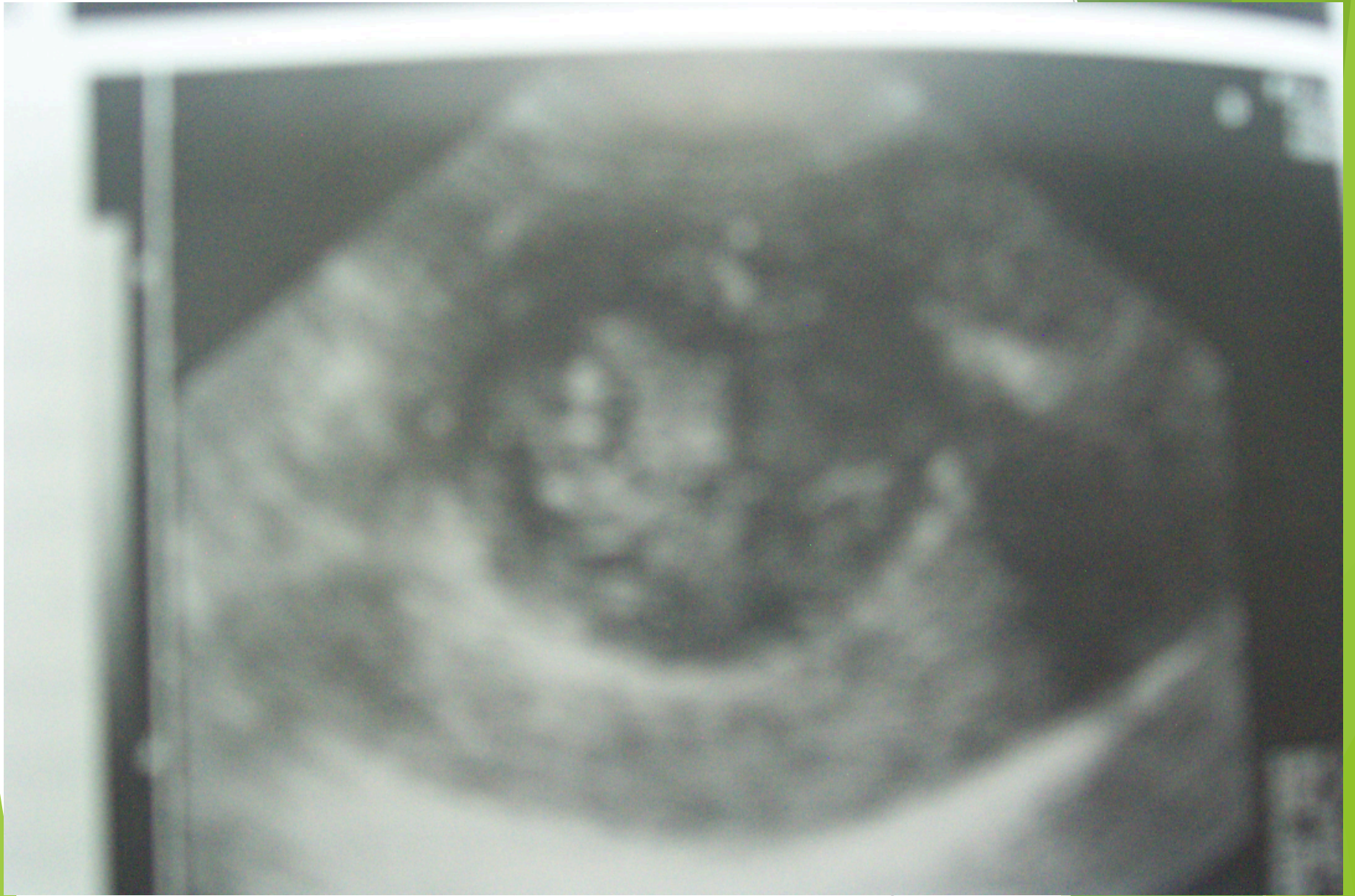
- ▶ **PLAIN X-RAY:** CALCIFICATION.
- ▶ **ULTRASONOGRAPHY:** H.Gharby 1981 classification:
 - 1- simple hydatid cyst.(budding + h.sand)
 - 2- fluid collection with a split wall(Water-lily)
 - 3- fluid collection with septa(Honeycomb).
 - 4- heterogeneous appearance.
 - 5- reflecting thick wall.

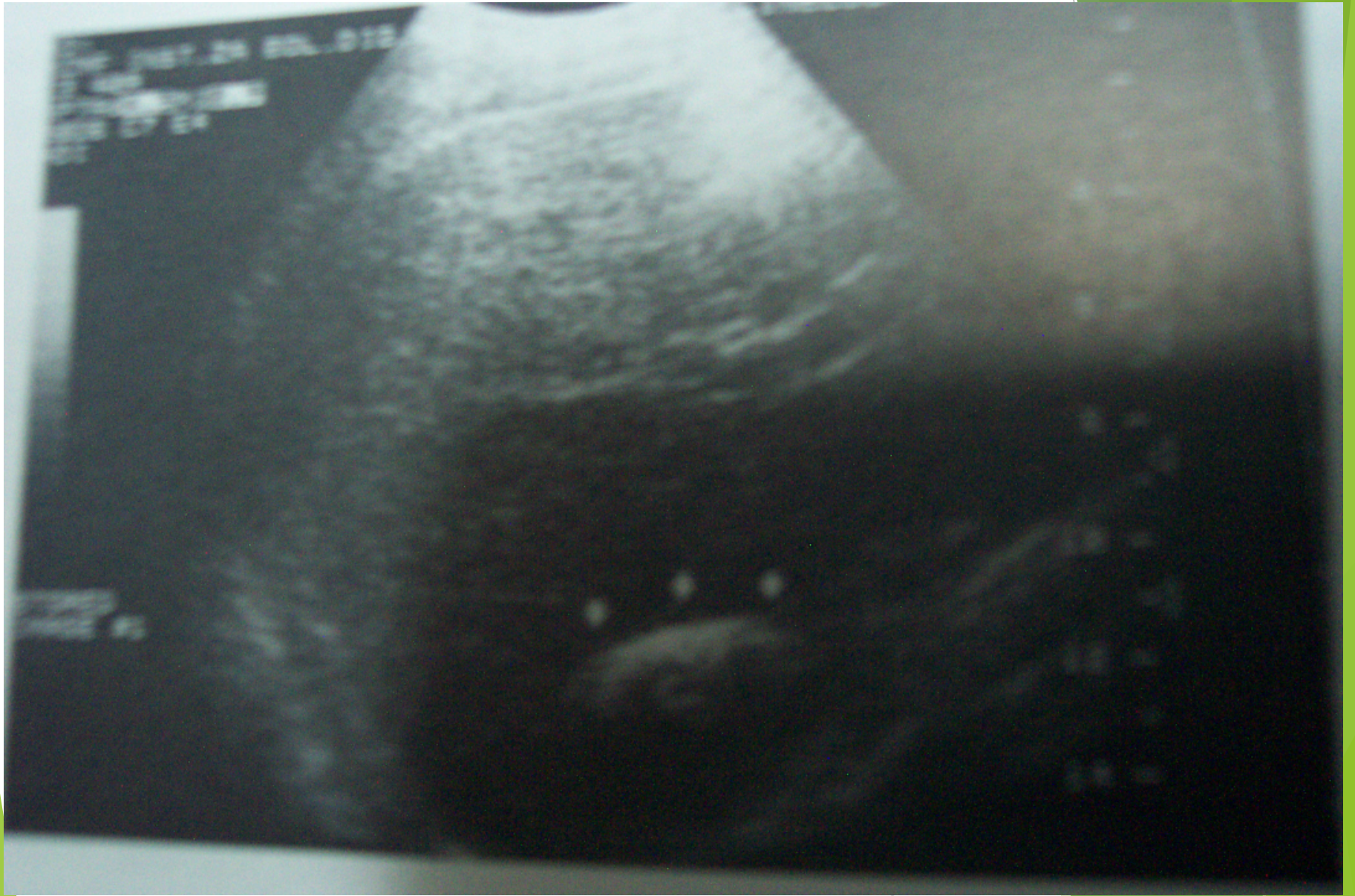


(B)

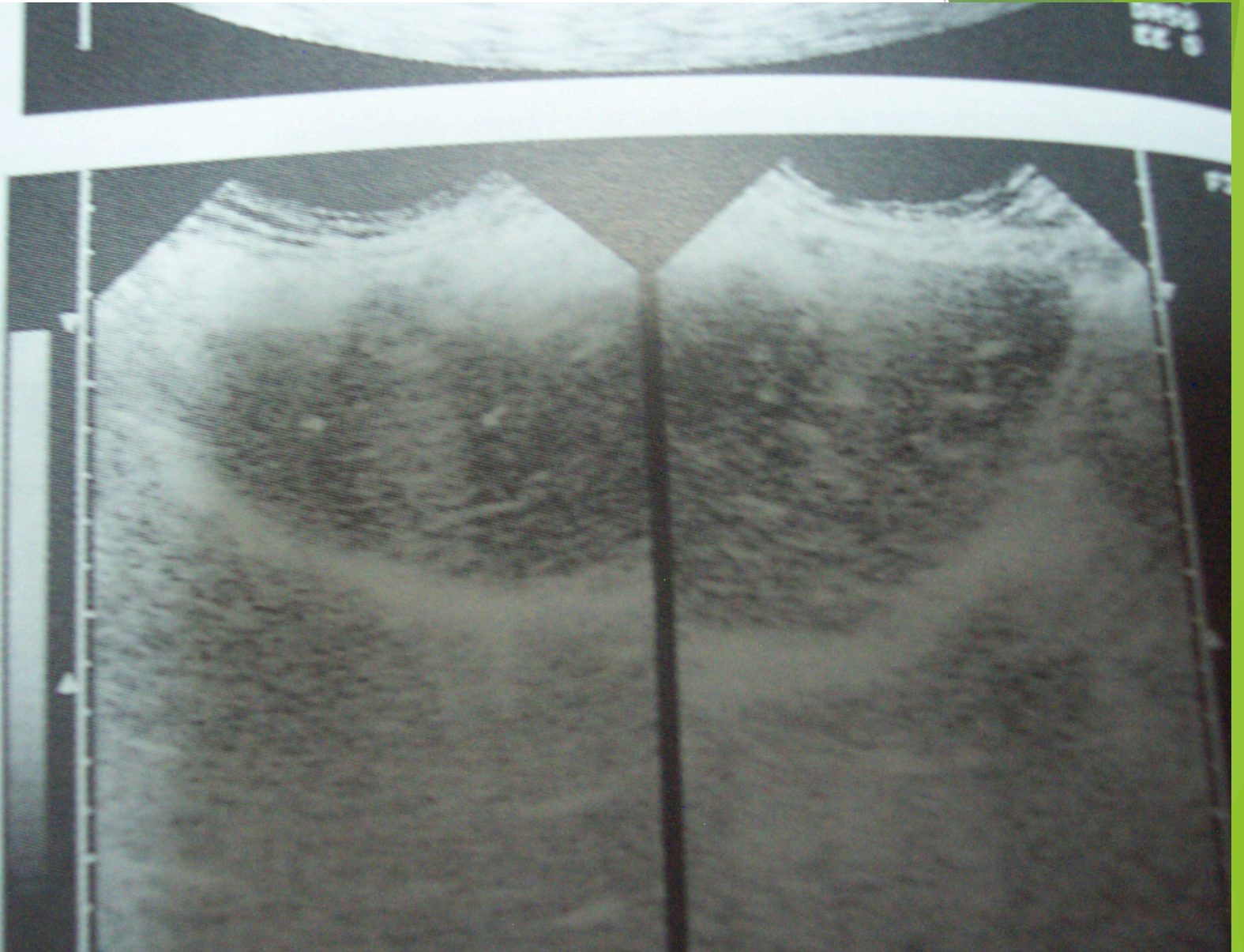
(A)







(D)



Diagnosis-Imaging

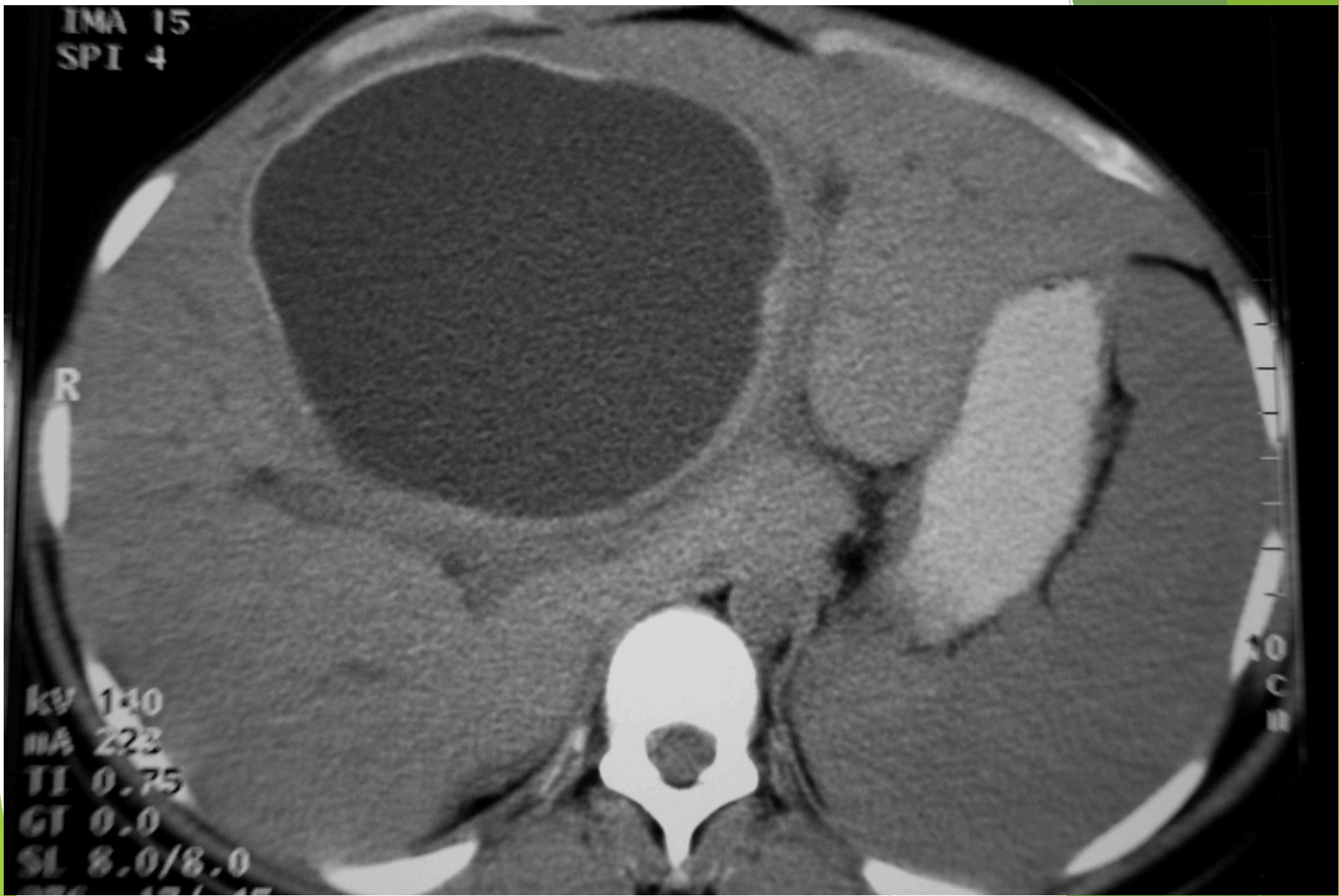- ▶ CT SCAN:
- ▶ MRI.
- ▶ ERCP.
- ▶ PTC.
- ▶ ANGIOGRAPHY.
- ▶

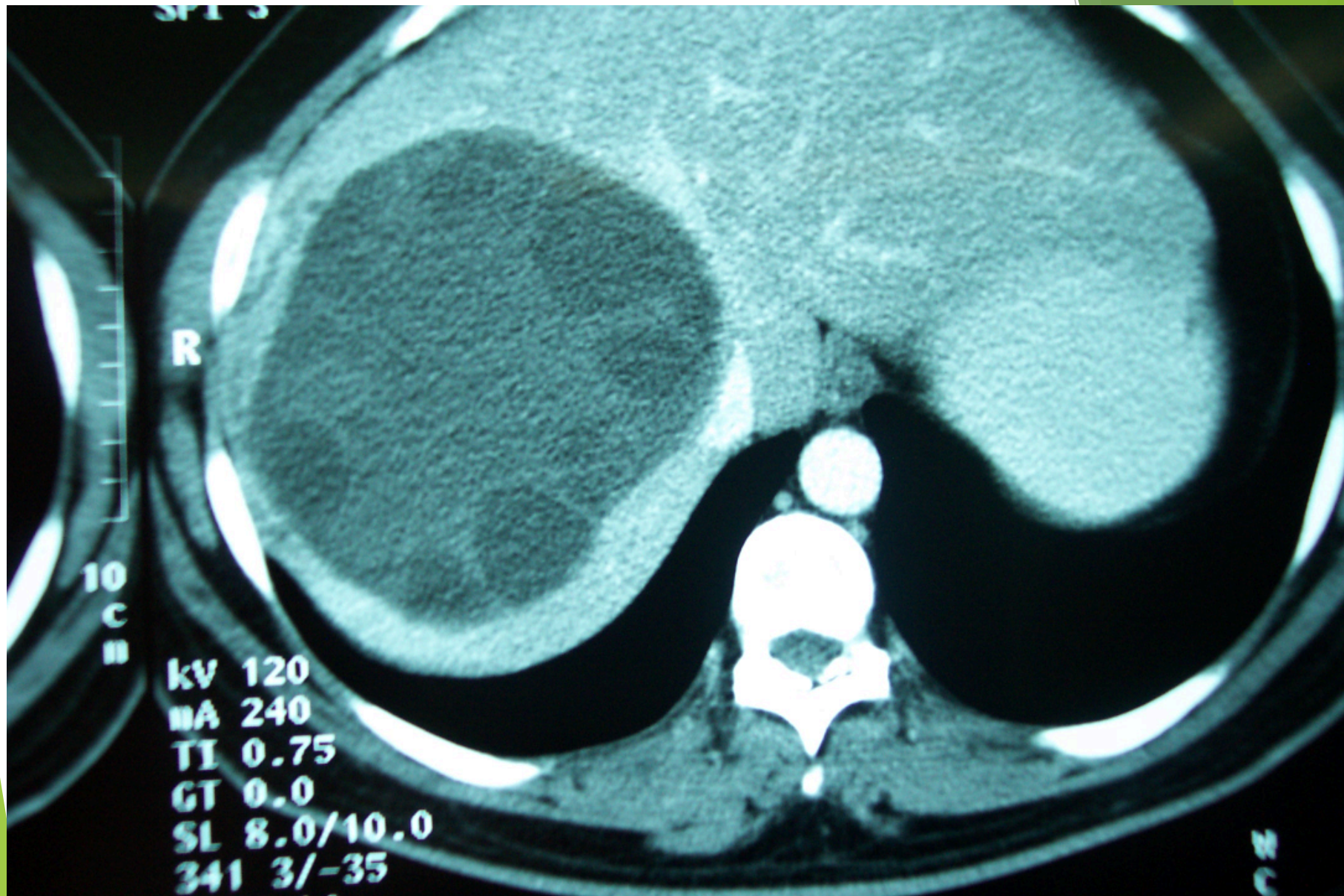
IMA 15
SPI 4

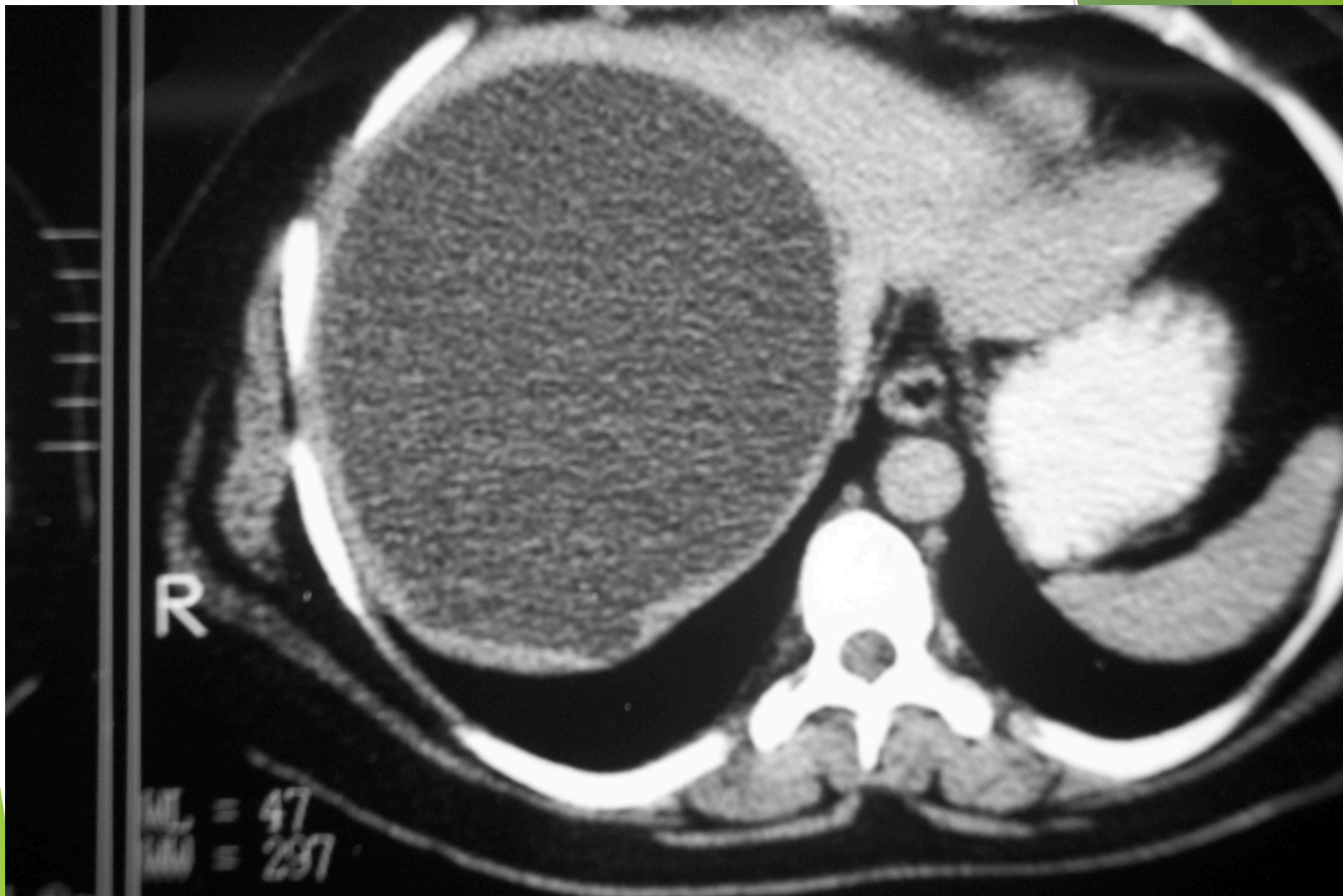
R

kV 140
mA 223
TI 0.75
GT 0.0
SL 8.0/8.0

100







30-JUN-2003
10:35:10.53

30-JUN
10:35:

R

R

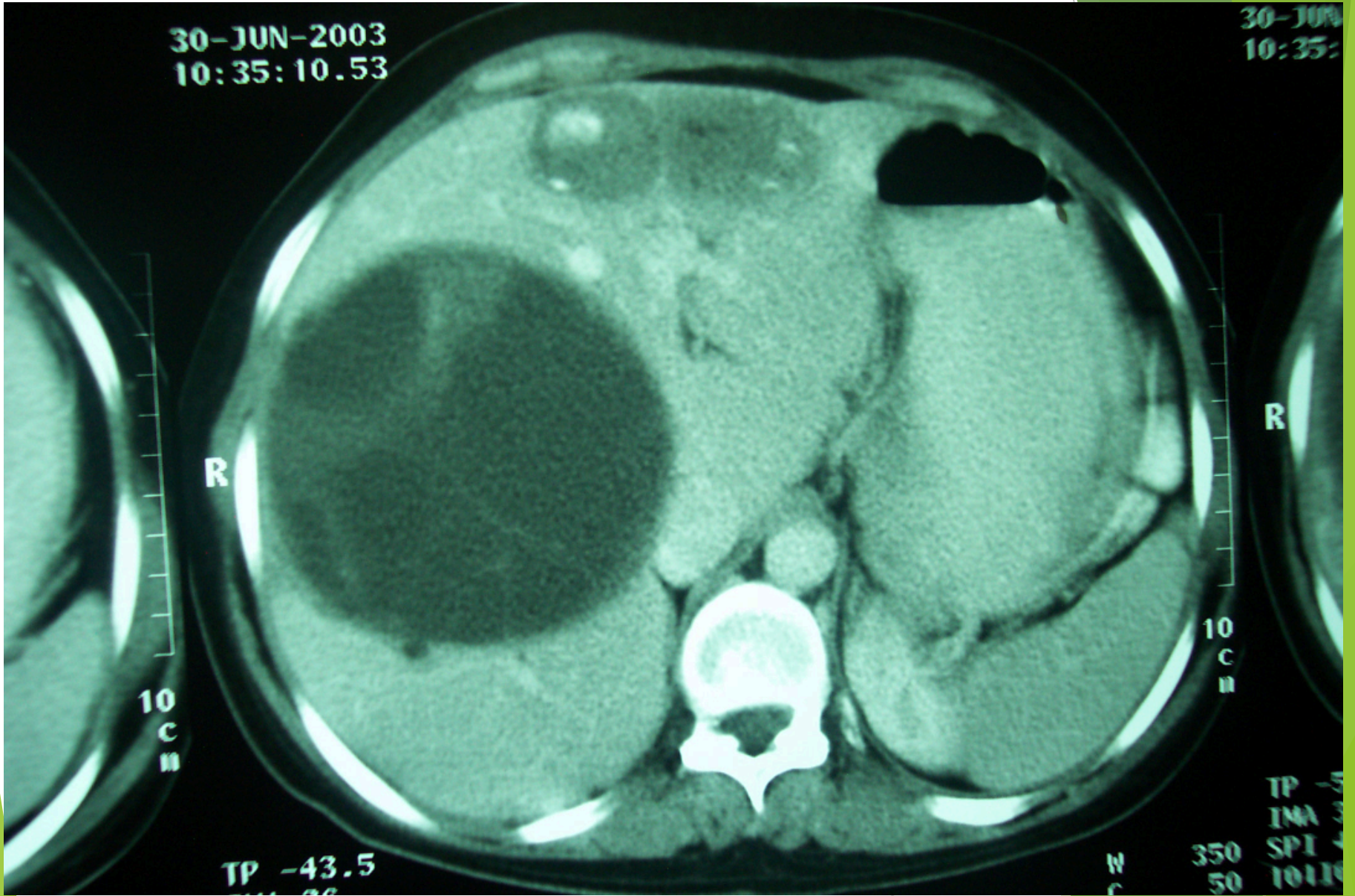
10
C
M

10
C
M

TP -43.5

350
50

TP -5
IMA 3
SPI 4
1011



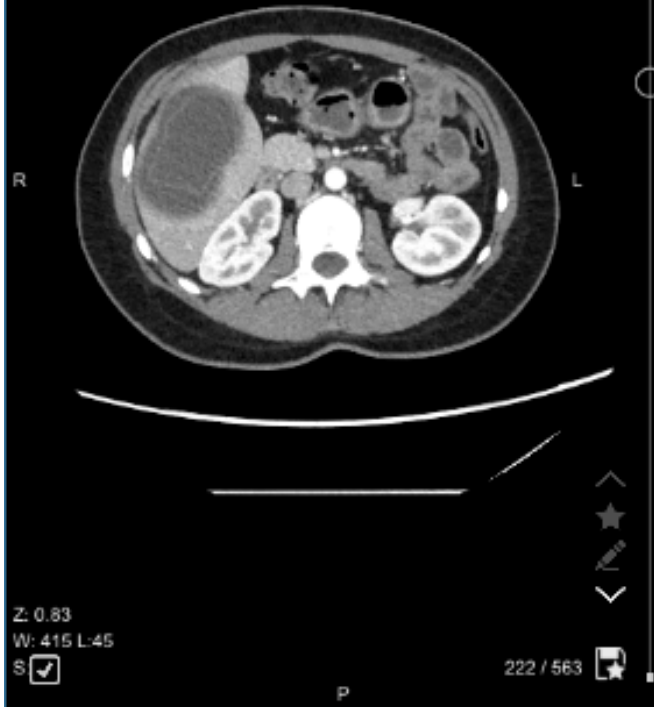18:08

Messages



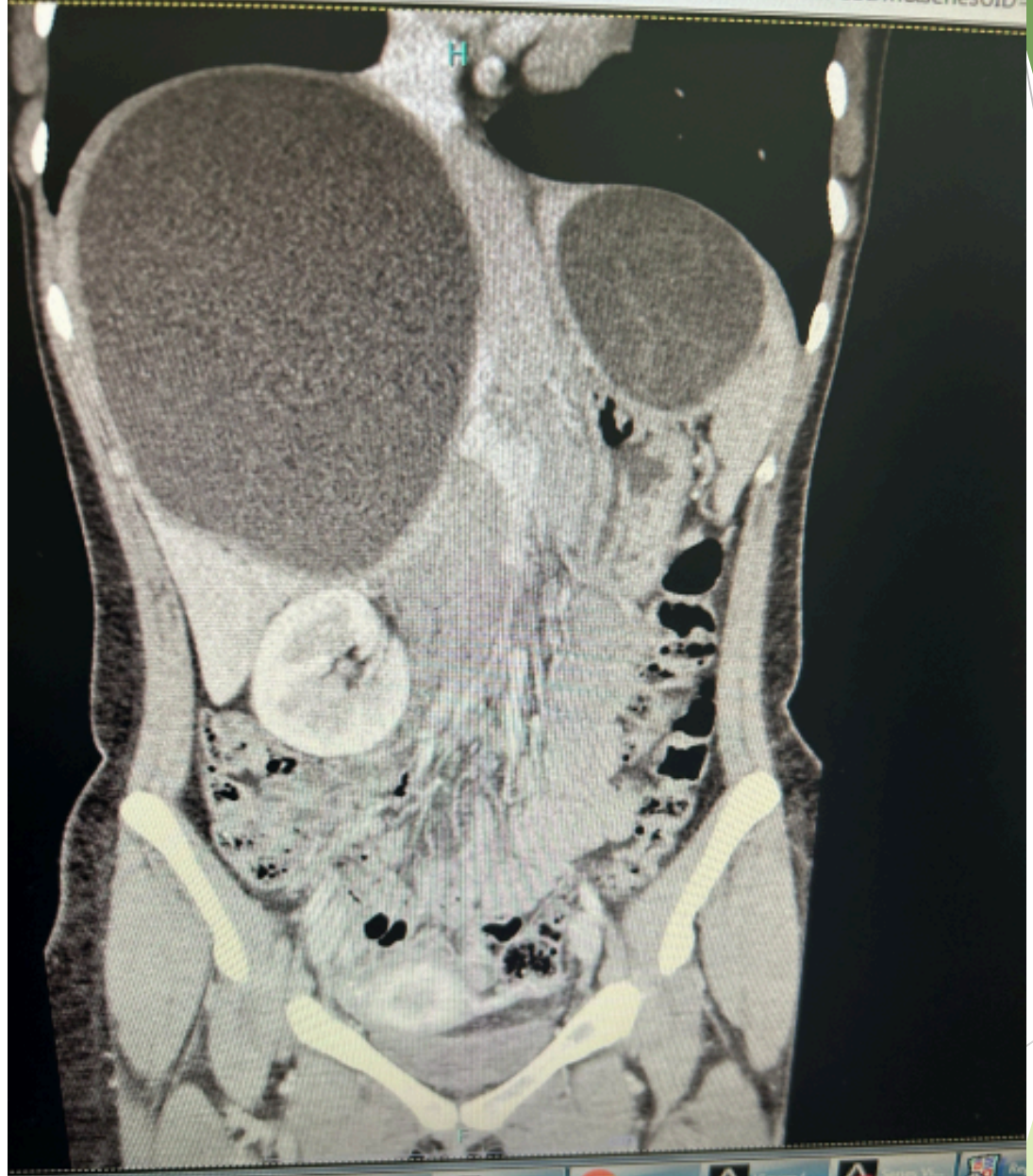196
512 x 512

A Tala Waasef Turkey Aldwari
10647037
ART
2026-03-16 08:45:25

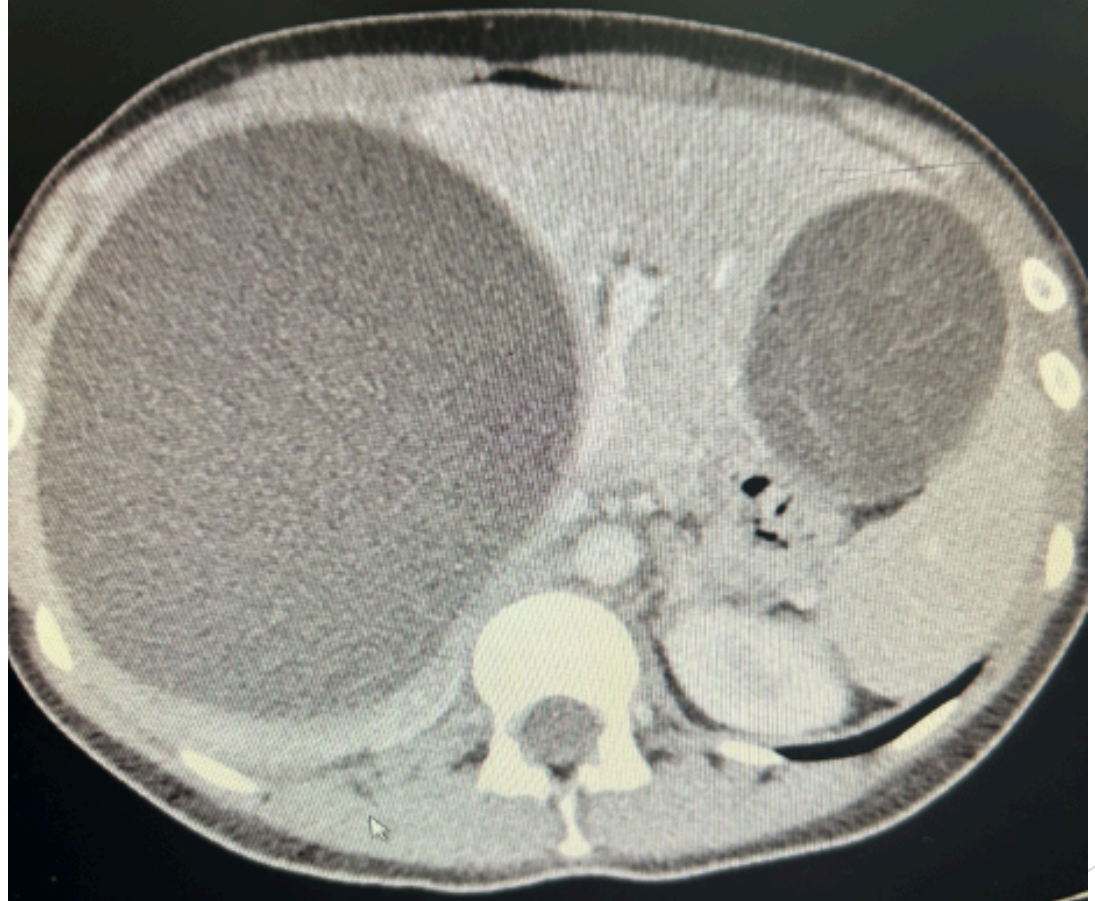


ats.specialty-hospital.com






A



P



DIAGNOSIS- IMMUNOLOGY

- ▶ IHA.
- ▶ CFT.
- ▶ LA.
- ▶ IEF.
- ▶ CIE.
- ▶ ELISA.

Treatment of Hydatid Disease

Medical

Ideal: not yet completely efficient

Radiological
Selective
PAIRS

SURGICAL

Attractive
Laparoscopic

Radical
conventional

Medical treatment

- ▶ Antimony, Arsenic, Thymol derivatives, Iodides & Mercury.
- ▶ Mebendazole.
- ▶ **Albendazole**: 10-14mg/kg/day, three 28 courses separated by 2 weeks rest.
- ▶ **Praziquantel**.

Effect of Albendazole

- Can be used preop: for 8 weeks kills the parasite in 90%.
- Adjuvant after surgery.
- Preop +adjuvant
- As scolicidal
- Decreases the recurrence after surgery from 18% to 5%.

Albendazole Tx of hydatid diasease

author	yr.	no.	duration (mo)	cure	'success'
Nahmias	'94	68	4	41	57
Horton	89	253	1-12	29	
Davis	89	46	1-3	--	39
DeRosa	90	46	3	9	--
Todorov	92	35	4	--	43

success = marked improvement

Long-term evaluation of albendazole Tx of hydatid disease (Italy)

Franchi, CID, 1999;29:304-9

- ▶ n = 323 patients
- ▶ Tx: 440 liver, 57 abdom., 143 lung cysts
- ▶ albendazole 10 mg/kg/d x 3-6 mo.
- ▶ assessment: degeneration by CXR, U/S, CT, MRI q 6-12 mo.
- ▶ f/u: 2 yrs. (1-14 yrs)

Long-term evaluation of albendazole Tx of hydatid disease: results

(Franchi)

- Post Tx degeneration in:
 - 82% liver, 67%, abd. 88% lung
- long-term: + 22%
- 25% relapsed
- 78% relapses occurred < 2 yrs

CID 1999;29:304-9

Tx of hydatid disease (liver) with albendazole + praziquantel vs. alb. alone

- ▶ RT pre-op in Spain, x 1 month (no controls)
Cobo et al. Trop Med Int H 1998;3:462-66
- ▶ groups: I (12) albendazole 10 mg/kg/d
 - II (14) albendazole 10 mg/kg/d
 - III (21) alb. (10 mg/kg) + praz. 25 mg/kg
- ▶ viability: supravital staining, movements, flame cell activity

Table 2. Cyst response to Albendazol (Adrien, MD)
 World J. Surg. 25(1) 2001.

Data source	Evaluateable cysts	Cure	Improved	No change	Worse
European data	435	160 (35.2%)	187 (41%)	102 (22.4%)	6 (1.3%)
Publication	2912	663 (22.8%)	1418 (48.7%)	831 (28.5%)	
Total	3347	823 (24.6%)	1605 (48%)	919	

Table 1. Clinical response to Albendazol (Adrien G. Saimot MD)

World J.Surg.25(1)2001

Data source	No of patients	Cured	Improved	No change	Worse
European data	253	72(28.5%)	129(51%)	46(18%)	6(2.4%)
publication	1116	372(33.5%)	469(42%)	275(24.6%)	
Total	1369	444(32.4%)	598(43.7%)	327(23.9%)	

Techniques used for PAIR

1. Percutaneous puncture:

- 18 g Seldinger needle
- aspirate 25-35% est. volume
- 15-25% NaCl = ~10% aspirated vol.
injected. (kill in 5 min,)
- wait (10 min.) for pericyst separation
- reaspirate

Techniques used for PAIR

2. Catheterization:

- as above
- 6F catheter inserted
- wash out with hypertonic saline
- drain x 24 hrs. (<10 cc/24 hr = no bile connection)
- cystogram
- 95% alcohol (25-35% vol.)
- reaspirate & withdraw catheter

PAIR vs Laparoscopic approach

- Results of meta-analysis-2018 comparing
- Complications
- Mortalities
- Cure rates
- Recurrence rate:lap is superior

Percutaneous (PAIR) Tx of liver cysts

Akhan, Eur J Radiol 1999;32:76-85

1. Hydatid liver disease: 14 studies

- 13 studies (641 cysts) 1 Chinese study (996 cysts)
- 1,637 cysts in 1,000 pts
- instillation of alcohol or hypertonic saline
- f/u 1-3 years (1 yr)

1. Liver hydatid disease: results

- cure or significant change: 90-100%
- recurrence 0 - 4%
- complications: ~ 10%
 - biliary fistula: ~ 5-10% (7 studies)
 - fever, urticaria: 10-20%
 - cyst cavity infection: ~ 3%
 - death: 0.1 - 0.2%

PAIR: In a literature review

Table3: review of recent experience(1994-1998).

(Iskende Sayek)

Finding	Surgically treated	Per cutaneously drained
Total	46(37%)	79(63%)
Solitary cysts	29	55
Types	III-V:34(74%)	I-III:65(82%)
Complications:	2	11
Minor		
Complications:	6	9
Major		
Cavity infection	5	8

Table 3..... continue

Finding	Surgically treated	Per cutaneously drained
Biliary drainage	1	1
Wound infection	2	-
Patients requiring surgery	-	2

Laparoscopic

- ▶ Minimal invasive.
- ▶ Stands in the midway between PAIR&conventional surgery.
- ▶ Risk of spillage as open.
- ▶ Radicality as open.
- ▶ Gold standard procedure.

Types of surgery

- ▶ Marsupialization.
- ▶ Cystectomy plus.
 - Pericystectomy- partial
 - Pericystectomy- subtotal.
 - Pericystectomy- Total.
- ▶ Resection: segmental, lobar, total+transplantation.

Remaining cavity

- ▶ Primary closure.
- ▶ Simple drainage.
- ▶ Capitonage.
- ▶ Introflexion.
- ▶ **Omentoplasty.**

Cysto-Biliary communication(5-25%)

- 1.Simple - fistulization.
2. Frank rupture.

Ahmet et al in a study of 304 cases concluded that:”For management of hydatid cyst of the liver . Capitonnage , omentoplasty, cyst excision,cystenterostomy are all superior to tube drainage.”

Source: *Arch.Surg.vol 134 Feb.1999.*

N.B:However 35/122 patients with tube drainage had infected cysts.

Cysto-Biliary Communication: 171 cases Milicevic

▶ Suture	115	67.25%
▶ Suture+T-tube	15	8.77%
▶ T tube only	16	9.34%
▶ Roux-en-y jej.	4	2.34%
▶ Intracavitary reconstruction	2	1.17%
▶ Nothing	19	11.11%

Post-operative complications

▶ Wound infection	111	13.5%
▶ Chest problems	42	5.14%
▶ Subphrenic abscess	43	5.26%
▶ Biliary leakage	40	4.89%
▶ Liver abscess	20	2.45%
▶ Total series: 818 Milicevic		

Results of surgical treatment

- ▶ Def.of recurrence: controversy.
- ▶ Amir Jahed 1975: 0.9%
- ▶ Dugalic 1982: 1.7%
- ▶ Pitt 1986: 10%
- ▶ Magistrelli 1991: 10.8%
- ▶ Little 1988 : 22%

Table 4. Postoperative morbidity & mortality in a series of 298 patients. (Anaceleto Cirenei, MD, Innocenzo Bertoldi MD)

Treatment	No.	Morbidity	Mortality
Conservative methods	134	12(12.6%)*	8(5.9%)**
Marsupialization	20	8(40%)	6(30%)
Partial cystopericystectomy	114	9(7.9%)	2(1.7%)
Resection of pericyst & subtotal pericystectomy	85	6(7.1%)	2(2.3%)
By peeling the pericystium	29	3(10.3%)	--

Table4. Continue
World J.Surg25(1) 2001.

Treatment	No	Morbidity	Mortality
Radical methods	164	9(5.5%)	3(1.8%)
Total pericystectomy	132	5(3.7%)	3(2.2%)
Liver resection	32	4(12.5%)	--
Total	298	26(8.7%)	11(3.6%)

P* < 0.05,
P** = NS.

Table 5. Surgical procedures performed on hydatid cyst of the liver with a large biliocystic fistula.

(Abeljelil Zaouche et al)

World J.Surg 25 (1)2001.

Procedure	No
Radical treatment	24(9.8%)
<i>Left lobectomy</i>	7
<i>Pericystectomy</i>	17
Conservative treatment	220(90.2%)
<i>Internal transfistulary drainage</i>	52
<i>Deroofing procedure</i>	140

Table 5.....continue

Procedure	No
<i>Respected fistula</i>	20
External drainage	10
<i>External drainage +omentoplasty</i>	8
<i>External drainage +capitonnage</i>	2
<i>Sutured fistula</i>	93
<i>External drainage</i>	49

Table 5. continue

Procedure	No
<i>External drainage+omentoplasty</i>	28
<i>External drainage +capitonnage</i>	16
Direct fistulization	27
Transcholedochal evacuation	28

Personal experience(1993-2000)

- ▶ Number of cases: 82
- ▶ males: 36(43.9%), Females:46(56.1%).
- ▶ **Anatomical distribution:**
- ▶ RT lobe: 35 (42.6%).
- ▶ LT lobe: 23 (28%).
- ▶ Both lobes: 22 (26.8%).
- ▶ Central : 2 (2.4%).
- ▶ Involvement of other organs: (12.1%).
- ▶ Associated pathology: Pregnancy(2), Cirrhosis(2).

Technique

Standard surgical principles were applied:

- ▶ Complete isolation of the operative field.
- ▶ Two powerful suctions.
- ▶ Aspiration- Suction(after stopping breathing)infusion-Reaspiration.
- ▶ Opening of the cyst, evacuation & Irrigation-suction. (scolicidal agent).
- ▶ Unfoldindg of the pericyst.
- ▶ Mobbing of the cavity.
- ▶ Dealing with cystobiliary communication if present.
- ▶ *Abdominal approach was exclusively used.Scolicidal agent: Sterimide0.5%- 1%.*

Surgical procedures Adopted

- ▶ The procedure of choice was: Cystectomy+(partial/subtotal) pericystectomy+ Drainage of the remaining cavity: 69 cases(84.1%).
- ▶ Other procedure, Capitonage, Omentoplasty, Hepatectomy, Exploration of CBD, Transduodenal sphincteroplasty&total pericystectomy.
- ▶ Cholecystectomy performed in 22 patients(26.8%).

Management of cysto-Biliary Communication: 32/82 (39%)

- ▶ **Simple fistula 22/32:** Respected+drainage, Cannulation with small tubes, Draining the cavity, direct suturing of the fistula.
- ▶ **Frank Rupture 10/32:** Daughter cyst in CBD 8/10, Preoperative EPST+intraoperative trans duodenal sphincteroplasty+ T-tube drainage of CBD. 5/10 , Internal transfistulary drainage of CBD+Postoperative EPST. 3/10.
- ▶ **Fistula > 5mm -** Internal transfistulary drainage. 2/10 . **Noticeably:** In the same patient- Multiple cysts tend to have communication with the biliary tree, regardless to their number or size.

Results

- ▶ **Operative Mortality:**
0/82
 - ▶ **Mortality rate:** 2/82
(2.4%) multiple infected cyst(1), biliary peritonitis(1)
 - ▶ **Infection of the remaining 8 cavity:**
7/82(8.5%)
 - ▶ **Persistent bile leakage through the drain:**
3/82(3.6%)
 - ▶ **Encysted bile collection:** 1/82
 - ▶ **Simple liver cyst:** 1/82
 - ▶ **Recurrence:**
4/82(4.8%)
hospital stay: 9 days.
- Average

Follow-up

- ▶ **Clinically : OPD.**
- ▶ **Radiological : U/S, CT Scan.**
- ▶ **Serological: ELISA, IHA.**

CONCLUSION

- ▶ Treatment of liver hydatid cyst is not as simple as just draining a cysts.
- ▶ Calcified cysts(partially/Totally)should be approached very carefully.
- ▶ Central cysts(portahepatis) with biliary involvement more difficult to deal with.
- ▶ With more experience in liver & biliary surgery it's easier to deal with complicated hydatid cyst.
- ▶ Treatment of Hydatid cyst of the liver should be a multidisciplinary approach. (surgeon, gastroenterologist, radiologist, parasitologist, immunologist)