

Anesthesia mini-OSCE

First month- second semester



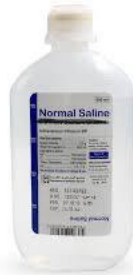2025-2026

First question



How do you use this?
Explain all the steps

Second question



- which one is hypotonic? D5W
- which one has 0.9 NaCl? Normal saline
- which one is balanced? Ringer lactate
- which one is crystalloid? All

Third question

2 pic for 2 kids with blue cannulas (1: 6-year old, eyes are open and cannula is on the forearm, 2: 3-year old, eyes are closed and cannula is on the arm):

- which one receives a higher flow?
(1):The 6-year-old child

- explain your answer.

Bc he has larger veins with larger diameters, and larger diameter is associated with a higher flow

Fourth question

A 48-year-old male underwent right lung surgery (forgot what it exactly was). Shortly after the surgery, he developed sudden severe shortness of breath and sharp right-sided chest pain. HR= 122 bpm and BP of 85/— mmHg(hypotensive). On physical examination, there were decreased breath sounds over the right lung. The nurse mentioned that the right chest tube was not oscillating and that there was no blood drained.

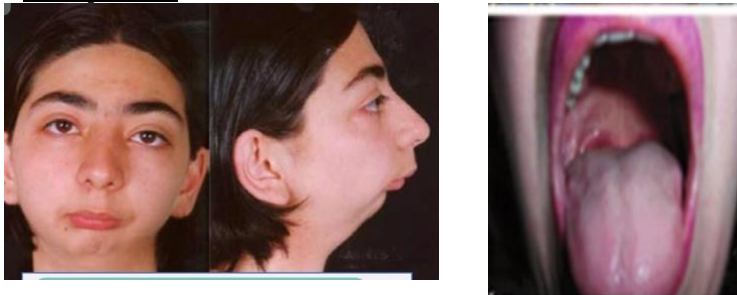
- type of shock
obstructive shock

- the cause
Pneumothorax

- what would be your first management
Needle decompression

- mention one investigation you would ask for
chest X-ray

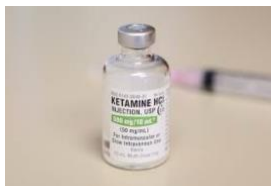Fifth question



This patient came to your anesthesia clinic for pre op evaluation

- mention one reason for difficult intubation
micrognathia (small chin)
- what is the mallampati class in the second pic
3
- what does the letter O indicate in LEMON method
obstruction (by an abscess, nodule...)
- how much is the distance between thyroid notch and mandible to indicate difficult intubation
less than 6 cm

Sixth question



- what is the family of the drug
Phencyclidines
- mention its effects on consciousness
causes dissociative amnesia (pt appears to be awake with open eyes but he is not)
- mention 1 relative contraindication for its use
space occupying lesions in brain

Seventh question



(1).



(2).



(3).



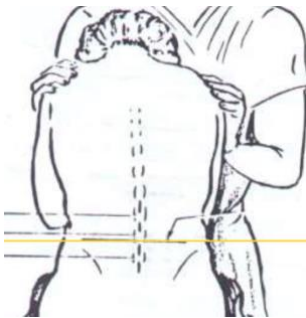
(4)

- what are the organic gases among these
1+2+4
- which one reacts with the absorber to give CO
1

- which one is best for an intracranial surgery
2

- which one should be heated (not sure)
1

Eighth question



- what is the type of anesthesia used here
spinal anesthesia

- on which level of spinal cord does the yellow line pass
L4/L5

- which landmark do we look for here at the yellow line level
iliac crest

Ninth question

Chain of survival pic (ما عليها ولا كتابة)

- what is this and define it


the chain of survival, a sequence of events that should be done to minimise the chances of developing cardiac arrest and enhance the survival if it occurred

- what are the numbers of the rings that show evidence based steps. And what are they
2 and 3 (2: perform CPR to buy time, 3: early defibrillation to restart the heart)

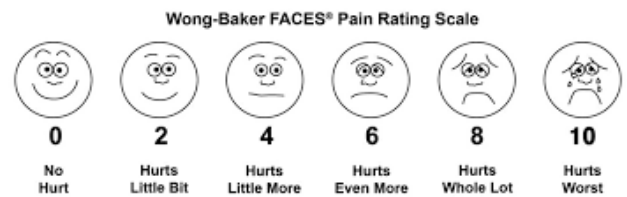- ring 3 is used in which types of cardiac arrests
cardiac arrest with shockable rhythm (v fib or pulseless v tach)

- ناسية اذا في فرع رابع

10th question



(1)

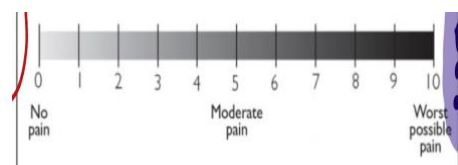

©1993 Wong-Baker FACES Foundation. www.WongBakerFACES.org
Used with permission. Originally published in Whalley & Wong's Nursing Care of Infants and Children. ©Elsevier Inc.

(2)



(3).



(4)

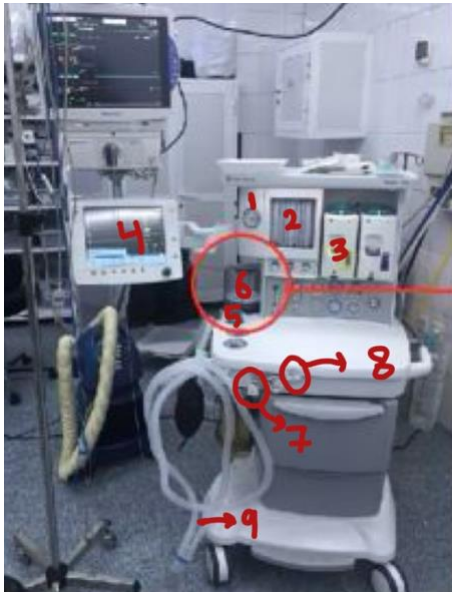
- which one is used for somatic pain assessment in adults
1+3+4

- neuropathic pain assessment in adults
1+3+4

- used in children
2+4

- in unconscious pts
None

11th question



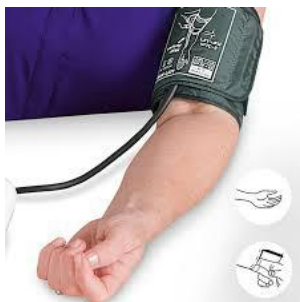- Where do you attach mapelson system
7

- what gives a high fresh gas flow
8

- what monitors pressure in airways and tubing system
1

- what gives the pt a positive ventilation pressure
6

12th question



- what is this
BP cuff for non invasive BP monitoring

- what would happen if it was of a smaller size than what it should be
falsely high BP

- mention one invasive device that has the same function arterial line

- ناسية اذا في فرع رابع

13th question

Pic of a 6 year old crying baby: this child is planned for a hernial repair surgery and IV access was done:

- mention 2 drugs that can reduce his anxiety
IV midazolam, IM ketamine

- mention 1 way to reduce his pain post op
Caudal block

- proper size of ETT
5mm (if cuffed)

- mention the drug used for induction of anesthesia in this pt
IV propofol (since he has an IV access)

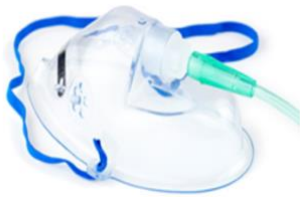14th question

Pic of asystole/fine v fib (flat line), you are the team leader and your team checked his airway, attached him to the monitor, did an IV access and prepared his meds and started chest compressions:

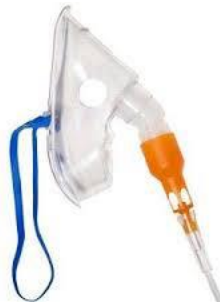- What is the first order you give when you arrive
Complete chest compressions and give IV adrenaline

- What are the meds they prepared
-adrenaline

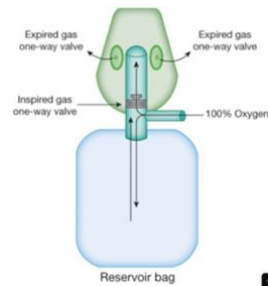
15th question



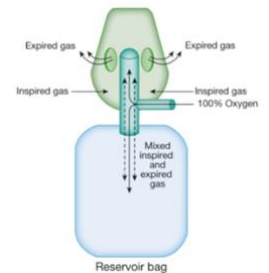
(1).



(2).



(3).



(4).

- which one has room air entrapment
Venturi (not sure) (2)

- which one is used to deliver fixed FiO2
Venturi (2)

- one with the highest o2 flow
non rebreather (3)

- which causes eye dryness due to leakage
All

- لا تنسوننا من صالح دعواتكم-